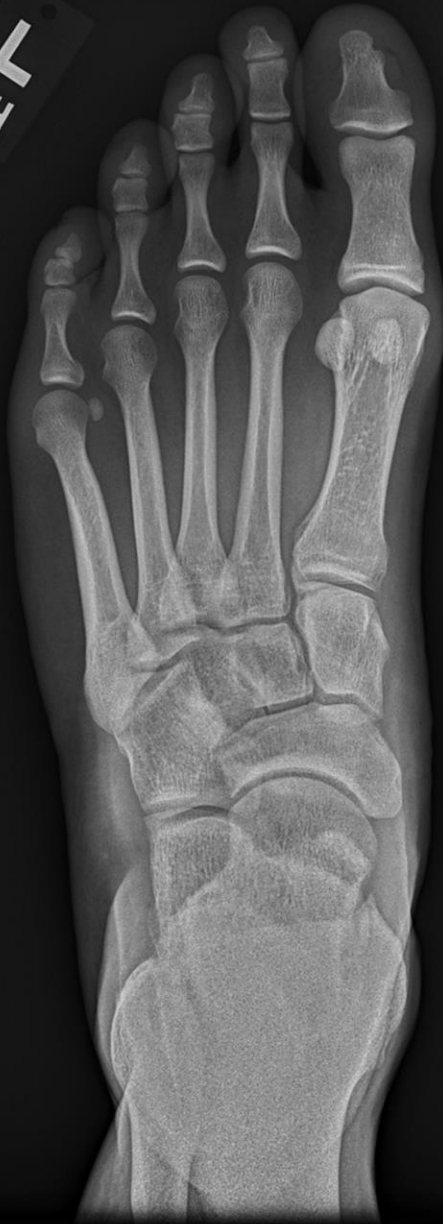



29 year old male American football player with bilateral ankle pain.

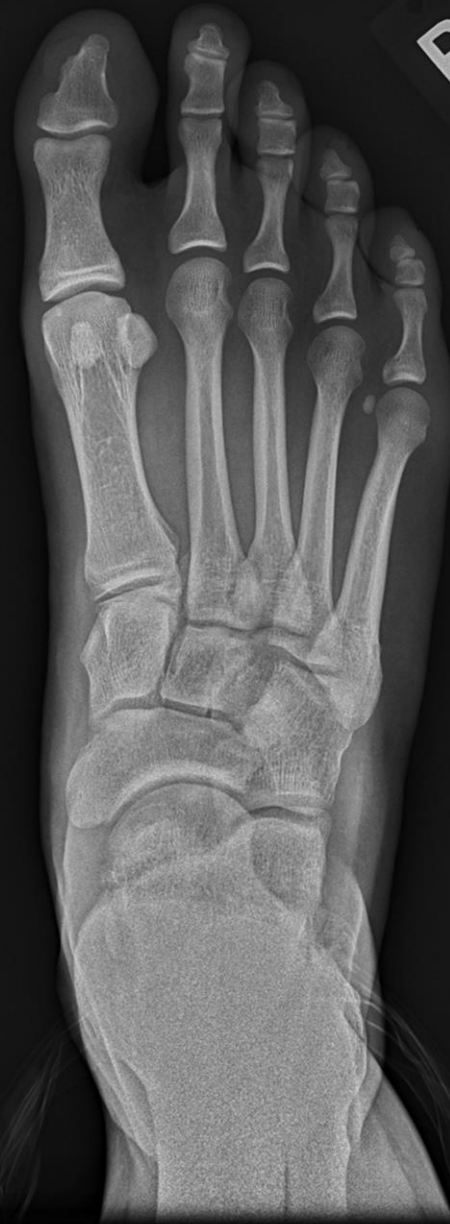WEIGHT BEARING

L
SH



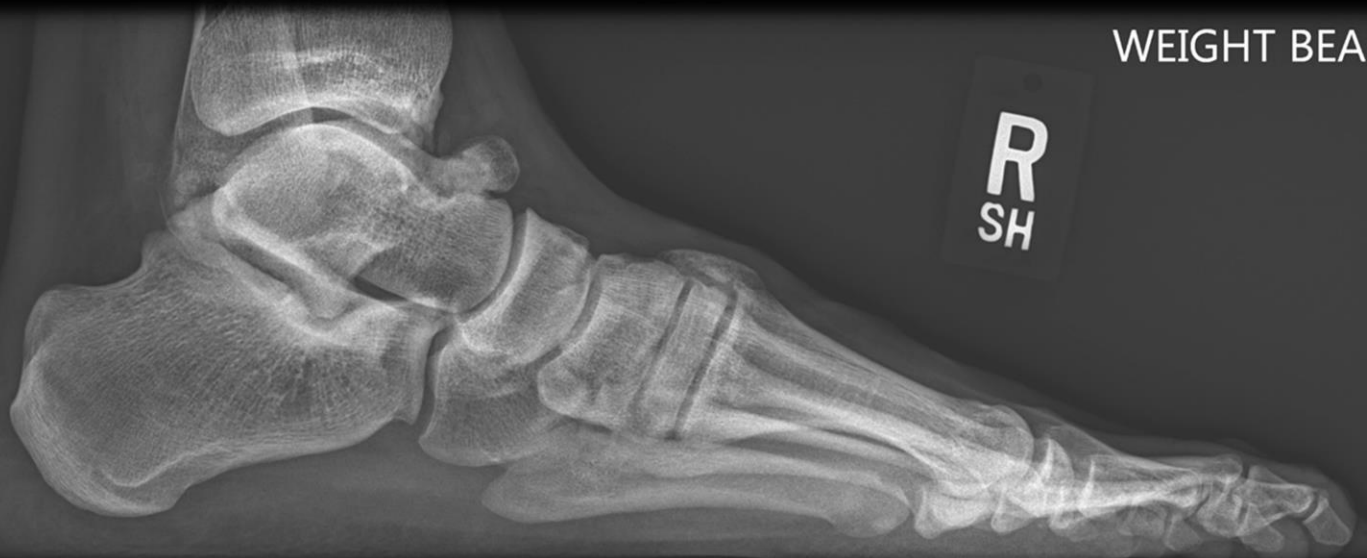WEIGHT BEARING

R
SH



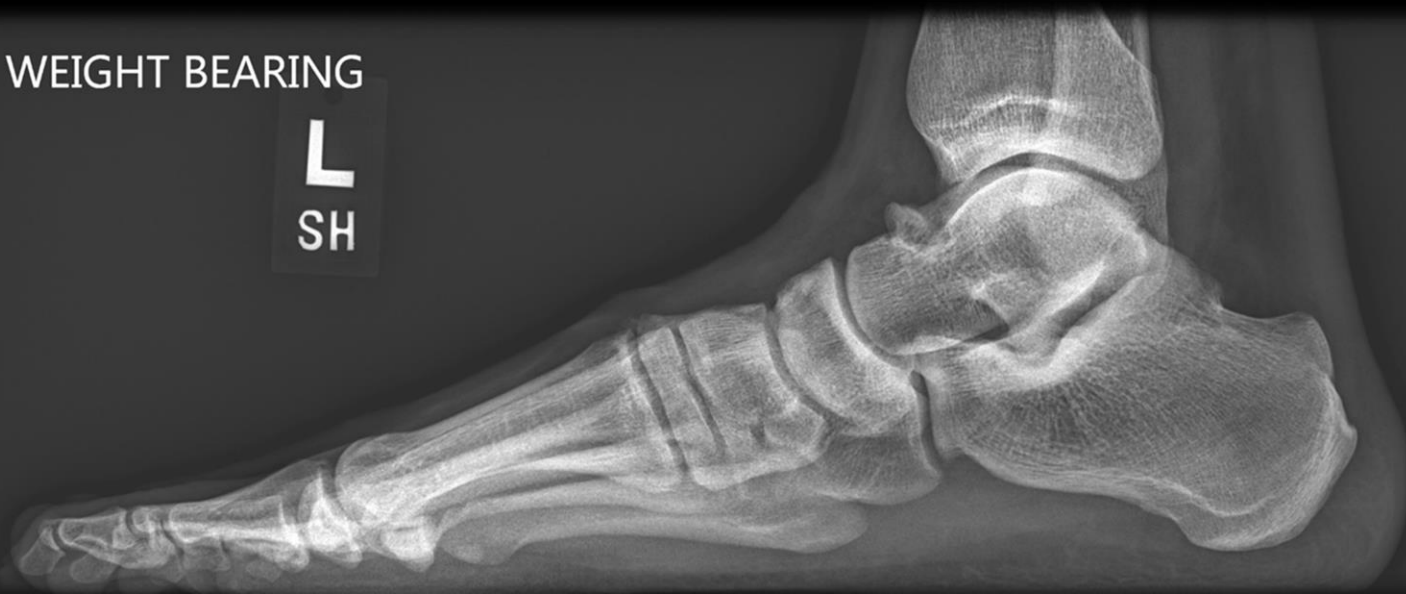WEIGHT BEARING

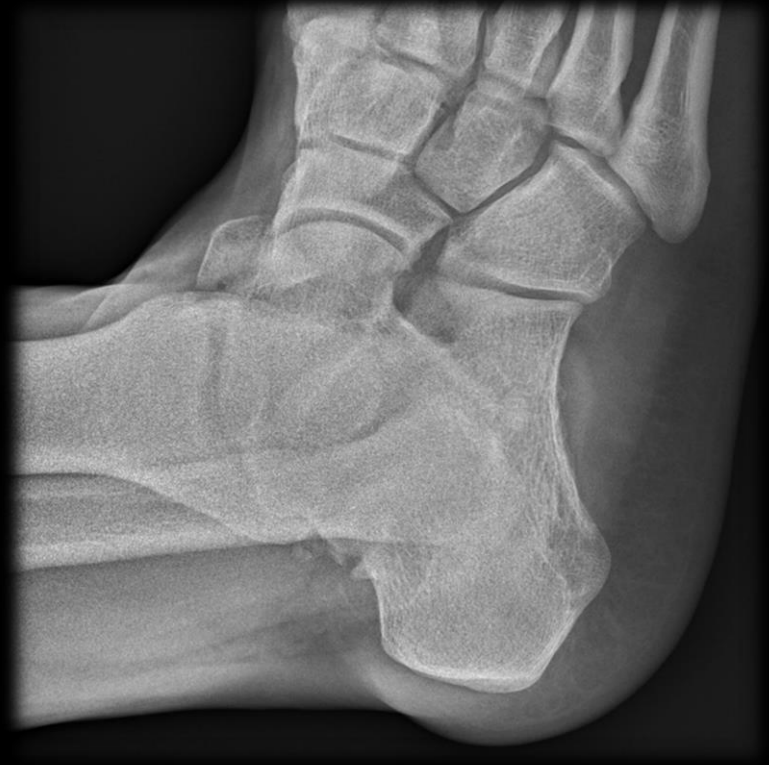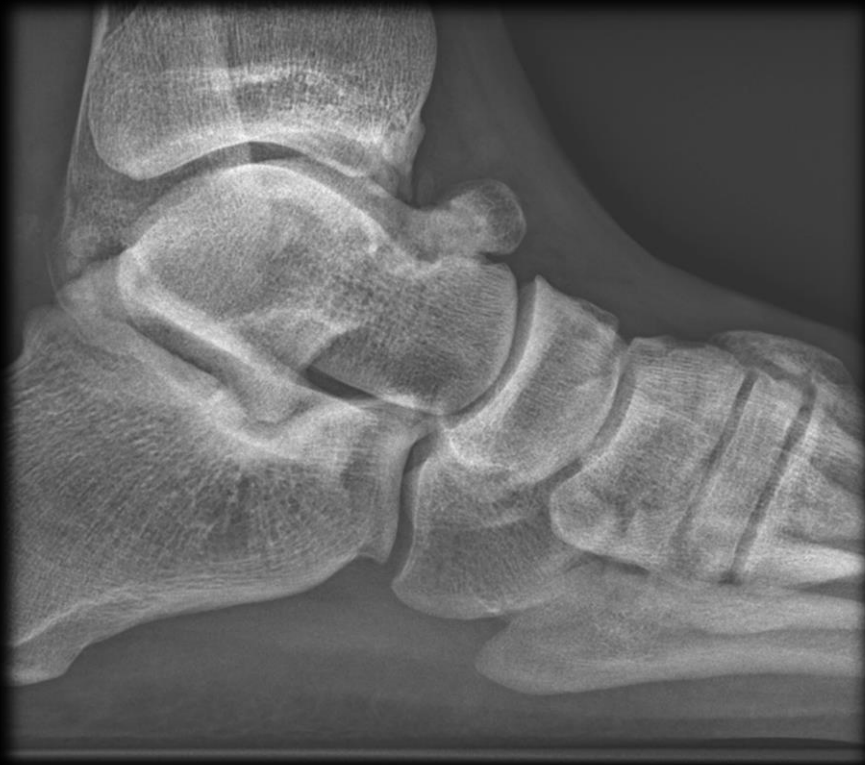R
SH



WEIGHT BEARING

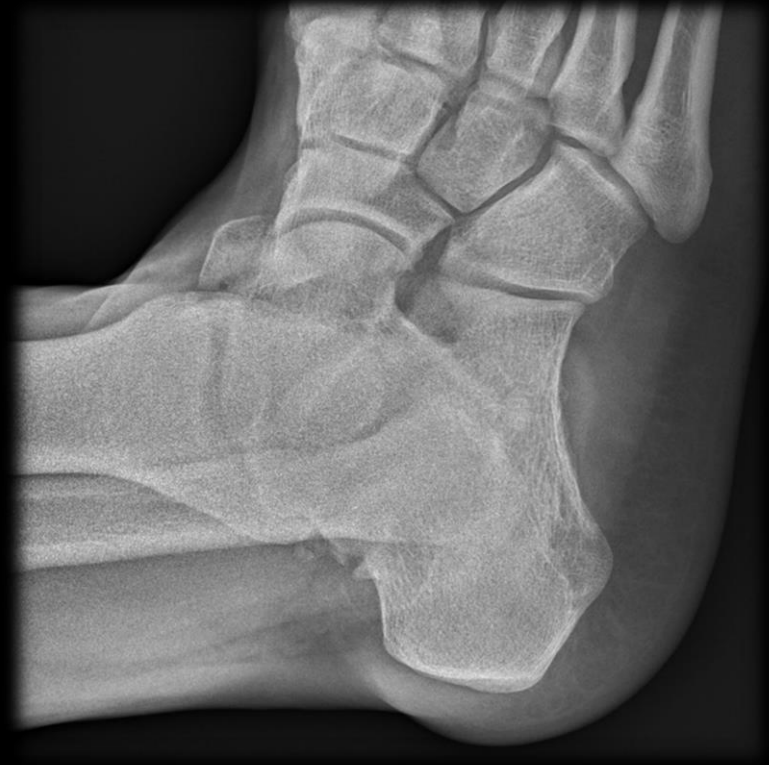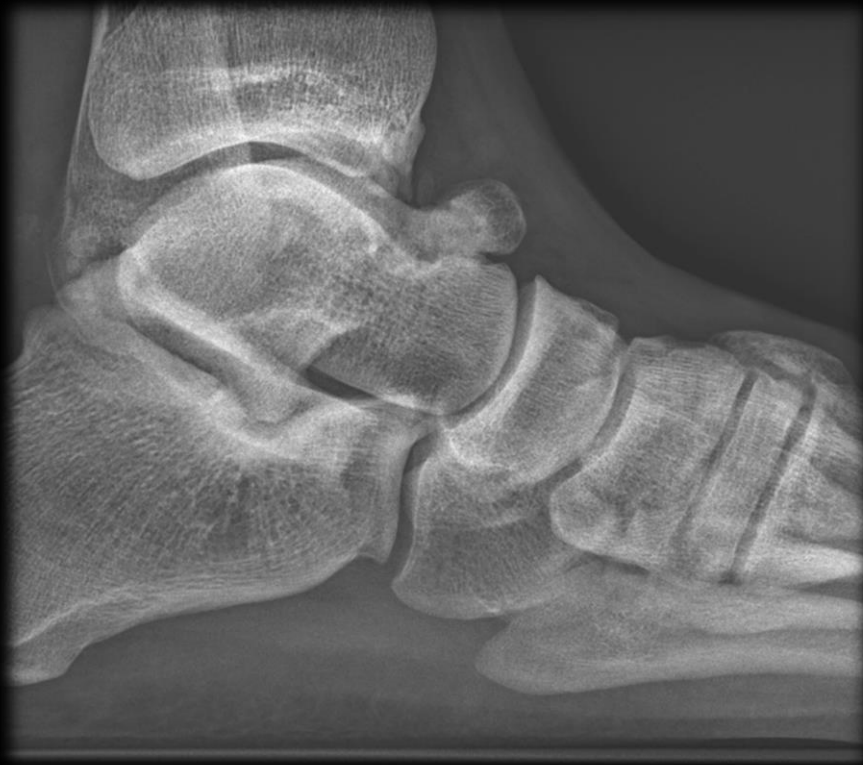L
SH





Right Ankle Coned Down

Anterior Ankle Impingement



Anterior Ankle Impingement

An impingement by any other name:

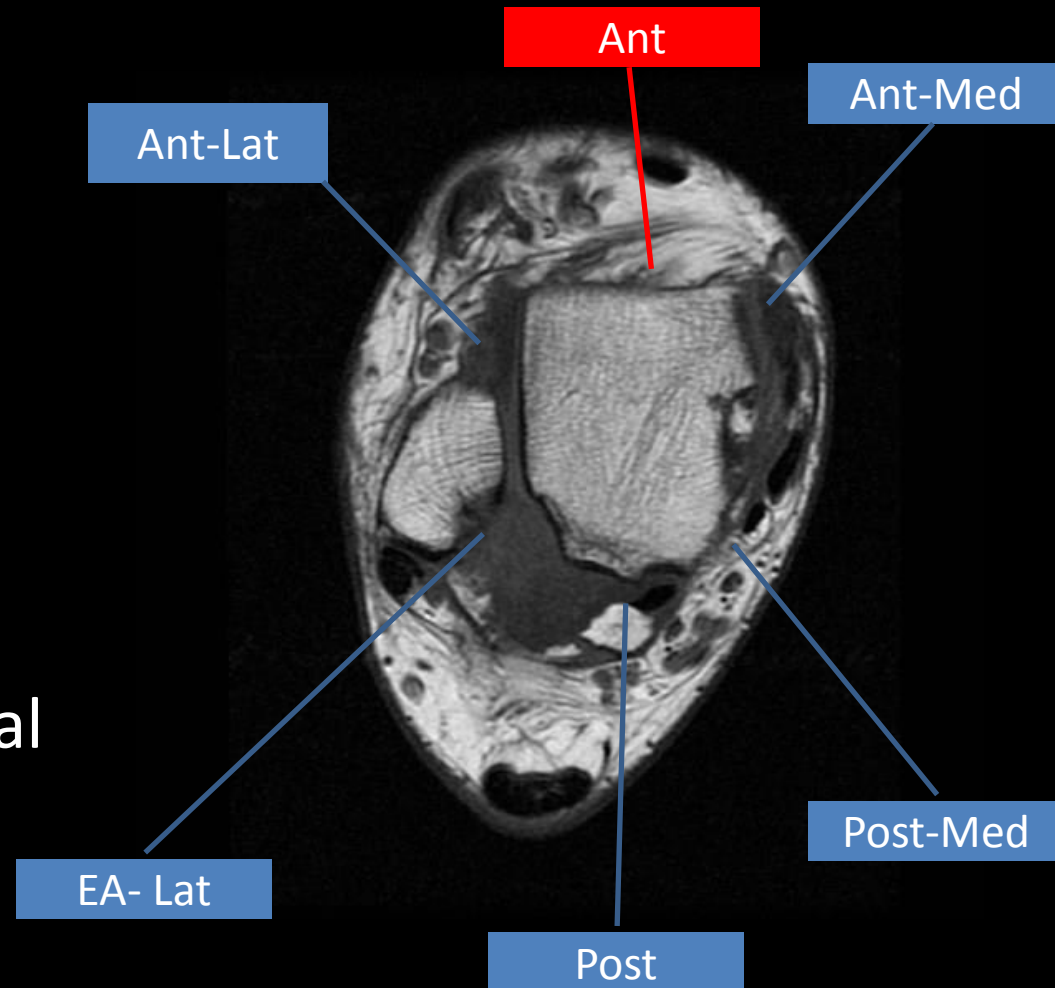
- Athlete's ankle in 1943 by Morris
- Footballer's ankle in 1950 by McMurray
- Impingement exostoses in 1957 by O'Donoghue
- Anterior bony ankle impingement

Occurs in:

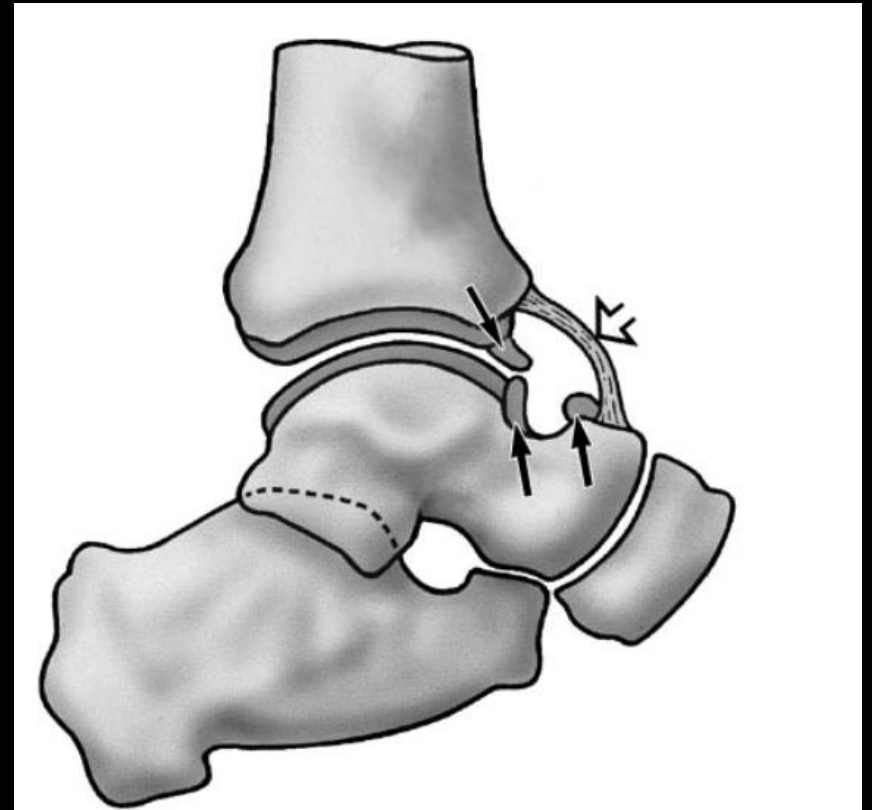
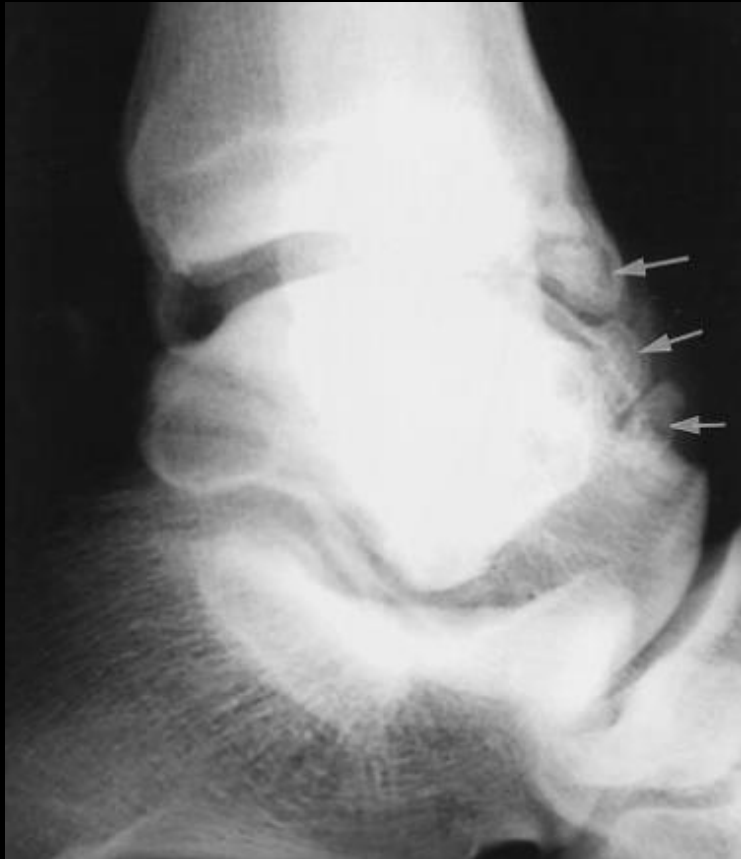- ***Soccer***, football, rugby, runners, ***ballet dancers***, high jumpers and volleyball players, and other sporting activities.

Types of Ankle Impingement

1. Anterolateral
2. Anterior
3. Anteromedial
4. Posteromedial
5. Posterior
6. Extra-Articular Lateral



Anterior Ankle Impingement



Etiology

Proposed mechanisms:

1. Repetitive kicking in plantar flexion has been postulated to lead to traction on the anterior capsule and enthesophyte formation.
2. Alternatively, osteophyte formation may be attributed to joint abnormalities related to hyperdorsiflexion, microtrauma, ankle instability, and recurrent supination.

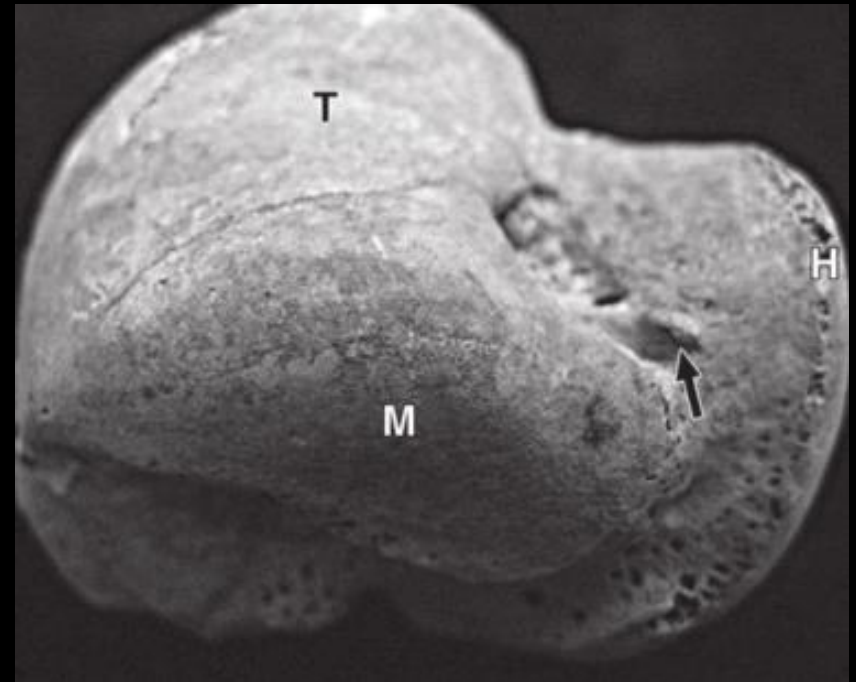
Etiology



Etiology

In a cadaveric study by Hayeri et al. noted that:

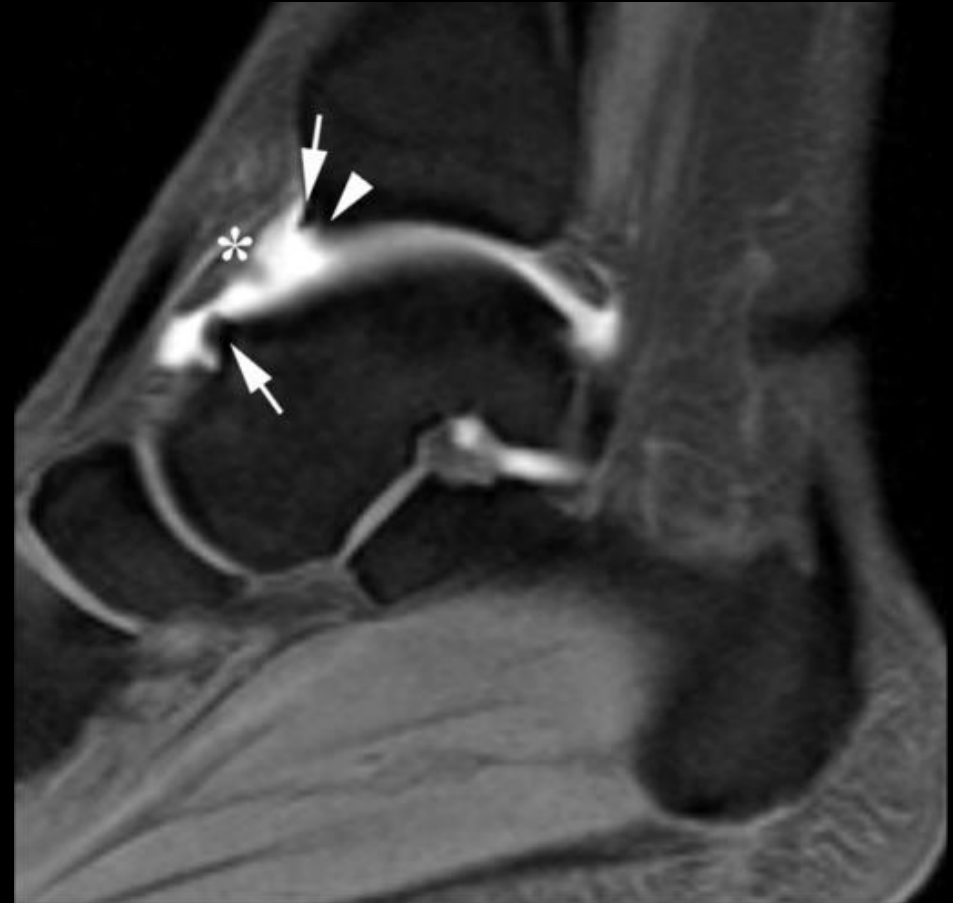- Medially situated anterior talar osseous outgrowths occur intraarticularly
- Lateral talar outgrowths develop extraarticularly



Etiology

In a cadaveric study by Hayeri et al. noted that:

- Medially situated anterior talar osseous outgrowths occur intraarticularly
- Lateral talar outgrowths develop extraarticularly



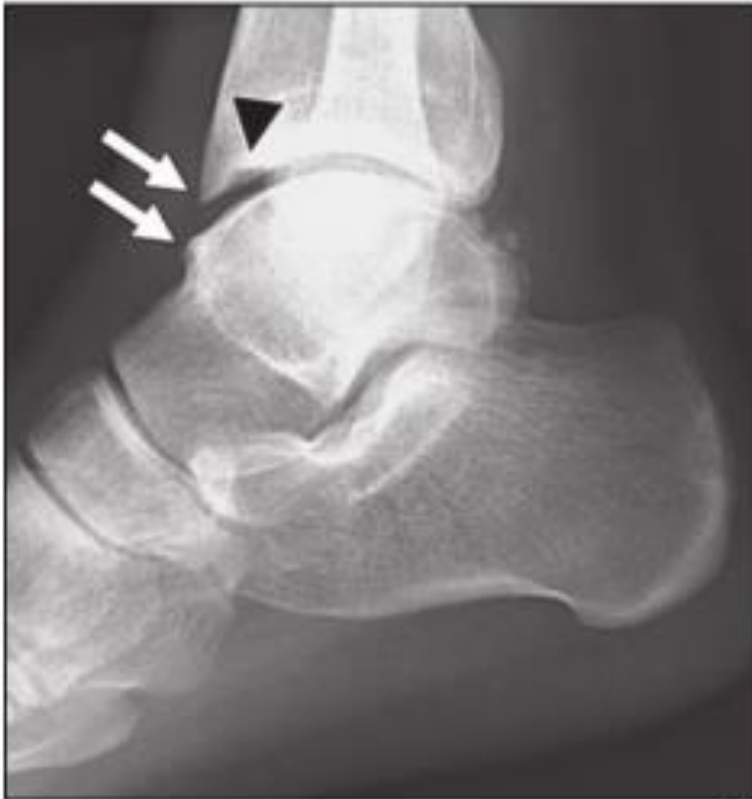Clinical Presentation

Symptoms: Pain in the anterior ankle, worsened with dorsiflexion and weight bearing

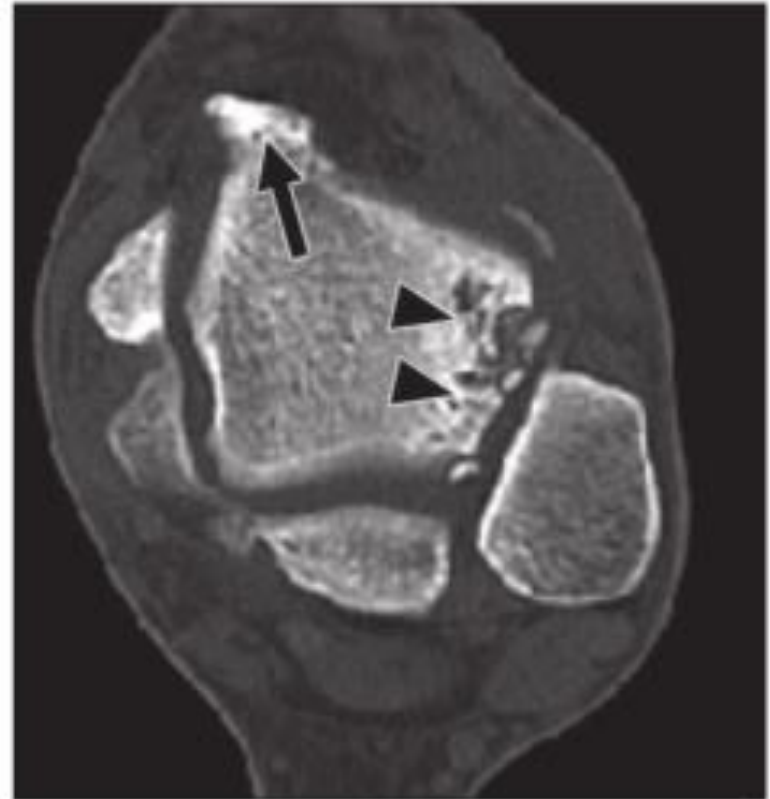
Physical Exam: Palpation of the anteromedial aspect for bony outgrowths and observe for elicitation of pain.

Diagnosis is made by combination of history, physical exam, and radiography, with CT and MRI in cases where the dx remains in doubt.

Imaging Features

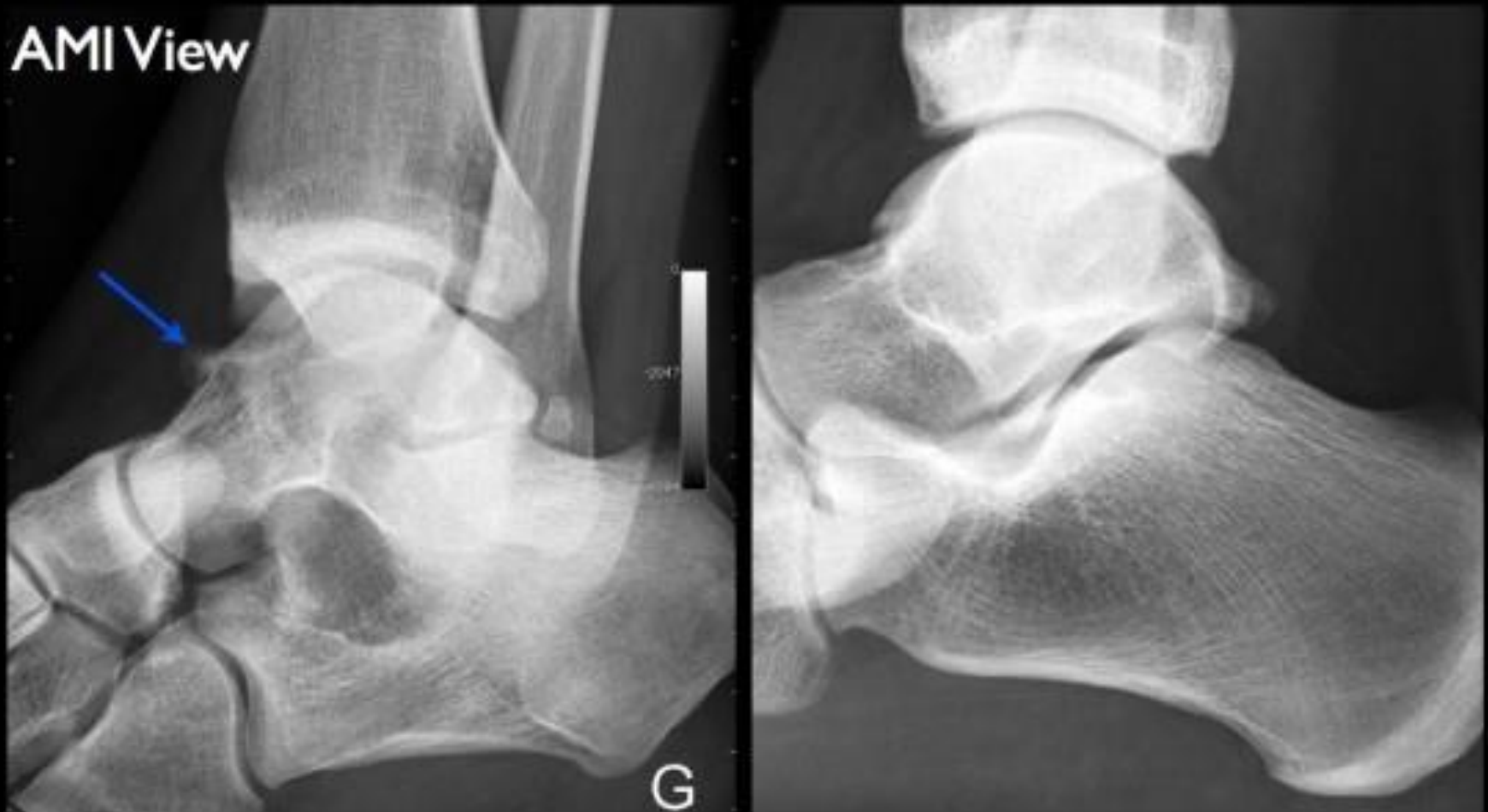

A

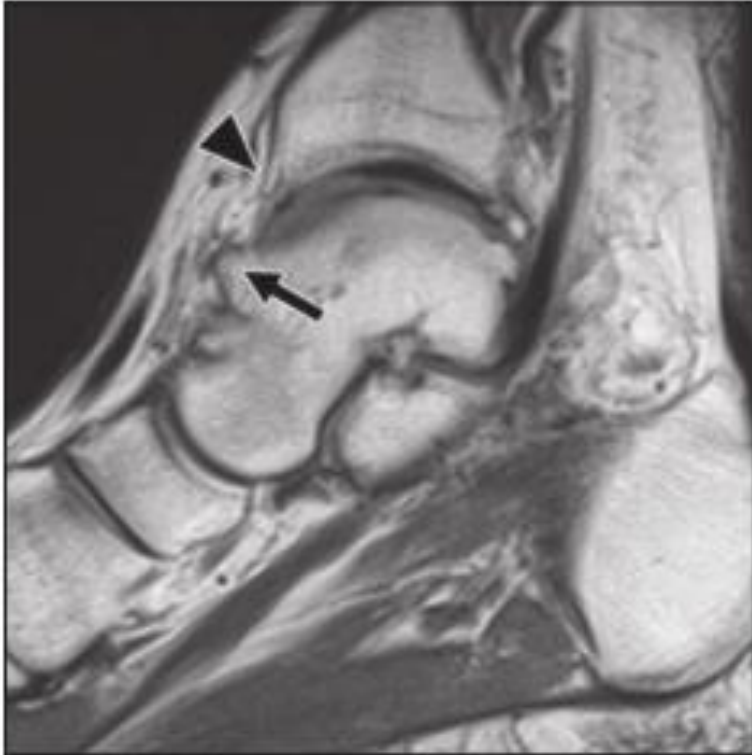


B

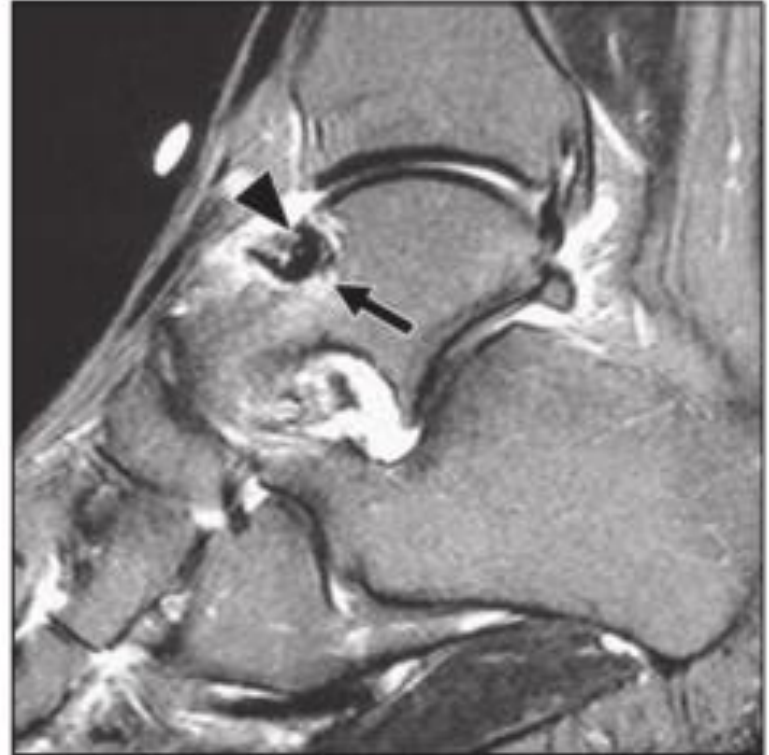Anteromedial Impingement (AMI) View



Imaging Features



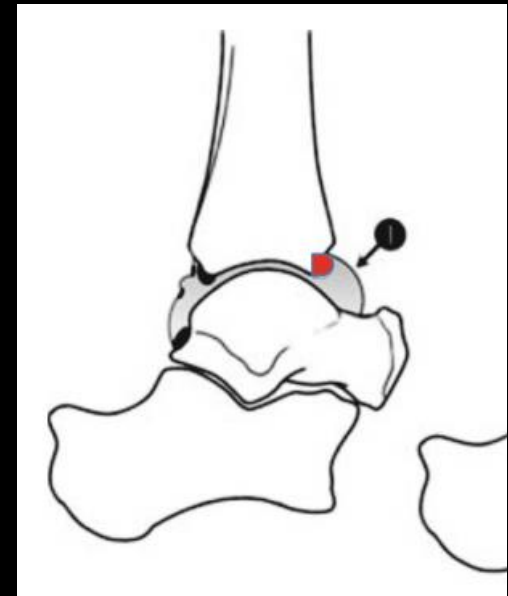
A



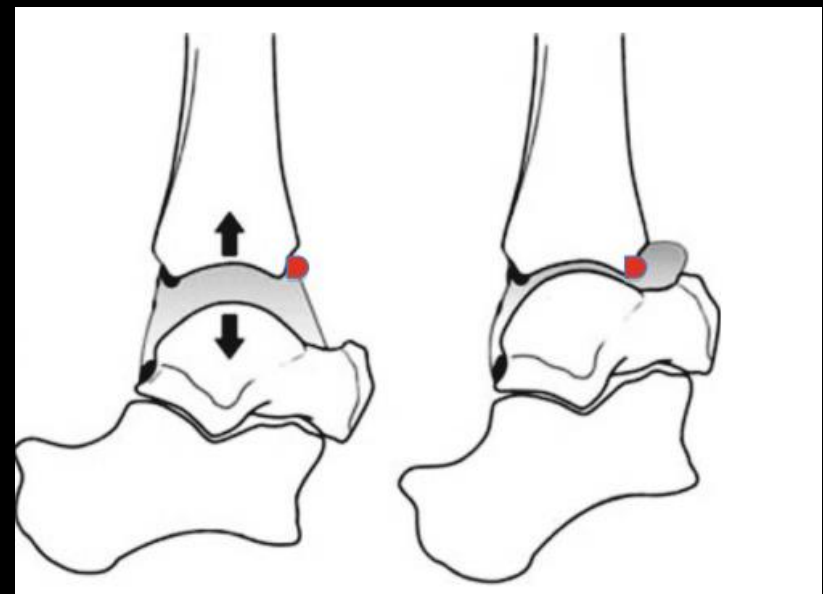
B

Treatment

- **PT, lifestyle modification, NSAIDS**
- Arthroscopic resection, using distraction method or the dorsiflexion method.
- Good to excellent results are reported in 74–100 % in various studies.



Resting Ankle

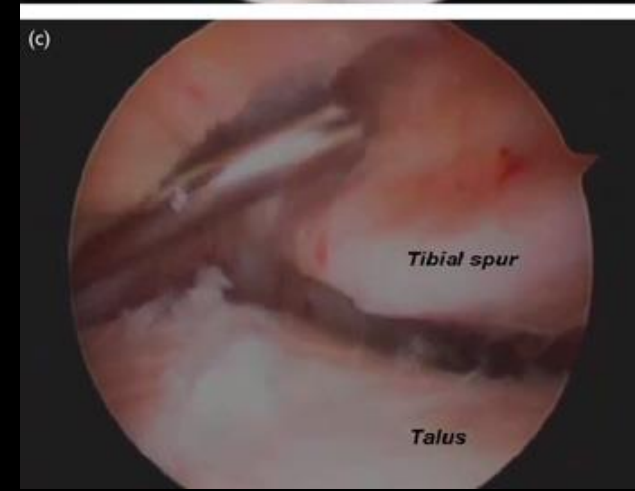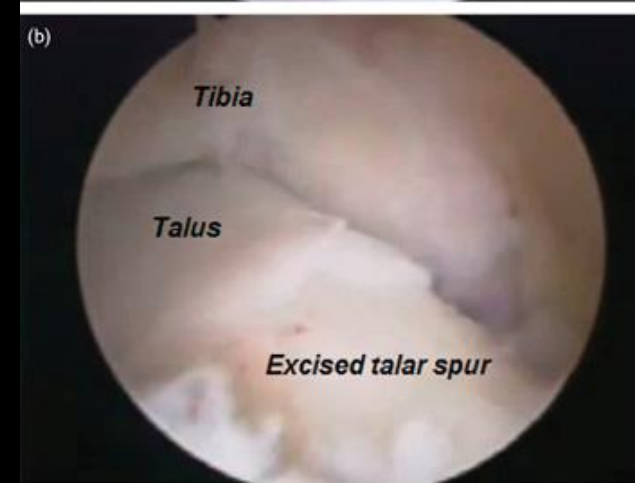

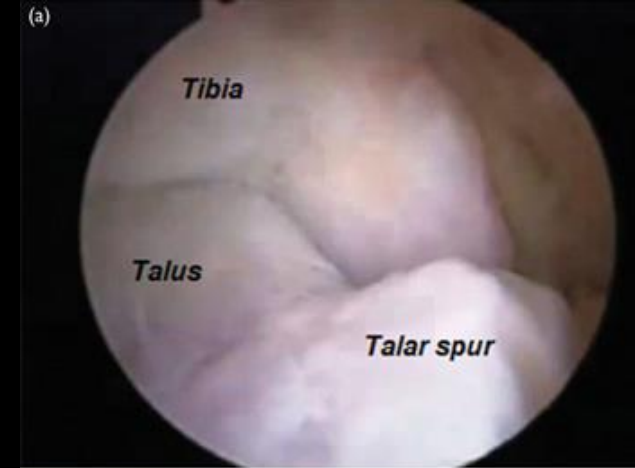
Distraction

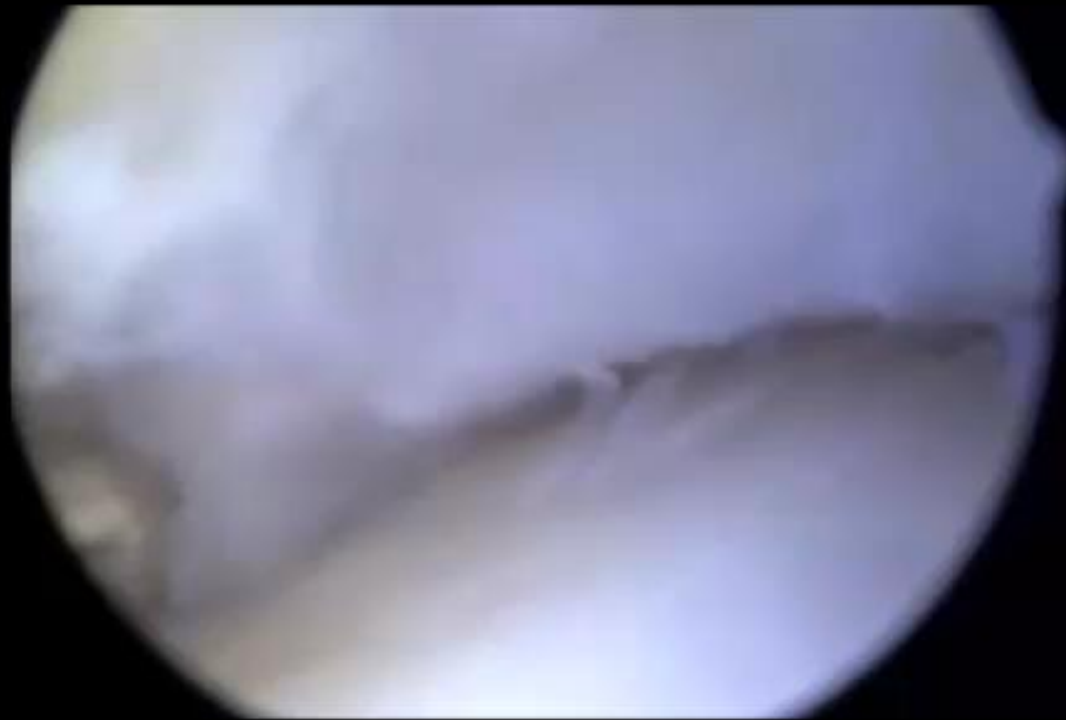Dorsiflexion

Treatment

- **PT, lifestyle modification, NSAIDS**
- Arthroscopic resection, using distraction method or the dorsiflexion method.
- Good to excellent results are reported in 74–100 % in various studies.



Arthroscopy



Summary

- Athlete's ankle, Footballer's ankle, Impingement exostoses, **Anterior bony ankle impingement**
- Intracapsular osteophytes, at the anteromedial aspect of talus and anterior tibia.
- Hyperdorsiflexion, microtrauma, ankle instability, and recurrent supination likely mechanism.
- Patients with radiographic findings often asymptomatic.
- CT and MR typically to exclude other causes of pain.
- Conservative treatment, arthroscopic resection.

References

1. Donovan, A., & Rosenberg, Z. S. (2010). MRI of Ankle and Lateral Hindfoot Impingement Syndromes. *American Journal of Roentgenology*, 195(3), 595-604. doi:10.2214/ajr.09.4199
2. Cerezal, L., Abascal, F., Canga, A., Pereda, T., García-Valtuille, R., Pérez-Carro, L., & Cruz, A. (2003). MR Imaging of Ankle Impingement Syndromes. *American Journal of Roentgenology*, 181(2), 551-559. doi:10.2214/ajr.181.2.1810551
3. Robinson, Philip, and Lawrence M. White. "Soft-Tissue and Osseous Impingement Syndromes of the Ankle: Role of Imaging in Diagnosis and Management1." *RadioGraphics* 22.6 (2002): 1457-469. Web.
4. P. Randelli et al. (eds.), *Arthroscopy: Basic to Advanced*, DOI 10.1007/978-3-662-49376-2_80
5. Hayeri, M. R., Trudell, D. J., & Resnick, D. (2009). Anterior ankle impingement and talar bony outgrowths: Osteophyte or enthesophyte? Paleopathologic and cadaveric study with imaging correlation. *American Journal of Roentgenology*, 193(4), 334–338. <http://doi.org/10.2214/AJR.09.2427>

