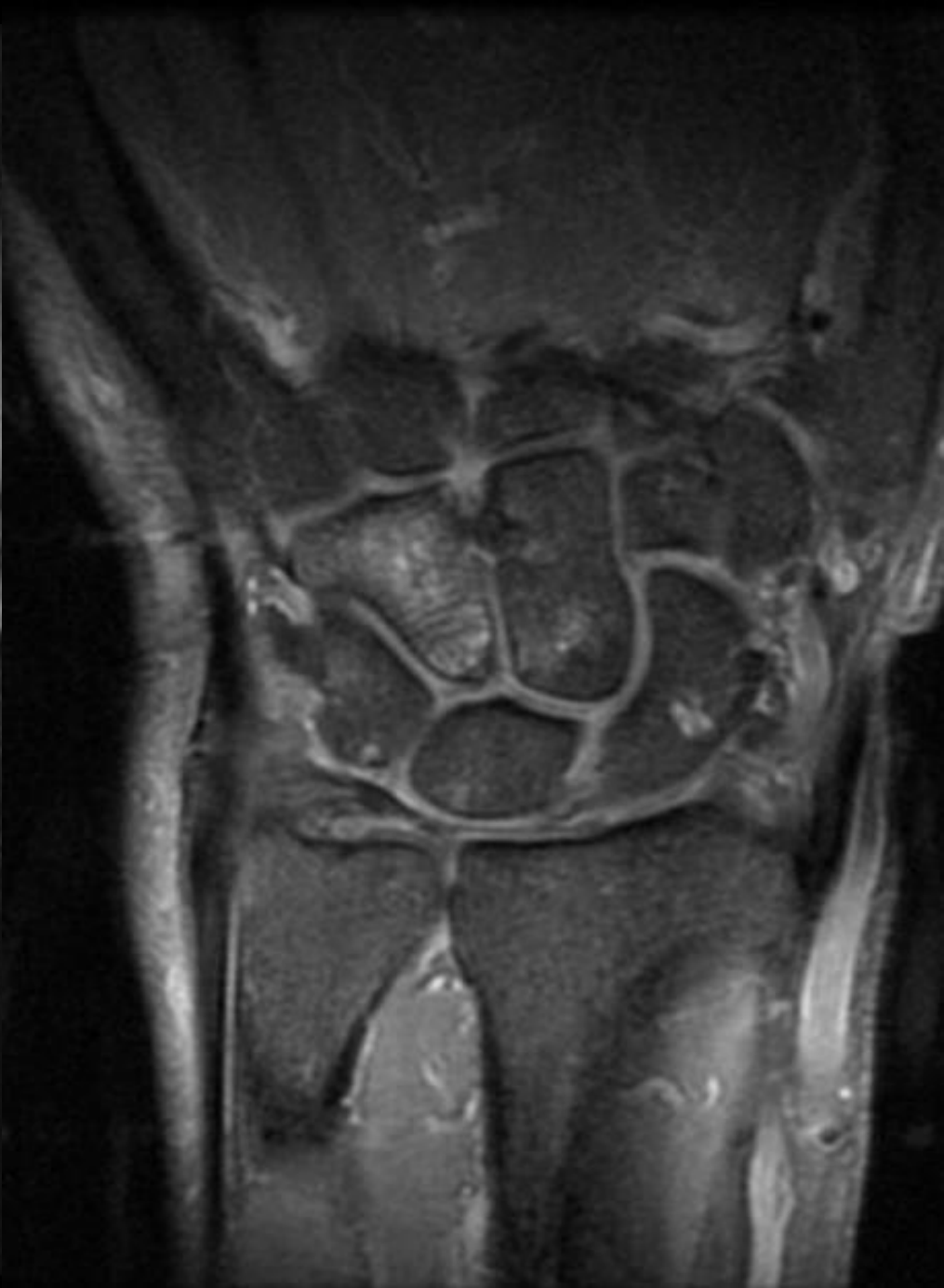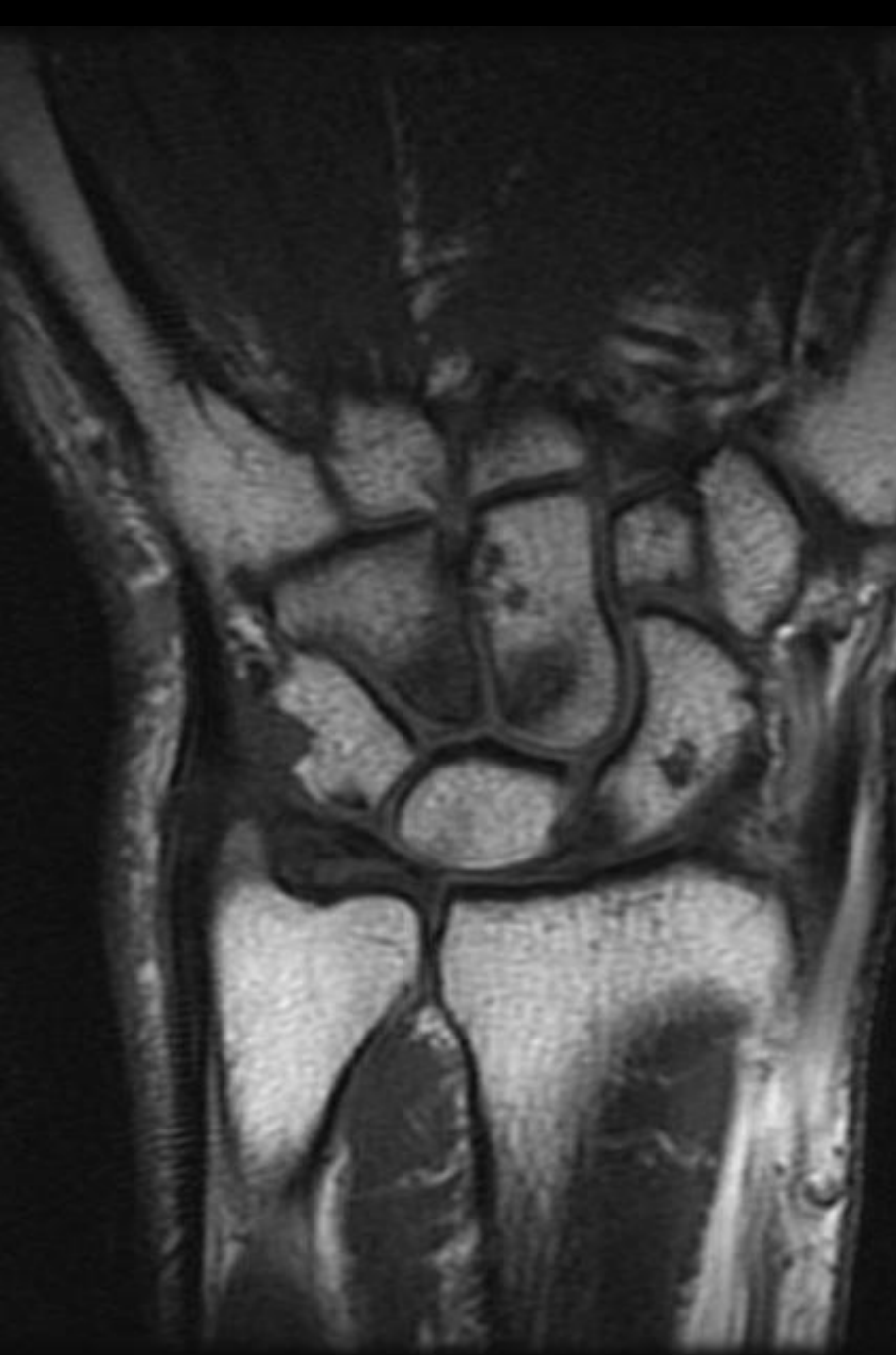



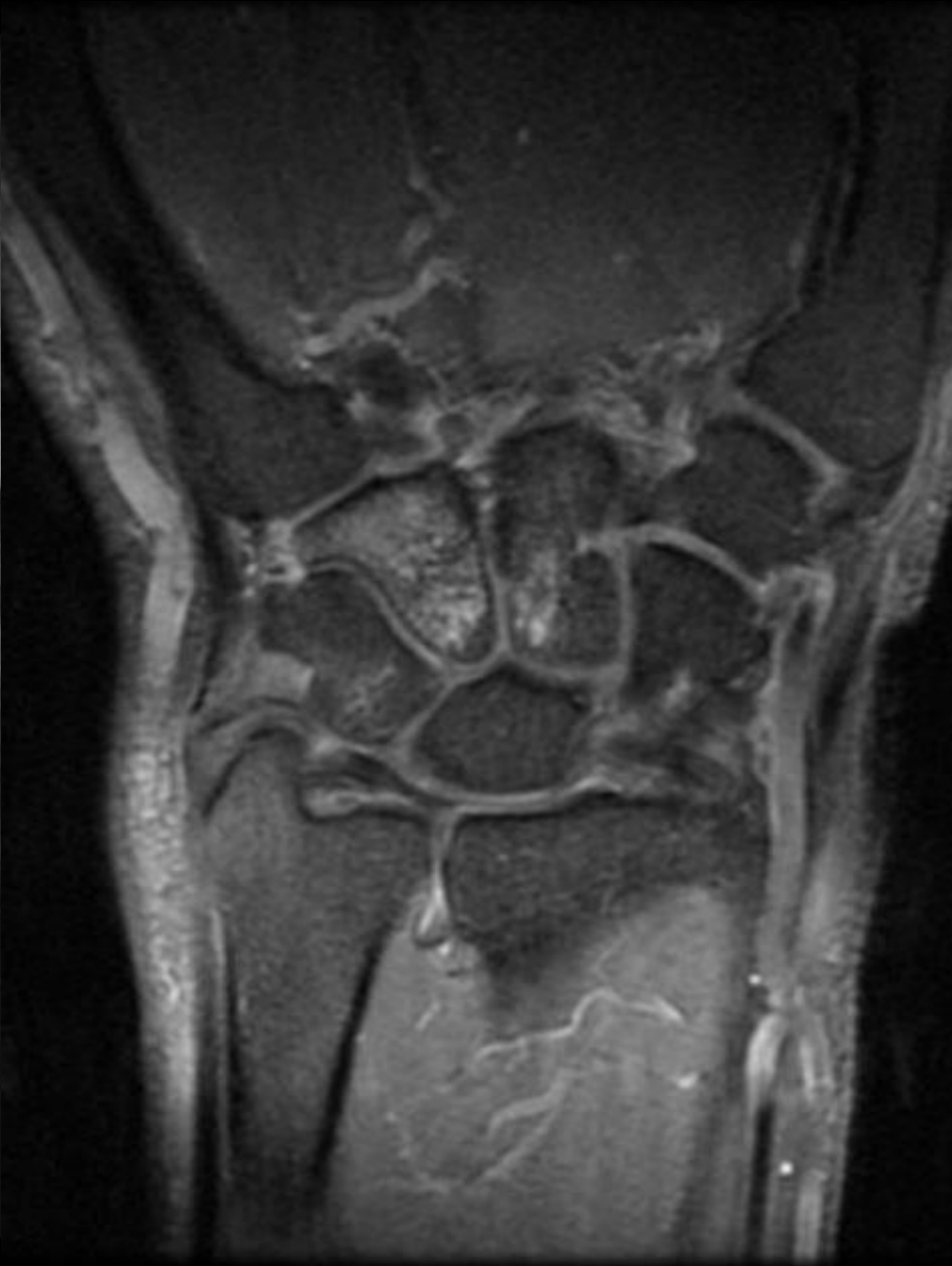
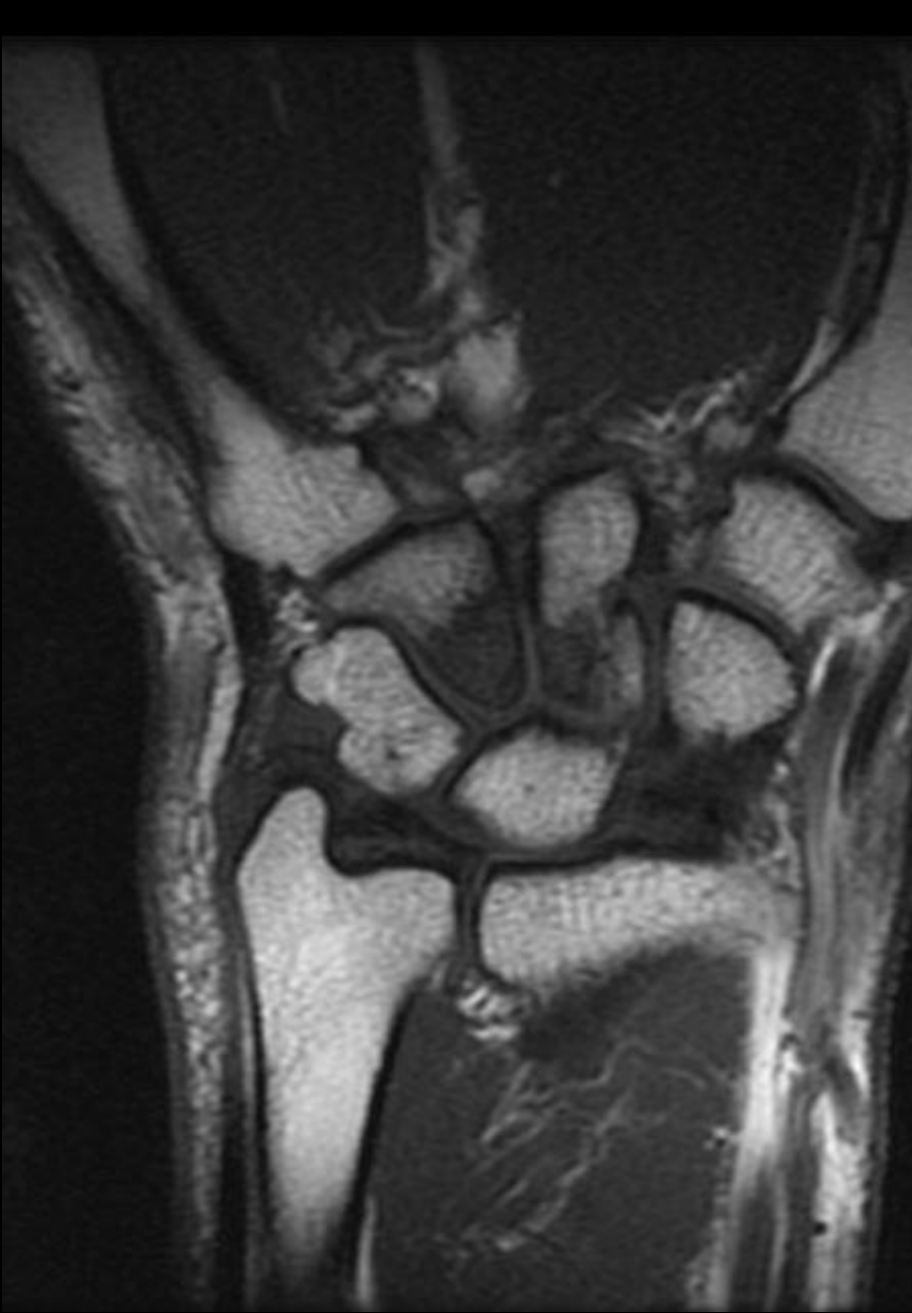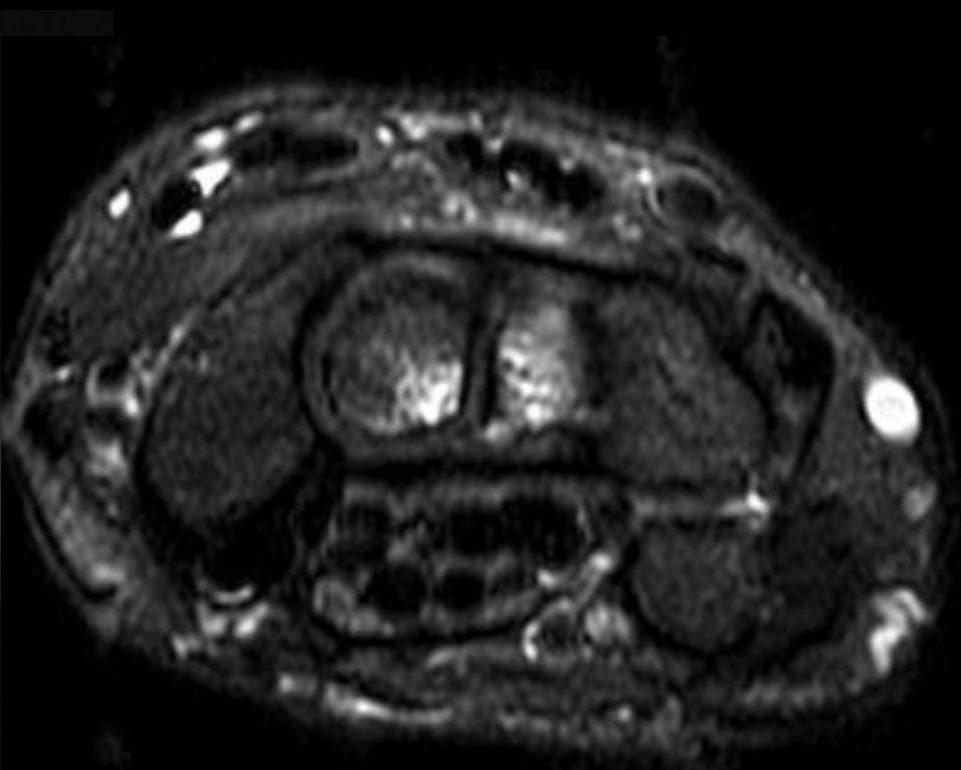
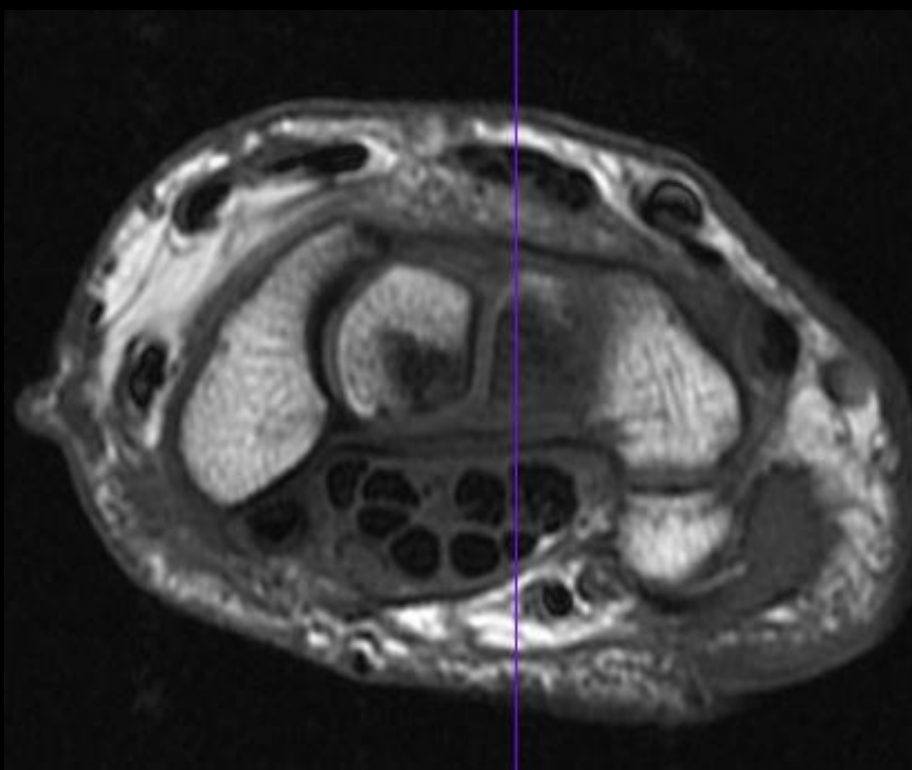
56 y/o male custodian with persistent right ulnar wrist pain, points to ulnocarpal wrist and hook of hamate region. No history of trauma or injury.

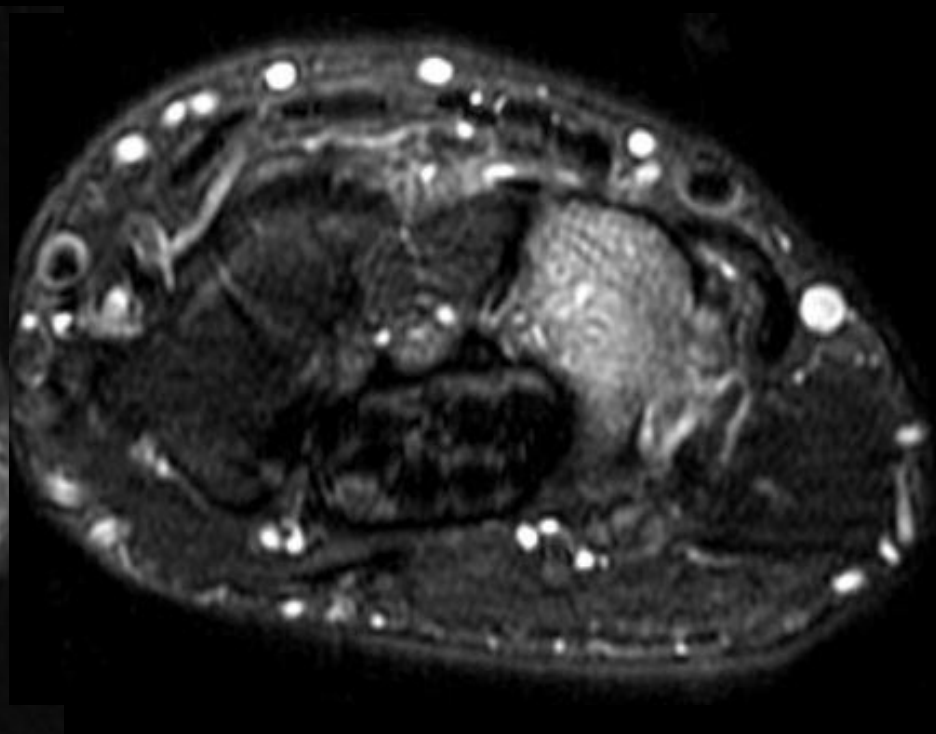
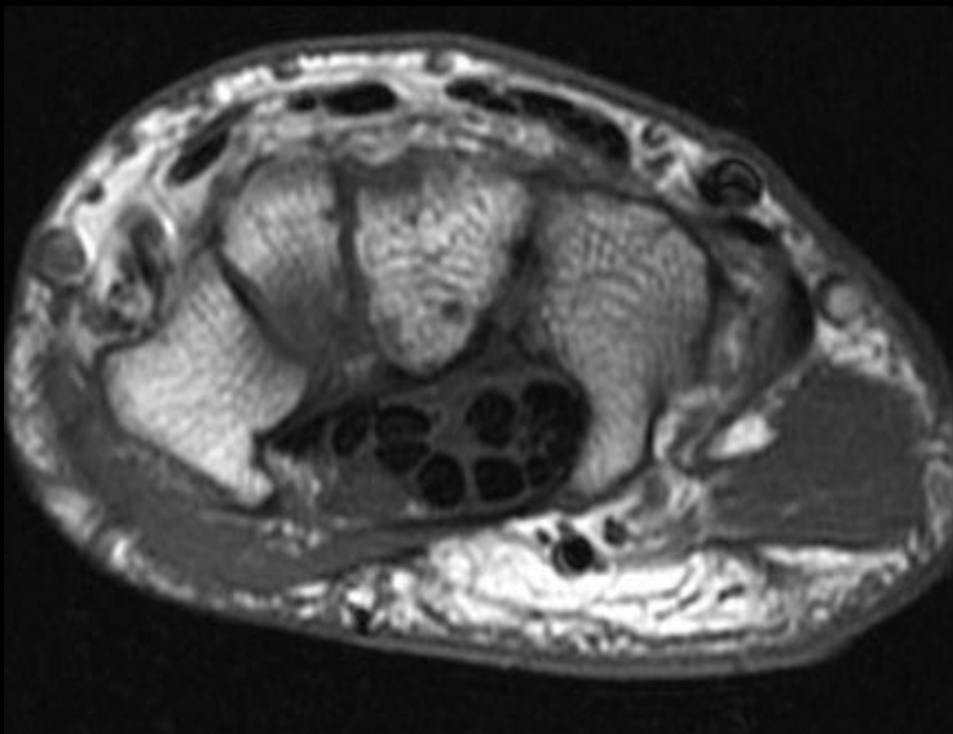
Loren Longenecker

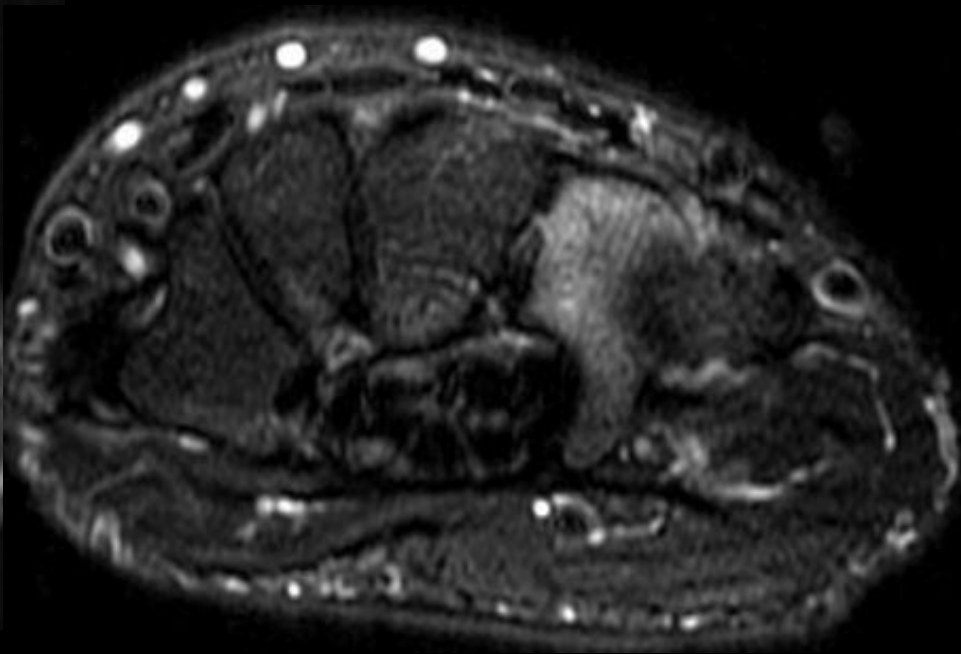
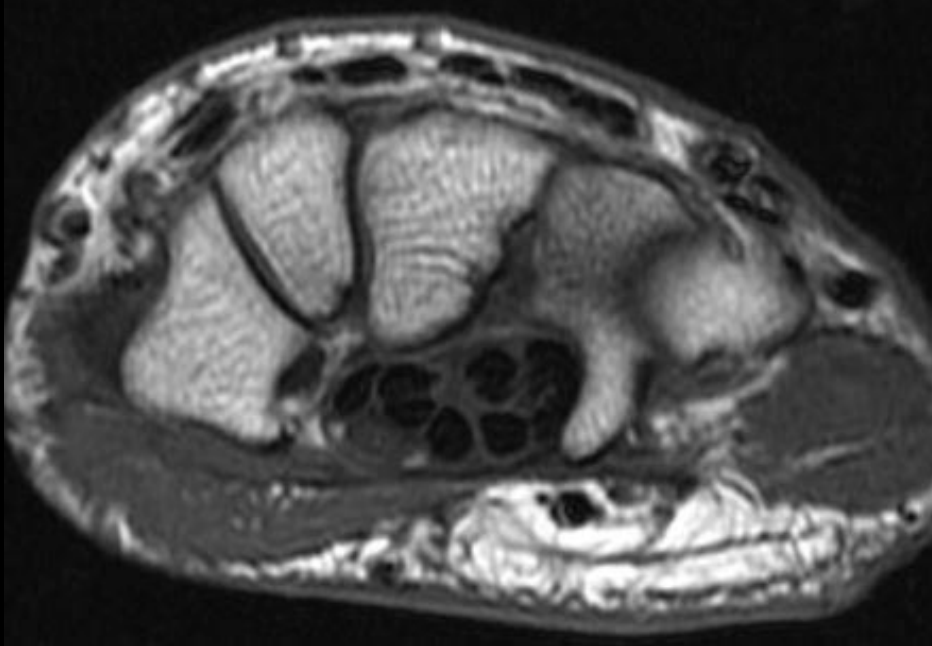
10/28/2016











# Avascular Necrosis of the proximal pole of the Hamate

## Avascular Necrosis of the Hamate: Three Cases and Review of the Literature

Sebastian J. Peters, MD<sup>1,2</sup> C. Verstappen, MD<sup>1</sup> Ilse Degreef, MD, PhD<sup>1</sup> Luc De Smet, MD, PhD<sup>1</sup>

<sup>1</sup> Orthopaedic Department, Hand Unit, University Hospitals Leuven, Pellenberg Campus, Pellenberg, Belgium

<sup>2</sup> Orthopaedic department, Regional Hospital Heilig Hart Leuven, Leuven, Belgium

**Address for correspondence** Sebastian J. Peters, MD, Weligerveld 1, 3212 Pellenberg, Belgium (e-mail: sebastianjpeters@gmail.com).

J Wrist Surg 2014;3:269–274.

# AVN of the hamate

- Rare
- Because of rarity, currently no consensus on etiology, disease presentation or best management.
- Presentation non specific
  - Most common symptoms is ulnar swelling with pain present dorsal, volar or both. If AVN of hook- volar TTP
  - Grip strength and ROM variably affected
- Etiology
  - Trauma/fracture- 5
  - Repetitive motion/microtrauma, overuse- 4
    - 2 tennis players, 1 gymnast
  - Unknown, idiopathic- 2
  - Corticosteroids- 1
- Diversity of location of AVN within hamate
  - Hook- 2
  - Proximal pole- 4
  - Total - 4
  - Distal pole- 4
- Average delay in diagnosis of 1 year

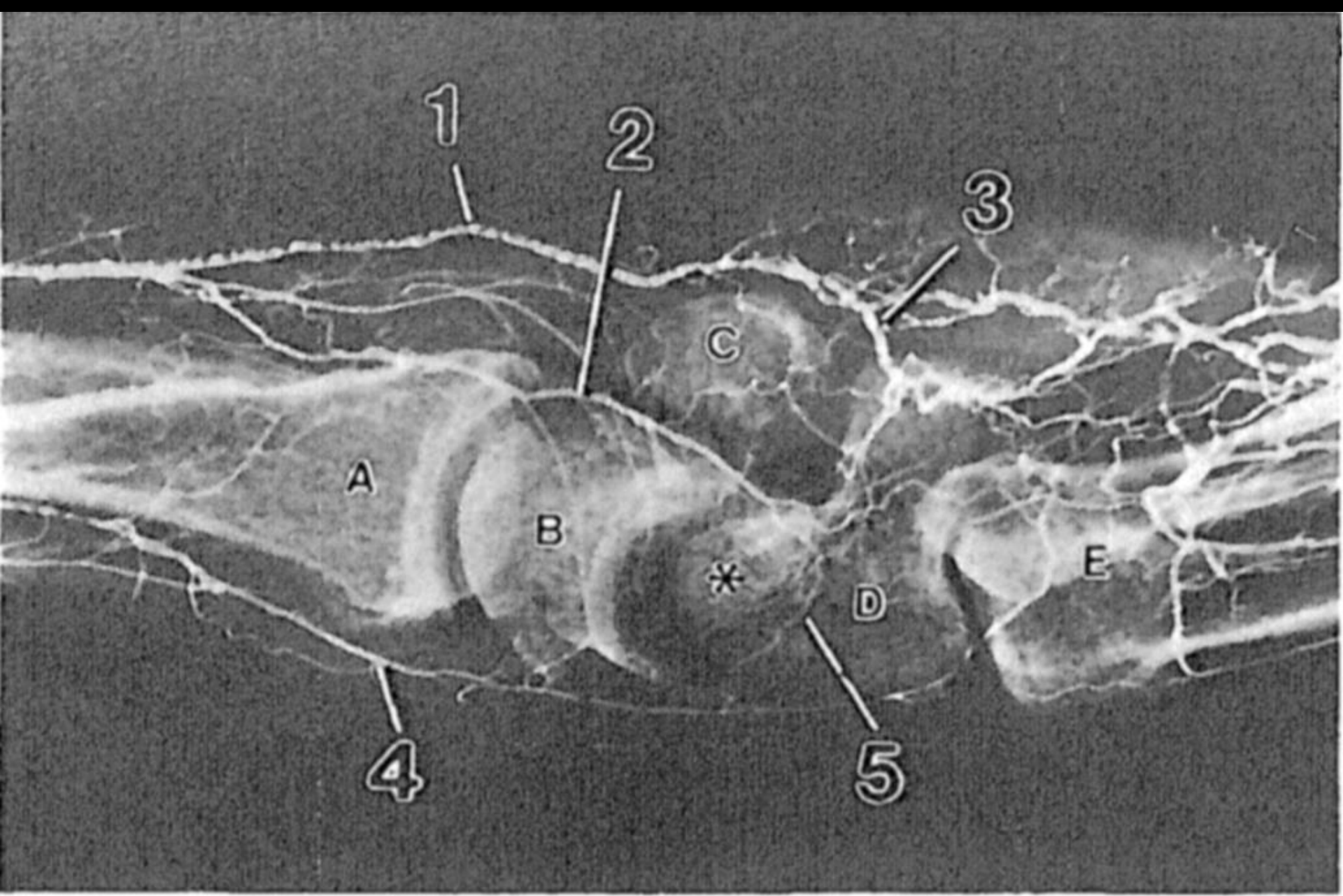


**Table 1** Data on all reported cases of avascular necrosis of the hamate

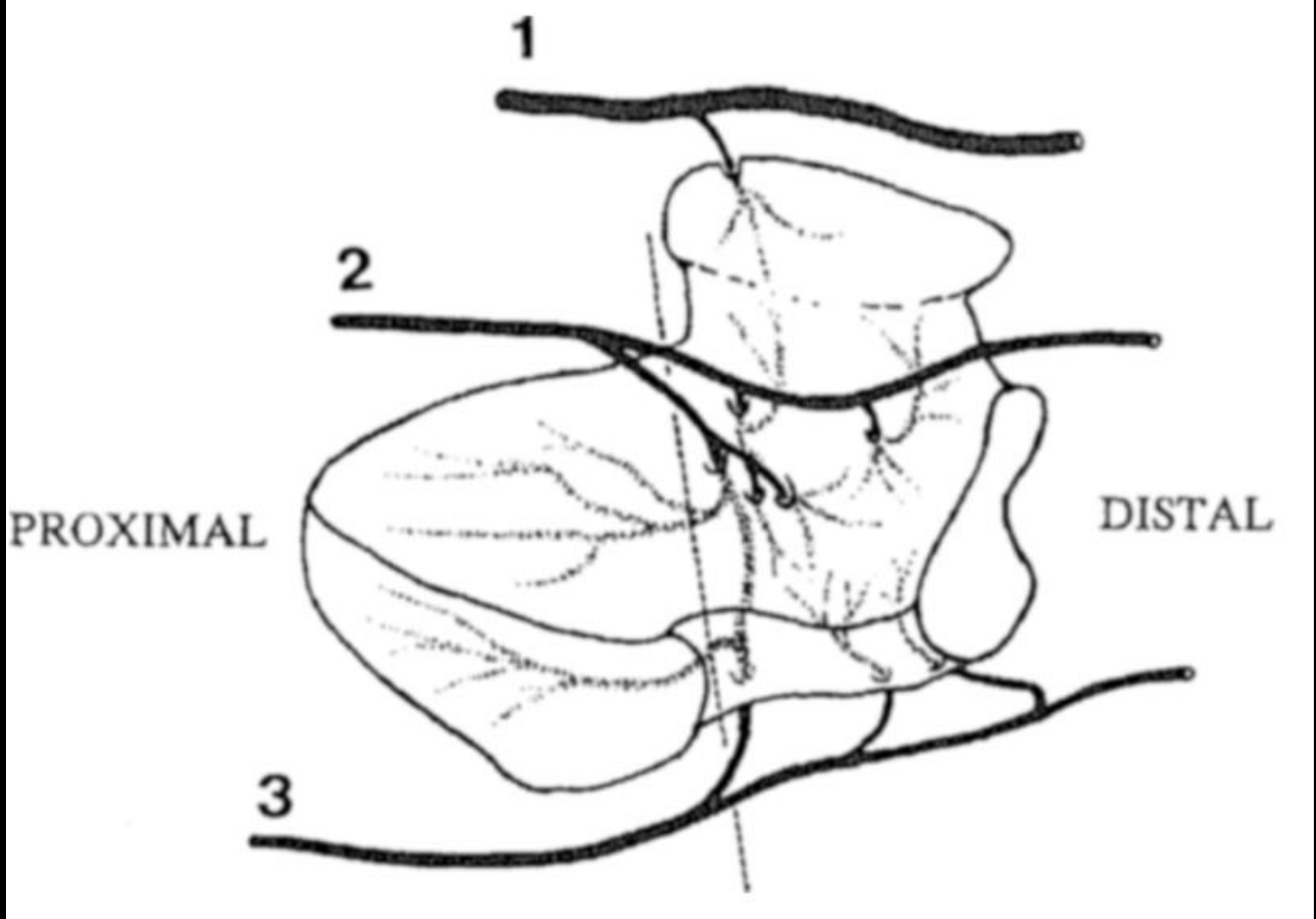
Author, year	Age, sex	Complaints	Side	Etiology	Location	Treatment	Histology proven	FU	Outcome
	years, M/F	years	L/R				Y/N	Years	
Peters 2014	8, F	1.5	L	Unknown	Hook	Excision hamate hook	Y	8	No pain, full strength and motion compared with other hand, QuickDASH 0
Peters 2014	44, M	1.5	R	Sports (tennis)	Proximal pole	Débridement, VBG from distal radius based on 5th ECA	Y	7	Po pain, full strength and motion compared with other hand, QuickDASH 0
Peters 2014	36, F	0.2	R	Trauma (fall)	Proximal pole	Débridement, impaction with cancellous graft (distal radius)	Y	1	Disabling pain hamate region, F/E 40/0/40, UD/RD 15/0/25, grip strength 18 vs 27 kg other hand, QuickDASH 70
Mazis 2012 <sup>8</sup>	58, M	2	R	Unknown	Total	Débridement, capitulunato-hamate fusion with cancellous graft (iliac crest)	N	0.3	Mild pain, reasonable force, F/E 30/0/30, DASH from 25 to 17
Juon 2008 <sup>6</sup>	21, M	0.3	L	Repetitive motion	Total	Débridement, VBG from dorsal distal radius based on posterior interosseus artery	Y	0.5	No pain, resumed work, good incorporation graft and normal signal hamate on MRI
Tukenmez 2005 <sup>5</sup>	25, M	3	R	Sports (gymnast)/repetitive motion	Proximal pole	Débridement, capitoamate fusion with spongy graft	Y	2	No pain, grip strength and ROM equal to other side
De Smet, 1999 <sup>7</sup>	66, F	0.2	L	Corticosteroids	Total	Proximal row carpectomy (for AVN of scaphoid, lunate and triquetrum)	N	3	No pain, grip strength 12 versus 17 kg other hand, F/E 30/0/60, UD/RD 20/0/25
Telfer, 1994 <sup>4</sup>	16, M	1.5	L	Trauma (fall)	Total	Débridement, capitulunato-triquetroamate fusion with cancellous graft (iliac crest)	Y	1	No pain, F/E 25/0/35, nonunion in CMC 5 and hamatolunate joint
Failla 1993 <sup>14</sup>	36, F	1.5		Sports (tennis)	Hook	Excision hamate hook	Y	0.2	return to sports, grip strength equal to other side
Van Demark 1992 <sup>3</sup>	45, M	0.3	R	Trauma (machine)	Proximal pole	None (patient declined surgery as he was able to return to work)	N	1	Nondisabling pain, F/E 45/0/53, UD/RD 20/0/14, grip strength 50 versus 57 kg other hand
Vogel 1963 <sup>3</sup>	23, M	1	L	Sport trauma (hockeystick on hand)	Distal pole	Unknown	N	—	—
Logròscino, 1938 <sup>2</sup>	29, M	0.2	R	Trauma / osteomyelitis	Distal pole	Débridement, sequester and macroscopic necrotic bone	N	0.3	—

# Vascular supply of hamate

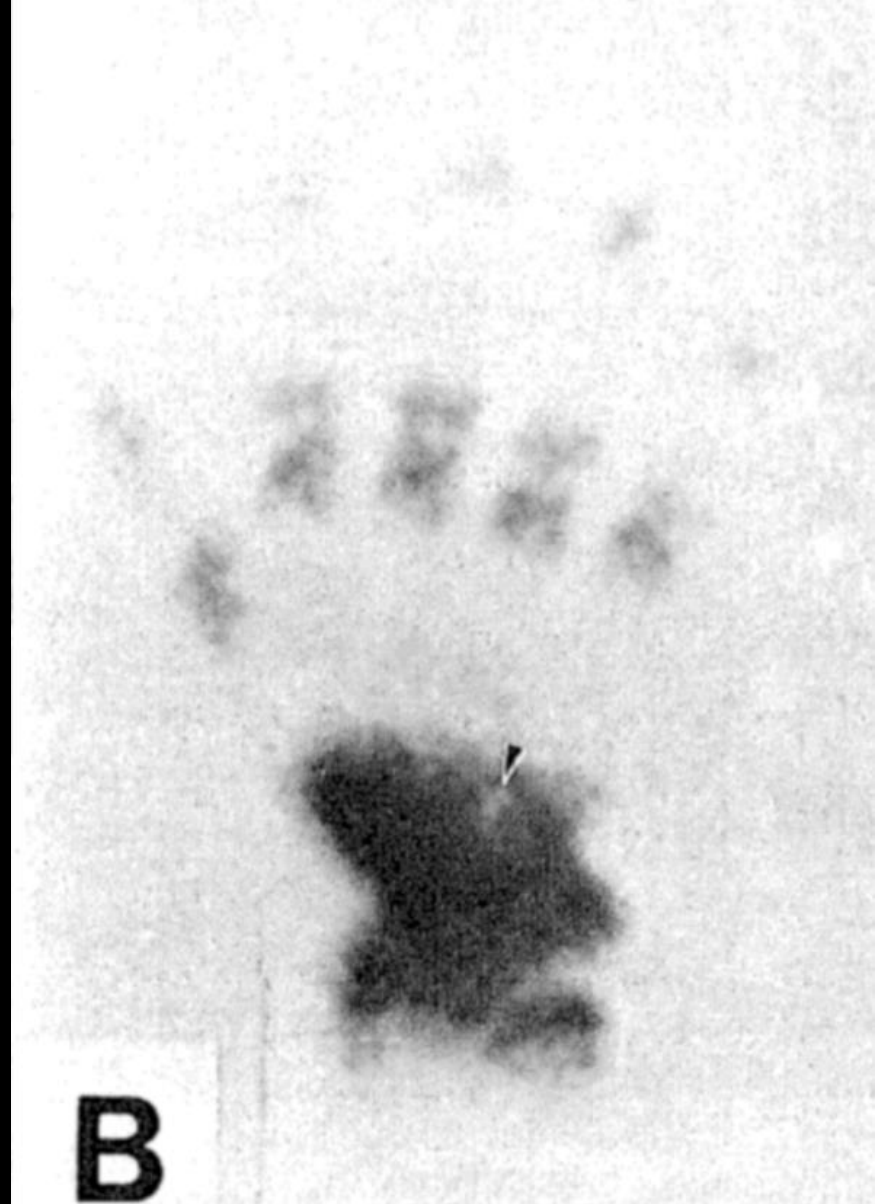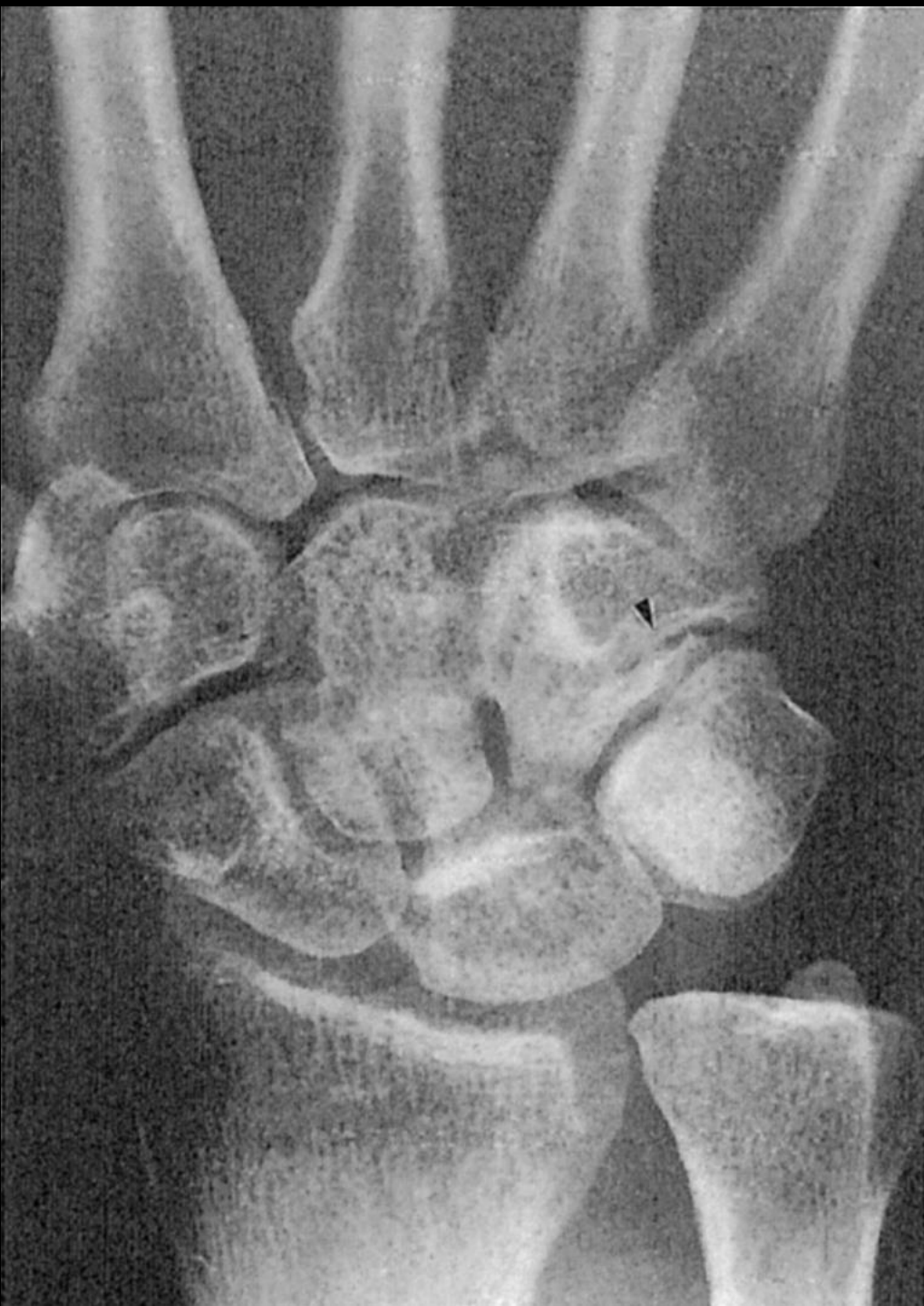- 4 subtypes of AVN (total, proximal pole, distal pole and hook) correlate with vascular supply
- Receives blood via dorsal intercarpal arch, recurrent ulnar artery and ulnar artery at 3 non articular surfaces: dorsal, volar, medial on base of hook of hamate.
- Intraosseous anastomoses in body of hamate seen during injection studies.
- Proximal pole and hook are more prone to AVN based on vascular supply
  - Proximal pole solely depending on interosseous supply
  - Hamate hooks supplies by single vessel are more prone in cases of hamate fx



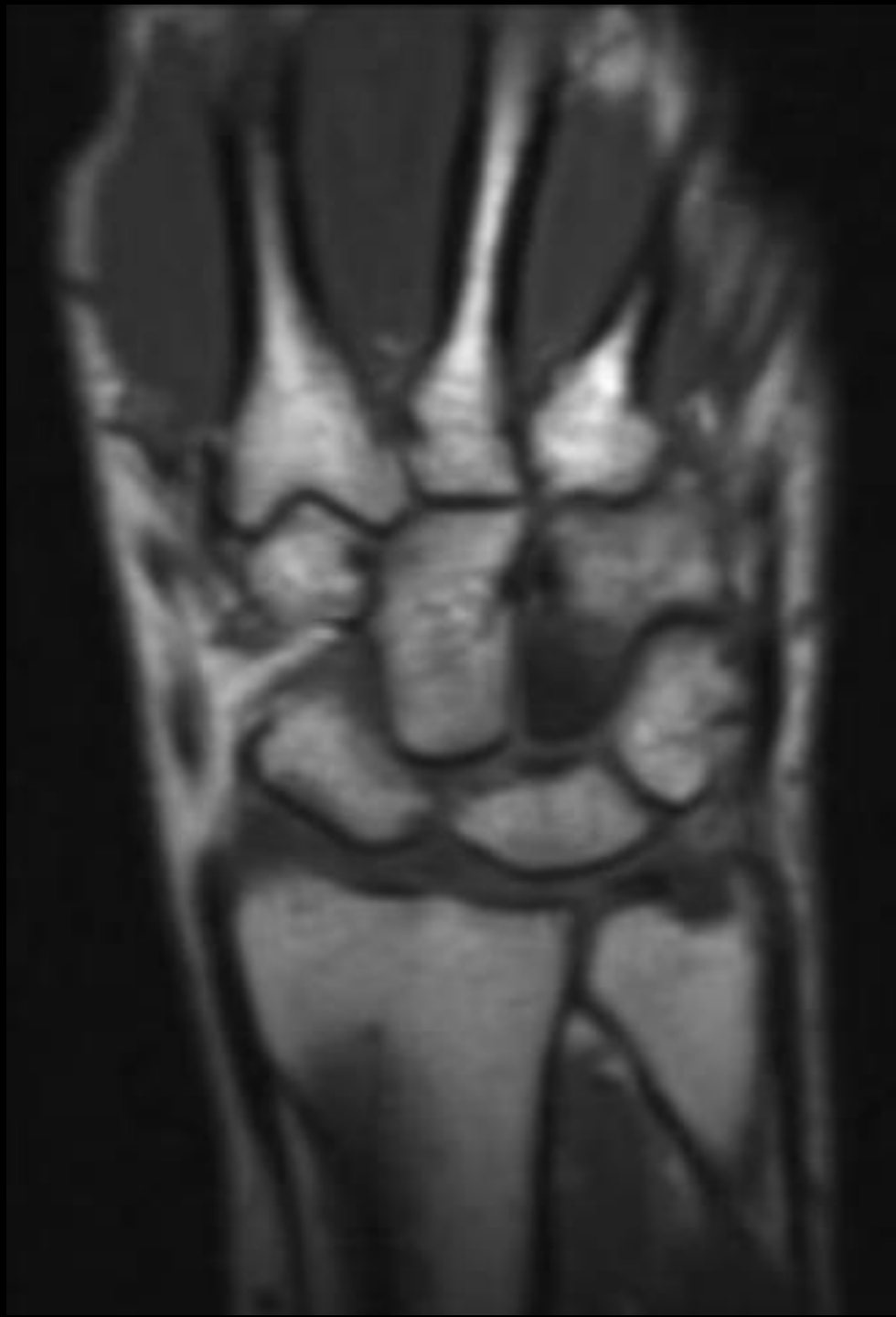
Van Demark RE, Parke WW, et al. Avascular necrosis of the hamate: A case report with reference to the hamate blood supply. *J Hand Surgery* 1992;17A:1086-90.



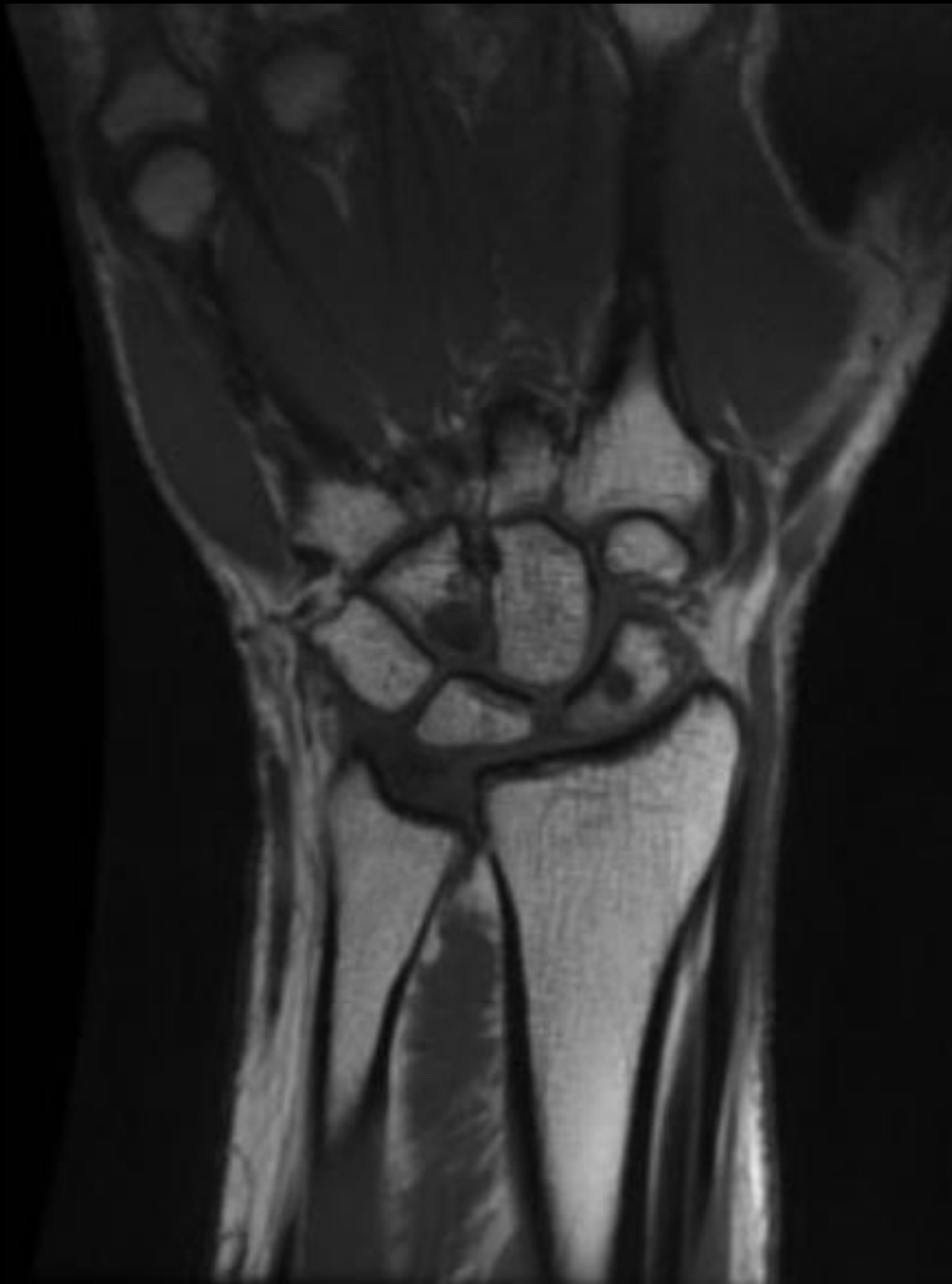Van Demark RE, Parke WW, et al. Avascular necrosis of the hamate: A case report with reference to the hamate blood supply. *J Hand Surgery* 1992;17A:1086-90.



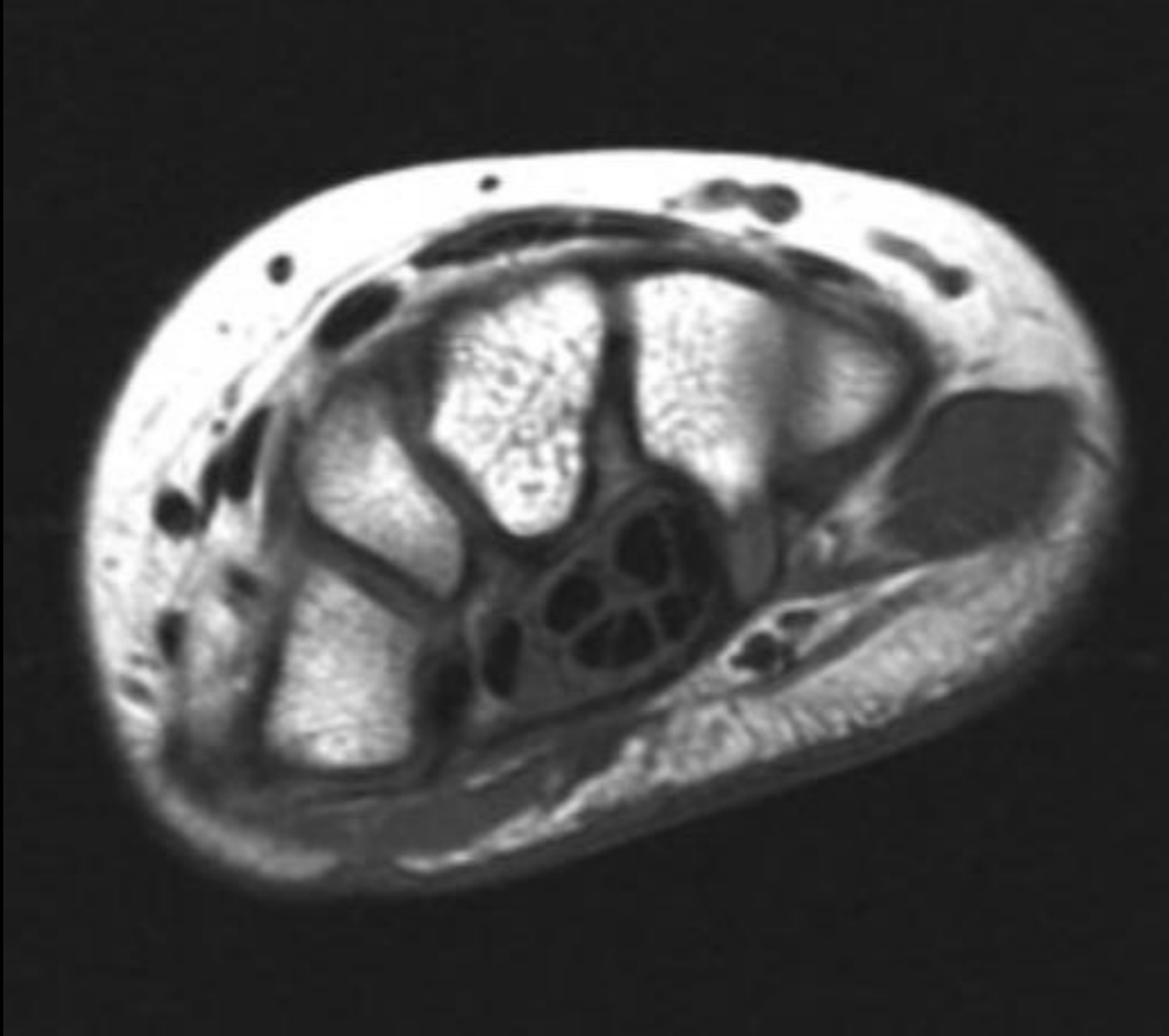
Van Demark RE, Parke WW, et al. Avascular necrosis of the hamate: A case report with reference to the hamate blood supply. *J Hand Surgery* 1992;17A:1086-90.



Peters JP, Verstappen C, et al.  
Avascular Necrosis of the  
Hamate: Three cases and  
Review of the Literature. *J*  
*Wrist Surgery* 2014;3:269-274.



Peters JP, Verstappen C, et al.  
Avascular Necrosis of the  
Hamate: Three cases and  
Review of the Literature. *J Wrist  
Surgery* 2014;3:269-274.



Peters JP, Verstappen C, et al. Avascular Necrosis of the Hamate: Three cases and Review of the Literature. *J Wrist Surgery* 2014;3:269-274.



# References

1. Peters JP, Verstappen C, et al. Avascular Necrosis of the Hamate: Three cases and Review of the Literature. *J Wrist Surgery* 2014;3:269-274.
2. Van Demark RE, Parke WW, et al. Avascular necrosis of the hamate: A case report with reference to the hamate blood supply. *J Hand Surgery* 1992;17A:1086-90.