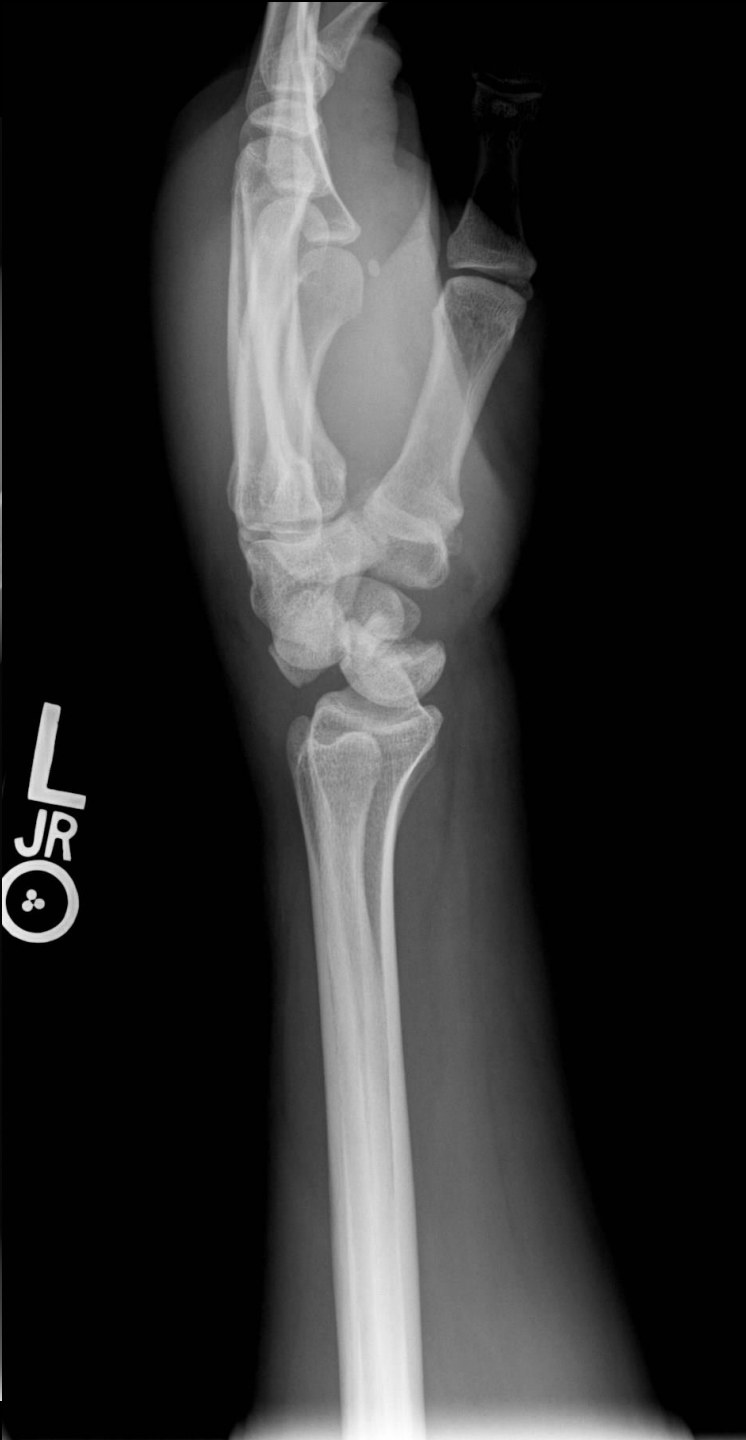
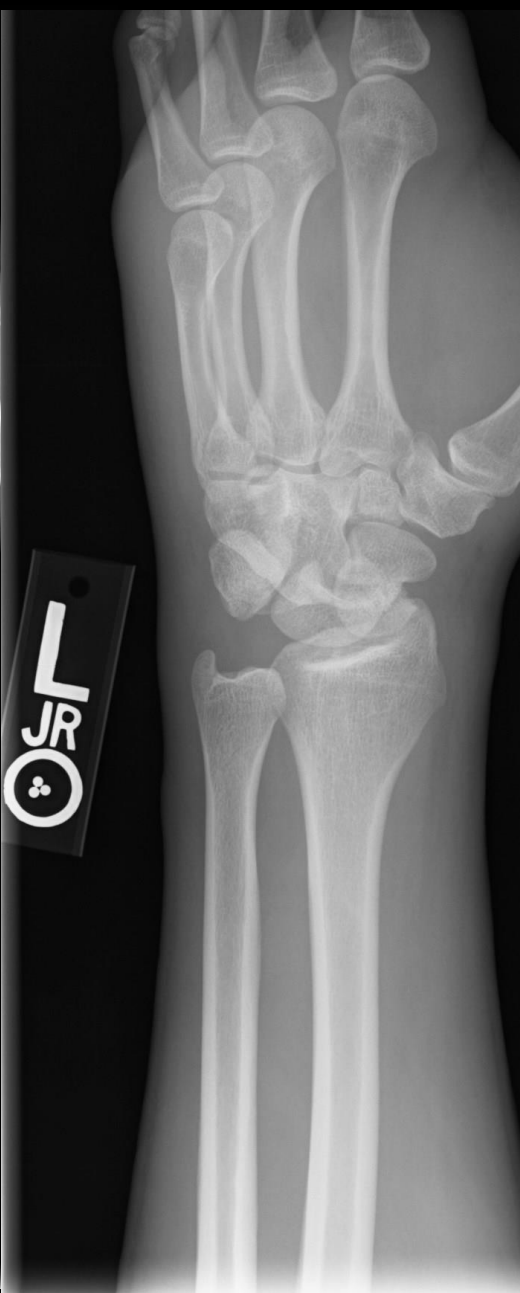
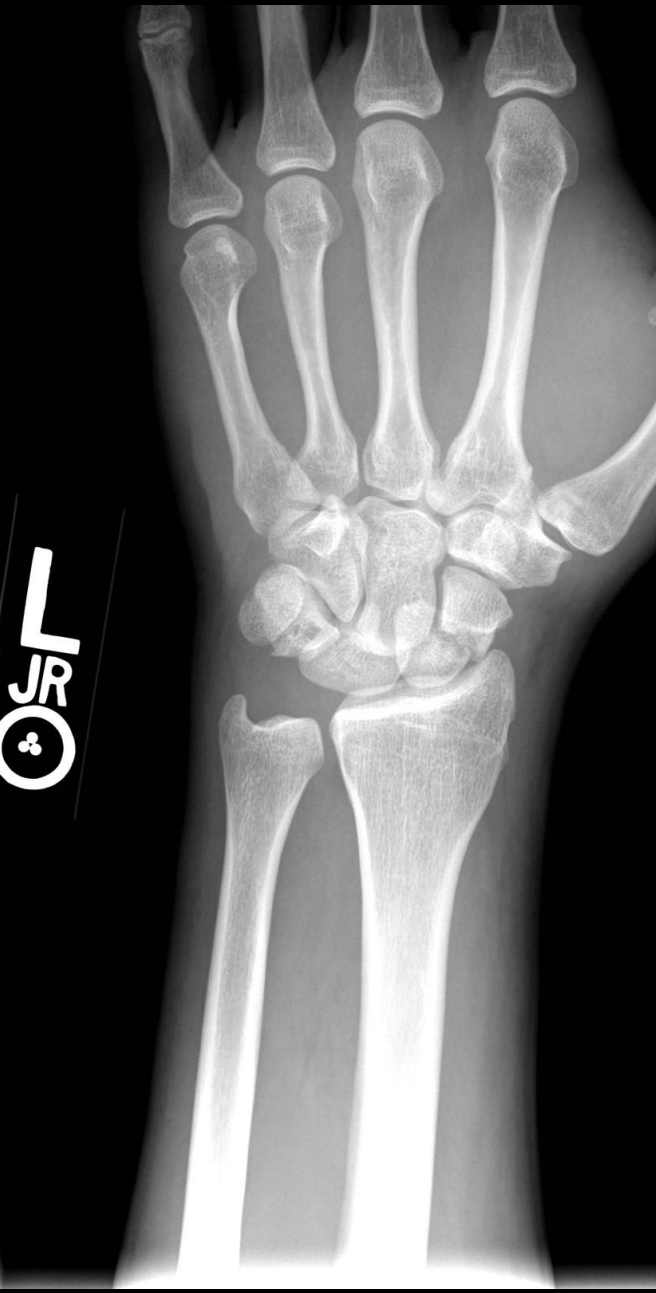

28 year old male s/p fall while
running.

Paul Jabour

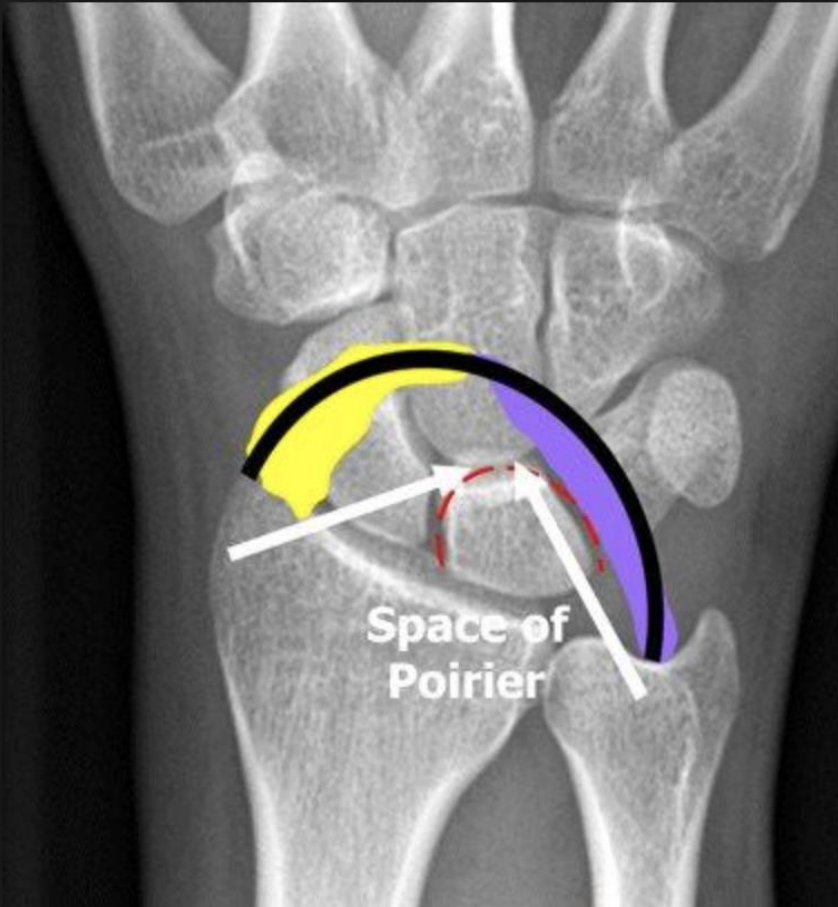
11.4.2016



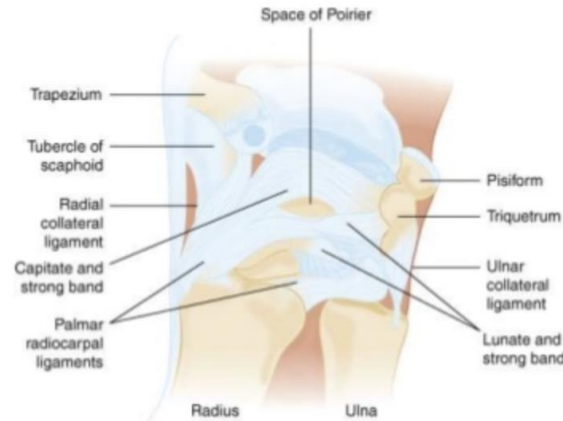
Mechanism

- - **Mechanism:**
- - carpal dislocations result from hyperdorsiflexion;
- - severe ligament injury is necessary to tear the distal row from the lunate to produce perilunate dislocation;
- - **sequence of injury:**
- - this injury pattern usually begins radially & destabilizes thru body of scaphoid (w/ frx) or thru scapholunate interval (w/ dissociation);
- - scaphoid bridges the proximal and distal carpal rows;
- - w/ dislocation between these rows, the scaphoid must either rotate or fracture
- - this produces a perilunate dislocation, which may cause: trans-scapoid perilunate dislocation:
- - distal half of scaphoid & remaining carpus dislocate around lunate;
- - force is transmitted ulnarly thru the [space of Poirier \(between lunate and capitate\)](#);
- - next force transmission disrupts the luno-triquetral articulation;
- - as a manifestation of the most severe form of the injury, the lunate may be dislocated into the carpal tunnel;
- - [transradial styloid perilunate dislocation](#):
- - fx of radial styloid w/ dislocation of it & remaining carpus around lunate;
- - further destabilization passes distal to lunate, either thru [space of Poirier or thru capitate \(transcapitate frx\)](#), & then ulnar to lunate, either through [hamate & triquetrum](#) or thru [lunotriquetral interval](#);

http://www.wheelessonline.com/ortho/perilunate_dislocations



SPACE OF POIRIER



- Ligament free area in palmar aspect of capitulunate space is area of potential weakness
- This area expands when the wrist is dorsiflexed and disappears in palmar flexion.
- A rent develops during dorsal dislocations, and it is through this interval that the lunate displaces into the carpal canal.

Source: Tintinalli JE, Stapczynski JS, Ma OJ, Cline DM, Cydulka RK, Meckler GD:
Tintinalli's Emergency Medicine: A Comprehensive Study Guide, 7th Edition:
<http://www.accessmedicine.com>
 Copyright © The McGraw-Hill Companies, Inc. All rights reserved.

<http://www.slideshare.net/kommireddy239/carpal-bone-fractures>

<http://www.meddybear.net/space-of-poirier/>

Spectrum of Carpal Dislocations and Fracture-Dislocations: Imaging and Management

Luke R. Scalcione¹
Lana H. Gimber¹
Annette M. Ho¹
Stephen S. Johnston¹
Joseph E. Sheppard²
Mihra S. Taljanovic¹

OBJECTIVE. The objectives of this article are to discuss the imaging of carpal dislocations and fracture-dislocations and to review the ligamentous anatomy of the wrist, mechanisms of injury, and routine management of these injuries.

CONCLUSION. Perilunate dislocations, perilunate fracture-dislocations (PLFDs), and lunate dislocations are high-energy wrist injuries that can and should be recognized on radiographs. These injuries are a result of important sequential osseous and ligamentous injuries or failures. Prompt and accurate radiographic diagnosis aids in the management of patients with perilunate dislocations, PLFDs, and lunate dislocations while assisting orthopedic surgeons with subsequent surgical planning. CT may better show the extent of the injury and help in treatment planning particularly in cases of delayed treatment or chronic perilunate dislocation. A CT examination with coronal, sagittal, and 3D reformatted images is ordered at our institution in cases in which the extent of the carpal injuries is poorly shown on radiographic examination.

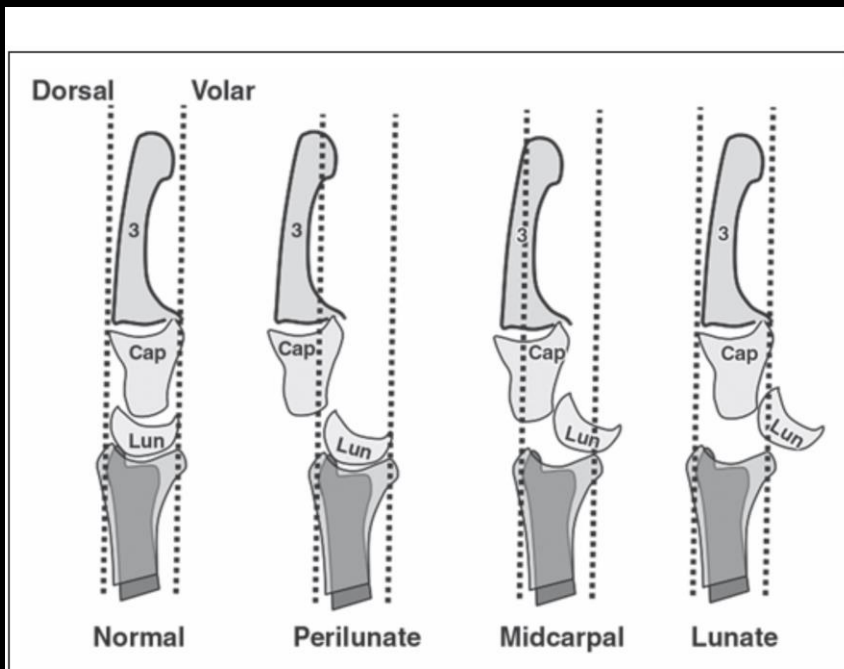
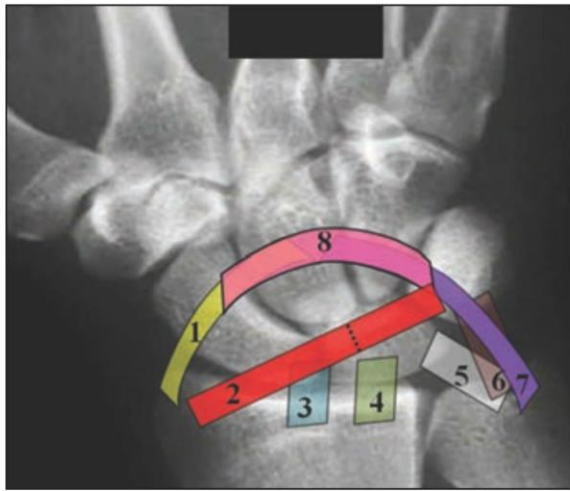
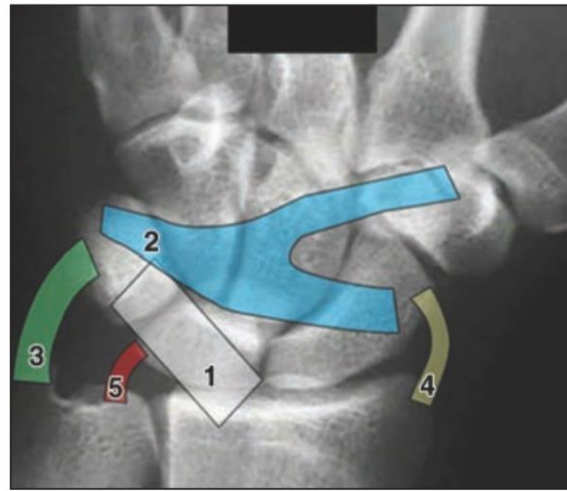


Fig. 5—Perilunate and lunate dislocations overview. Drawings show lateral view of wrist. Normal wrist maintains colinearity (*dashed lines*) of radius, lunate (Lun), capitate (Cap), and third metacarpal and middle finger (3). Perilunate dislocations maintain colinearity of radius and lunate while capitate and middle finger metacarpal are dorsally dislocated. Midcarpal dislocations disrupt colinearity of radius and lunate with volar tilt and volar subluxation of lunate and dorsal subluxation of capitate and middle finger metacarpal. Late lunate dislocations will show loss of colinearity of lunate and radius with lunate volarly tilted and dislocated, but colinearity of radius, capitate, and middle finger metacarpal is maintained.



A



B

Fig. 2—Extrinsic wrist ligaments in healthy 36-year-old male (same patient as in Fig. 1).

A, Drawing of palmar extrinsic wrist ligaments superimposed on posteroanterior radiograph of normal wrist. 1 = radioscaphocapitate (also known as radiocapitate), 2 = long radiolunate (also known as radiolunotriquetral, radiotriquetral, and lunotriquetral), 3 = radioscapholunate (also known as ligament of Testut and Kuenz), 4 = short radiolunate (also known as radiolunate), 5 = palmar ulnolunate, 6 = palmar ulnotriquetral, 7 = lunocapitate (also known as ulnotriquetrocipitate), 8 = palmar scaphotriquetral (also known as triquetrocipitoscaphoidal and triquetrosaphoidal).

B, Drawing of dorsal extrinsic wrist ligaments superimposed on posteroanterior radiograph of normal wrist. 1 = dorsal radiocarpal (also known as radiotriquetral and radiolunotriquetral), 2 = dorsal intercarpal (also known as triquetrosaphoidal and triquetrotapezoidotrapezial), 3 = ulnar collateral, 4 = radial collateral, 5 = dorsal ulnotriquetral (also referred to as “capsular thickening”).

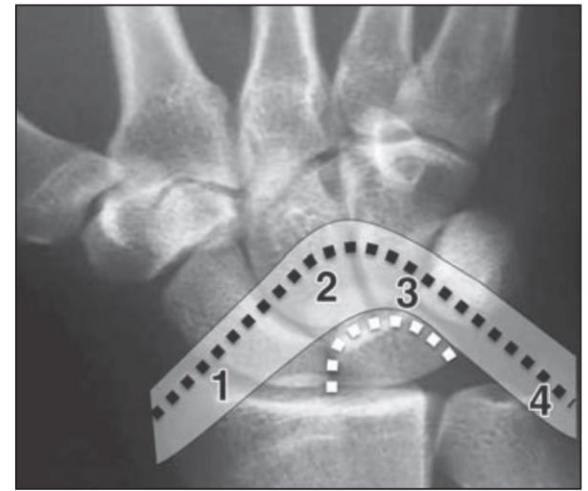


Fig. 3—Zone of vulnerability and greater and lesser arcs. Drawing of zone of vulnerability and greater and lesser arcs superimposed on posteroanterior radiograph of normal wrist of 36-year-old healthy man (same patient as in Fig. 1). Greater arc (*dashed black line*) outlines osseous failure in perilunate fracture-dislocations. Lesser arc (*dashed white line*) outlines lunate and represents purely ligamentous failure in perilunate dislocations or lunate dislocations. 1 = fracture of radial styloid, scaphoid waist, or proximal pole and failure of scapholunate joint (scapholunate interosseous ligament); 2 = fracture of capitate body or failure of capitulunate joint; 3 = fracture of base of hamate, fracture of triquetrum, or failure of lunotriquetral joint (lunotriquetral interosseous ligament); 4 = fracture of ulnar styloid.

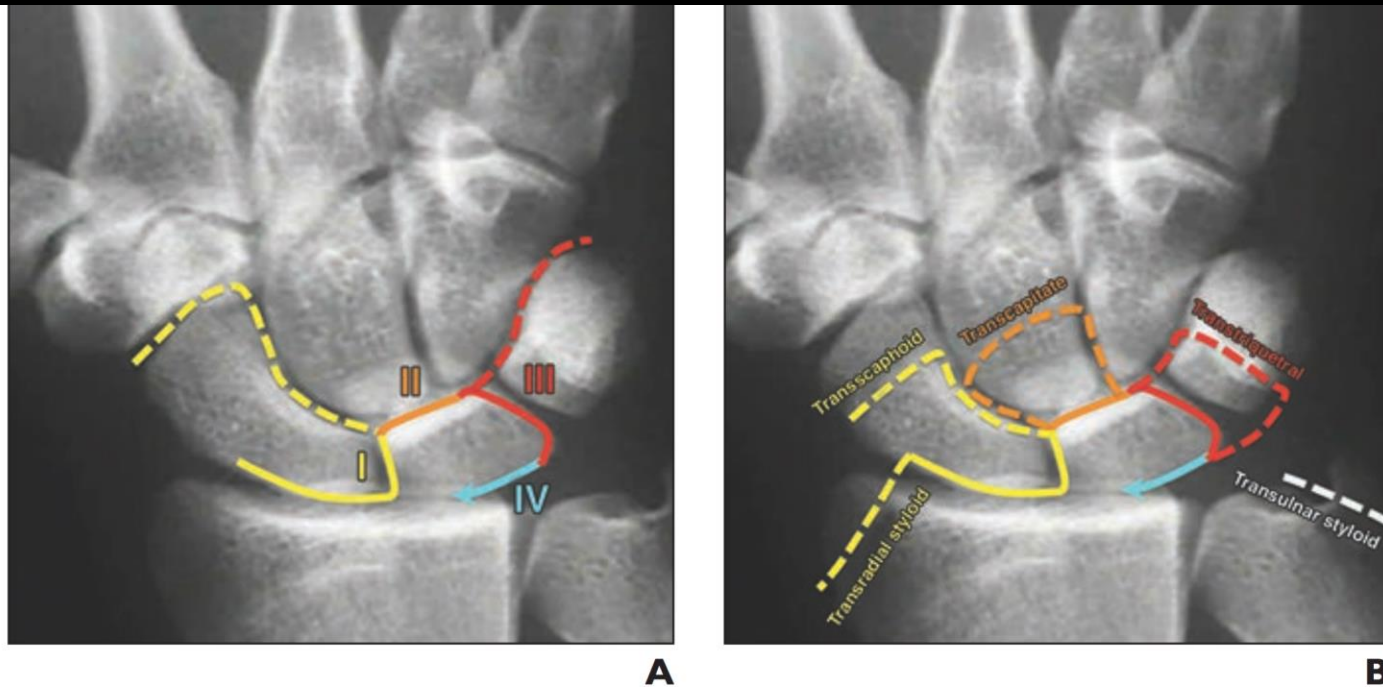
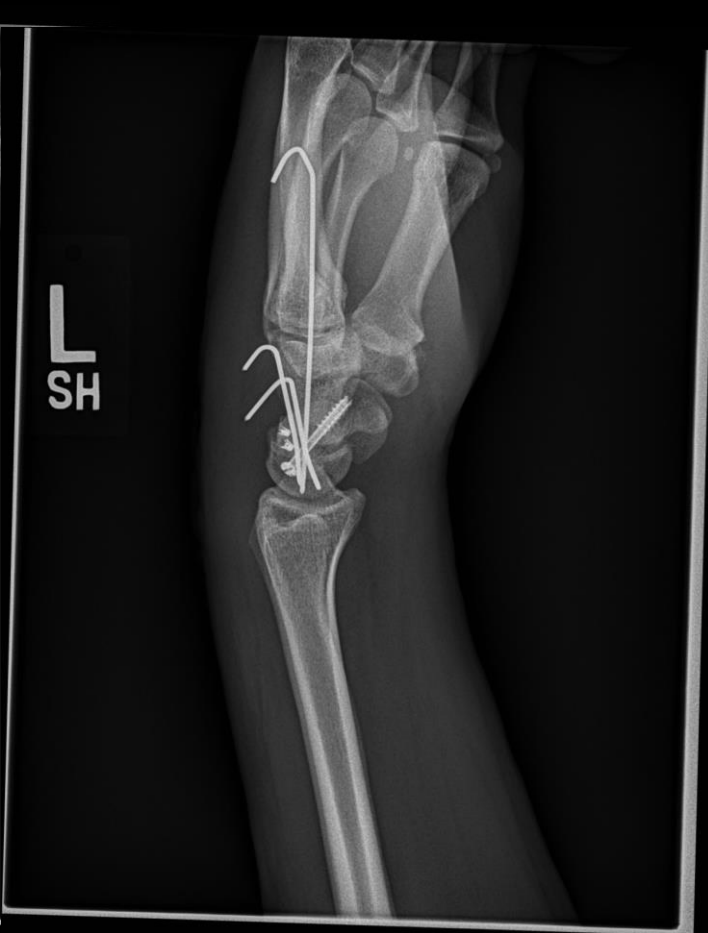
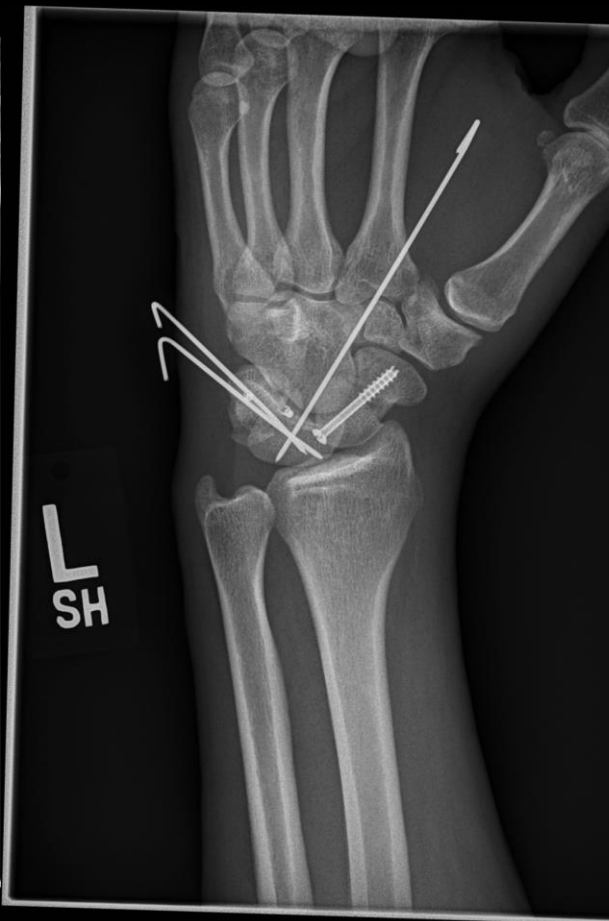
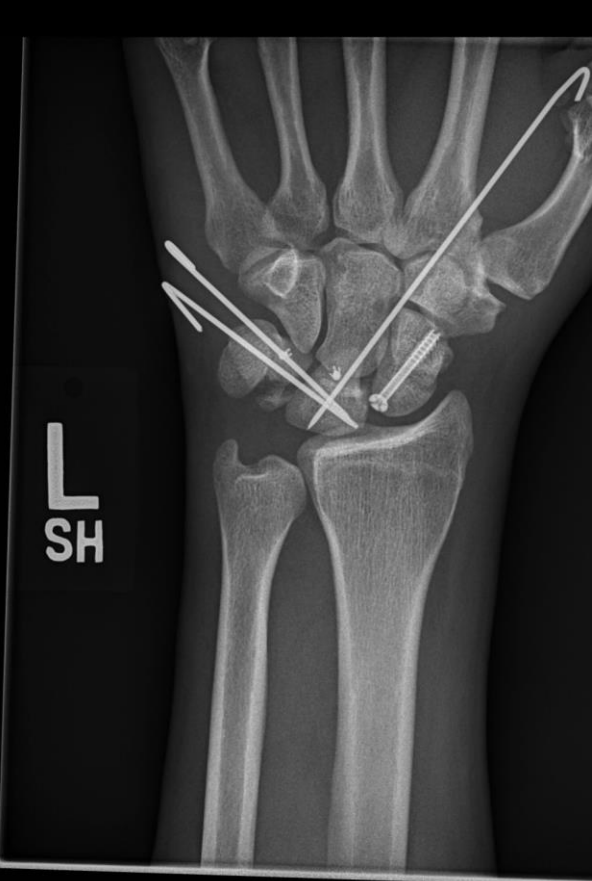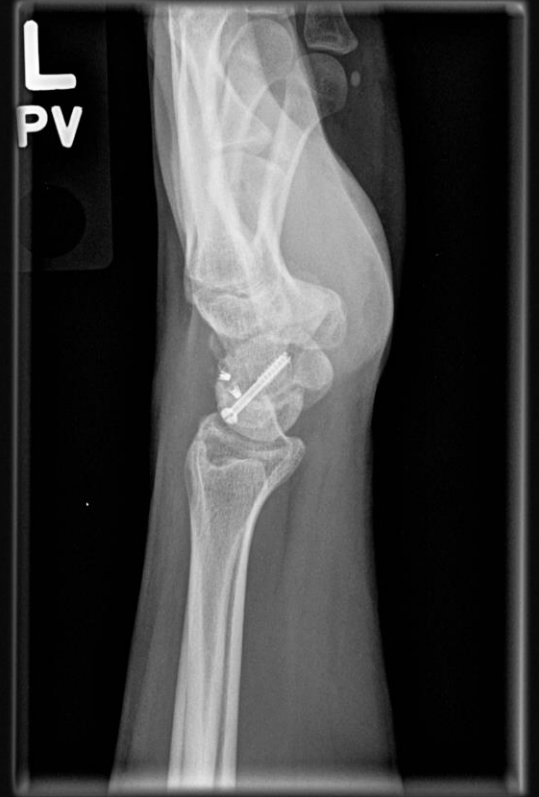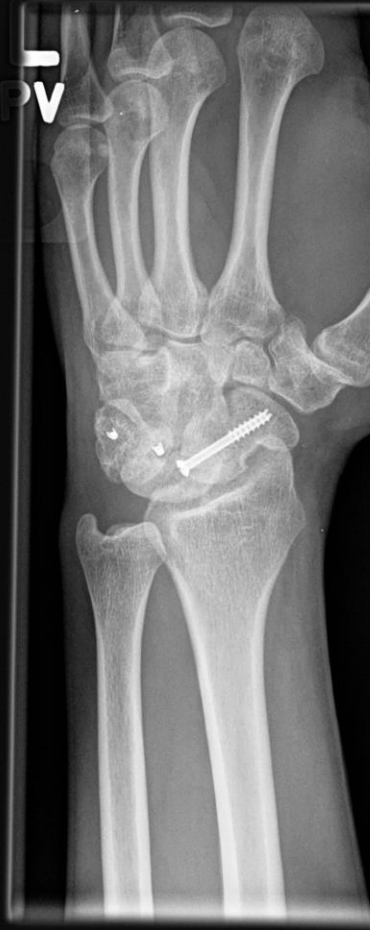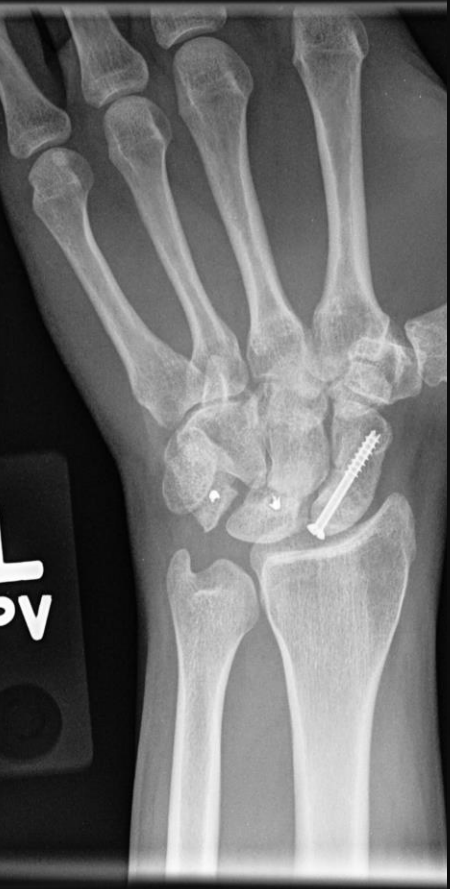Fig. 4—Ligamentous and osseous failures seen in perilunate fracture-dislocations (PLFDs) and lunate fracture-dislocations. Images obtained in healthy 36-year-old man (same patient as in Fig. 1).

A, Drawing shows pathways of ligamentous failures in perilunate dislocations according to Mayfield classification [2] superimposed on posteroanterior radiograph of normal wrist. Stage I injuries involve disruption of scapholunate joint (*solid yellow line*) with failure of scapholunate interosseous ligament and radioscapohcapitate ligament or failure at triscaphe joint (*dashed yellow line*). Stage II injuries disrupt capitoulunate joint (*orange line*). Stage III injuries disrupt lunotriquetral joint (*solid red line*) with failure of lunotriquetral interosseous ligament, long radiolunate ligament, and palmar ulnotriquetral ligament or disrupt triquetrohamate joint (*dashed red line*). Finally, stage IV injuries completely mobilize lunate with failure of short radiolunate ligament and dorsal radiocarpal ligament (*blue line and arrow*).

B, Drawing shows alternate osseous pathways involved in PLFDs involving greater arc injuries of carpus superimposed on posteroanterior radiograph of normal wrist. Stage I injuries can take transscaphoid or transradial styloid course from avulsive injuries of radioscapohcapitate ligament or radial collateral ligament (*dashed yellow lines*). Stage II injuries follow transcapitate course (*dashed orange line*). Stage III injuries follow transtriquetral course (*dashed red line*) with failure of ulnotriquetral ligament or long radiolunate ligament. Finally, ulnar styloid fractures (*dashed white line*) can occur in conjunction with PLFD. Solid yellow line = scapholunate interosseous ligament, solid orange line = capitoulunate, solid red line = lunotriquetral interosseous ligament, blue line and arrow = dorsal radiocarpal ligament.

ORIF





References

- http://www.wheelessonline.com/ortho/perilunate_dislocations
- **AJR:203, September 2014; Spectrum of Carpal Dislocations and Fracture-Dislocations: Imaging and Management:**
www.ajronline.org/doi/pdf/10.2214/AJR.13.11680
- <http://www.slideshare.net/kommireddy239/carpal-bone-fractures>
- <http://radsourc.us/carpal-instability/>