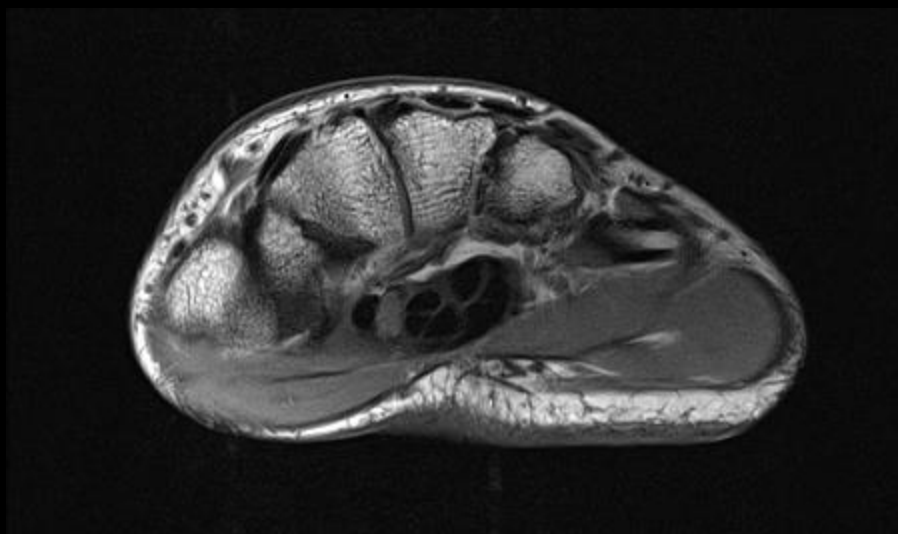
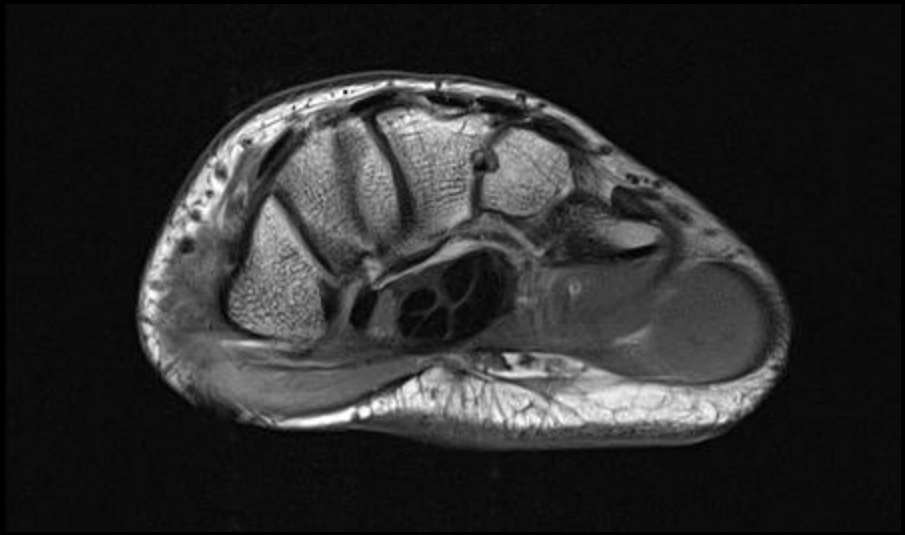


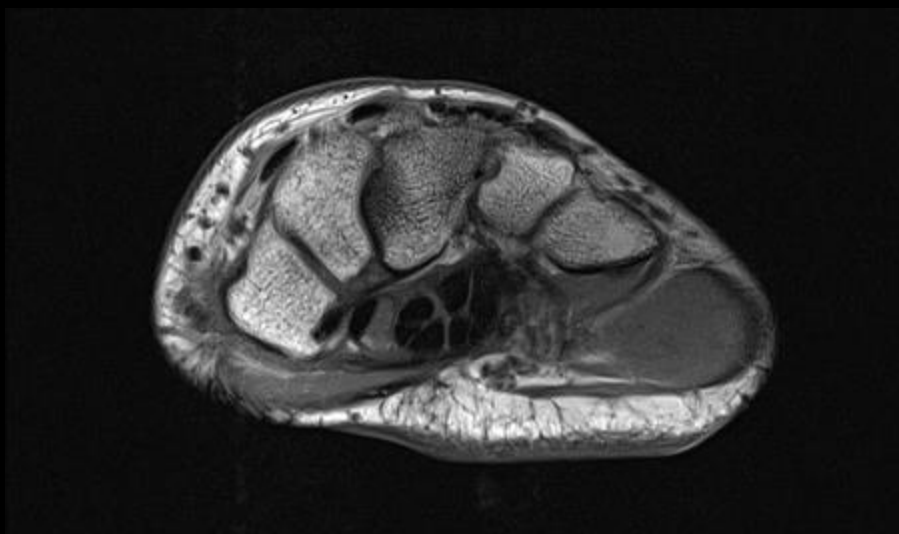


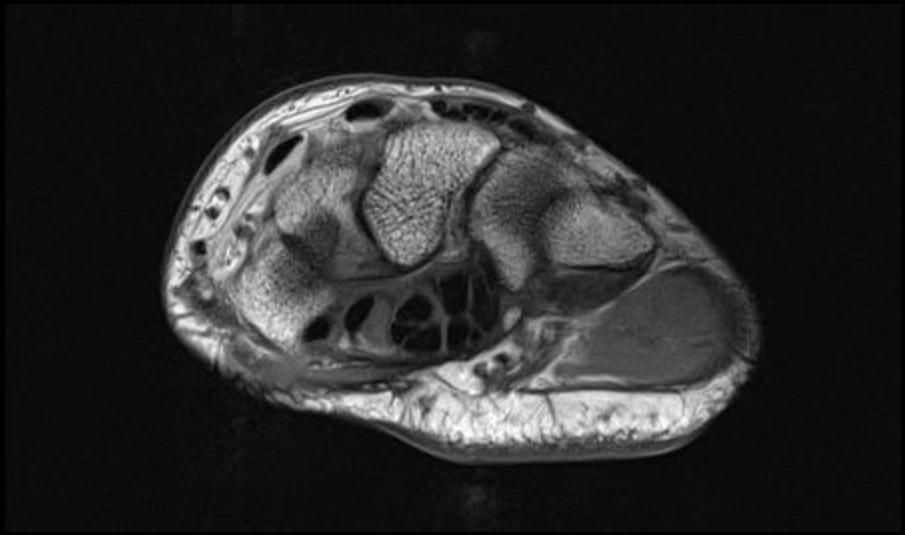
18 year old male with chronic wrist pain

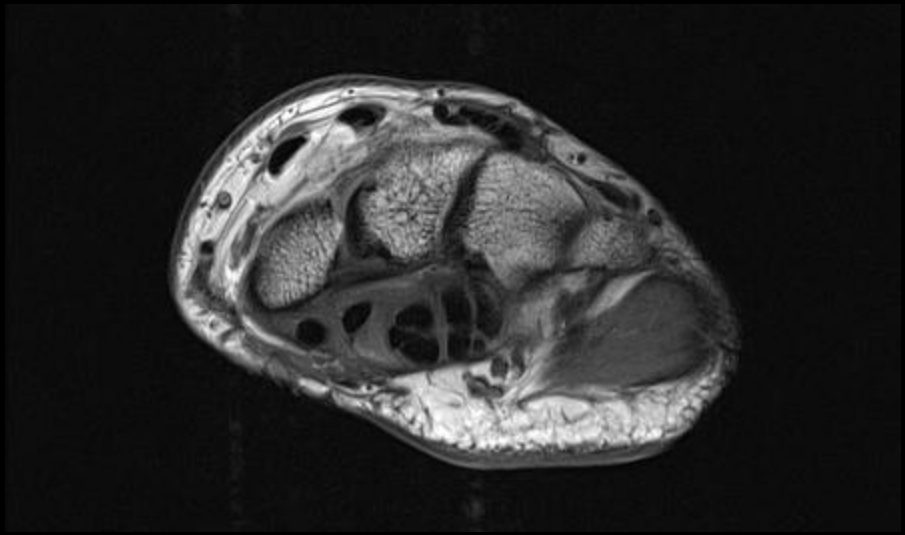
Amol Patil, MD.

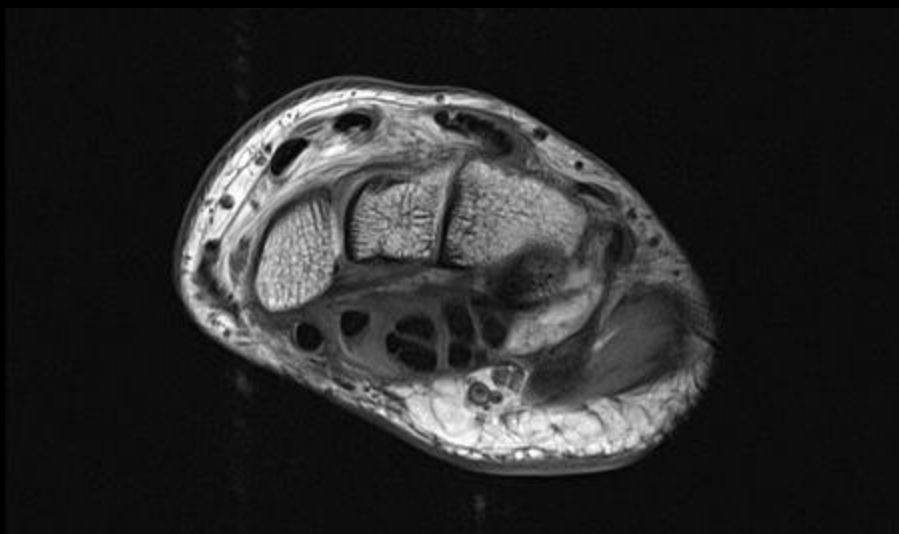


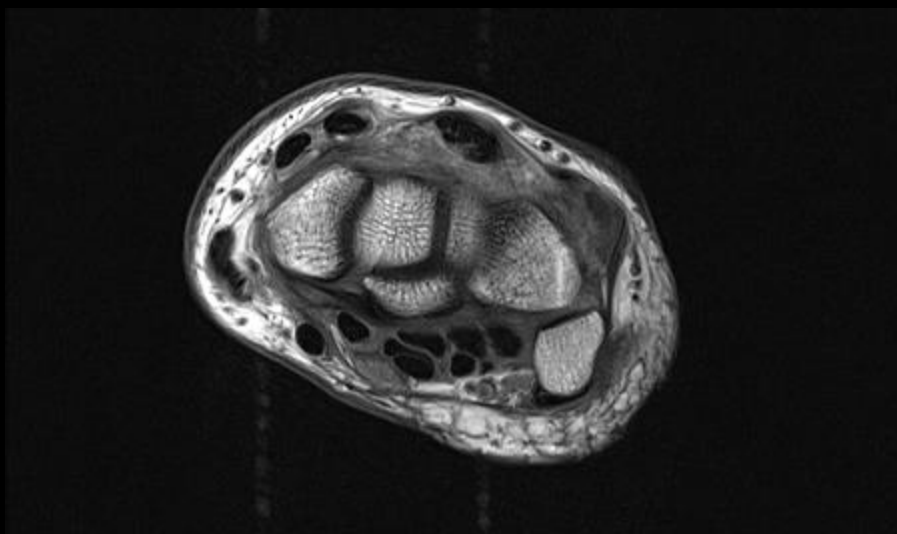


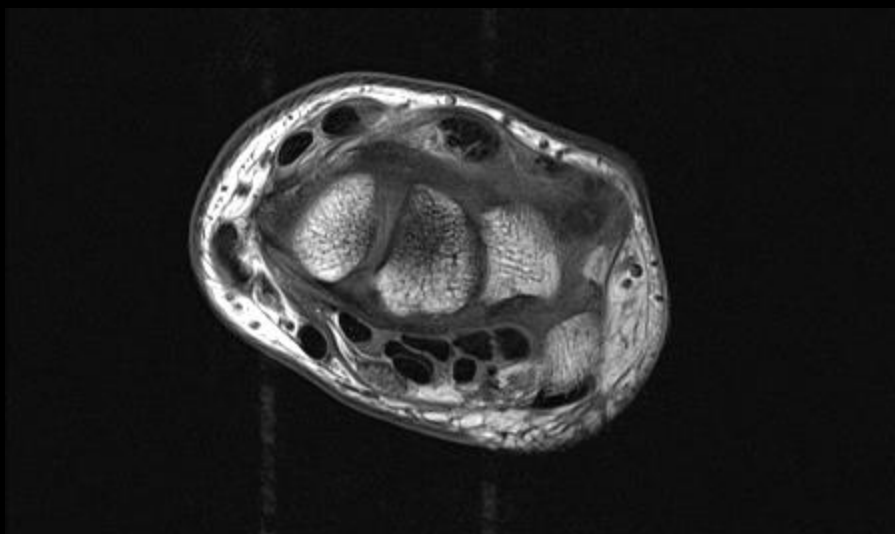


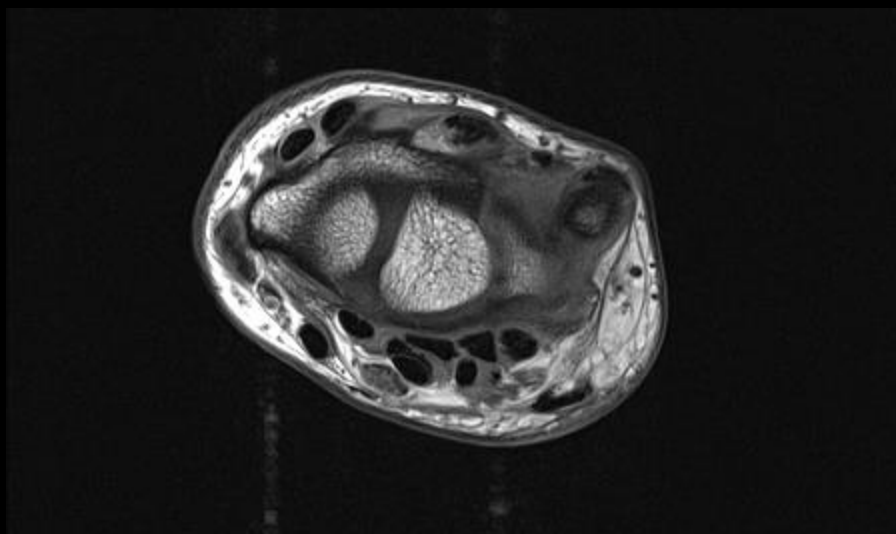


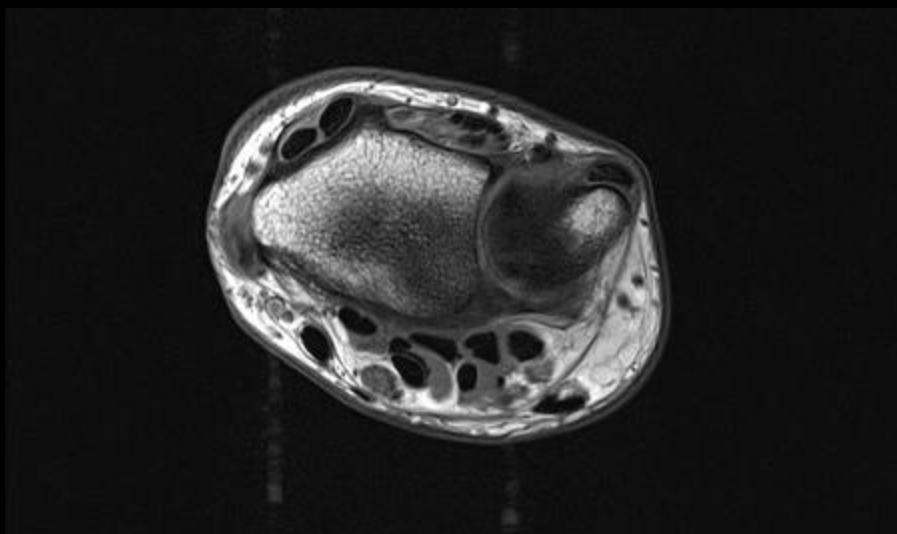


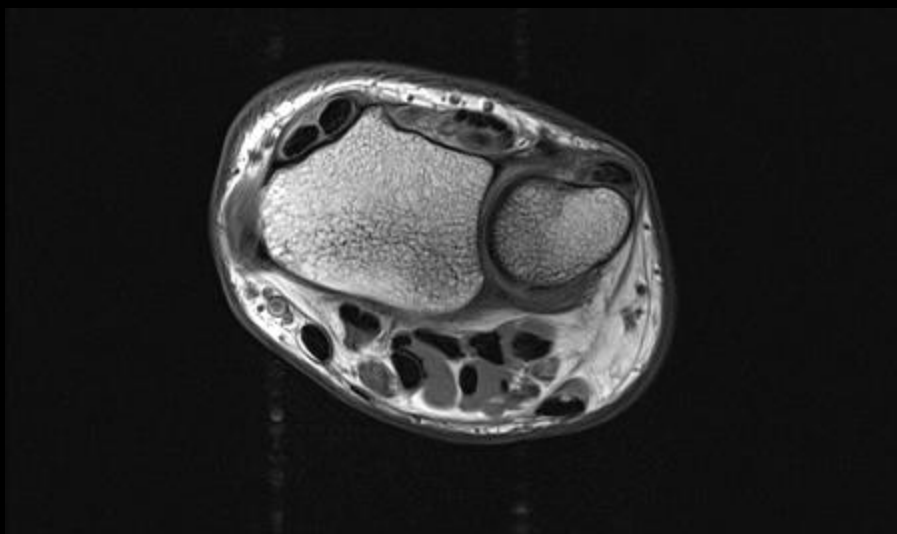


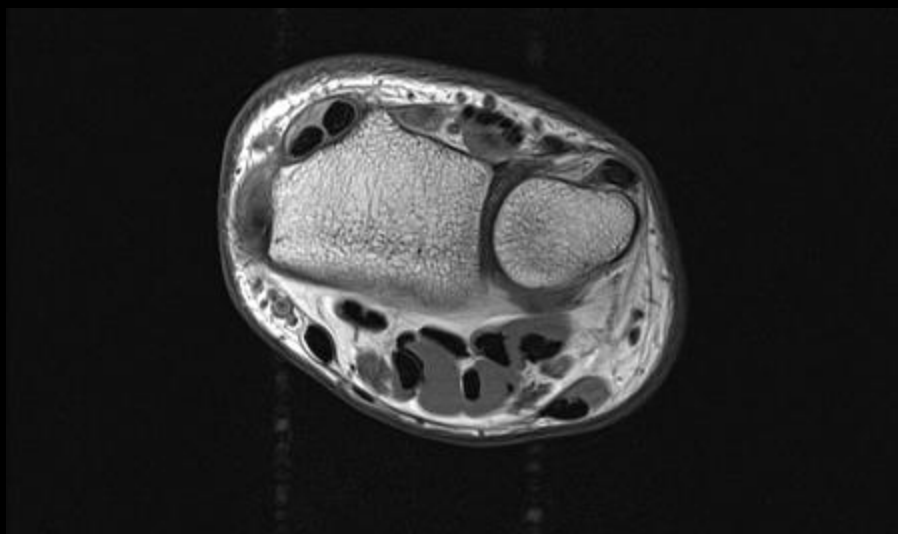

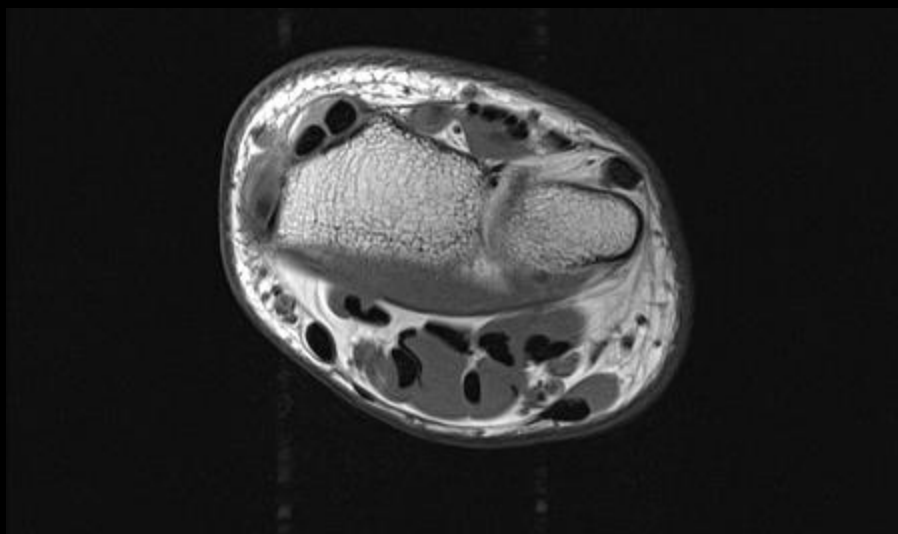


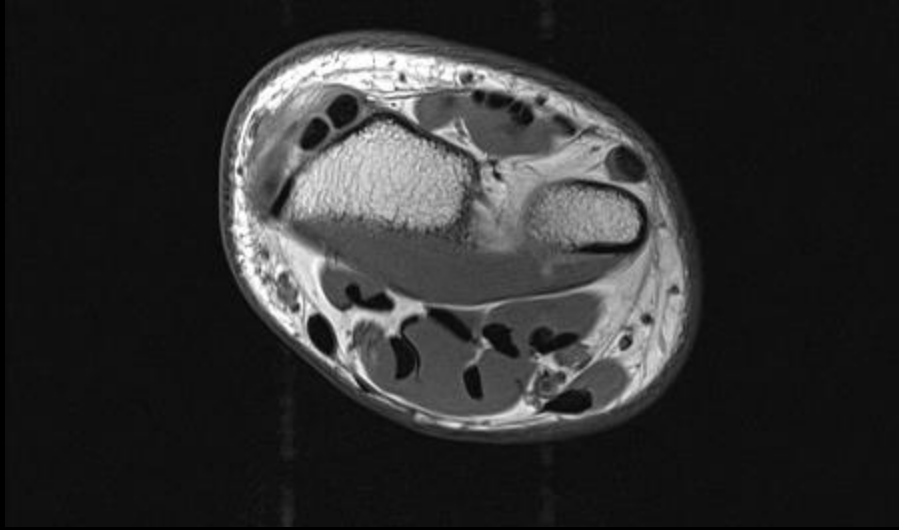


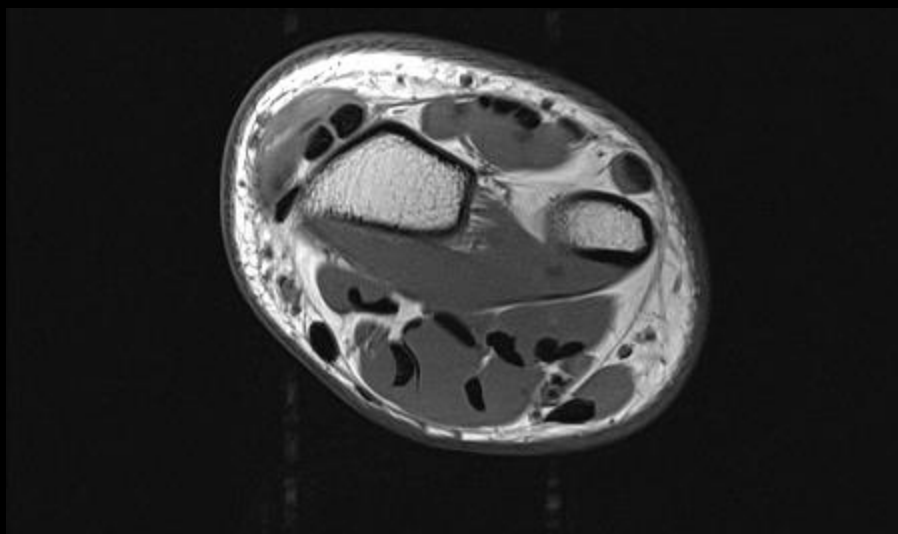


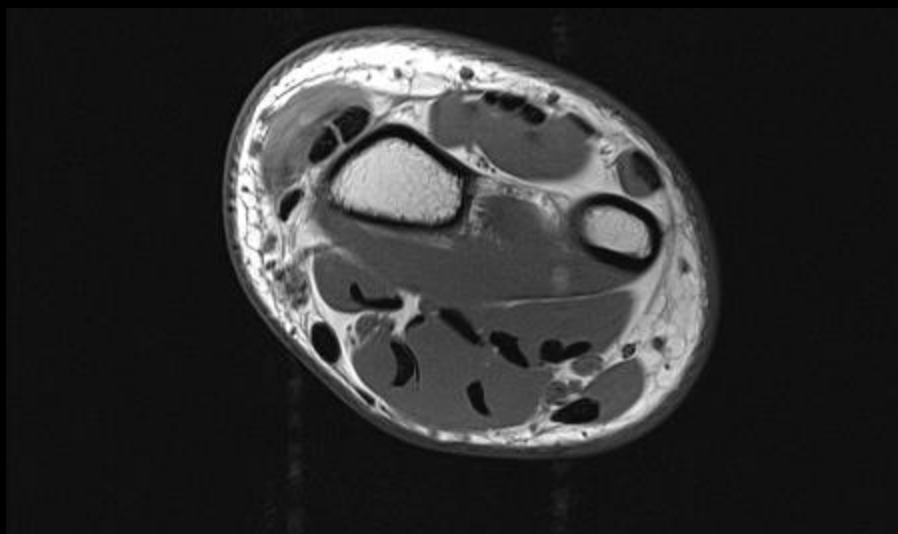


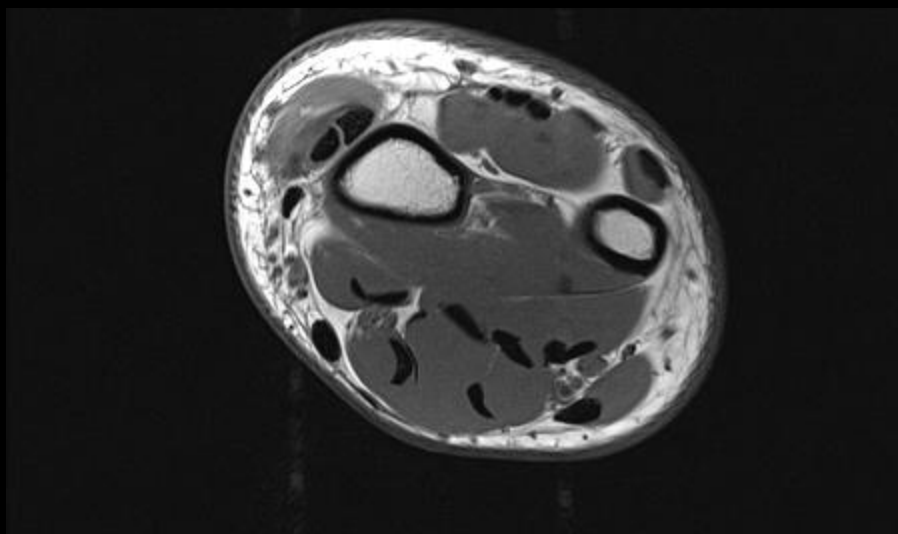


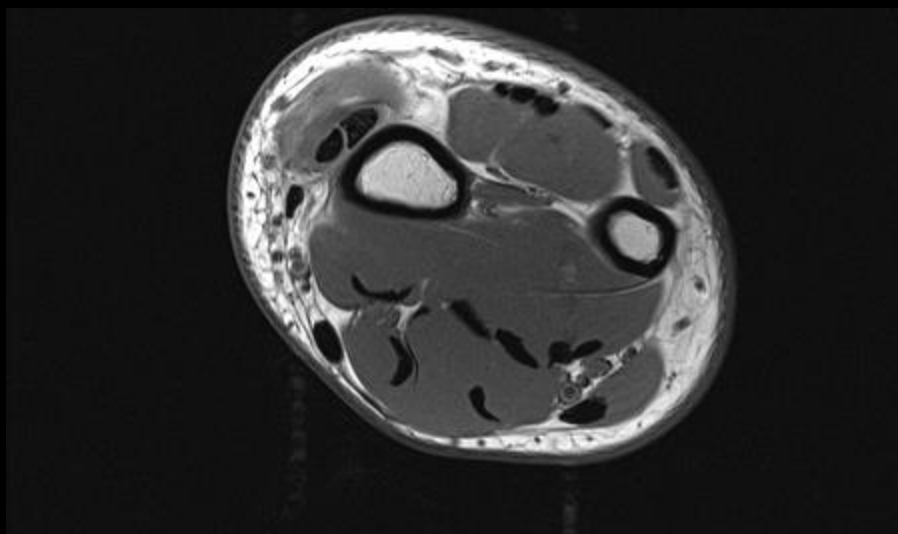


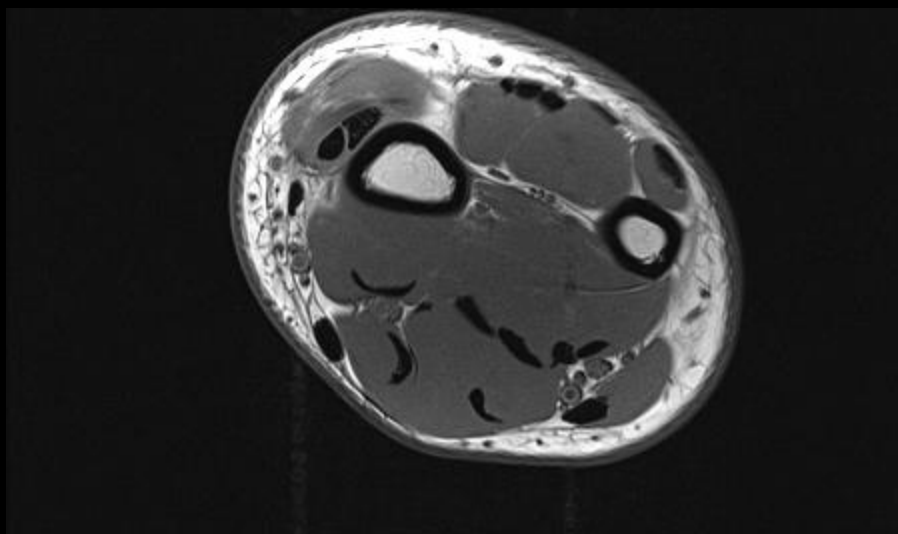


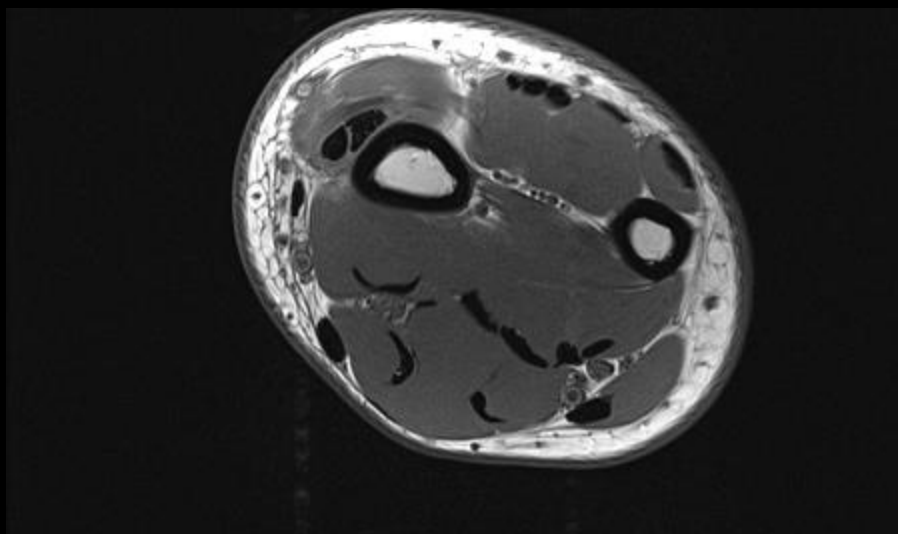


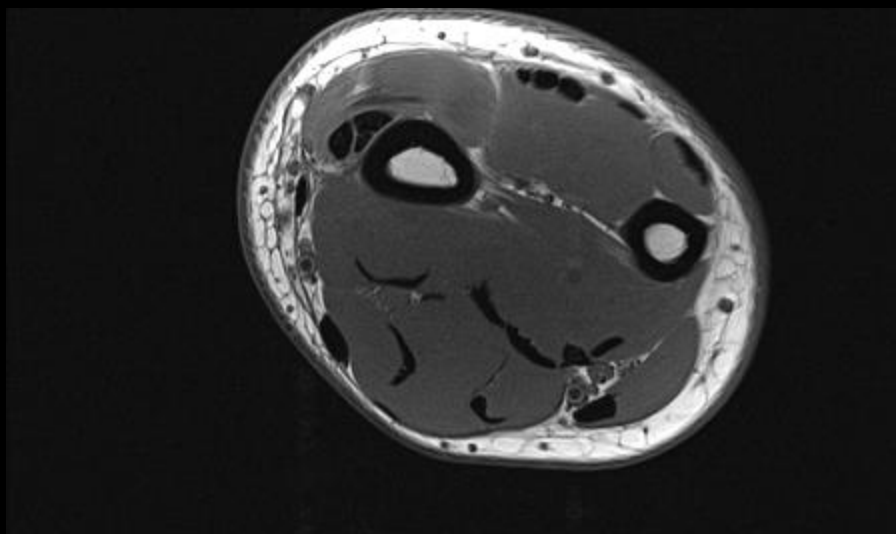


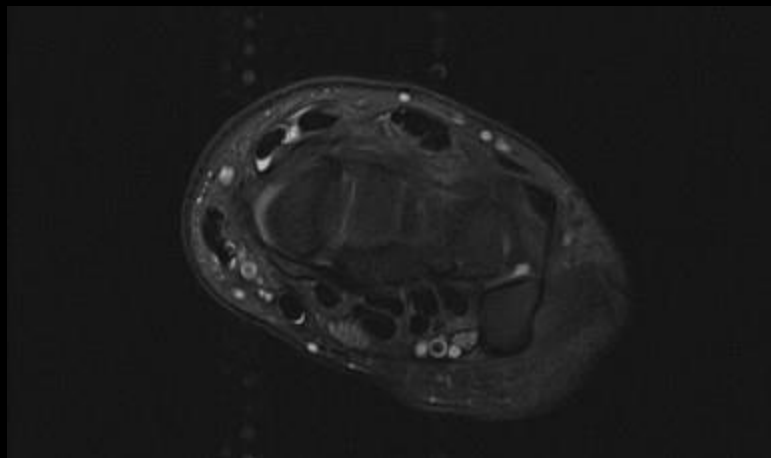


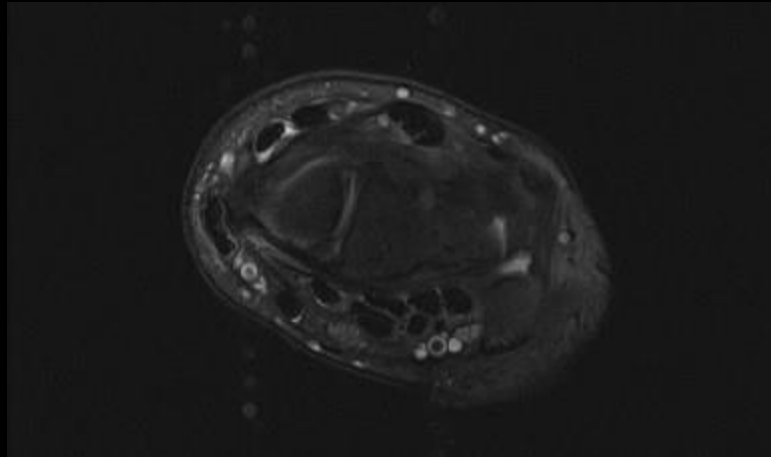


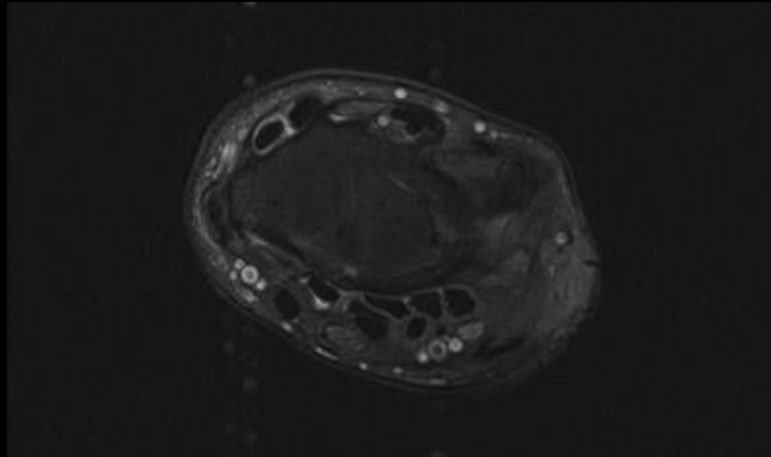


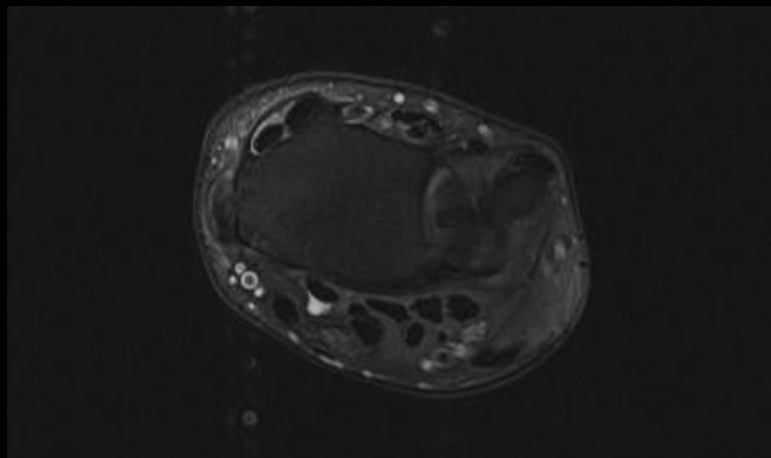


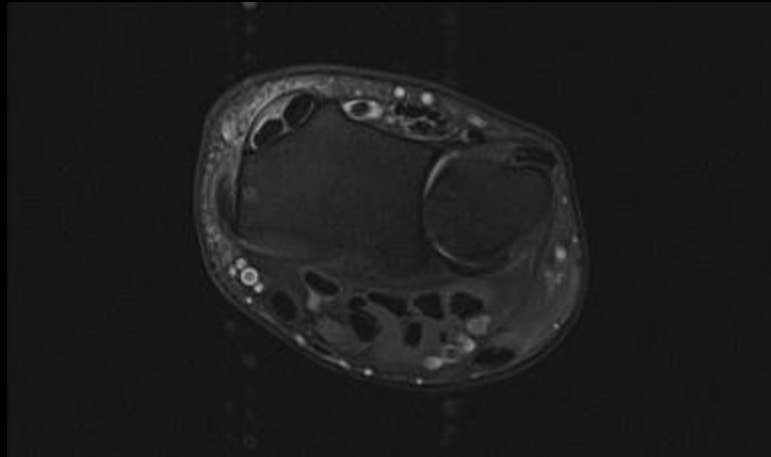


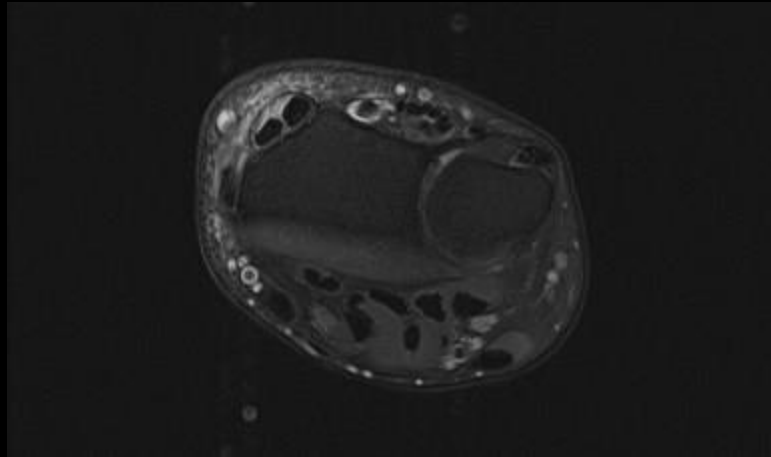


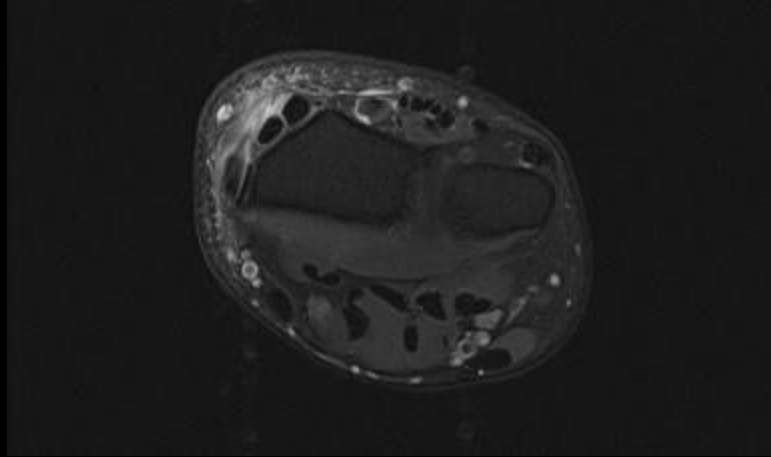


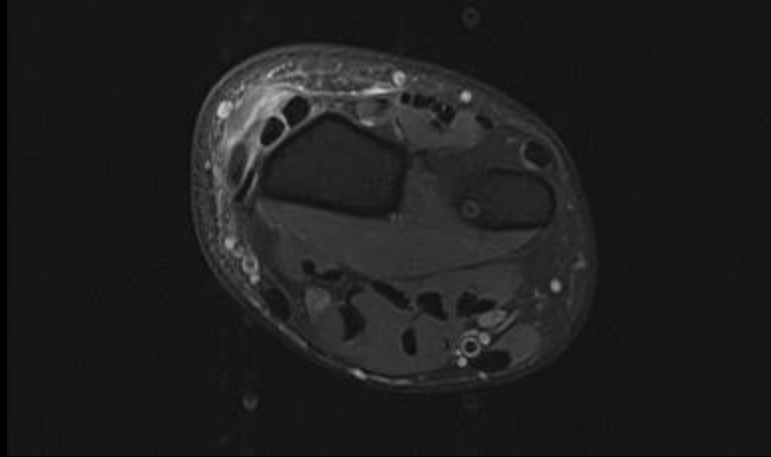


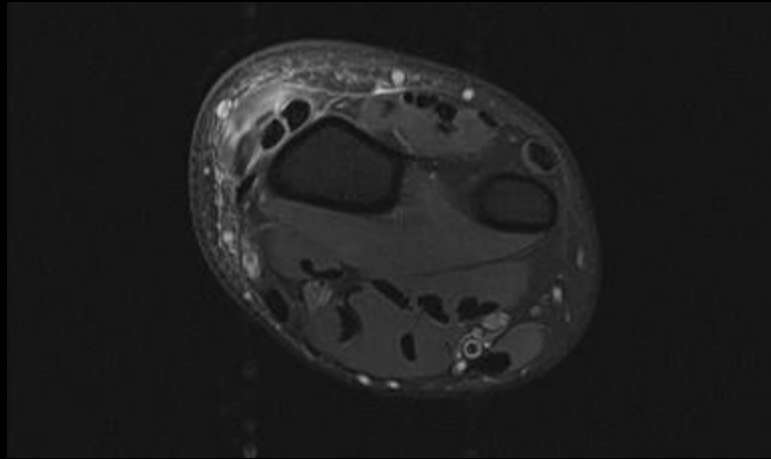


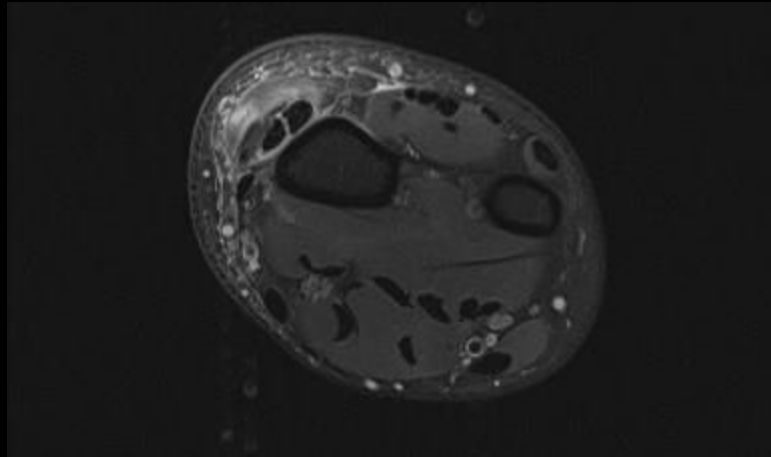


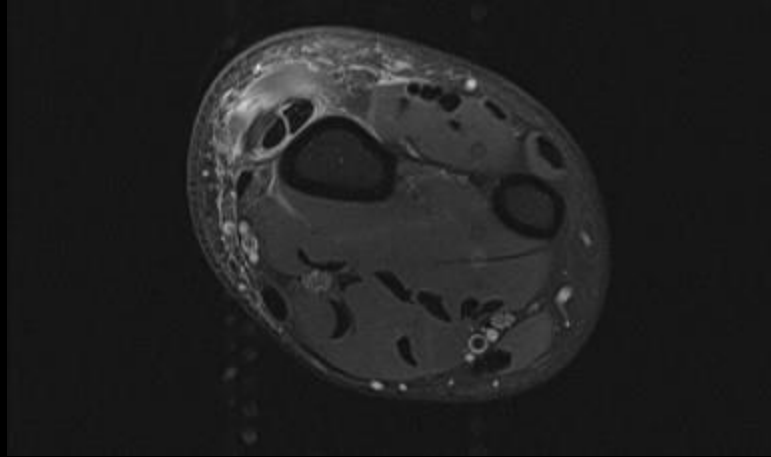


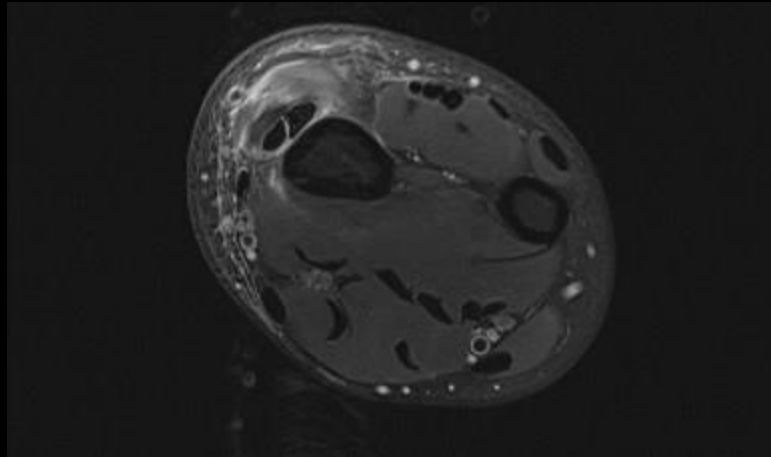


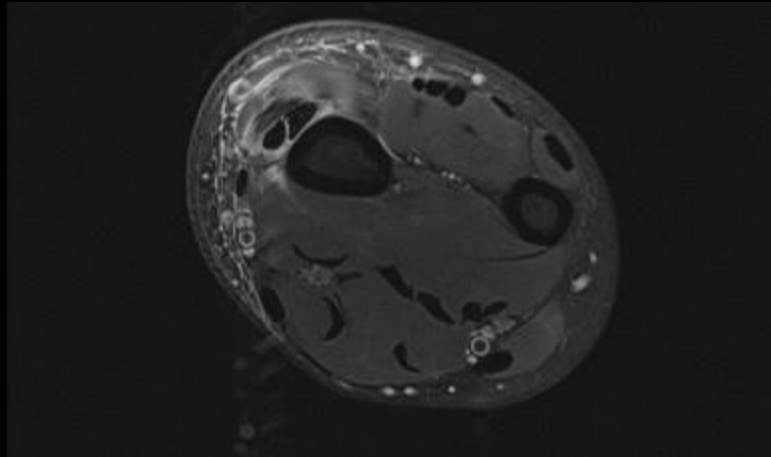


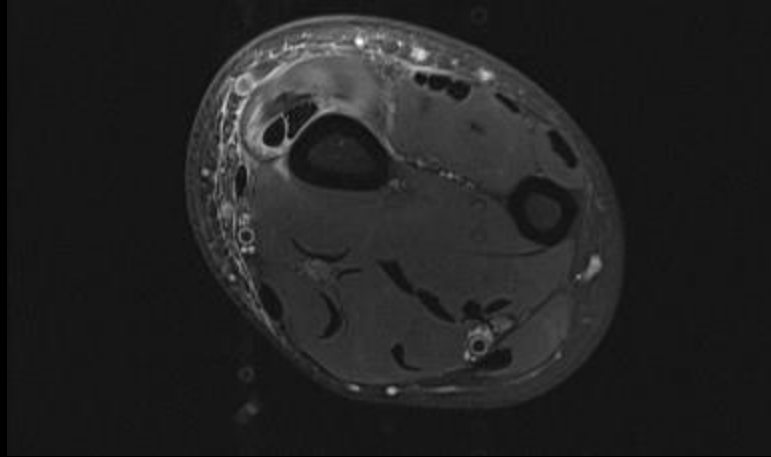


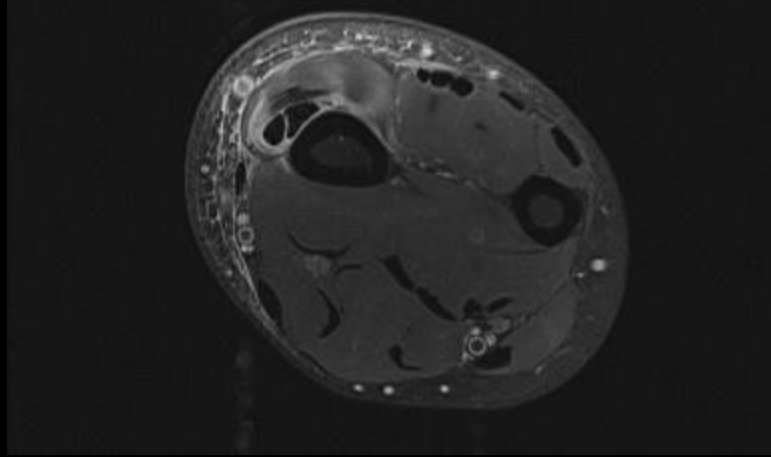


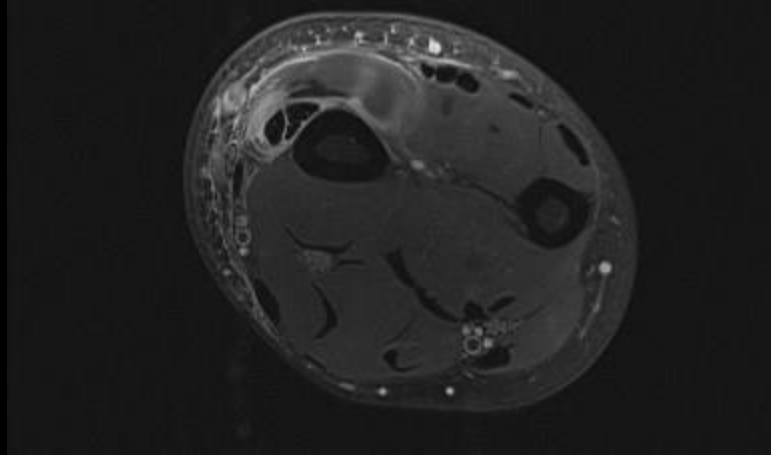


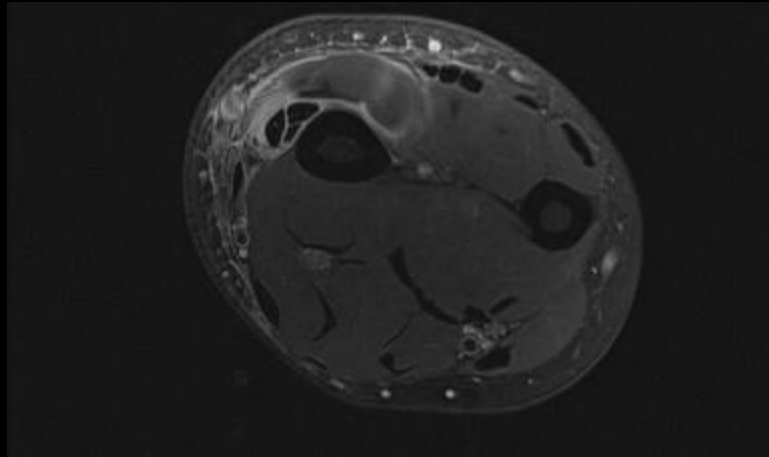


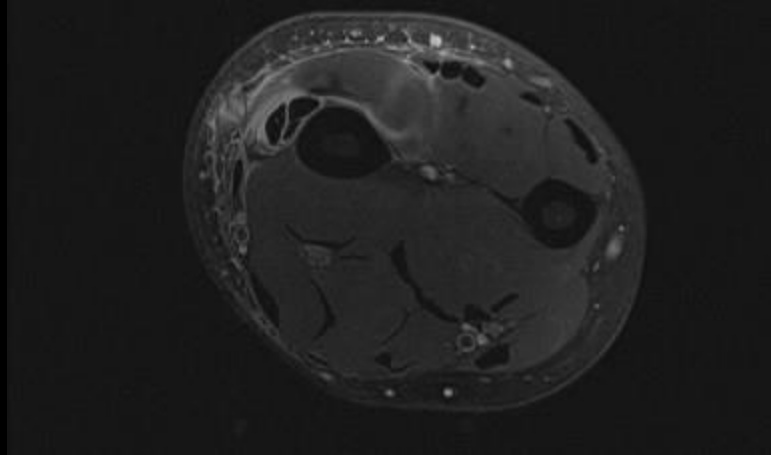


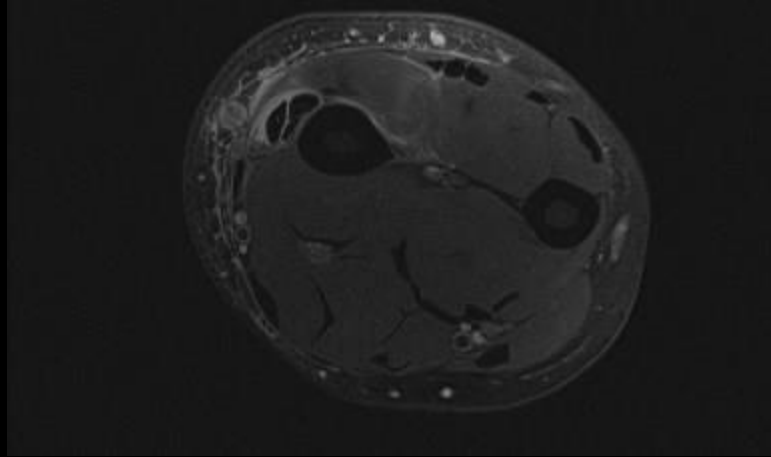


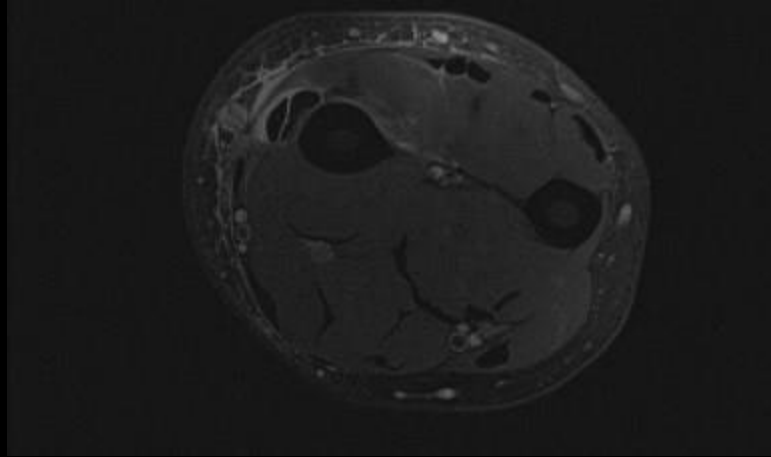


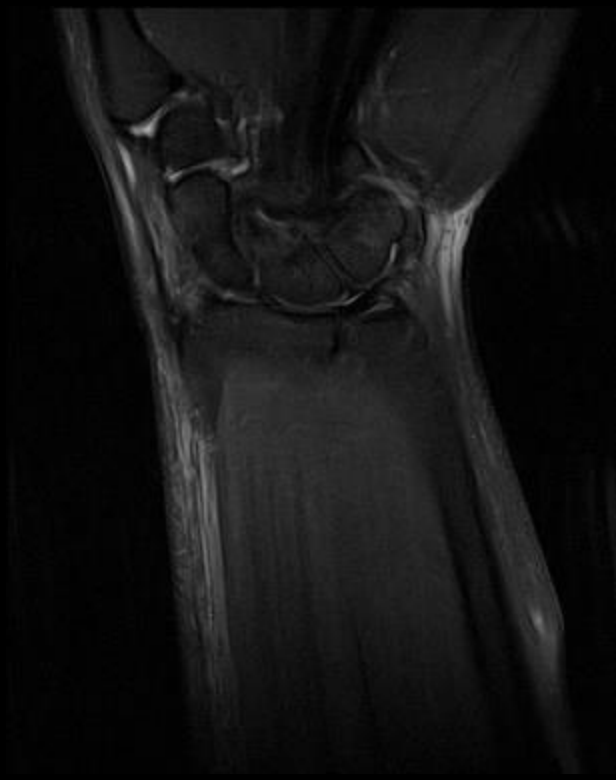



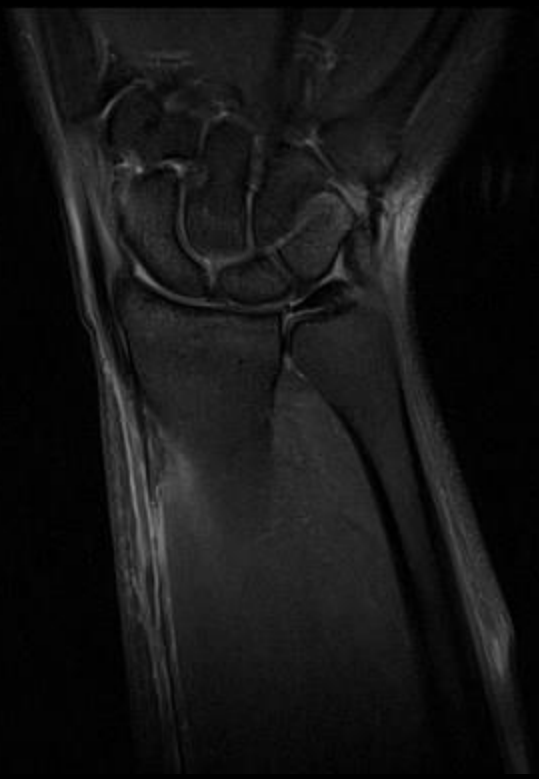


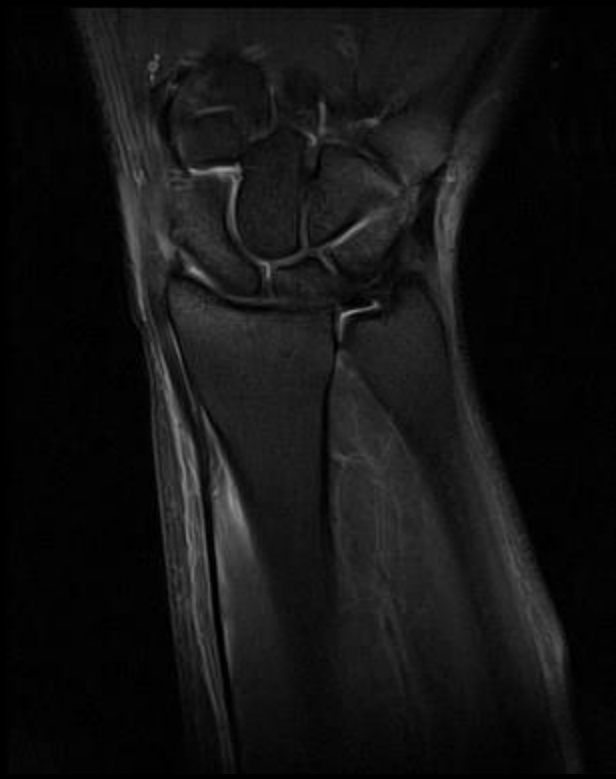


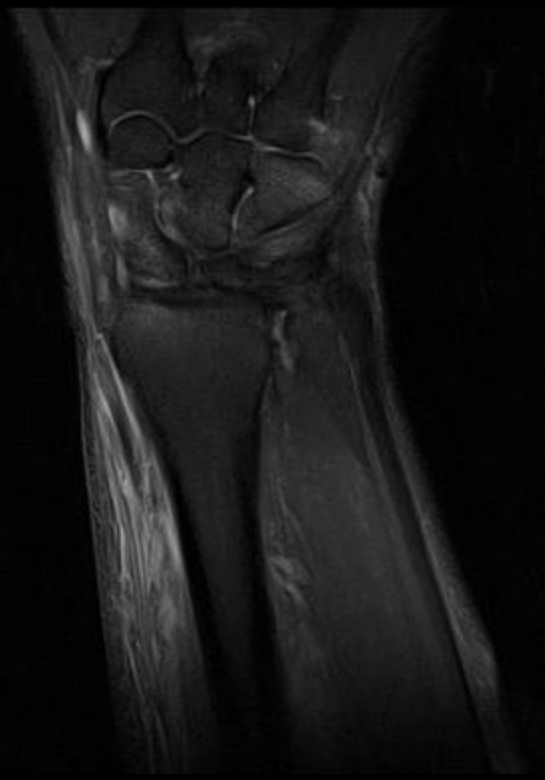


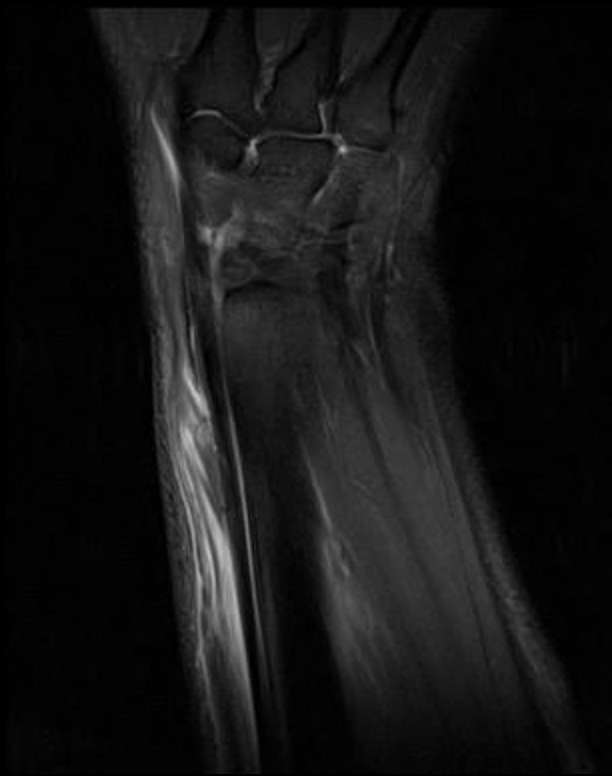

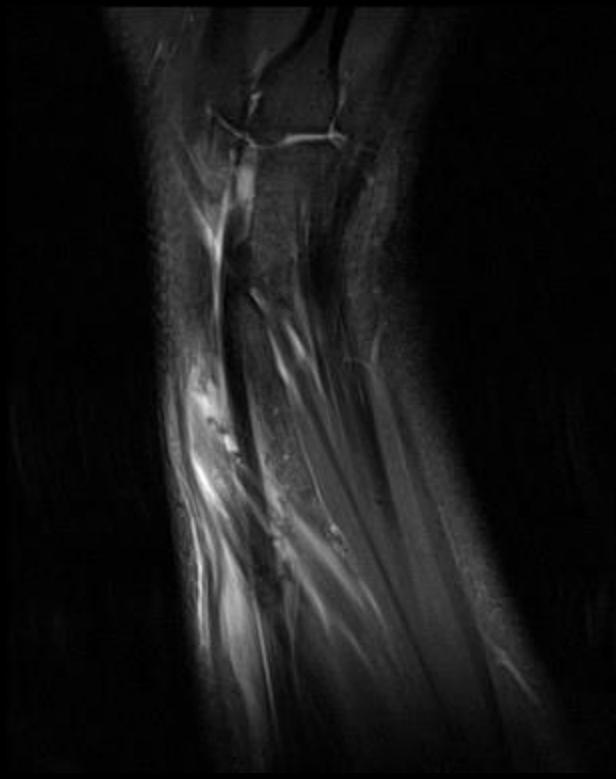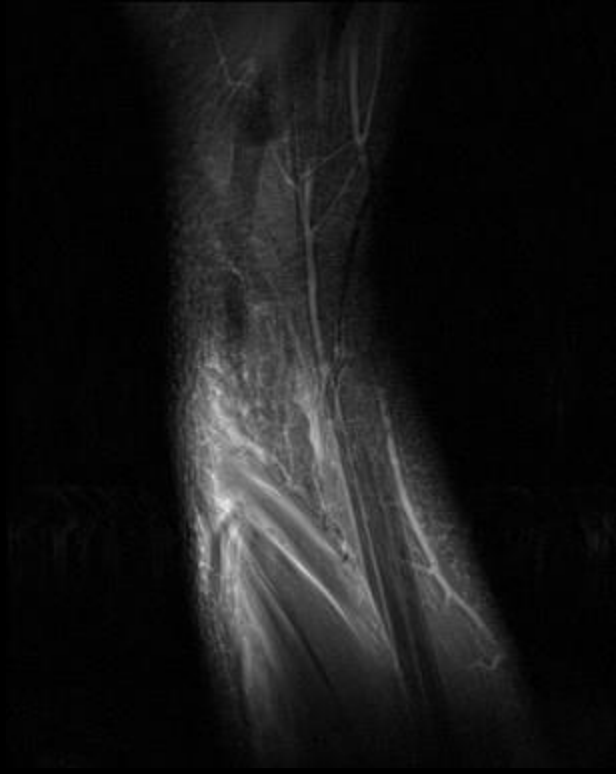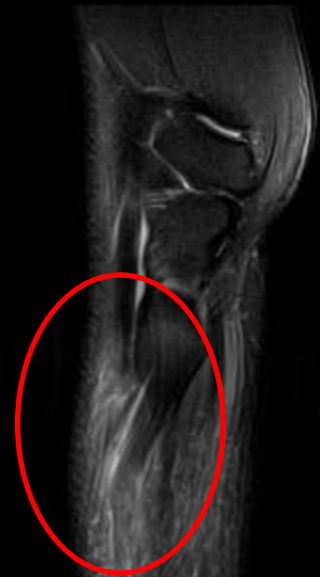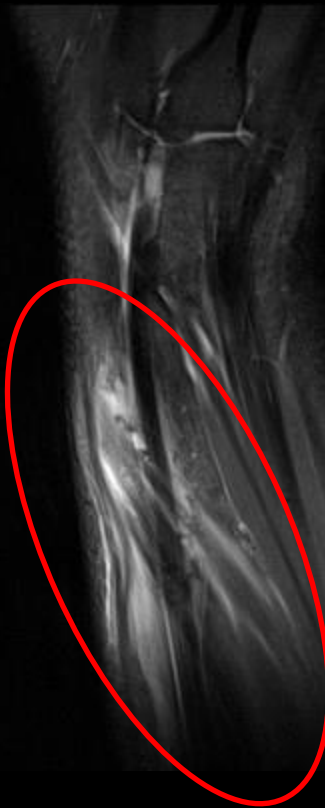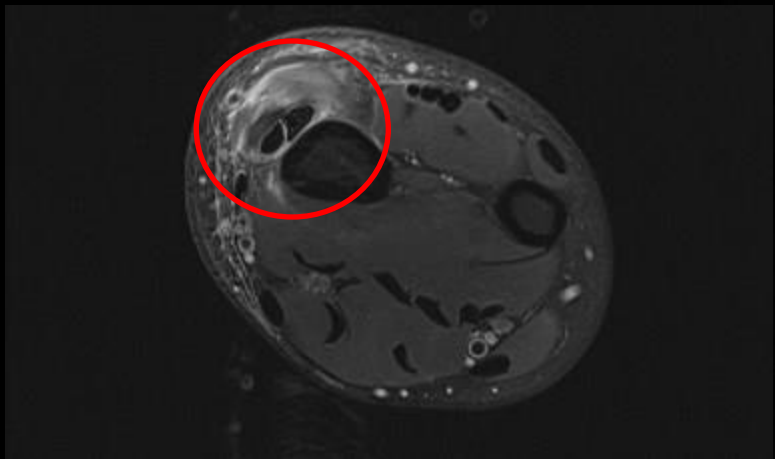












TENDON INTERSECTION SYNDROMES

- First described by Velpeau in 1841, and subsequently termed “intersection syndrome” by Dobyns et al. in 1978
- Synonyms :
 - Crossover syndrome
 - APL syndrome
 - Peritendinitis crepitans
 - Squeaker’s wrist
 - Oarsmen’s wrist
 - Bugaboo forearm
 - Subcutaneous perimyositis
- Pathogenesis: Overuse disorder of the dorsal distal forearm.

CLINICAL FEATURES

- Noninfectious inflammatory process of the second extensor compartment tendons of the forearm.
- Symptoms occur where the 1st extensor compartment tendons (APL & EPB) cross over the 2nd extensor compartment tendons (ECRL & ECRB).
- Pain and swelling proximal to the Lister's tubercle.
- Differential: De Quervain's tenosynovitis, wrist ligament sprain, ganglion cyst, tendinitis, and muscle strain.
- Typical demographic : Tennis players, skier's (repetitive dorsiflexion + radial deviation of the wrist against the resistance of deep snow on withdrawal of the planted ski pole)

PATHOLOGY

- Non-infectious peritendinous inflammation in the first and second dorsal extensor tendon compartments around their site of intersection.
- 4 to 8 cm proximal to Lister's tubercle.
- Exact etiology is still unclear, and may be **multifactorial**

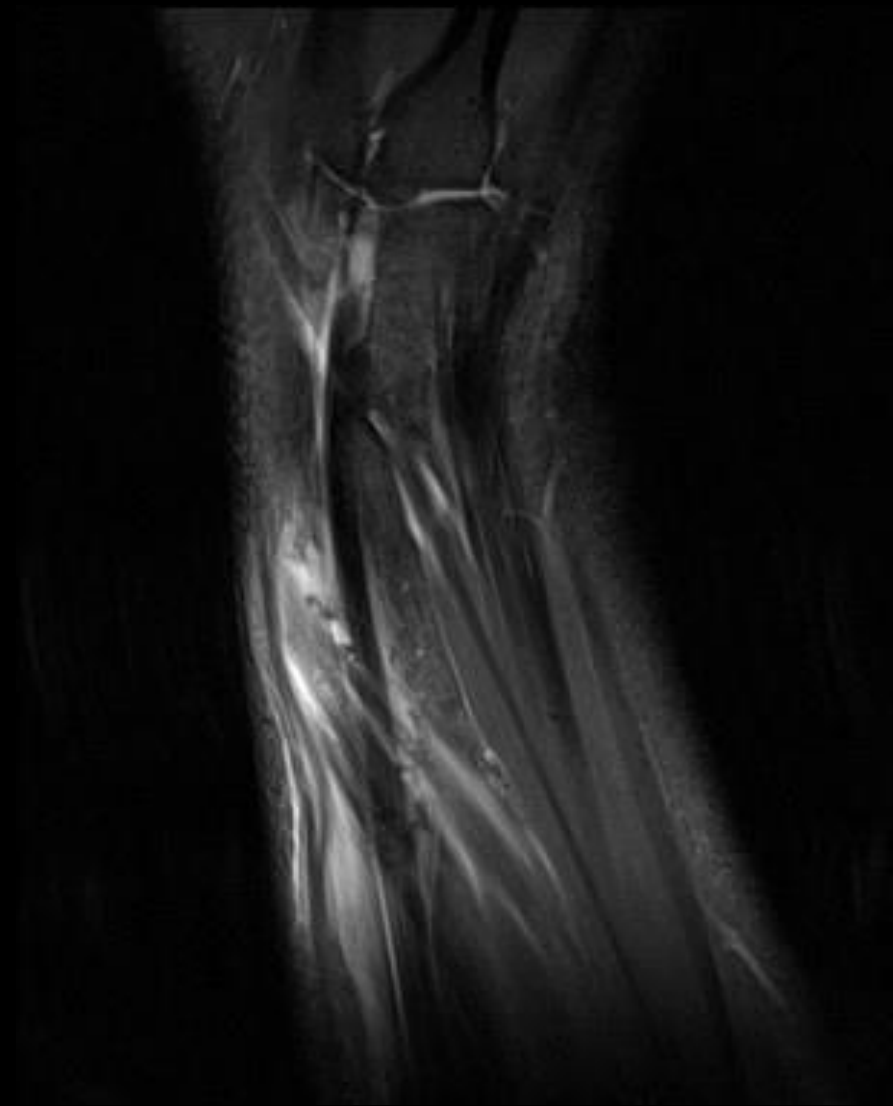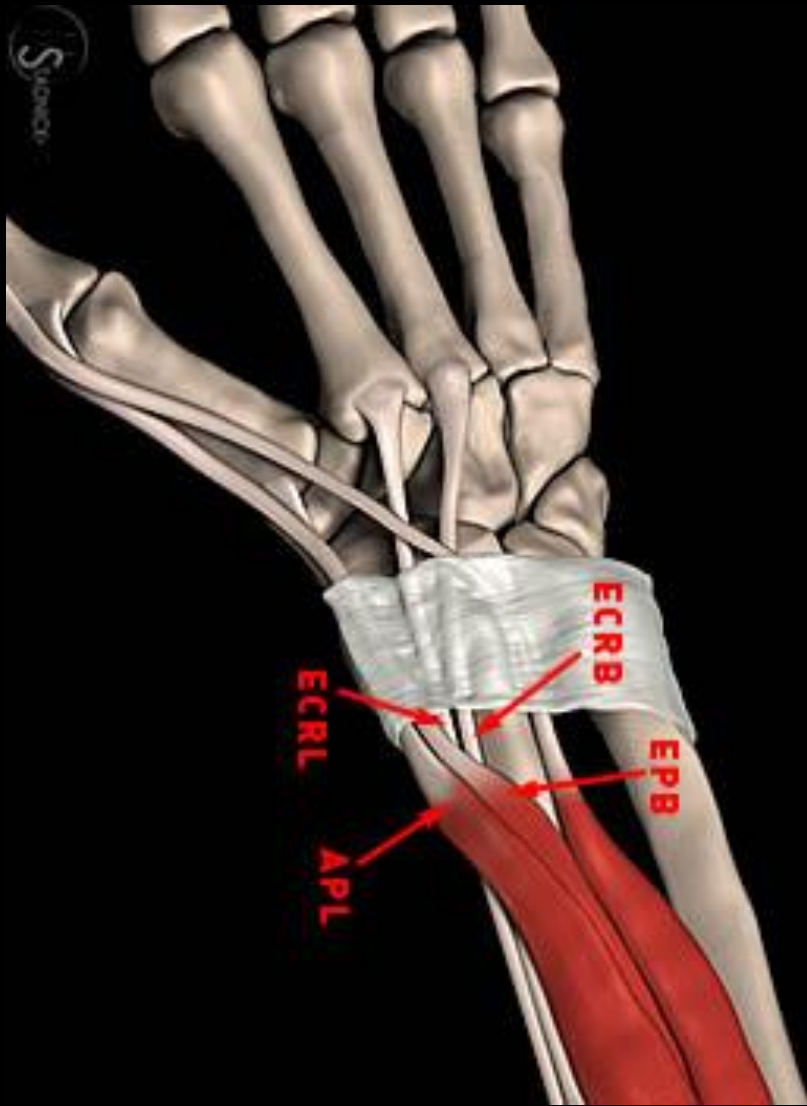
Mechanical friction between the two tendon compartments.

Stenosis of the 2nd extensor compartment  secondary inflammation first compartment tendons. (1985, Grundberg et al)

Extensor fascia of the forearm contributes to stenosis of the tendon compartments in this region. (Idler et al)

RELEVANT ANATOMY

- **APL & EPB** muscles originate from the posterior radius and interosseous membrane; tendons course in the **first dorsal extensor tendon compartment** toward their insertions on the thumb.
- **ECRL & ECRB** muscles originate at the lateral humeral epicondyle, and course in the **second dorsal extensor tendon compartment** toward their metacarpal insertions.
- 1st compartment tendons cross over the 2nd compartment tendons in the radial dorsal forearm, approximately 4 cm proximal to Lister's tubercle.
- Repetitive thumb and wrist motion results in friction between the crossing tendons

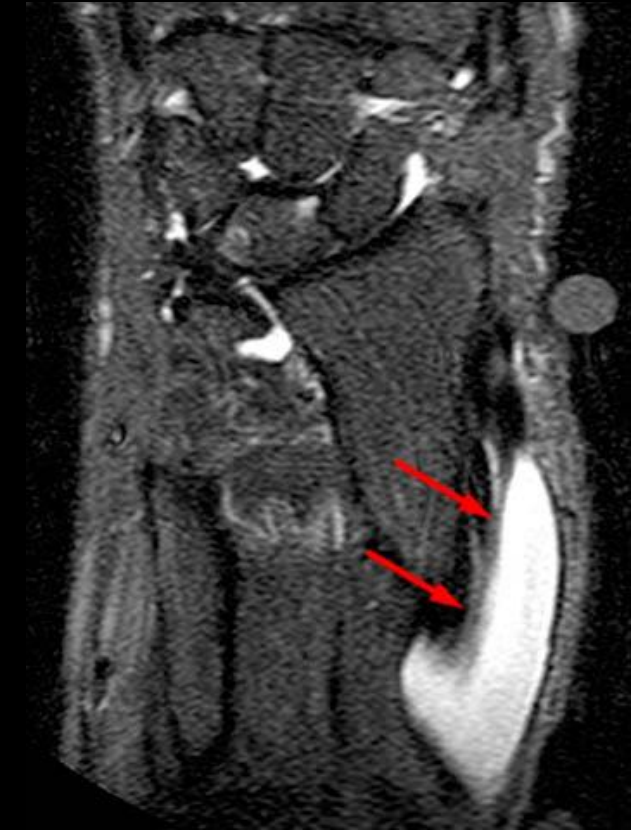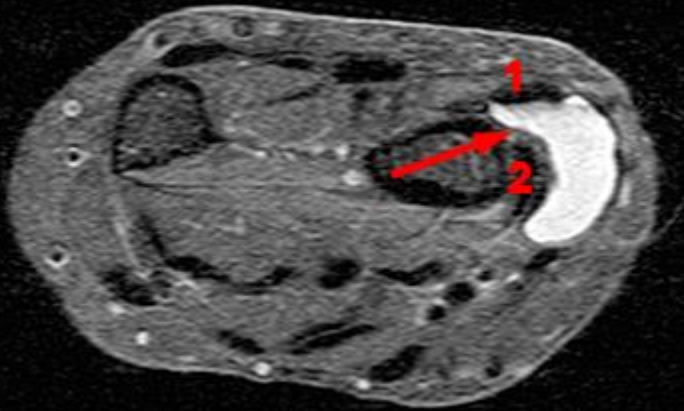


RADSOURCE (MRI Web Clinic 09/2012; Tendon intersection syndrome Leland Y. Tsao)

MRI IMAGING CHARACTERISTICS

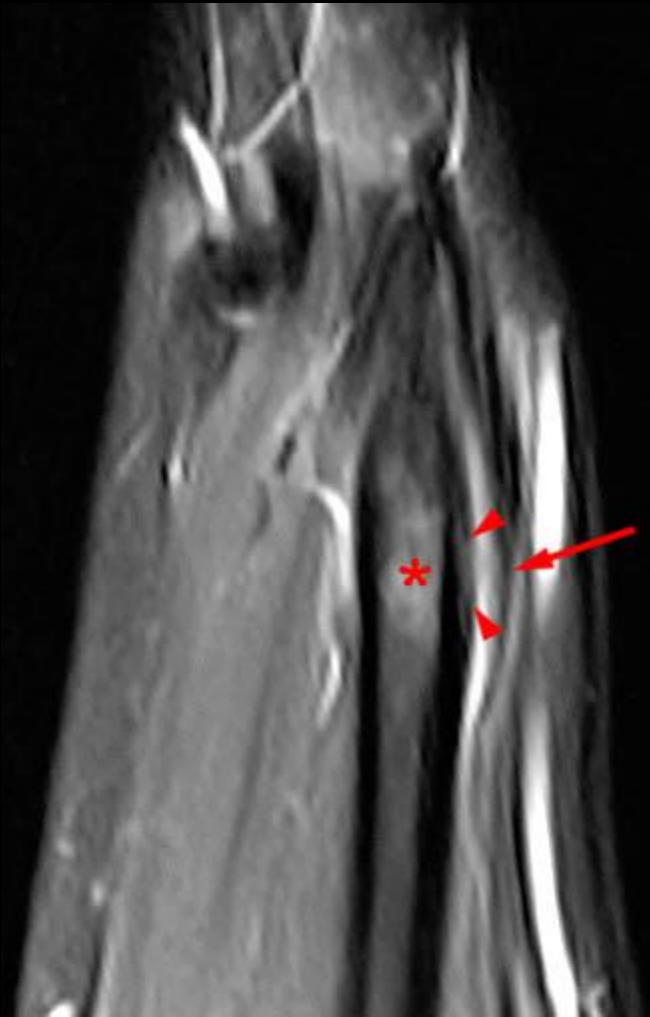
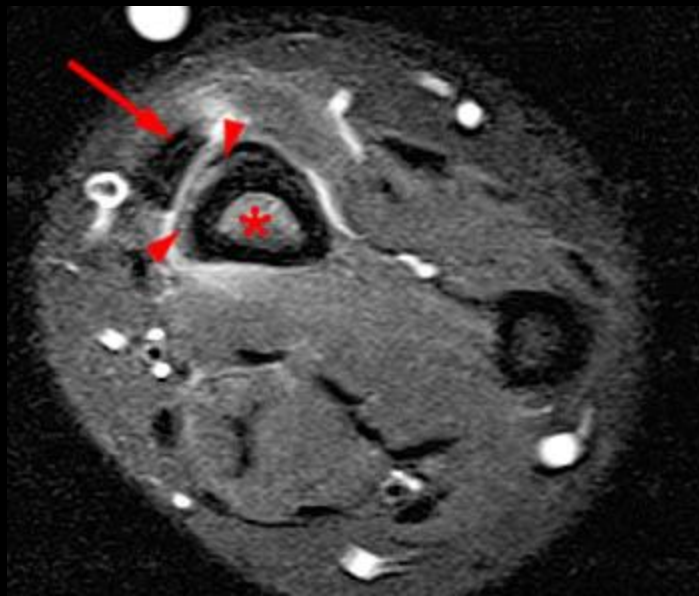
- MRI : Fluid sensitive sequences are the mainstay.
 - Peritendinous edema and fluid
 - Tendinosis
 - Muscular edema
 - Adventitial bursitis
 - Ganglion cyst
 - Periosteal edema
 - Enhancement in the areas of peritendinous edema.
- Role of Ultrasound

GANGLION CYST



RADSOURCE (MRI Web Clinic 09/2012; Tendon intersection syndrome Leland Y. Tsao)

PERIOSTEAL REACTION



RADSOURCE (MRI Web Clinic 09/2012; Tendon intersection syndrome Leland Y. Tsao)

MANAGEMENT

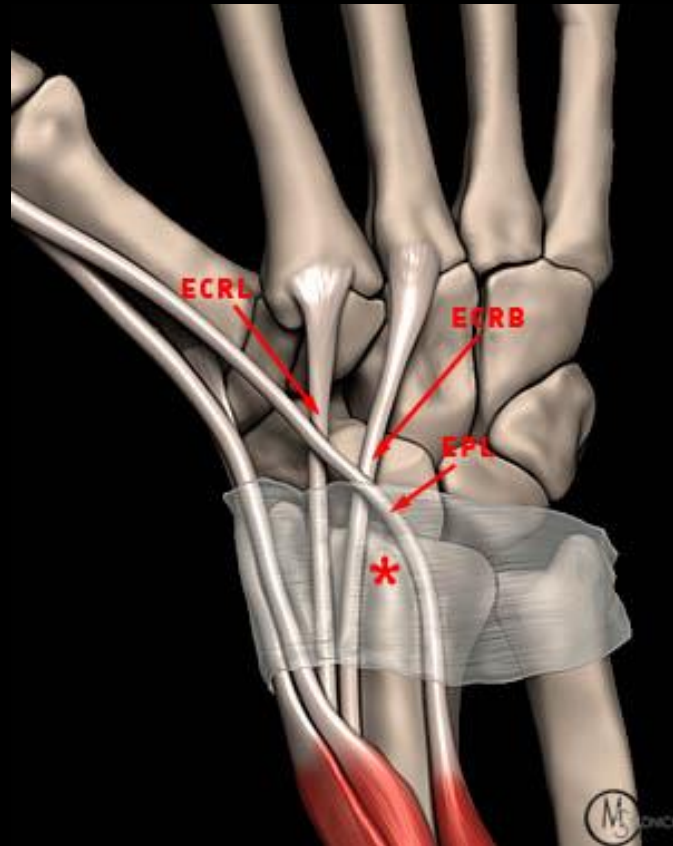
- Differential : DeQuervain's Tenosynovitis – Distal (early surgical intervention)
- Initial treatment - Rest and modification of activity, oral NSAIDs, ice, and splinting with the wrist in mild extension.

Taping the forearm.

Oral corticosteroids and injection of a local anesthetic and corticosteroid mixture.

Surgical synovectomy and Fasciotomy.

DISTAL INTERSECTION SYNDROME



RADSOURCE (MRI Web Clinic 09/2012; Tendon intersection syndrome Leland Y. Tsao)

REFERENCES

Dobyns JH, Sim FH, Linscheid RL. Sports stress syndromes of the hand and wrist. *Am J Sports Med.* 1978 Sep-Oct;6(5):236-54.

Palmer DH, Lane-Larsen CL. Helicopter skiing wrist injuries. A case report of “bugaboo forearm”. *Am J Sports Med.* 1994 Jan-Feb;22(1):148-9.

Hanlon DP, Luellen JR. Intersection syndrome: a case report and review of the literature. *J Emerg Med.* 1999 Nov-Dec;17(6):969-71.

Costa CR, Morrison WB, Carrino JA. MRI features of intersection syndrome of the forearm. *AJR Am J Roentgenol.* 2003 Nov;181(5):1245-9.

de Lima JE, Kim HJ, Albertotti F, Resnick D. Intersection syndrome: MR imaging with anatomic comparison of the distal forearm. *Skeletal Radiol.* 2004 Nov;33(11):627-31. Epub 2004 Sep 10.