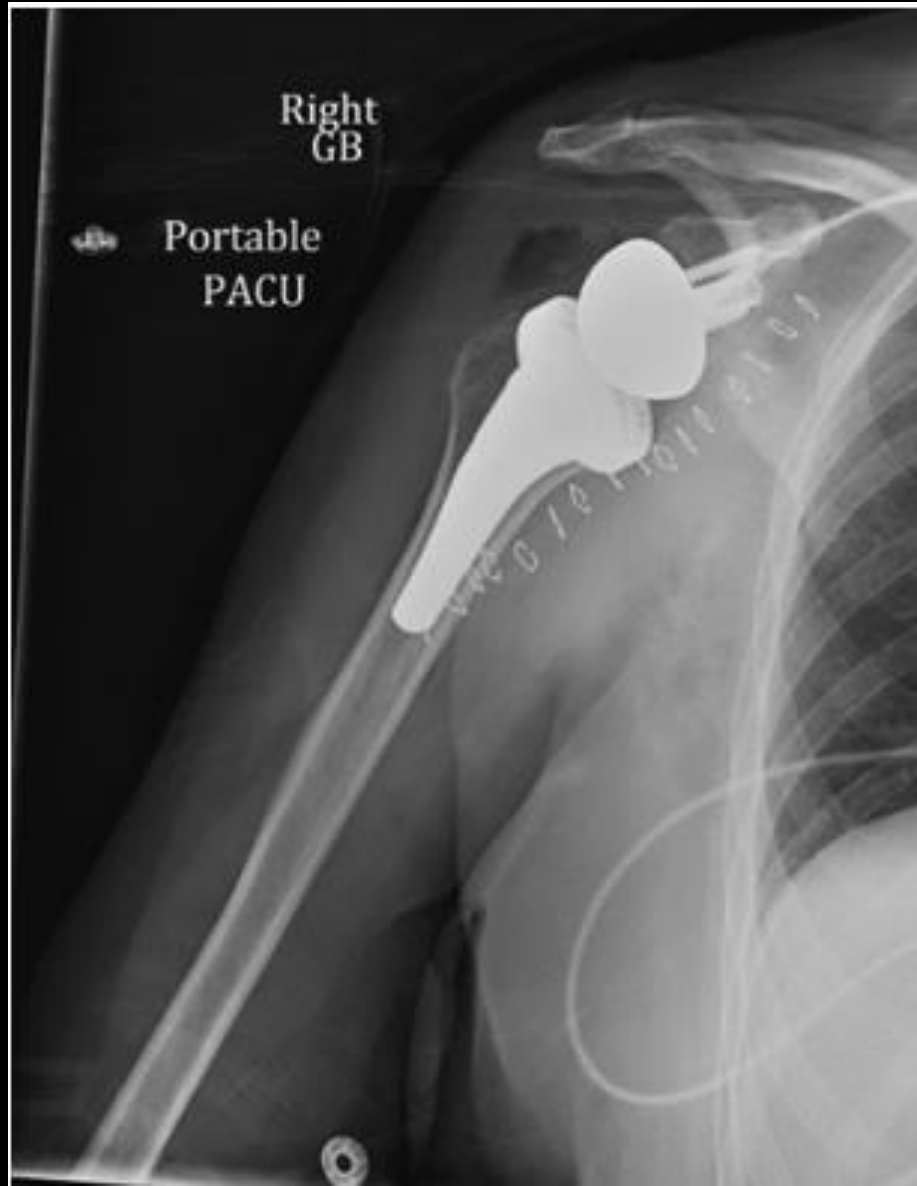

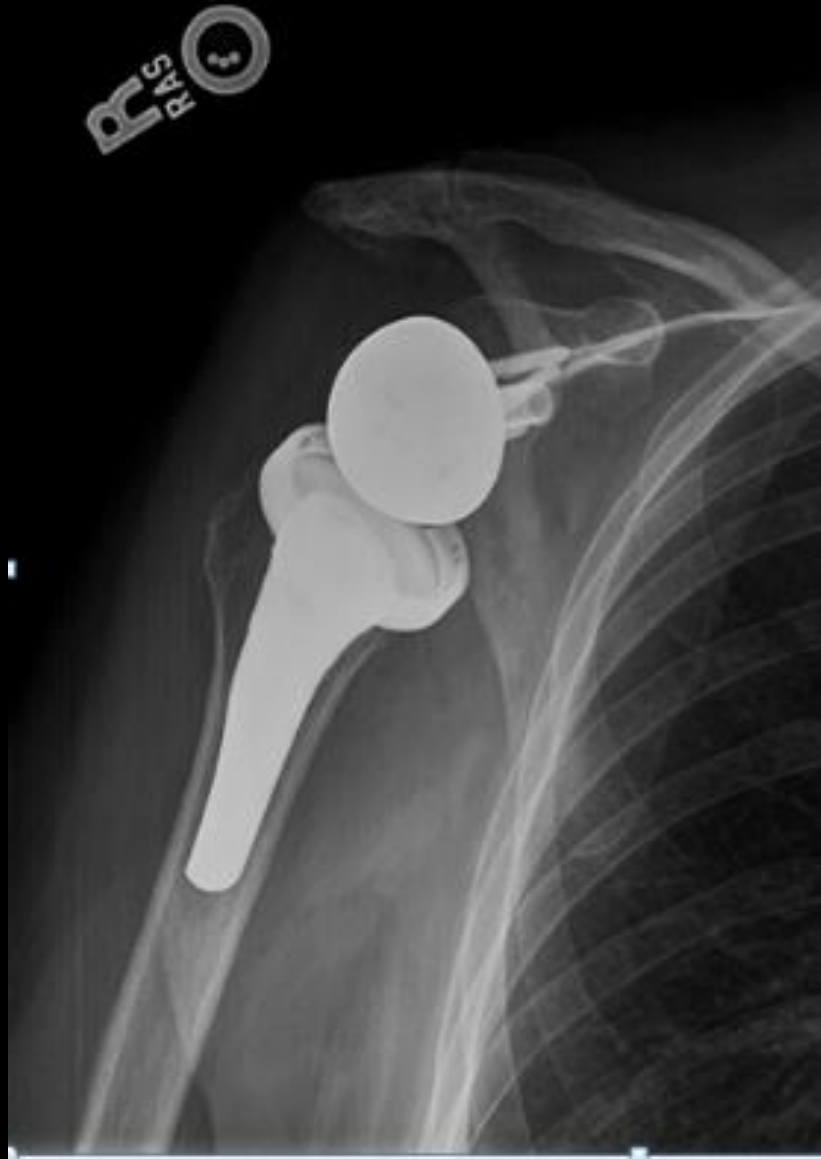59 y/o with RTSA for massive RTC
tear and “pseudoparalysis”.

Now 10 weeks post op imaging after
regaining motion

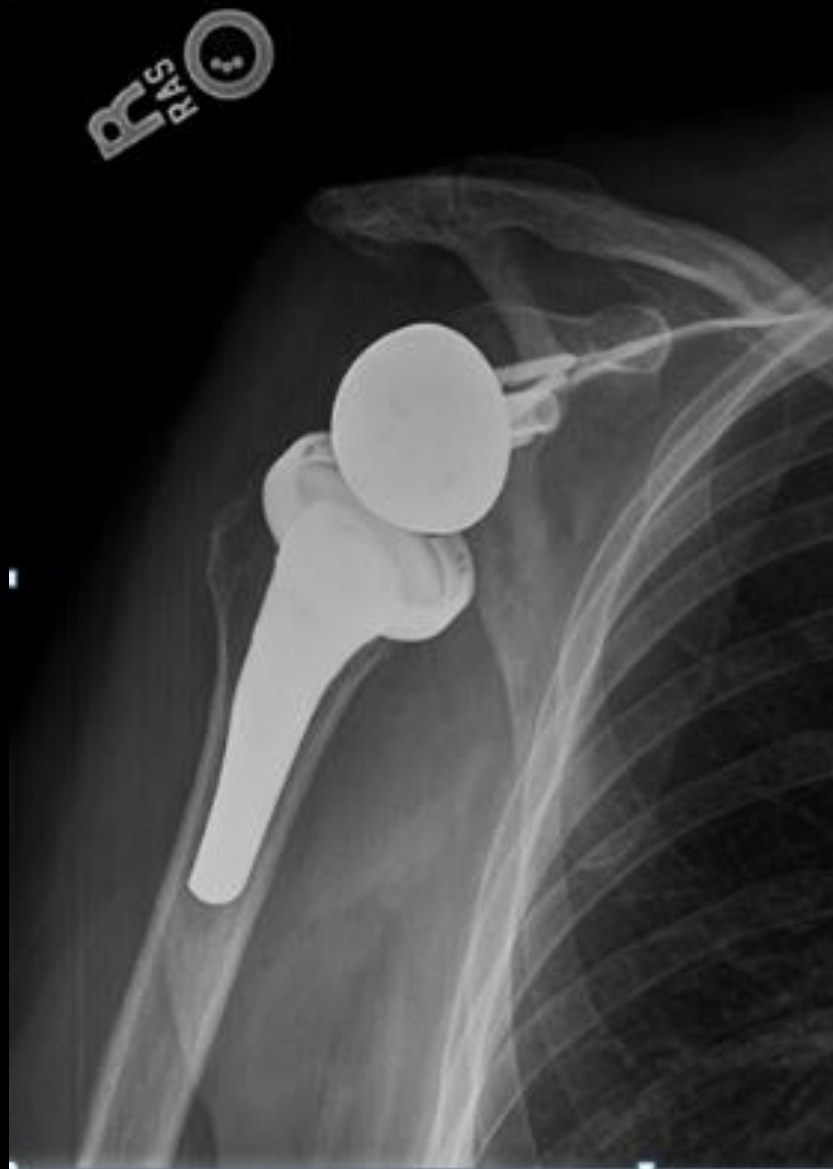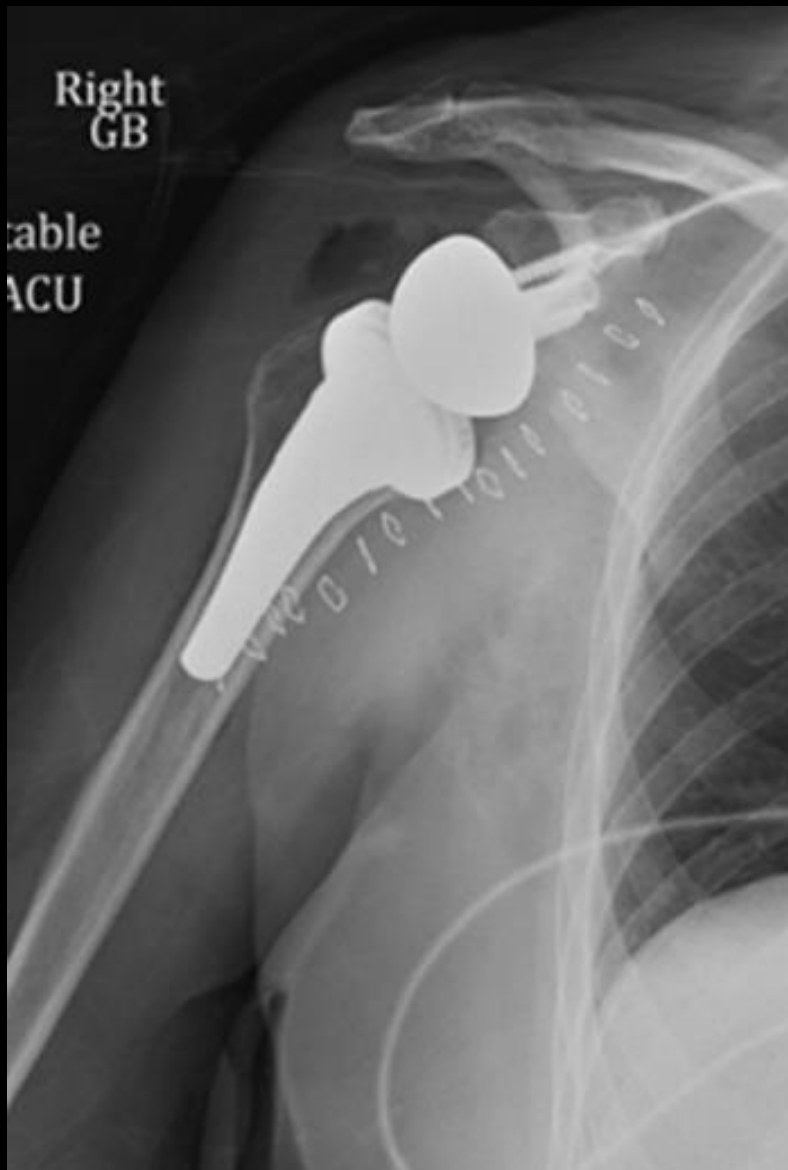
POD 1



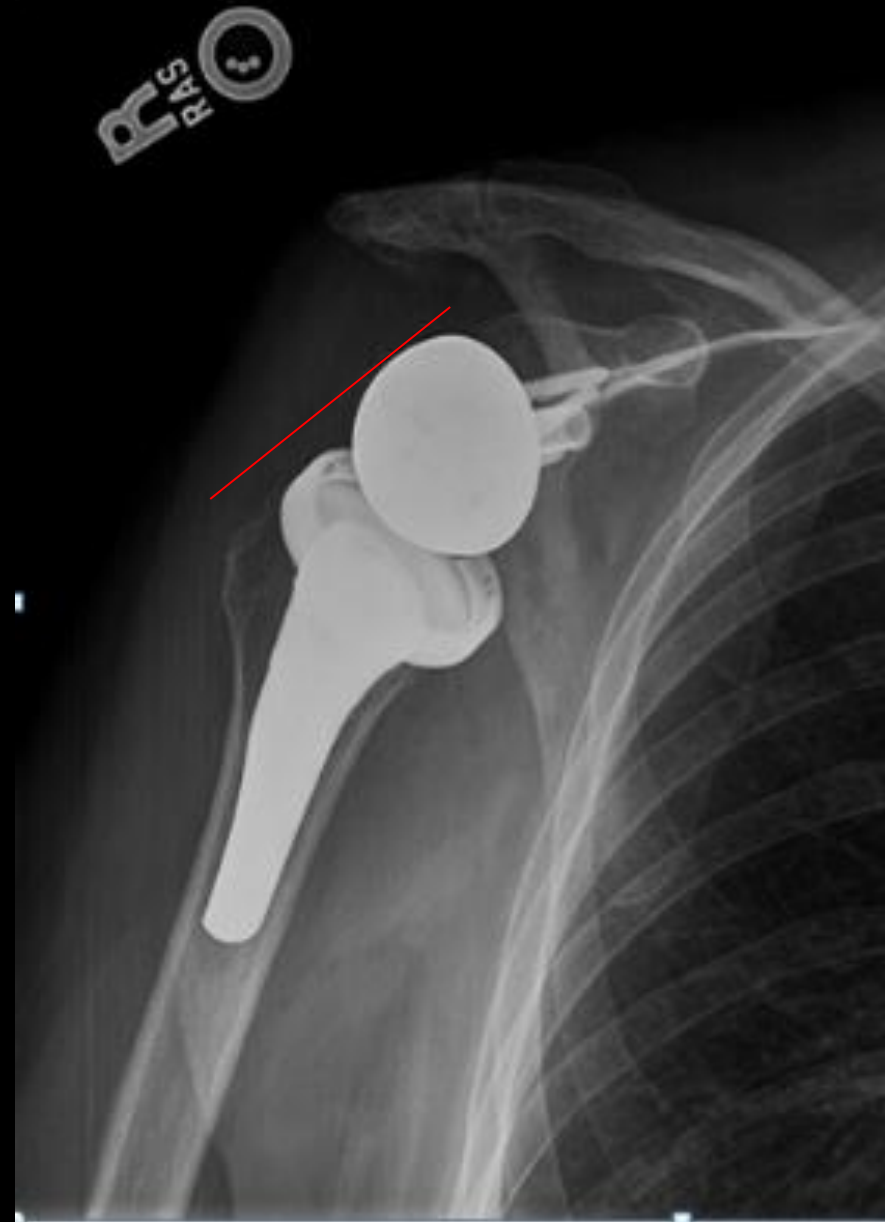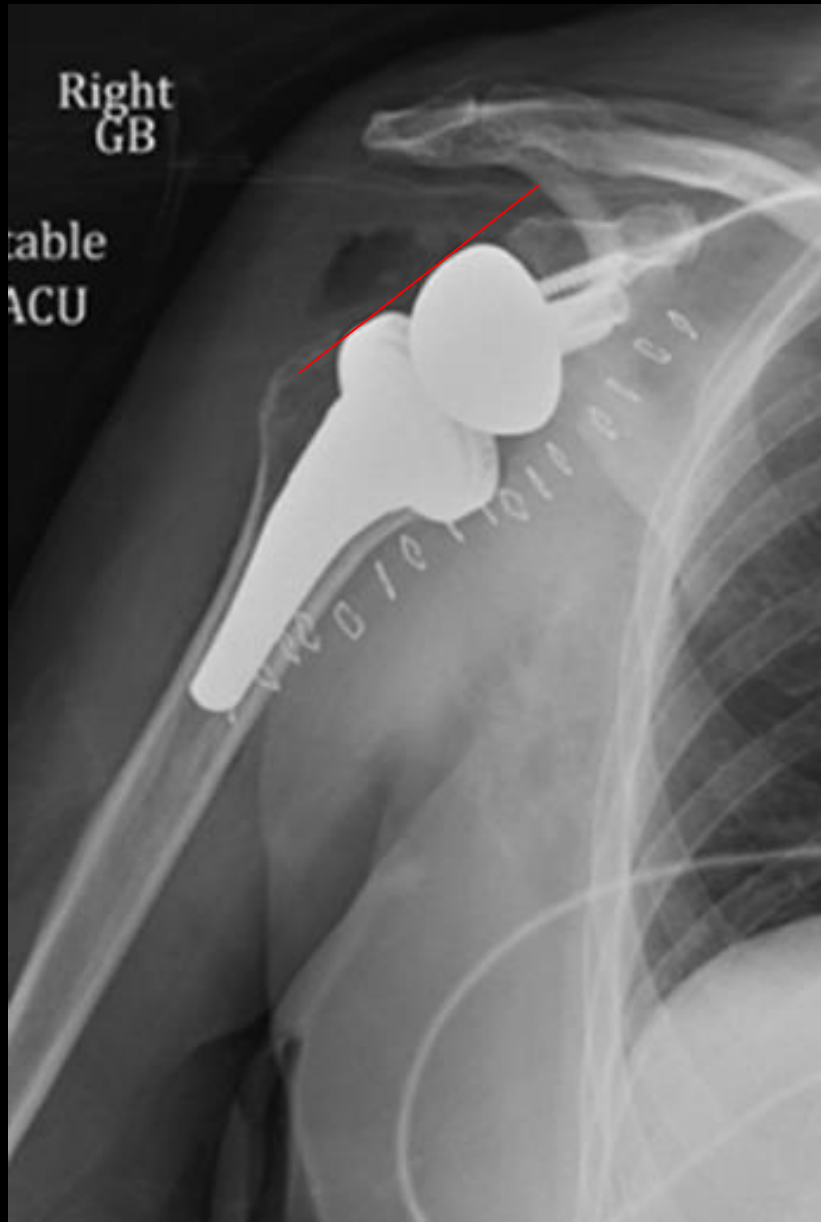
10 weeks PO



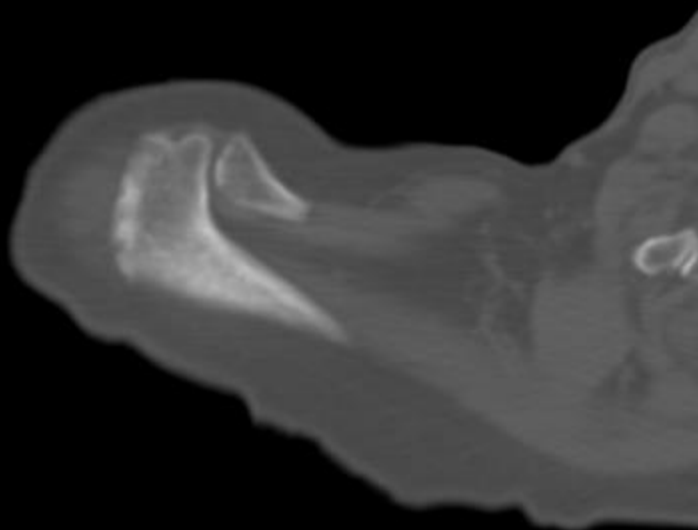
Status post RTSA 10 weeks ago



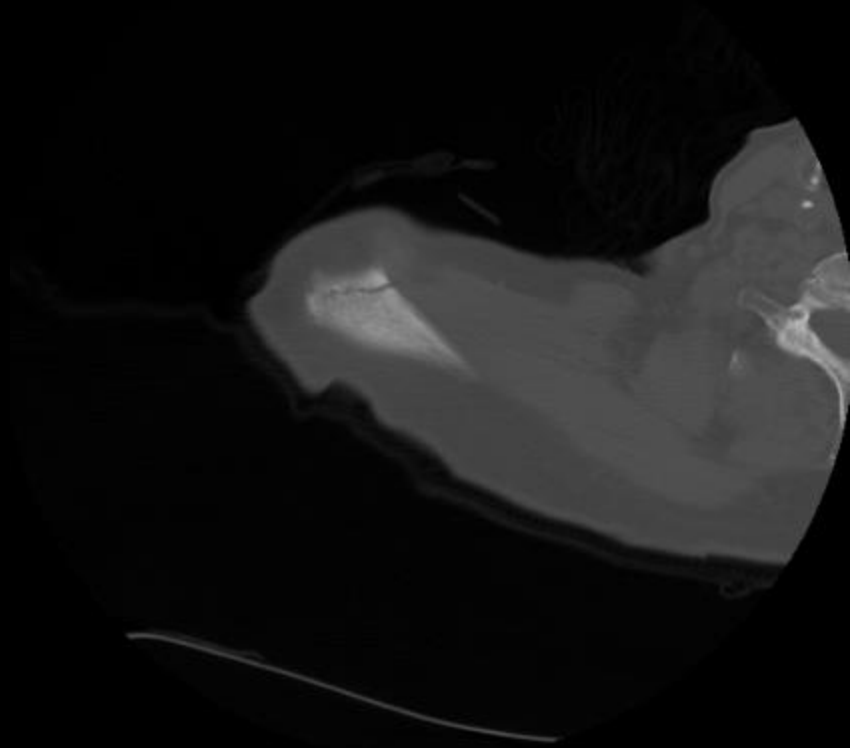
Status post RTSA 10 weeks ago

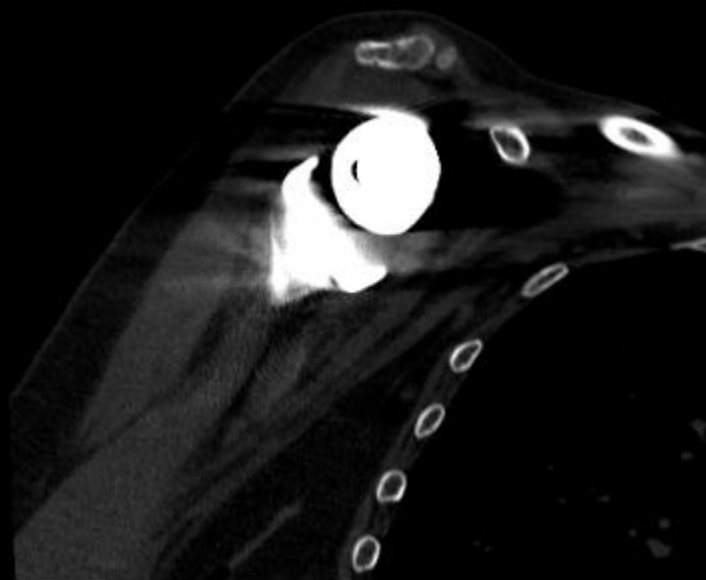
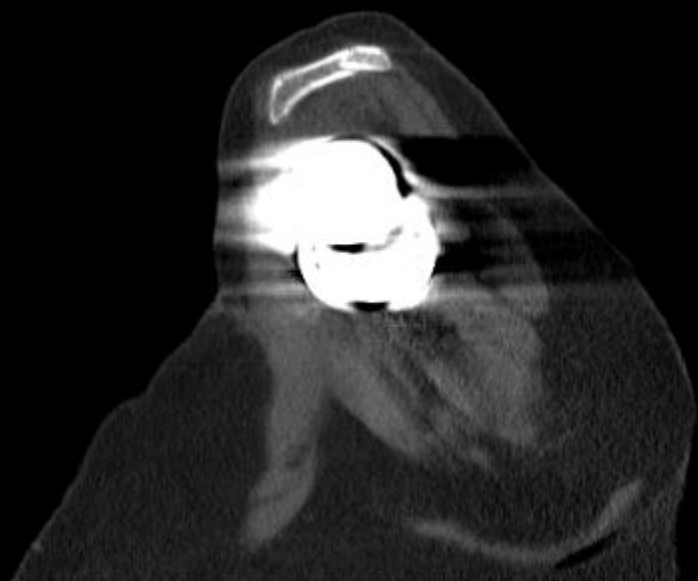


Before



After



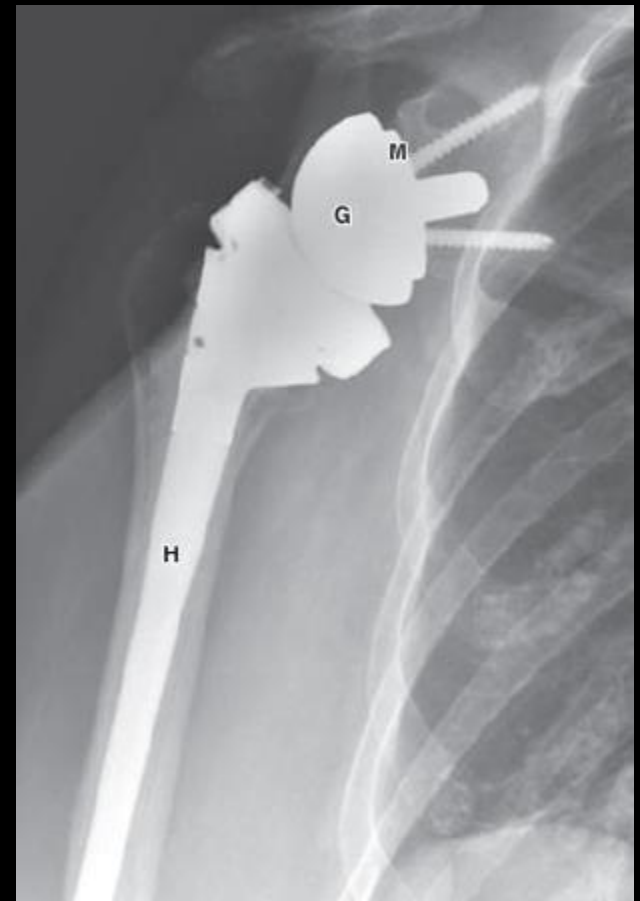


Indications

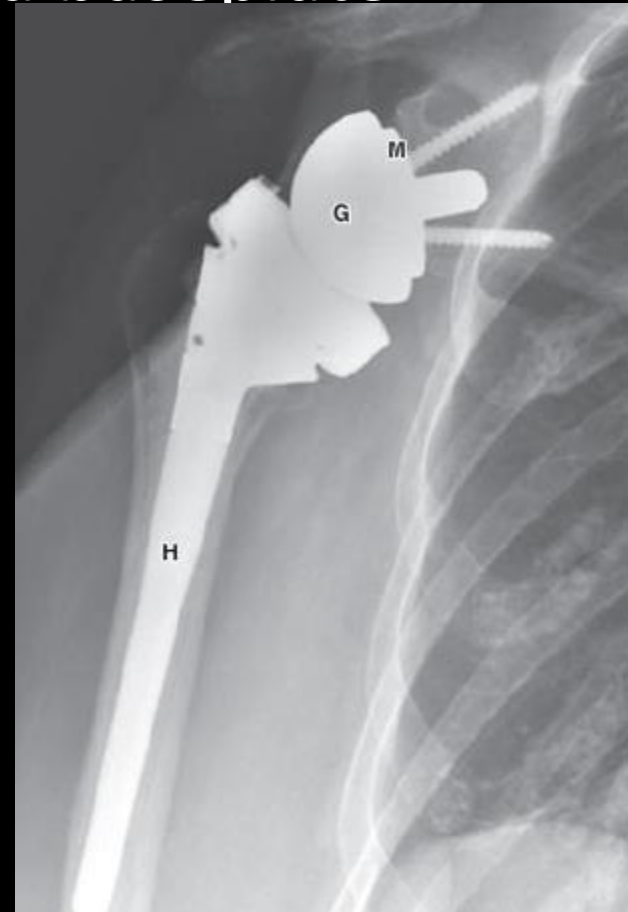
- Reverse total shoulder arthroplasty is indicated for:
 1. Rotator cuff deficient shoulders with pseudoparalysis,
 2. Tumor resection reconstruction,
 3. Prior failed total shoulder arthroplasty with subsequent rotator cuff failure, and
 4. Acute three- or four-part proximal humerus fracture
- With full-thickness rotator cuff tears, there is resultant superior humeral head migration, unopposed deltoid contraction, and loss of the glenohumeral fulcrum, **leading to inability to raise the arm above the horizontal or “pseudoparalysis”**
- **Reverse total shoulder arthroplasty requires an intact deltoid muscle**

- In 1987, Grammont et al first designed
- Moves the center of rotation more distally and medially, resultant lengthening and better contraction of the deltoid muscle
- Active arm elevation can be restored
- However, active external and internal rotations are limited

- The humeral component consists of a proximal cup-shaped portion and metal stem. A radiolucent polyethylene insert sits in this cup portion and articulates with the glenosphere.



- The glenosphere is the rounded metal ball of the prosthesis that attaches to a baseplate (metaglene) secured to the native glenoid by bicortical screws, which may be straight or angled or angled



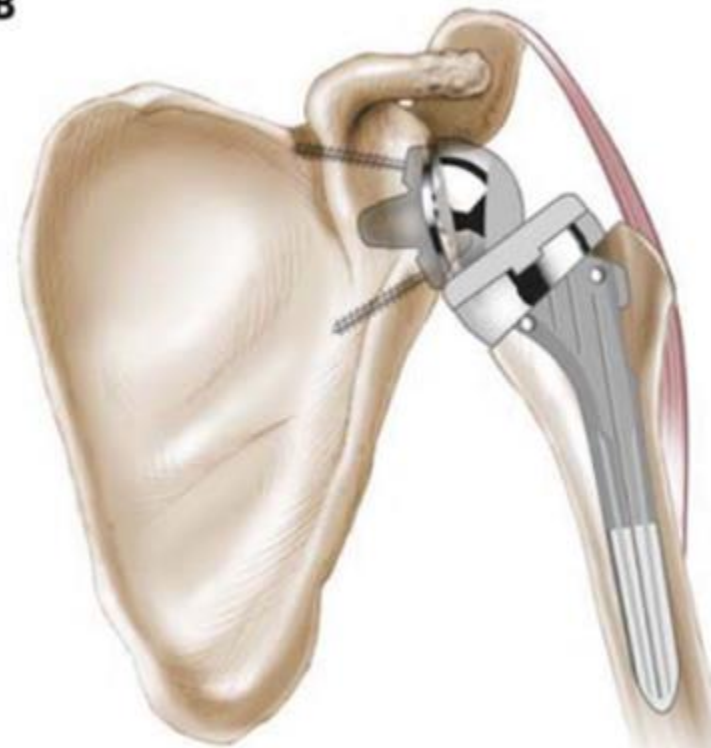
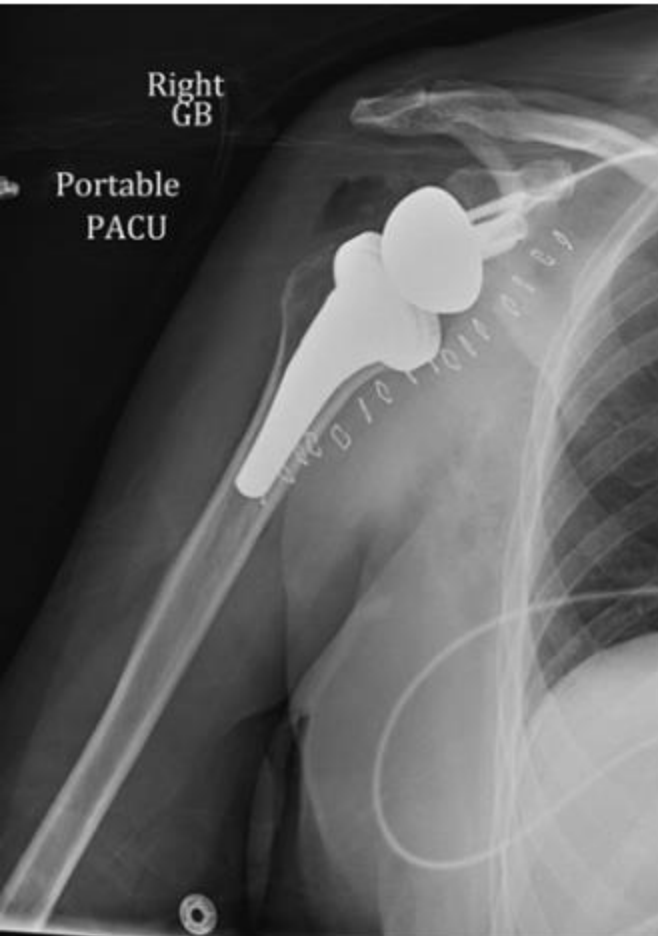
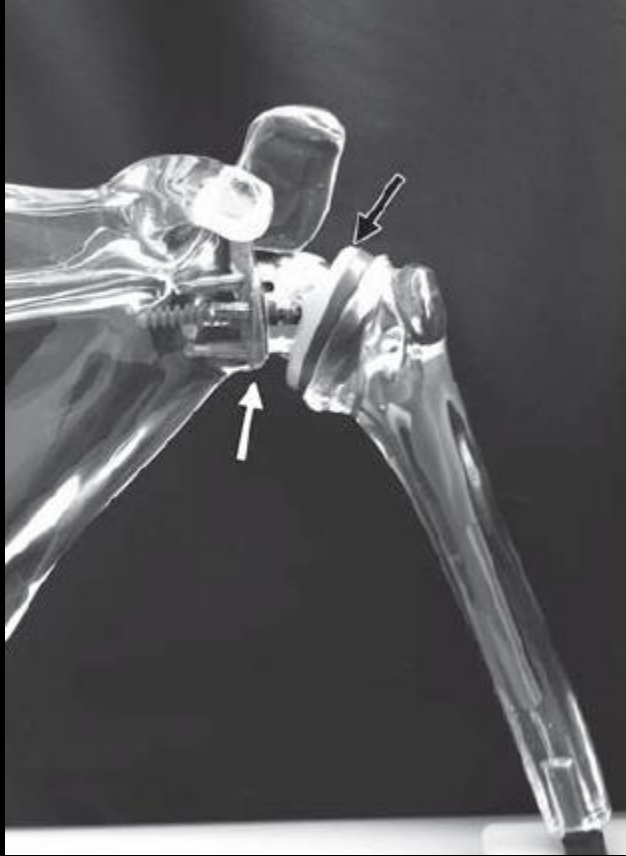

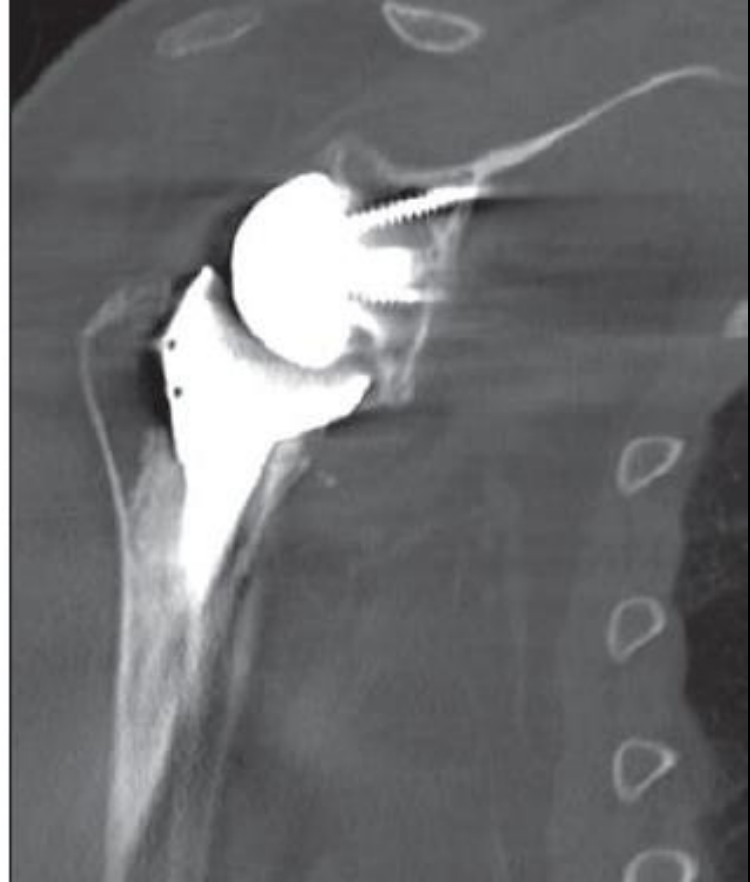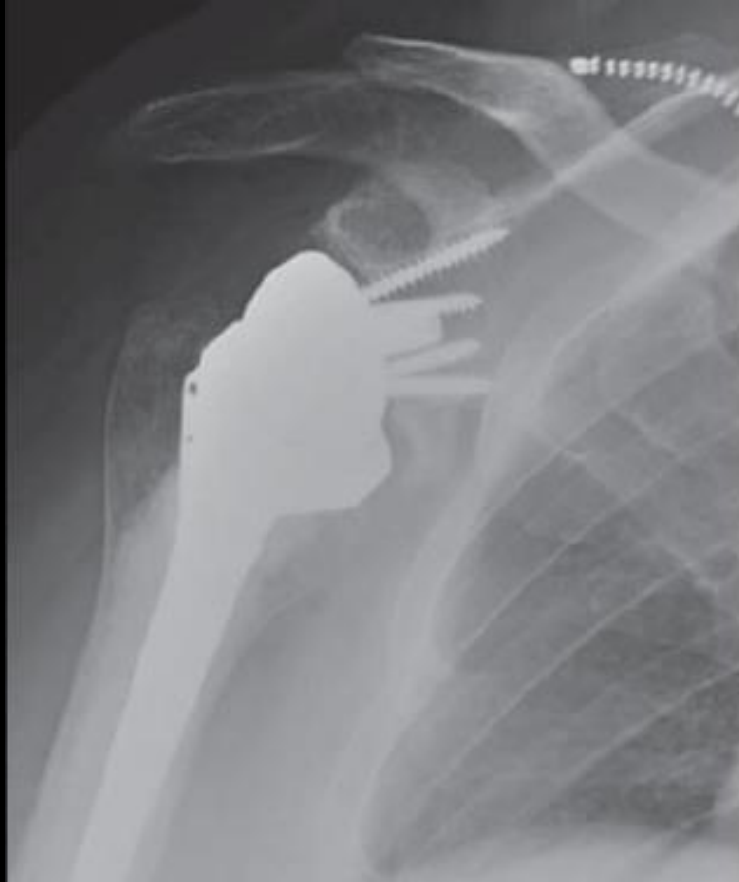FIGURE 2. Reverse total shoulder arthroplasty components (Zimmer, Warsaw, IN). The prosthesis has 5 parts: the glenoid base, the glenosphere, a polyethylene cup, humeral neck, and the humeral stem.



Complications

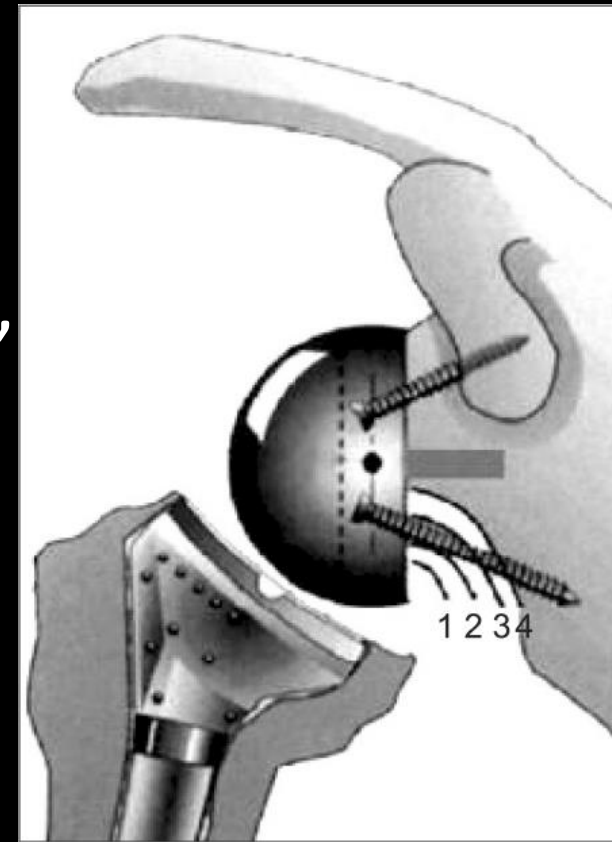
- Scapular notching;
- Postoperative hematoma;
- Glenosphere dissociation,
 - baseplate failure or
 - aseptic loosening with or without intraarticular metaglene migration
- Glenohumeral dislocation
- Acromial or scapular fracture
- Infection;
- Loosening or dissociation of the humeral component; and
- Nerve injury

Scapular notching

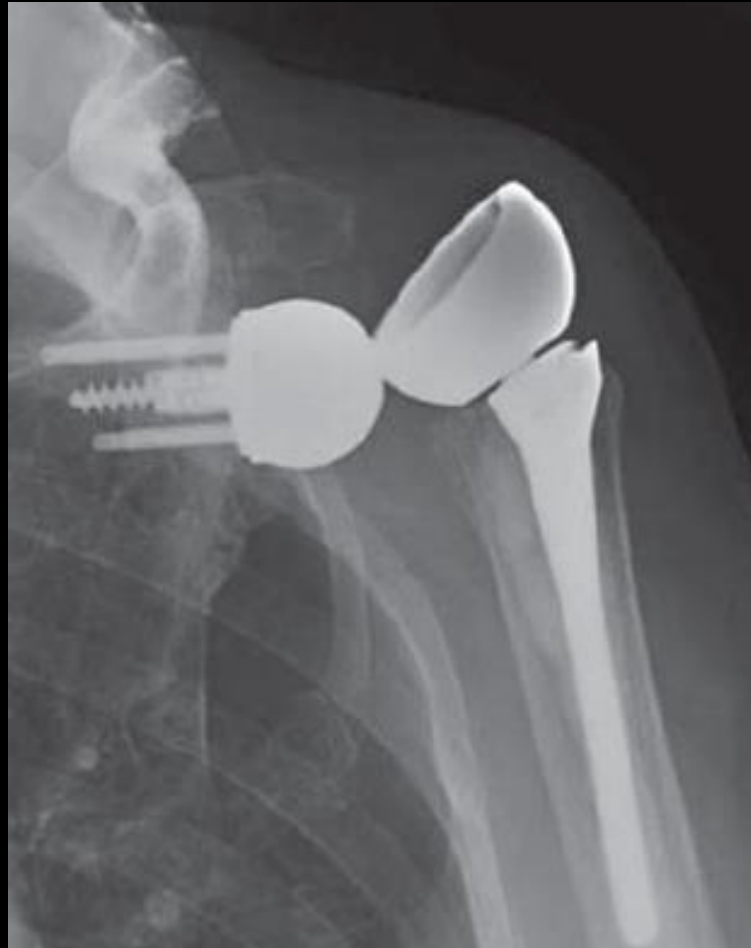

- Repetitive contact of the medial aspect of the humeral cup with the inferior border of the
- Reported in 50–96% of reverse total shoulder arthroplasties
- Notching tends to stabilize 1 year after surgery.

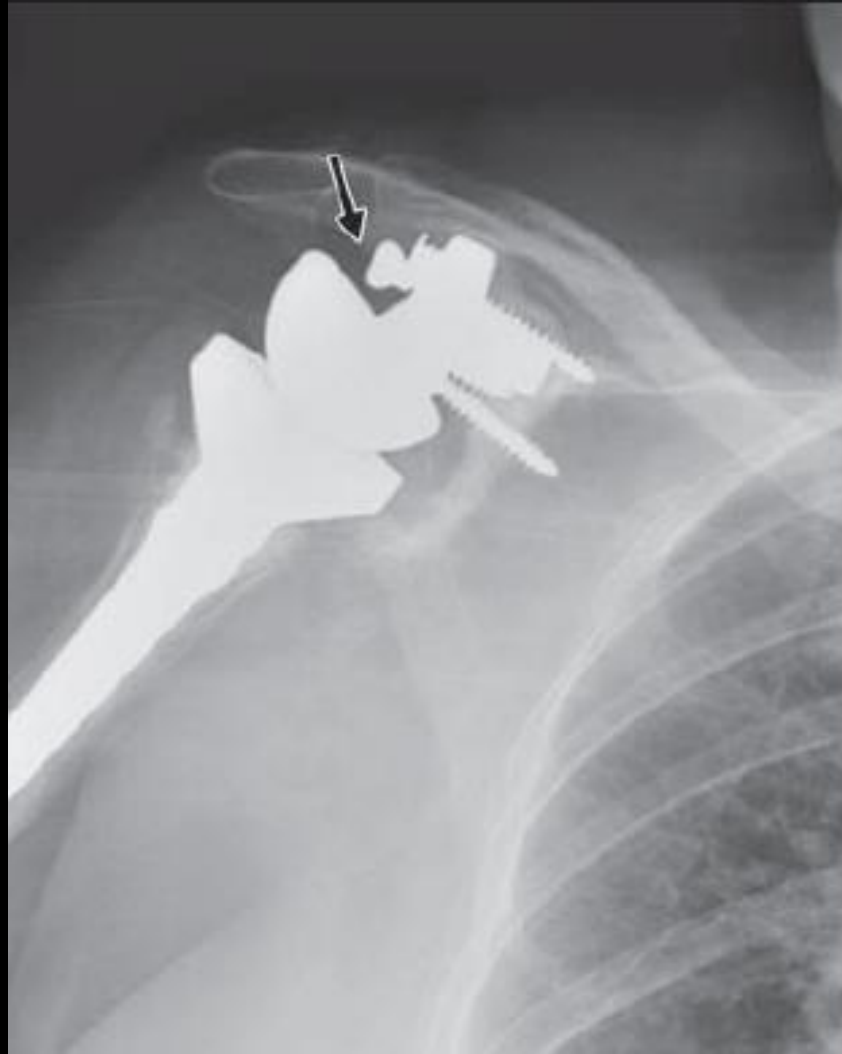
- Graded according to the classification of Sirveaux et al.
 - grade 1 only the pillar,
 - grade 2 inferior baseplate screw,
 - grade 3 over the inferior screw,
 - grade 4 under the baseplate



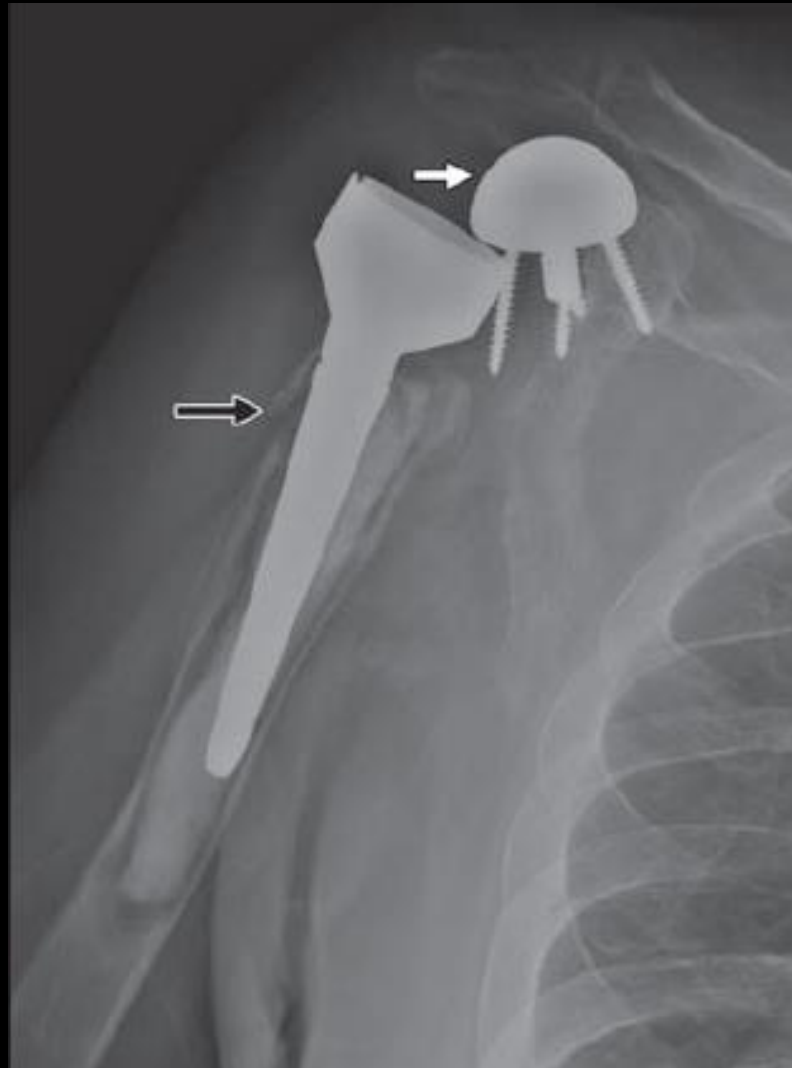
Glenohumeral dislocation

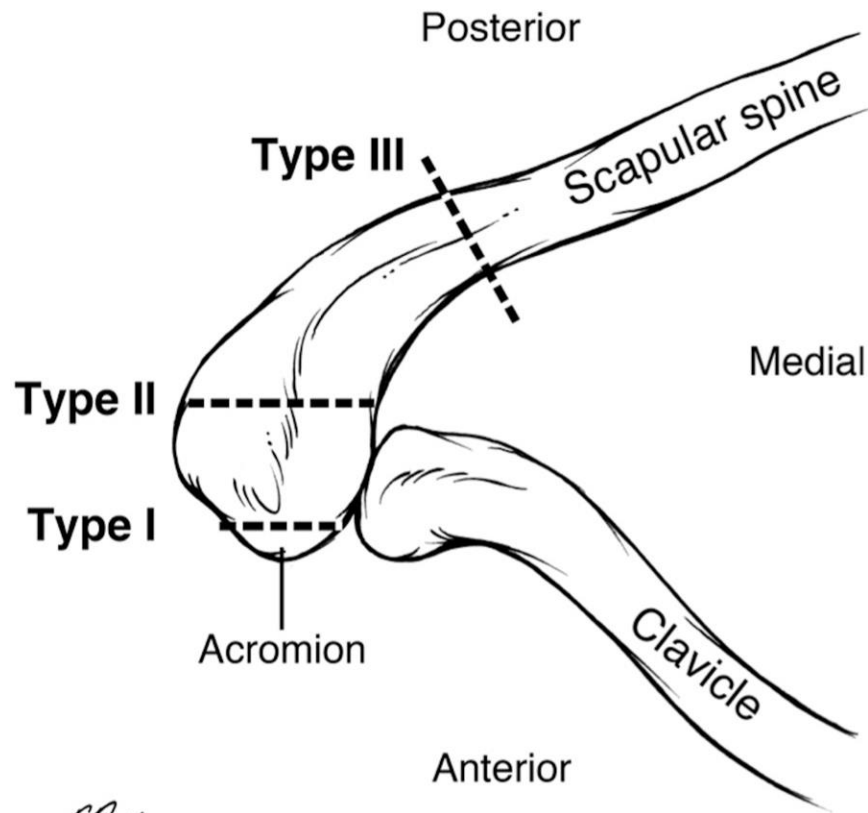


Glenosphere dissociation



Intraarticular migration of metaglene



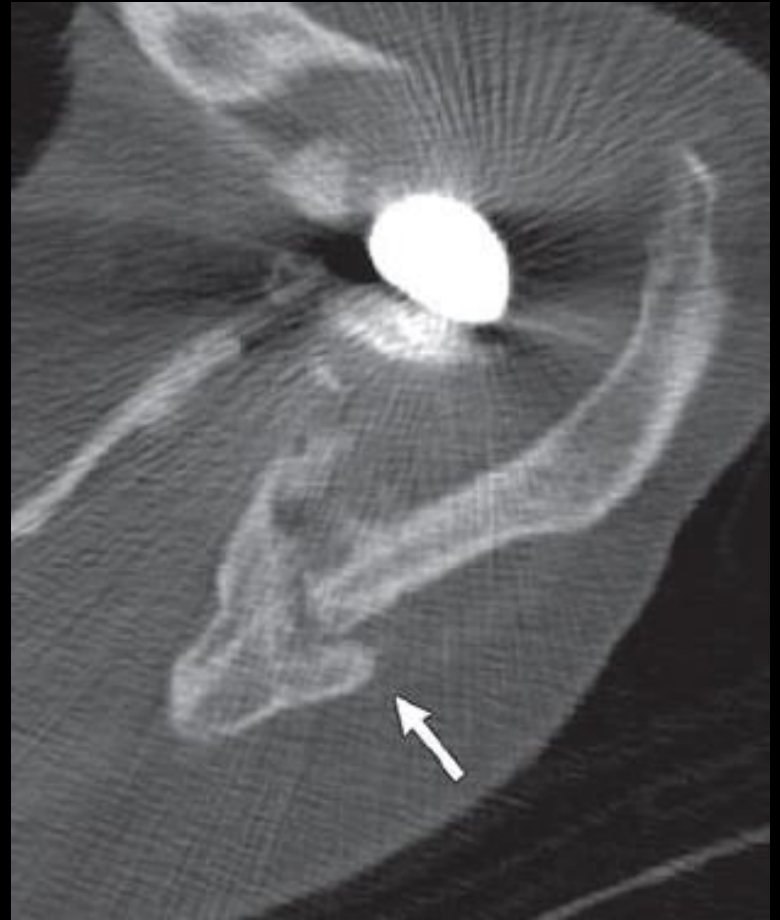
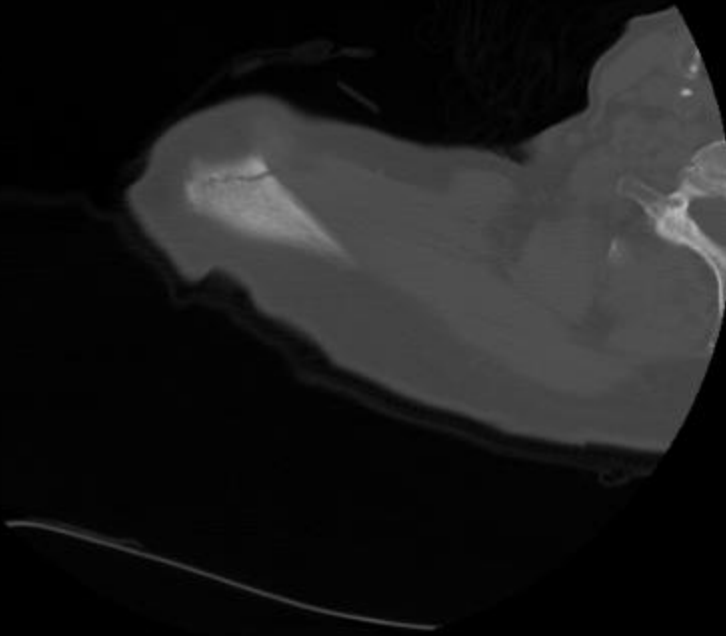


T. Proffers
© JHU 2014

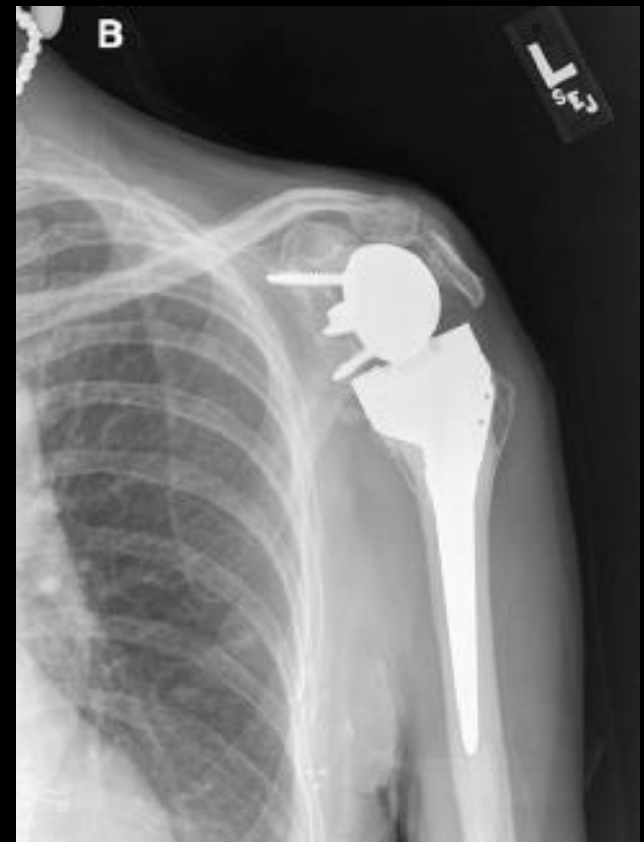Acromial or scapular fracture

- Unique to the reverse total shoulder arthroplasty design,
- Incidence of 5–6.9%
- Type 1, intraoperatively and often heal without surgical fixation.
- Type 2, patients with preexisting stiff arthritic acromioclavicular joints with increased stress over time as the patient regains glenohumeral motion, these fractures may become displaced without intervention.
- Type 3, superior metaglene screw acting as a stress riser

Acromial or scapular fracture



- An additional type acromial base fracture, appears different from the acromial spine fracture
- Worse functional outcomes
- Site of bony support for the entire deltoid.



References

- [Current Concepts of Shoulder Arthroplasty for Radiologists: Part 2 Anatomic and Reverse Total Shoulder Replacement and Nonprosthetic Resurfacing Alice S. Ha Jonelle M. Petscavage Felix S. Chew](#)
- **American Journal of Roentgenology** 2012; 199:4, 768-776 Grammont P, Trouilloud P, Laffay JP, Deries X. Concept study and realization of a new total shoulder prosthesis [in French]. *Rhumatologie* 1987; 39:407–418
- Bohsali KI, Wirth MA, Rockwood CA Jr. Complications of total shoulder arthroplasty. *J Bone Joint Surg Am* 2006; 88:2279–2292
- Sirveaux F, Favard L, Oudet D, Huquet D, Walch G, Mole D. Grammont inverted total shoulder arthroplasty in the treatment of glenohumeral osteoarthritis with massive rupture of the cuff: results of a multicentre study of 80 shoulders. *J Bone Joint Surg Br* 2004; 86:388–395