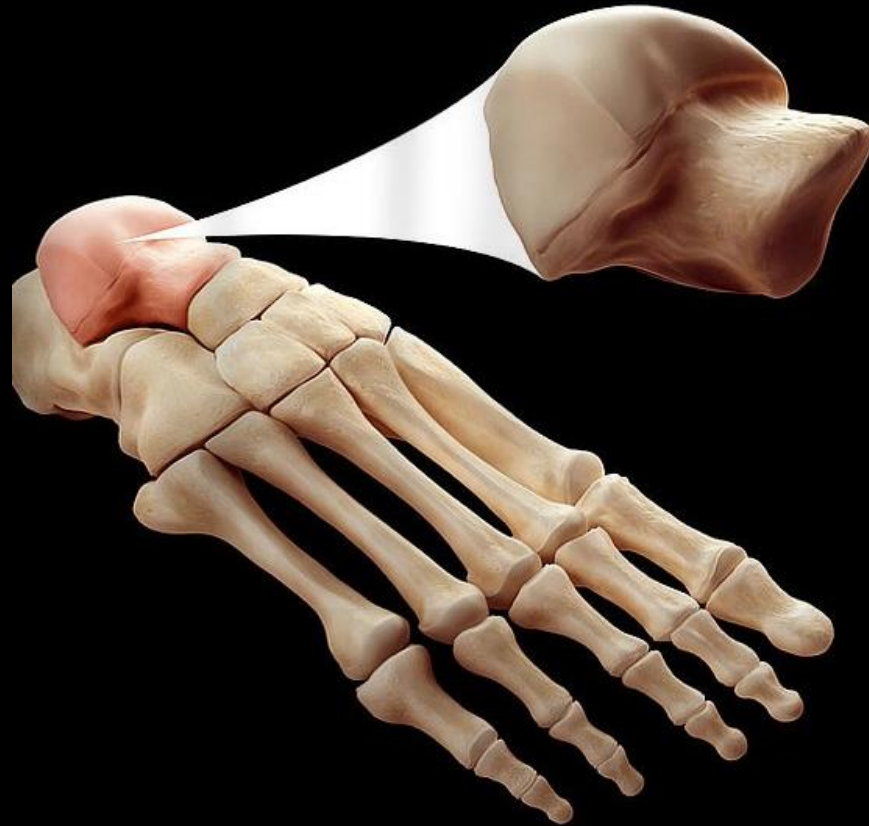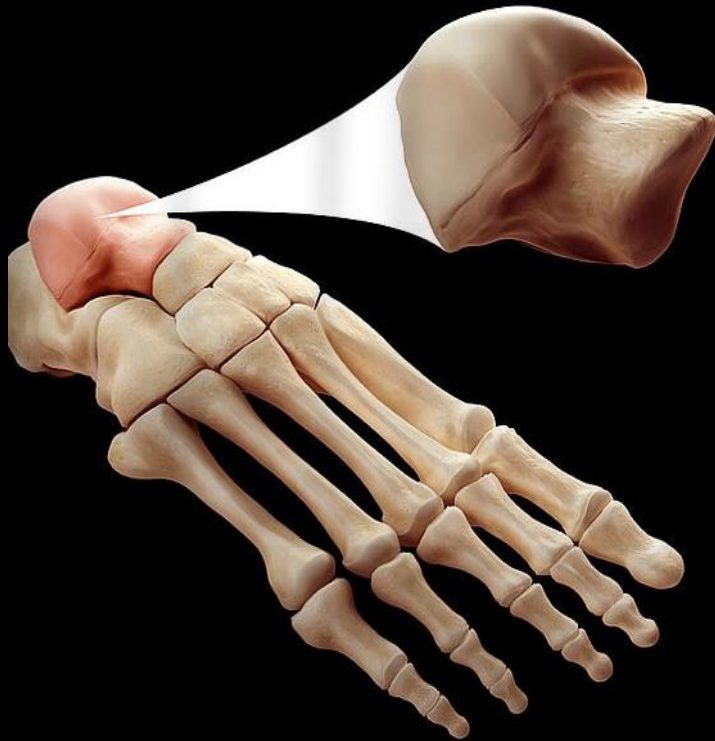


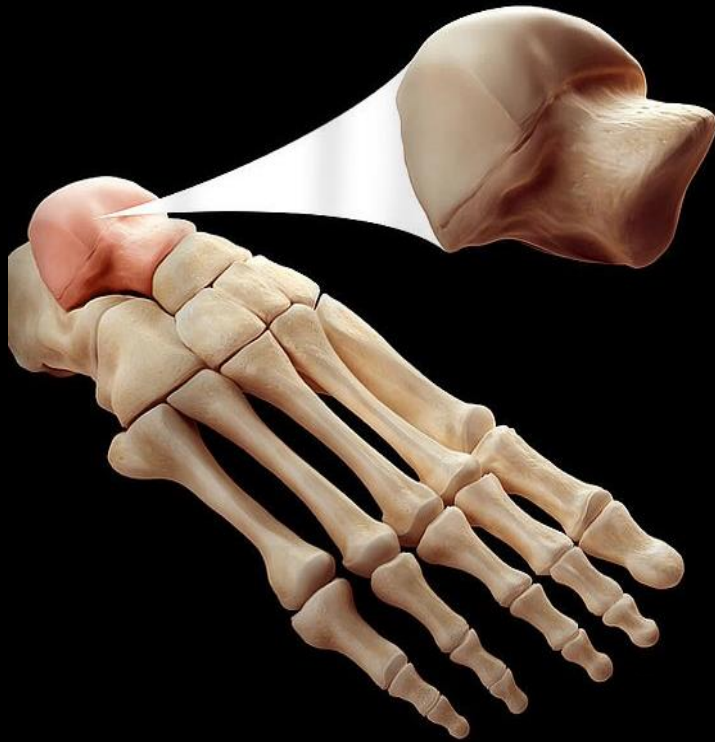
The Talus from A to Z

Eman Alqahtani, MD, MPH

06/14/2019

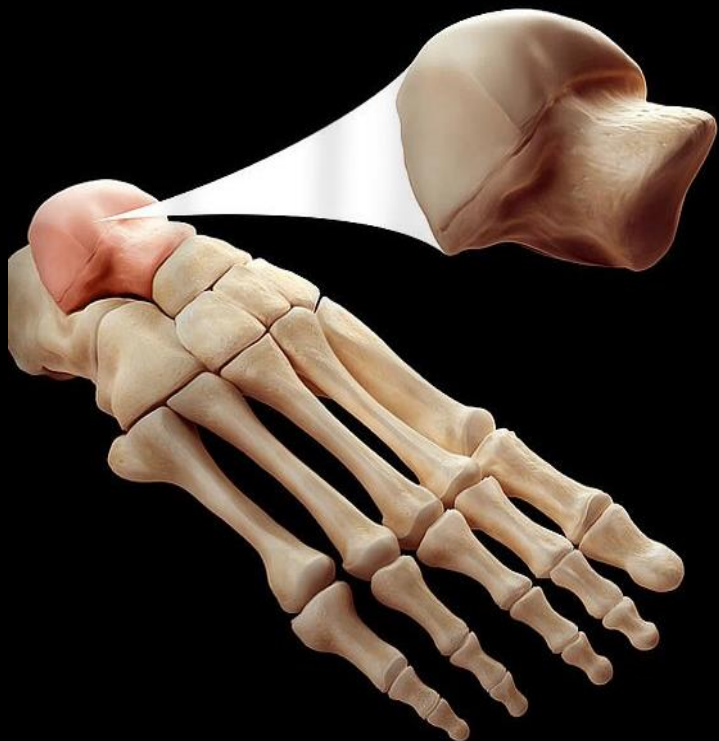
Anatomy





Anatomy

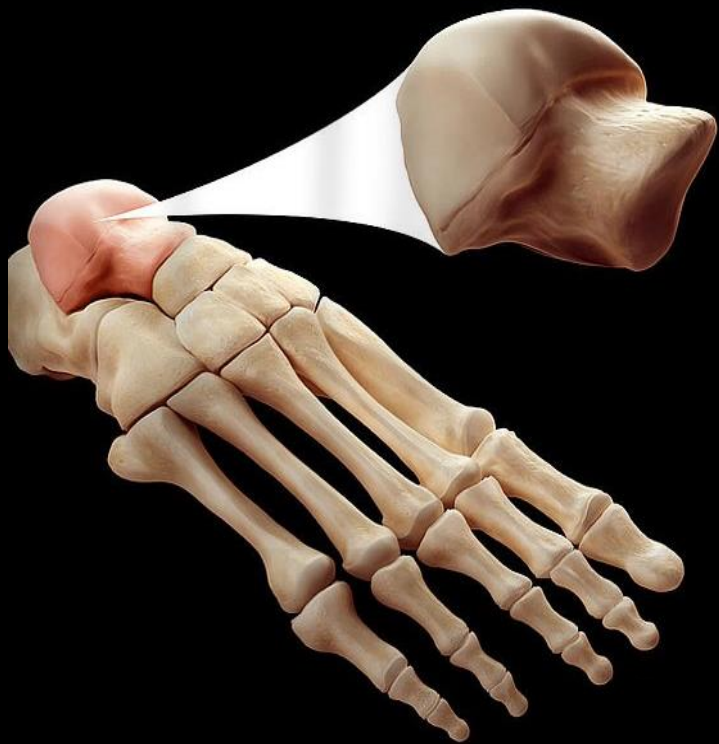
Congenital



Anatomy

Congenital

Fractures

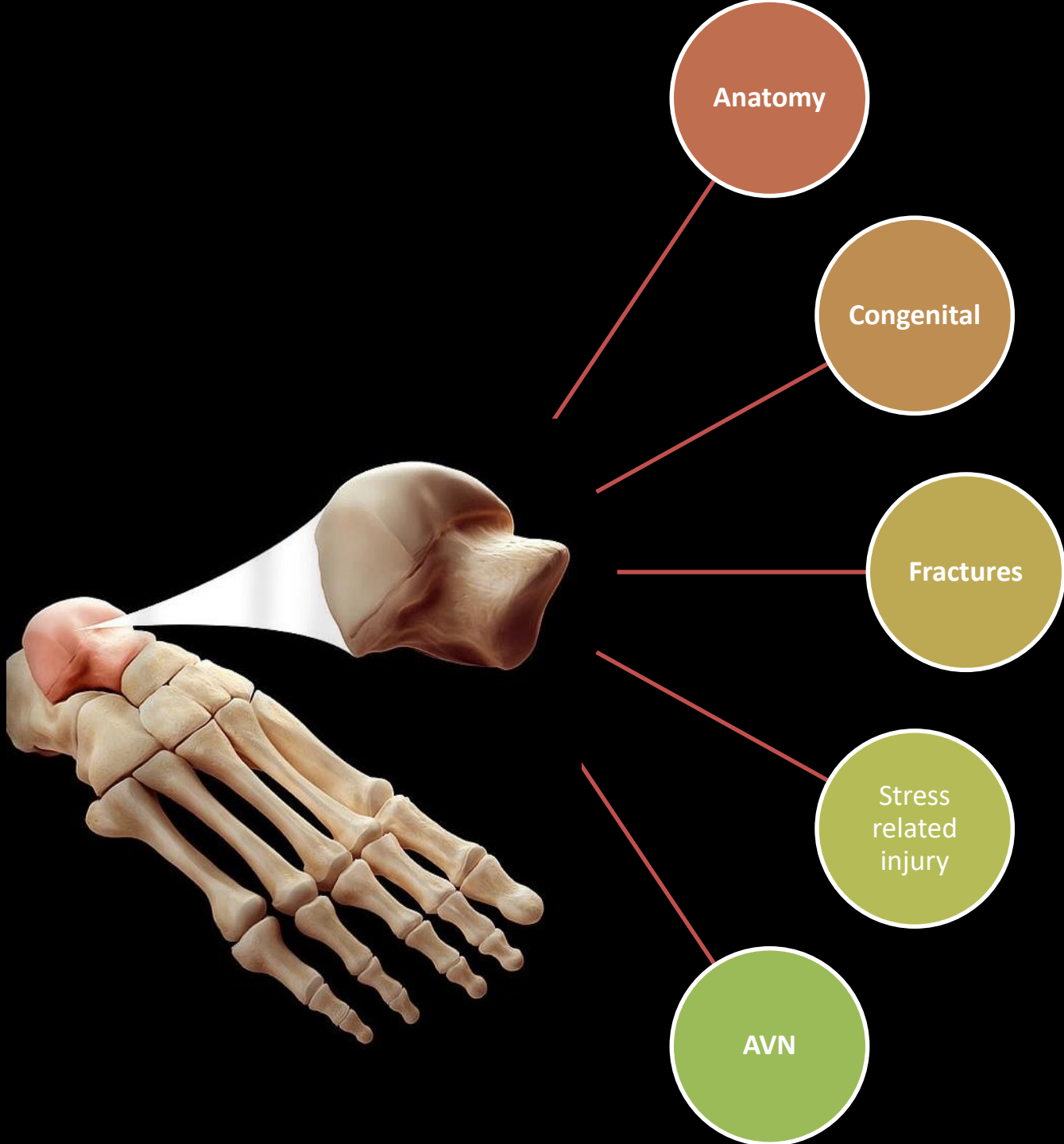


Anatomy

Congenital

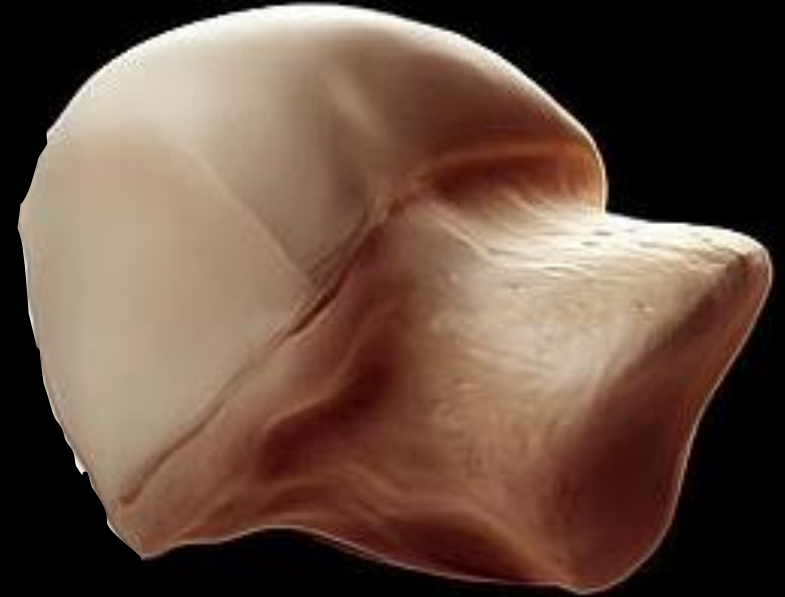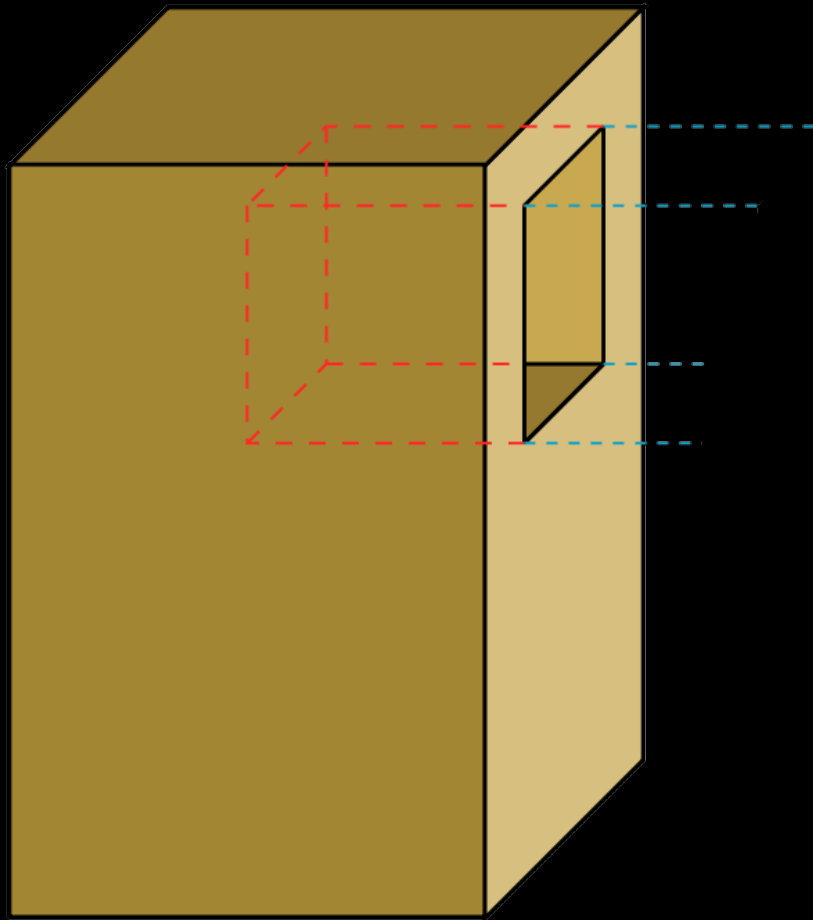
Fractures

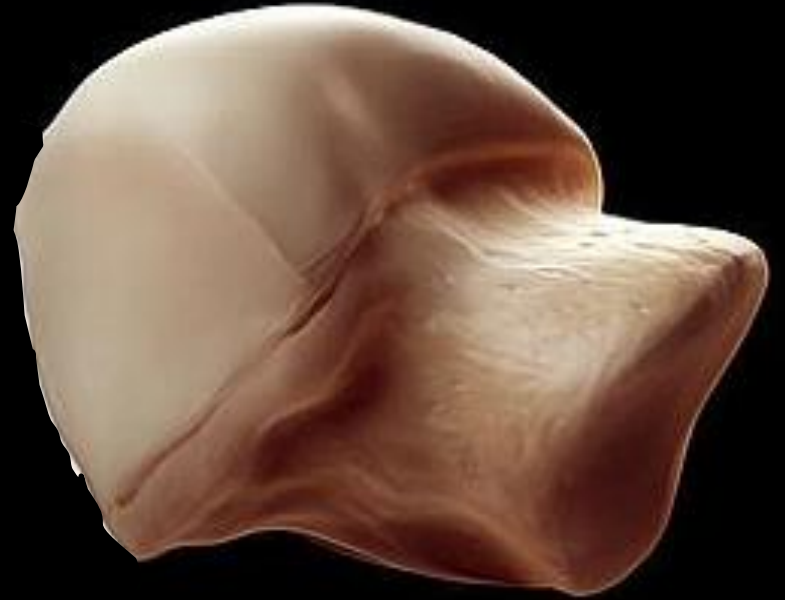Stress related injury



The Talus

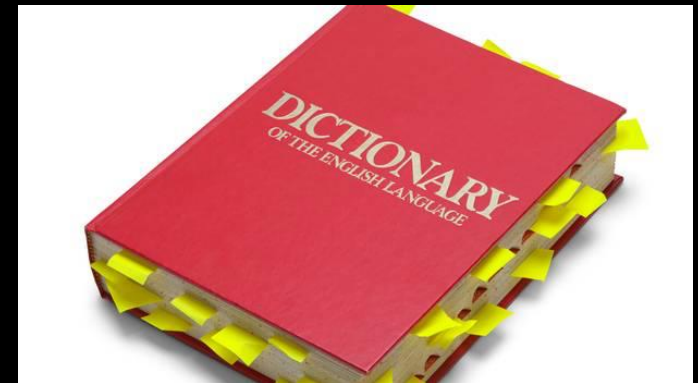
Mortise and ~~Tenon~~





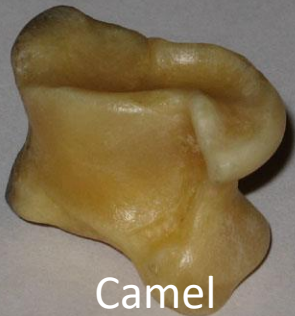The Talus

- **Talus** definition is - a slope formed especially by an accumulation of rock debris
- **Talus also called** - Astragalus /ə'strægələs
- Derived from the Latin word *taxillus*, which refers to the ankle bone of a horse

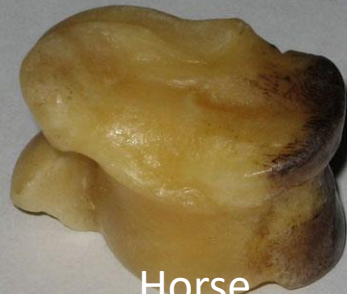

The Talus

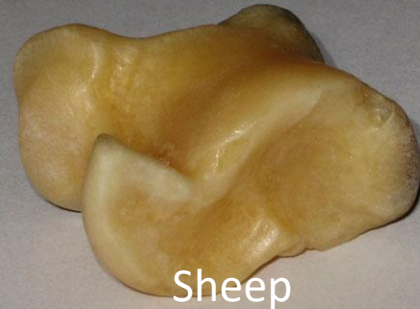- Shagai: Bones collected and used for traditional games and fortune-telling throughout central Asia



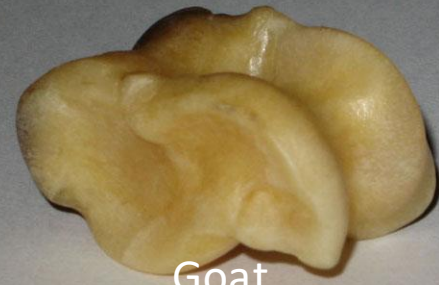Camel



Horse



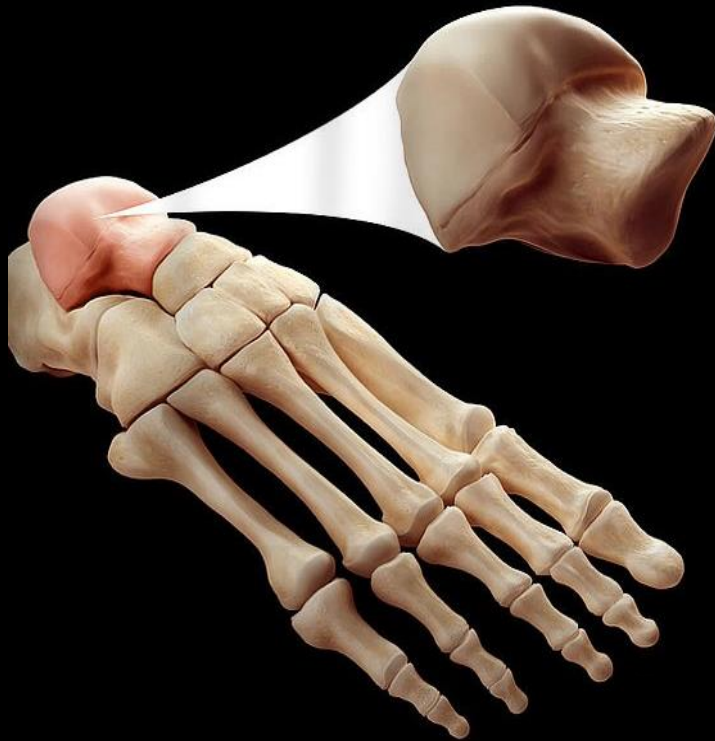
Sheep



Goat



Anatomy



The Talus: Anatomy

- Second largest of the tarsal bones
- Only bone articulating with the leg bones
- No muscle or tendon attachment
- Predominantly extraosseous vascular supply
- 60% covered by cartilage
- 3 parts:
 - Head
 - Neck
 - Body

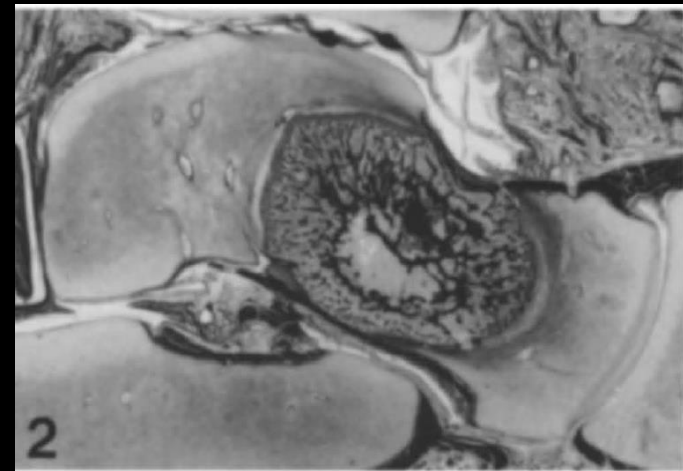
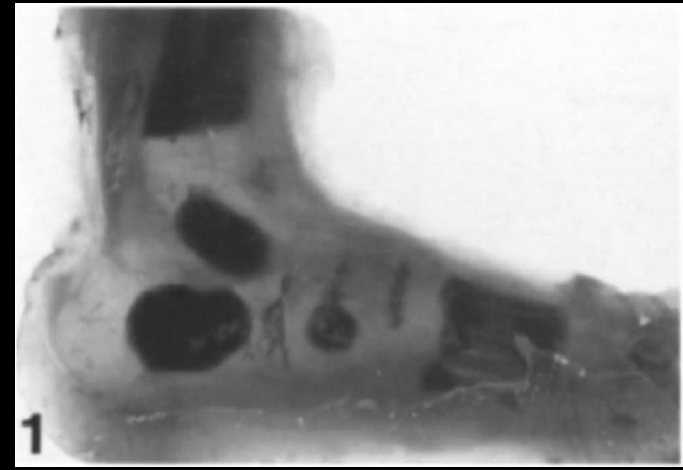

The Talus: Anatomy

- The talus consists of:
 - A. Two facets, one subtalar joint, and two processes
 - B. Two facets, two subtalar joints, and three processes
 - C. Three facets, two subtalar joints, and three processes
 - D. Three facets, two subtalar joints, and two processes
 - E. Three facets, three subtalar joints, and three processes

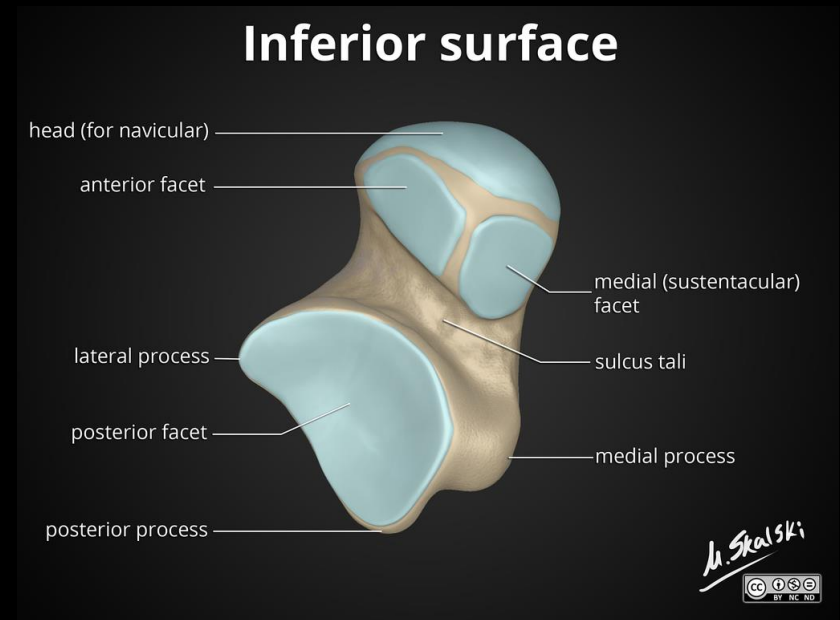
The Talus: Anatomy

- Embryology
 - Tarsal bones mesenchymal differentiation and segmentation sometime around the 8th week of gestation
 - Ossification of the talus originates from a *single primary center*
 - Elongation occur in an anteroposterior direction
 - In the newborn talus up to 24% of the talus already consists of bony tissue



The Talus: Anatomy

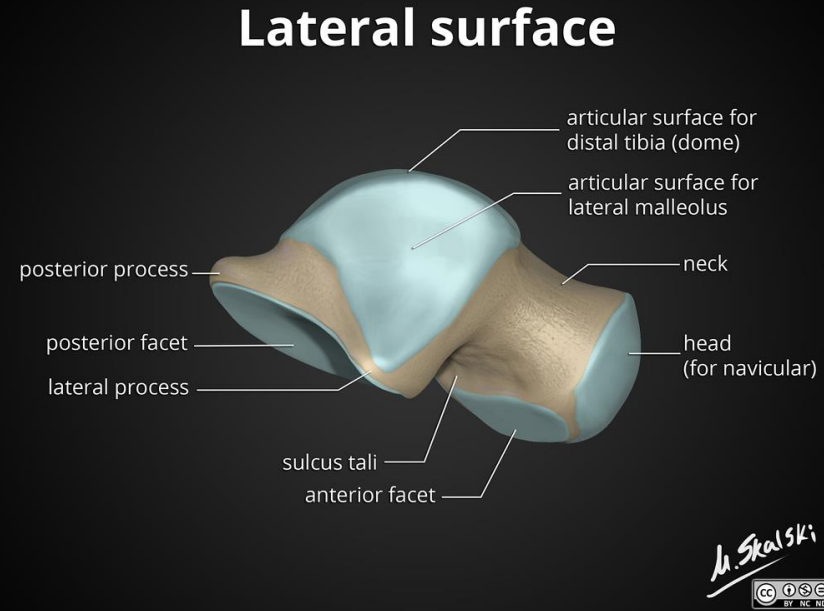
- Talar Head:
 - Covered with hyaline cartilage
 - Convex
 - Articulation:
 - Navicular anteriorly
 - Calcaneus inferiorly and medially



Anatomy of the talus , Dr Matt Skalski, radiopedia

The Talus: Anatomy

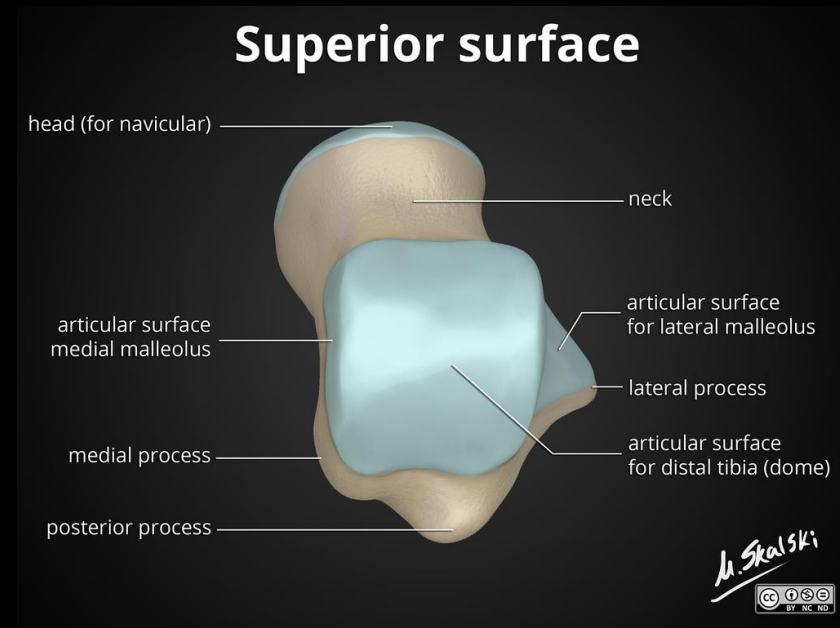
- Talar neck:
 - Directed plantar-medially
 - 150 degrees angle with the body
 - Inferior surface of the talar neck forms the tarsal canal
 - Opening into the sinus tarsi laterally
 - Tarsal canal is devoid of cartilage and is extra-articular
 - Sulcus tali:
 - Deep groove which separates middle and posterior talocalcaneal articular surfaces



Anatomy of the talus , Dr Matt Skalski, radiopedia

The Talus: Anatomy

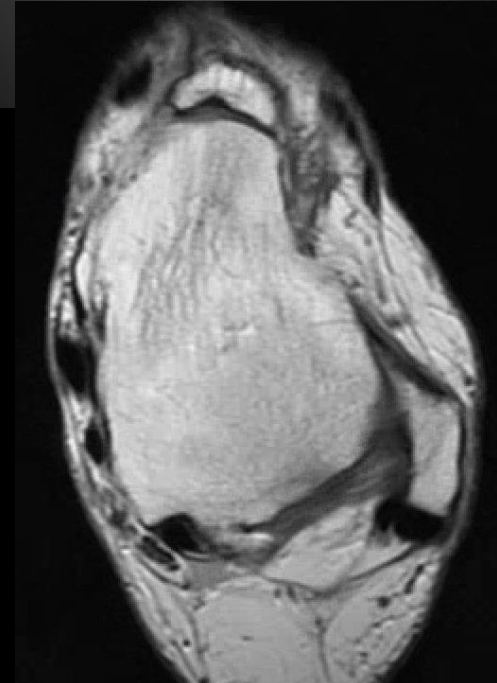
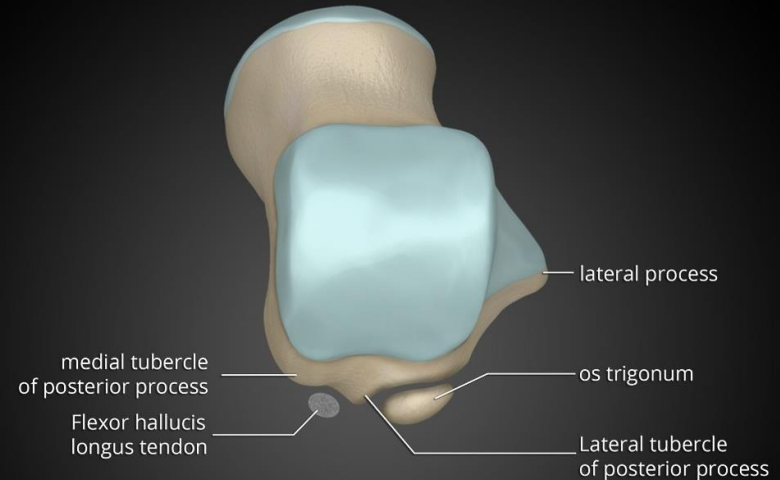
- Talar body:
 - Superior convex articular surface trochlea with shallow central groove (saddle shape)
 - Inferiorly:
 - Articulates with the calcaneus:
 - Posterior facet: larger and located posteriorly and laterally.
 - Middle facet: smaller and more medial, articulating with the calcaneal sustentaculum tali.



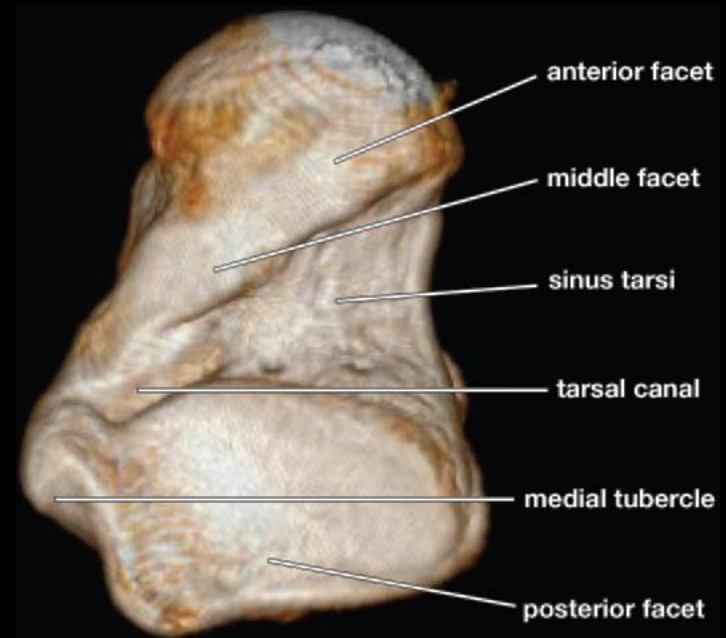
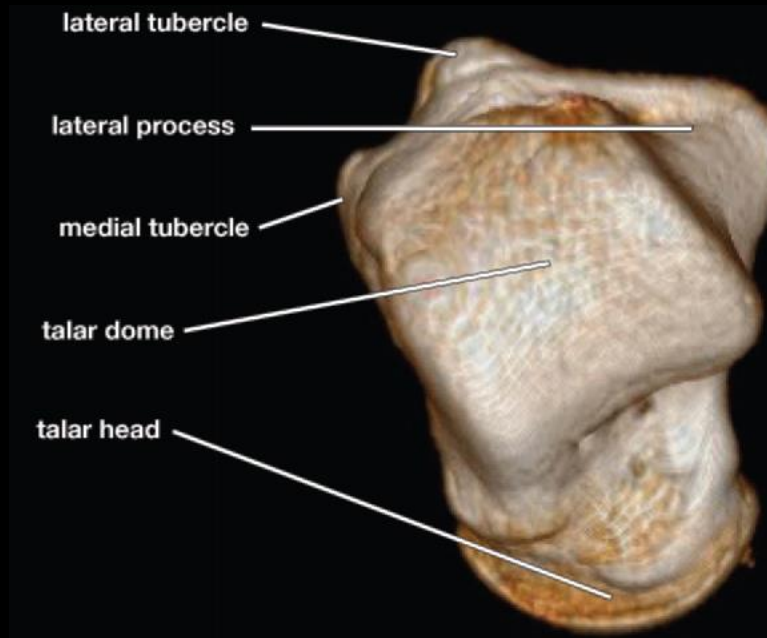
Anatomy of the talus , Dr Matt Skalski, radiopedia

The Talus: Anatomy

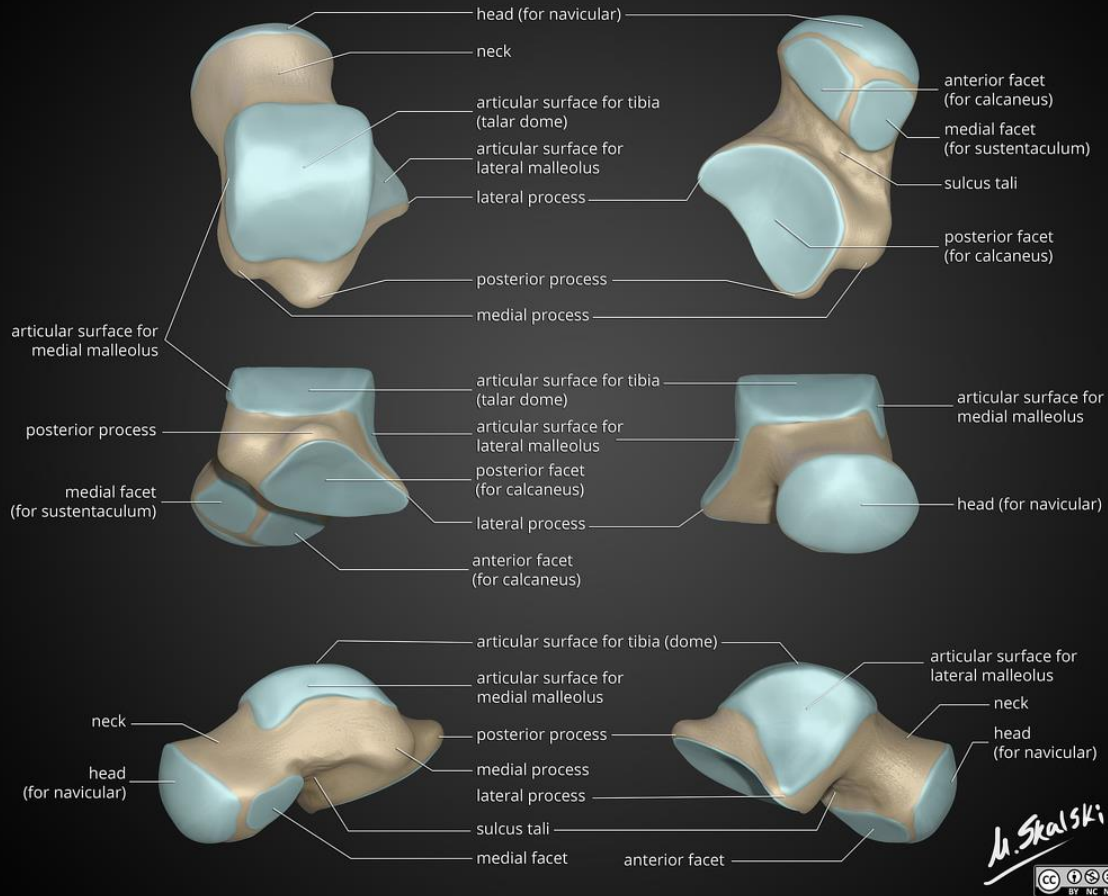
- Talar body:
 - Posterior Process:
 - **Lateral tubercle**: posterior talofibular ligament
 - » Stieda process
 - » Os trigonum: 1.7% to 50%
 - **Medial tubercle**: posterior fibers of the deltoid
 - Groove in between: FHL
 - Lateral Process:
 - Broad-based triangular lateral process:
 - » Articulate with the fibula superiorly
 - » Forms the **posterior facet** of the posterior subtalar joint



The Talus: Anatomy

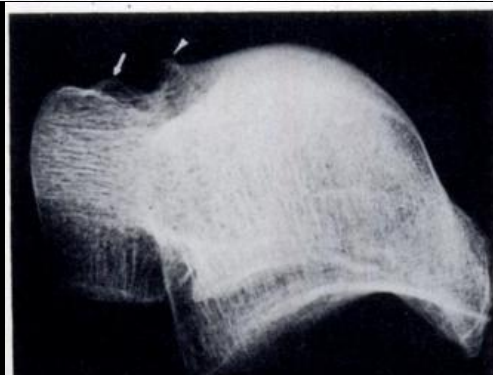
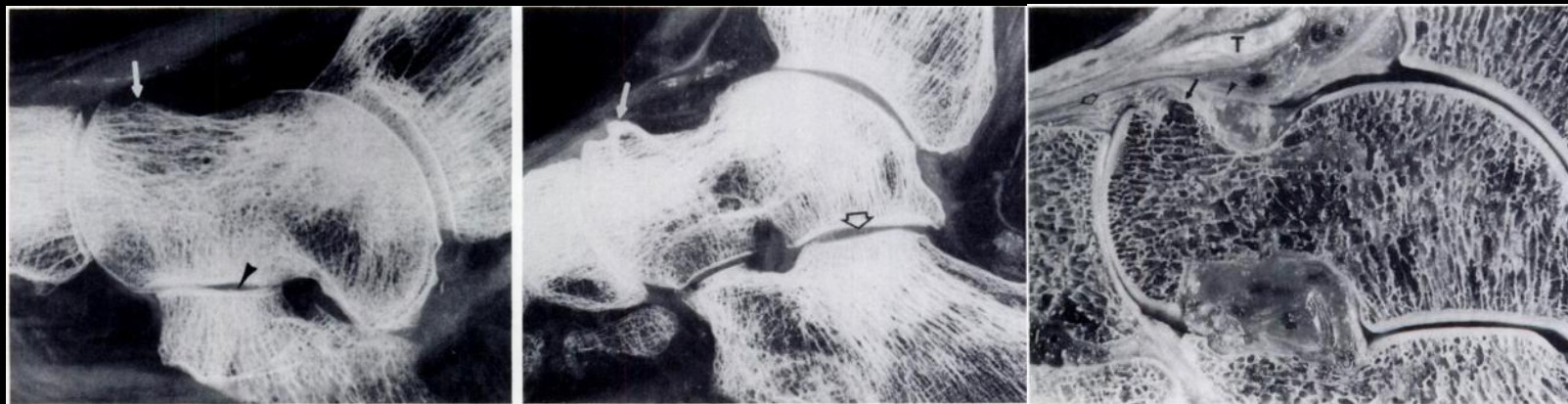


The Talus: Anatomy

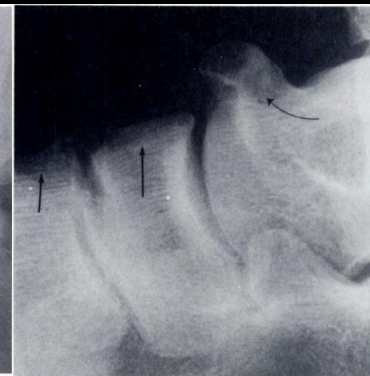
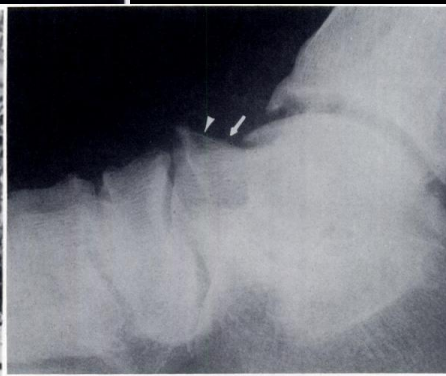
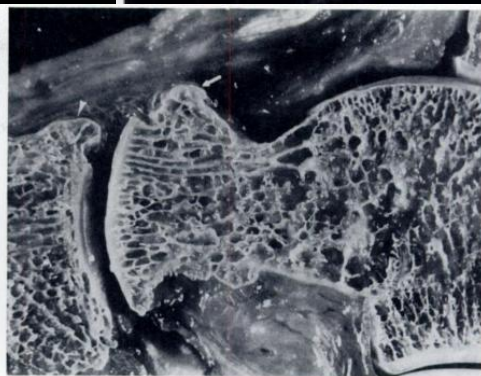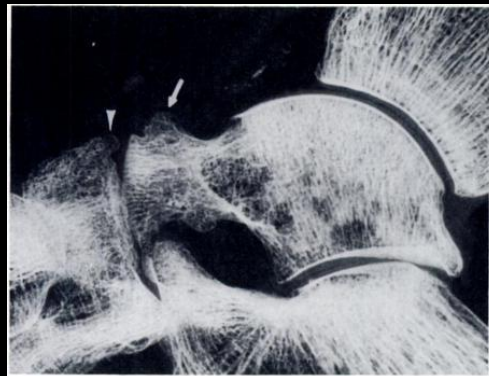


M. Skalski

The Talus: Anatomy

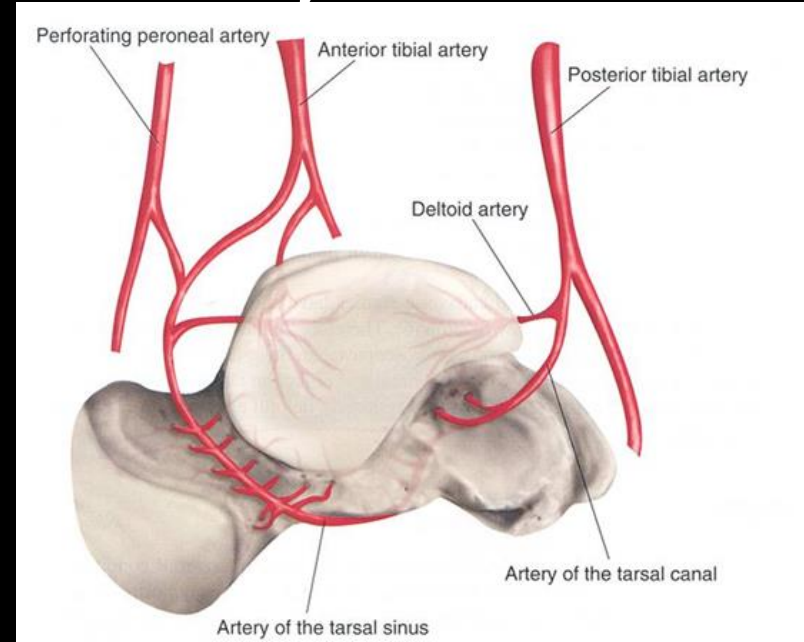


**Talar ridges, osteophytes, and beaks:
a radiologic commentary,
D. Resnick, 1984, Radiology**

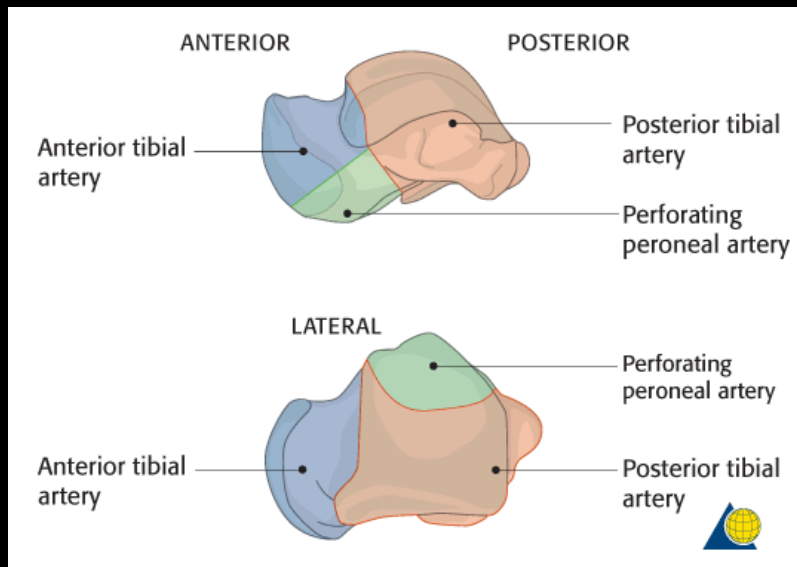


The Talus: Anatomy

- Vascular supply:
 - Posterior tibial artery- 36%
 - Dorsalis pedis artery- 47%
 - Perforating peroneal artery- 16%



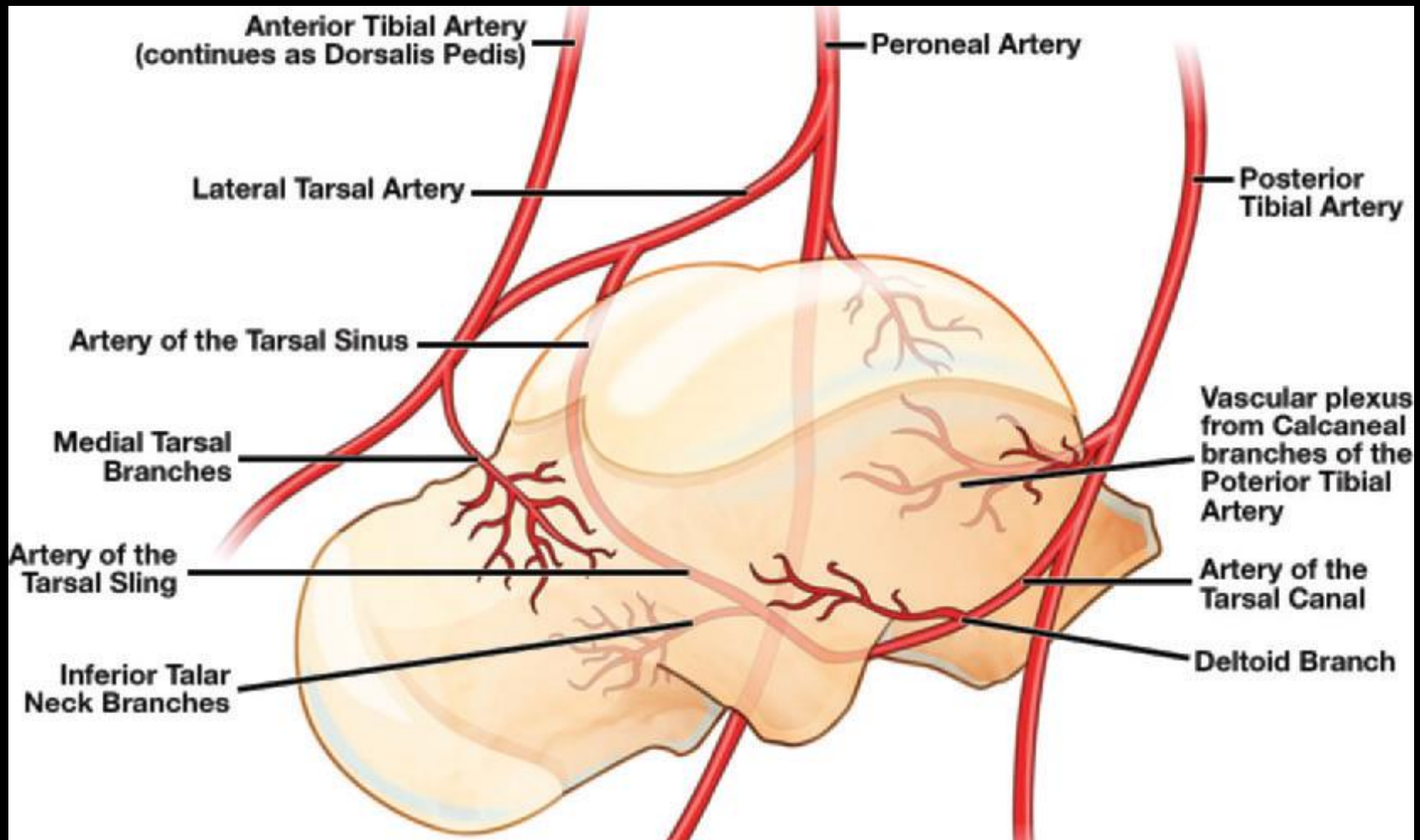
<https://boneandspine.com/blood-supply-of-talus/>



The Talus: Anatomy

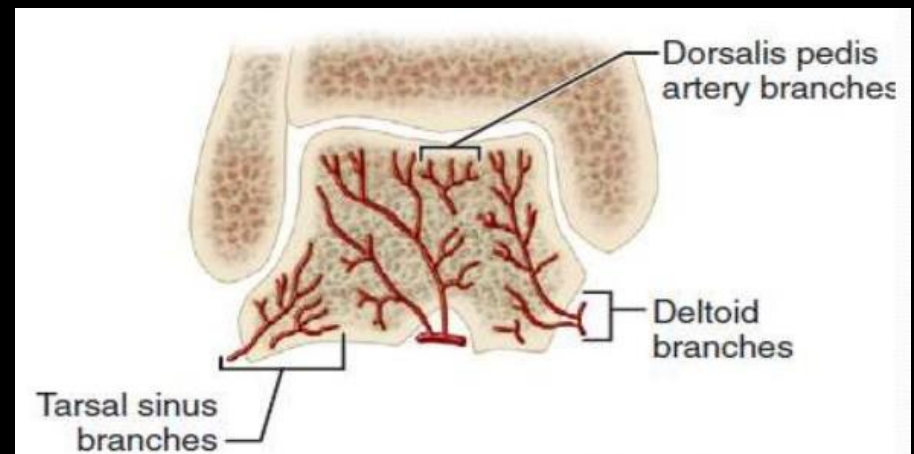
- **Posterior tibial artery:**
 - The posterior tubercle branches supply:
 - Both the medial and lateral tubercles
 - The tarsal canal artery:
 - Origin: 1 cm proximal to the bifurcation into the medial and lateral plantar arteries
 - Deltoid branches
 - Courses through the tarsal canal into the sinus tarsi
 - At the sinus tarsi, it forms an anastomosis with the tarsal sinus artery
- **Tarsal sinus artery:**
 - Branches from an anastomotic loop between the perforating peroneal artery and the lateral tarsal artery

The Talus: Anatomy



The Talus: Anatomy

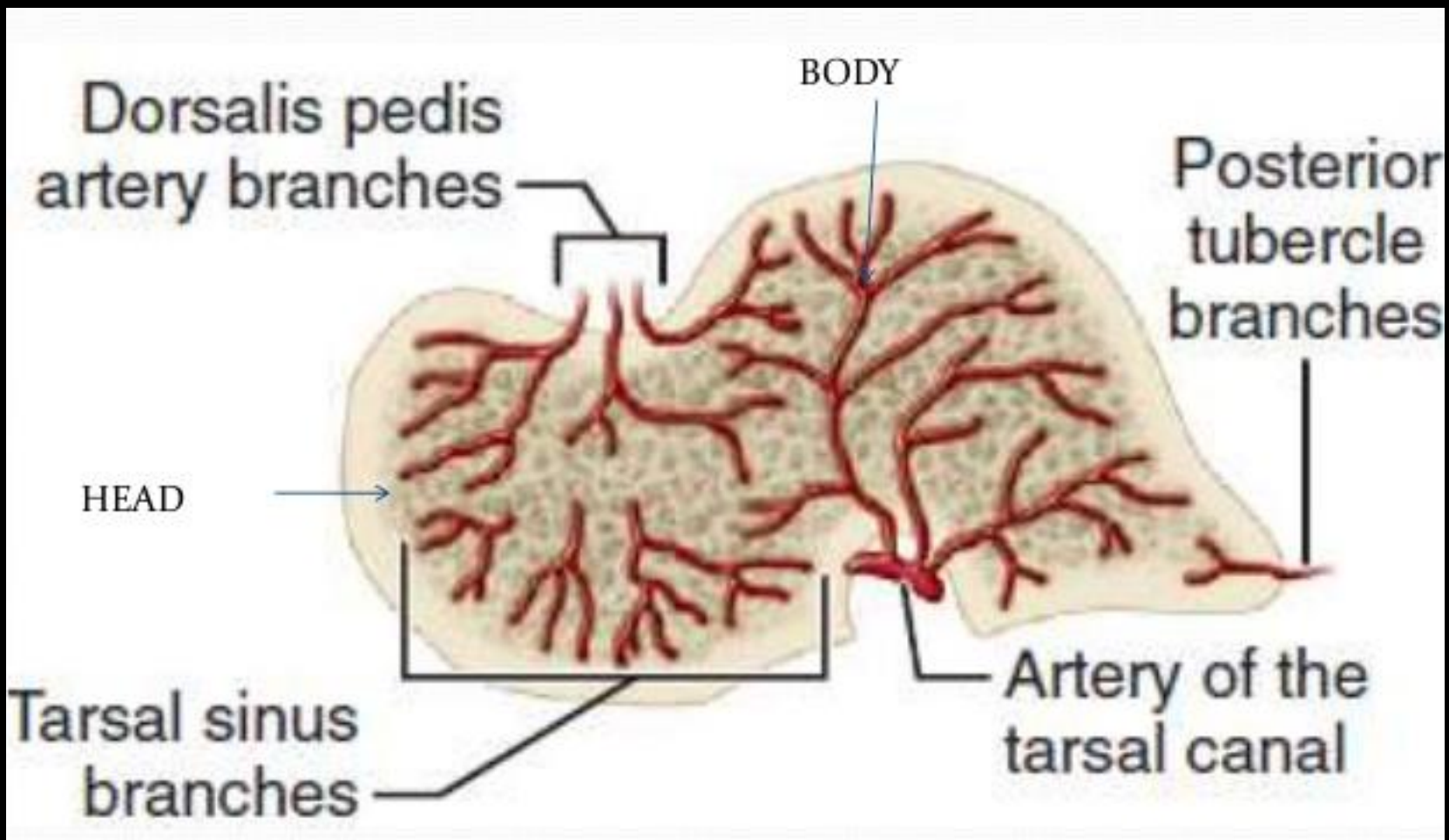
- Talar body blood supply:
 - Tarsal canal artery:
 - Supplies the central and lateral two-thirds of the talar body
 - The remaining medial third of the talar body receives deltoid branches, arising from the tarsal canal artery



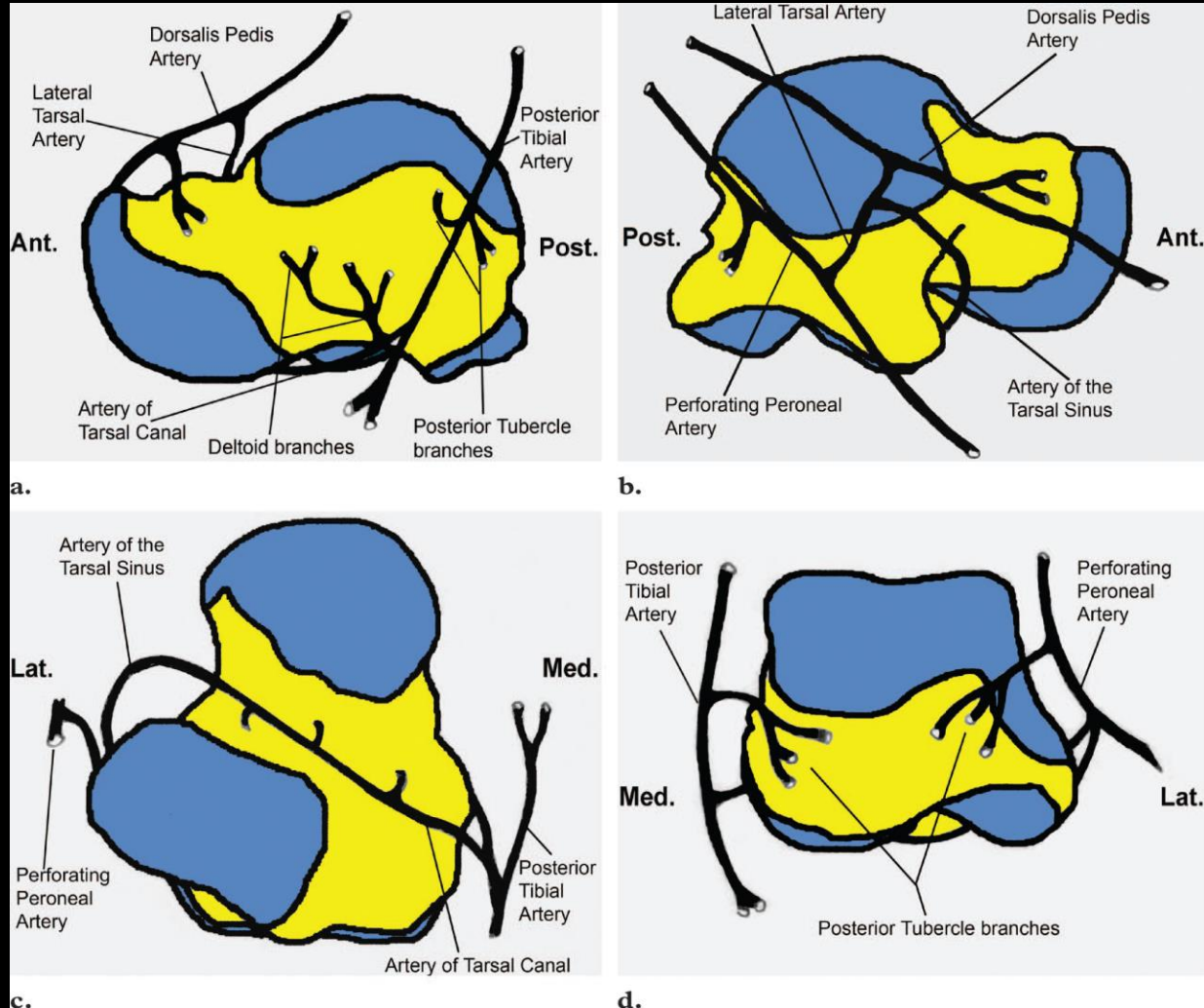
The Talus: Anatomy



- Talar neck blood supply:
 - The superomedial half of the talar neck and head is supplied by branches of the anterior tibial artery
 - The inferolateral half may be supplied:
 - Tarsal sinus artery
 - Branches of anastomosis of the tarsal sinus artery and the tarsal canal artery
 - Lateral tarsal artery, which arises from the dorsalis pedis artery

The Talus: Anatomy




The Talus: Anatomy



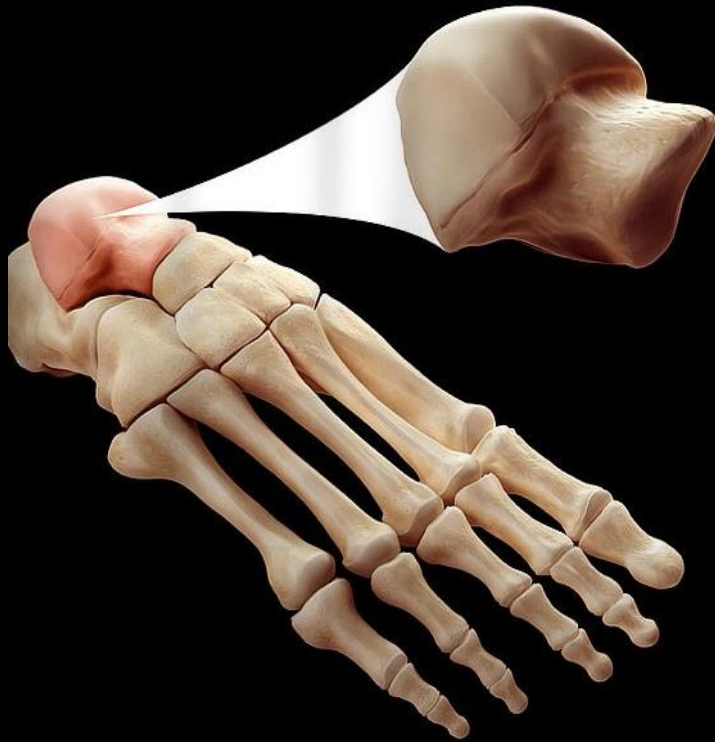


The Talus

- Rady Children's Hospital 3D Printing Lab



Special thanks to:
Dr. John Naheedy
Dr. Jerry Dewek
Dr. Daniel Vincour



Anatomy

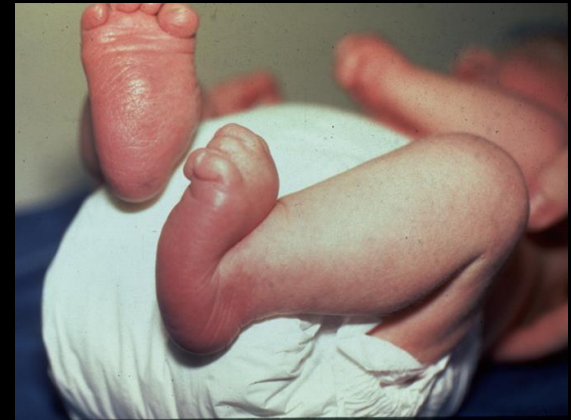Congenital

The Talus: Congenital Anomalies

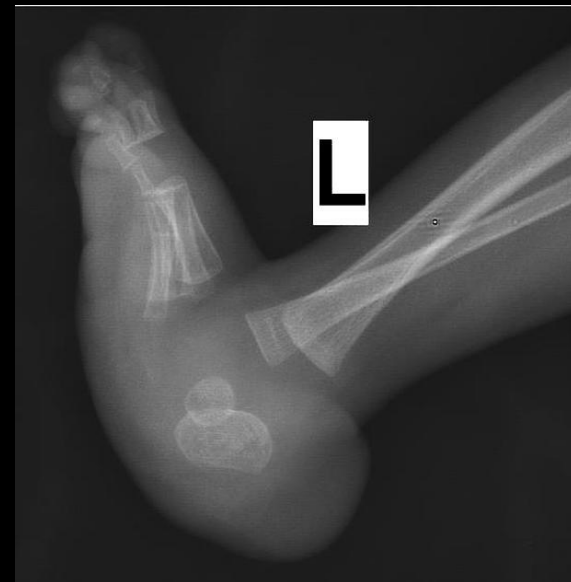
- Congenital Vertical Talus (CVT)
- Clubfoot
- Talar coalition
- Accessory anterolateral talar facet (AALTF)

The Talus: Congenital Anomalies

- **Congenital Vertical Talus**
 - **Rocker bottom foot**
 - Prominent calcaneus/heel and a convexly rounded sole
 - Irreducible dorsal dislocation of the navicular on the talus producing a rigid flatfoot deformity present at birth



<https://www.orthobullets.com/pediatrics/4066/congenital-vertical-talus>

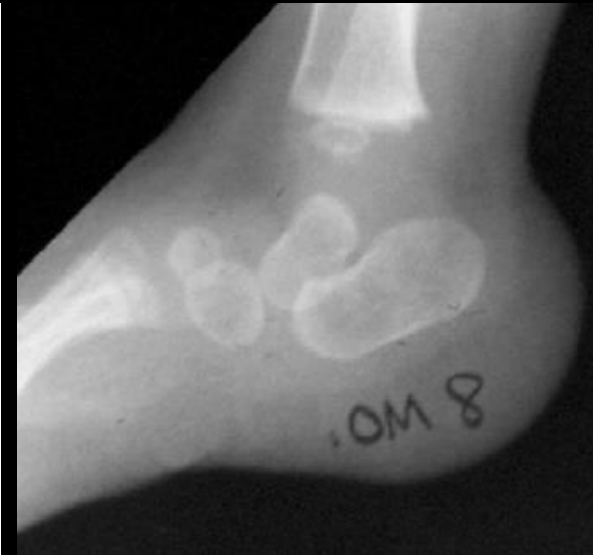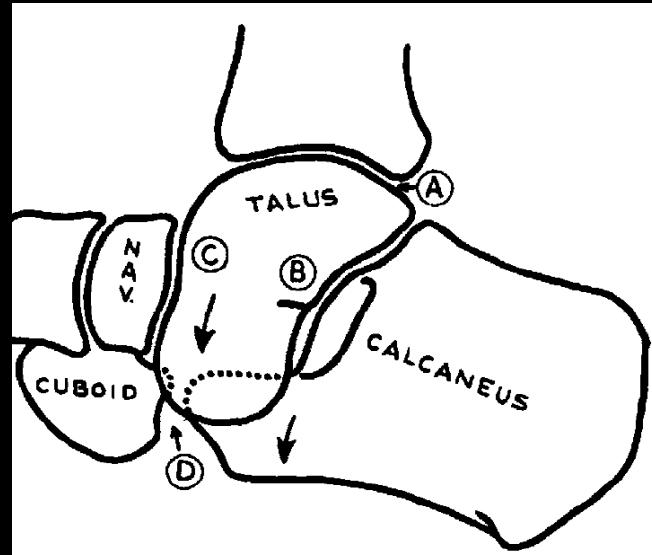
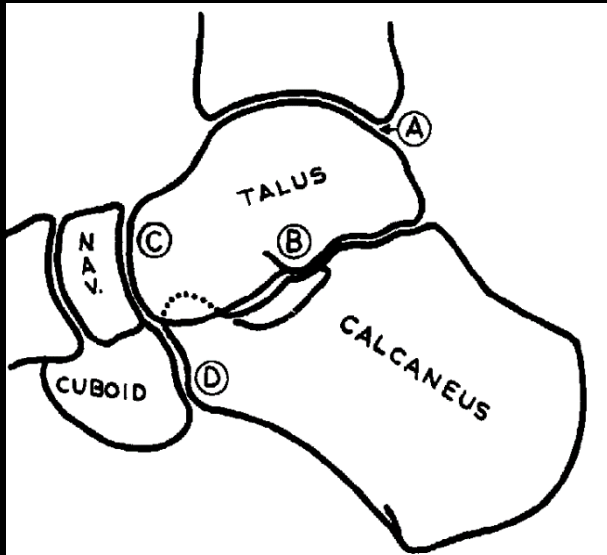


The Talus: Congenital Anomalies

- **Congenital Vertical Talus**

Normal

CVT



HAVESON, et al Congenital Flatfoot Due to Talonavicular Dislocation (Vertical Talus)

The Talus: Congenital Anomalies

- **Congenital Vertical Talus**

- Epidemiology:

- Rare, 1:150,000 births

- 50% associated with neuromuscular disease
chromosomal aberrations

- 50% bilateral

- M:F ratio of 2:1

The Talus: Congenital Anomalies

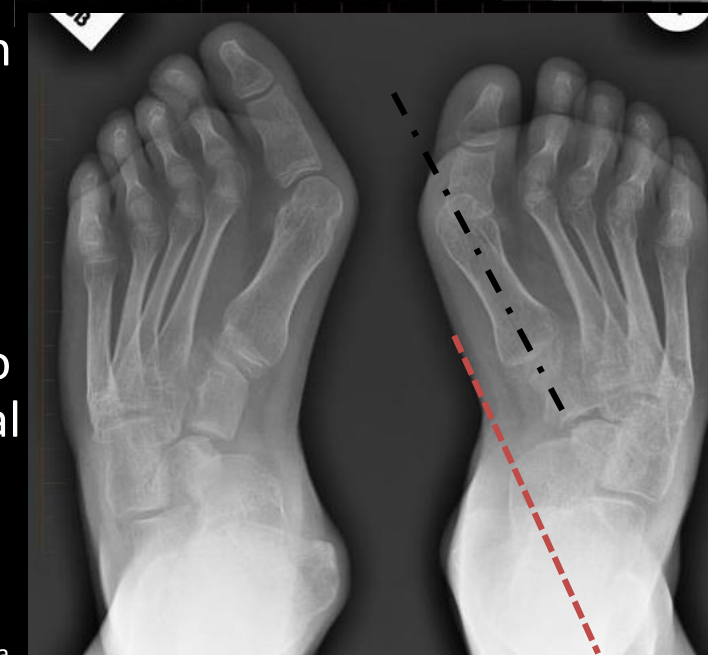
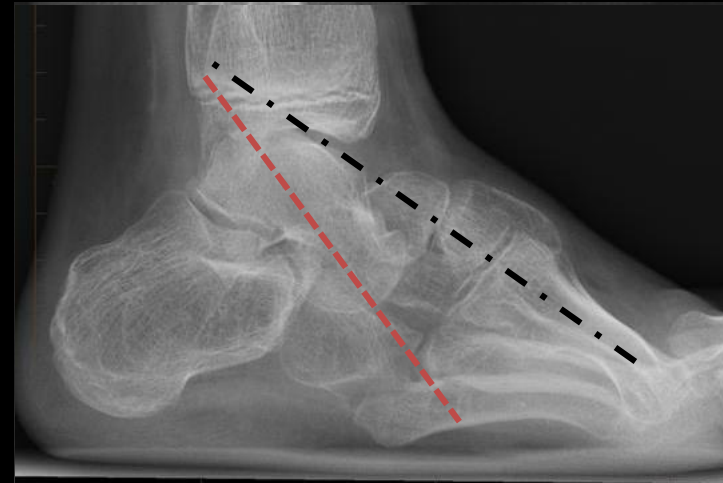
- **Congenital Vertical Talus**
 - Association:
 - Trisomy 13, 18
 - Myelomeningocele
 - Arthrogyryposis
 - Diastematomyelia
 - Congenital dislocation of the hip
 - Cerebral palsy
 - Spinal muscular atrophy

The Talus: Congenital Anomalies

- **Congenital Vertical Talus**

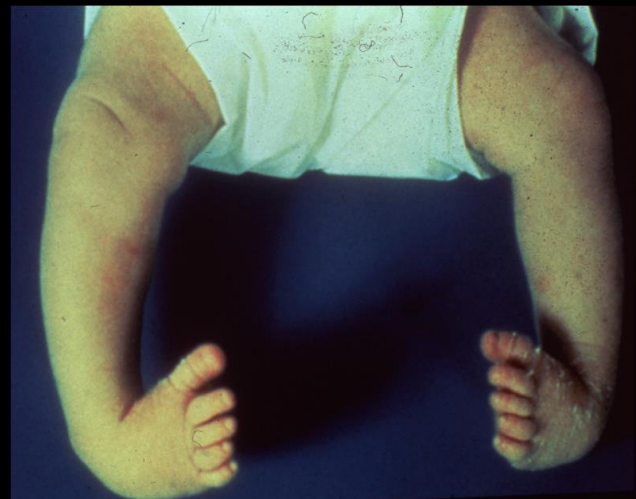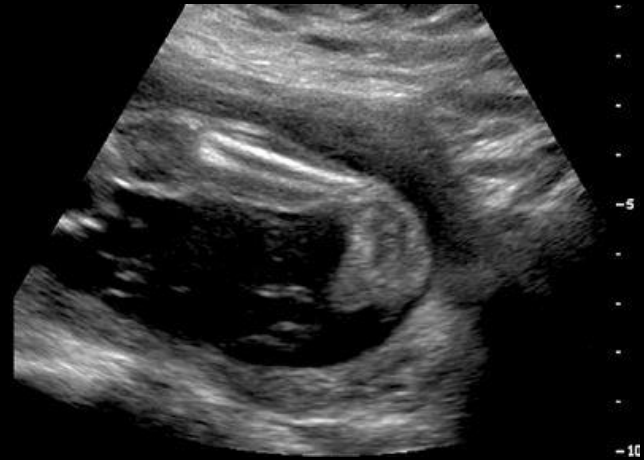- Radiologic features:

- Fixed equinus: plantarflexion of the calcaneus
- Vertical talus: plantarflexion of the talus
- Irreducible dorsal navicular dislocation
- Forefoot valgus: divergence of the metatarsal bases (AP) and superimposition of the metatarsal bones (lateral)
- Long axis of the talus passes plantar to the metatarsal axis (lateral) and medial to the first metatarsal (AP)



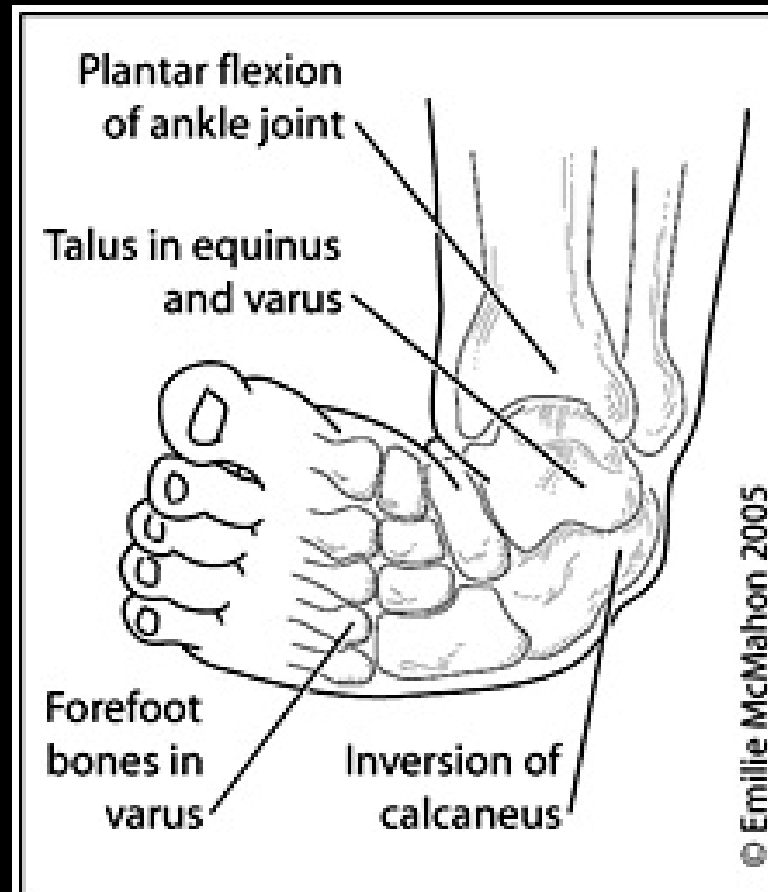
The Talus: Congenital Anomalies

- **Congenital Talipes equinovarus:**
 - **ClubFoot**
 - Idiopathic deformity of the foot of unclear etiology



The Talus: Congenital Anomalies

- **Clubfoot (congenital talipes equinovarus):**



The Talus: Congenital Anomalies

- **Clubfoot (congenital talipes equinovarus):**
 - Most common musculoskeletal birth defect
 - Overall incidence 1:1,000, though some populations 1:250 (Hawaiians and Maoris)
 - Male:female ratio 2:1
 - 50% bilateral
 - May be idiopathic, neurogenic, or syndrome-associated
 - 80% isolated

The Talus: Congenital Anomalies

- **Clubfoot (congenital talipes equinovarus):**
- Pathophysiology
 - Muscle contractures contribute to the characteristic deformity that includes (*CAVE*)
 - Cavus (tight intrinsics, FHL, FDL)
 - Adductus of forefoot (tight tibialis posterior)
 - Varus (tight tendoachilles, tibialis posterior, tibialis anterior)
 - Equinus (tight tendoachilles)

The Talus: Congenital Anomalies

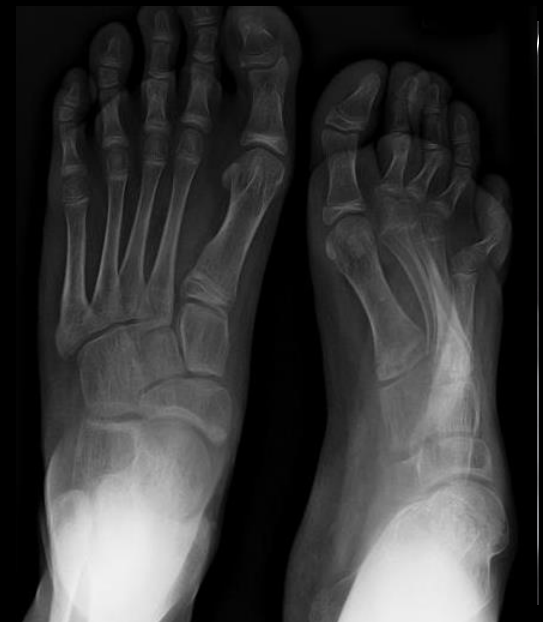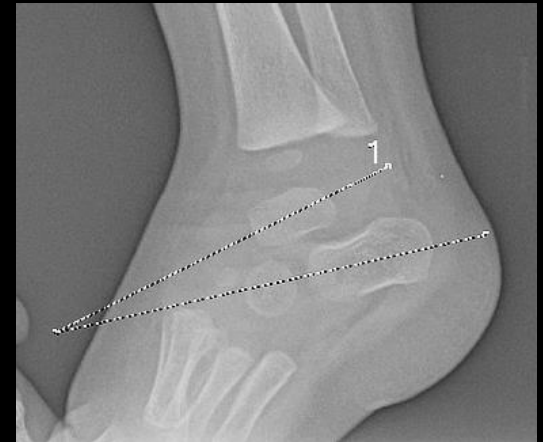- **Clubfoot (congenital talipes equinovarus):**
- Pathophysiology
 - Genetics
 - Genetic component is strongly suggested
 - Unaffected parents with affected child have 2.5% - 6.5% chance of having another child with a clubfoot
 - Familial occurrence in 25%
 - Recent link to *PITX1*, transcription factor critical for limb development
 - Common genetic pathway may exist with congenital vertical talus

The Talus: Congenital Anomalies

- **Clubfoot (congenital talipes equinovarus):**
- Pathophysiology
 - Associated conditions
 - Arthrogryposis
 - Diastrophic dysplasia
 - Myelodysplasia
 - Tibial hemimelia
 - Amniotic band syndrome (streeter dysplasia)
 - Upper extremity and hand anomalies common in this population
 - Pierre robin syndrome
 - Opitz syndrome
 - Larsen syndrome
 - Prune-belly syndrome
 - Anterior tibial artery hypoplasia or absence is common, regardless of etiology of clubfoot

The Talus: Congenital Anomalies

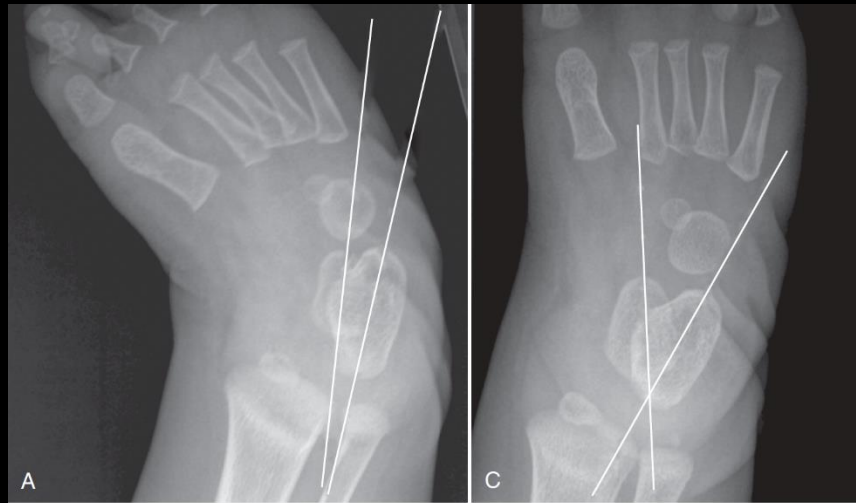
- **Clubfoot (congenital talipes equinovarus):**
 - Radiologic features:
 - Hindfoot equinus: lateral talocalcaneal angle less than 35°
 - Hindfoot varus: talocalcaneal angle less than 20°
 - Metatarsus adductus
 - Talonavicular subluxation: medial subluxation of the navicular on the talus



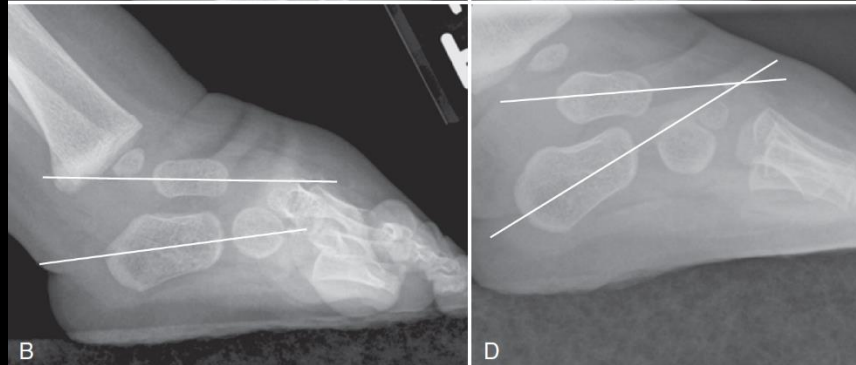
The Talus: Congenital Anomalies

- Clubfoot (congenital talipes equinovarus):

Frontal talocalcaneal angle



Lateral talocalcaneal angle





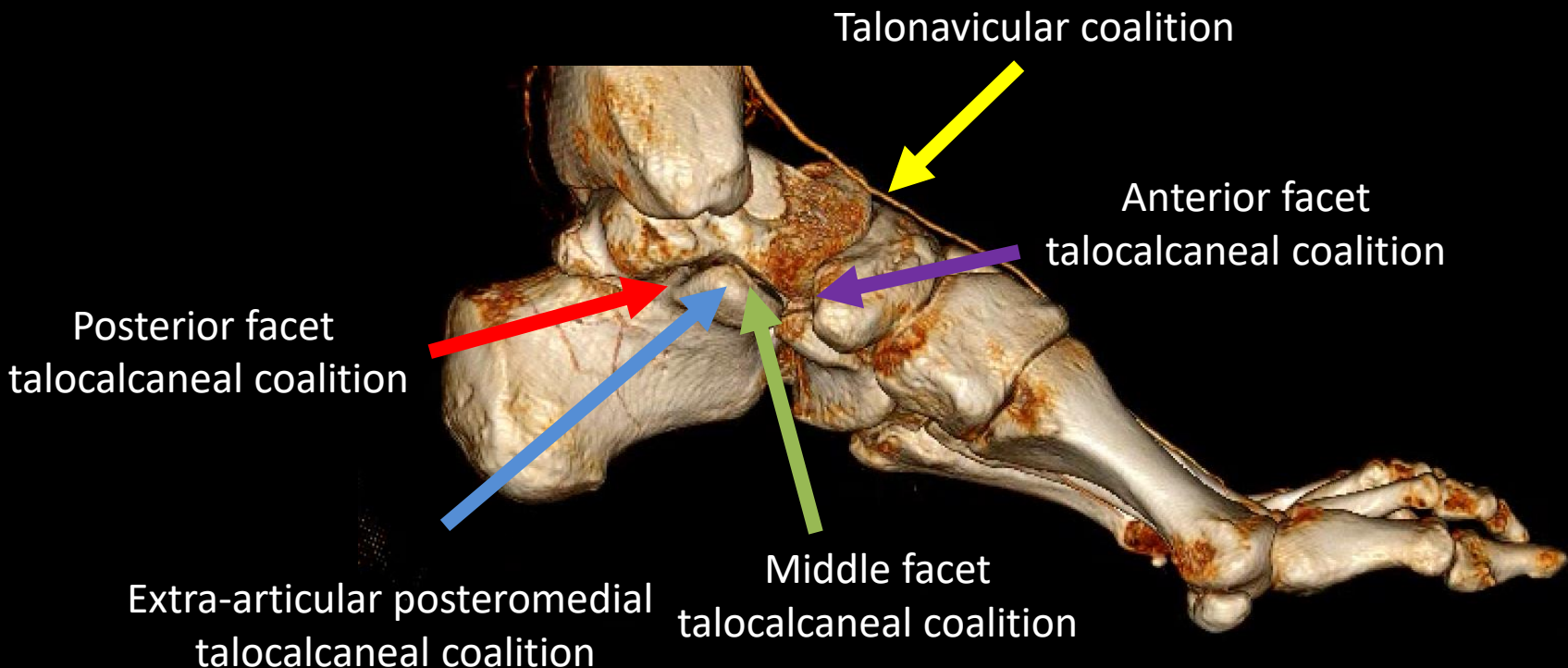
<https://www.etsy.com>

The Talus: Coalition

- **Tarsal Coalition:**
 - Abnormal union between two tarsal bone:
 - Osseous (synostosis)
 - Cartilaginous (synchondrosis)
 - Fibrous (syndesmosis)
 - Any age:
 - Hindfoot and midfoot pain
 - Frequent ankle sprains
 - Rigid flatfoot
 - Incidence of 1–2%

The Talus: Congenital Anomalies

- Talus coalition:



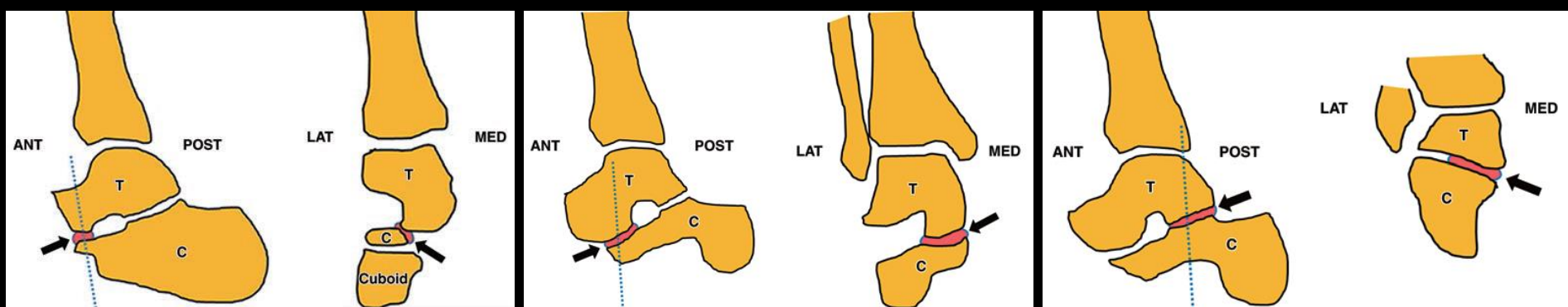
The Talus: Congenital Anomalies

- Talus Coalition:

Anterior facet TCC

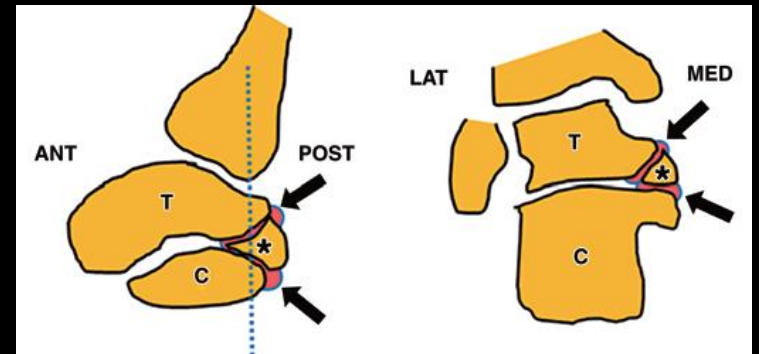
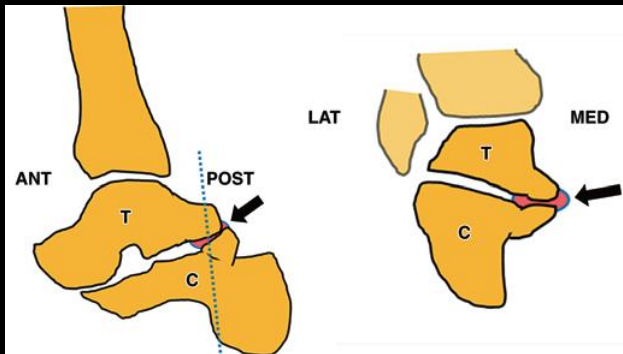
Middle facet TCC

Posterior facet TCC



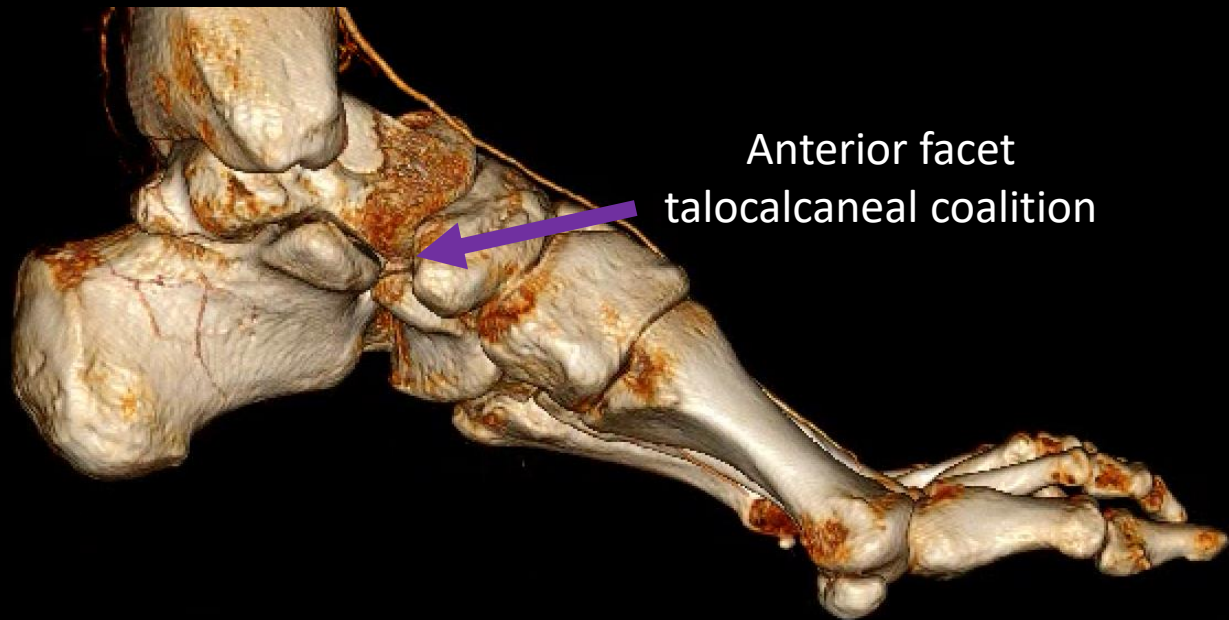
Extraarticular TCC

Extraarticular TCC with os sustentaculum



The Talus: Congenital Anomalies

- Talus Coalition:

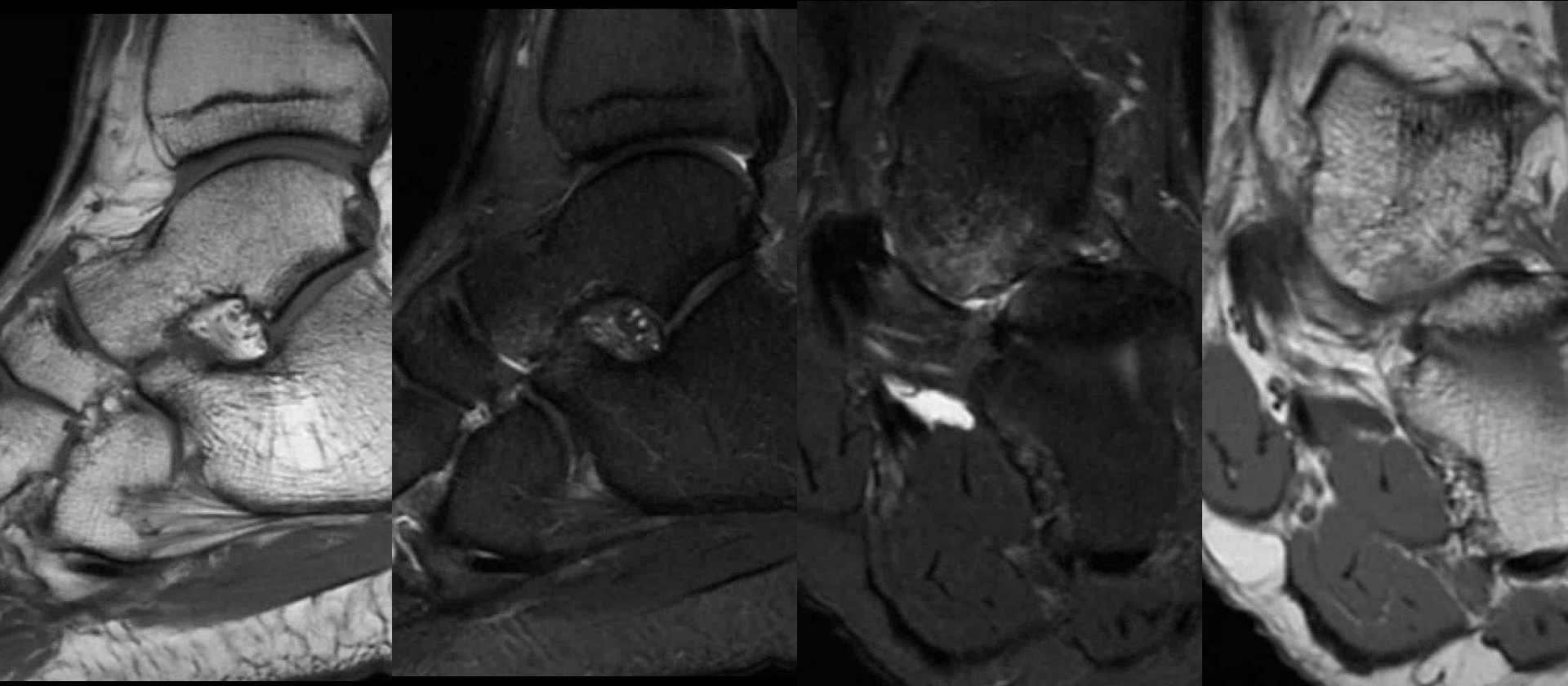


The Talus: Congenital Anomalies

- Anterior facet talocalcaneal coalition
 - Rare
 - Anterior process of the calcaneus and anterior facet of the talus

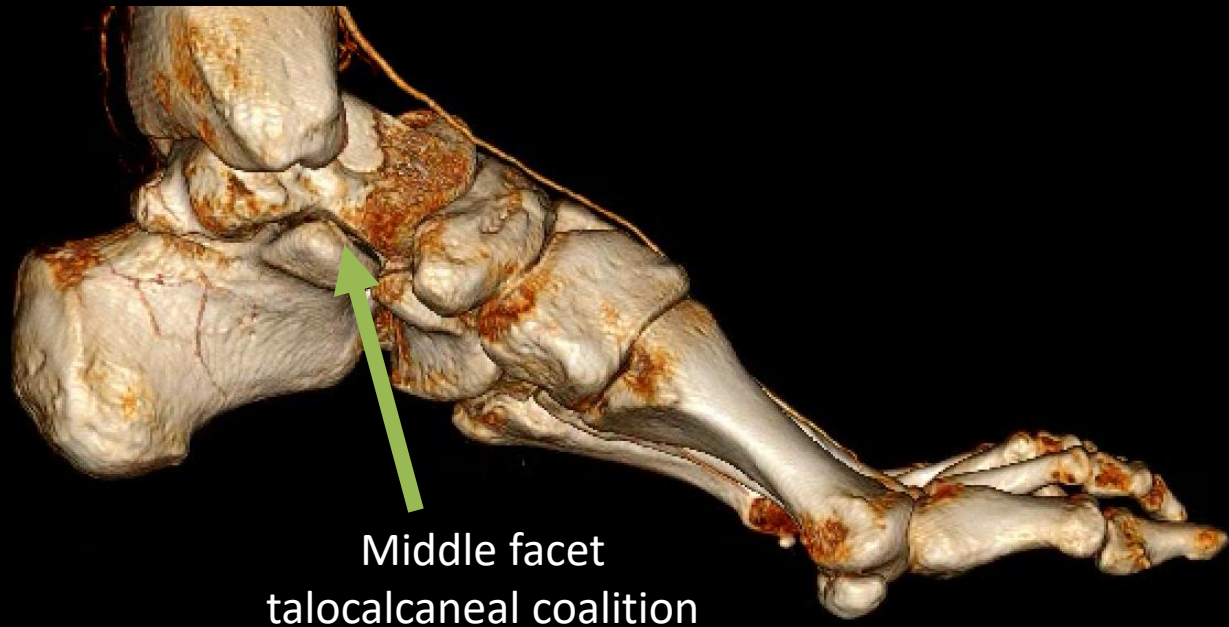
Anterior facet talocalcaneal coalition

30 year old male. Left ankle pain. Multiple sprains previously.
Painful medial, lateral talus, and anterior process of the calcaneus.



The Talus: Congenital Anomalies

- Talus Coalition:

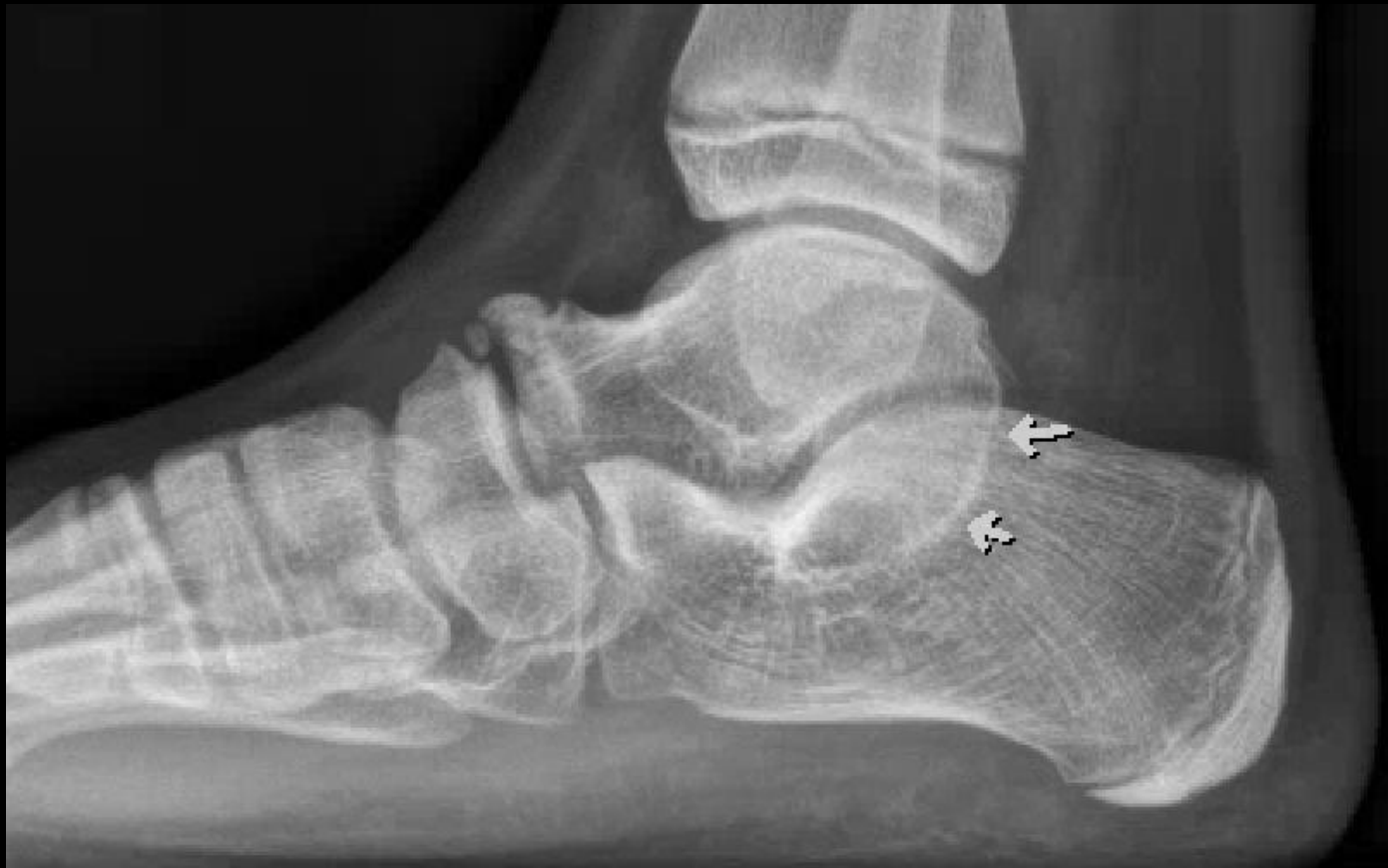

The Talus: Congenital Anomalies

- Middle facet talocalcaneal coalition
 - Most common TCC
 - C-sign
 - Talar beak
 - Typical downward medial sloping seen on coronal MR
 - Hypoplastic or aplastic sustentaculum tali may also be present

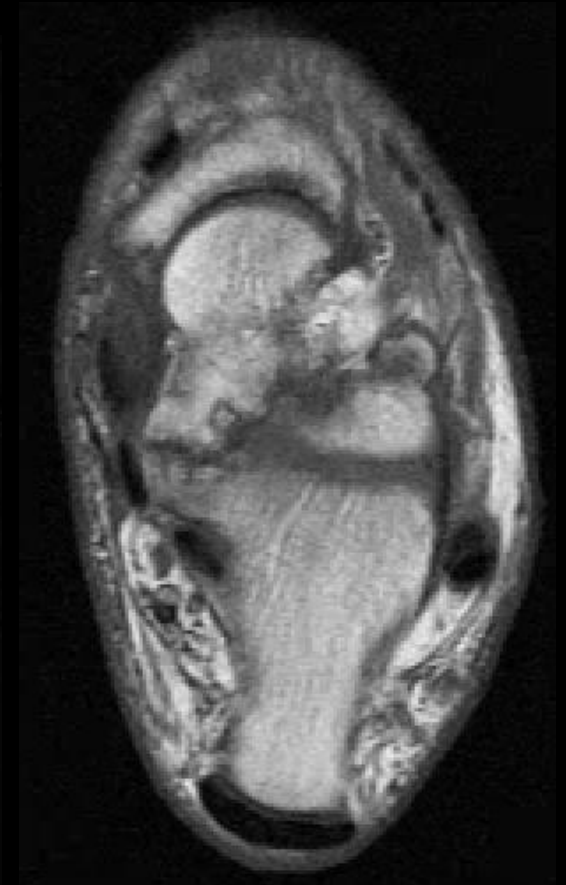
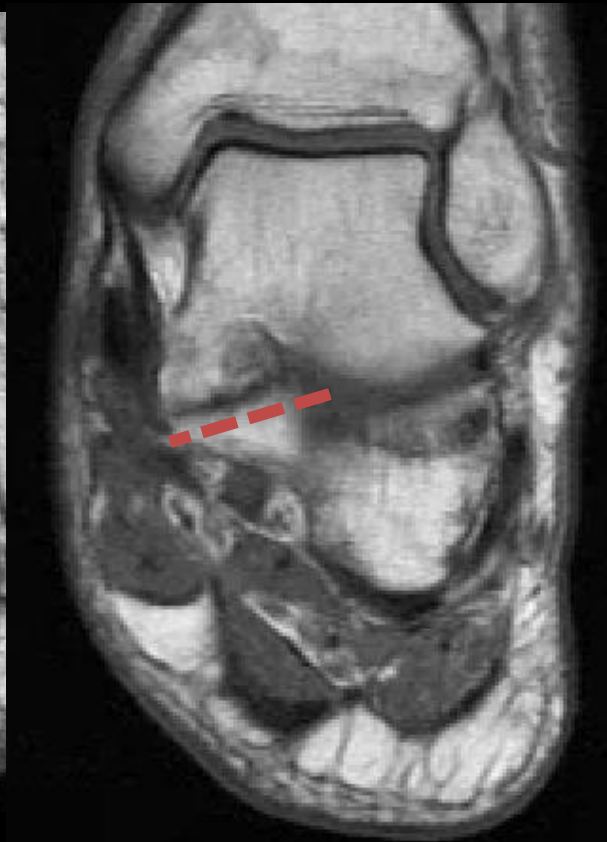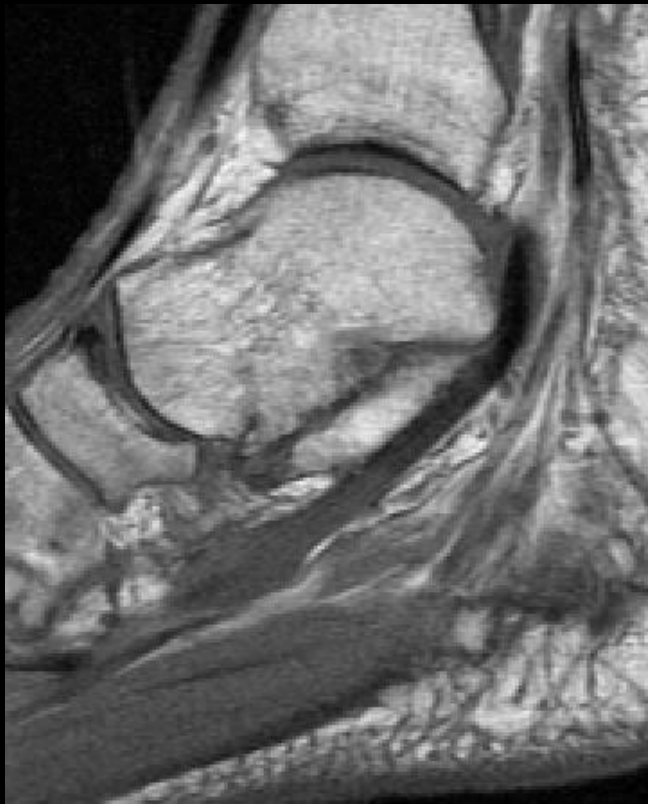
Middle facet talocalcaneal coalition

13 y/o male. Ankle pain.



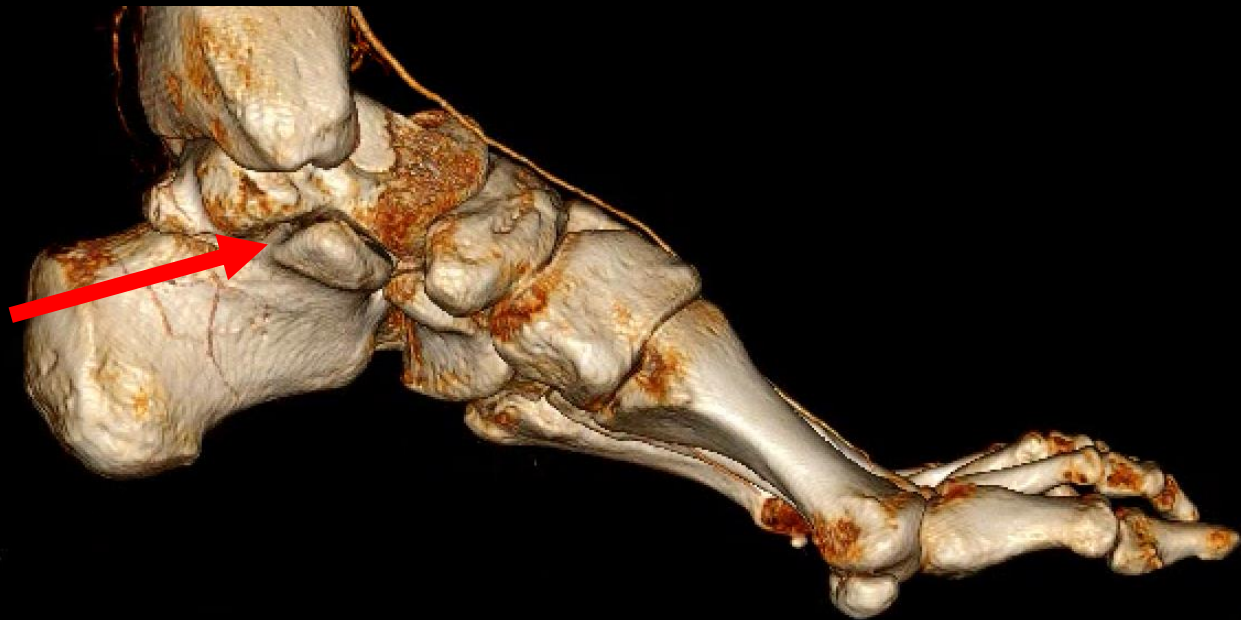
Middle facet talocalcaneal coalition

61 y/o male. Ankle pain.



The Talus: Congenital Anomalies

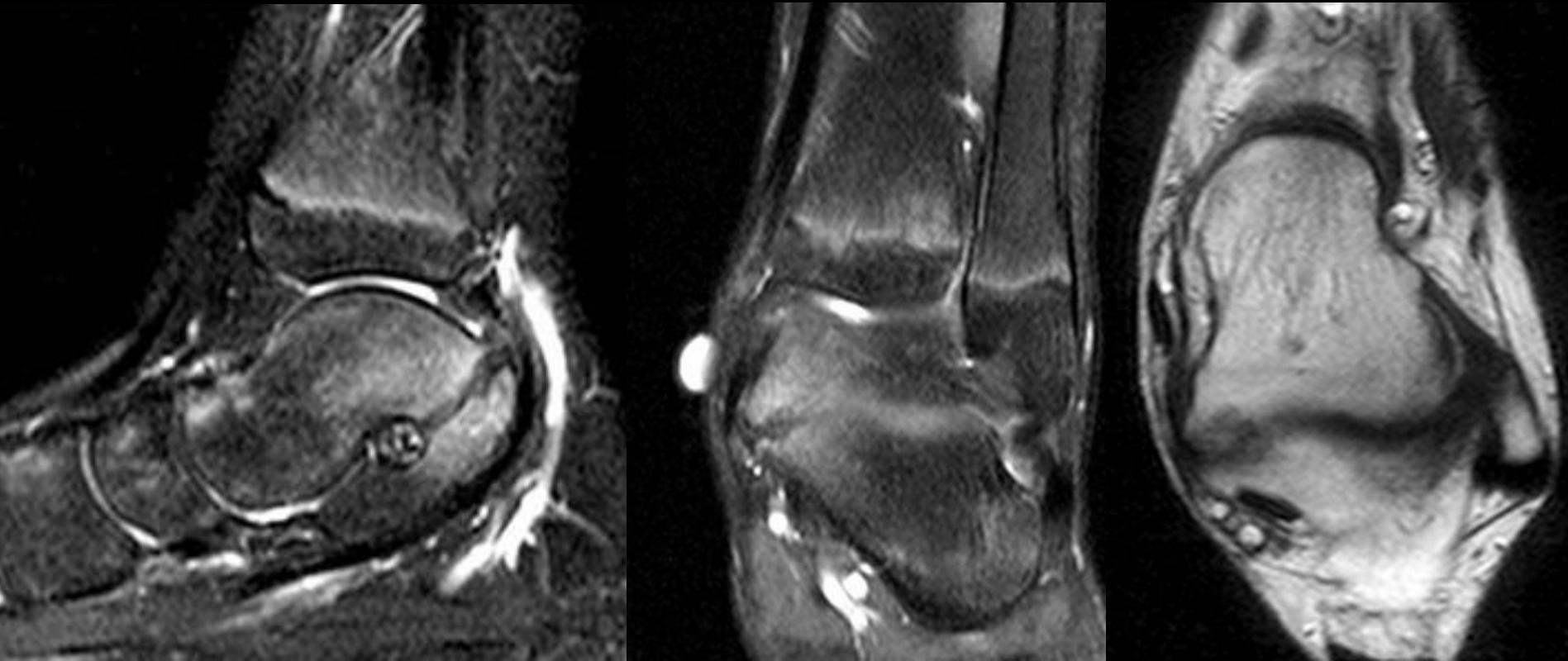
- Talus Coalition:



Posterior facet
talocalcaneal coalition

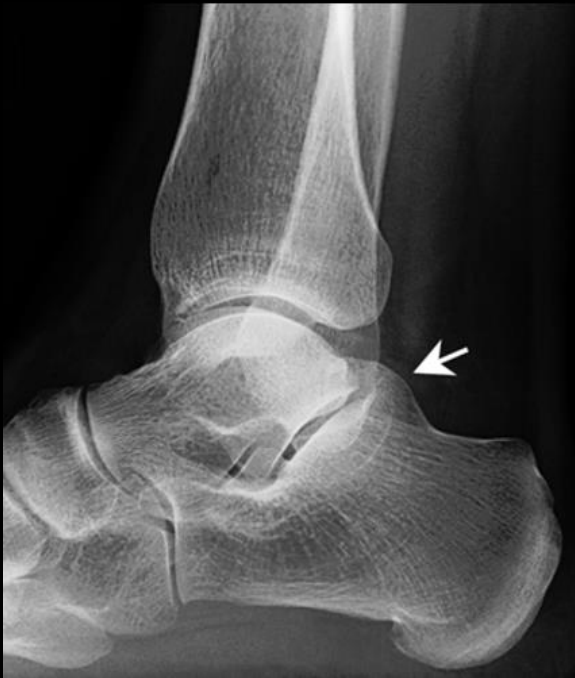Posterior facet talocalcaneal coalition

12 yo female presents with a history of medial pain

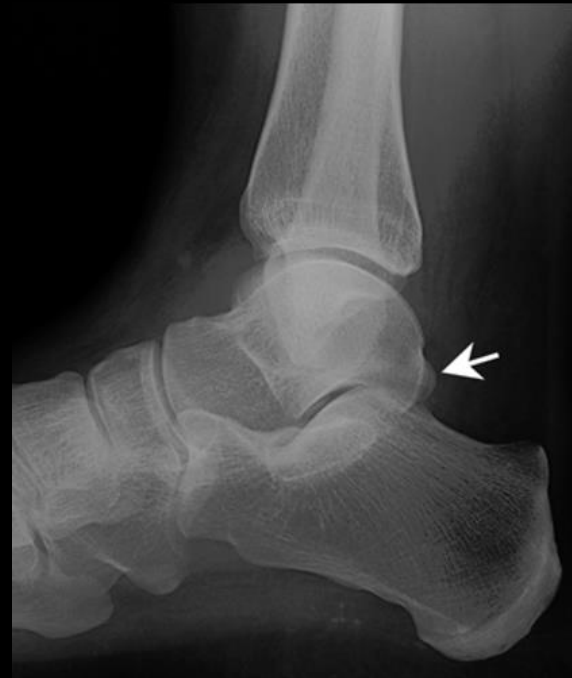

Posterior facet talocalcaneal coalition

48-year-old female with 3 months of worsening left heel pain. No preceding accident or injury.



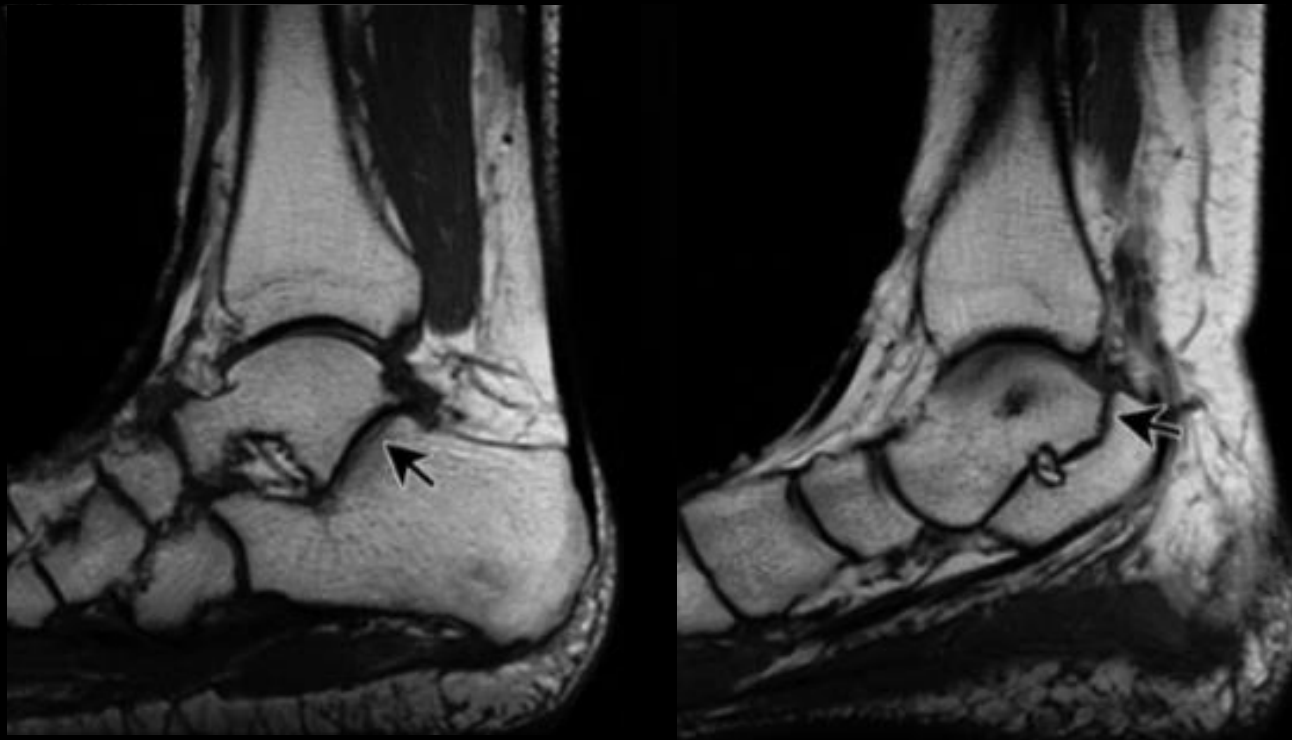
Moe et al. AJR:186, January 2006



Normal (For Comparison)

Posterior facet talocalcaneal coalition

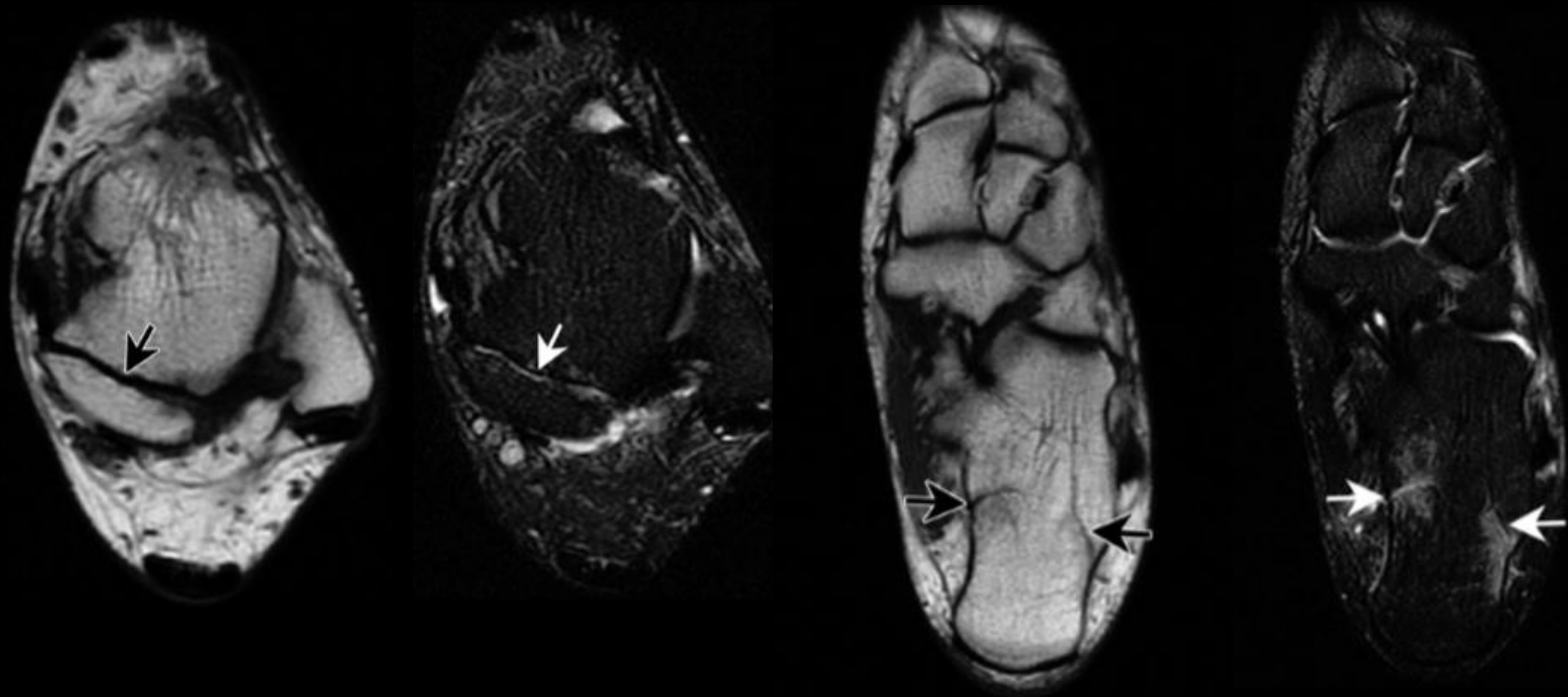
48-year-old female with 3 months of worsening left heel pain. No preceding accident or injury.



Moe et al. AJR:186, January 2006

Posterior facet talocalcaneal coalition

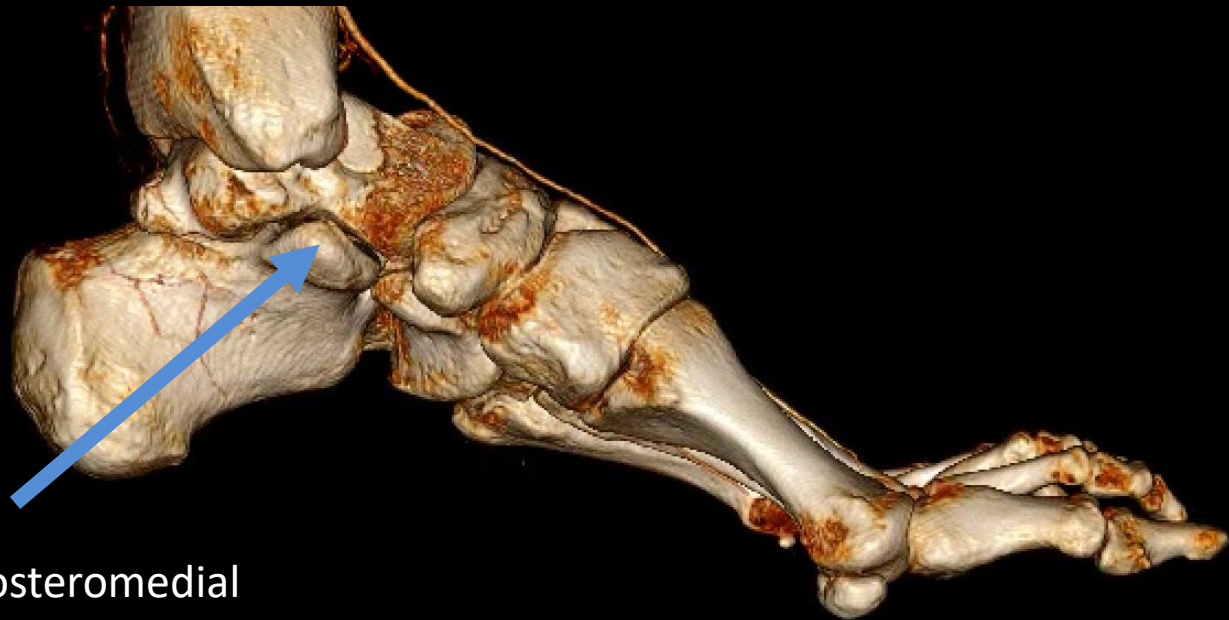
48-year-old female with 3 months of worsening left heel pain. No preceding accident or injury.



Moe et al. AJR:186, January 2006

The Talus: Congenital Anomalies

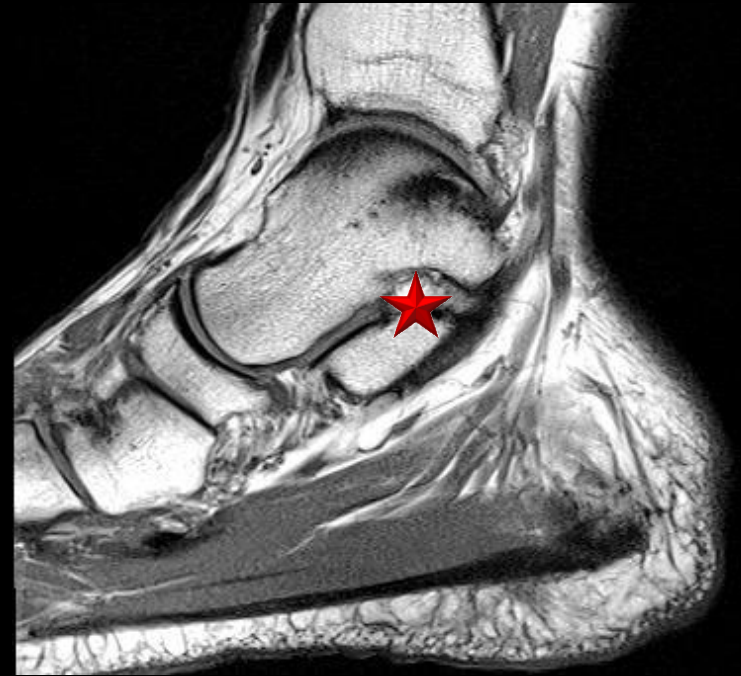
- Talus Coalition:



Extra-articular posteromedial
talocalcaneal coalition

The Talus: Congenital Anomalies

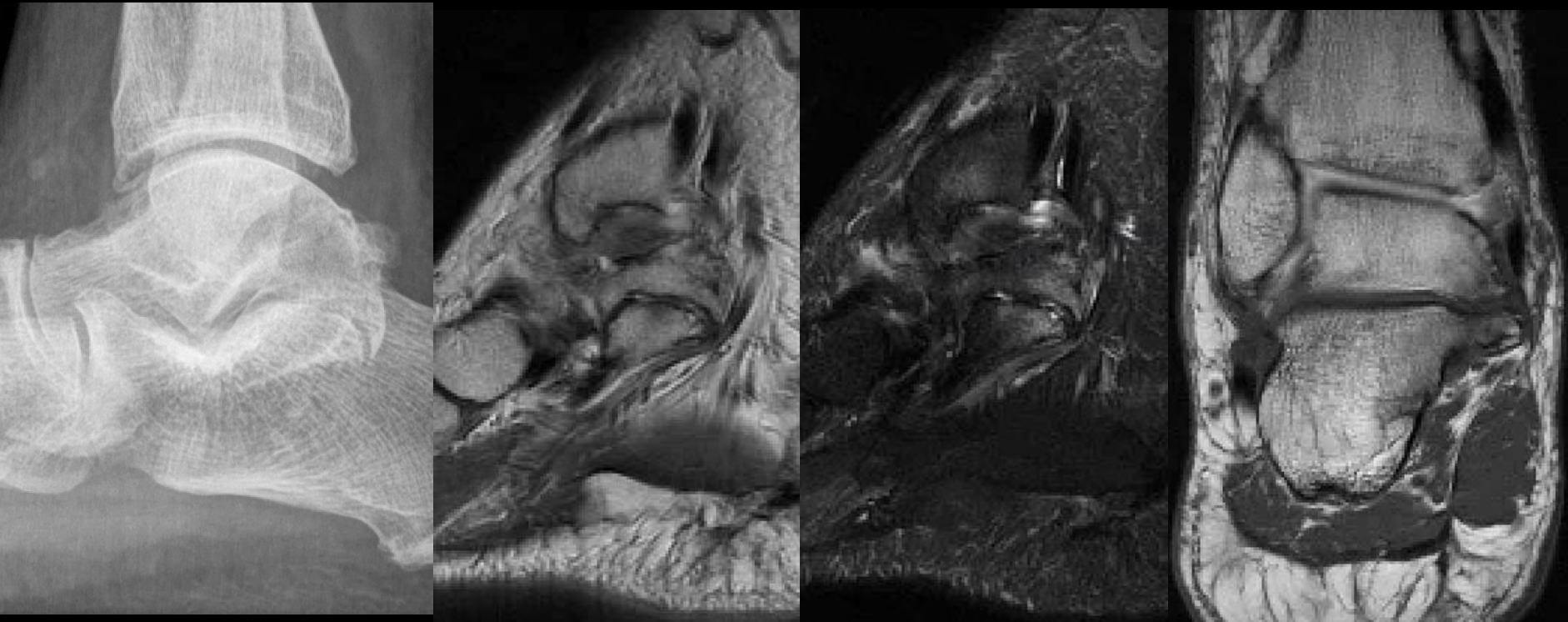
- Extra-articular posteromedial talocalcaneal coalition:
 - Described by Harris in 1955
 - Linklater et. al. suggested that EATCC is usually a fibrous coalition
 - Asymptomatic or minimally symptomatic adult patients
 - Accompanied by various bony deformities or relatively normal subtalar joint



The posterior sustentaculum tali★ is a ridge of bone posterior to the middle subtalar joint and medial to the posterior subtalar joint

Extra-articular posteromedial talocalcaneal coalition

52 y/o male ankle pain. No injury



The Talus: Congenital Anomalies

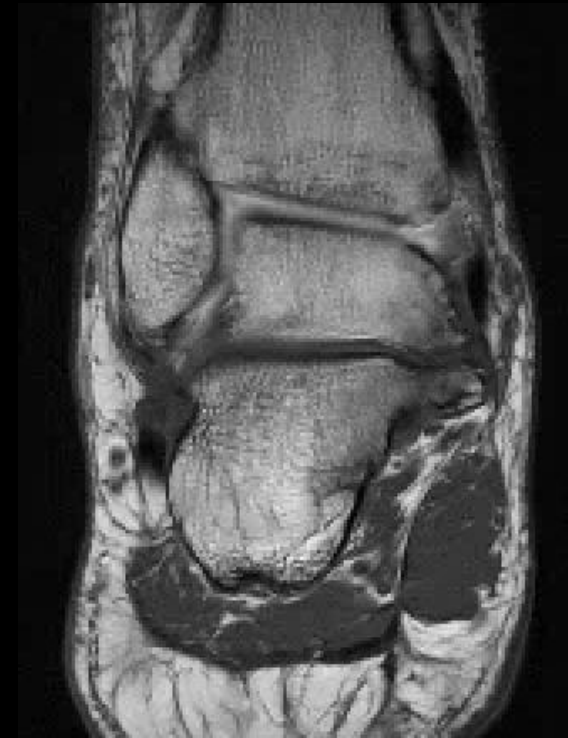- Extra-articular posteromedial talocalcaneal coalition:
 - Bixby, et al: 138 patients

Table 1 Location of coalition with respect to posterior facet, posteromedial sustentaculum and middle facet, and number of osseous coalitions at each site

Type of coalition	# of coalitions (%)	# of osseous coalitions (%)
Middle facet	97 (70.2)	33 (34)
Posterior facet	2 (1.4)	0 (0)
Posteromedial subtalar	39 (28.2)	0 (0)
Total	138 (100)	33 (23.9)

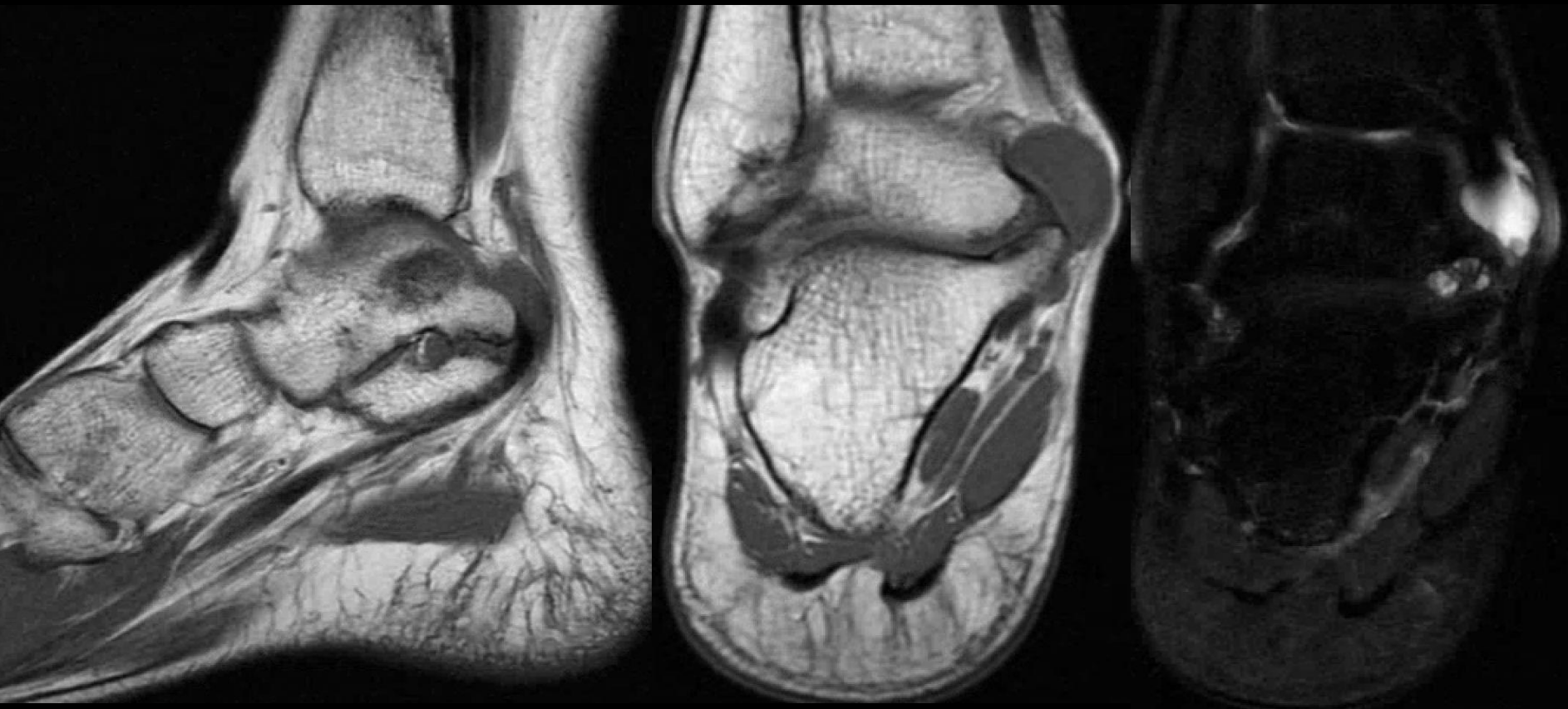The Talus: Congenital Anomalies

- Extra-articular posteromedial talocalcaneal coalition:
 - EATCC can result in tarsal tunnel syndrome:
 - Direct pressure by the bony protrusion on the tarsal tunnel structures
 - Secondary to ganglion cysts arising from the coalition and decompressing into the tarsal tunnel



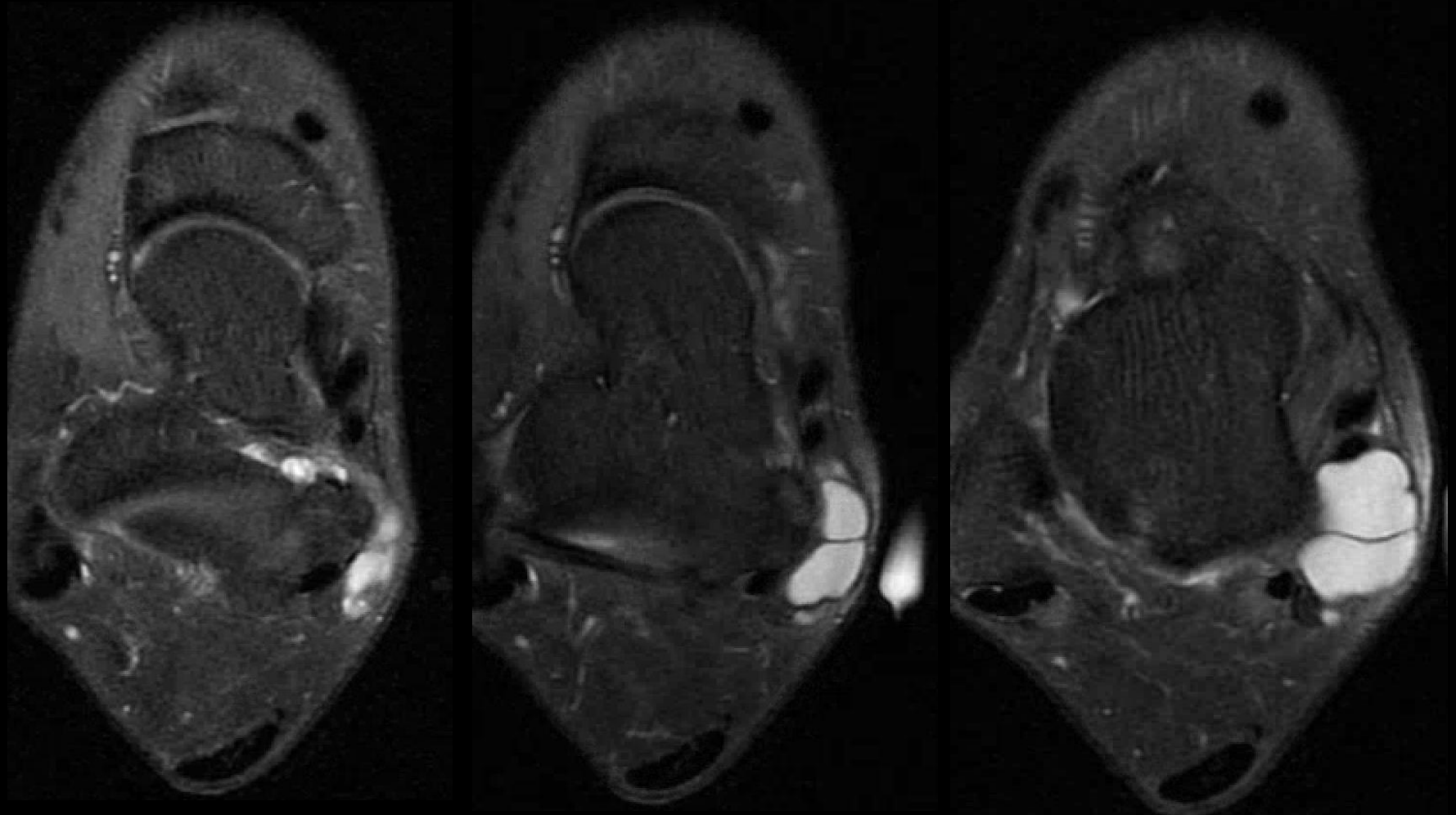
Extra-articular posteromedial talocalcaneal coalition

25 y/o female. Medial ankle mass status post injury 1 year ago causing pain and numbness.



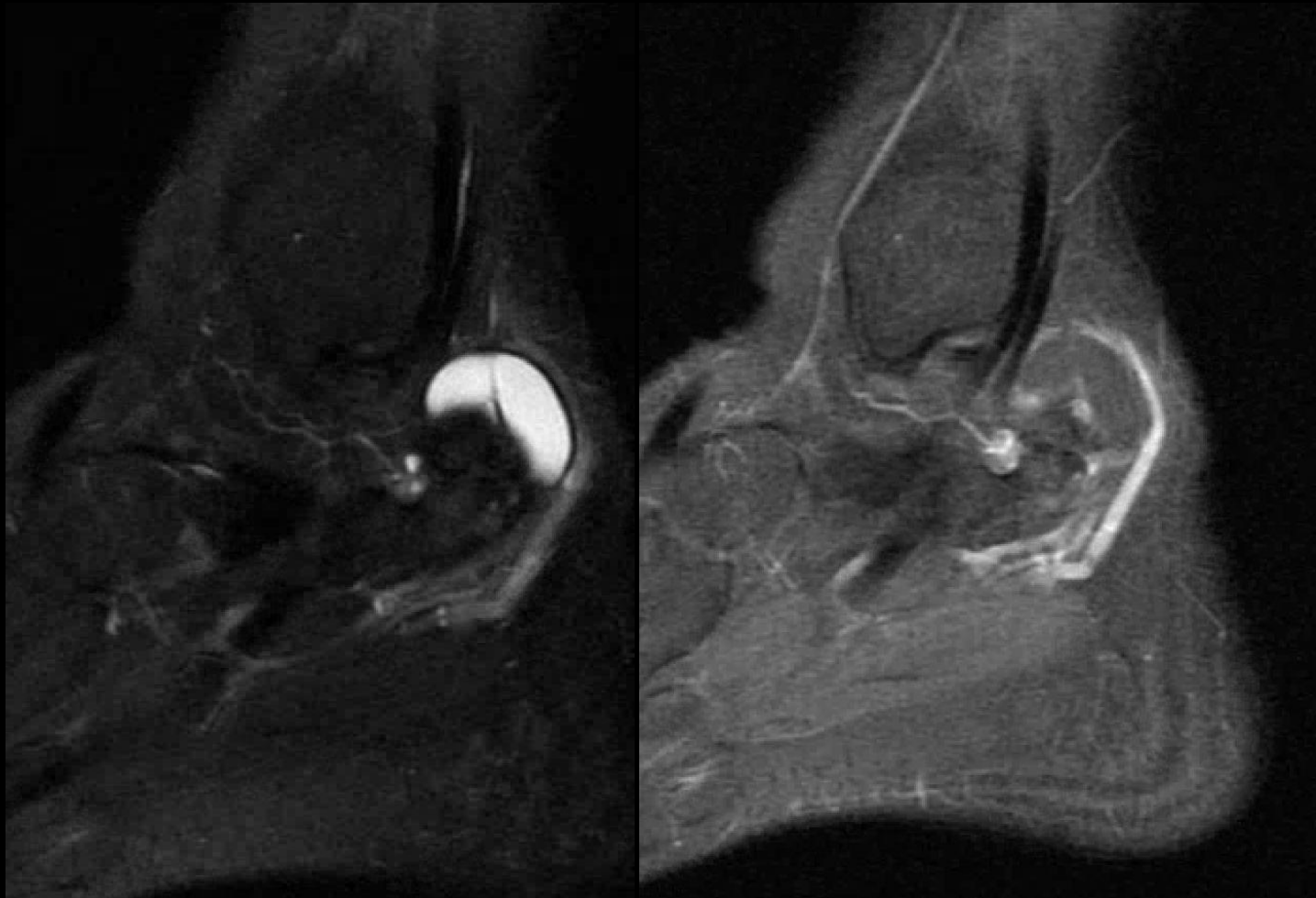
Extra-articular posteromedial talocalcaneal coalition

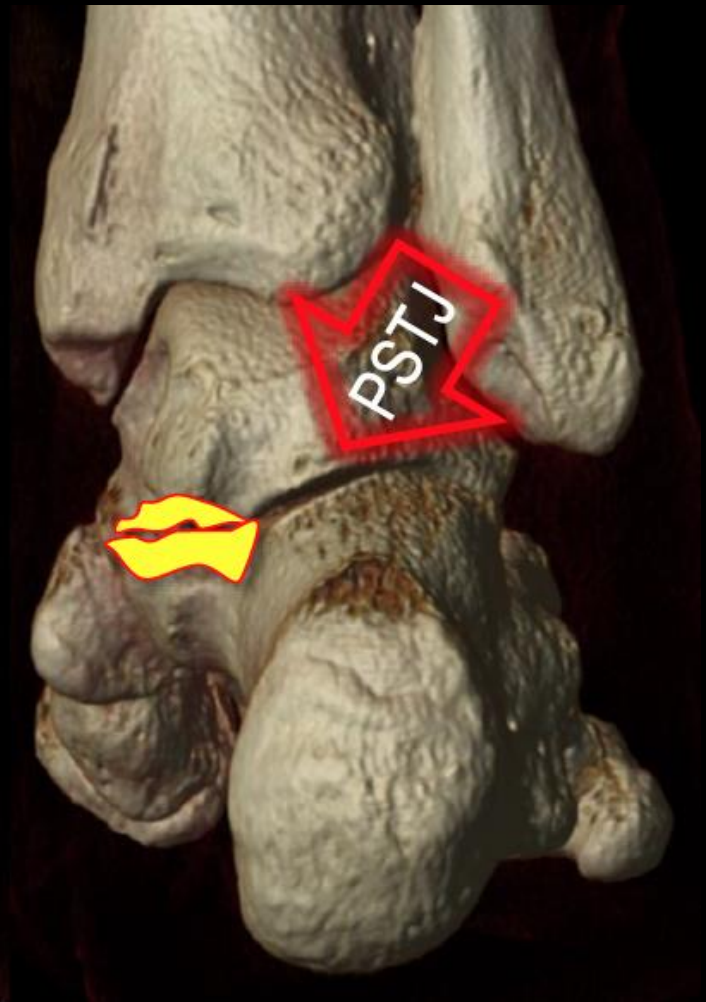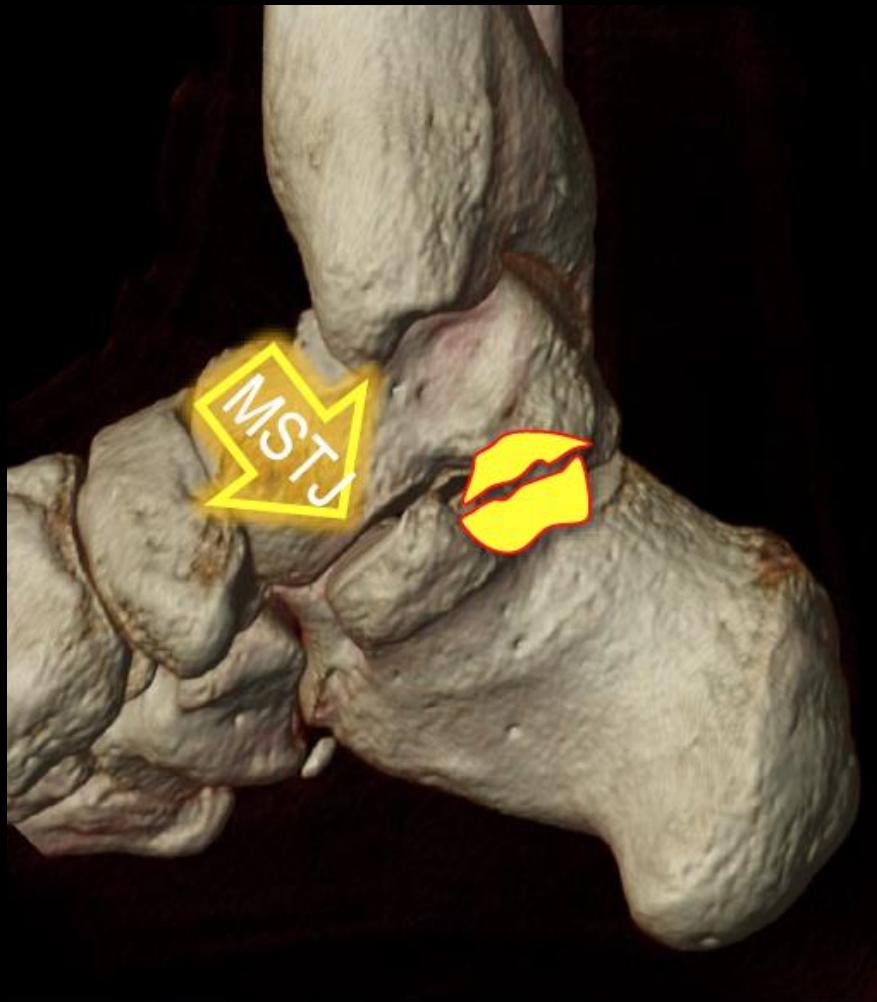25 y/o female. Medial ankle mass status post injury 1 year ago causing pain and numbness.



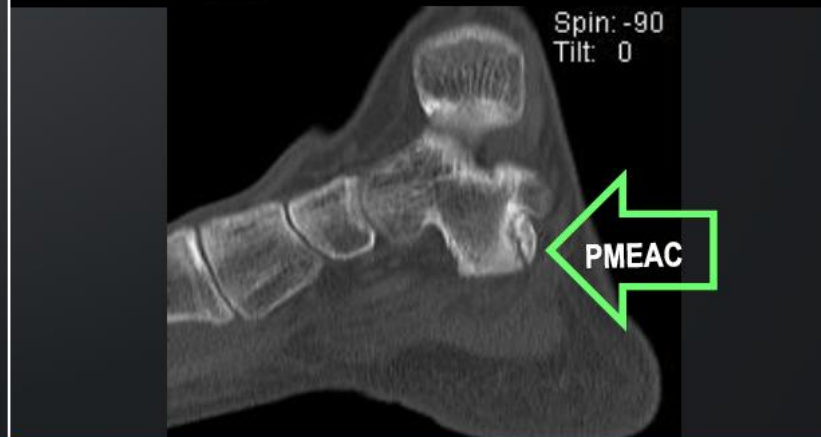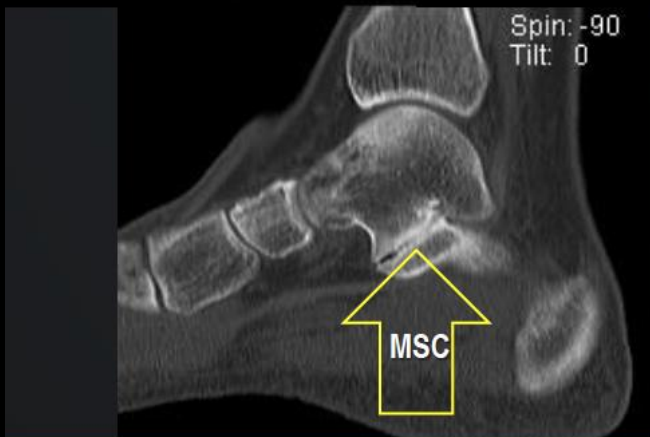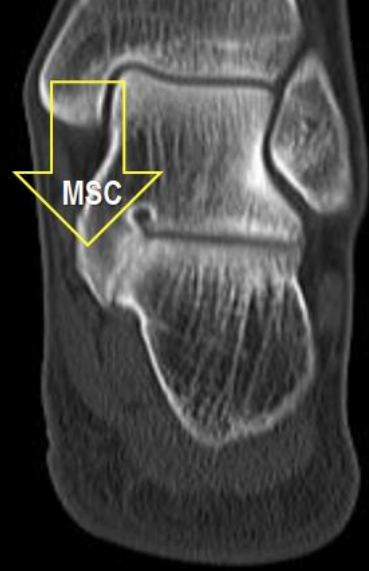
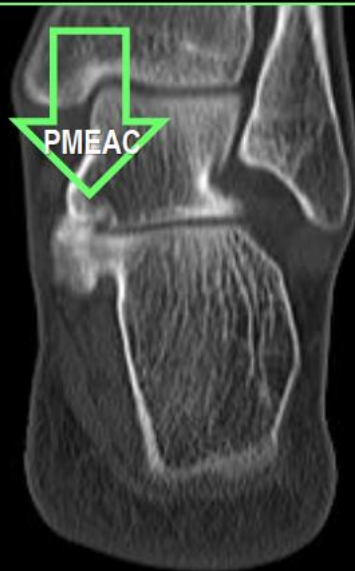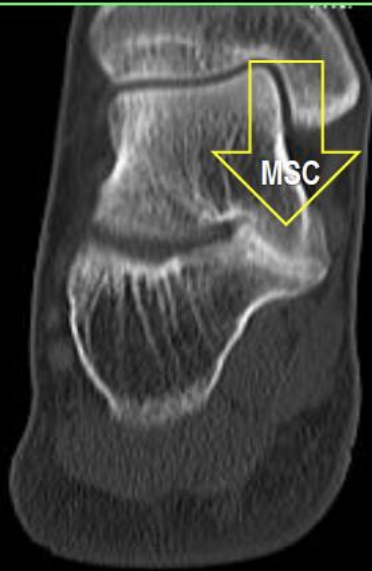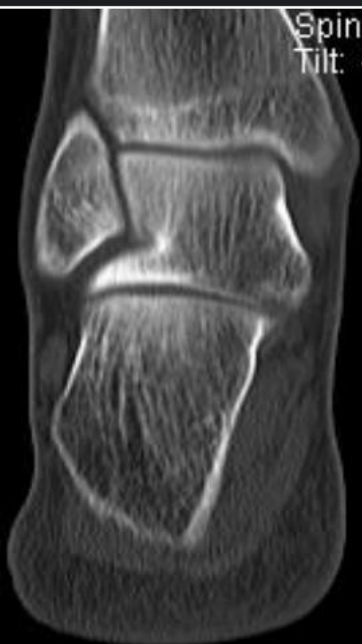Extra-articular posteromedial talocalcaneal coalition

25 y/o female. Medial ankle mass status post injury 1 year ago causing pain and numbness.





17 year old man with bilateral ankle pain



Middle subtalar coalition (MSC)

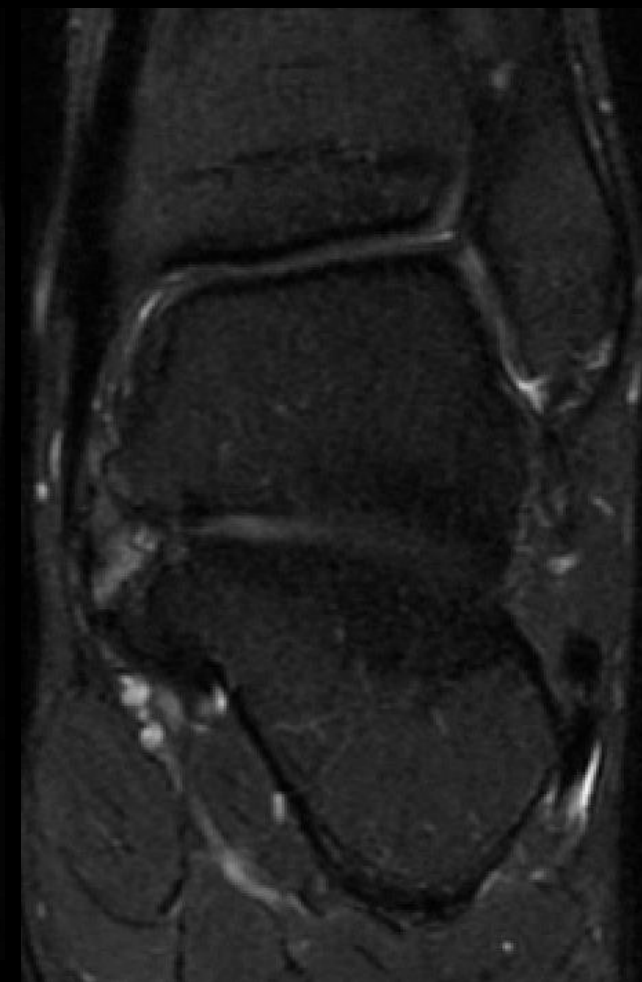
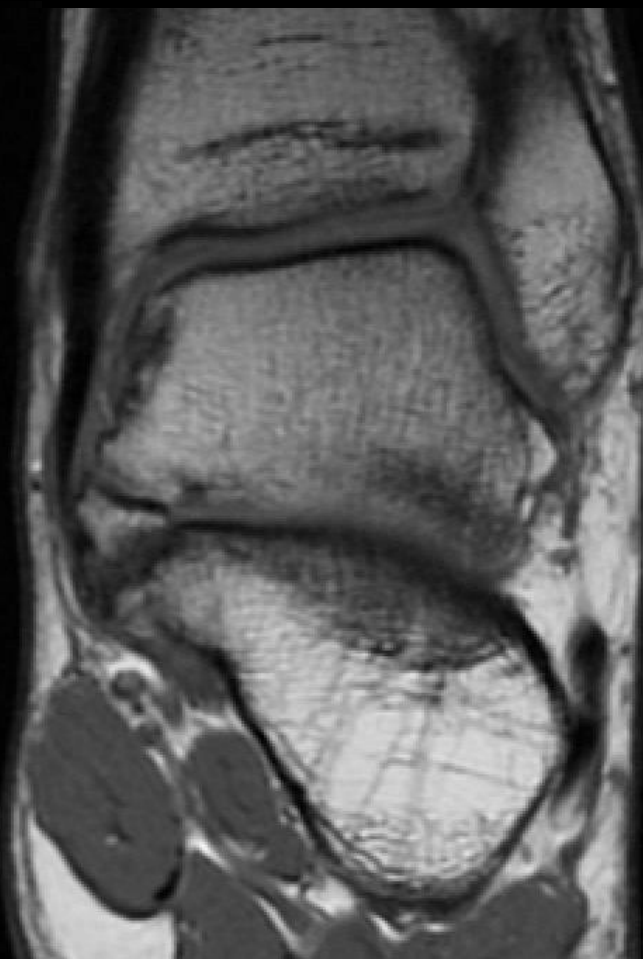
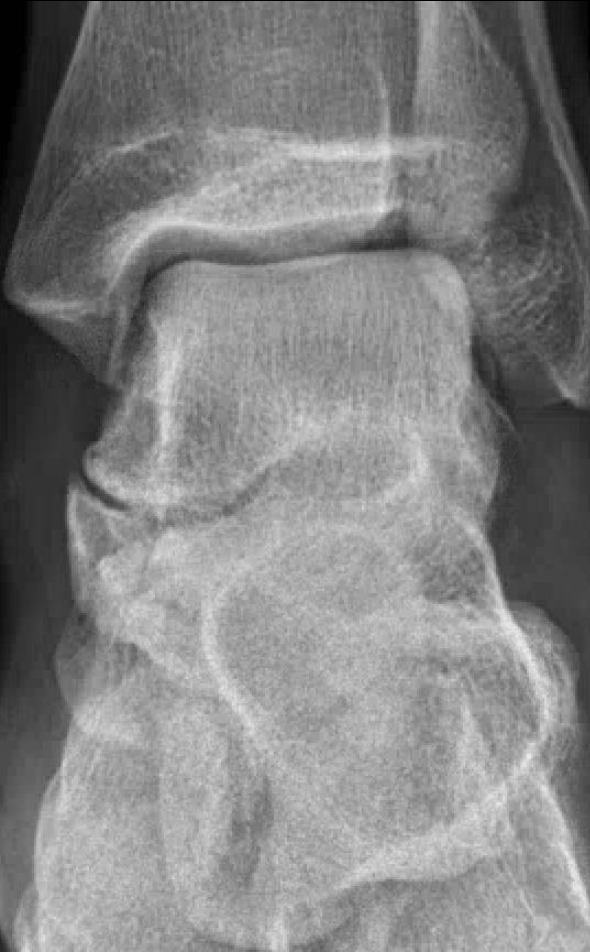Middle subtalar coalition + PMEAC

The Talus: Congenital Anomalies

- Os sustentaculum:
 - First described by Pfitzner in 1896
 - Small accessory bone lodged at the medial and posterosuperior aspects of the sustentaculum tali inferomedial aspect of the medial talar tubercle
 - Rare: 0.3–0.4%
 - Component of a type of extraarticular talocalcaneal coalition

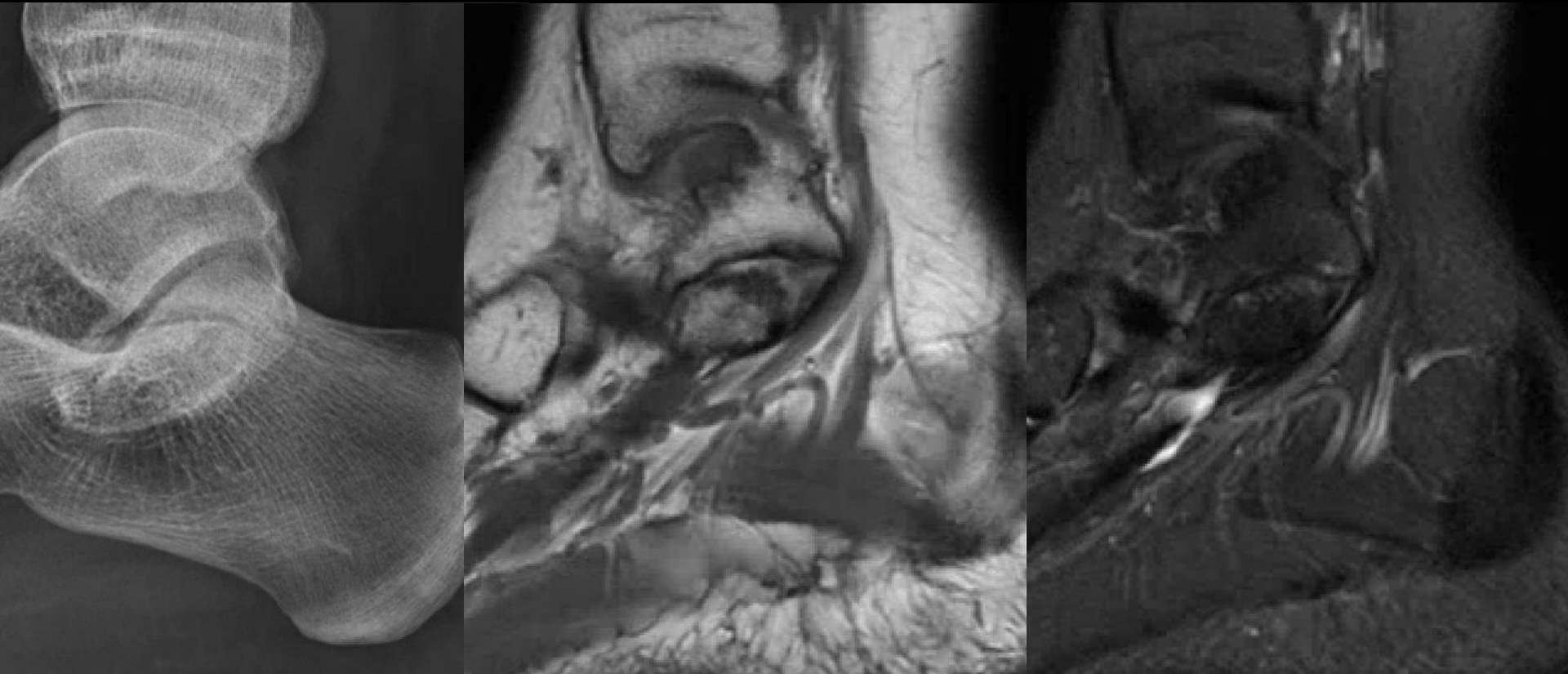
Os sustentaculum

30 year old male. Left ankle pain. Multiple sprains previously.
Painful medial, lateral talus, and anterior process of the calcaneus.



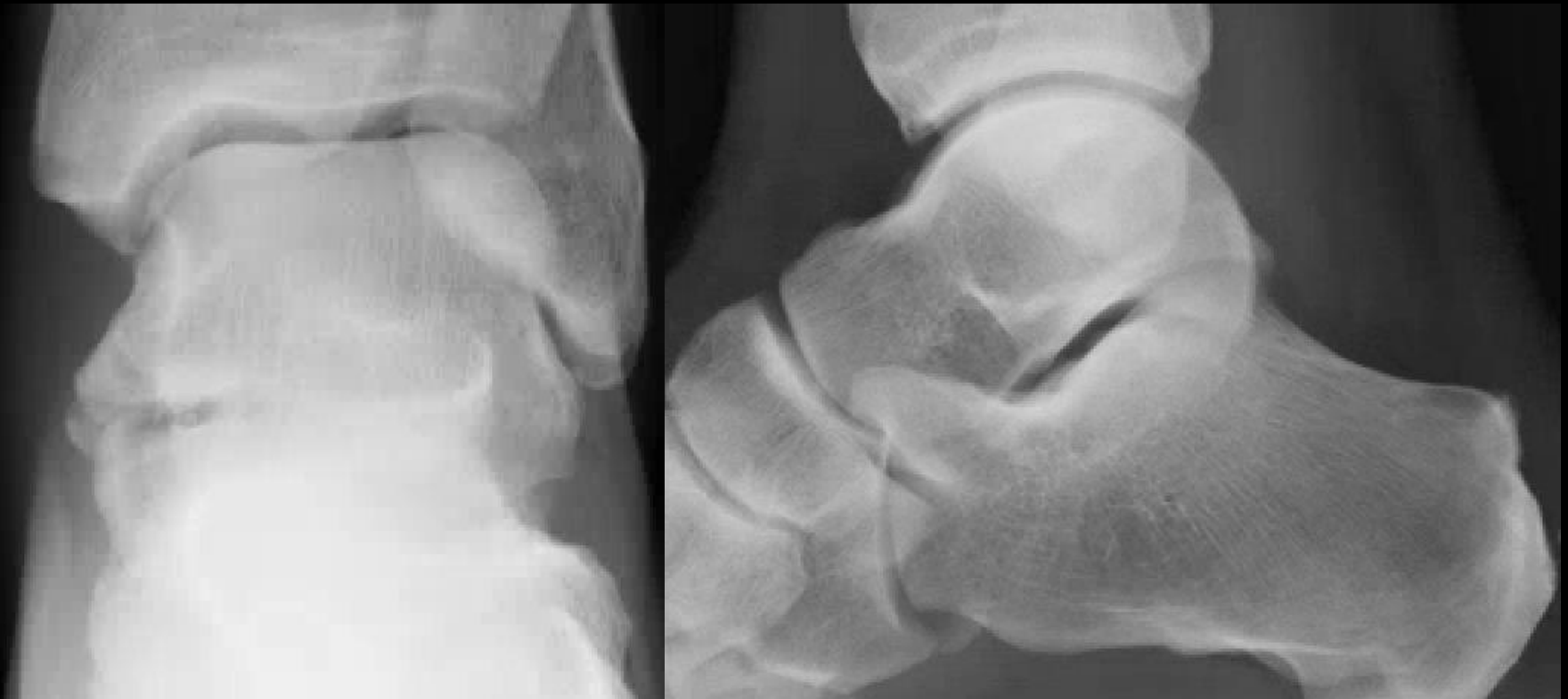Os sustentaculum

30 year old male. Left ankle pain. Multiple sprains previously.
Painful medial, lateral talus, and anterior process of the calcaneus.



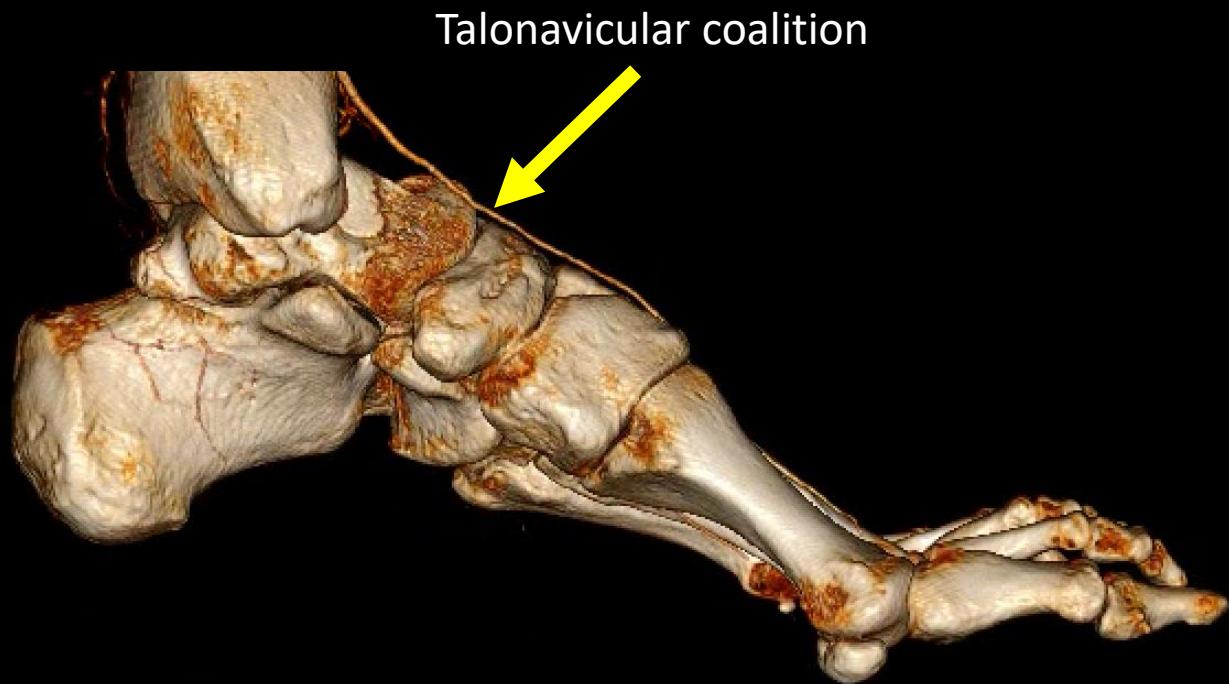
Os sustentaculum

68 year old male. Recent fleck from France. Left leg pain since then.



The Talus: Congenital Anomalies

- Talus Coalition:

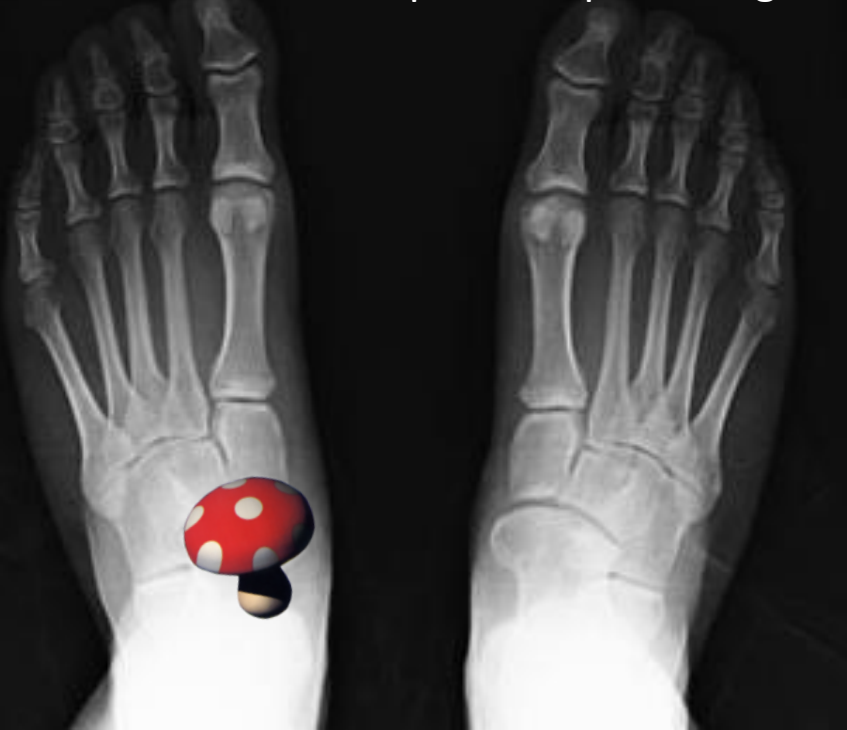

The Talus: Congenital Anomalies

- Talonavicular coalition:
 - Rare
 - Uni or bilateral
 - Associations:
 - Symphalangism
 - Clinodactyly
 - Great toe that is shorter than the second toe
 - Pes cavus
 - Calcaneonavicular coalition
 - Talocalcaneal coalition
 - Mushroom sign (AP)
 - Loss of the talar-scaphoid joint line at the level of Chopart's joint (Lateral)

Talonavicular coalition

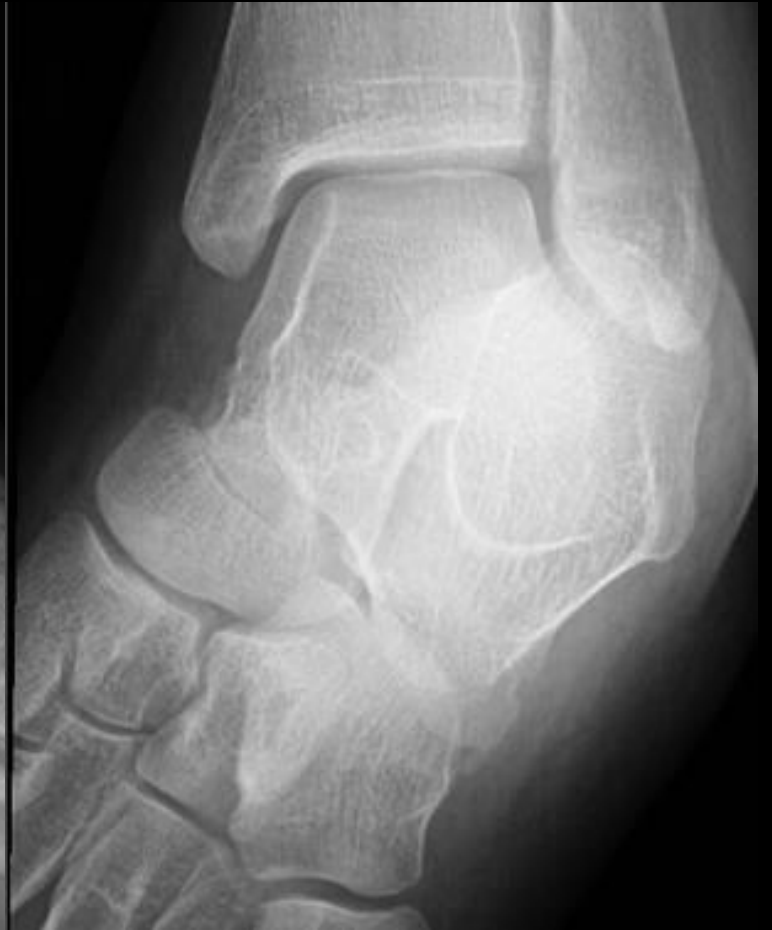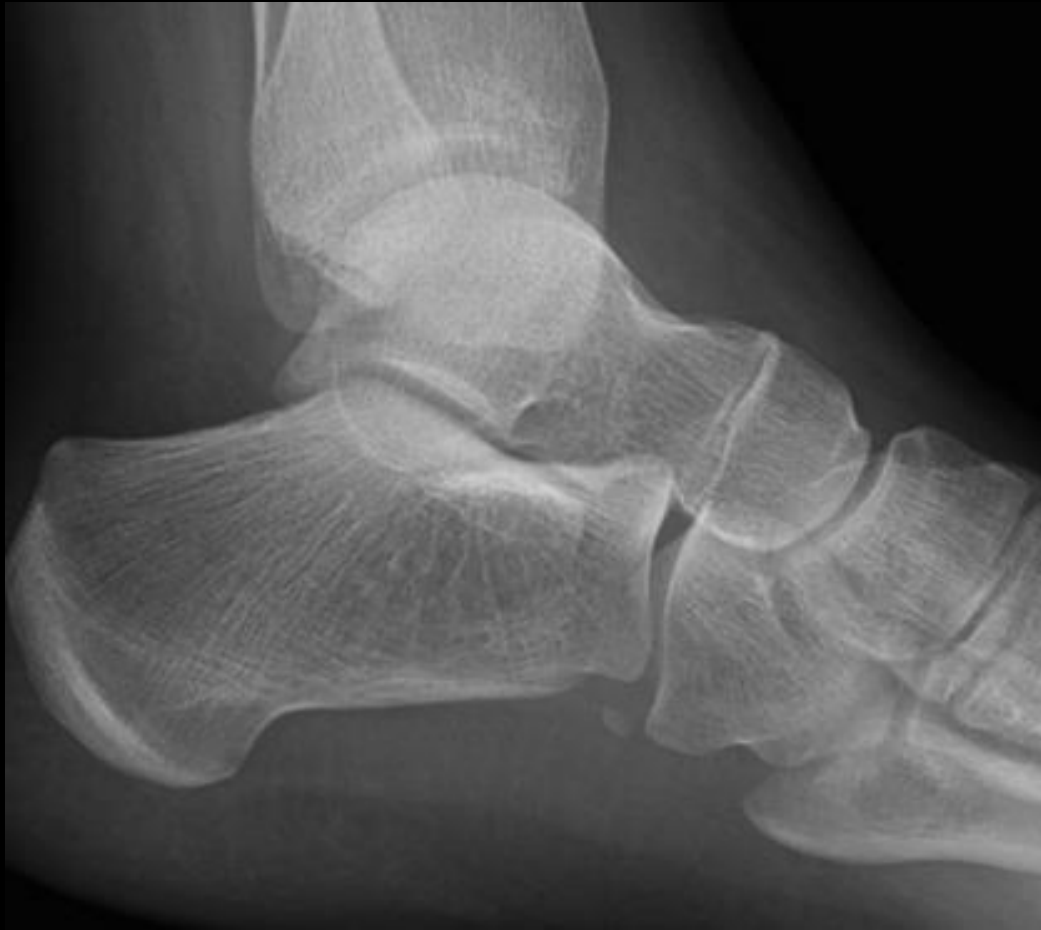35-year-old male. Bilateral ankle pain. No preceding accident or injury.



Talonavicular Coalition Macera et al. 2017

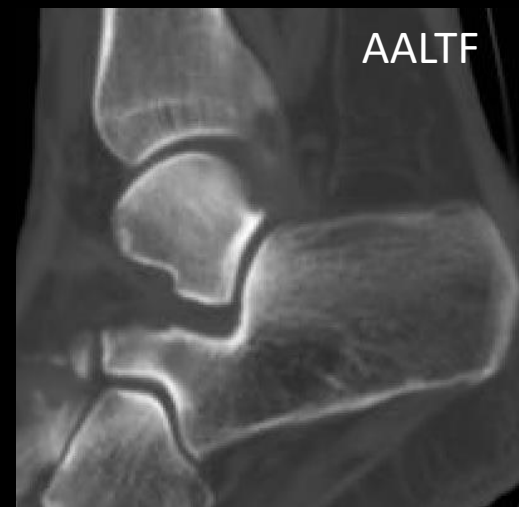
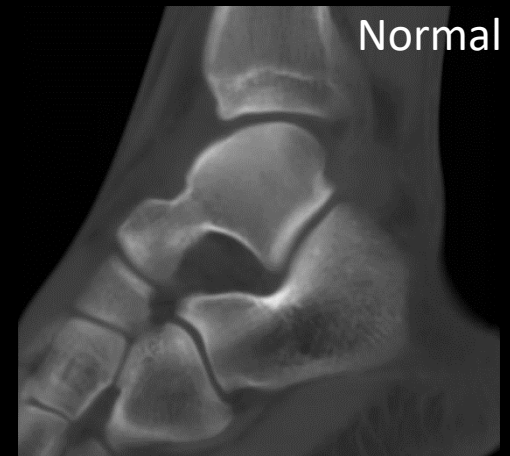
Talonavicular coalition



The Talus: Congenital Anomalies

- Accessory Anterolateral Talar Facet
 - First described by Sewell in 1904
 - Previously known as “**facies externa accessoria corporis tali**”
 - Squaring or broadening of the apex of the lateral aspect of the talus

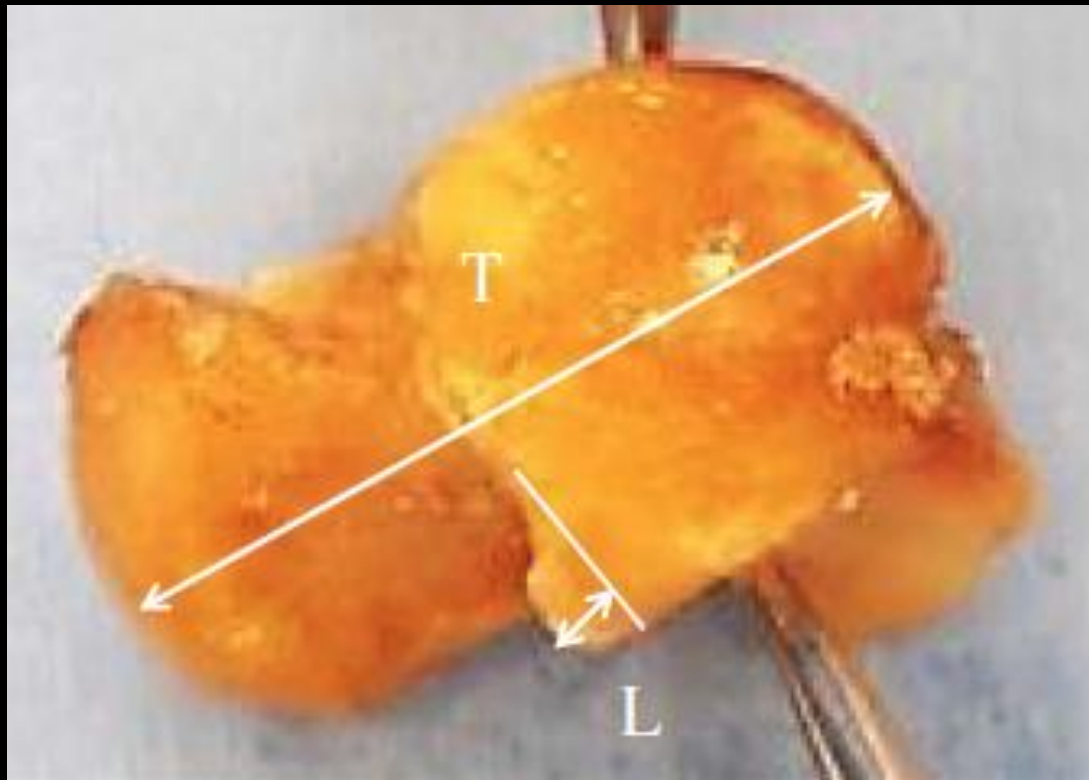


The Talus: Congenital Anomalies

- Accessory Anterolateral Talar Facet
 - One of the causes of a **painful rigid flat foot**
 - Other more recognized and established causes of flat foot:
 - Tarsal coalition
 - Hindfoot valgus
 - Infectious
 - Inflammatory
 - Degenerative arthritides
 - Neoplastic or neurologic processes
 - Osteochondral fractures

The Talus: Congenital Anomalies

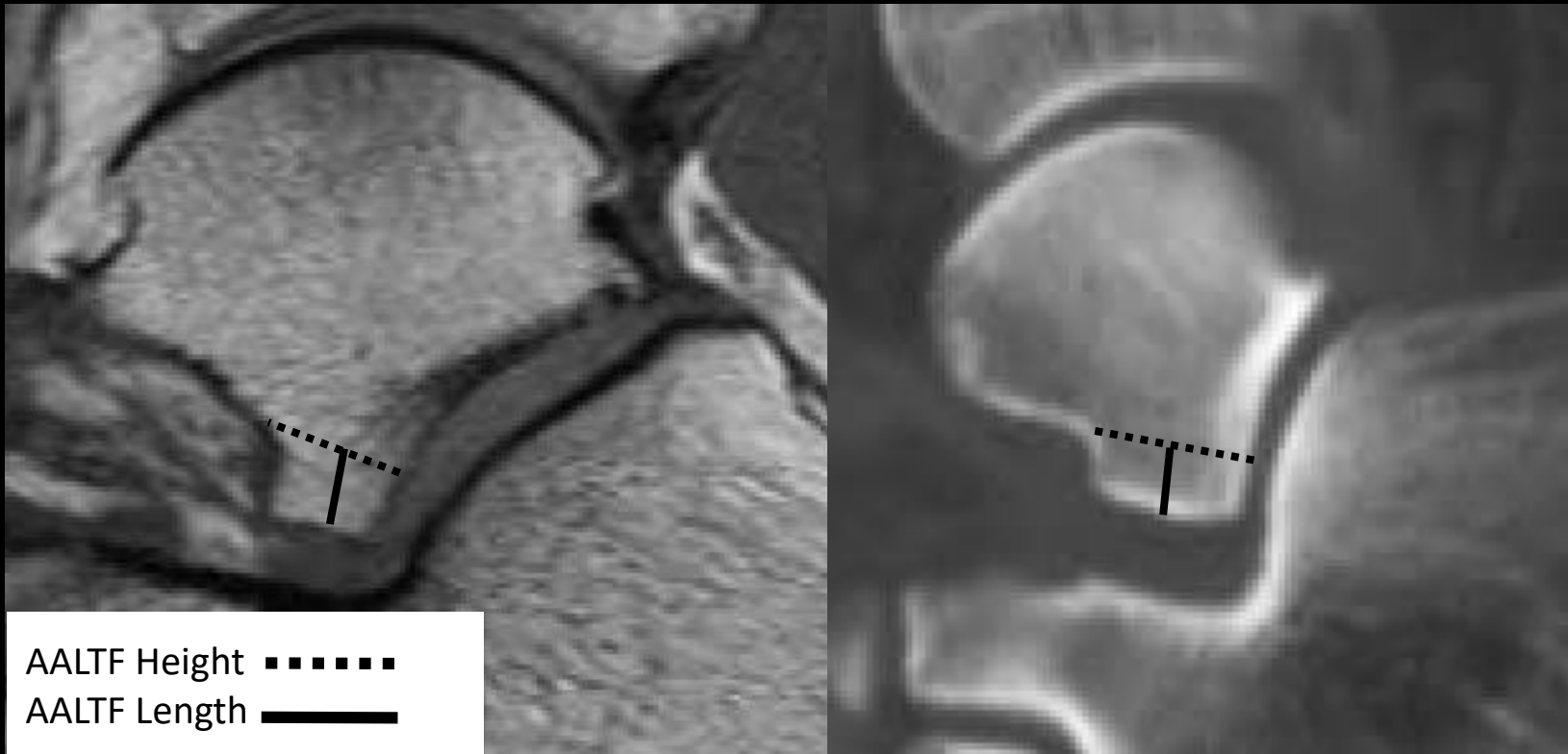
- Accessory Anterolateral Talar Facet



Hirano T, Niki H, Akiyama Y, Beppu M. Anatomical characteristics of the accessory antero-lateral talar facet. *J Orthop Sci.* 2015; 20(1):124-128.

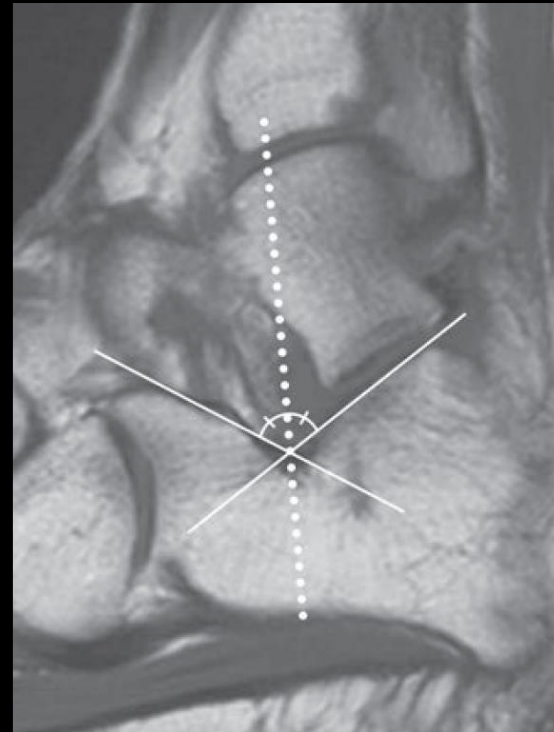
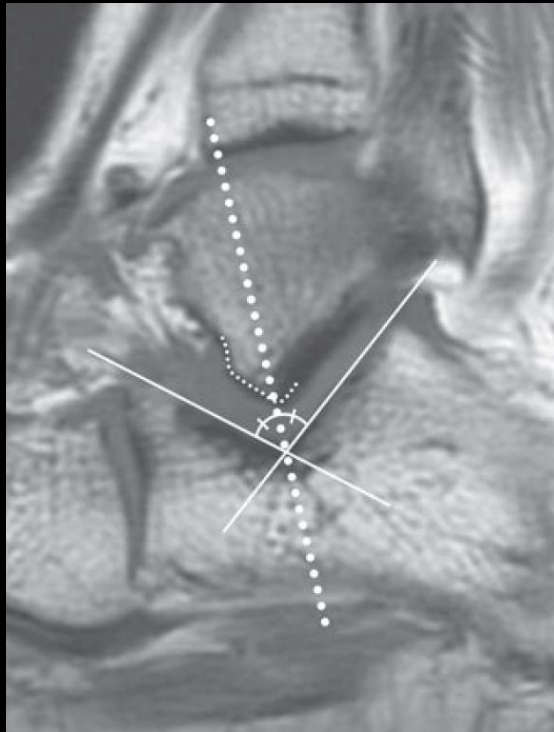
The Talus: Congenital Anomalies

- Accessory Anterolateral Talar Facet

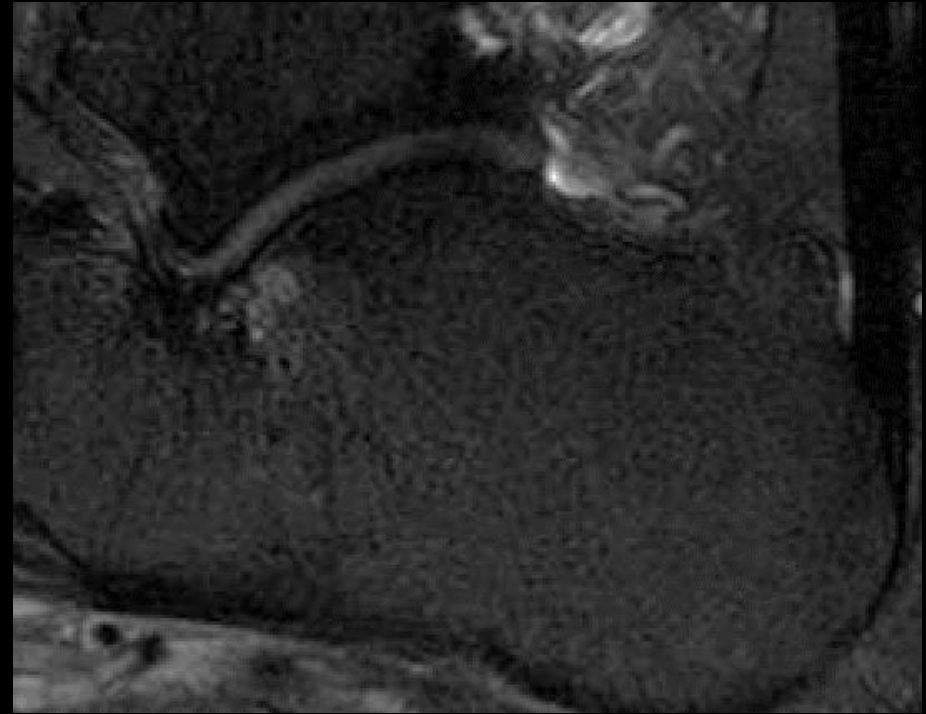
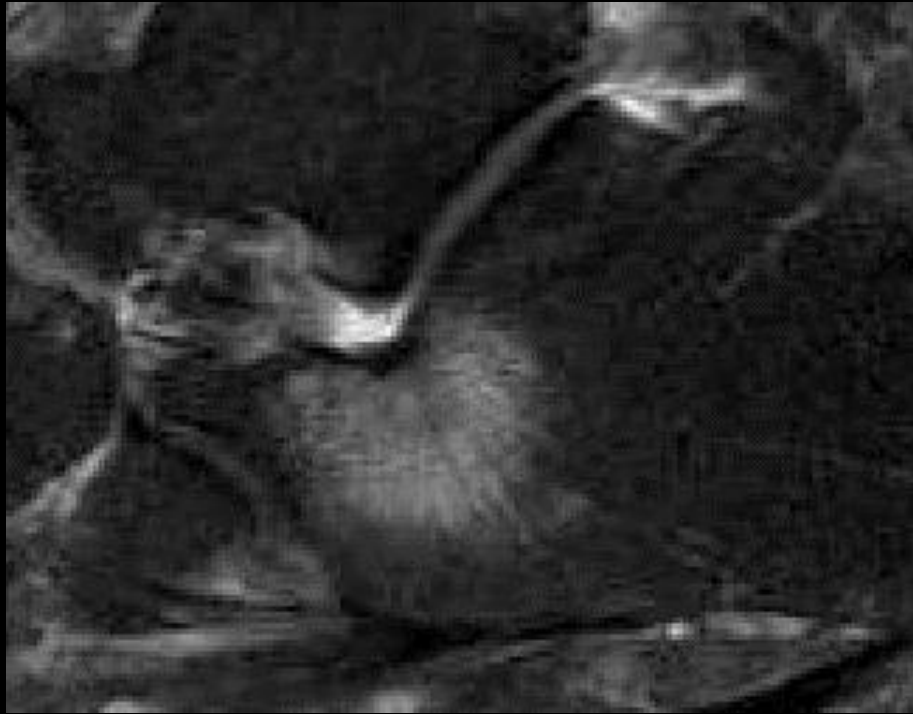


The Talus: Congenital Anomalies

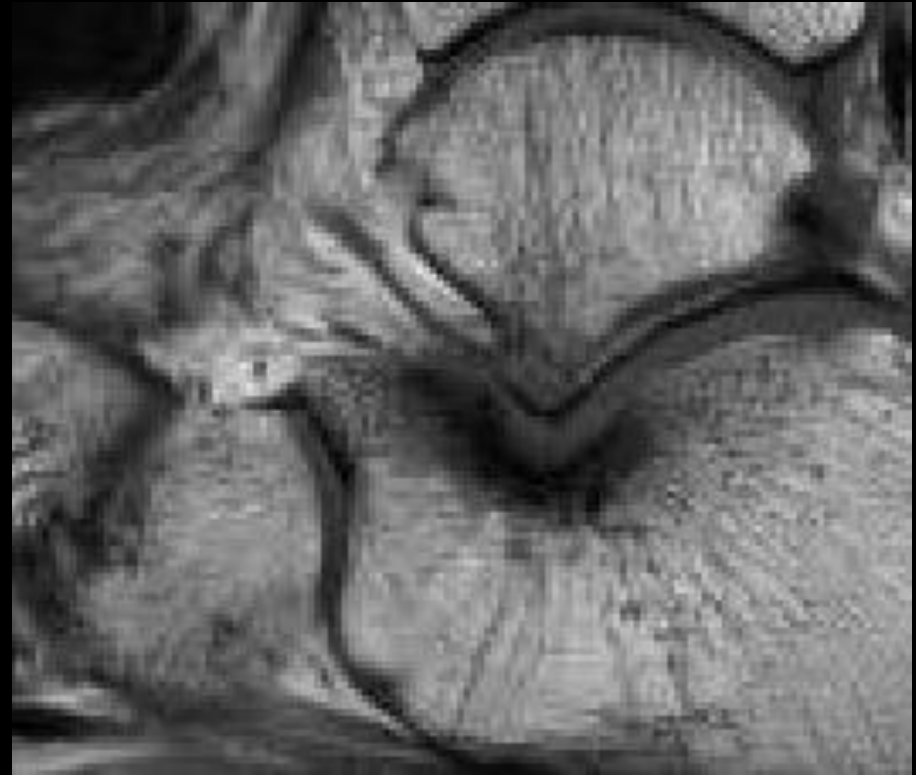
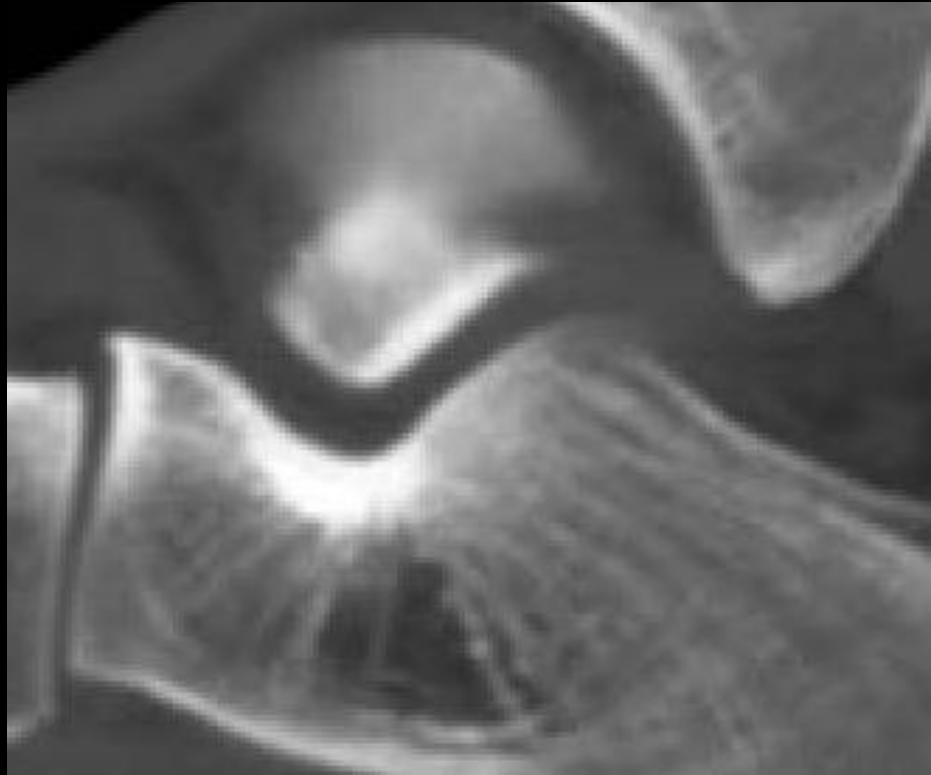
- Accessory Anterolateral Talar Facet



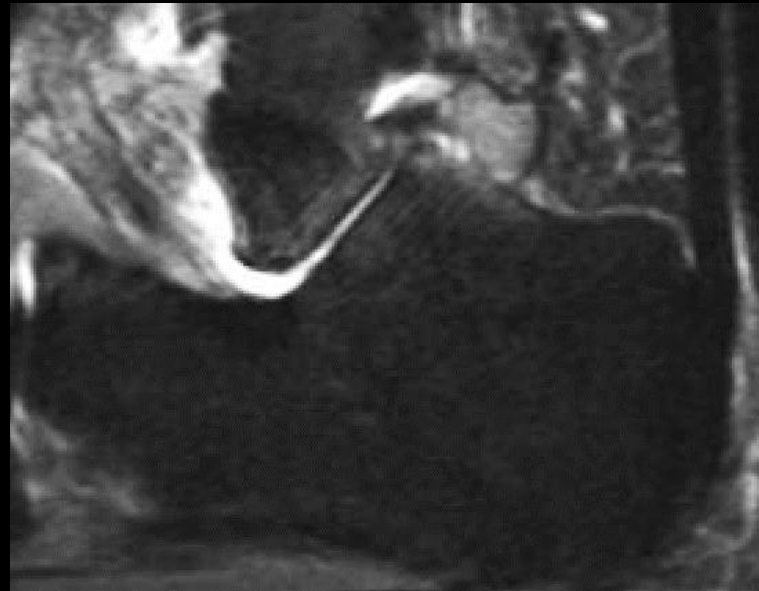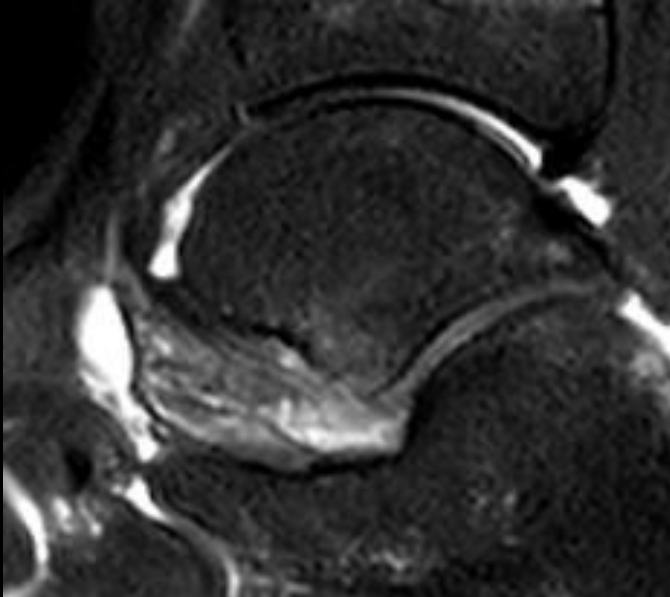
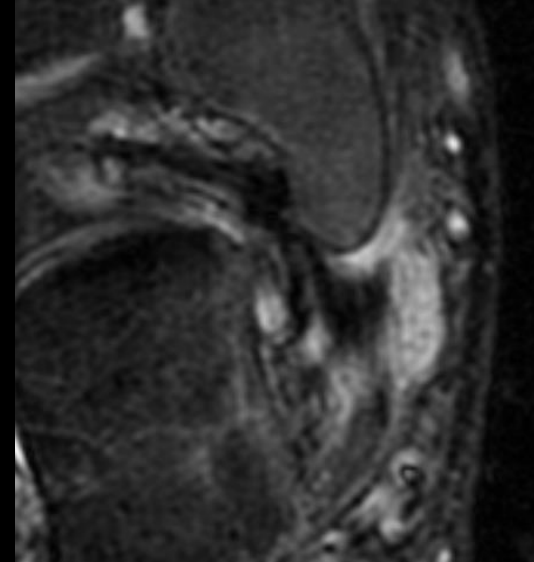
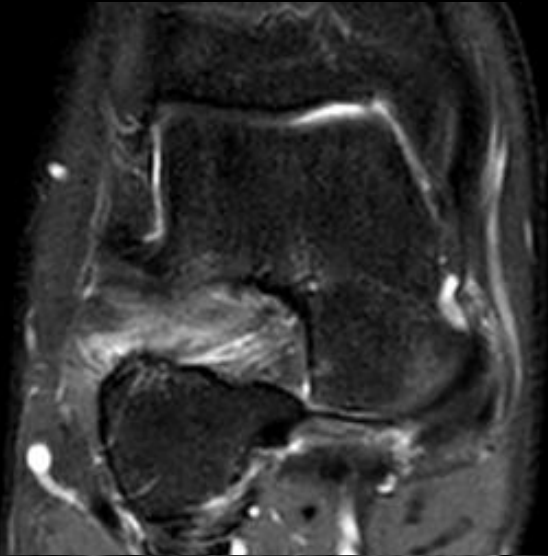
AALTF Osseous Findings



AALTF Osseous Findings



AALTF Soft Tissues Findings




The Talus: Congenital Anomalies

- Accessory Anterolateral Talar Facet:
 - Prevalence initially reported by Sewell: only 10.2%
 - MR imaging prevalence of the AALTF:
 - 32.7% of symptomatic patients
 - 26.0% of asymptomatic volunteers
 - Two cadaveric studies by Martus et al. and Sarrafian in which an AALTF was seen in 34% of specimens in both studies

The Talus: Congenital Anomalies

- Alqahtani et al, reported AALTF in **31.55%** of 187 patients with sinus tarsi syndrome and/or tarsal coalition



The Talus: Congenital Anomalies

Table 1 Demographics and Imaging Characteristics of AALTF

	Total n (%)	AALTF	
		n (%)	P-value
Total	187 (100.00)	59 (31.55)	
Male	88 (47.10)	36 (40.91)	
Female	99 (52.90)	23 (23.23)	
Side			
Right	95 (50.80)	31 (32.63)	>0.1
Left	92 (49.20)	28 (30.43)	>0.1
Modality			
MRI +/- CT	165 (88.24)	52 (31.15)	
CT only	22 (11.76)	7(31.82)	
Osseous changes			
Calcaneal bone marrow edema*	45(27.27)	36 (80.00)	<0.001
Talar bone marrow edema*	39 (23.64)	35 (89.74)	<0.001
Cortical thickening	36 (19.25)	34 (94.44)	<0.001
Cystic changes	35 (18.72)	24 (68.57)	<0.001
Subfibular soft tissue edema*	37 (22.42)	29 (78.38)	<0.001
Sinus tarsi edema*	117 (70.91)	45 (38.46)	0.014

*Bone marrow and soft tissue edema was only evaluated on 165 patients who had MR imaging.

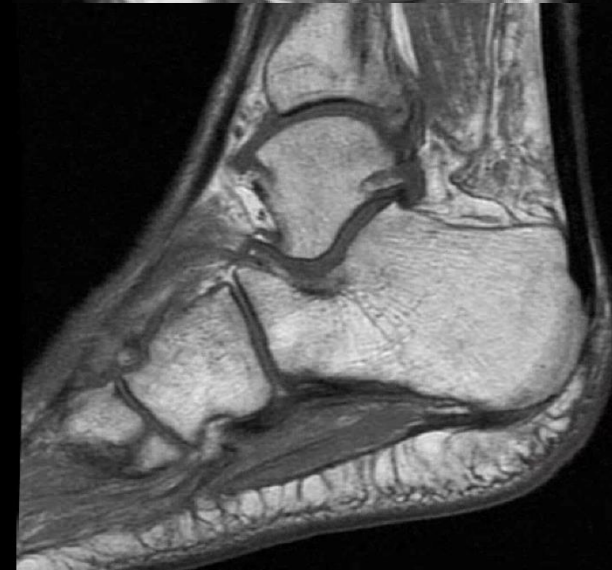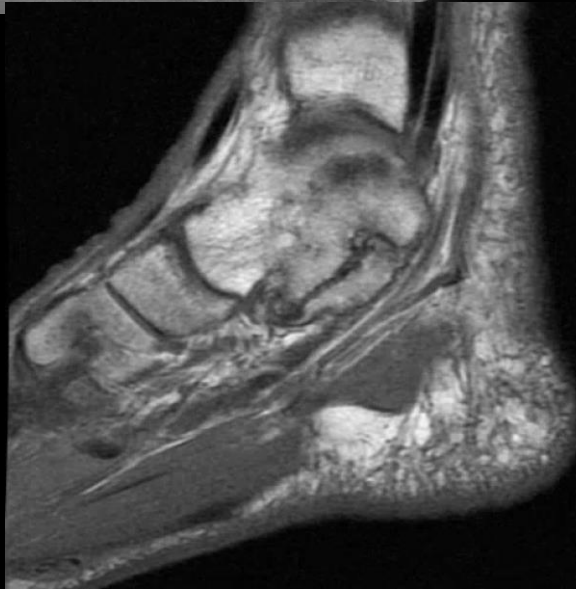
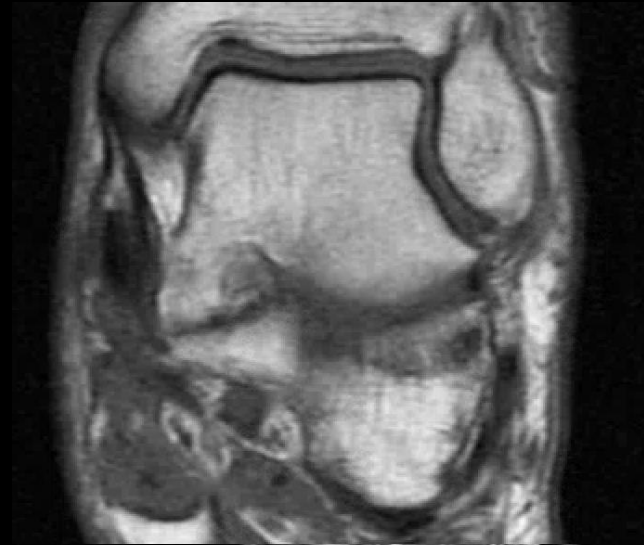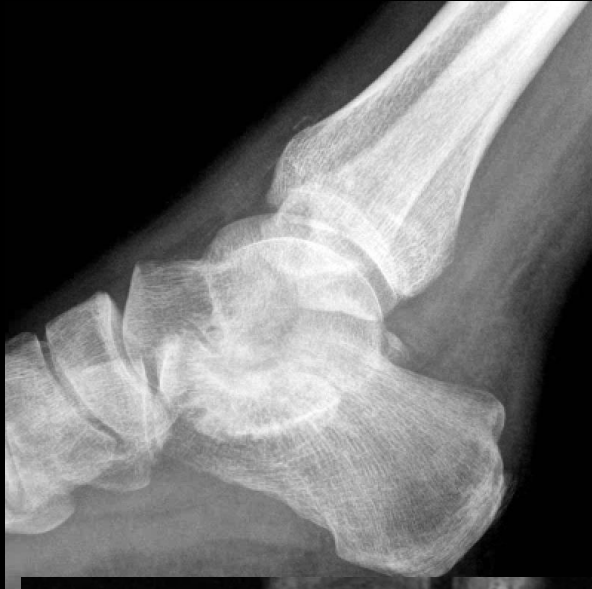The Talus: Congenital Anomalies

Table 2 Frequency of Coalition and AALTF

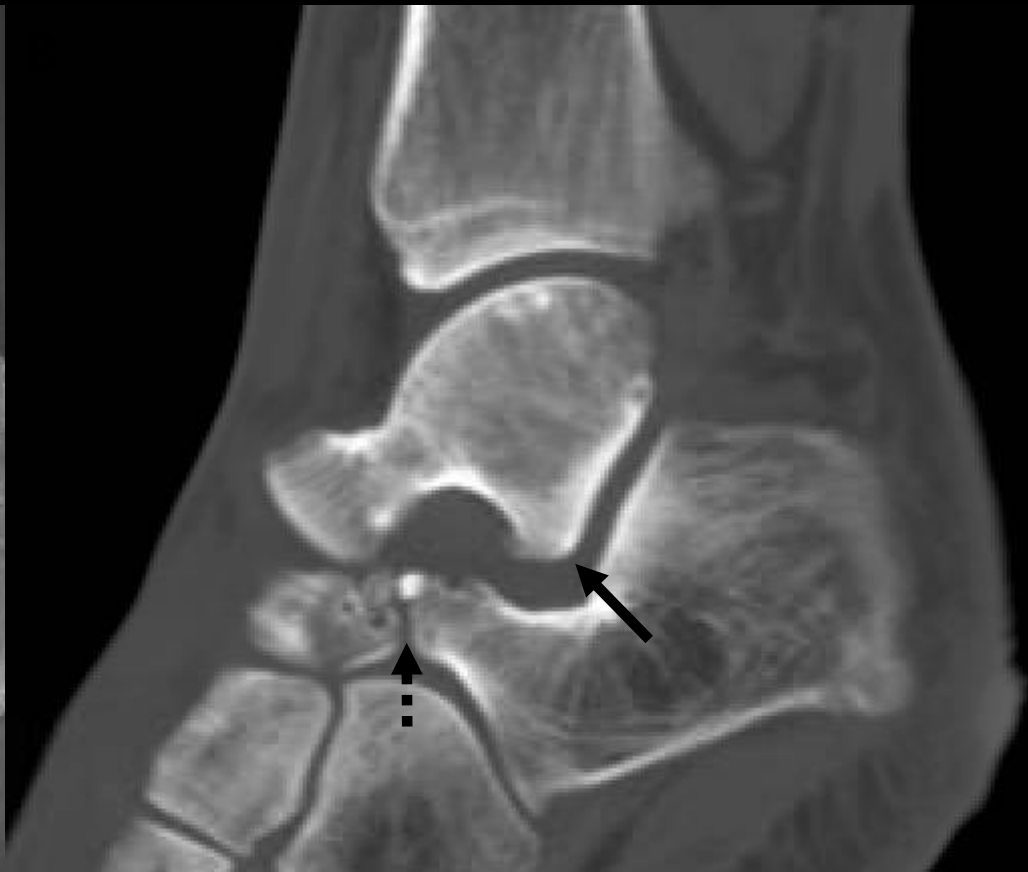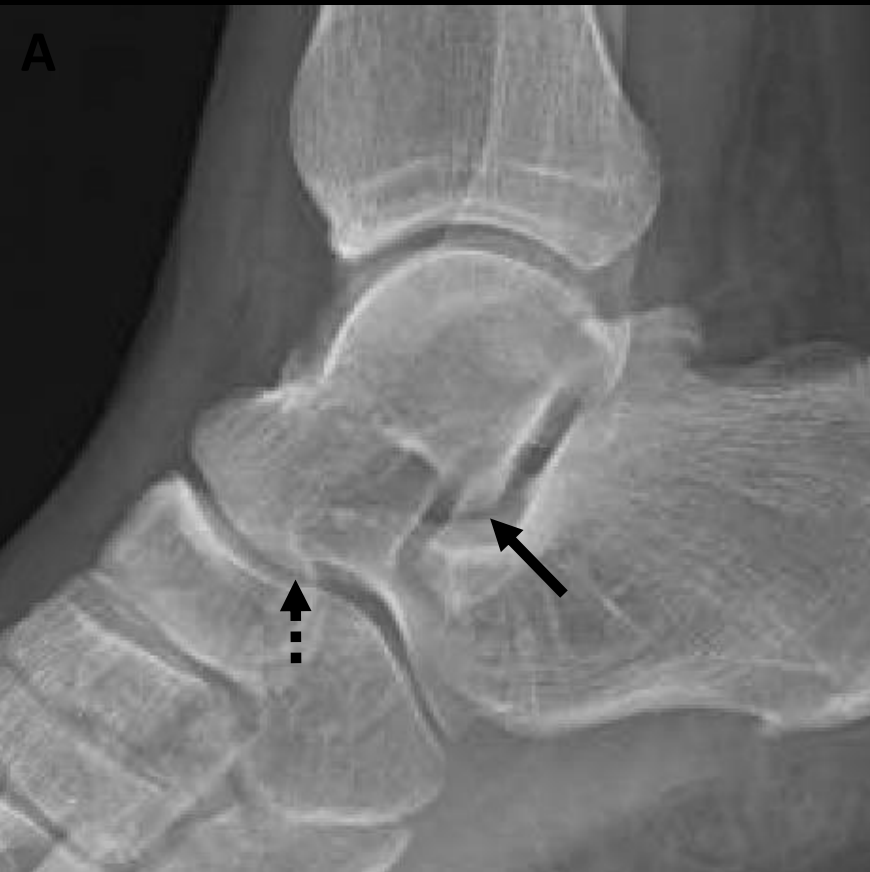Tarsal coalition	Total n (%)	AALTF	
		n (%)	P-value
Any coalition	70 (37.43%)	31 (44.29%)	0.005
CNC	37 (19.79%)	11 (29.73%)	0.478
MFTCC	9 (4.81%)	7 (77.78%)	0.005
PFTCC	5 (2.67%)	1 (20.00%)	>0.1
EATCC	25 (13.37%)	19 (76.00%)	<0.001
Other	6 (3.21%)	1 (16.67%)	0.901

* CNC= Calcaneonavicular coalition, MFTCC= Middle facet talocalcaneal coalition, PFTCC= Posterior facet talocalcaneal coalition, EATCC= Extra-articular talocalcaneal coalition

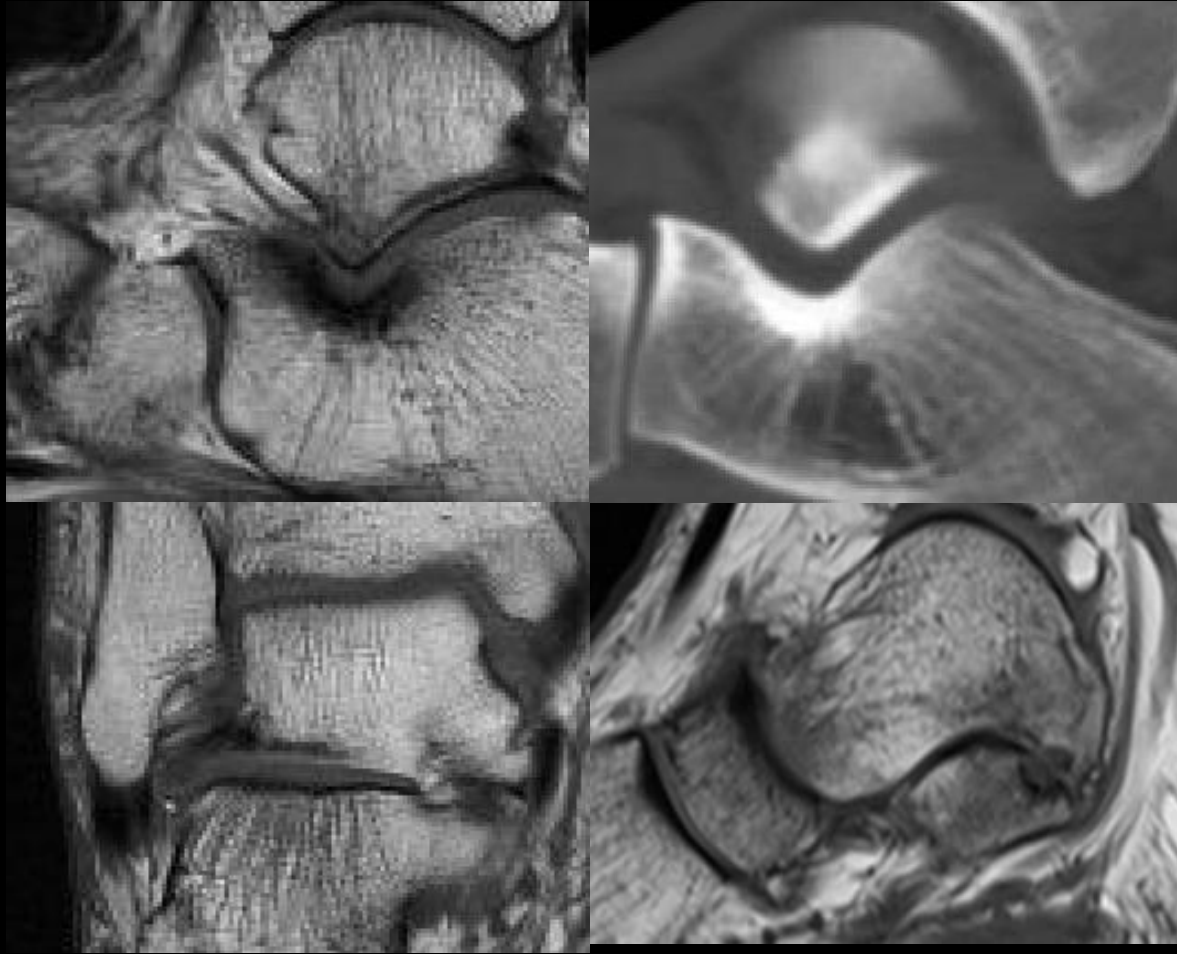
Accessory Anterolateral Talar Facet



Accessory Anterolateral Talar Facet



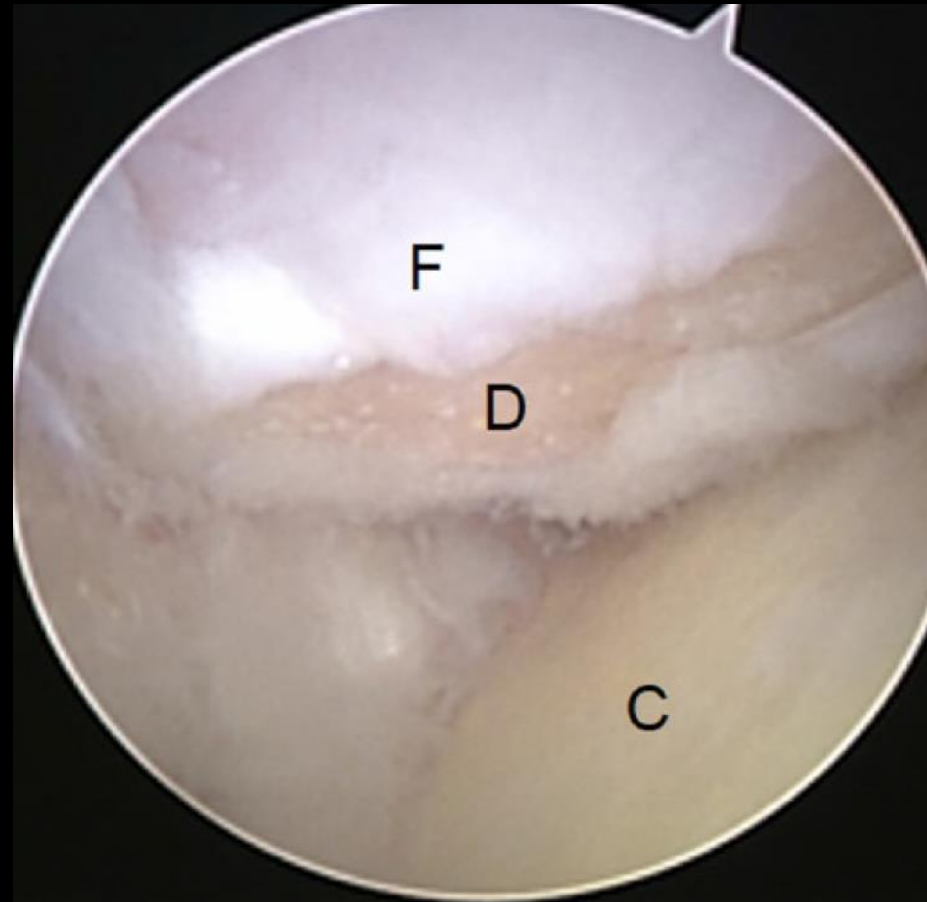
Accessory Anterolateral Talar Facet



Accessory Talar Facet Impingement in Pathologic Conditions of the Peritalar Region in Adults

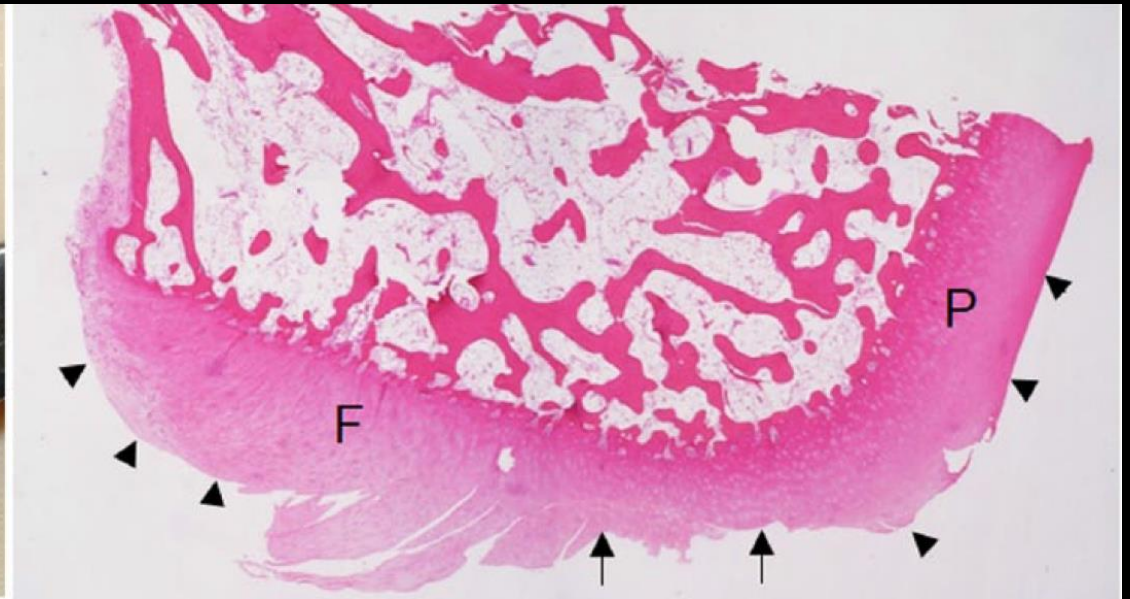
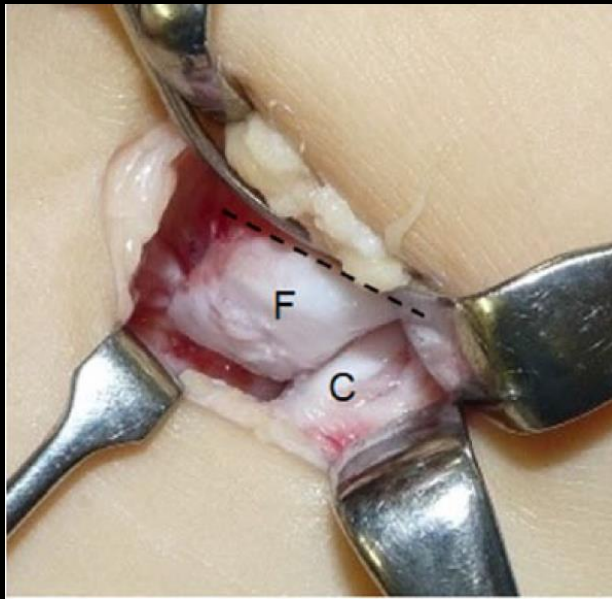
Hisateru Niki, MD, PhD¹, Takaaki Hirano, MD, PhD¹, Yui Akiyama, MD, PhD¹, and Moroe Beppu, MD, PhD¹

- 31 patients (aged 19-75 years) with persistent sinus tarsi pain
- Subjects **underwent accessory facet resection with balancing reconstruction**
- Arthroscopically,
 - 66% focal defect on the AALTF cartilage surface
 - 83% attenuation of the posterior capsular ligament



Accessory Talar Facet Impingement in Pathologic Conditions of the Peritalar Region in Adults

Hisateru Niki, MD, PhD¹, Takaaki Hirano, MD, PhD¹,
Yui Akiyama, MD, PhD¹, and Moroe Beppu, MD, PhD¹



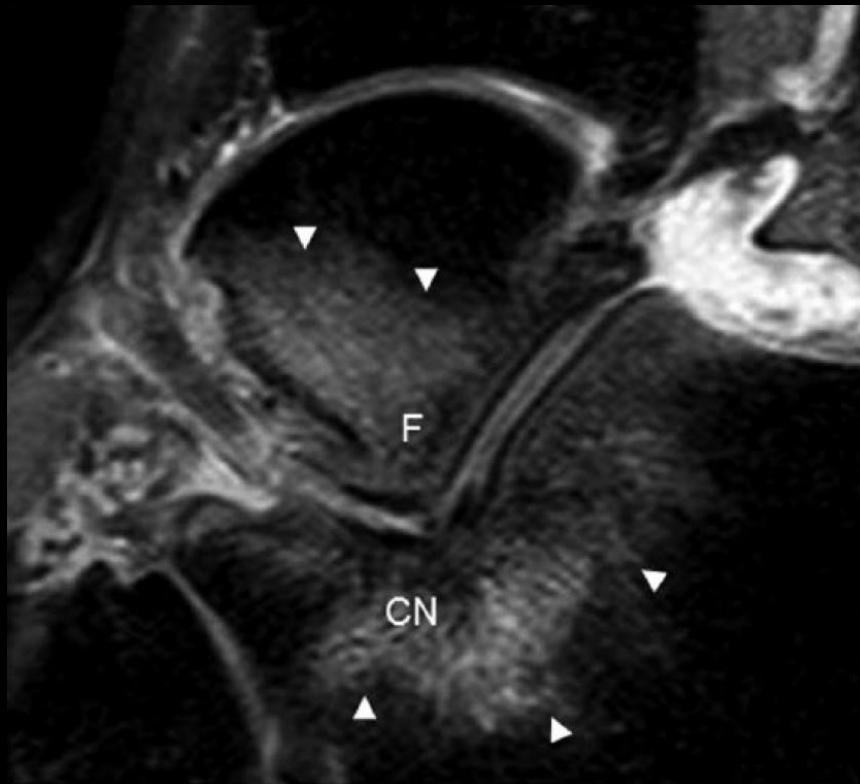
Accessory Talar Facet Impingement in Pathologic Conditions of the Peritalar Region in Adults

Hisateru Niki, MD, PhD¹, Takaaki Hirano, MD, PhD¹,
Yui Akiyama, MD, PhD¹, and Moroe Beppu, MD, PhD¹

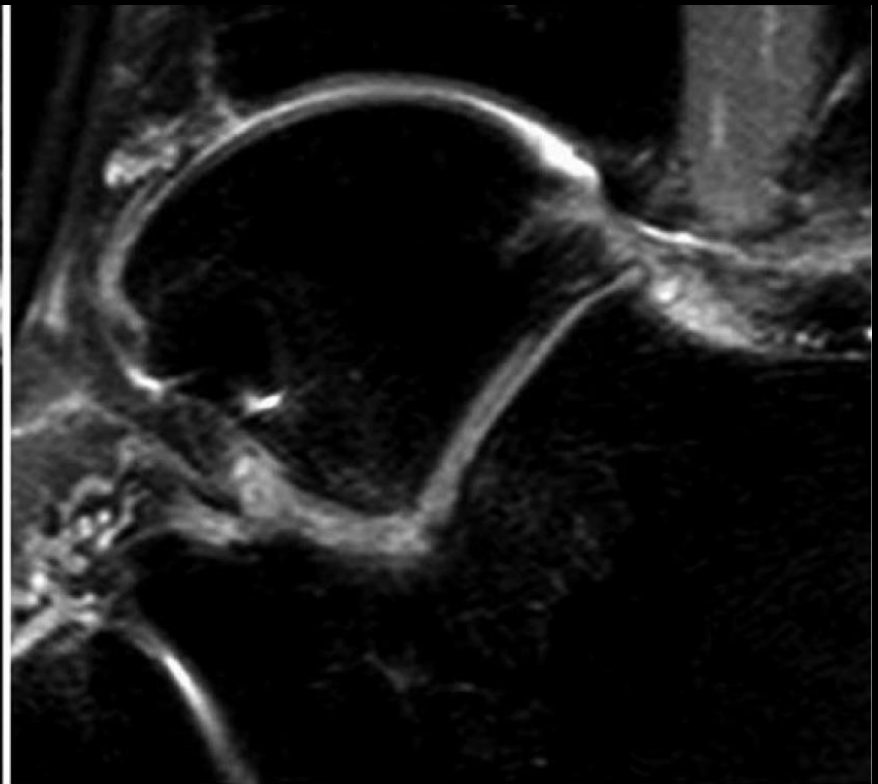
- All x-ray parameters showed significant improvement postoperatively ($P < .001$)
- Mean objective scores improved from 54.0 preoperatively to 91.0 postoperatively ($P < .001$)
- Sinus tarsi pain and FABME were absent in all cases at the final follow-up

Accessory Talar Facet Impingement in Pathologic Conditions of the Peritalar Region in Adults

Hisateru Niki, MD, PhD¹, Takaaki Hirano, MD, PhD¹,
Yui Akiyama, MD, PhD¹, and Moroe Beppu, MD, PhD¹

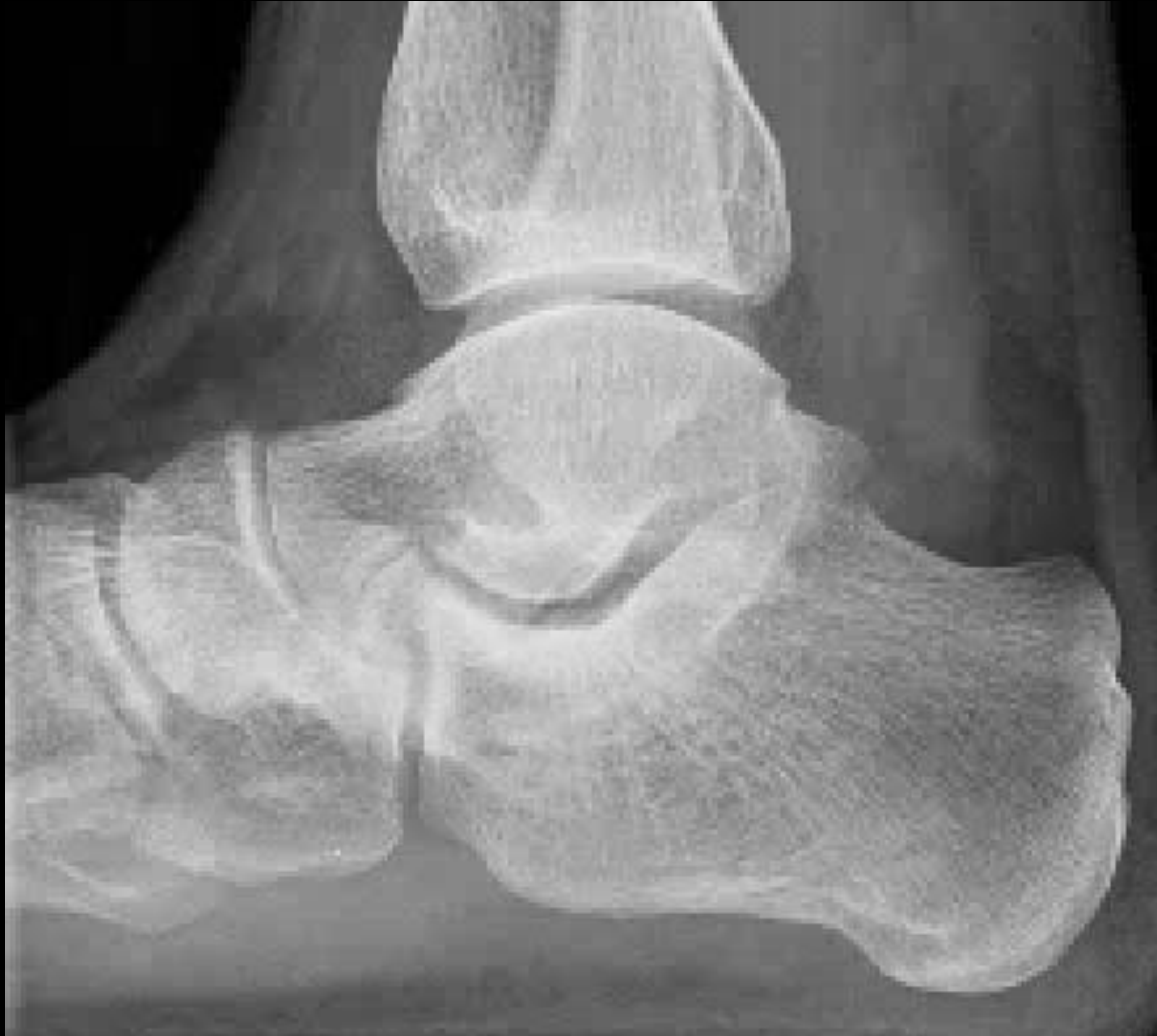

A. Preoperative

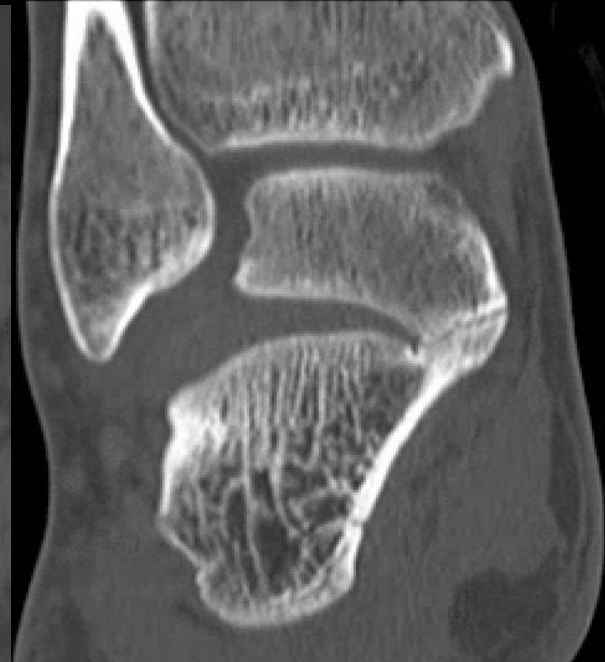
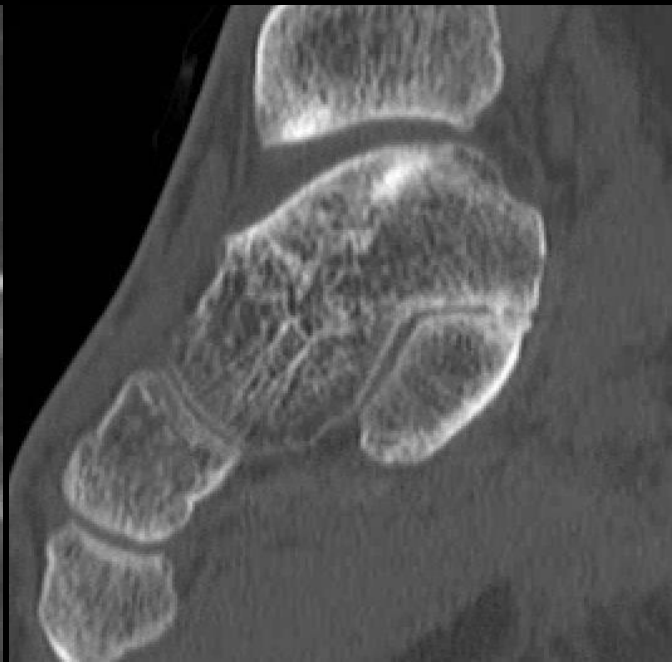
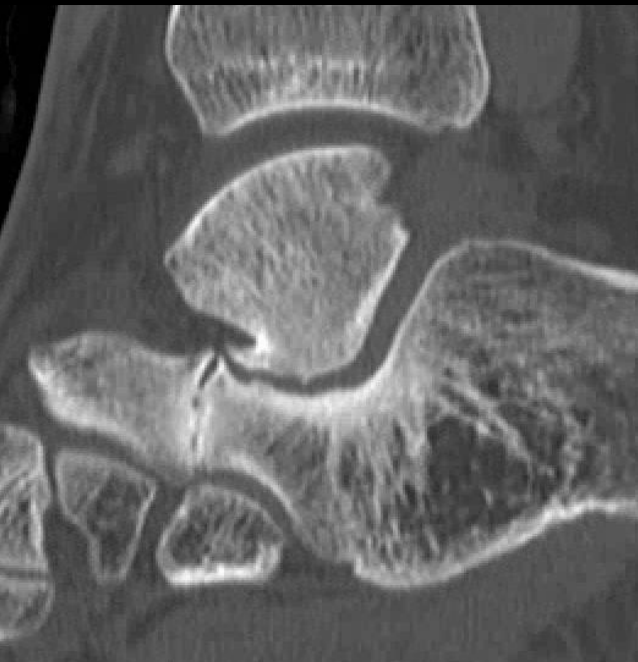

B. Postoperative

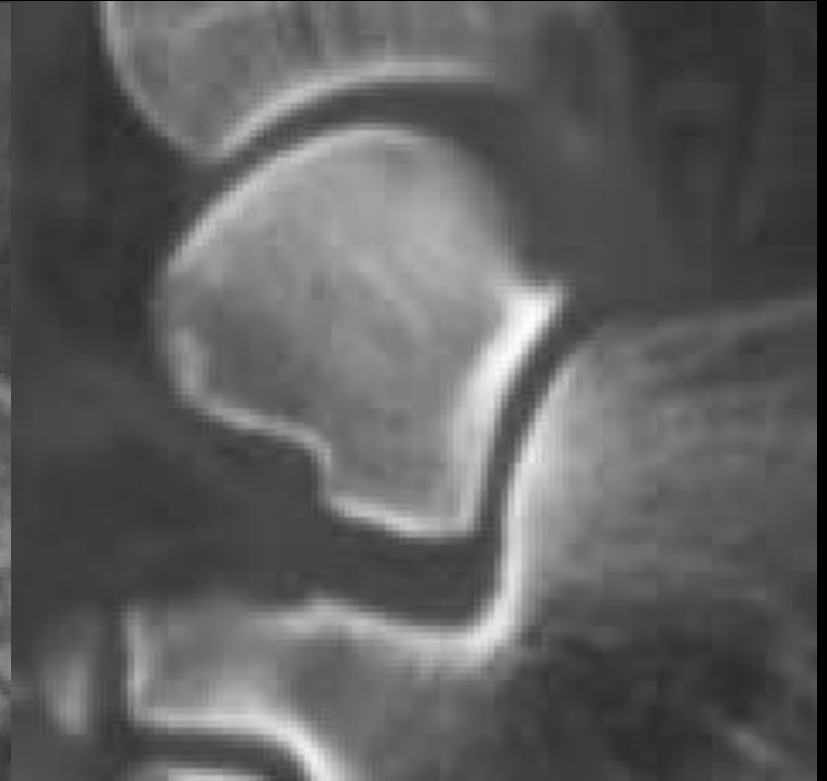
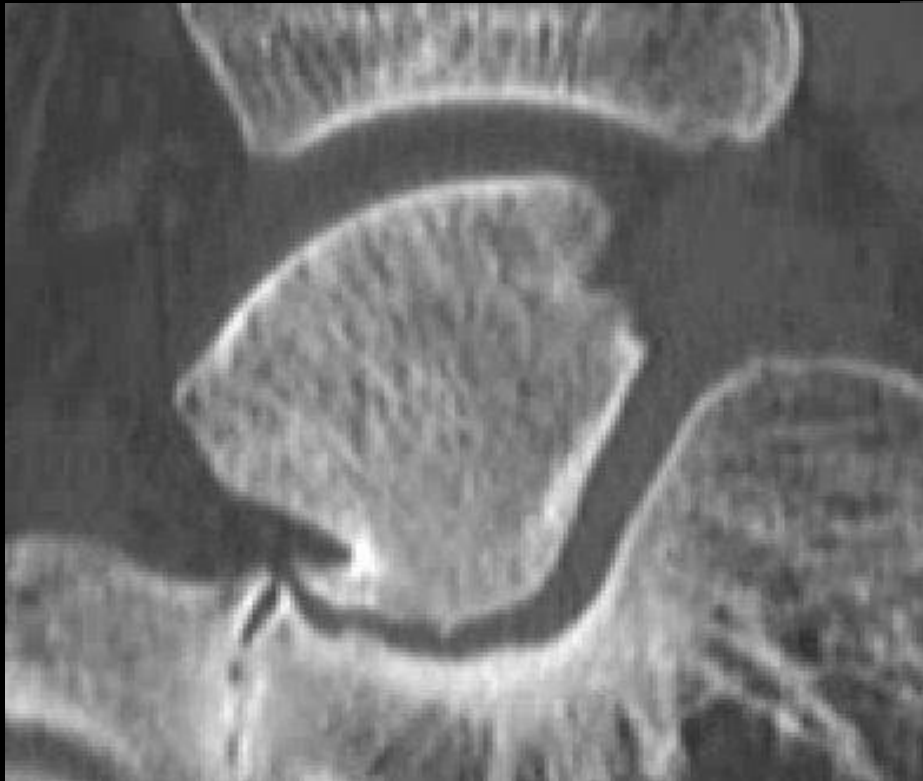32 year old male. Ankle pain



32 year old male. Ankle pain

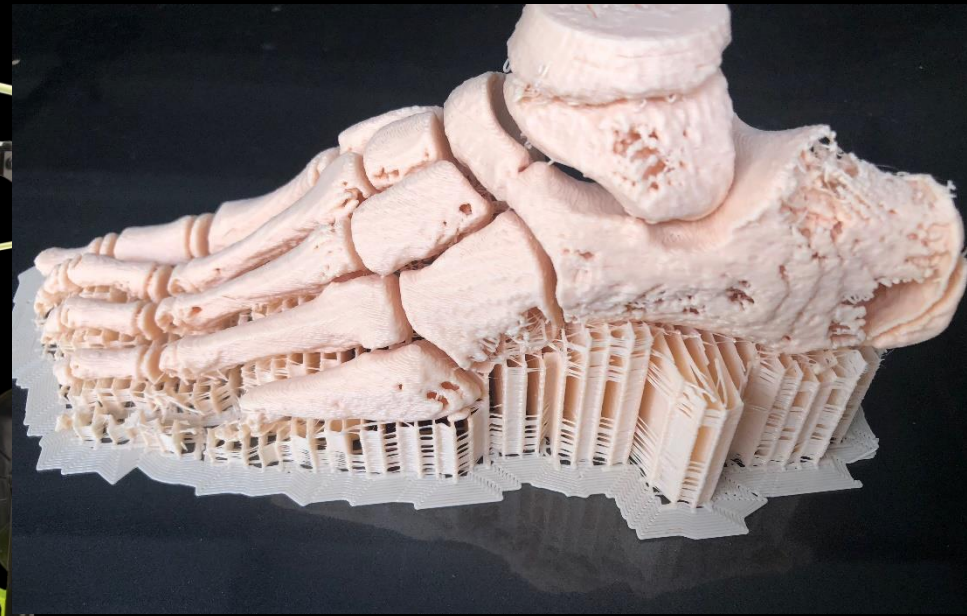


AALTF Acquired vs Congenital

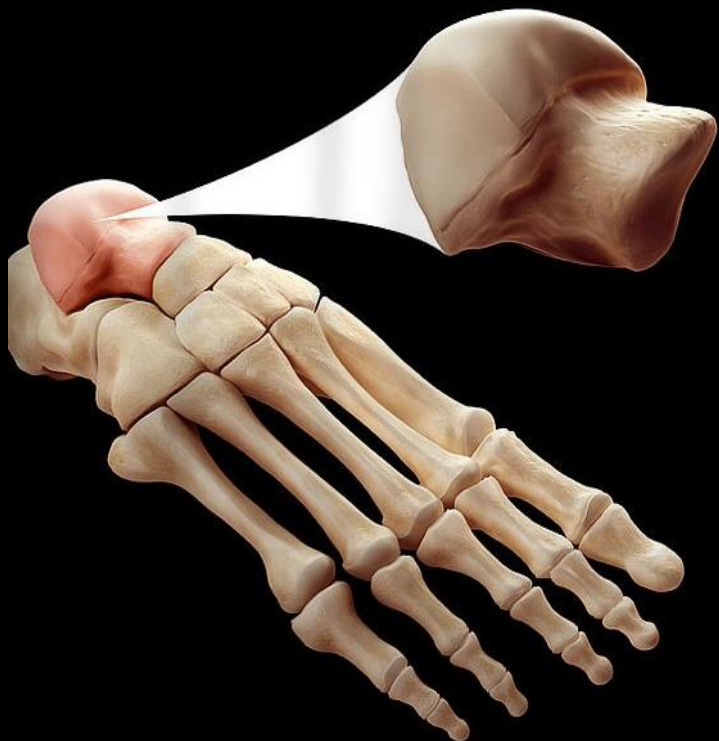


The Talus

- Rady Children's Hospital 3D Printing Lab



Special thanks to:
Dr. John Naheedy
Dr. Jerry Dewek
Dr. Daniel Vincour



Anatomy

Congenital

Fractures

The Talus: Fractures

- Talar fractures represent less than 1% of all fractures in the human body
- 3% and 6% of fractures in the foot
- High-energy trauma
 - Talar head (5%), neck (50%), and body (23%) fractures
 - Posterior process fracture
 - Lateral process fracture
 - Talar dome injuries

The Talus: Fractures

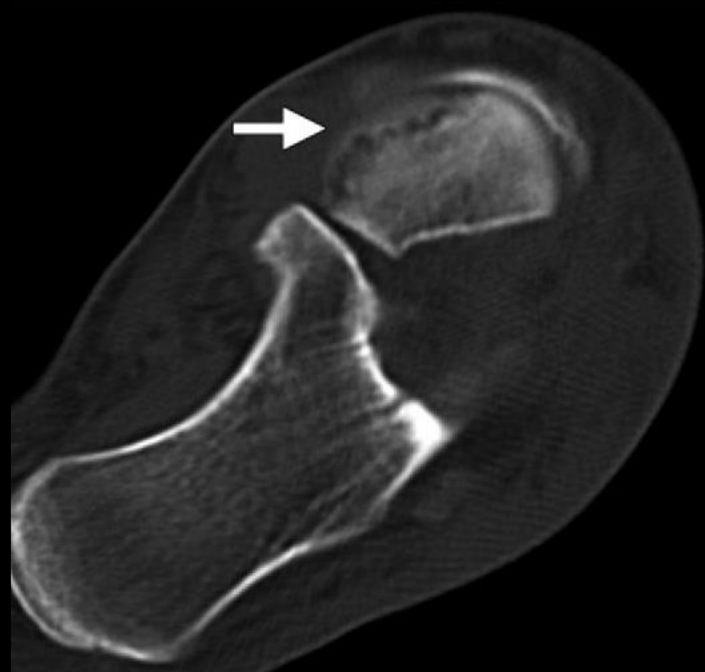
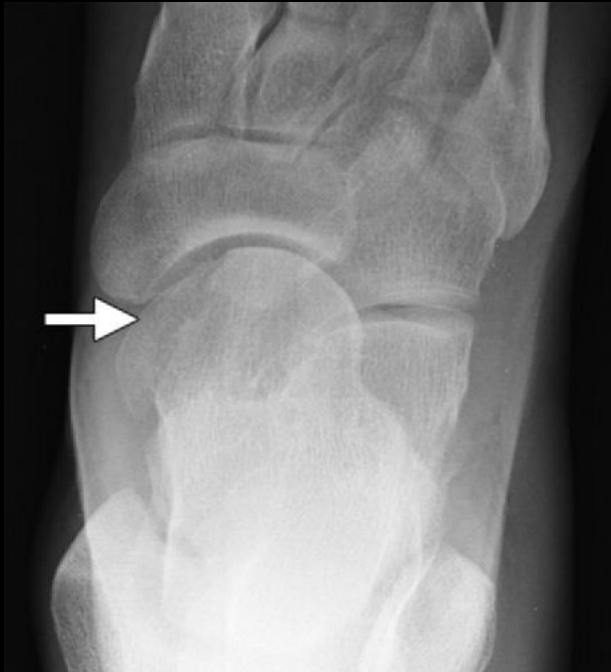- **Talar Head Fractures :**
 - Articular surface of the talus at the talonavicular articulation
 - Accompanied by dislocation or subluxation and adjacent bone fractures
 - 5%– 10% of all talar fractures
 - Pain at the dorsal midfoot, swelling and focal tenderness to palpation over the talar head, and painful range of motion

Mechanism:

- Crush injury to the articular surface
- Significant comminution
- Shear fracture

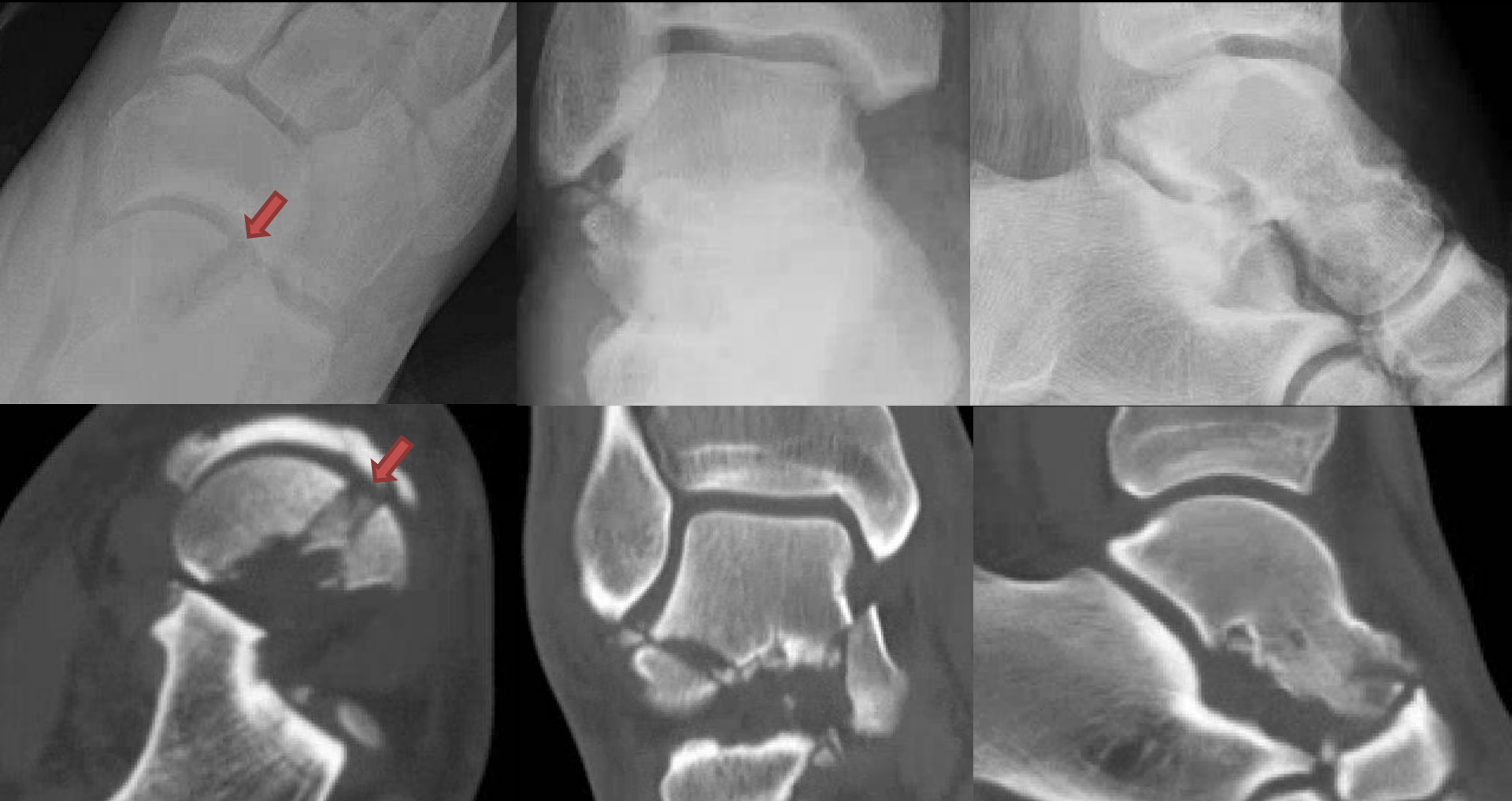Talar head fracture

20 years old male, status post MVA



Talar head fracture

20 years old male, status post MVA

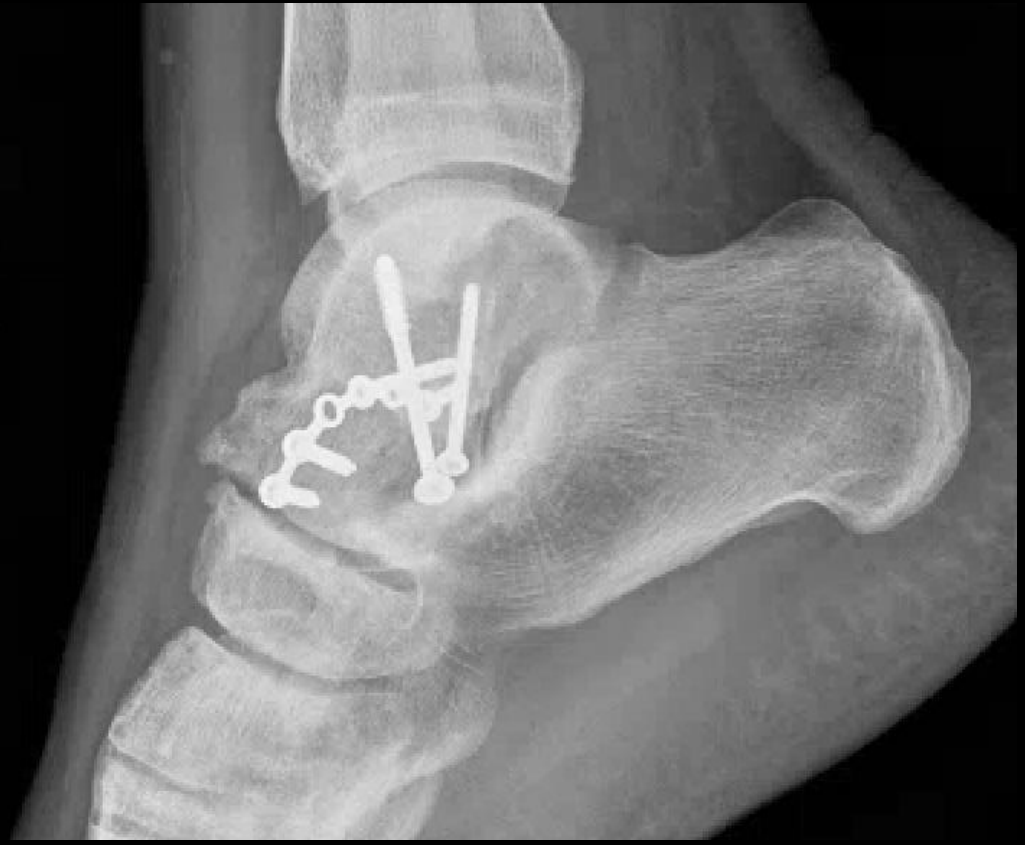
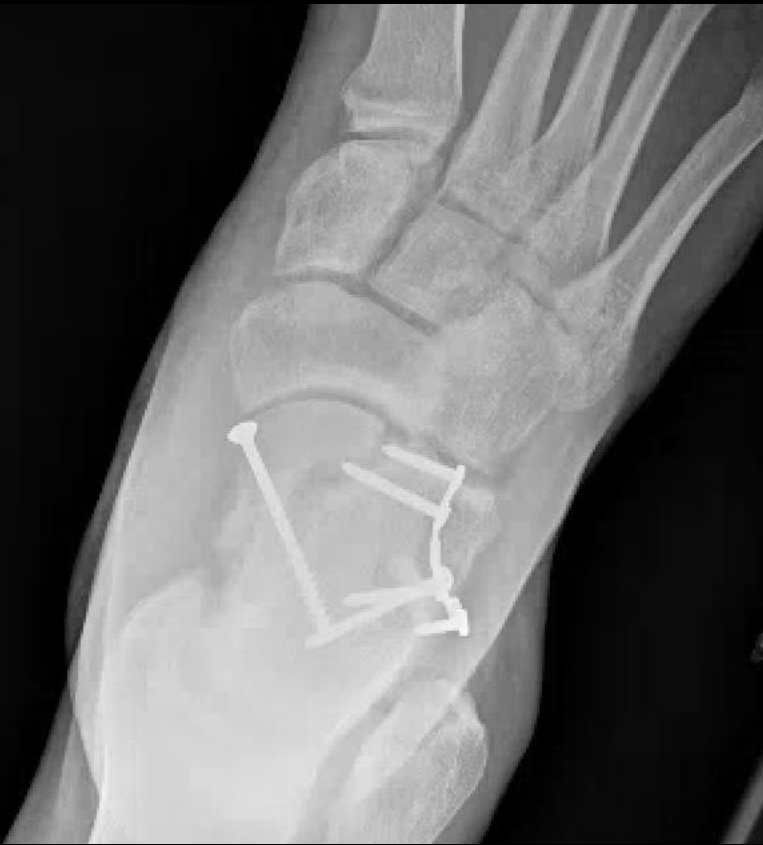
The Talus: Fractures

- **Talar Head Fractures :**
 - Imaging:
 - AP, oblique, and lateral radiographs of the foot
 - CT
 - Management:
 - Nondisplaced talar head fractures are treated conservatively
 - Displaced fractures require surgical intervention
 - Goal:
 - Maintain congruity of the talonavicular joint
 - Reduce the incidence of subsequent osteoarthritis and avascular necrosis

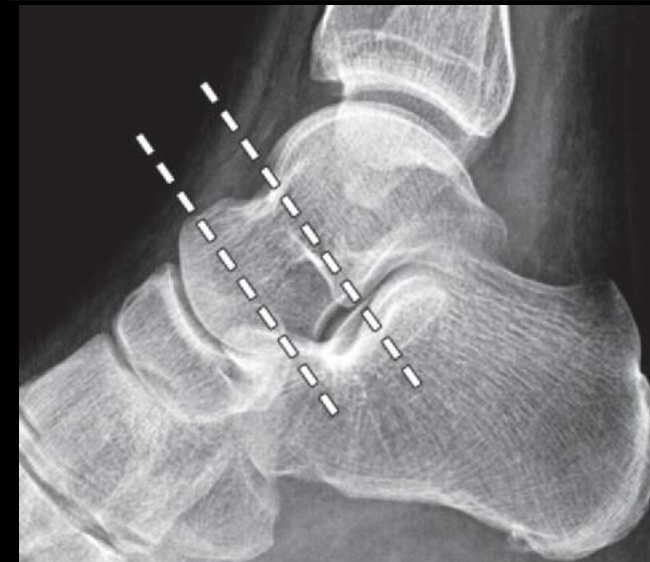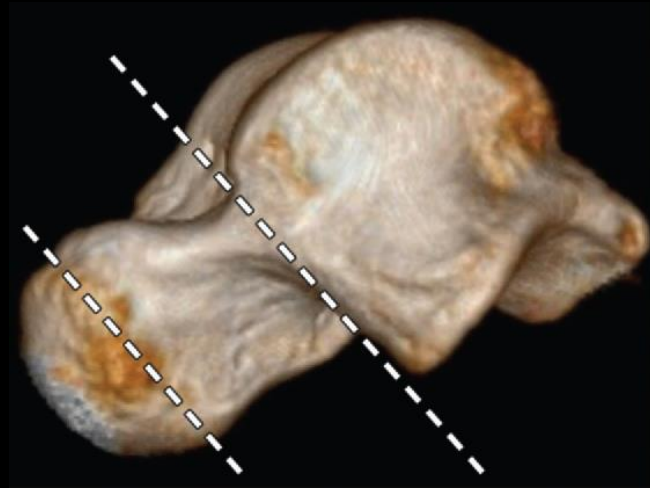
Talar head fracture

20 years old male, status post MVA



The Talus: Fractures

- **Talar Neck Fractures :**
 - Traditionally considered the most common talar fracture
 - Anterior or inferior to the lateral process of the talus and the talar dome cartilage
 - High incidence:
 - Small cross-sectional area
 - Vascular ingrowth, which increases the neck's porosity



The Talus: Fractures

- **Talar Neck Fractures :**
 - Mechanism of injury:
 - First described in airplane pilots during World War I and termed *aviator astragalus*
 - Motor vehicle or motorcycle collisions and high-level falls
 - Majority extended from the talar body or head

Mechanism:

- Combination of axial and dorsiflexion

The Talus: Fractures

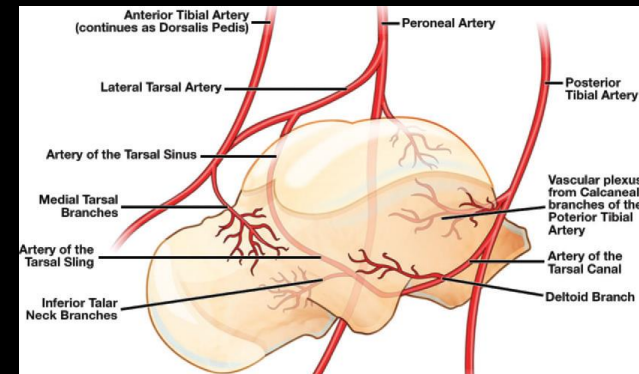
- **Talar Neck Fractures :**

Table 1: Risk of Osteonecrosis in Hawkins-Canale–Type Talar Fractures

Fracture Type	Description	Risk of Osteonecrosis (%)
I	Nondisplaced talar neck fracture	0–15
II	Talar neck fracture and talocalcaneal dislocation	20–50
III	Talar neck fracture, talocalcaneal dislocation, and tibiotalar dislocation	100
IV	Talar neck fracture and disruption of all talar articulations	100

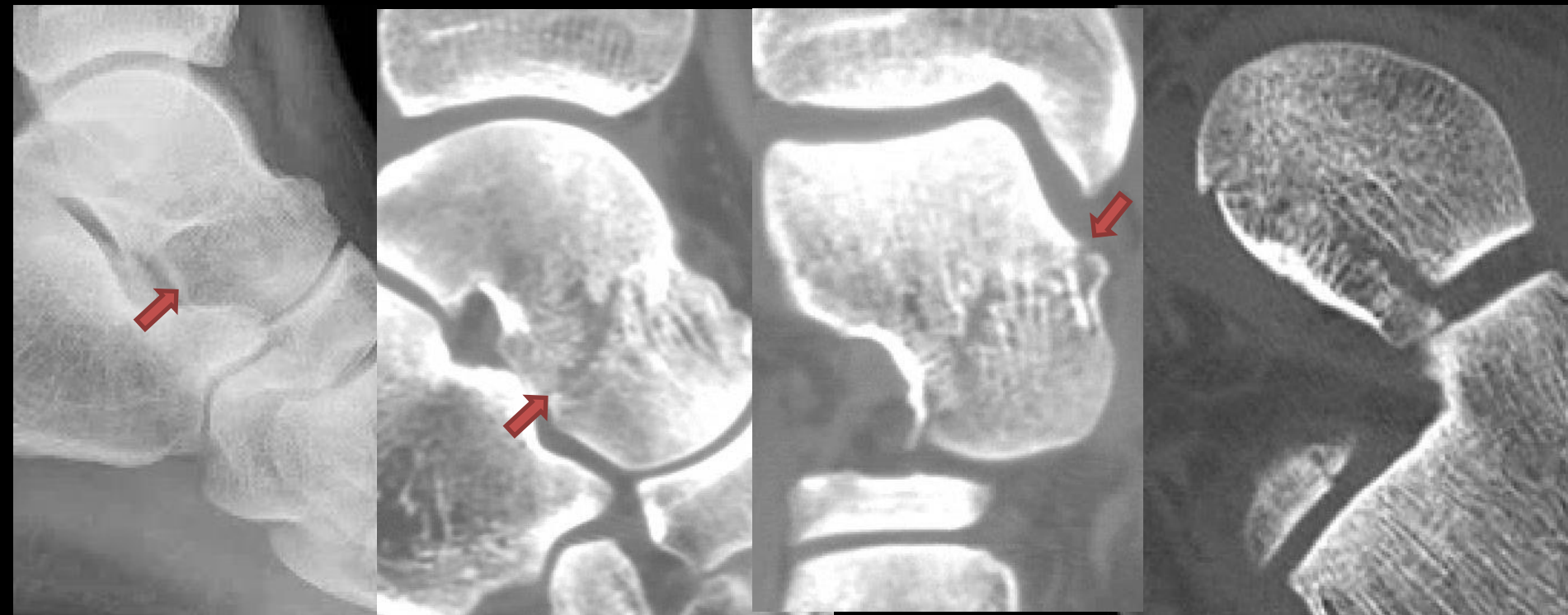
The Talus: Fractures

- **Talar Neck Fractures :**
 - Type I fracture: all three major sources of blood supply remain intact
 - Type II fractures: may lead to disruption of the artery of the tarsal canal
 - Type III fractures: disrupt both the artery of the tarsal canal and the deltoid and calcaneal branches
 - Type IV fractures: all three major sources of blood supply to the talus are likely compromised



The Talus: Fractures

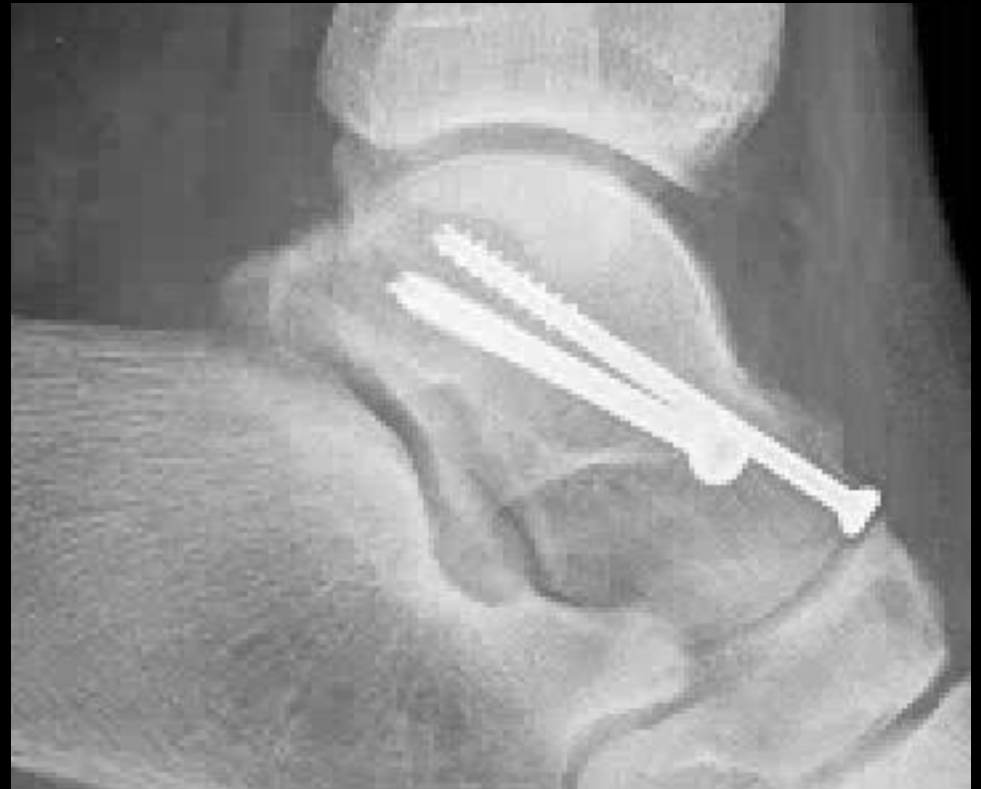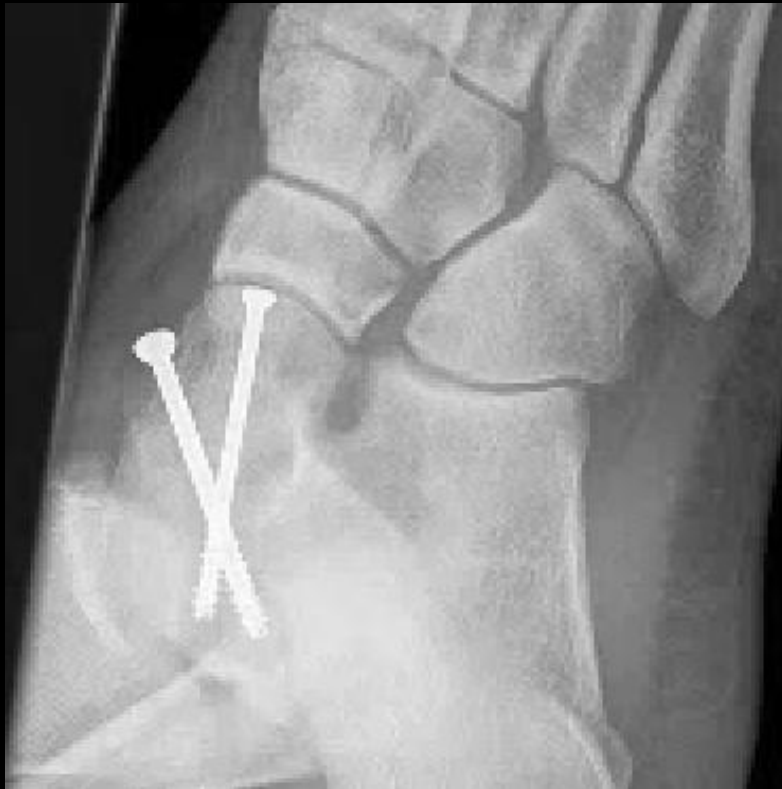35 years old male, fall from car



Hawkins-Canale type I talar neck fracture

The Talus: Fractures

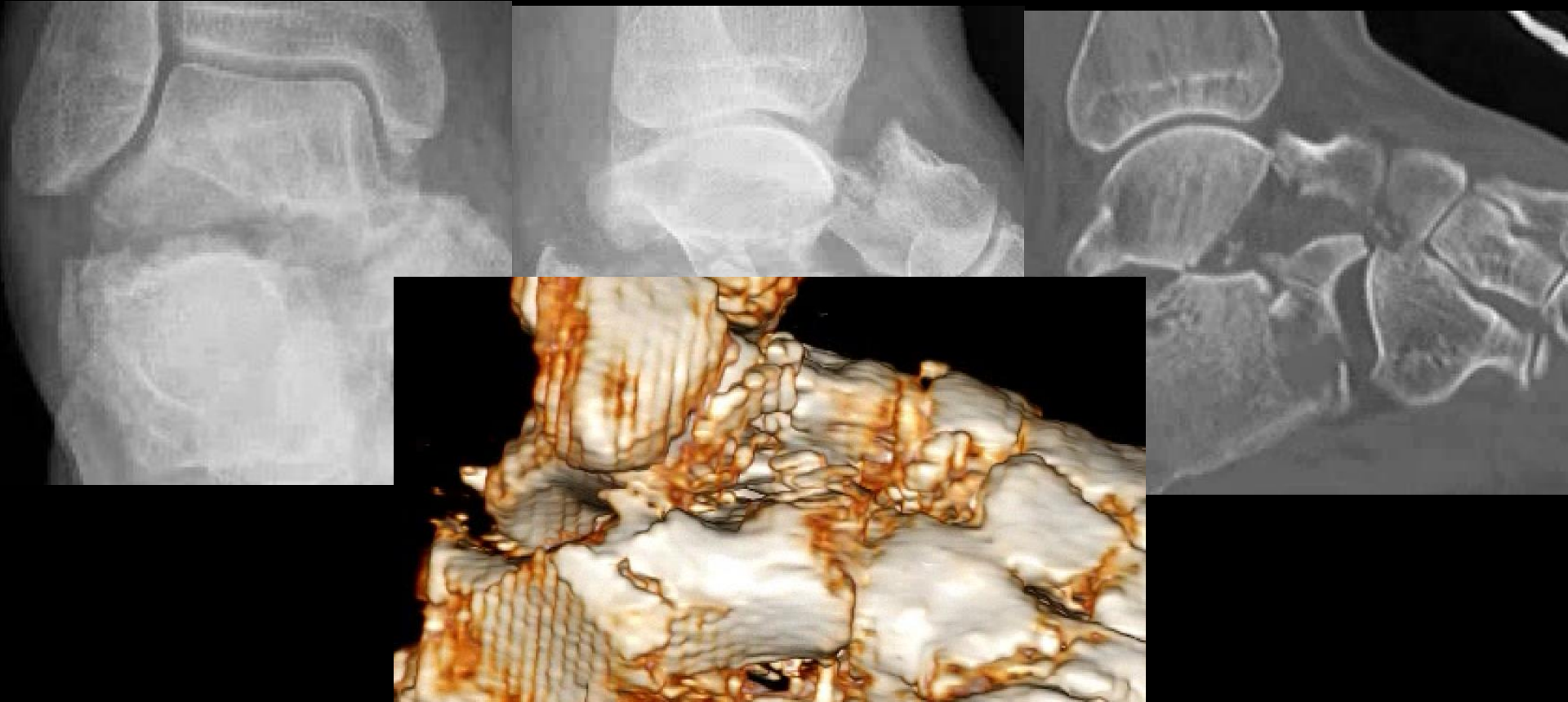
35 years old male, fall from car



Hawkins-Canale type I talar neck fracture

The Talus: Fractures

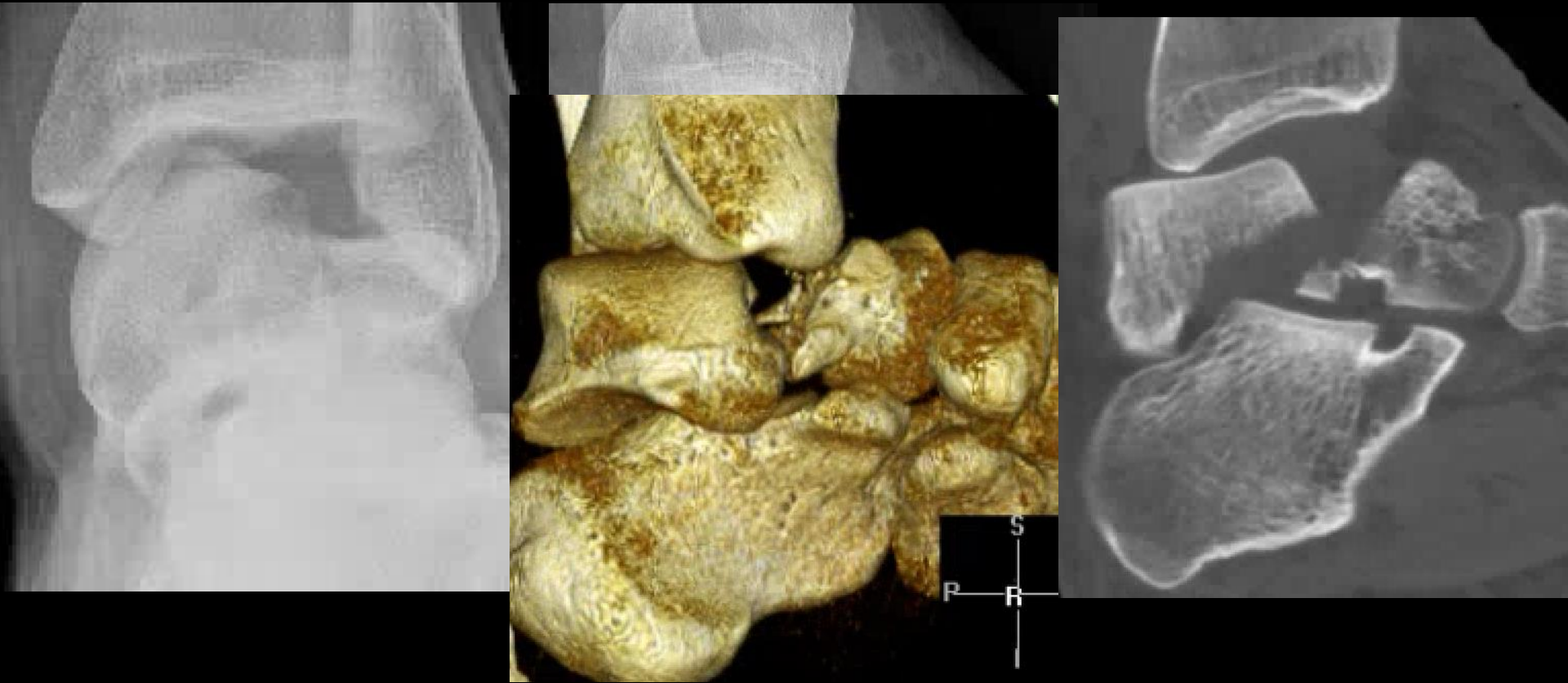
67 years old female, head on motor vehicle collision



Hawkins-Canale type II talar neck fracture

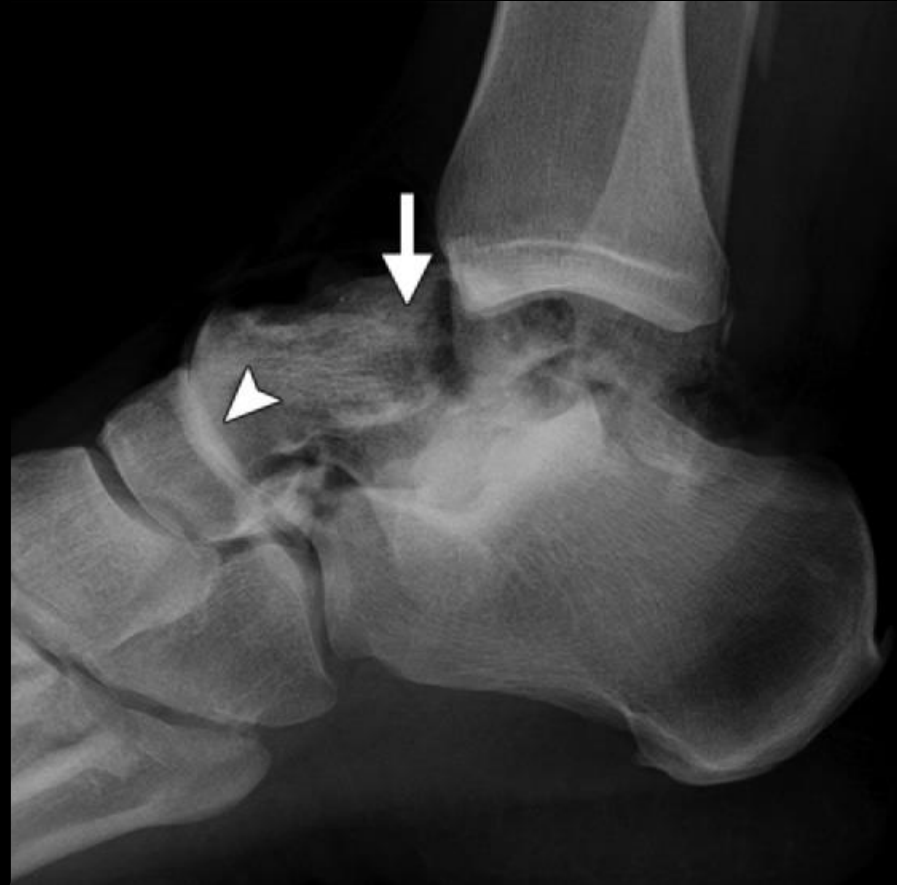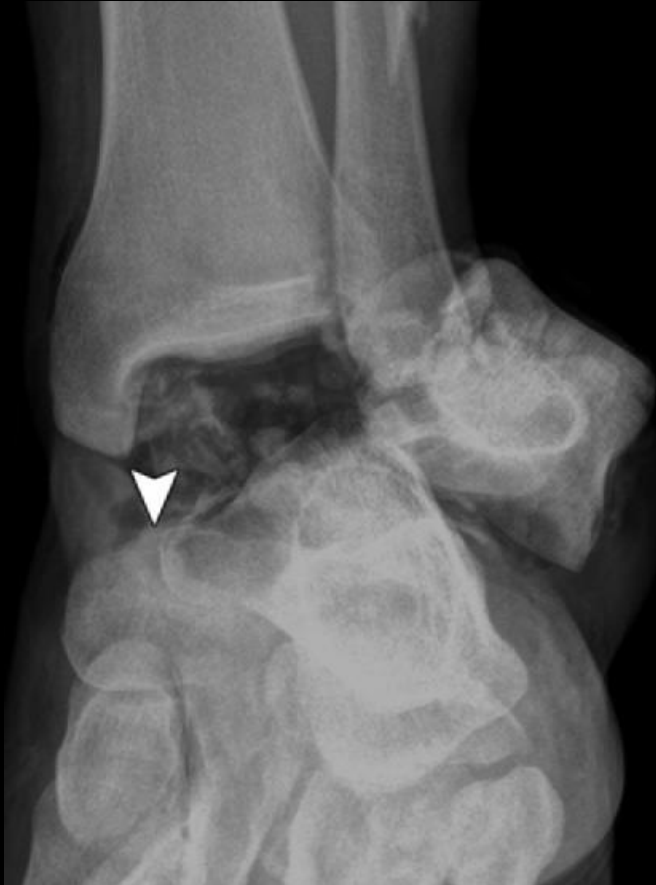The Talus: Fractures

29 years old male, status post fall from 25 feet



Hawkins-Canale type III talar neck fracture

The Talus: Fractures



Hawkins-Canale type IV talar neck fracture

The Talus: Fractures

- **Talar Neck Fractures :**
 - Type I: Nonoperative management
 - Most type II fractures are treated with surgical reduction
 - Type III and IV fractures:
 - Closed reduction
 - Open reduction and internal fixation

The Talus: Fractures

- **Talar Body Fractures :**

- 13% to 61%
- Simple, two-fragment fractures or extensively comminuted injuries
- Majority of talar body fractures are displaced and will require operative treatment
- Complications such as osteonecrosis and posttraumatic osteoarthritis are commonly encountered

Mechanism:

- High energy
- Shear and crush fractures
- Axial load on a dorsiflexed foot

The Talus: Fractures

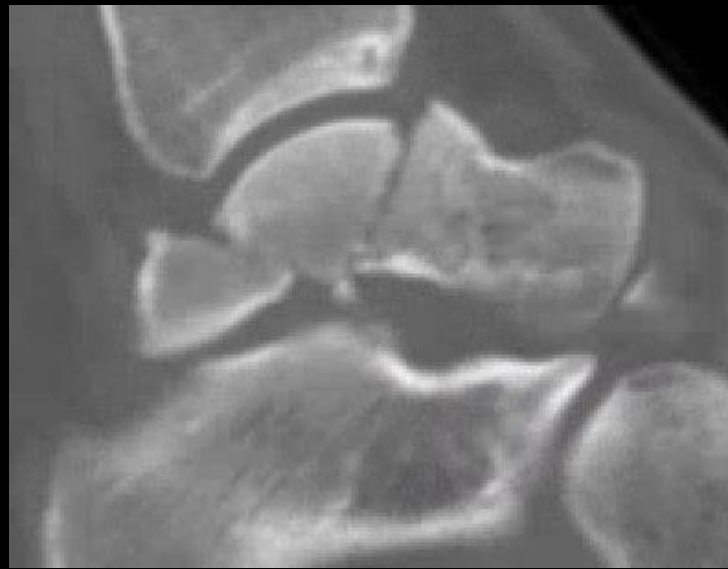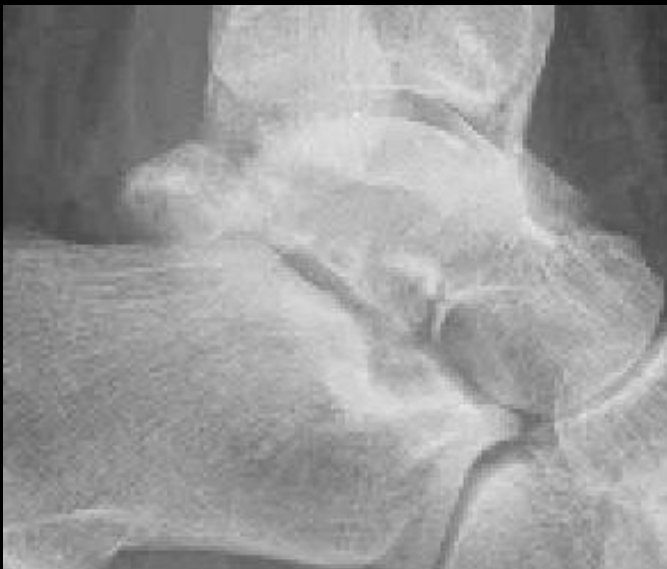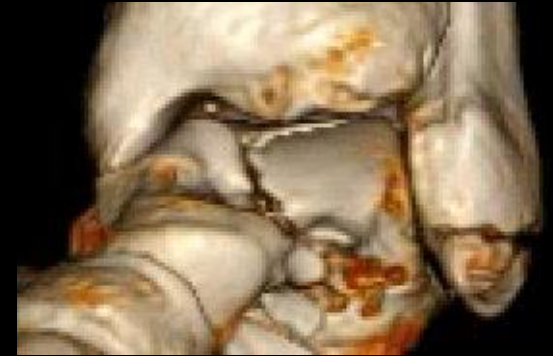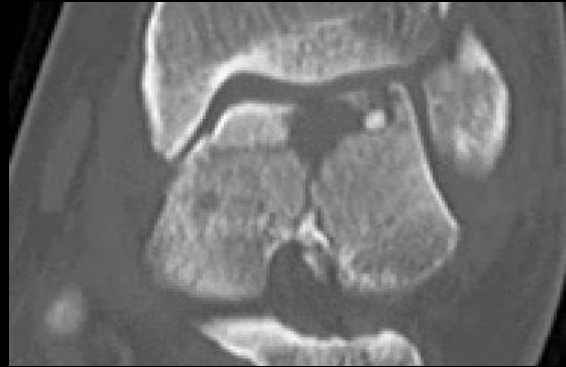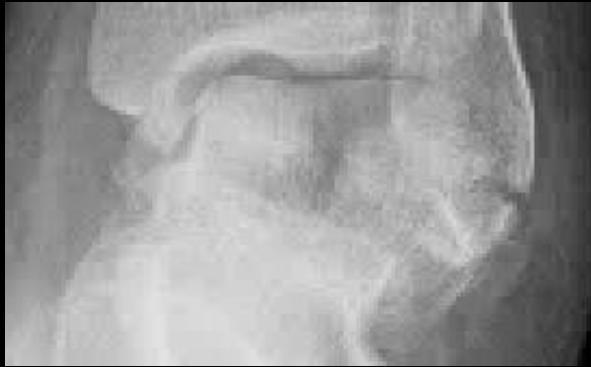- **Talar Body Fractures :**

Table 2: Sneppen Classification of Talar Body Fractures

Type	Description
A	Compression or osteochondral dome fracture
B	Coronal shear fracture
C	Sagittal shear fracture
D	Posterior tubercle fracture
E	Lateral tubercle fracture
F	Crush comminuted fracture

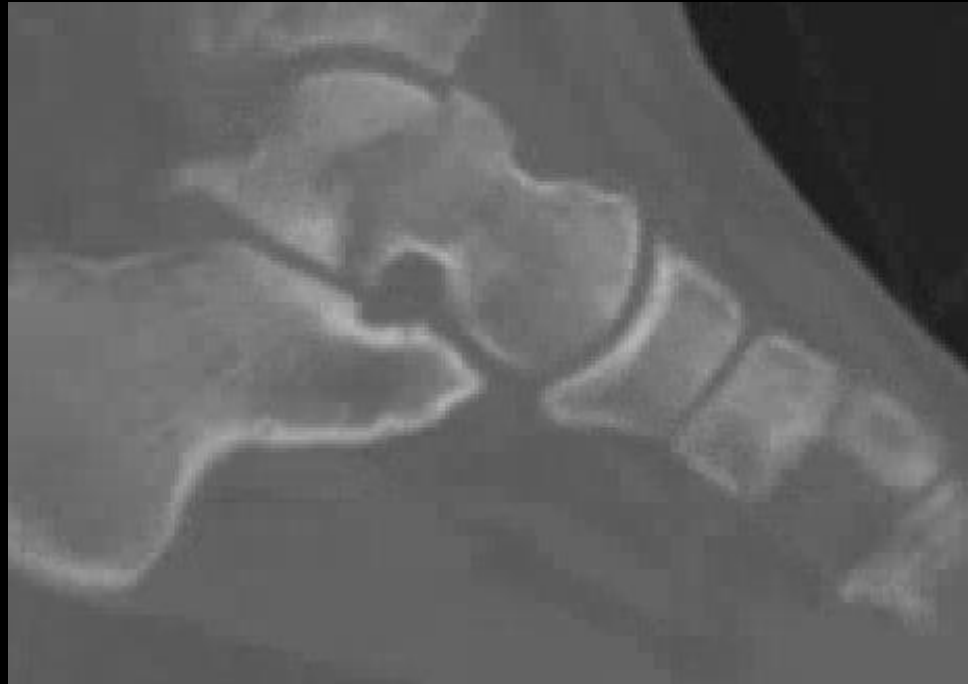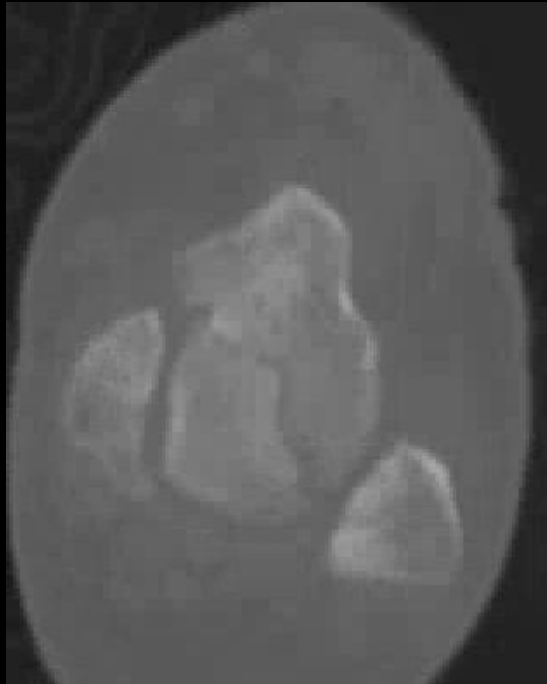
Talar body fracture

38 years old female, jumped off a cemented wall



Talar body fracture

20 years old male, status post trauma



The Talus: Fractures

- **Osteochondral Fractures of the Talar Dome:**
 - Impaction injury, which damages the articular cartilage and subchondral bone
 - 31% of talar dome compression fractures are occult on radiographs
 - *Lesion* and *fracture* have often been used interchangeably to describe osteochondral defects (OCDs).
 - OCD lesions account for about 1% of all talar fractures
 - The most commonly used system for classifying OCD lesions was presented by Berndt and Harty in 1959

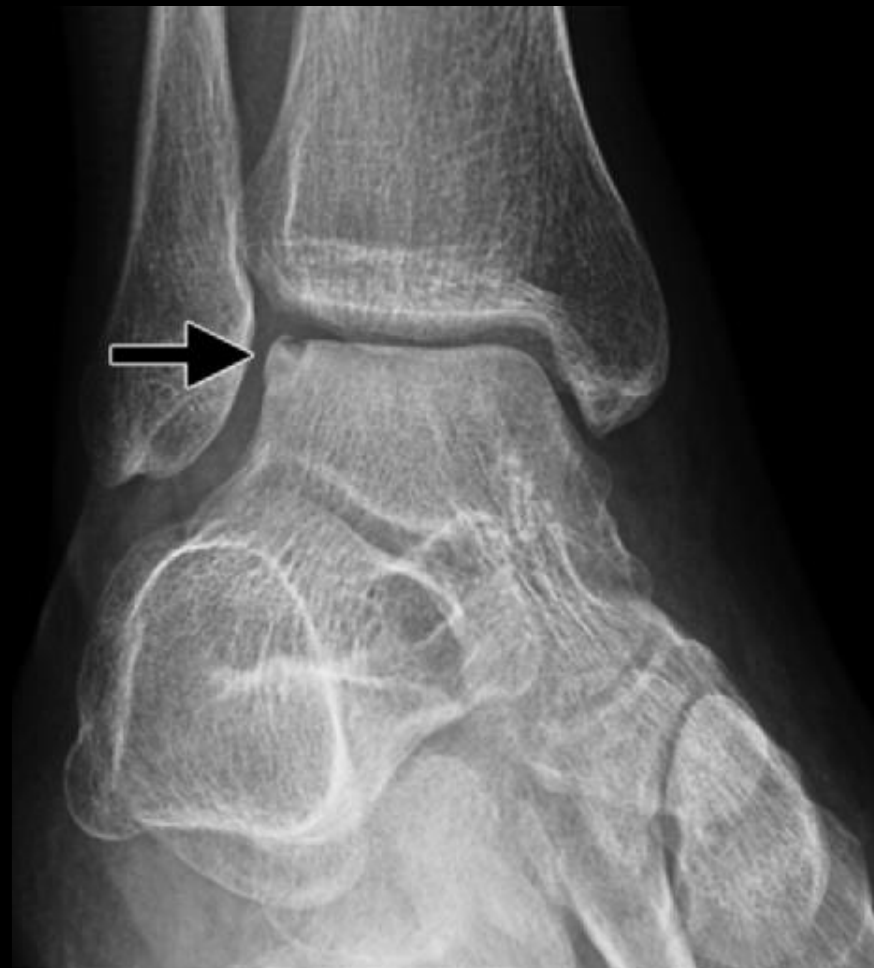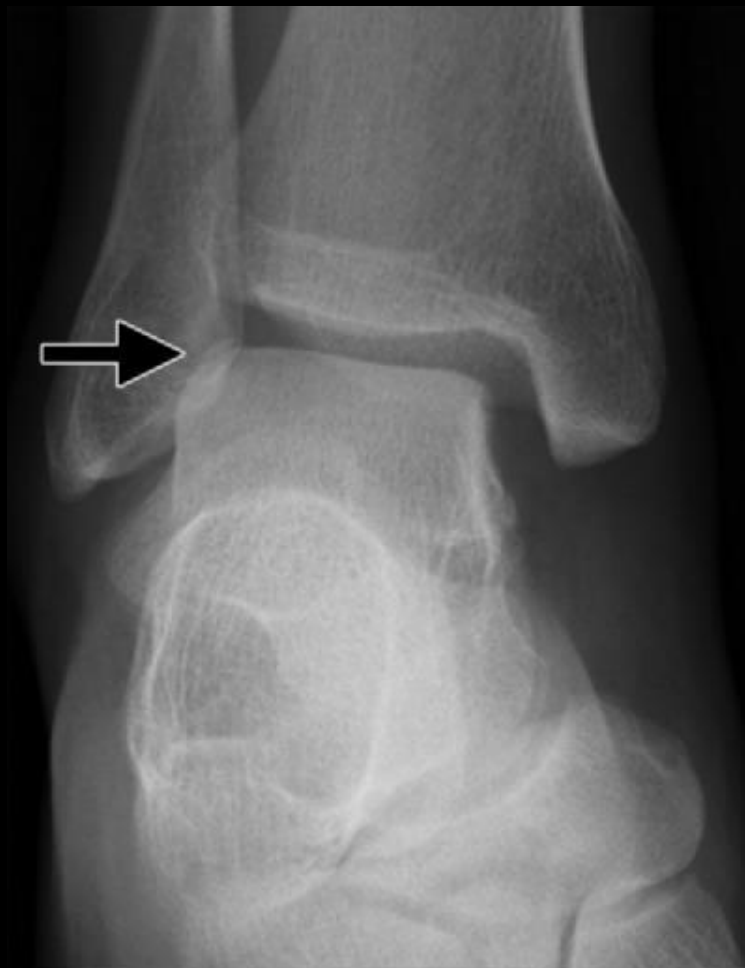The Talus: Fractures

- **Osteochondral Fractures of the Talar Dome:**
 - Additional staging described by Scranton and McDermott in 2001
 - Stage 1 is subchondral bone compression
 - Stage 2 is a partially detached osteochondral fragment
 - Stage 3 is a completely detached but nondisplaced osteochondral fragment
 - Stage 4 is a completely detached and displaced osteochondral fragment
 - Stage 5 is a large cyst below the articular surface.

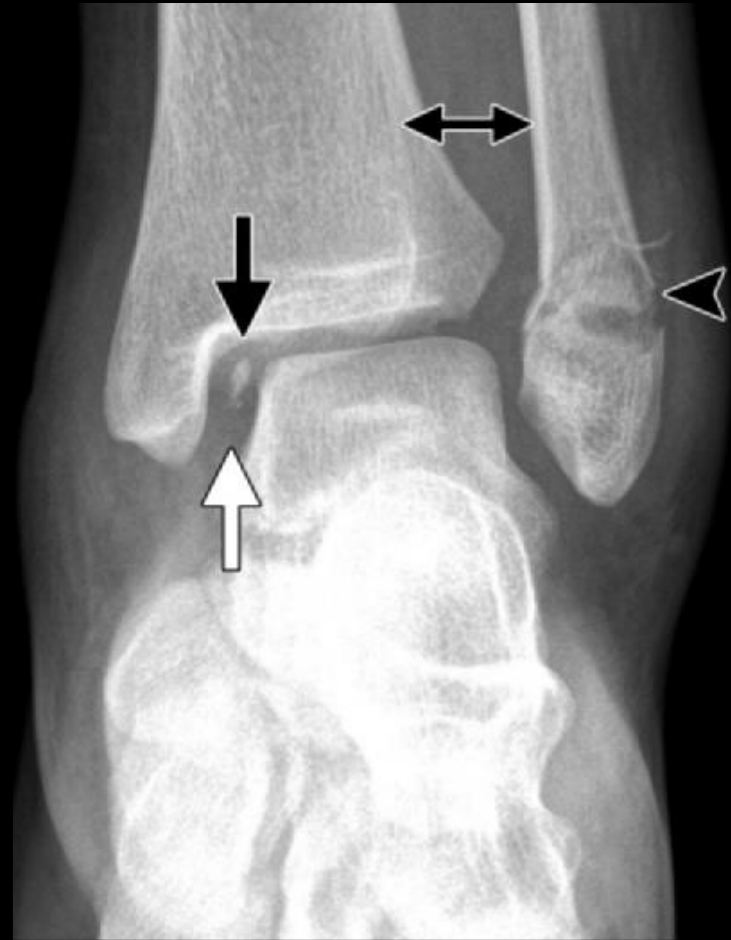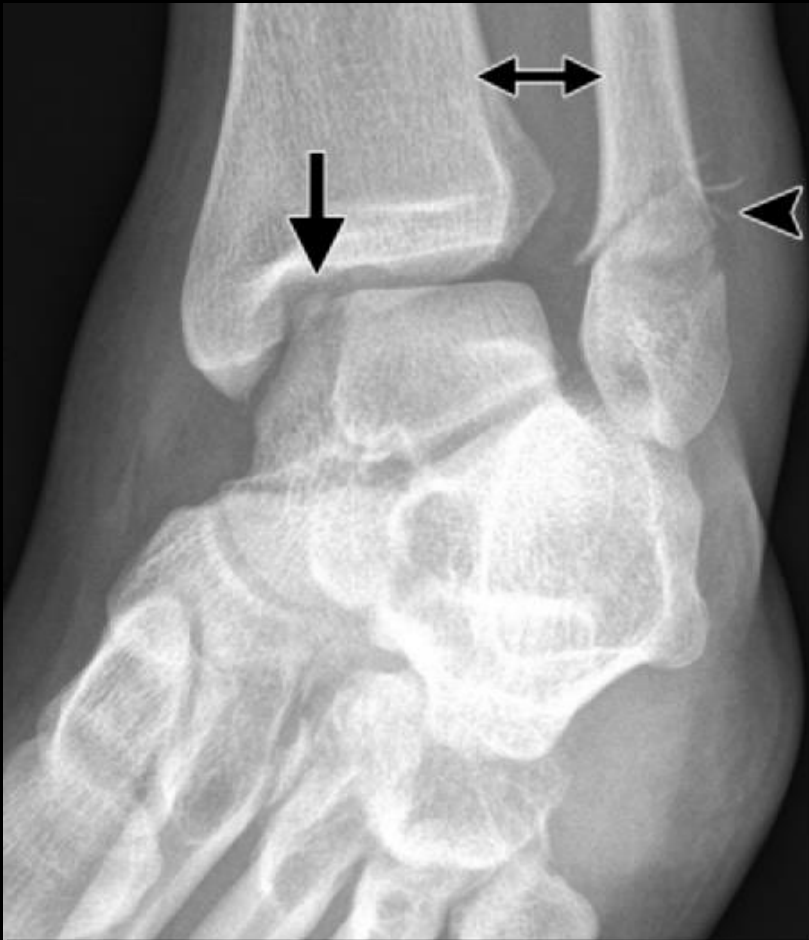The Talus: Fractures

- **Osteochondral Fractures of the Talar Dome:**
 - Lateral lesions:
 - Shallow
 - Wafer-shaped
 - Dorsiflexion and inversion injuries
 - Medial lesions:
 - Less symptomatic
 - Deep and cup-shaped
 - Plantar flexion and inversion (Fig 12).
 - Stable and nondisplaced OCD fragments: heal
 - Displaced unstable fragments: AVN

Osteochondral Fractures



Osteochondral Fractures



The Talus: Fractures

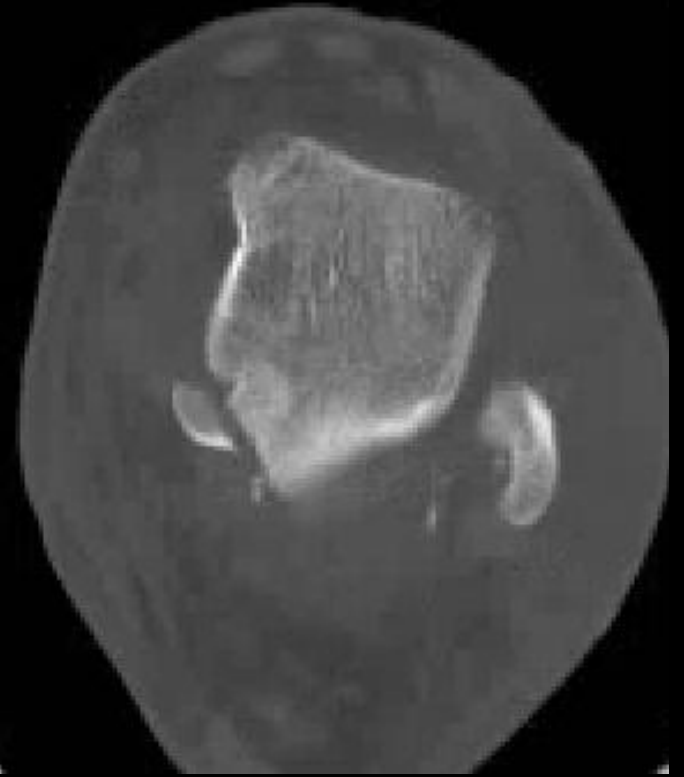
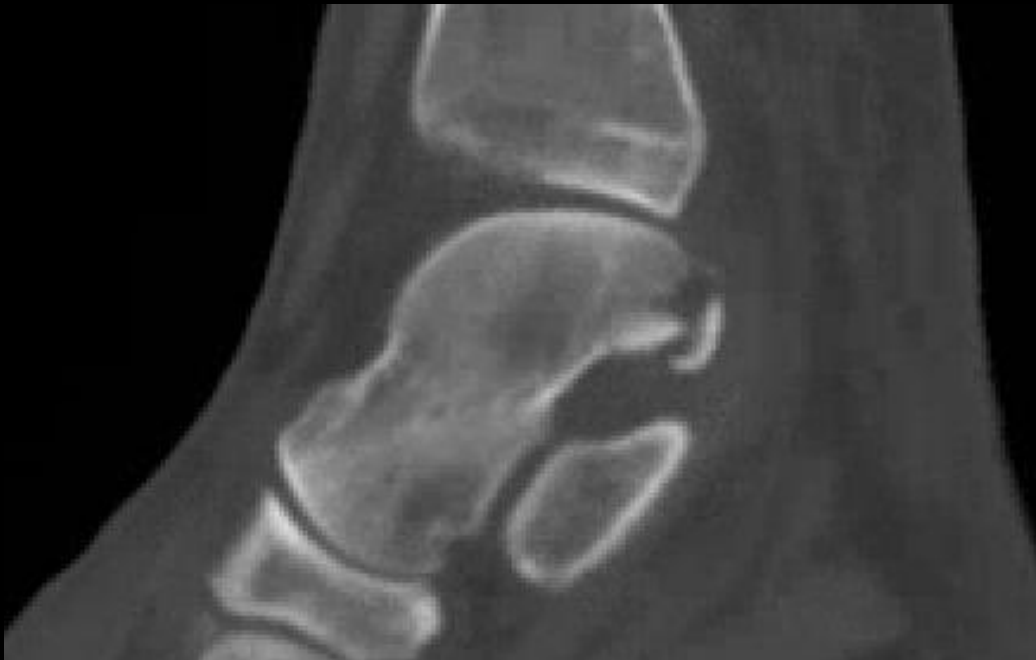- **Posterior Process Fractures:**
 - Lateral tubercle (Shepherd fracture)
 - Medial tubercle (Cedell fracture) → posteromedial fragment
 - Positive nutcracker sign: Pain and crepitation on forced plantar flexion of the ankle
- Treatment: Immobilization or excision of the fragment

Mechanism:

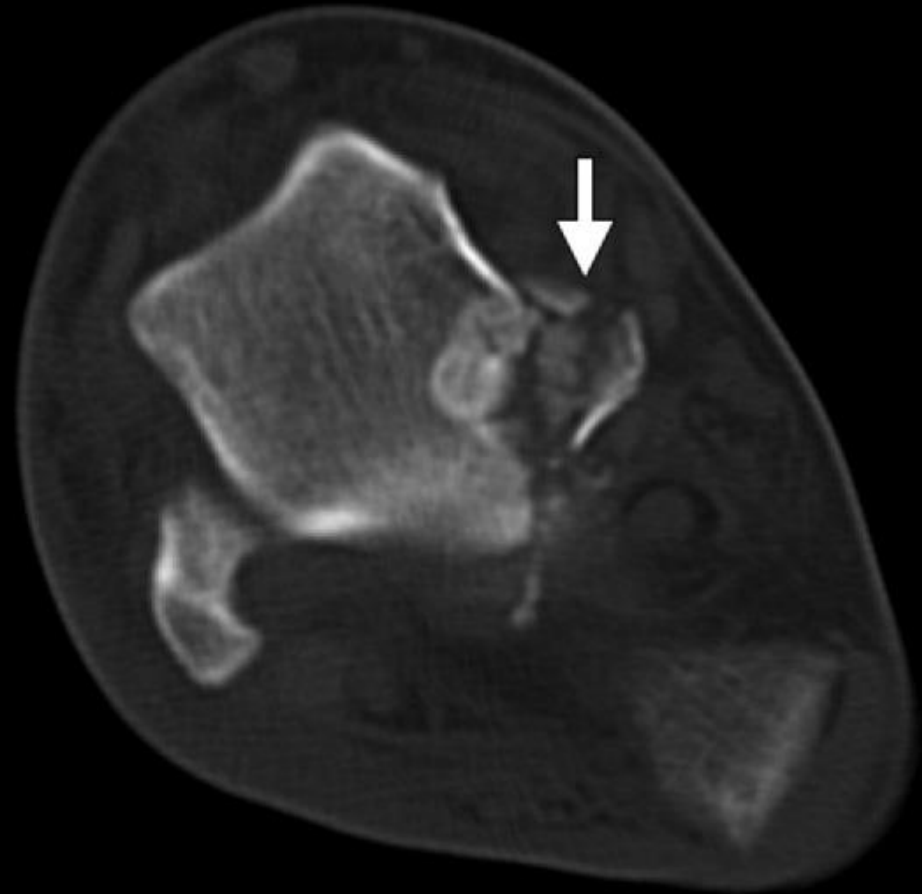
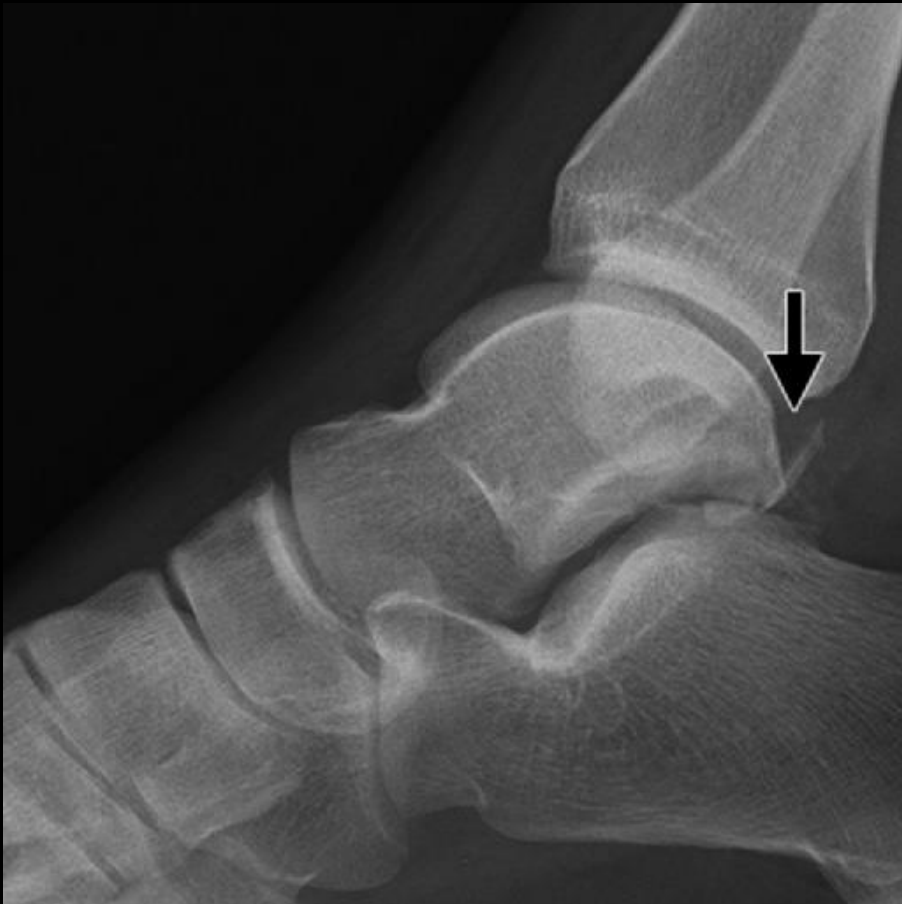- Direct trauma or forced plantar flexion
- Dorsiflexion and pronation → avulsion of PTAF

Posterior Process Fractures

20 years old, status post injury



Posterior Process Fractures



The Talus: Fractures

- **Lateral Process Fractures:**
 - Occult on initial radiographs → best on AP view
 - 2.3% of all snowboarding injuries
 - 15% of all ankle injuries
 - 19% of talar fractures in patients injured in motor vehicle accidents and falls from a height



Mechanism:

- Dorsiflexed
- Eversion
- Axial loading

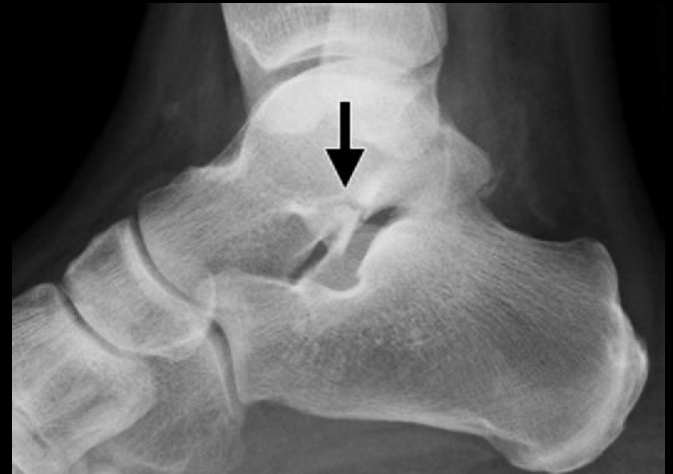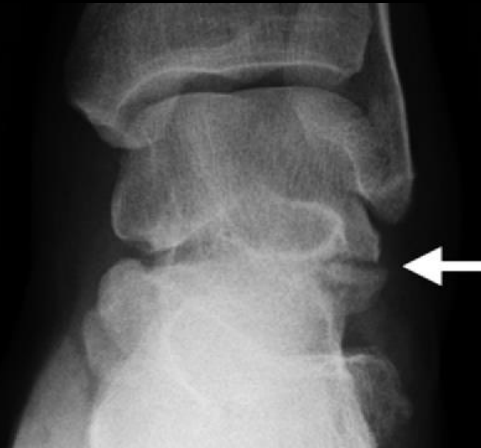
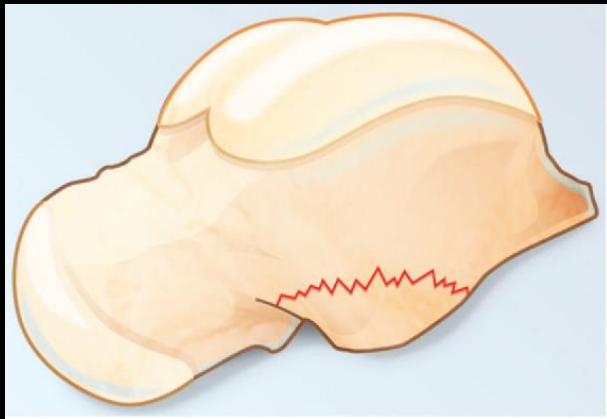
The Talus: Fractures

- **Lateral Process Fractures:**

- Classification (Hawkins criteria):

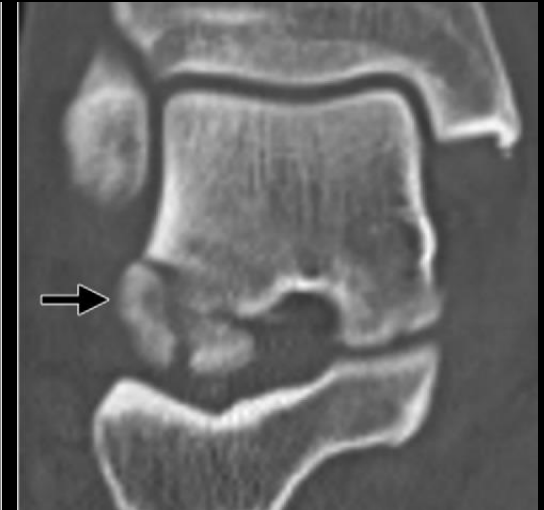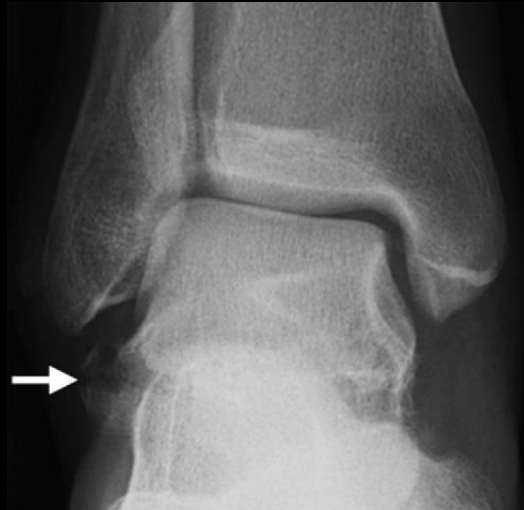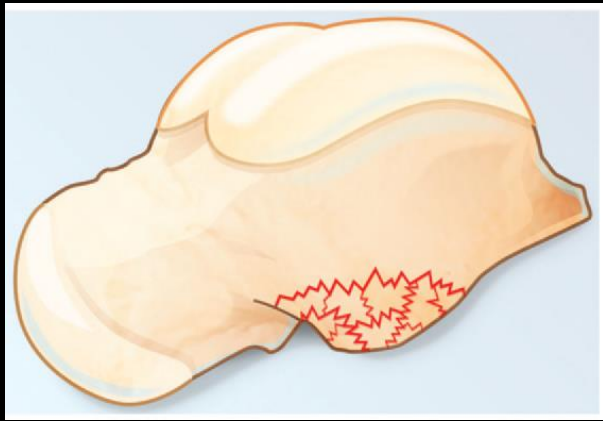
- simple (type I): Most common

- Single fracture line extending from the talofibular articular surface to the subtalar joint



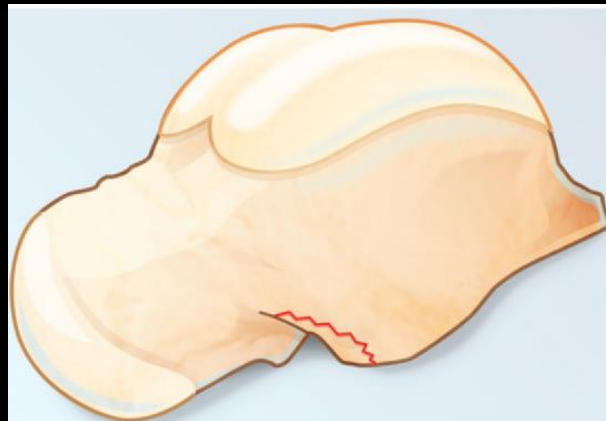
The Talus: Fractures

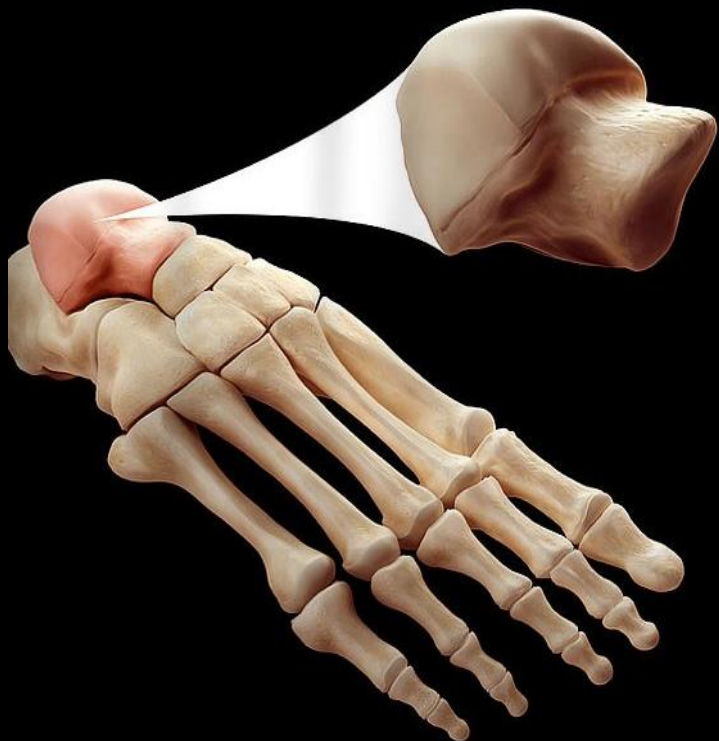
- **Lateral Process Fractures:**
 - Classification (Hawkins criteria):
 - Comminuted (type II)
 - Involving the entire lateral process and both articular surfaces



The Talus: Fractures

- **Lateral Process Fractures:**
 - Classification (Hawkins criteria):
 - Chip (type III)
 - Region of the sinus tarsi and are usually visualized only on lateral radiograph





Anatomy

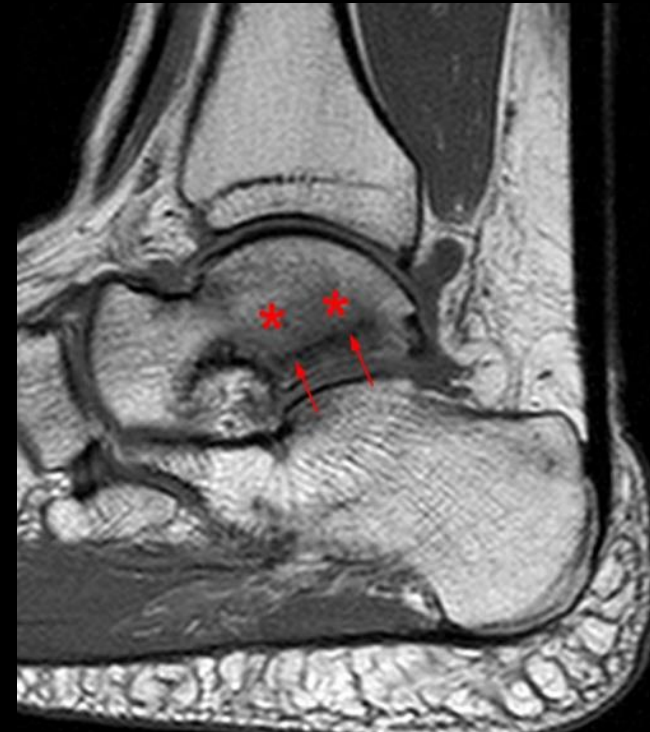Congenital

Fractures

Stress related injury

The Talus: Stress fractures

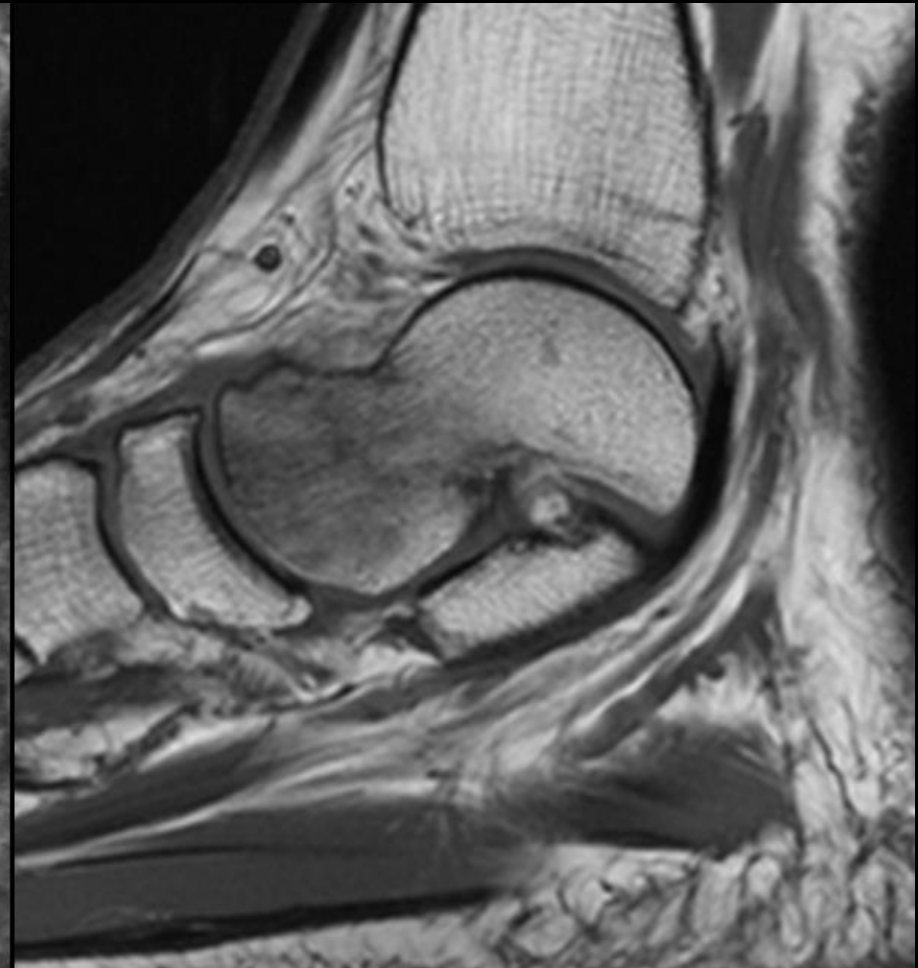
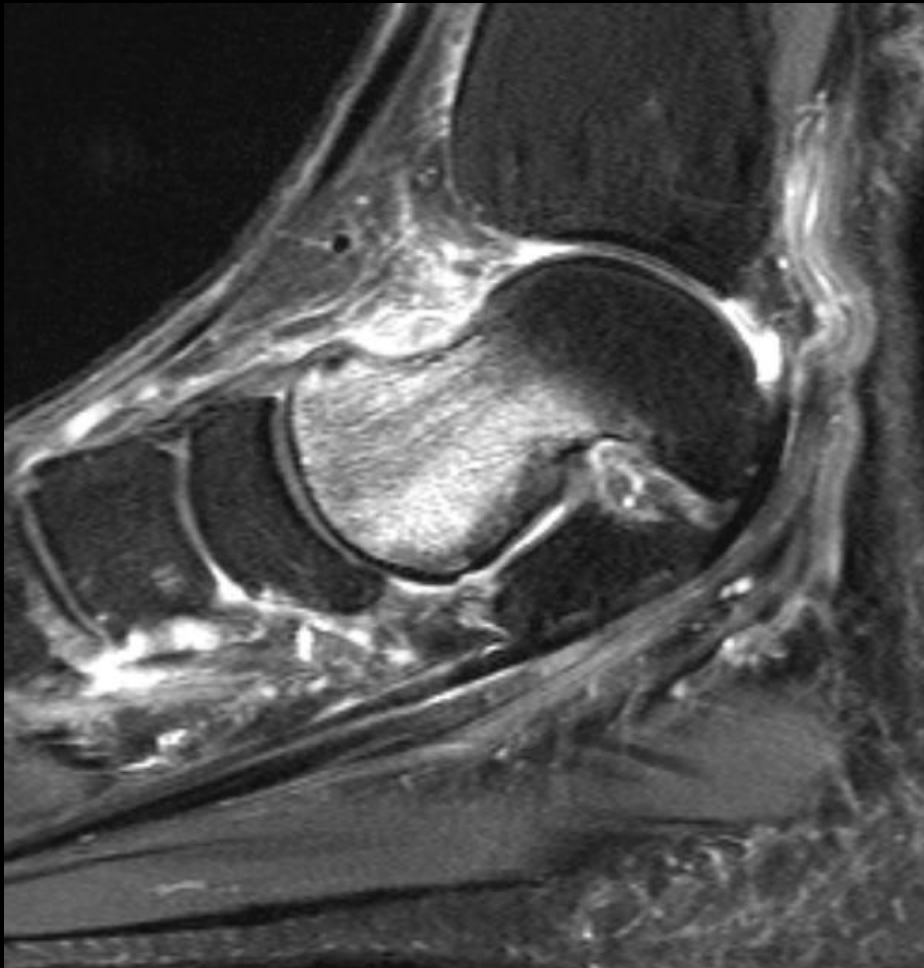
- Talus is a relatively uncommon site of a stress fracture
- First report by McGlone in 1965
- Athletes, military recruits, and sports enthusiasts
- Talar head stress fracture is the most common



<http://radsourc.us/stress-fractures-foot-ankle/>

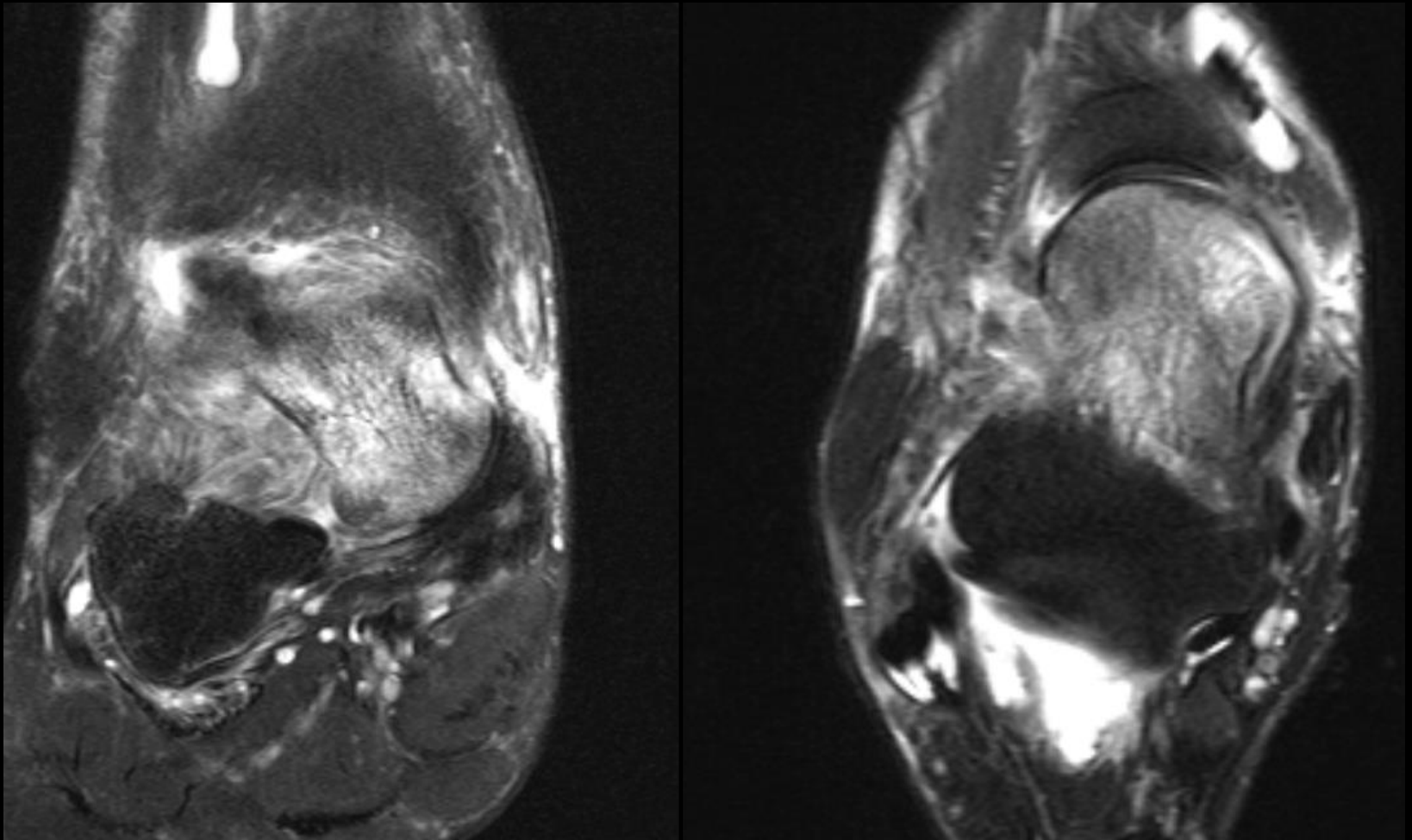
The Talus: Stress fractures

56-year-old female status post fall November 2018 with persistent ankle pain and edema.
No additional history of trauma.



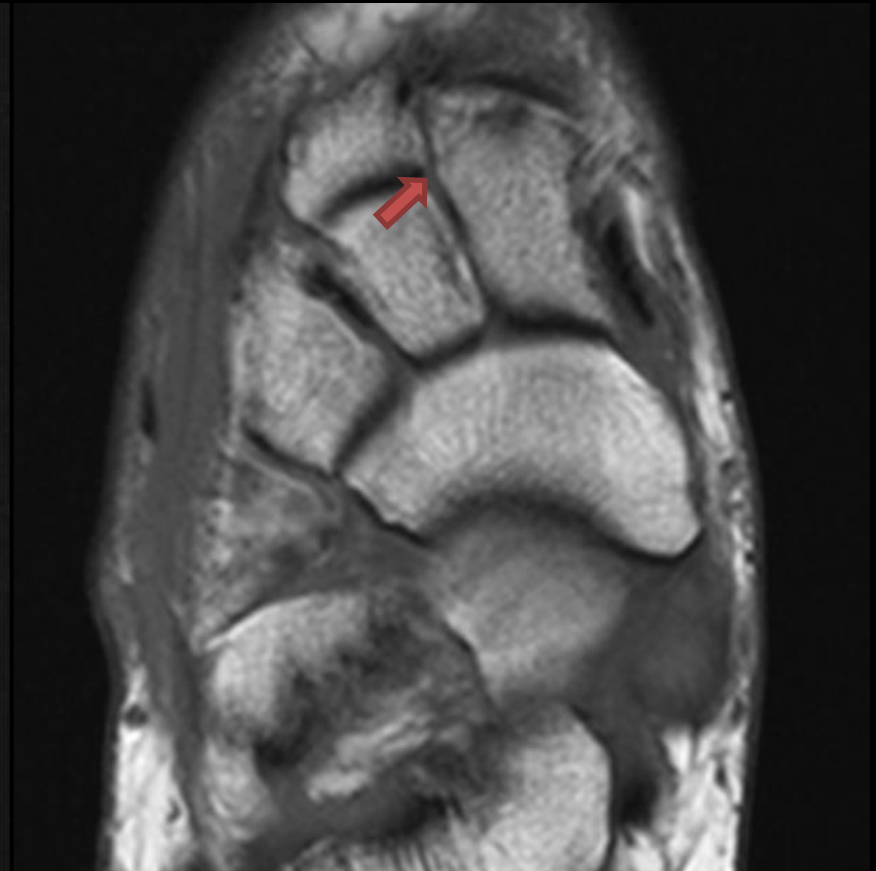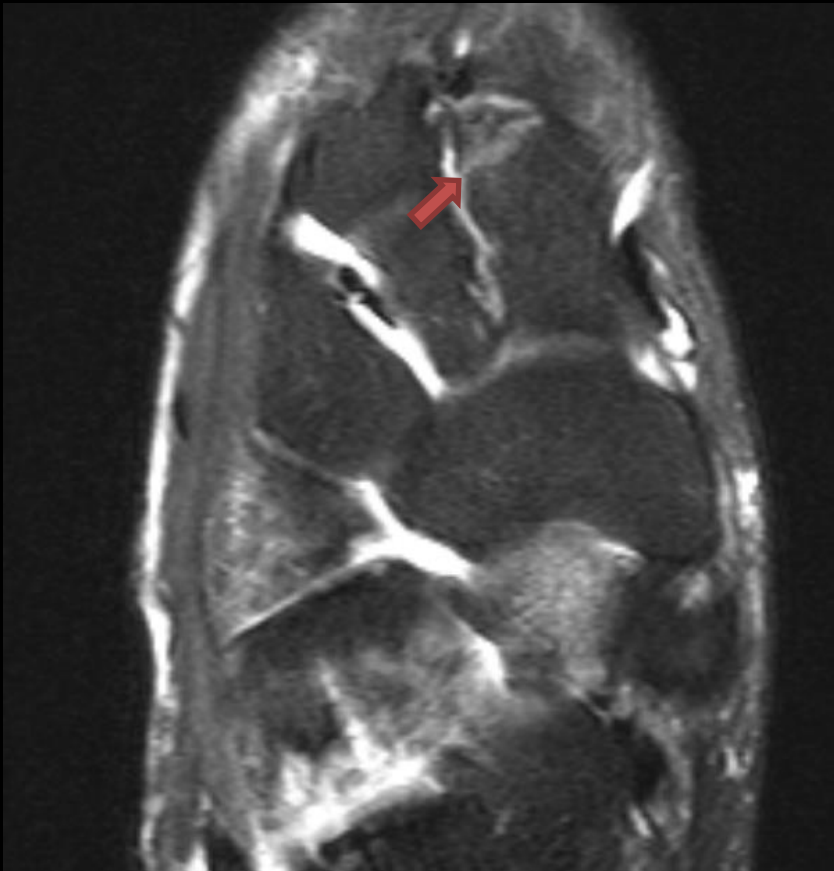The Talus: Stress fractures

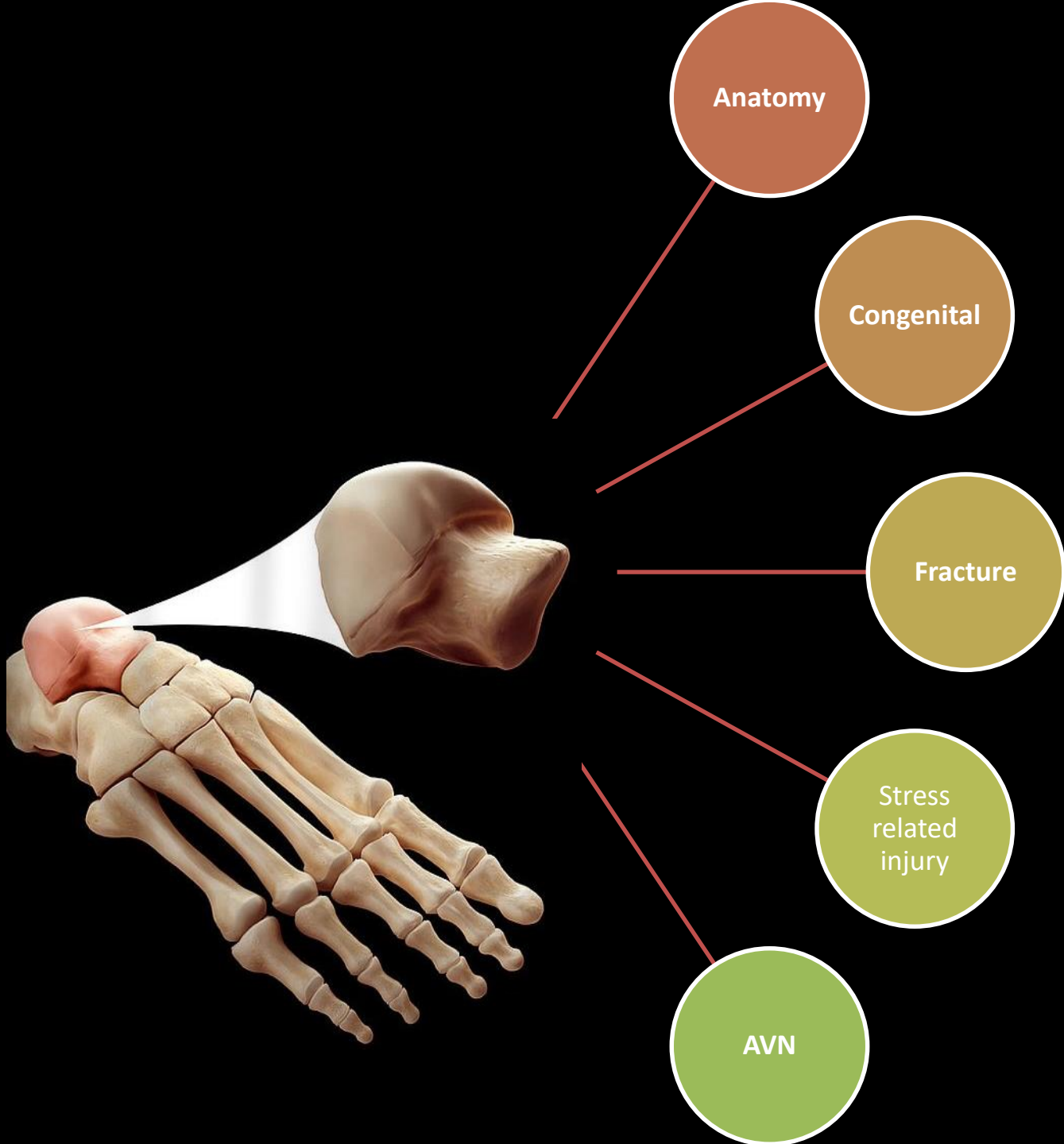
56-year-old female status post fall November 2018 with persistent ankle pain and edema.
No additional history of trauma.



The Talus: Stress fractures

56-year-old female status post fall November 2018 with persistent ankle pain and edema.
No additional history of trauma.





The Talus: Avascular Necrosis

- Anatomic consideration:
 - 60% of its surface is covered by articular cartilage
 - No muscular or tendinous attachments
 - Only a limited area of penetrable bone is available for vascular perforation
 - Small nutrient vessels
 - Variations in intraosseous anastomoses
 - Lack of collateral circulation

The Talus: Avascular Necrosis

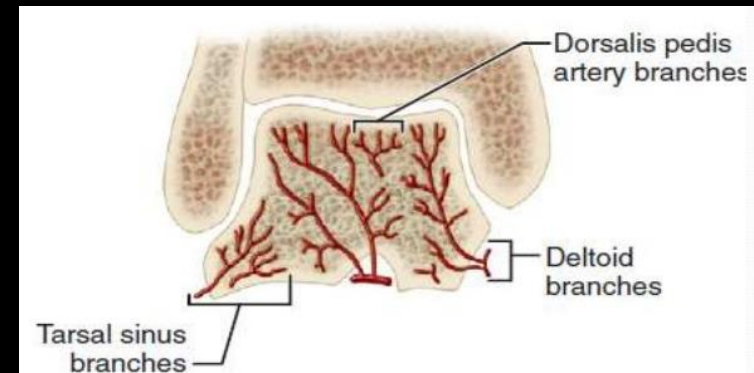
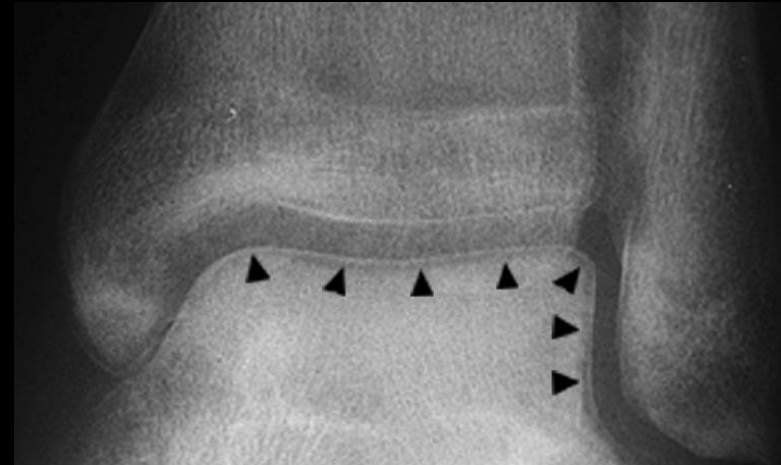
- AVN (osteonecrosis) of the talus:
 - Interruption in any part of the vascular network:
 - Arteries, capillaries, sinusoids, and veins
 - This interruption can be classified as:
 - Obstruction
 - Compression
 - Physical disruption
- The body's response to AVN is an attempt at repair by means of reossification, revascularization and resorption of necrotic bone
→ radiographic appearance of AVN

The Talus: Avascular Necrosis

- AVN (osteonecrosis) classification:
 - Traumatic
 - Fracture and dislocation of the talar neck
 - Atraumatic
 - Corticosteroids
 - Alcoholism
 - Systemic lupus erythematosus
 - Renal transplants
 - Sickle cell anemia
 - Hyperlipidemia
 - Irradiation
 - Inherited thrombophilias

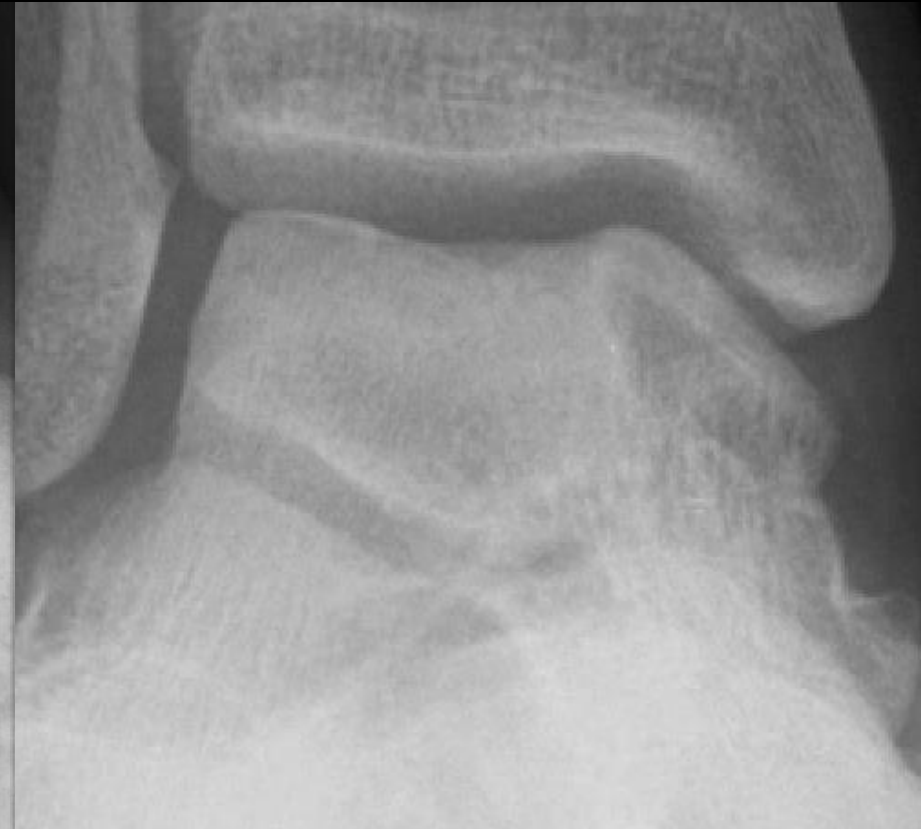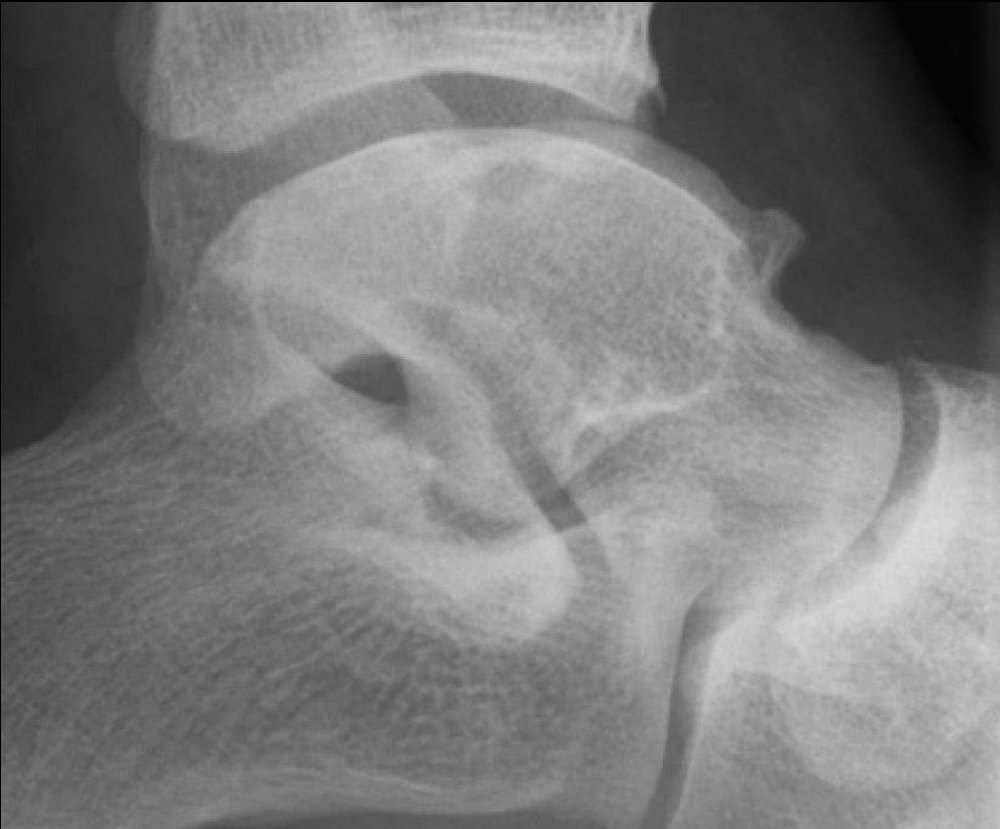The Talus: Avascular Necrosis

- **Hawkins sign:**
 - Thin subchondral radiolucent line along all or part of the talar dome
 - 6–8 weeks after injury
 - AP radiographs
 - Adequate blood supply
- **Partial Hawkins:** incomplete (partial) AVN → lateral > medial



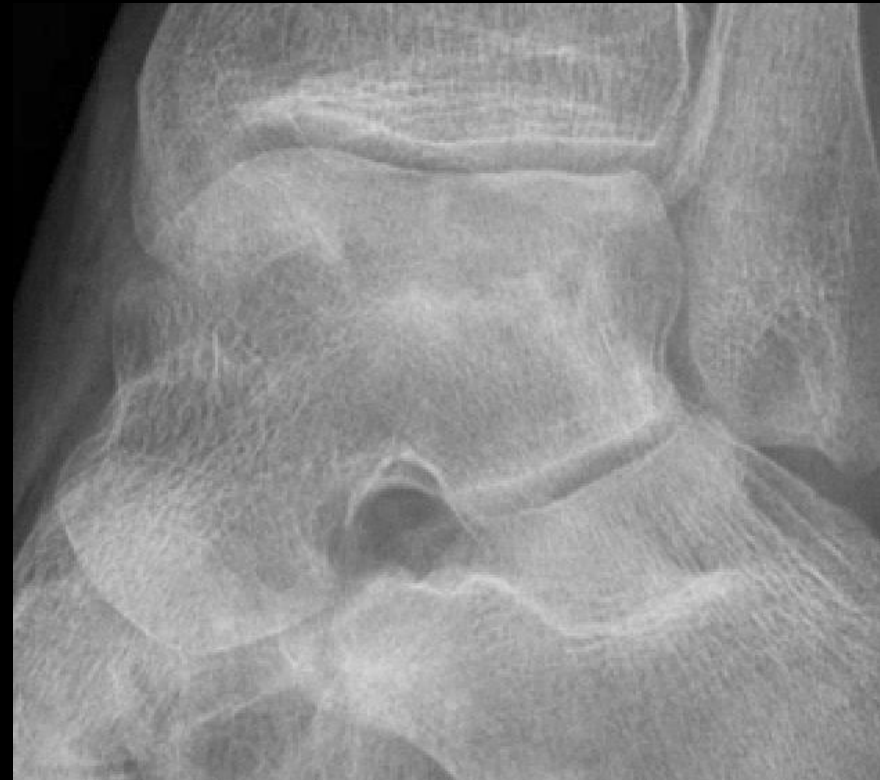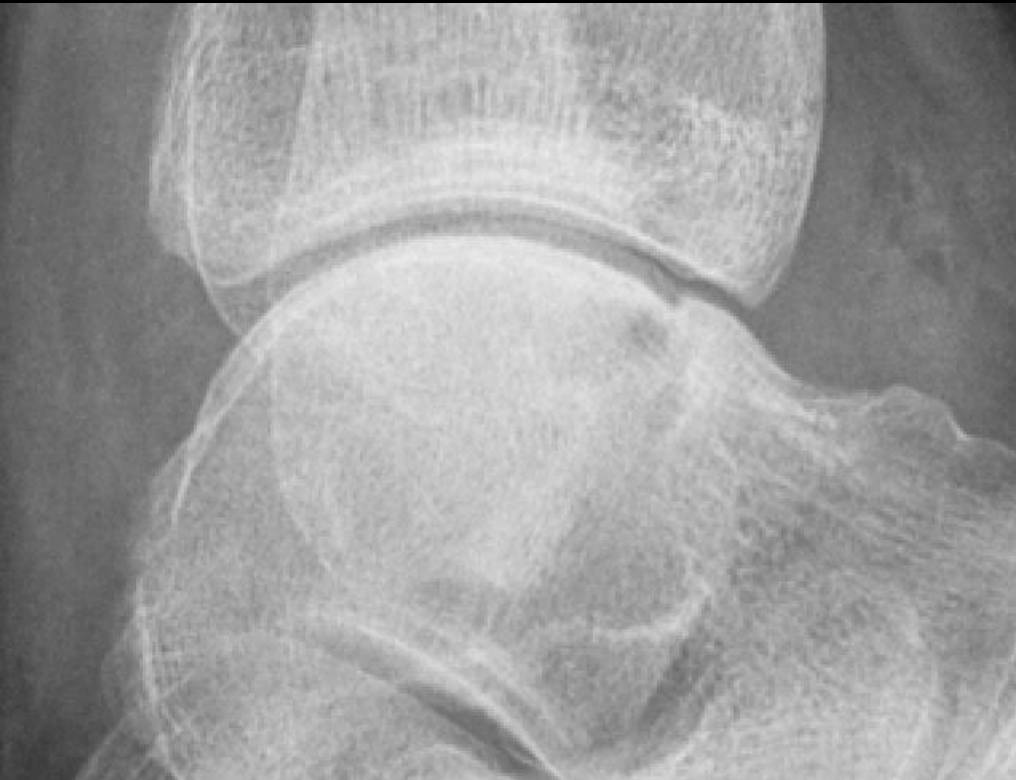The Talus: Avascular Necrosis

38 year old male, history of fall from fence.



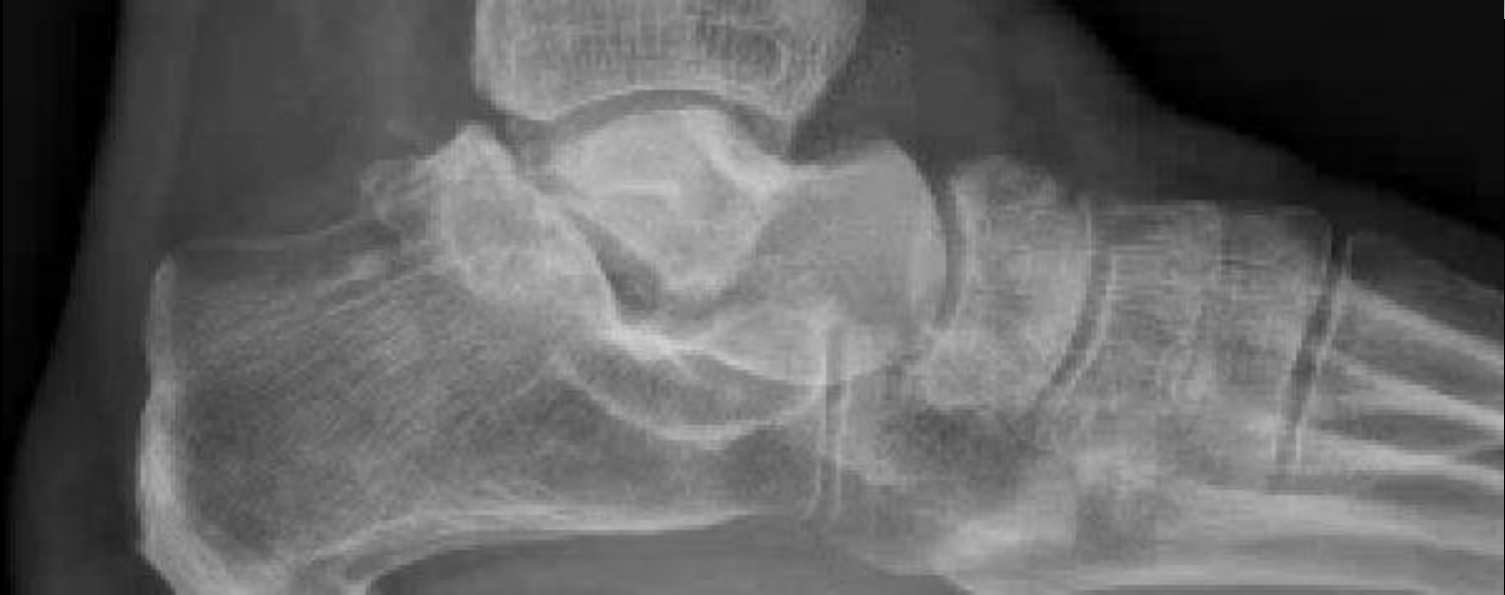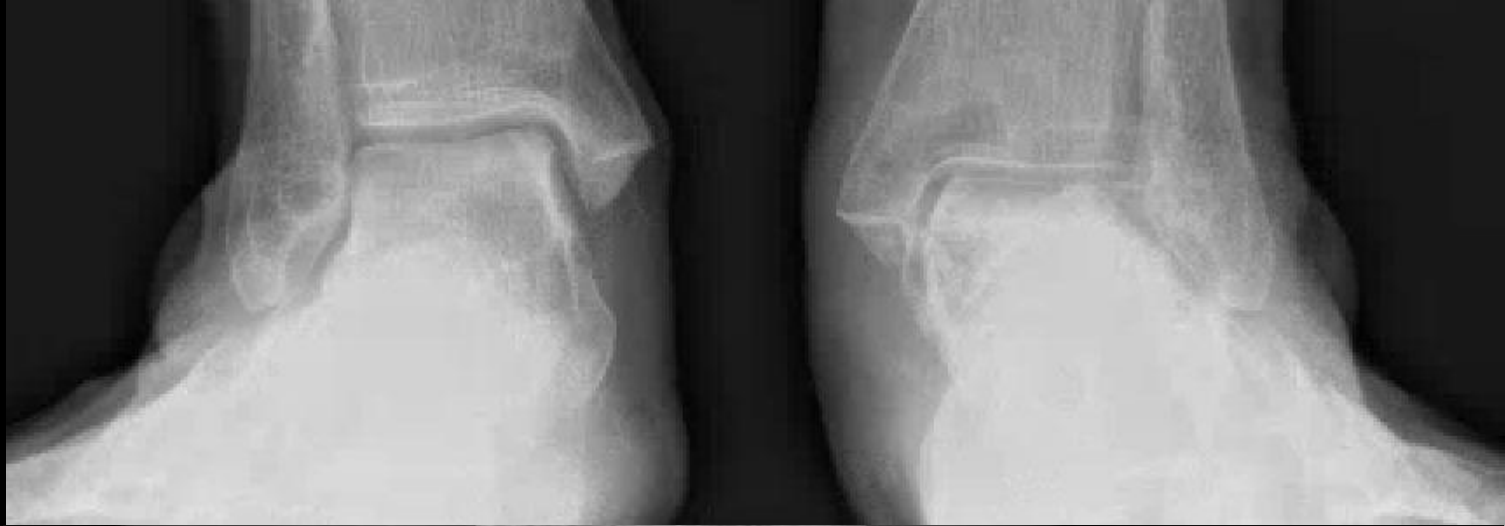The Talus: Avascular Necrosis

24 year old male, history of SLE. No Trauma.



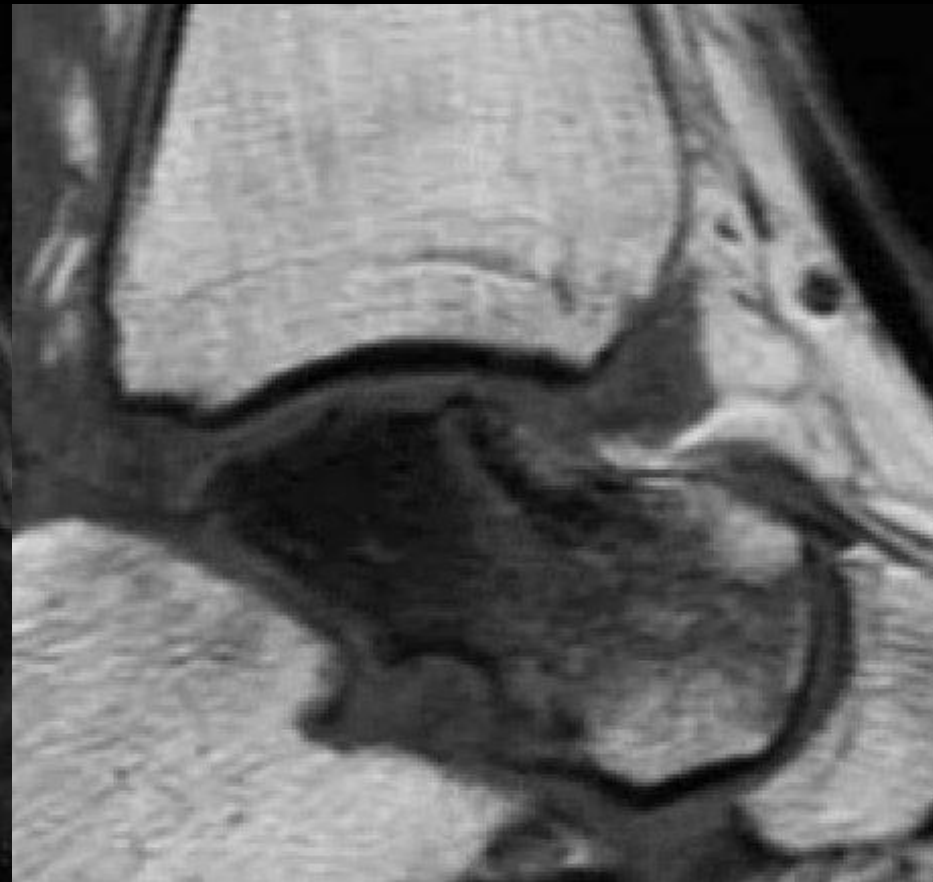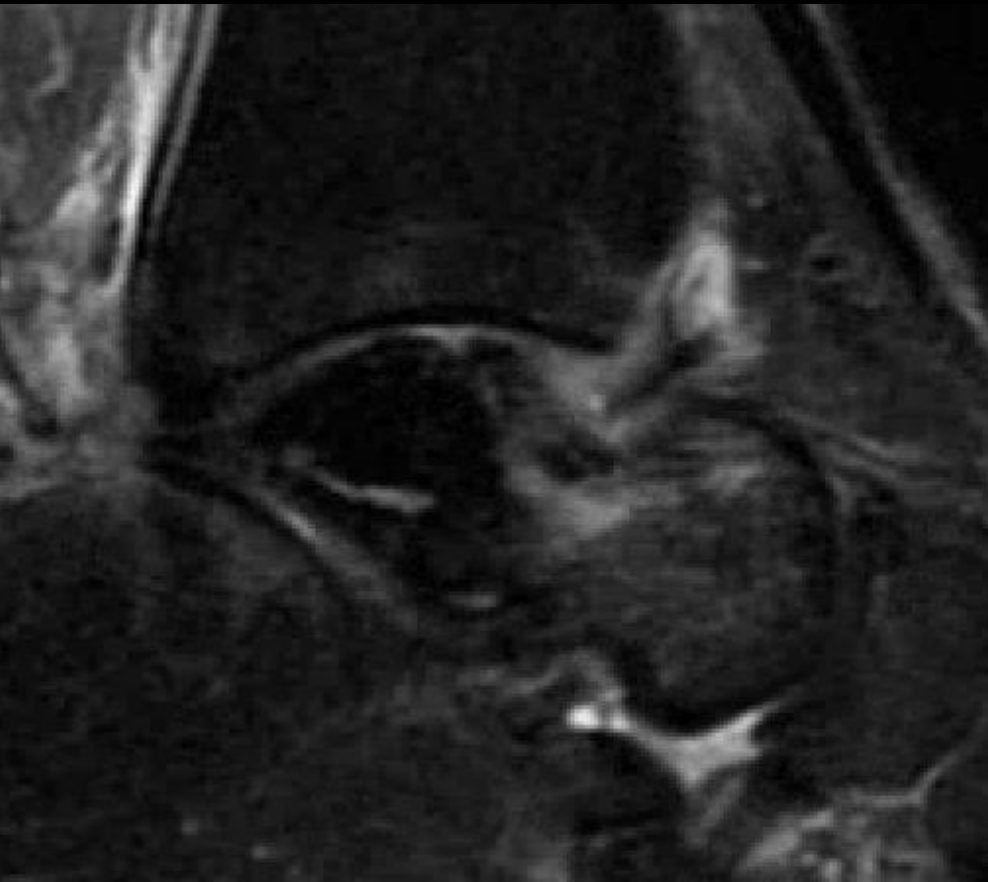
The Talus: Avascular Necrosis

68 year old female, bilateral ankle pain. Obesity. No other risk factors.



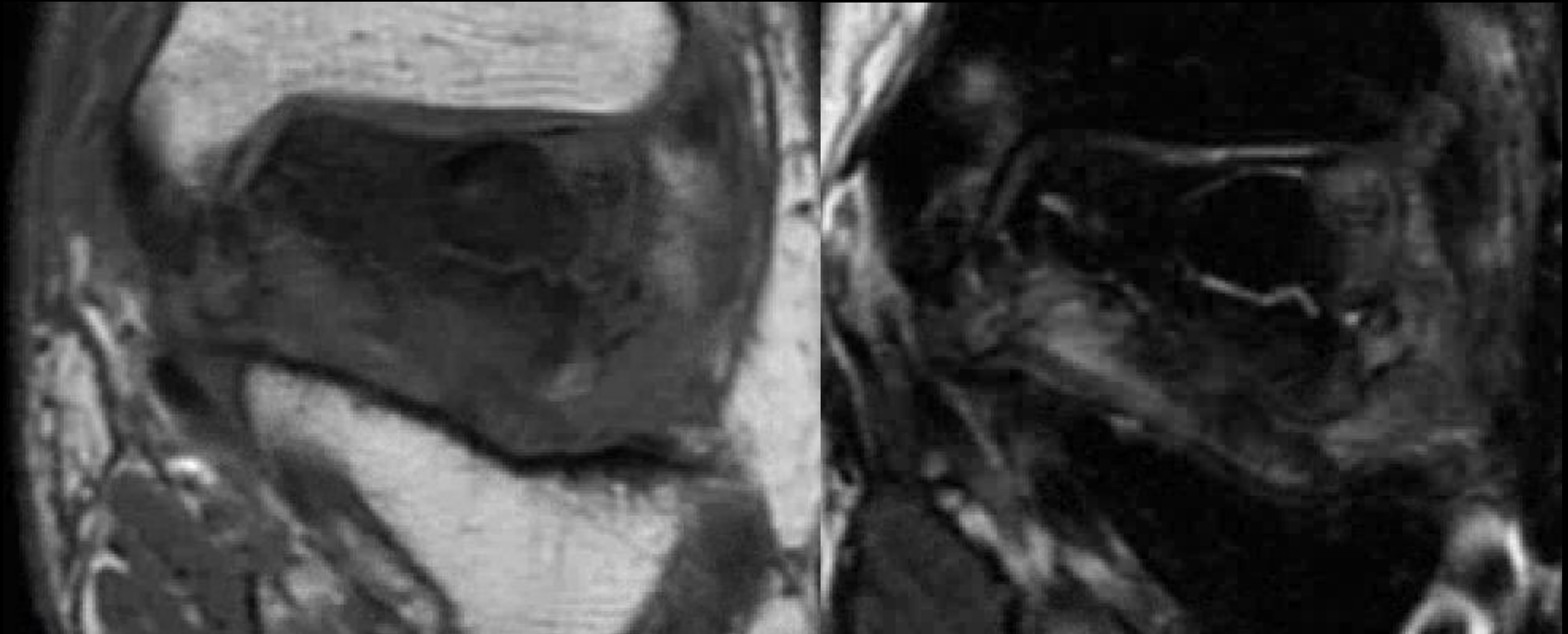
The Talus: Avascular Necrosis

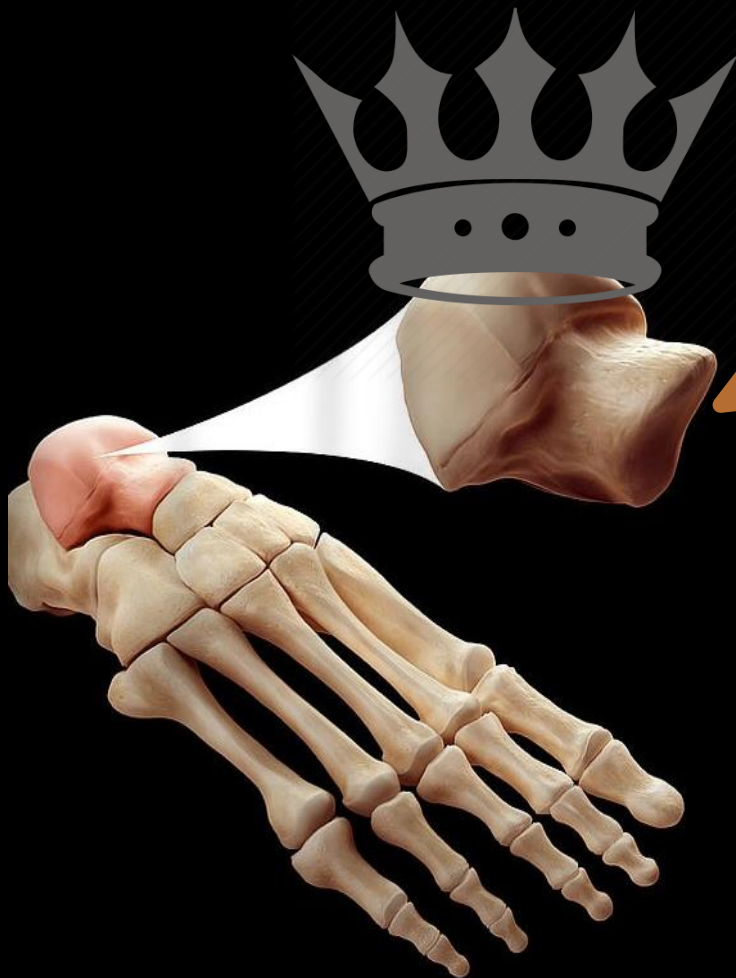68 year old female, bilateral ankle pain. No Trauma.



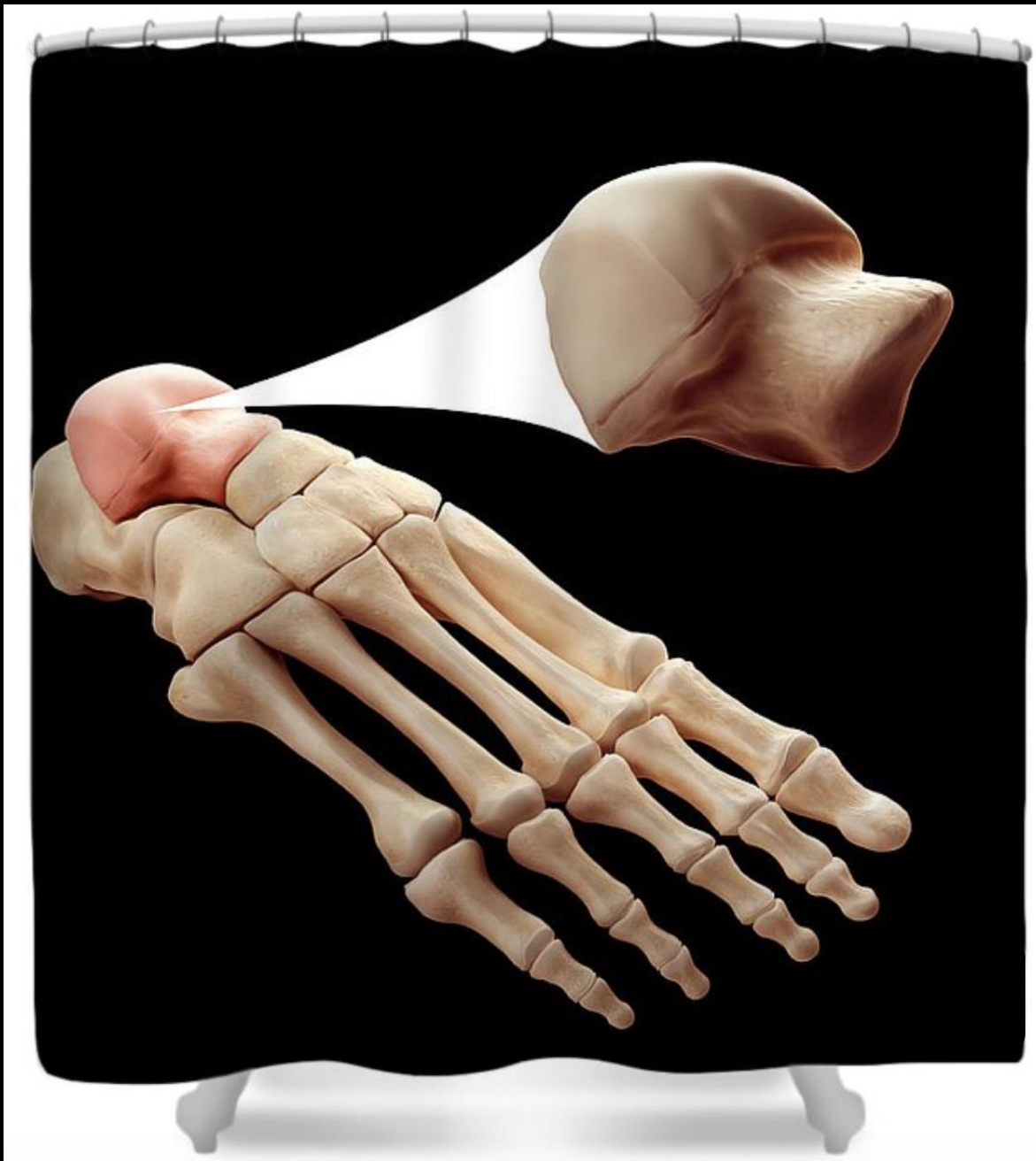
The Talus: Avascular Necrosis

68 year old female, bilateral ankle pain. No Trauma.





*"I, Talus of the House Tarsus,
First of my Name, King of the
Andals and the First Men,
and Lord of the Seven Tarsal
Kingdoms, protector of the
realm END THIS
PRESENTATION."*



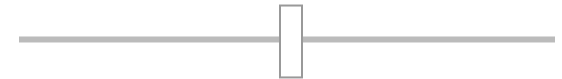Talus Bone Shower Curtain

 by Science Picture Co

\$90.00

ADD TO CART

IMAGE SIZE



DESCRIPTION

Our shower curtains are made from 100% polyester fabric and include 12 holes at the top of the curtain for simple hanging from your own shower curtain rings. The total dimensions of each shower curtain are 71" wide x 74" tall.

SHIPS WITHIN

2 - 3 business days

References

- Martus JE, Femino JE, Caird MS, Hughes RE, Browne RH, Farley FA. Accessory anterolateral facet of the pediatric talus. An anatomic study. *J Bone Joint Surg Am.* 2008;90(11):2452-9.
- Martus JE, Femino JE, Caird MS, Kuhns LR, Craig CL, Farley FA. Accessory anterolateral talar facet as an etiology of painful talocalcaneal impingement in the rigid flatfoot: a new diagnosis. *Iowa Orthop J.* 2008;28:1-8.
- Sewell RB. A Study of the Astragalus. *J Anat Physiol.* 1904;38(Pt 3):233-47.
- Newman JS, Newberg AH. Congenital tarsal coalition: multimodality evaluation with emphasis on CT and MR imaging. *Radiographics.* 2000;20(2):321-32; quiz 526-7, 32.
- Trattnig S, Breitensteiner M, Haller J, Heinz-Peer G, Kukla C, Imhof H. Sinus tarsi syndrome. MRI diagnosis. *Radiologe.* 1995;35(7):463-7.
- Aydingoz U, Melih Topcuoglu O, Gormez A, Cankurtaran T, Dilara Topcuoglu E, Bilge Ergen F. Accessory Anterolateral Talar Facet in Populations With and Without Symptoms: Prevalence and Relevant Associated Ankle MRI Findings. *AJR Am J Roentgenol.* 2016;207(4):846-51.
- Kulik SA, Jr., Clanton TO. Tarsal coalition. *Foot Ankle Int.* 1996;17(5):286-96.
- Linklater J, Hayter CL, Vu D, Tse K. Anatomy of the subtalar joint and imaging of talo-calcaneal coalition. *Skeletal Radiol.* 2009;38(5):437-49.
- Kumar SJ, Guille JT, Lee MS, Couto JC. Osseous and non-osseous coalition of the middle facet of the talocalcaneal joint. *J Bone Joint Surg Am.* 1992;74(4):529-35.
- Moe DC, Choi JJ, Davis KW. Posterior subtalar facet coalition with calcaneal stress fracture. *AJR Am J Roentgenol.* 2006;186(1):259-64.
- Takakura Y, Kumai T, Takaoka T, Tamai S. Tarsal tunnel syndrome caused by coalition associated with a ganglion. *J Bone Joint Surg Br.* 1998;80(1):130-3.
- Jayakumar S, Cowell HR. Rigid flatfoot. *Clin Orthop Relat Res.* 1977(122):77-84.
- Donovan A, Rosenberg ZS. Extraarticular lateral hindfoot impingement with posterior tibial tendon tear: MRI correlation. *AJR Am J Roentgenol.* 2009;193(3):672-8.
- Funk DA, Cass JR, Johnson KA. Acquired adult flat foot secondary to posterior tibial-tendon pathology. *J Bone Joint Surg Am.* 1986;68(1):95-102.
- Gray DJ, Gardner E, O'Rahilly R. The prenatal development of the skeleton and joints of the human hand. *Am J Anat.* 1957;101(2):169-223.

References

- Sarrafian SK. Anatomy of the foot and ankle. 3rd ed. Philadelphia, PA: Lippincott, William and Wilkins; 2011:40-119.
- Conway JJ, Cowell HR. Tarsal coalition: clinical significance and roentgenographic demonstration. Radiology. 1969;92(4):799-811.
- <https://en.wikipedia.org/wiki/Shagai>
- Fritsch, Ann Anat (1996) 178: 455 -4~9
- Anatomy of the talus , Dr Matt Skalski, radiopedia
- <https://slideplayer.com/slide/6198238/>
- *Melenevsky*, RadioGraphics 201
- Talar ridges, osteophytes, and beaks:a radiologic commentary, D. Resnick, 1984, Radiology
- <https://boneandspine.com/blood-supply-of-talus/>
- Pearce, RadioGraphics 2005
- <https://www.orthobullets.com/pediatrics/4066/congenital-vertical-talus>
- Khoshnaw et al, Radiopaedia
- HAVESON, et al Congenital Flatfoot Due to Talonavicular Dislocation (Vertical Talus)
- Donnelly, Pediatric Imaging: The Fundamentals
- Goel et al, Radiopaedia
- Yun, et. al, AJR:205, December 2015
- Burdett, Tarsal Coalition, Radsourc
- Moe et al. AJR:186, January 2006
- Petchprapa, et al
- Pediatr Radiol (2016) 46:1142–1149
- Talonavicular Coalition Macera et al. 2017
- Case courtesy of Karine Morche, Radiopaedia.org, rID: 68160
- <http://radsourc.us/stress-fractures-foot-ankle/>
- Pearce, **RadioGraphics 2005**

