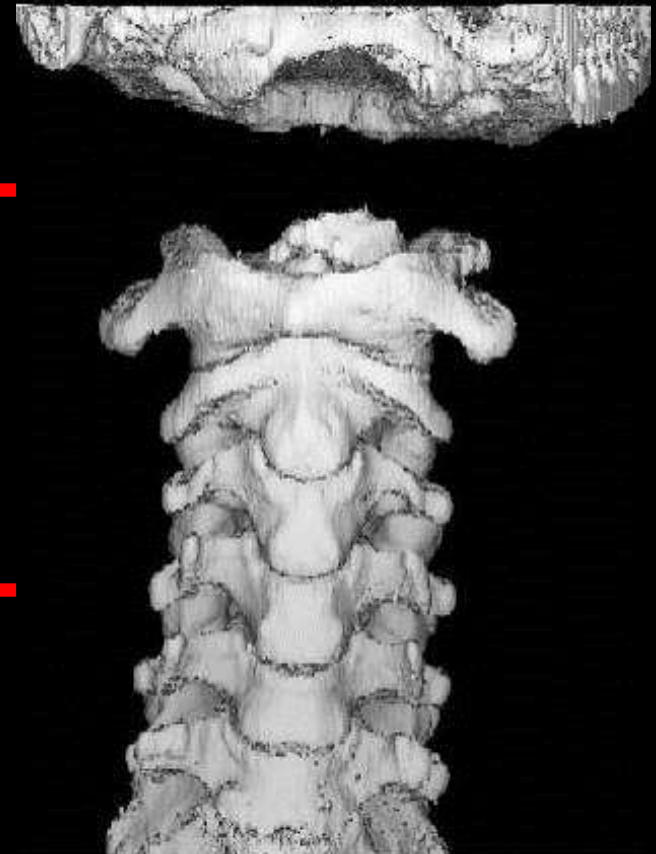




Cervical Spine Trauma

Dr. Tudor H. Hughes M.D., FRCR
Department of Radiology
University of California School of Medicine
San Diego, California



Trauma Cx Spine Protocols

- Issues
 - The clinically negative Cx-spine
 - Does everyone need a CT
 - Flex/Ext
 - Acute Flex/Ext in alert patients with a painful neck, negative x-rays
 - Supine
 - Fluoro Flex/Ext in obtunded patients
 - What is Instability

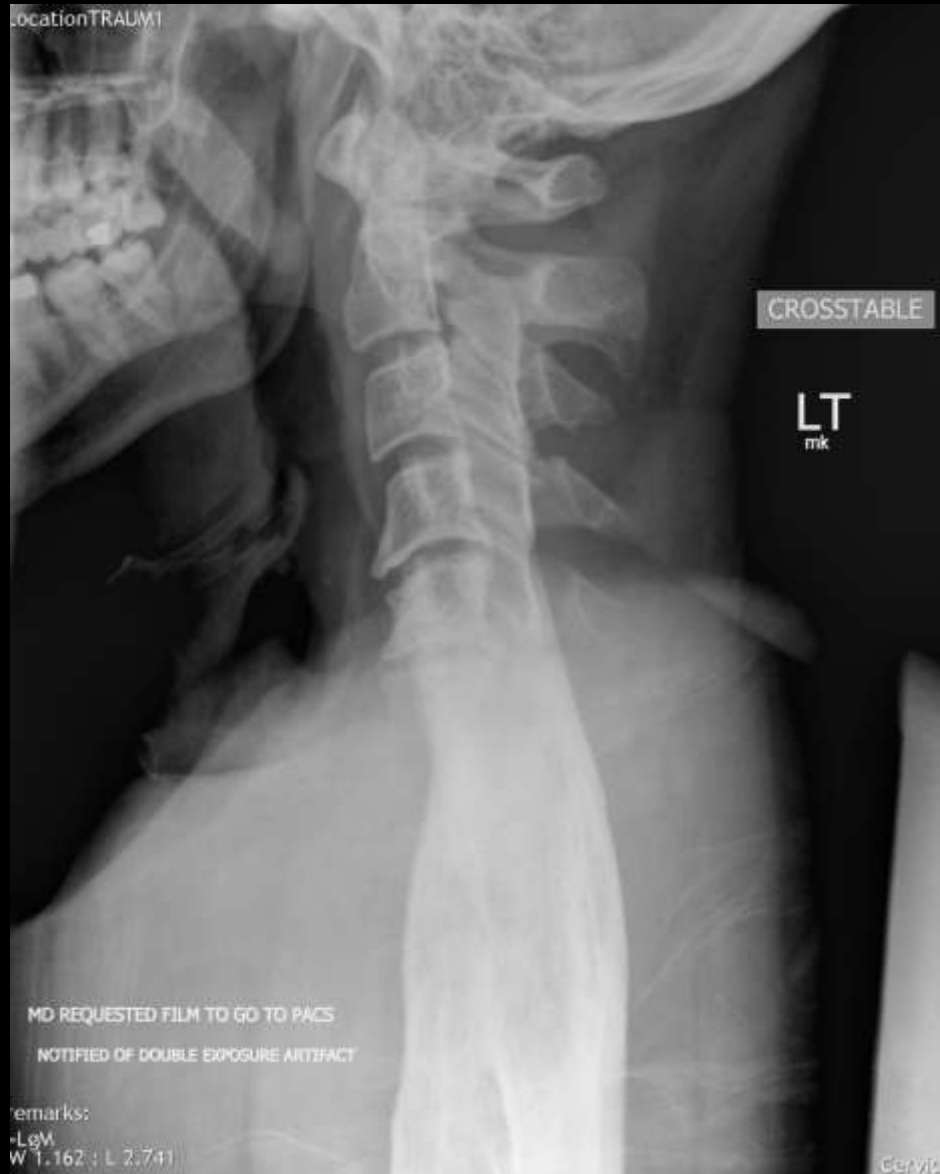Who to Image

- CCR and Nexus
 - CCR more sensitive and specific
 - CCR criteria more complicated

How to Image

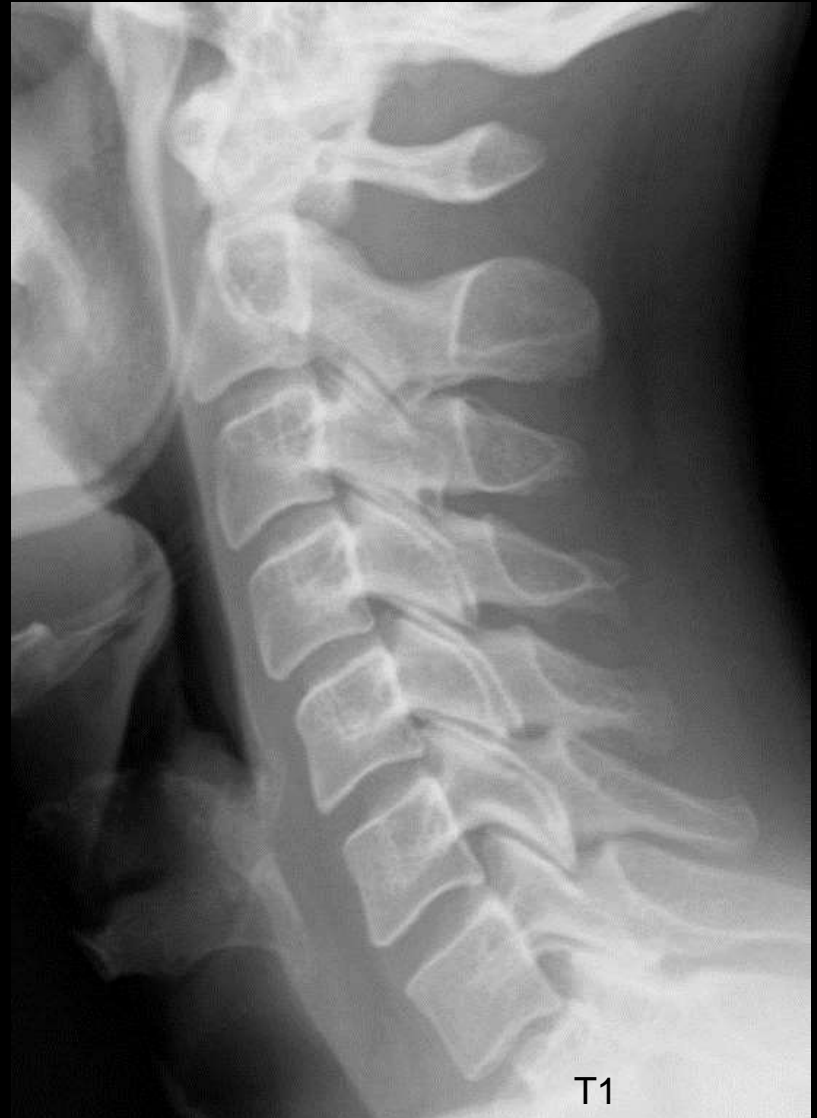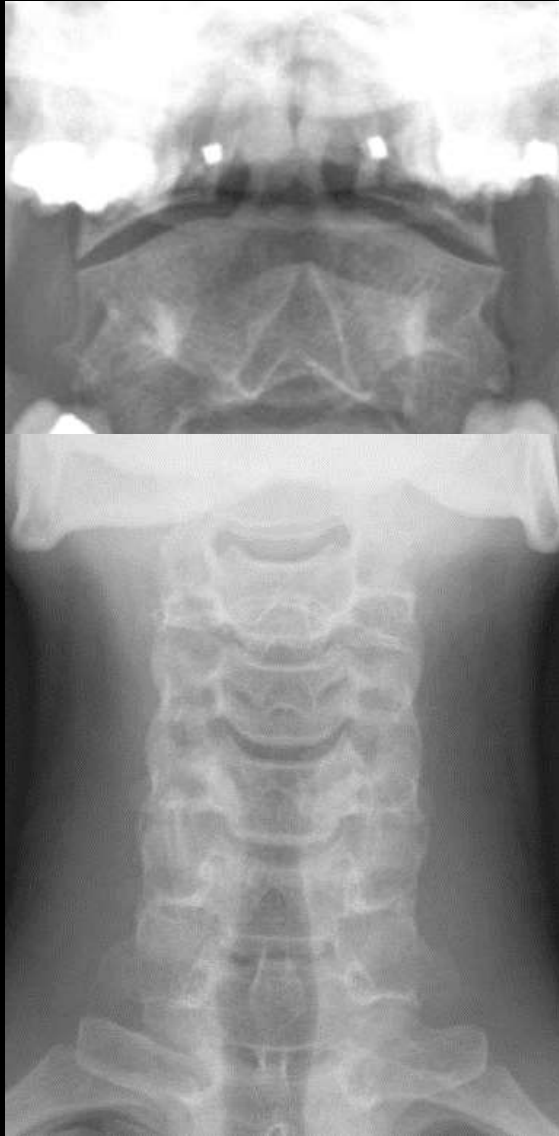- Alert, but tender
 - 3 view Cx spine
 - +/- Swimmers, Fuchs, Trauma obliques
- 39% of Cx spine injuries not seen on plain films - NEXUS
- Head injury – having head CT
 - CT Cx
 - 1.25mm cuts (or less) base of skull to T1
 - Minimal reconstructions prior to reformats
 - Bone and ST algorithms
 - Reformats in sagittal and coronal planes

Technique

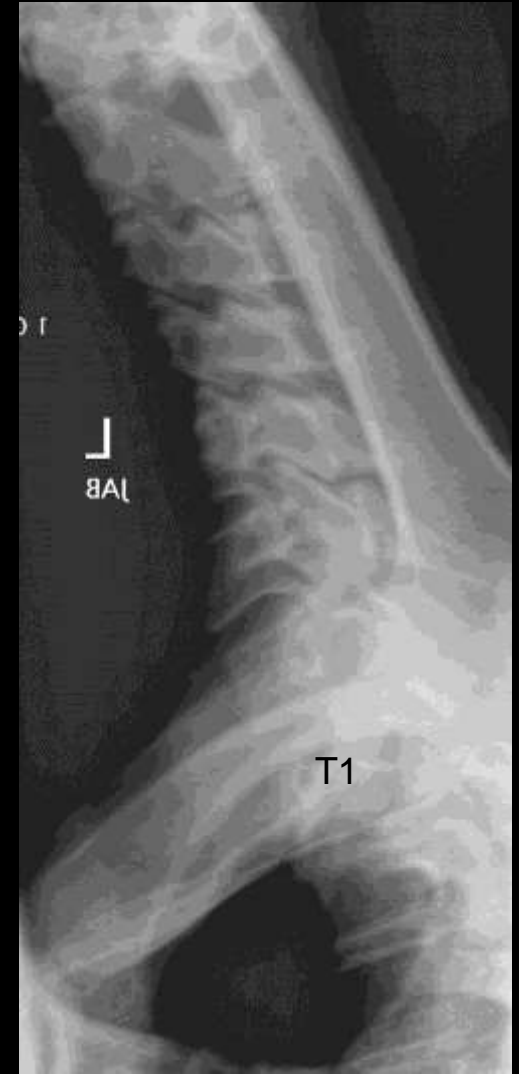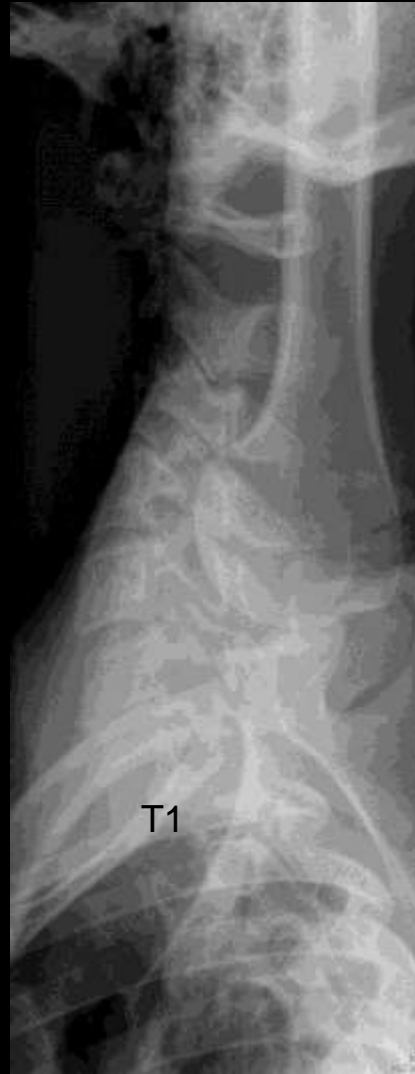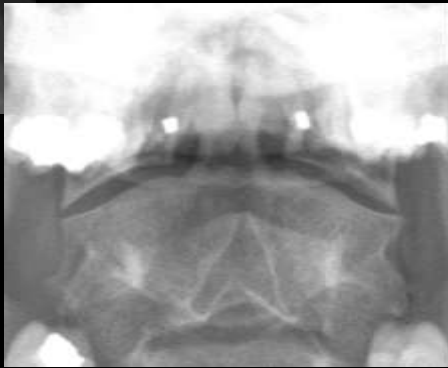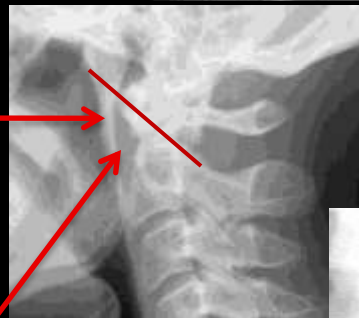


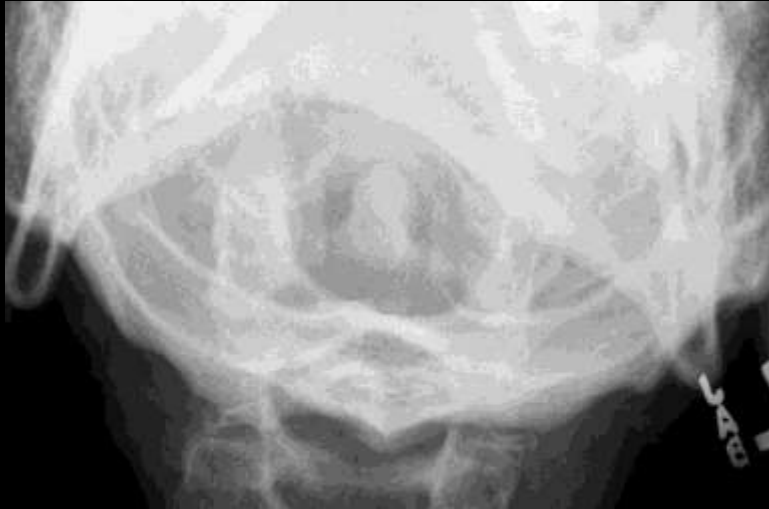Double exposure Cx spine

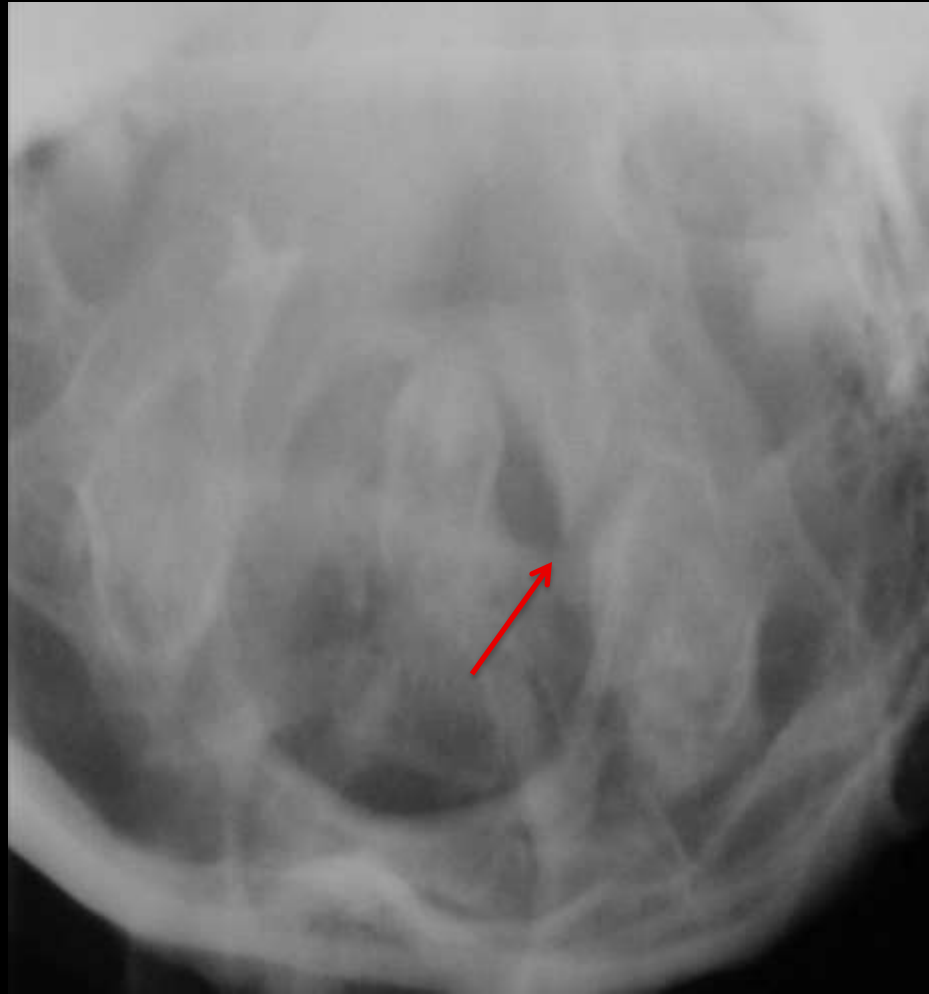Technique - Routine



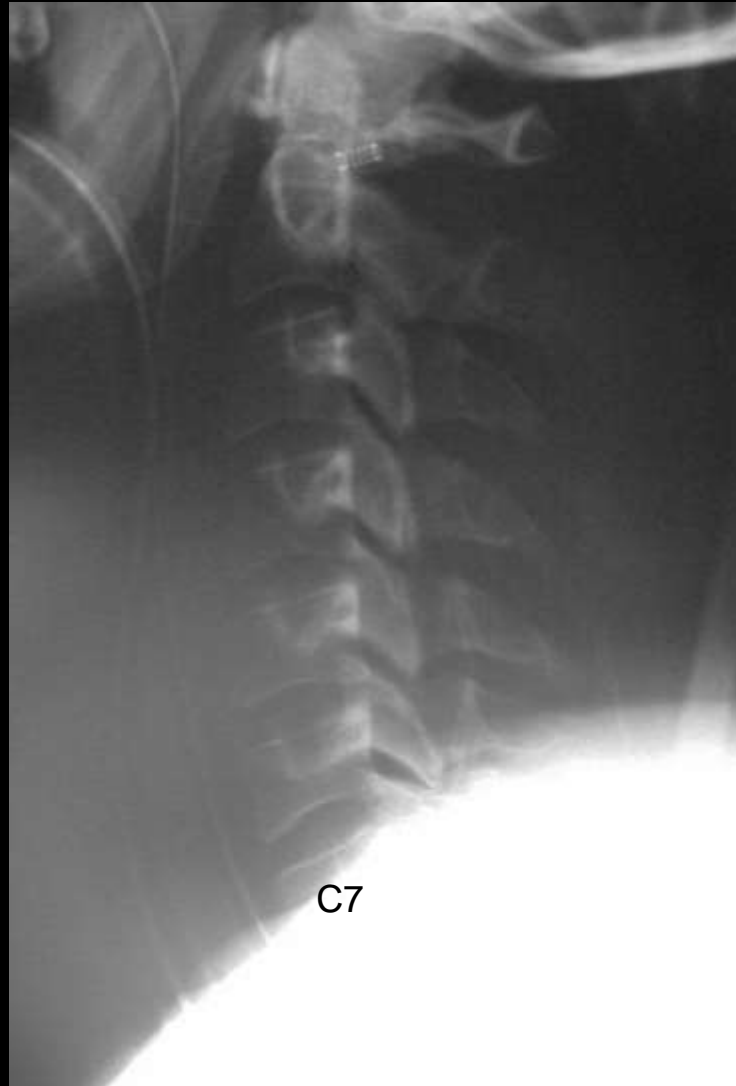Technique - Routine



Technique - Fuch's

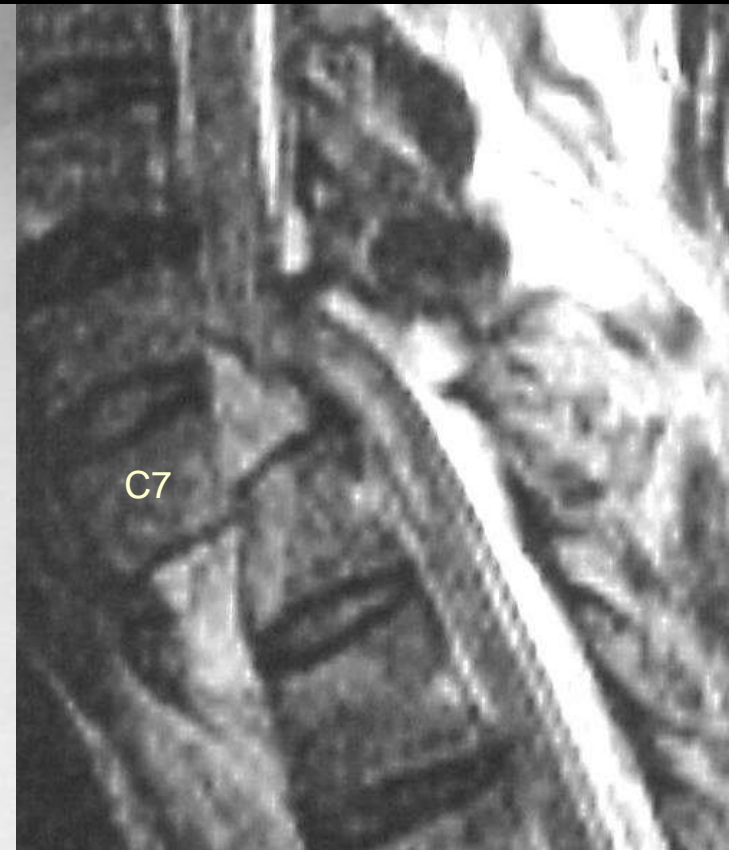
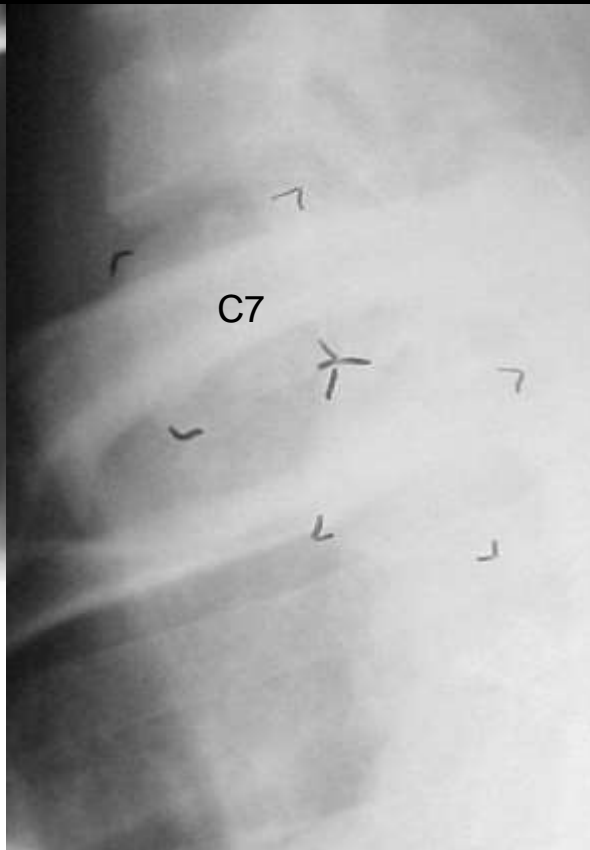
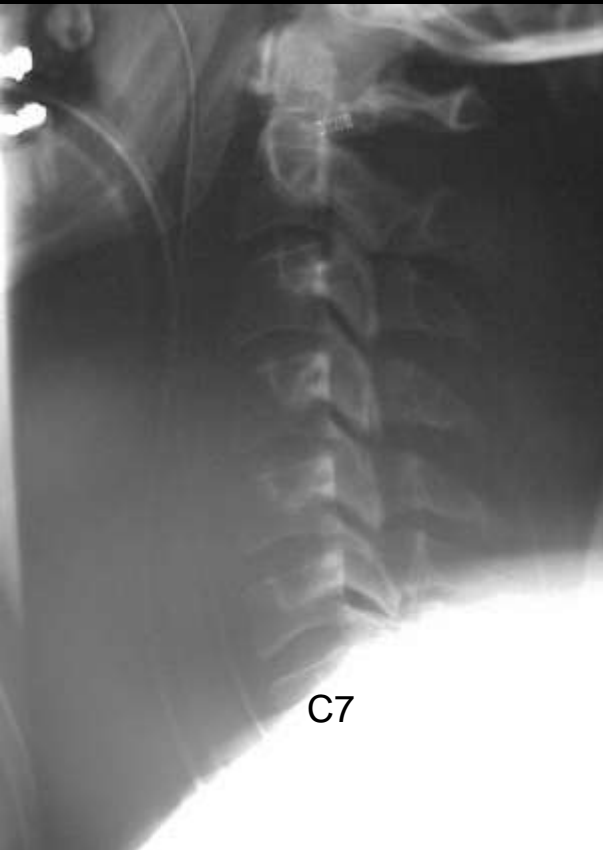Technique - Trauma



30M MVA Thought to be paraplegic

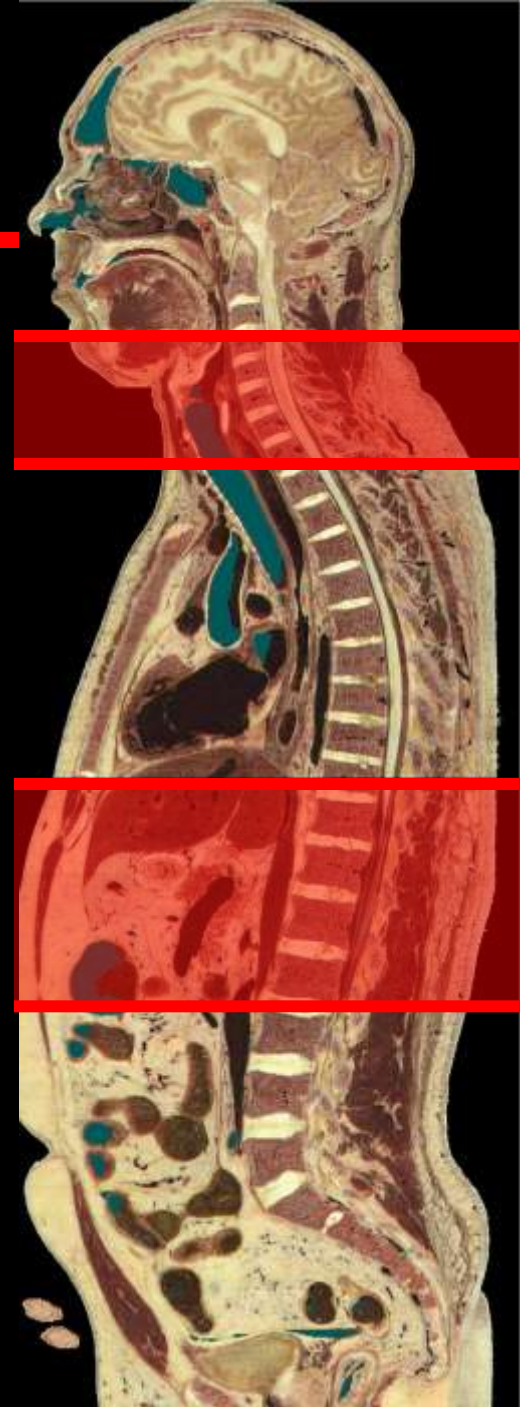
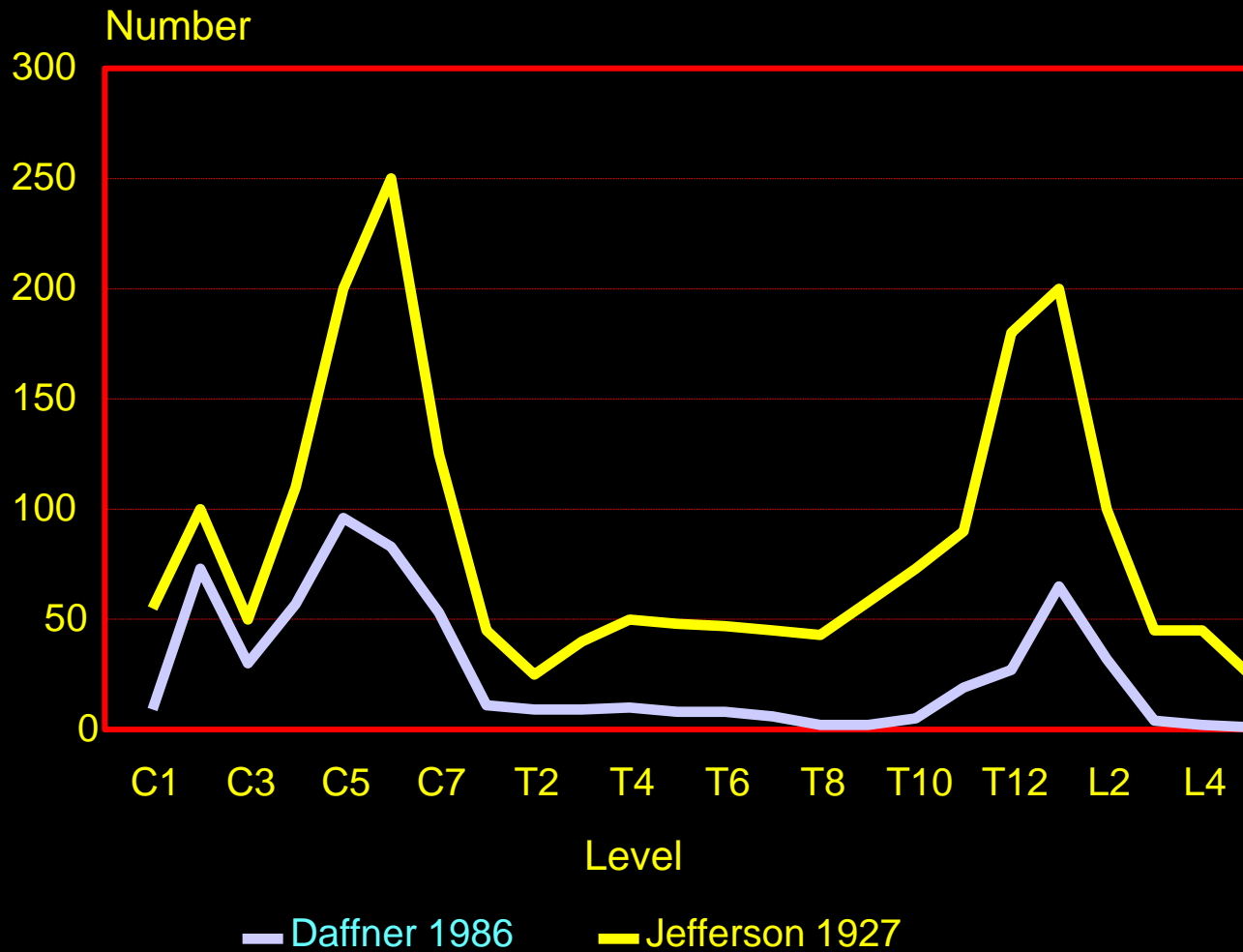
Need to see T1



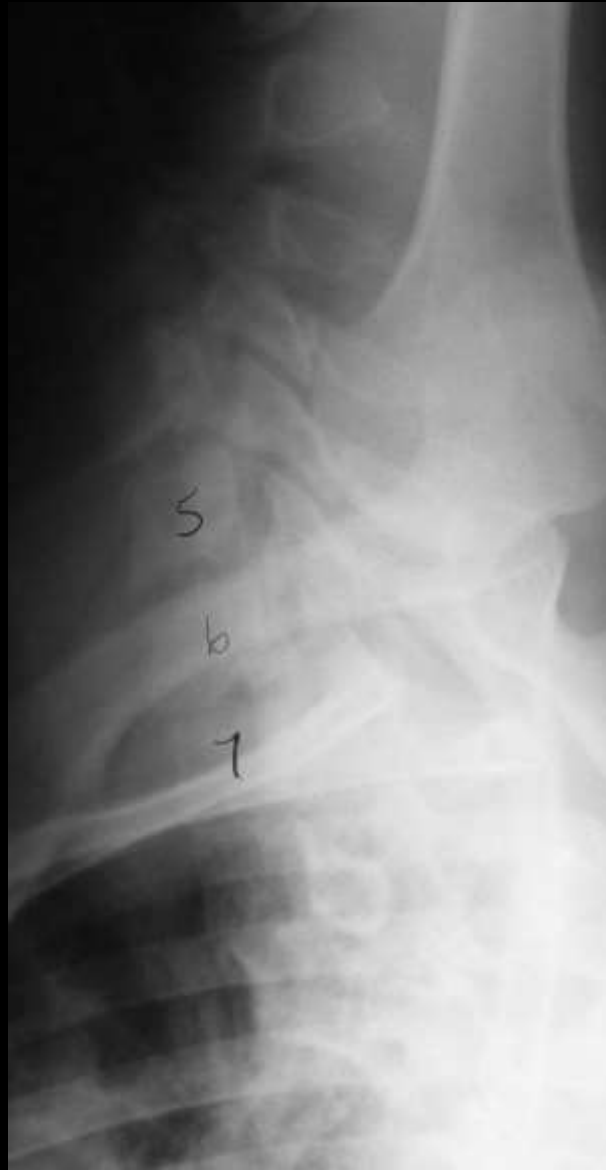Top 10 Missed Fractures

- 1. Base of skull
- 2. Odontoid process
- 3. Zygomatic arch and orbit
- 4. C7 Fracture dislocation
- 5. Posterior dislocation of humerus
- 6. Scaphoid, lunate and perilunar dislocation
- 7. Sacroiliac fractures
- 8. Undisplaced neck of femur
- 9. Dislocated hip with ipsilateral femoral fracture
- 10. Tibial plateau fractures

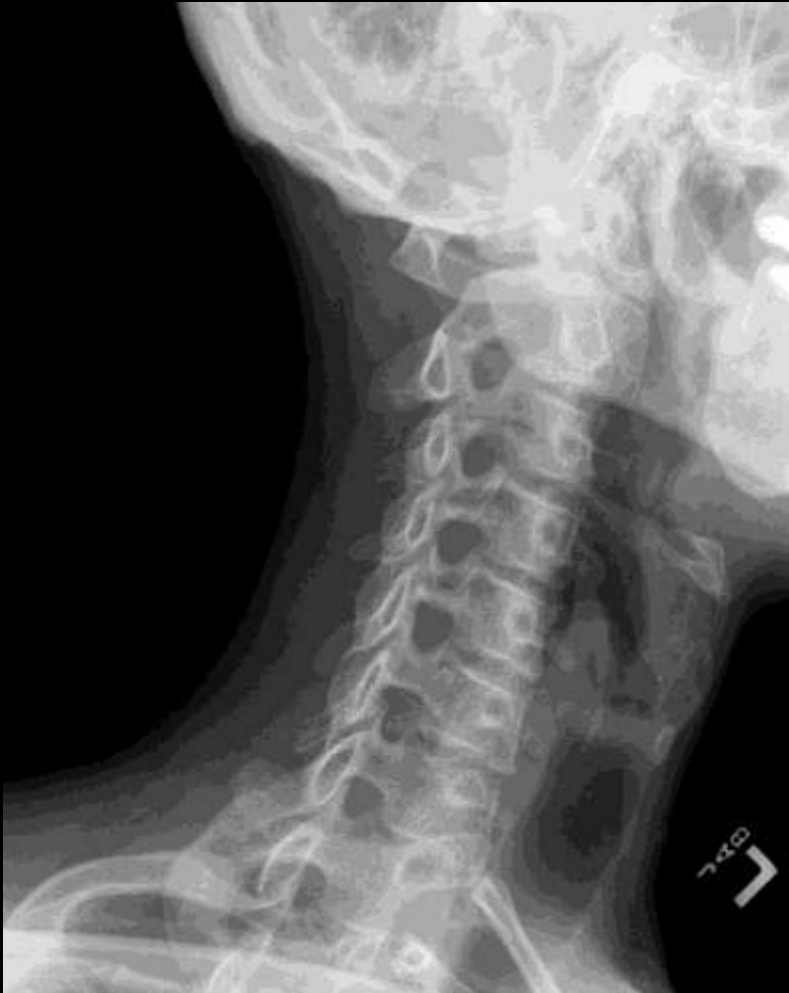Spinal trauma



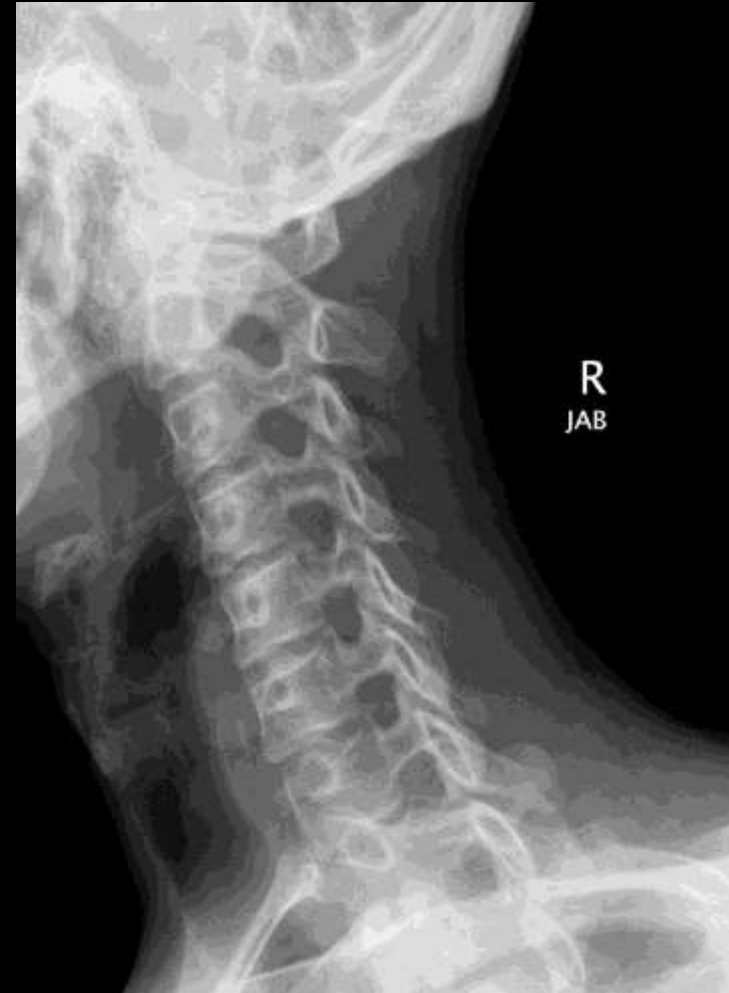Technique - Swimmers View



Technique - Routine

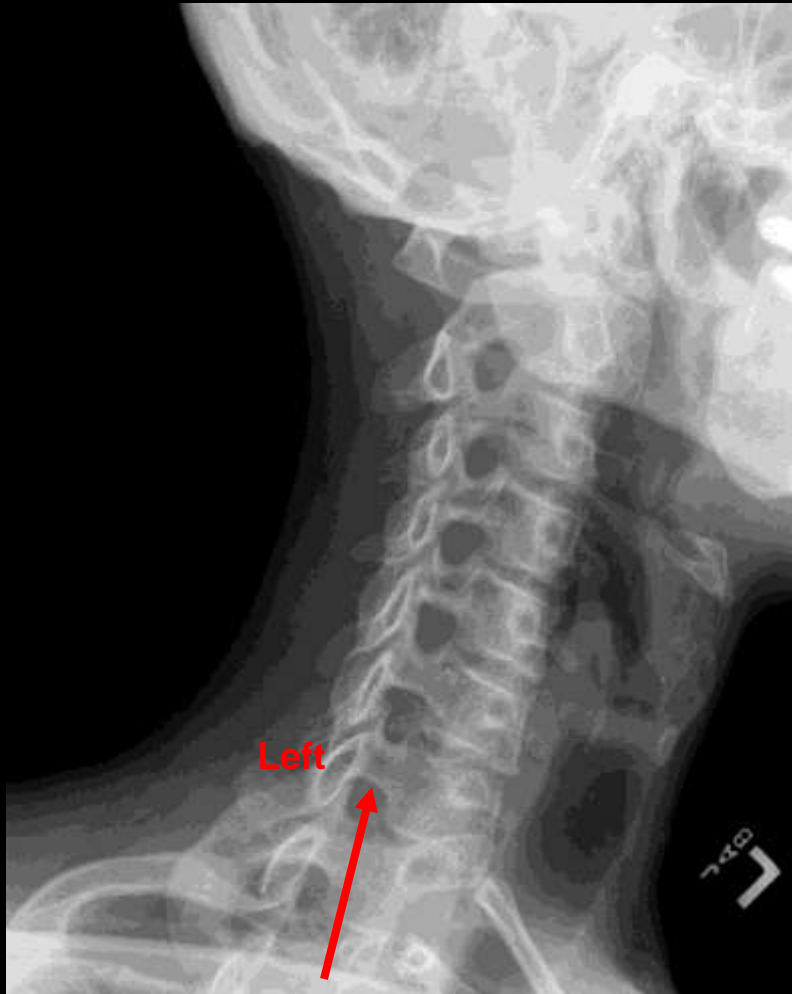

LAO or LPO

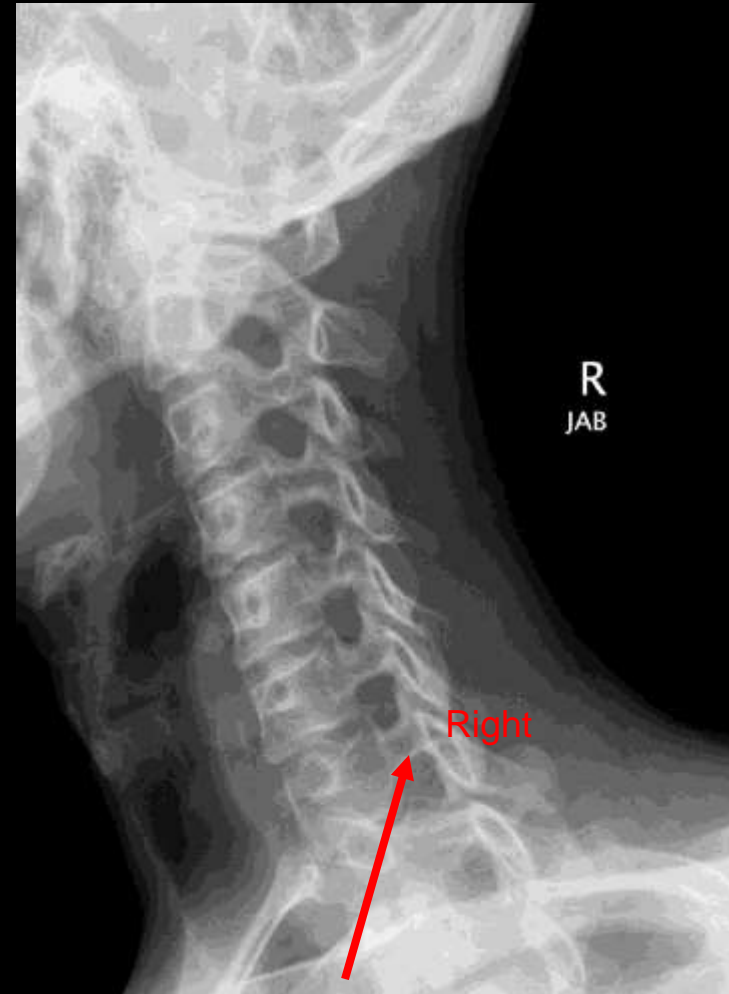


RAO or RPO

Technique - Routine

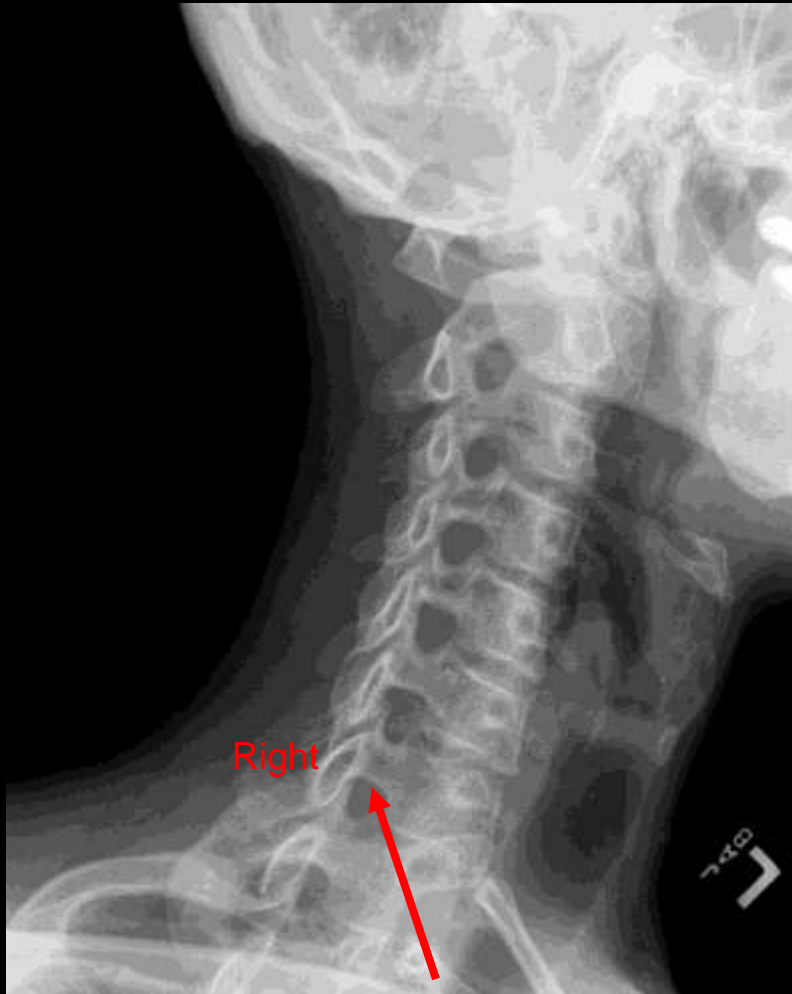

LAO or LPO

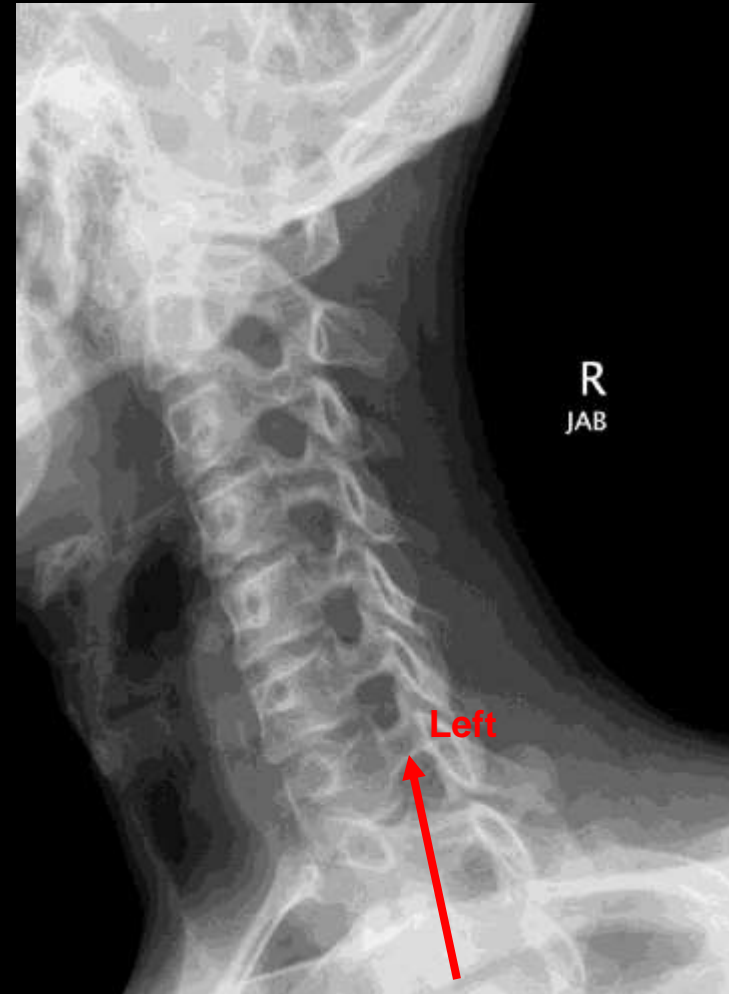


RAO or RPO

Technique - Routine



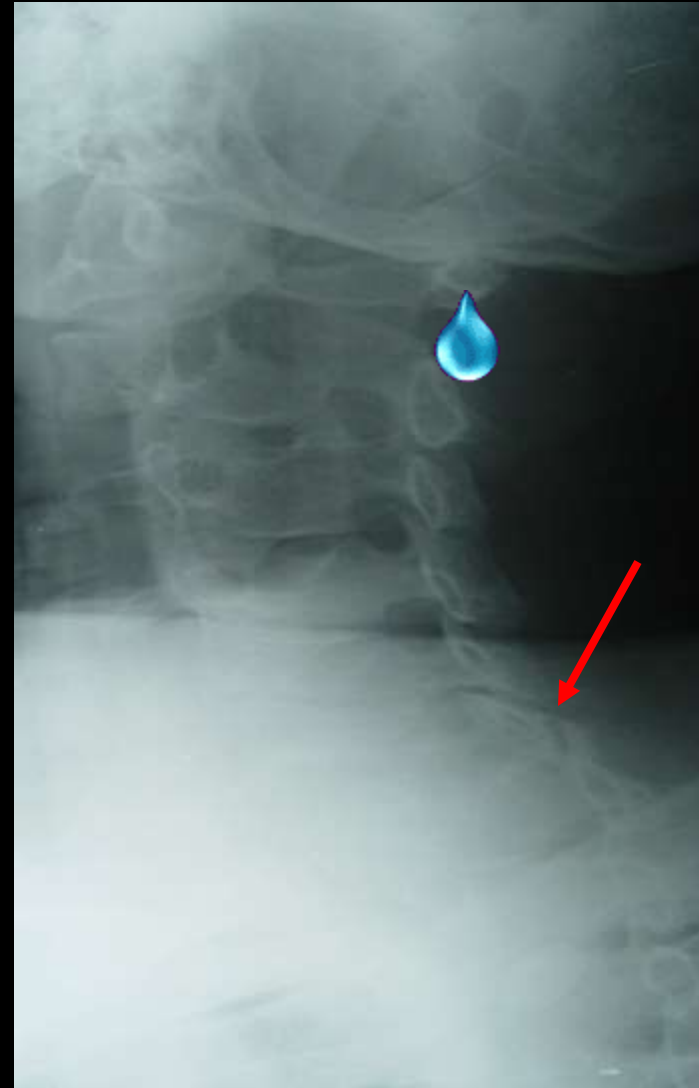
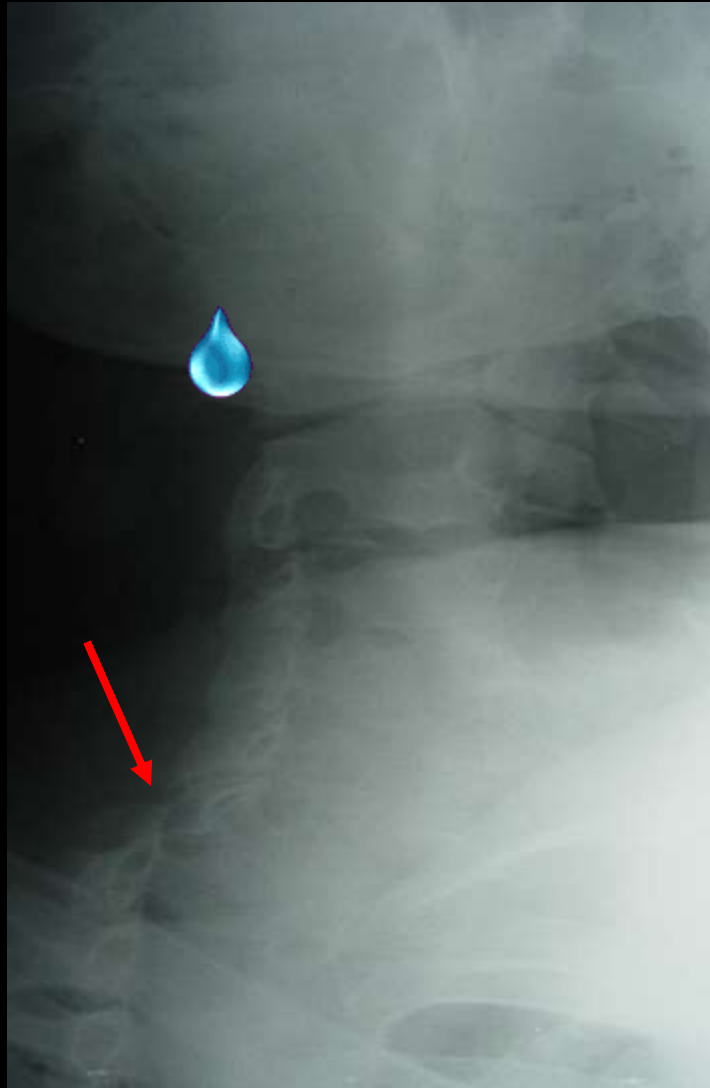LAO or LPO



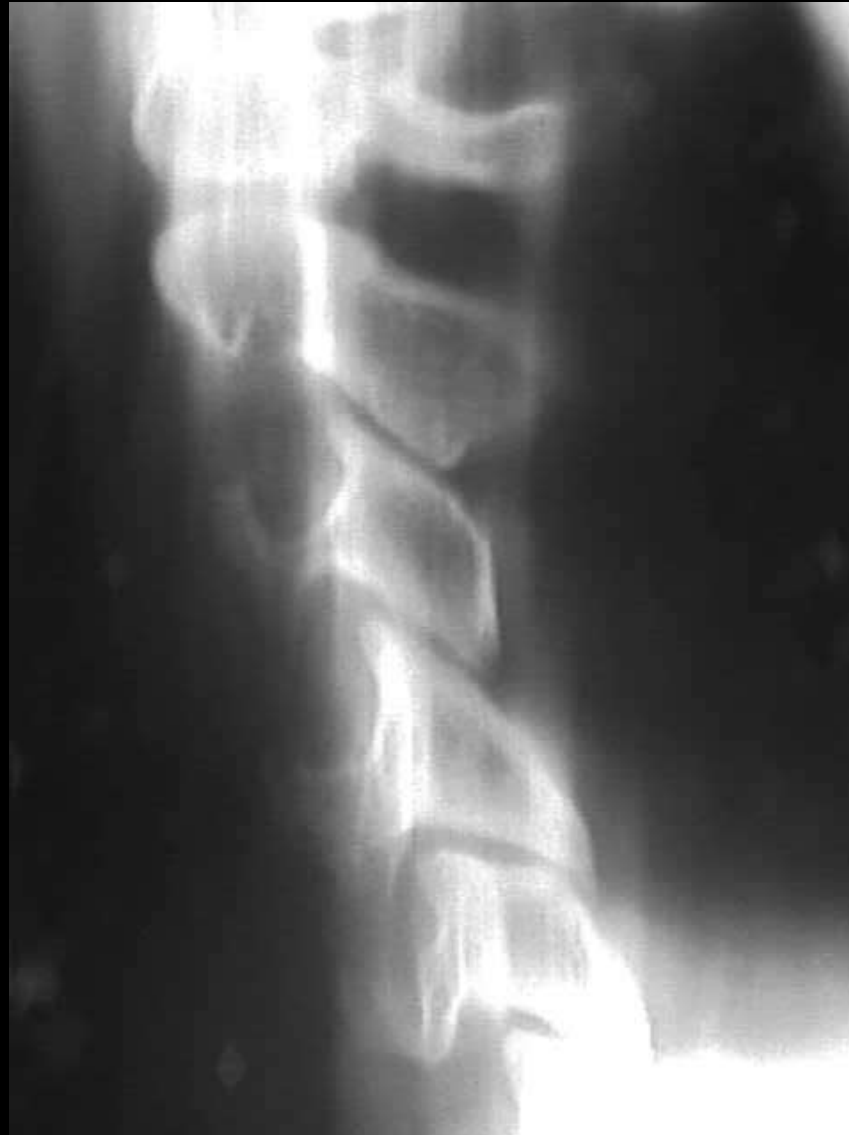RAO or RPO

Lead or digital

Trauma Obliques

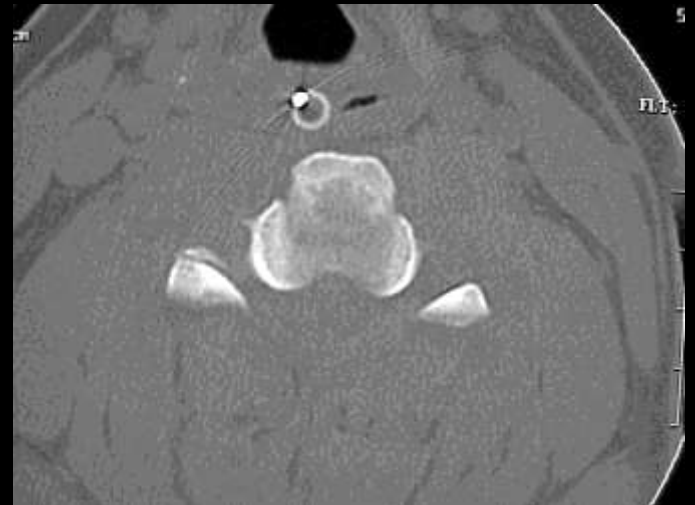


Technique - Tomography



Technique - CT

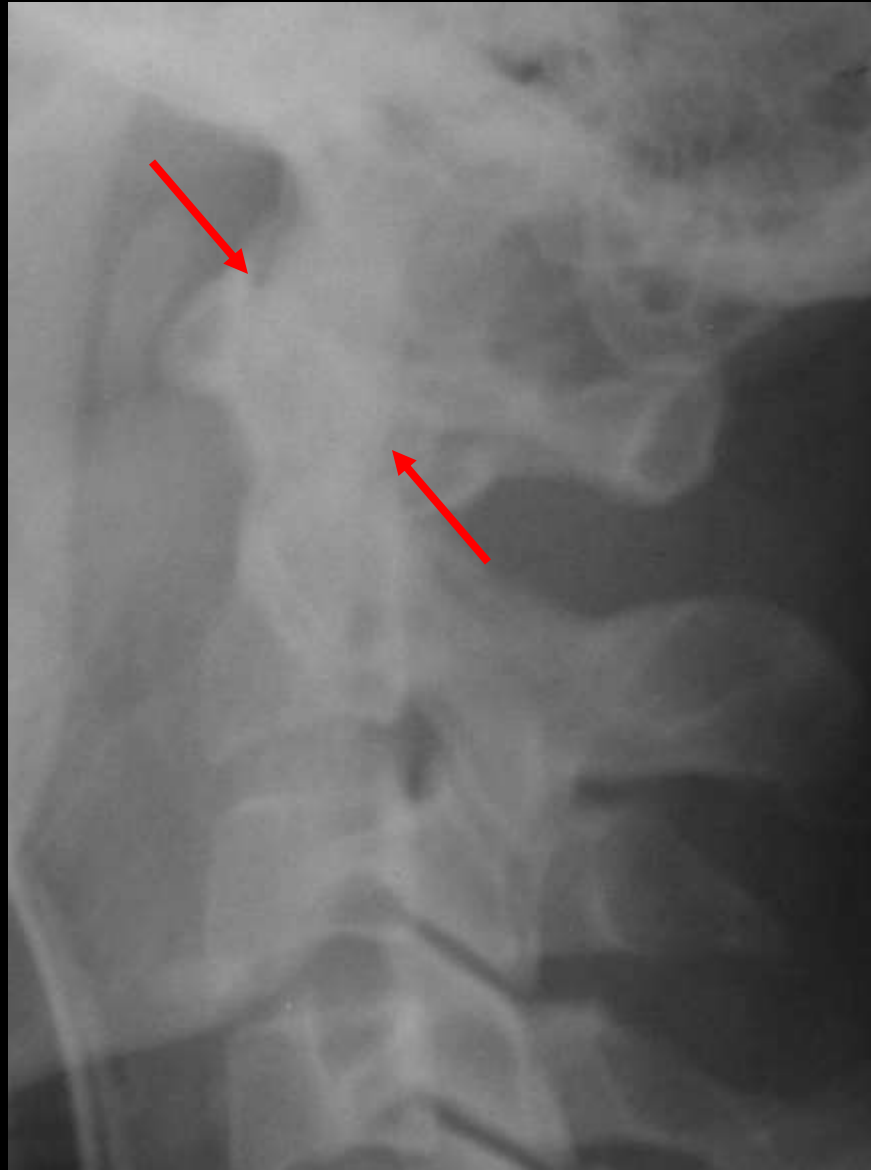- Excellent visualization of fractures
- Must be optimized
 - Volumetric acquisition
 - Thin slices 0.5 - 0.625 - 1.25mm
 - Bone and soft tissue algorithm / window
 - Orthogonal planes
 - Thin recons
 - Use workstation
 - 3D for alignment



Bifacet Dislocation

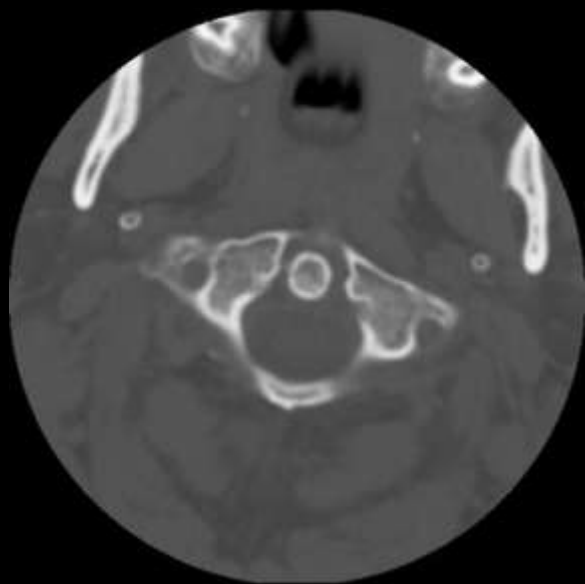
Optimizing CT

Type II Odontoid Fracture

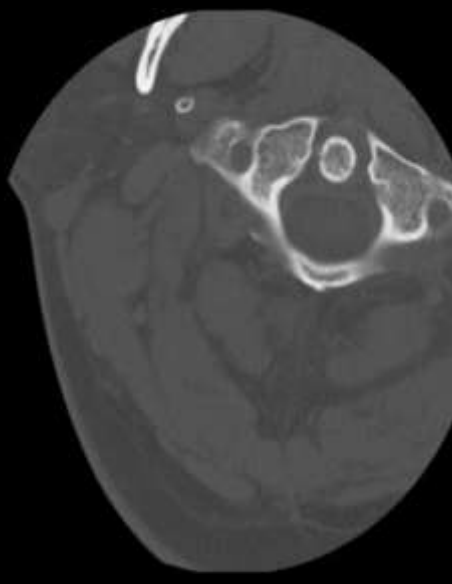


Optimizing CT

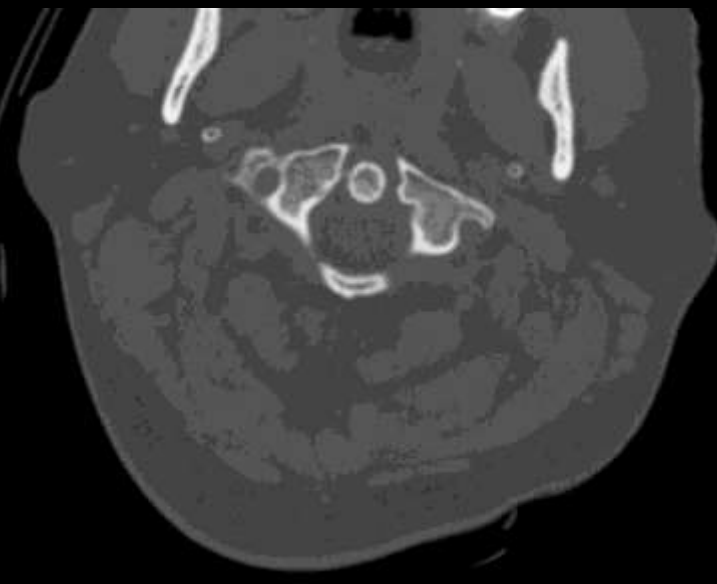
Type II Odontoid Fracture



2.5mm Standard algorithm



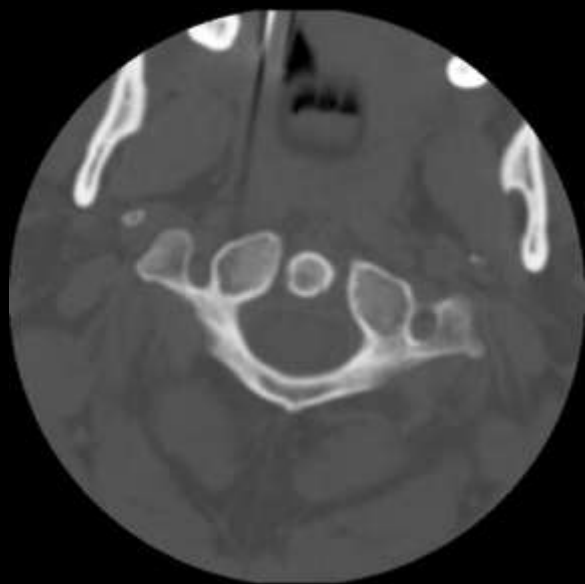
2.5mm Bone



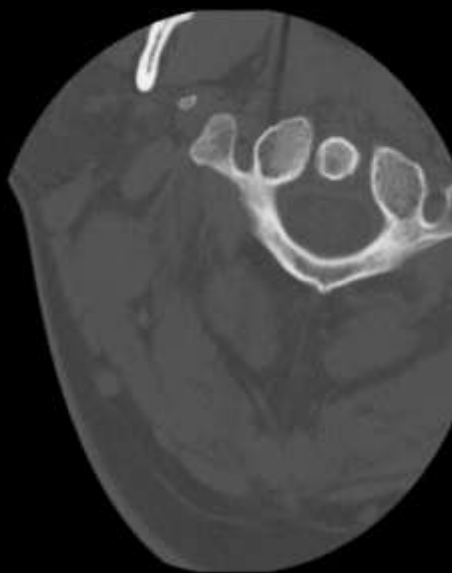
1.25mm Bone

Optimizing CT

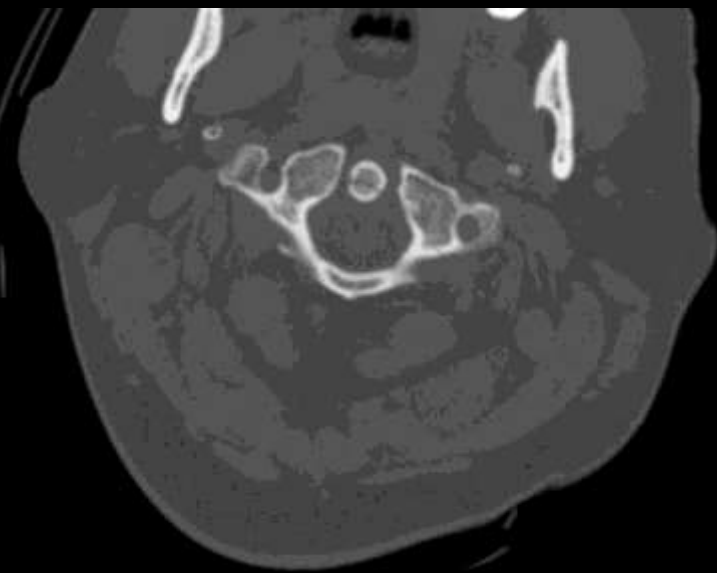
Type II Odontoid Fracture



2.5mm Standard algorithm



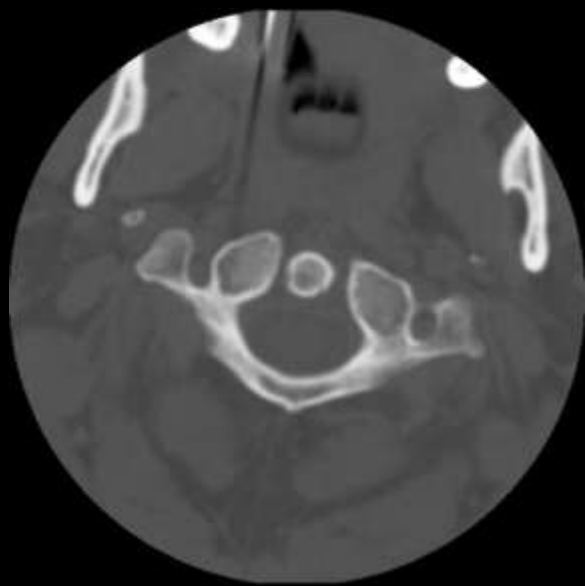
2.5mm Bone



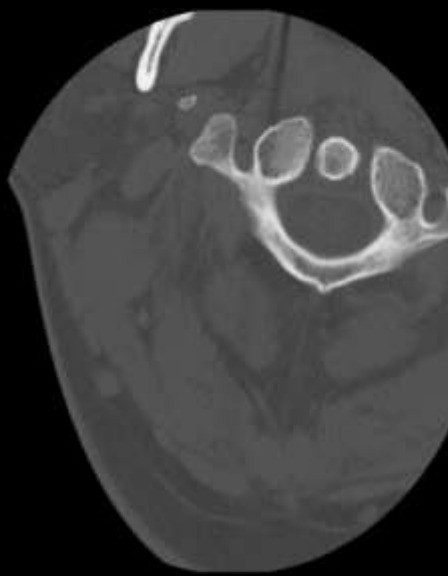
1.25mm Bone

Optimizing CT

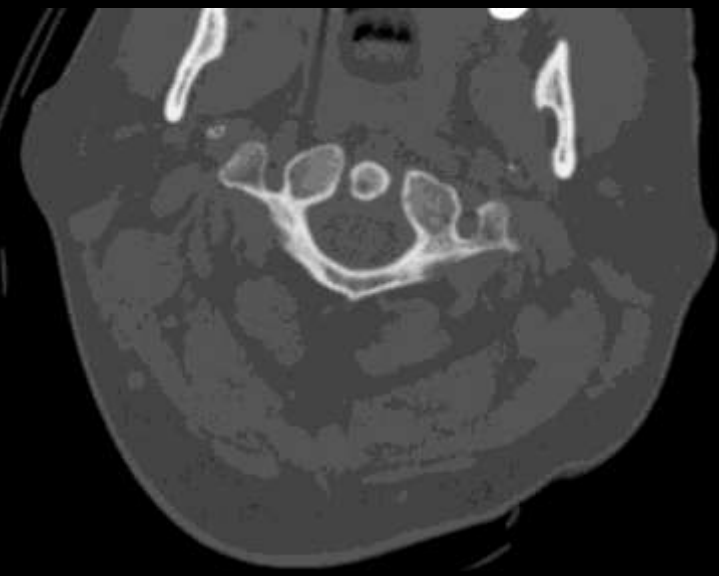
Type II Odontoid Fracture



2.5mm Standard algorithm



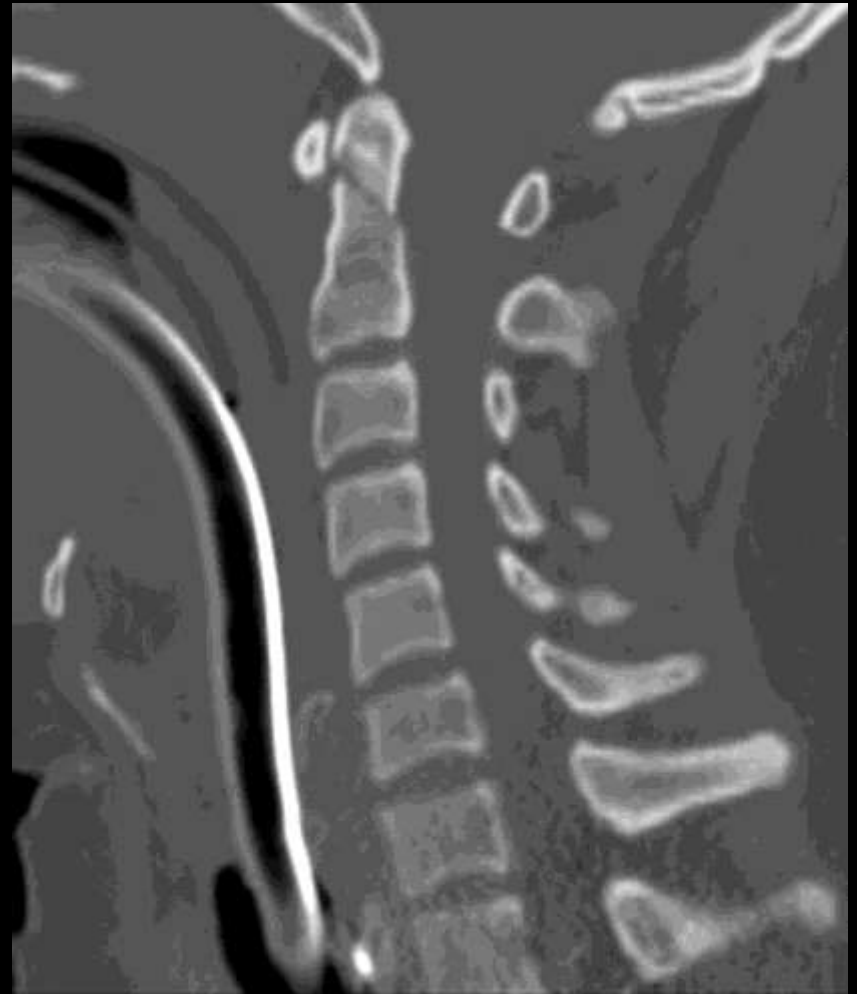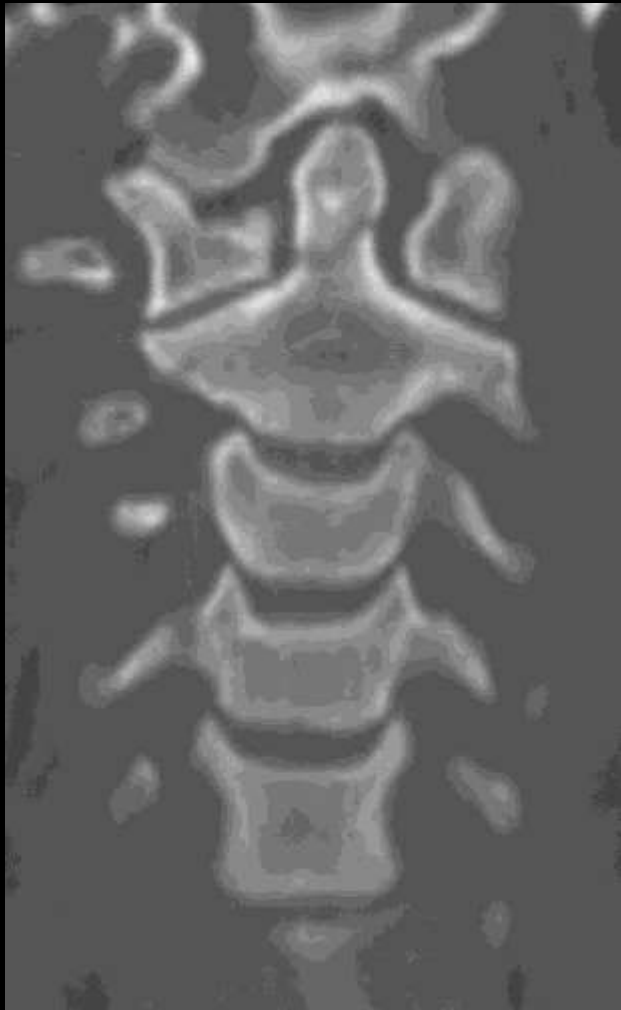2.5mm Bone



1.25mm Bone

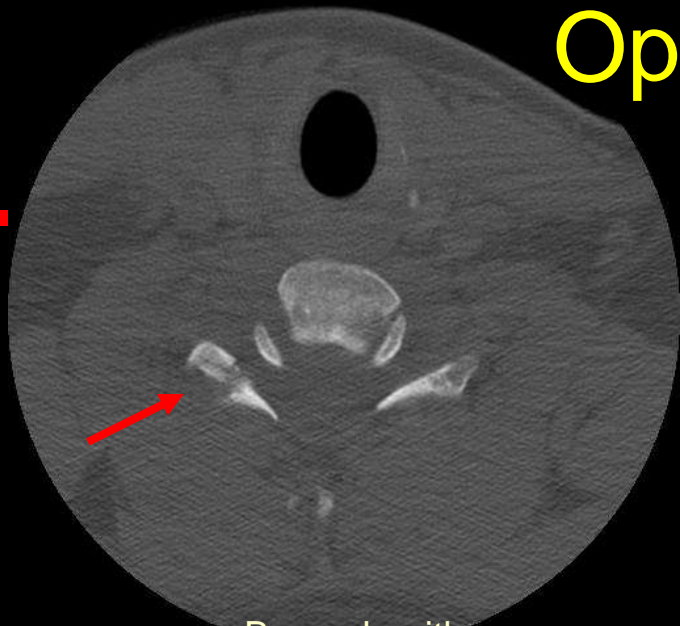
Optimizing CT

Type II Odontoid Fracture

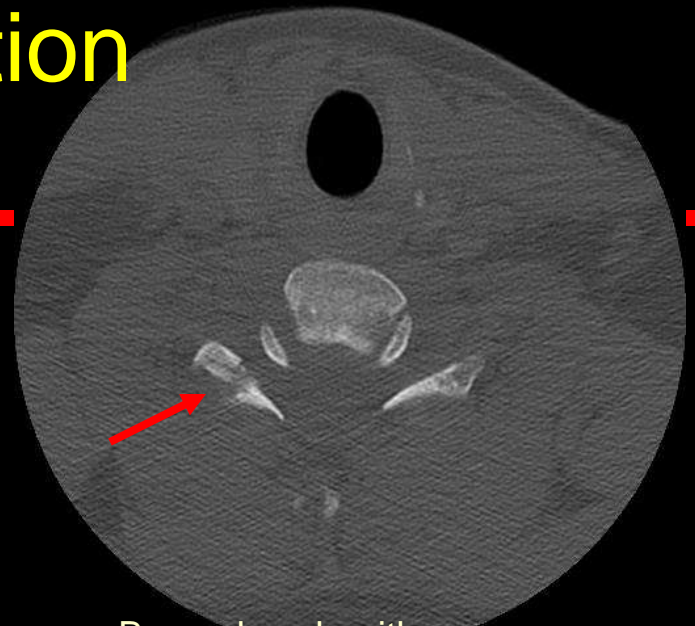


Made from 1.25mm standard algorithm

Optimization C7 Fx

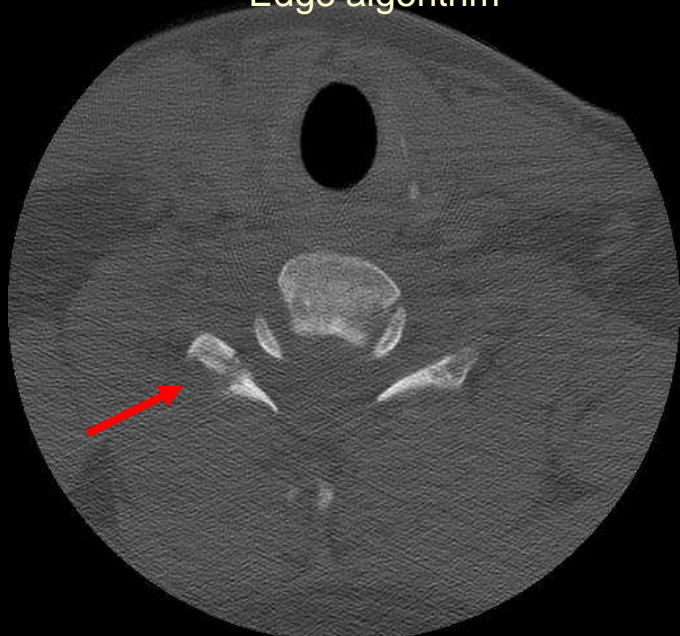


Bone algorithm

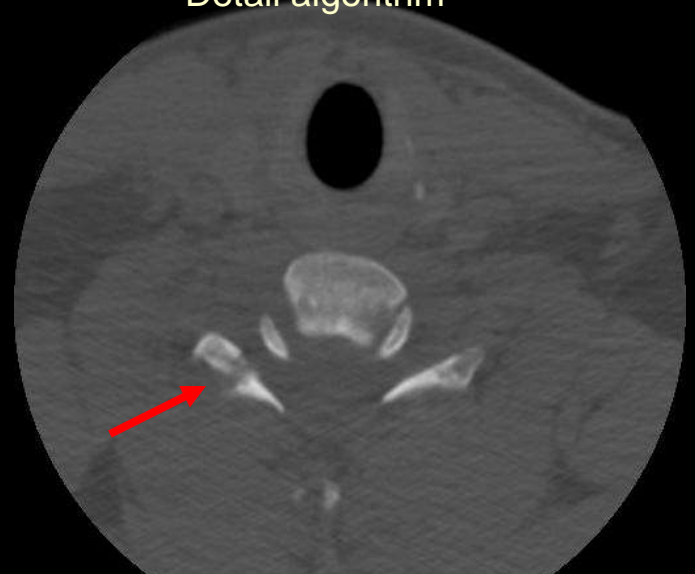


Bone plus algorithm

All bone window/level 2000/500 and 1.3mm thick



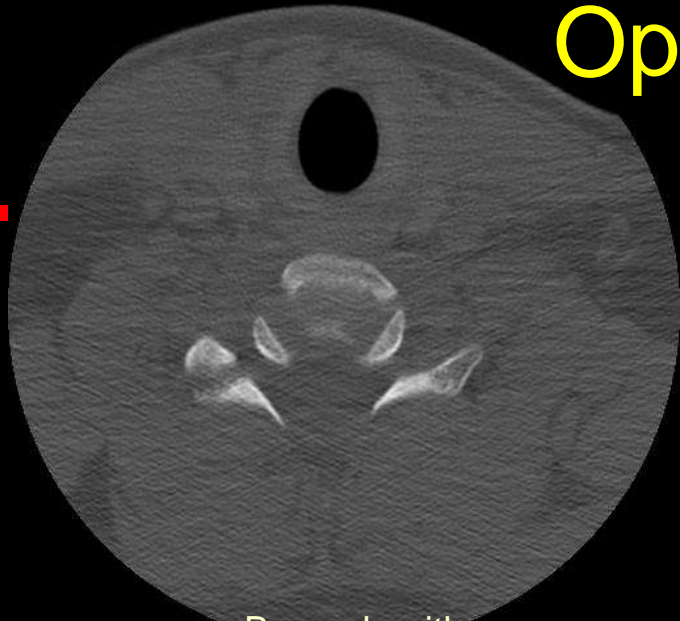
Edge algorithm



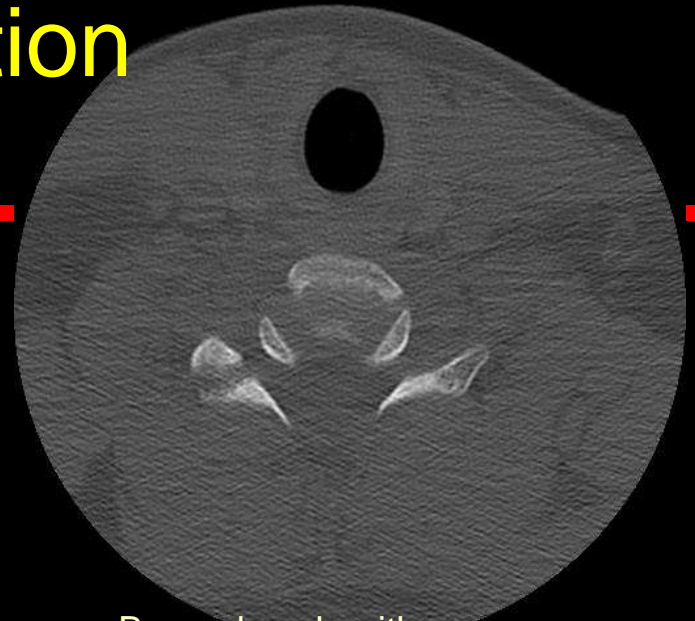Detail algorithm

Rt C7 superior facet and transverse process fracture

Optimization C7 Fx

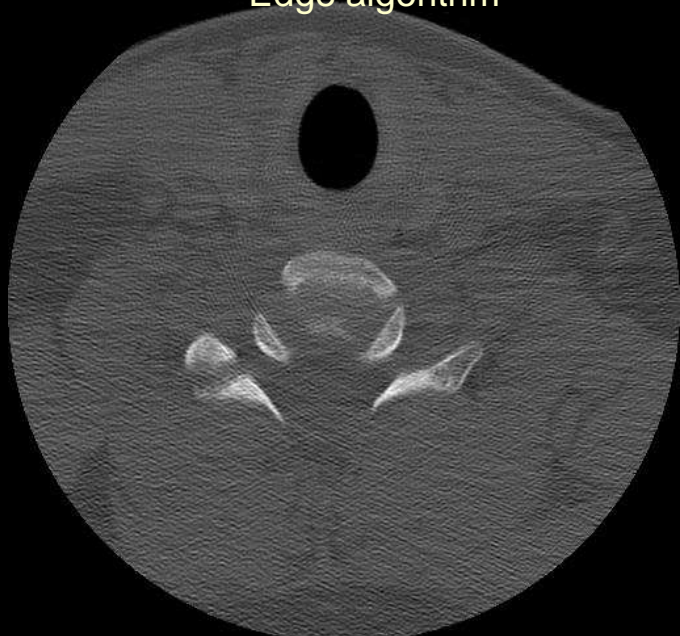

Bone algorithm

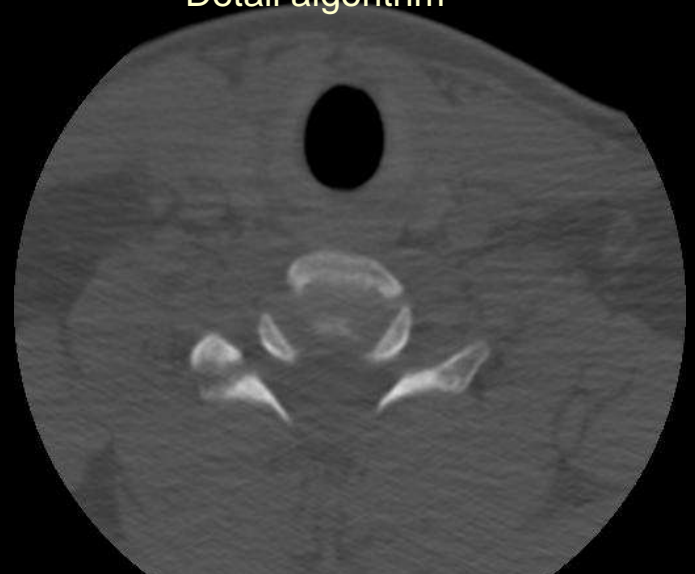


Bone plus algorithm

All bone window/level 2000/500 and 1.3mm thick



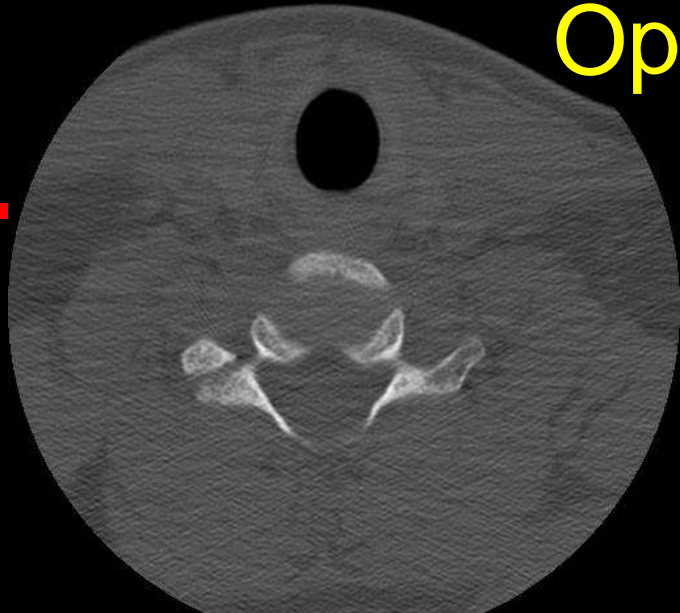
Edge algorithm



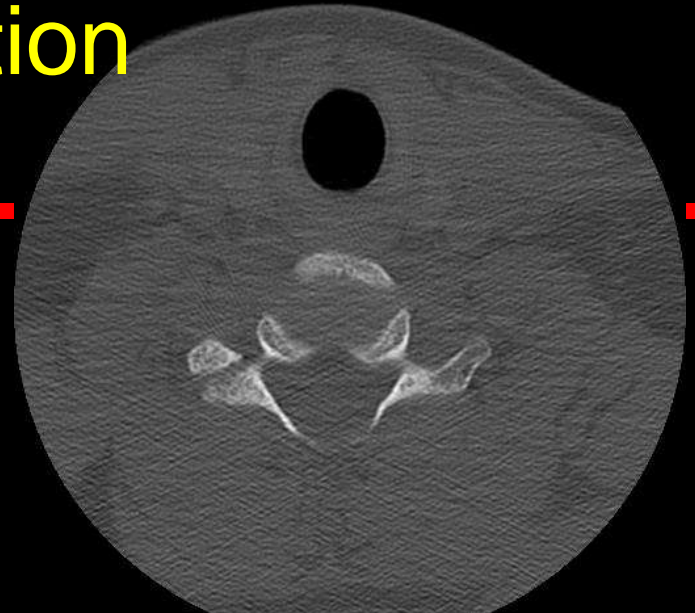
Detail algorithm

Rt C7 superior facet and transverse process fracture

Optimization C7 Fx

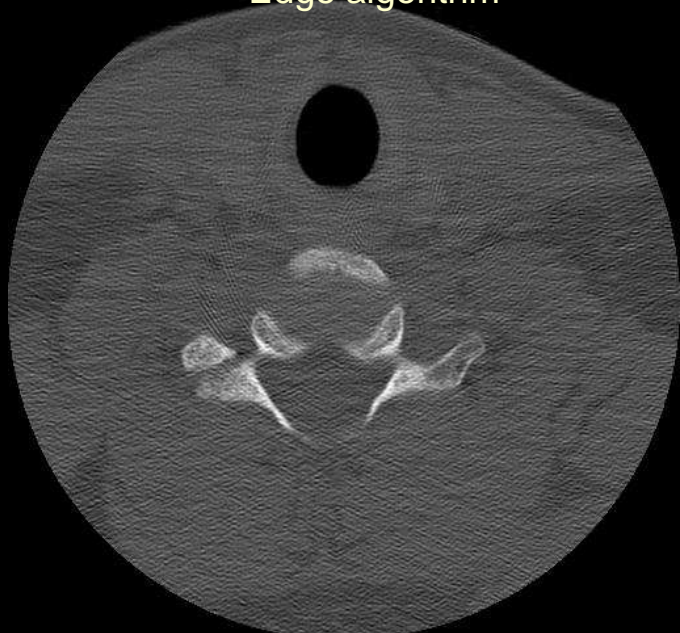

Bone algorithm

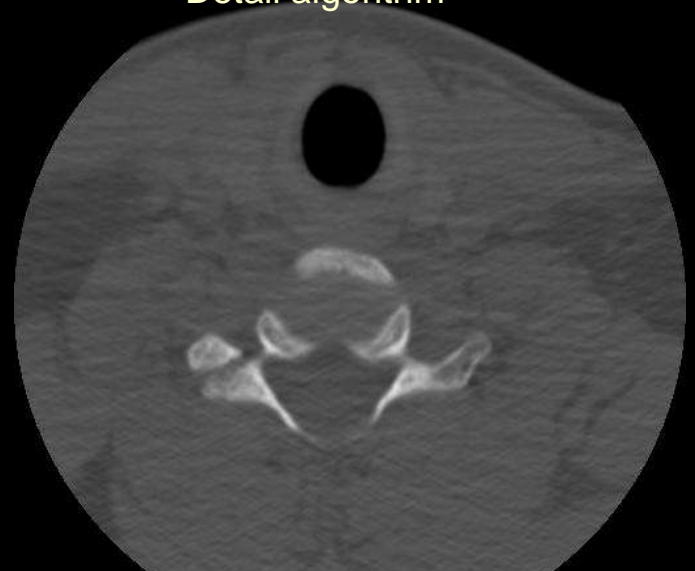


Bone plus algorithm

All bone window/level 2000/500 and 1.3mm thick



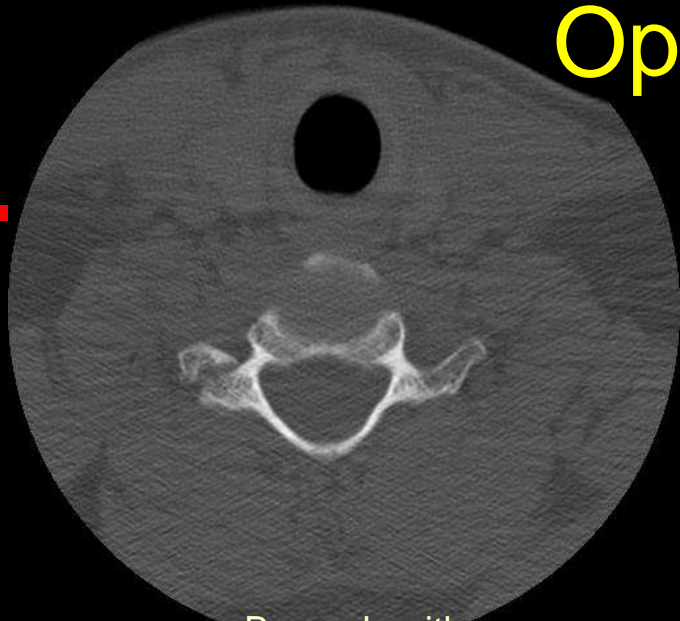
Edge algorithm



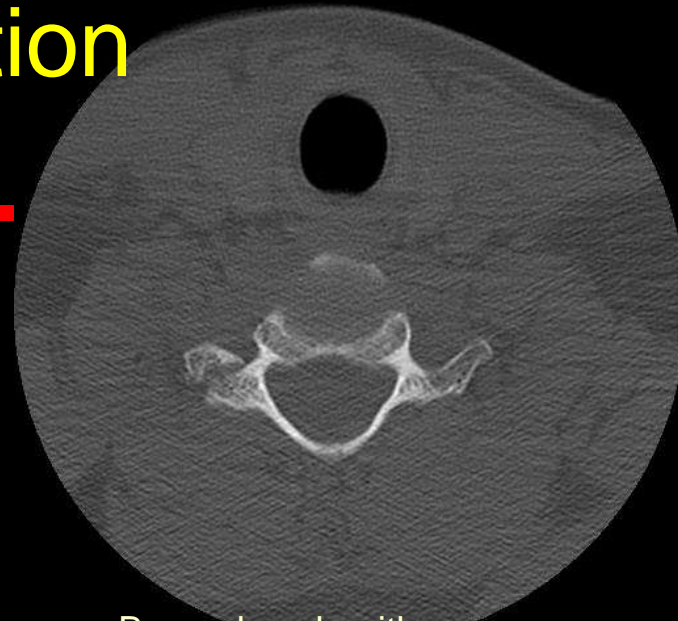
Detail algorithm

Rt C7 superior facet and transverse process fracture

Optimization C7 Fx

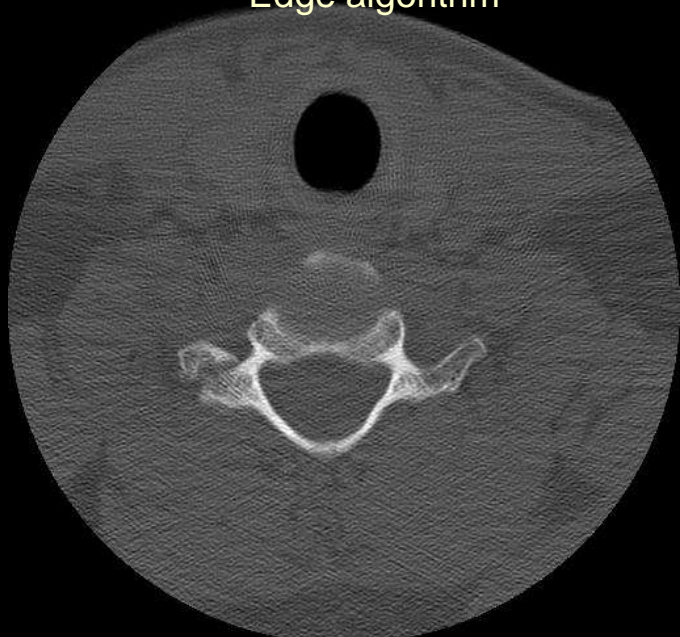


Bone algorithm

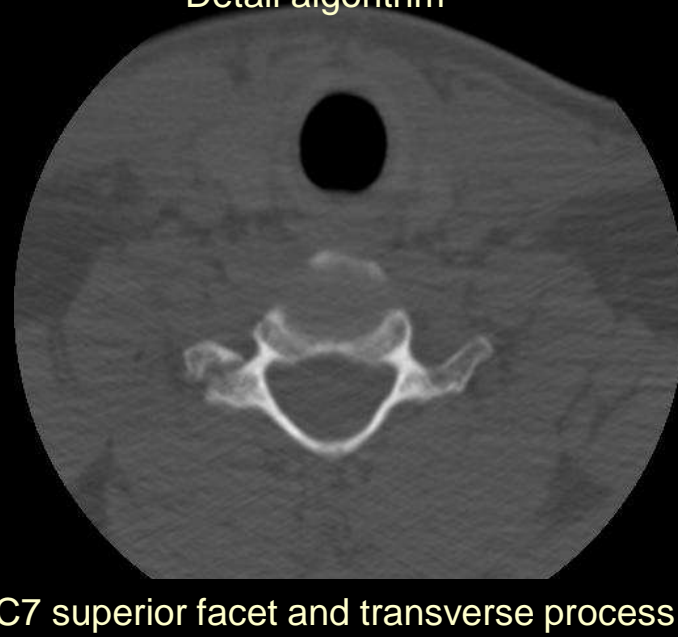


Bone plus algorithm

All bone window/level 2000/500 and 1.3mm thick



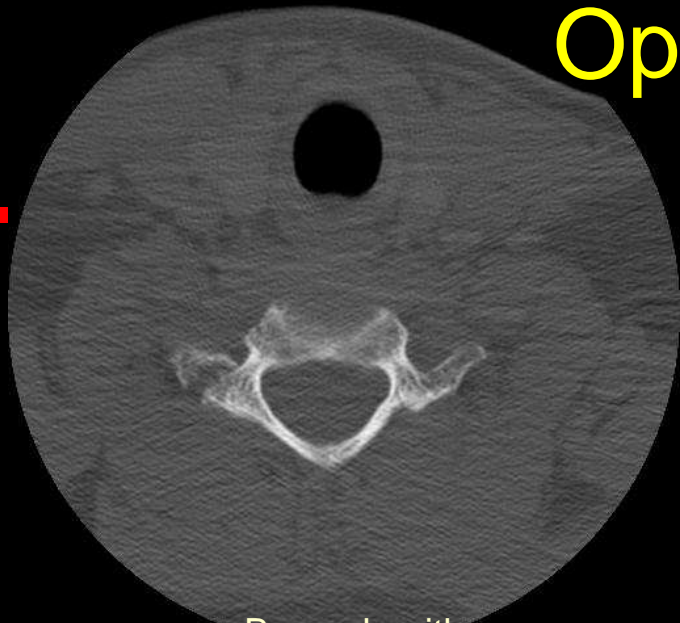
Edge algorithm



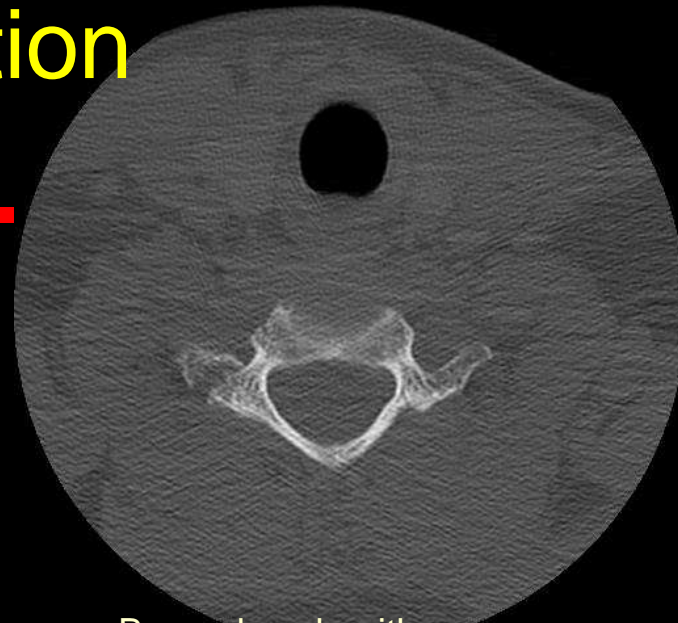
Detail algorithm

Rt C7 superior facet and transverse process fracture

Optimization C7 Fx

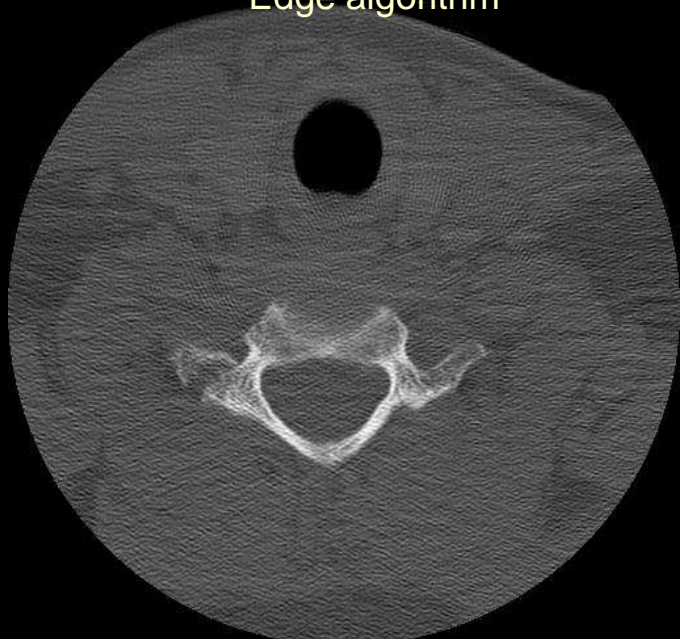


Bone algorithm

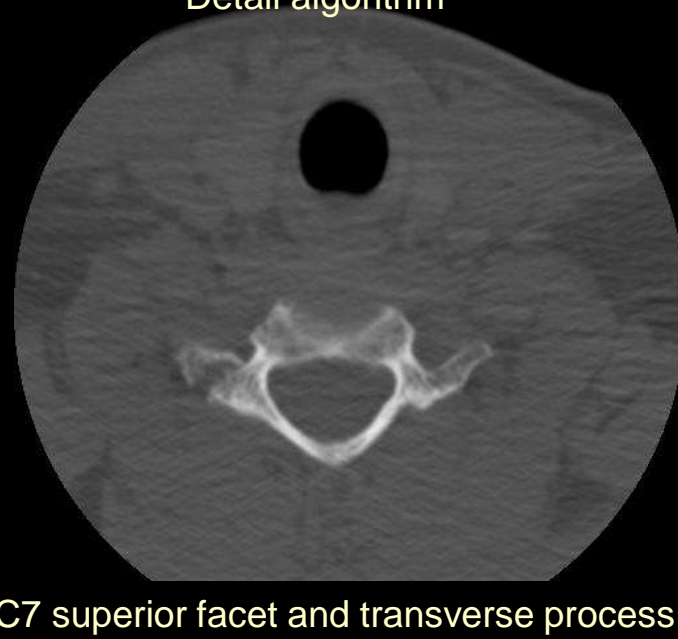


Bone plus algorithm

All bone window/level 2000/500 and 1.3mm thick



Edge algorithm

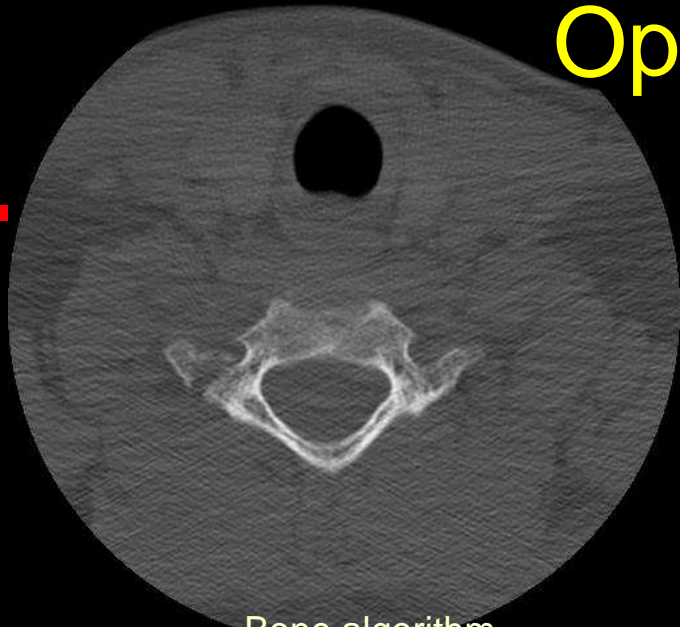


Detail algorithm

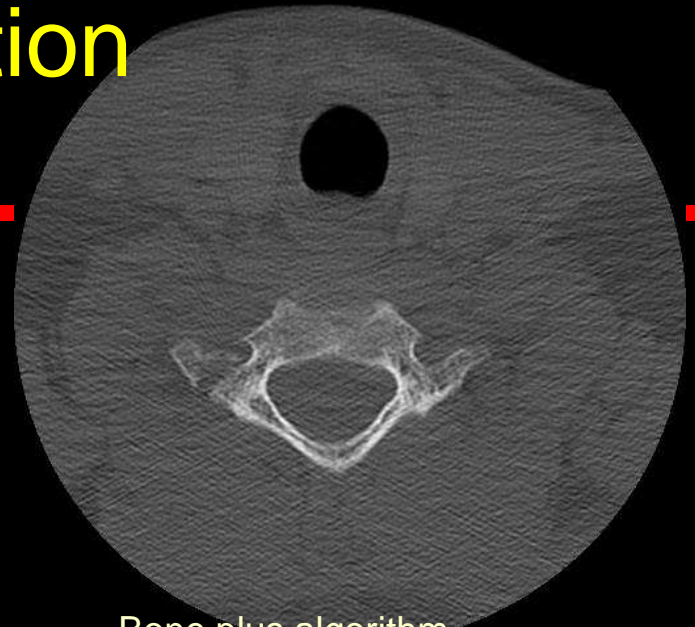Rt C7 superior facet and transverse process fracture

Optimization

C7 Fx

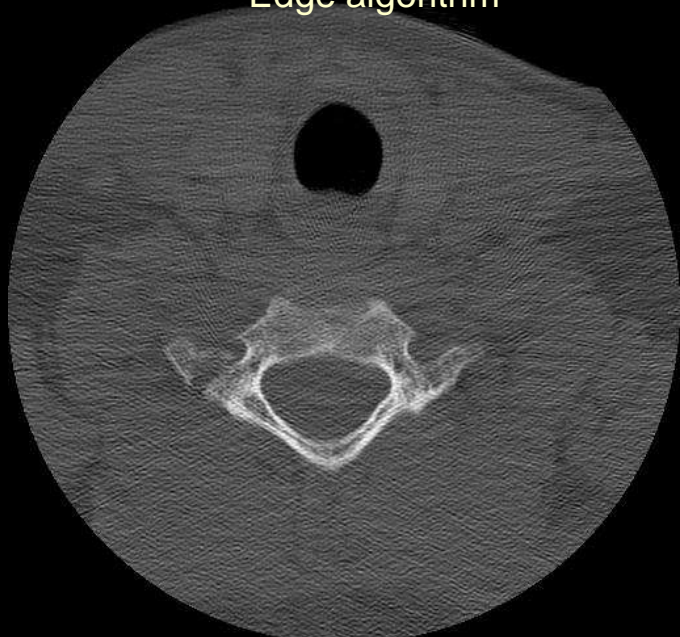


Bone algorithm

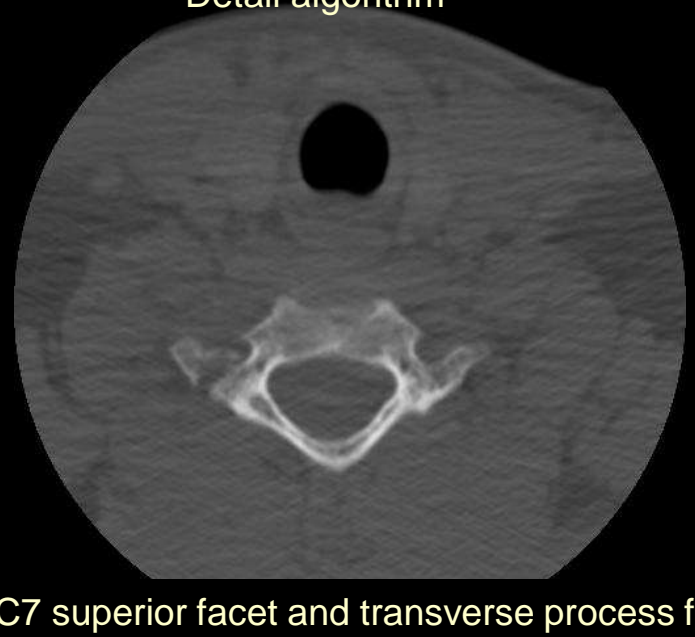


Bone plus algorithm

All bone window/level 2000/500 and 1.3mm thick



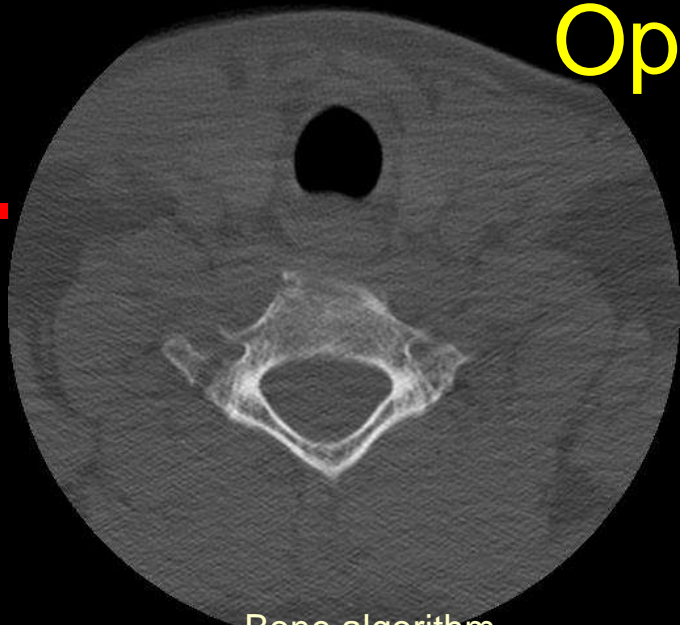
Edge algorithm



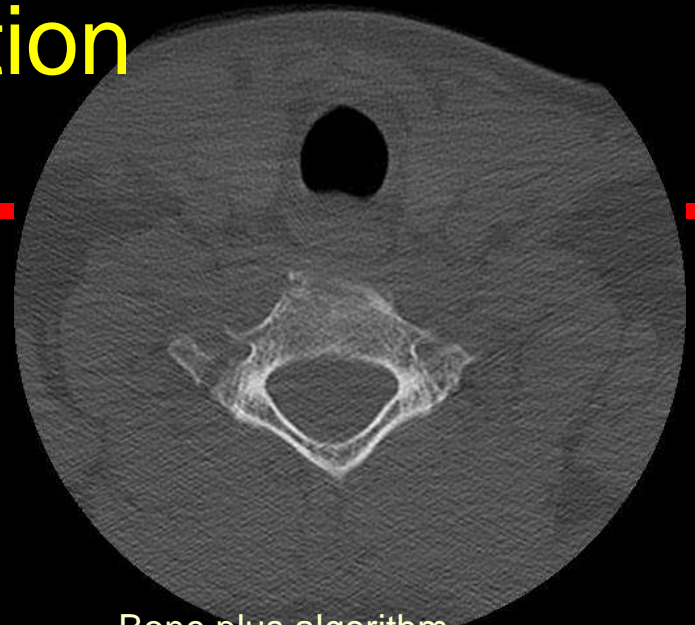Detail algorithm

Rt C7 superior facet and transverse process fracture

Optimization C7 Fx

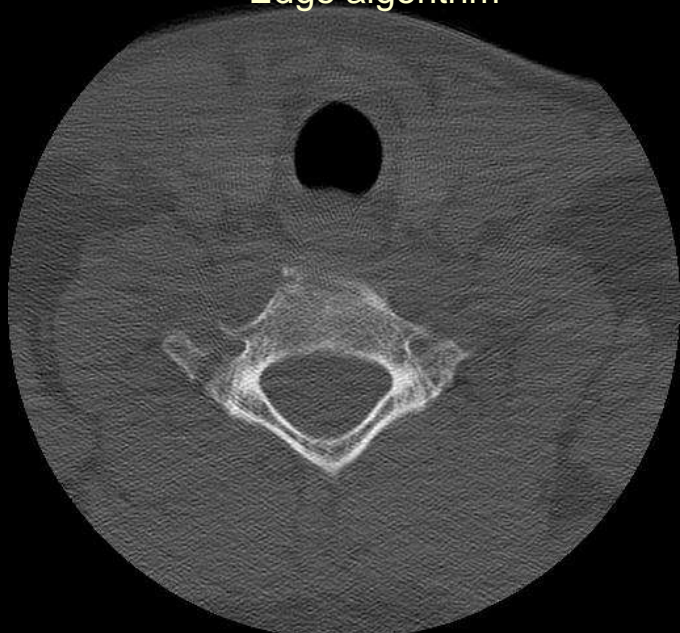


Bone algorithm

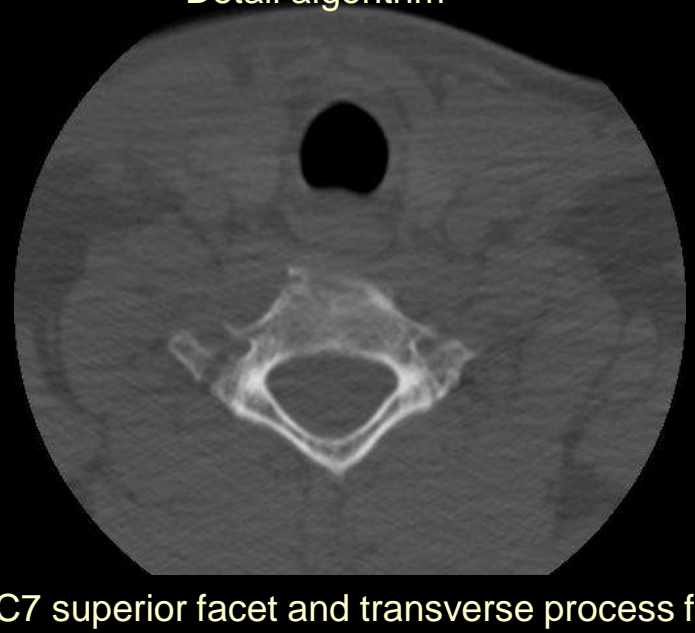


Bone plus algorithm

All bone window/level 2000/500 and 1.3mm thick



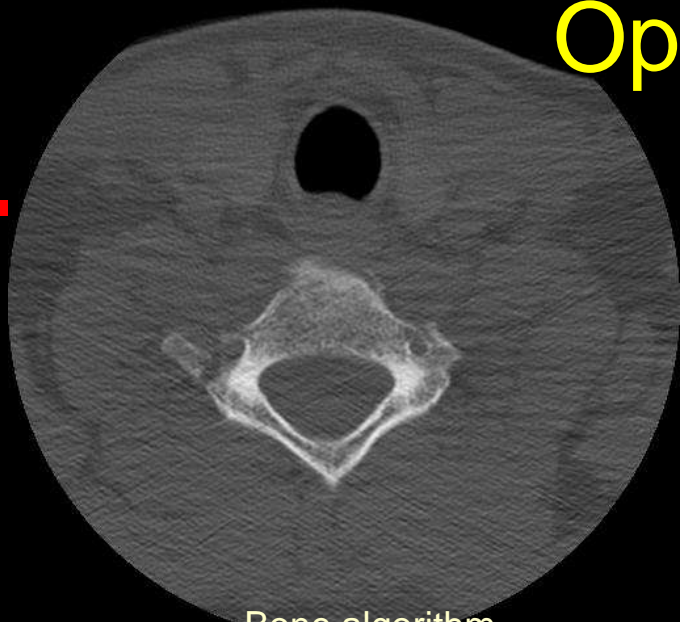
Edge algorithm



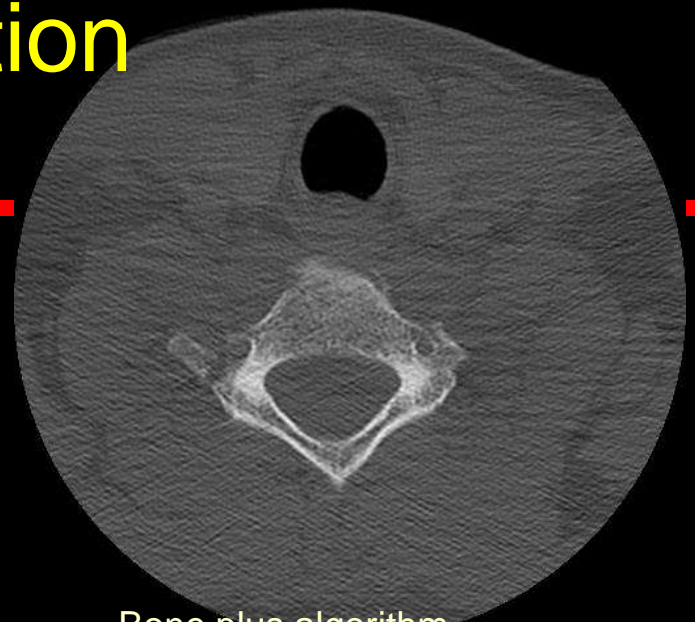
Detail algorithm

Rt C7 superior facet and transverse process fracture

Optimization C7 Fx

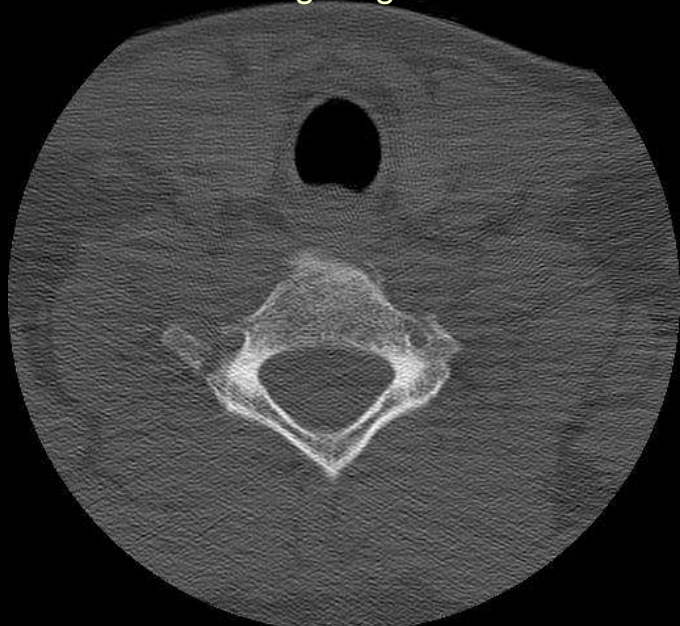


Bone algorithm

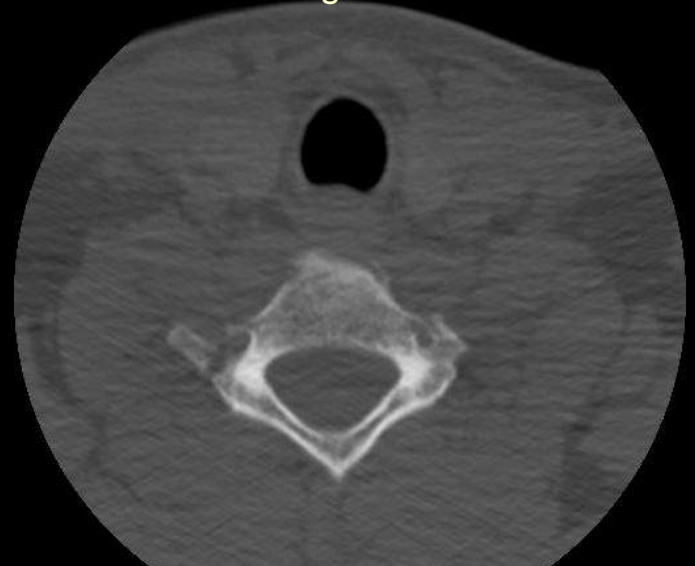

Bone plus algorithm

All bone window/level 2000/500 and 1.3mm thick



Edge algorithm

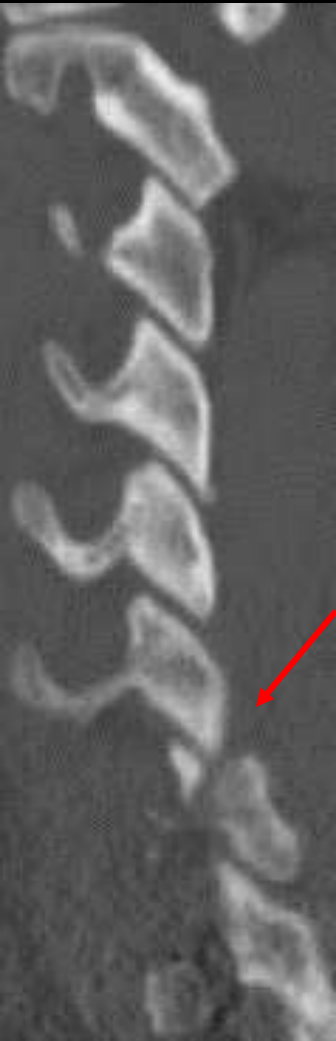

Detail algorithm

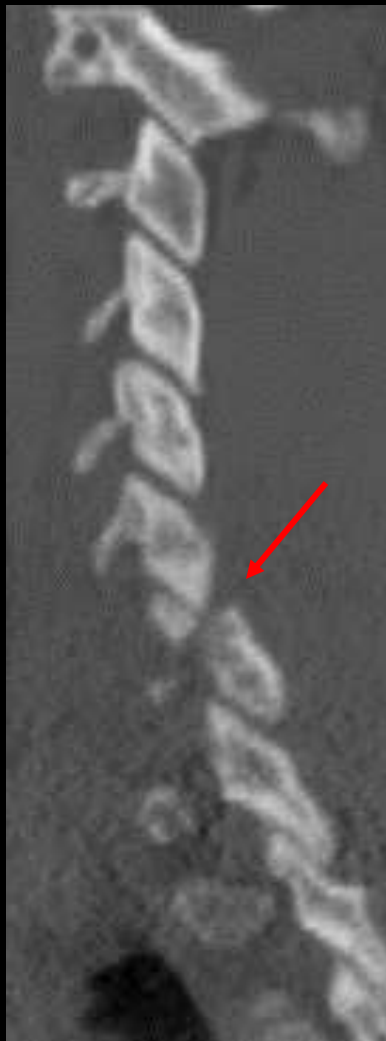Rt C7 superior facet and transverse process fracture

Optimization C7 Fx

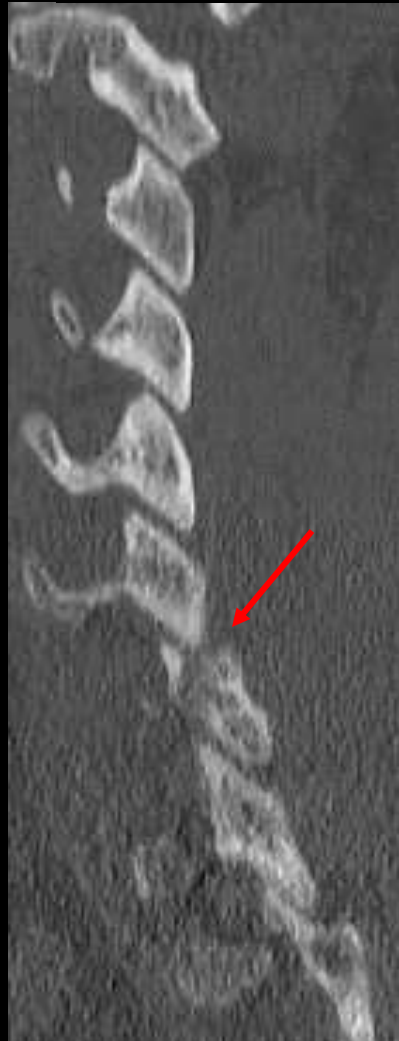Detail algorithm



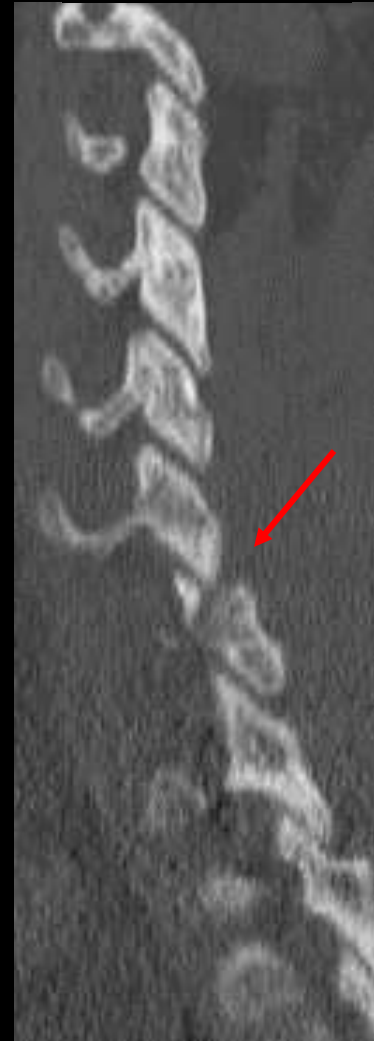Standard algorithm



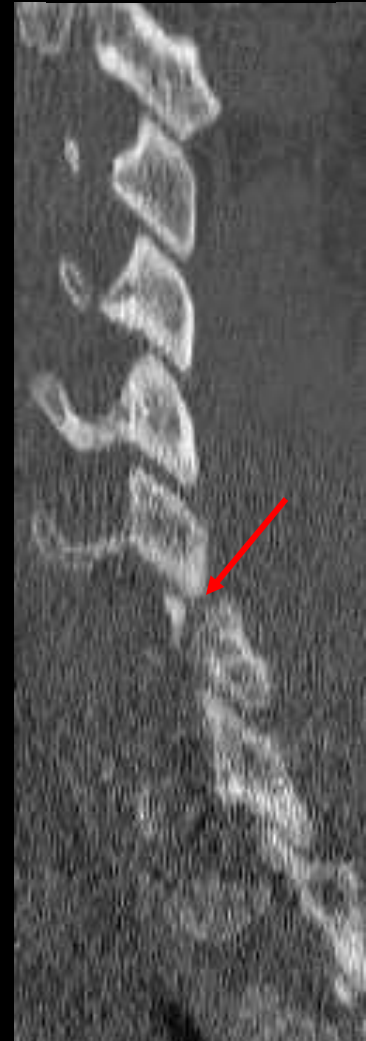Bone plus algorithm



Bone algorithm

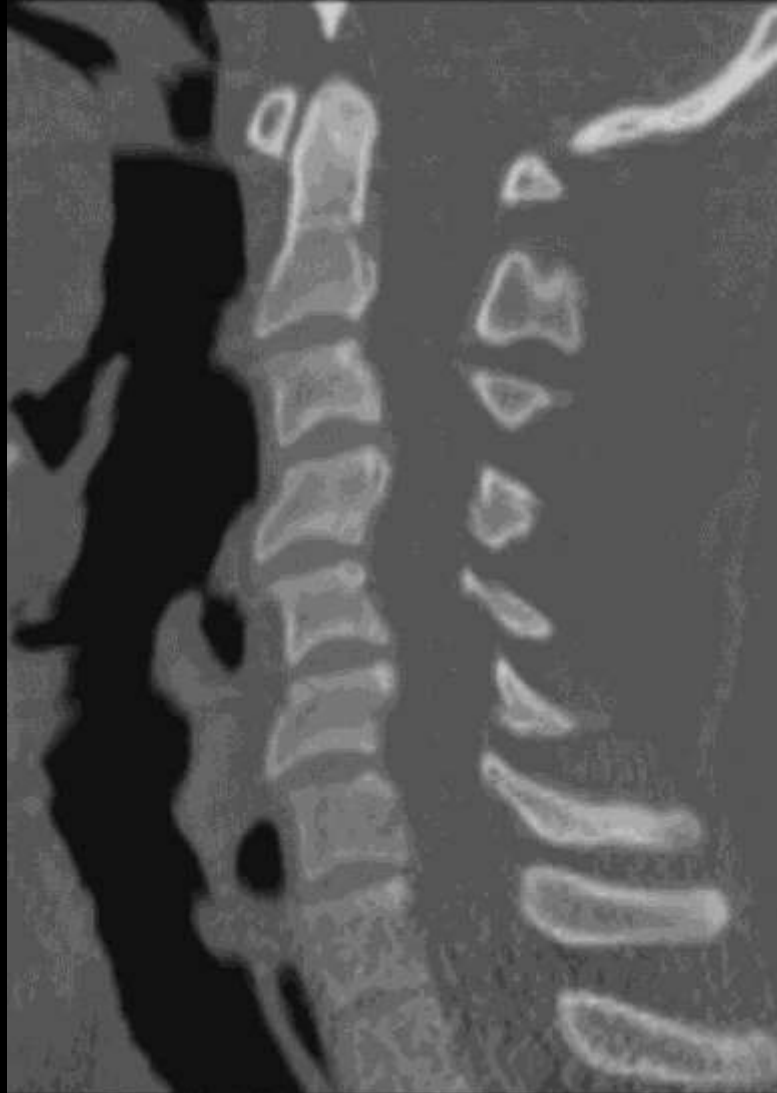

Edge algorithm



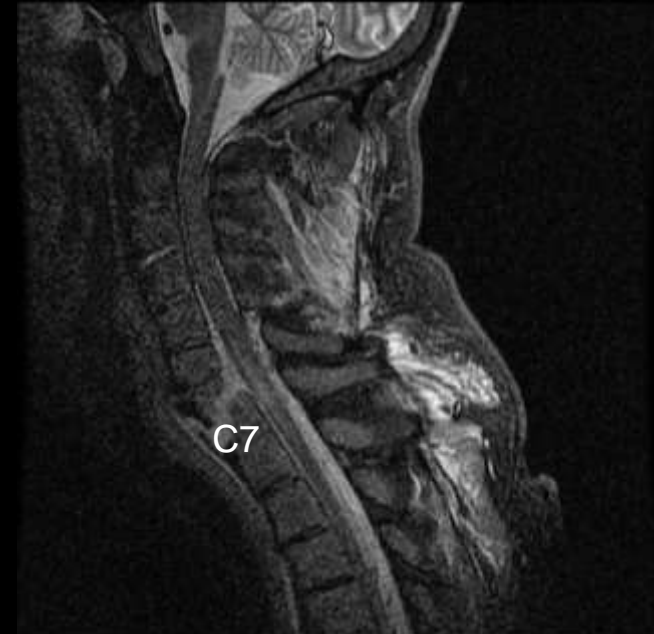All bone window/level 2000/500 and 1.3mm thick

Respiratory motion on CT



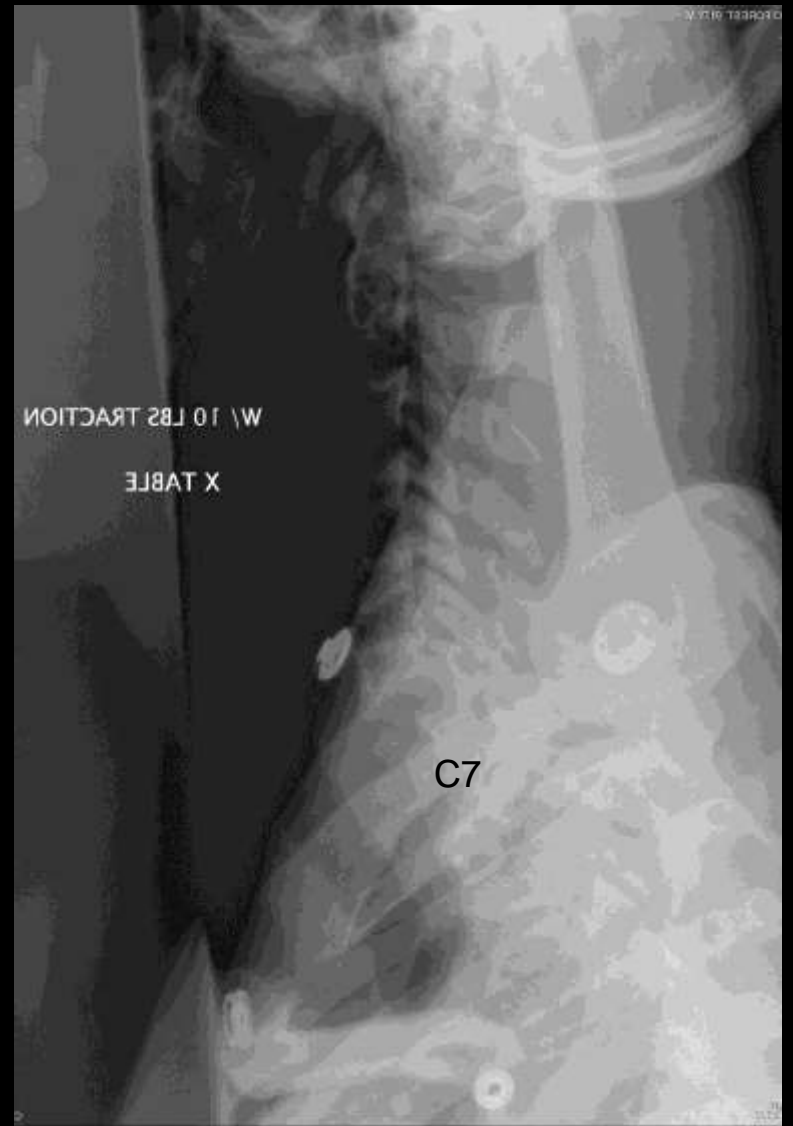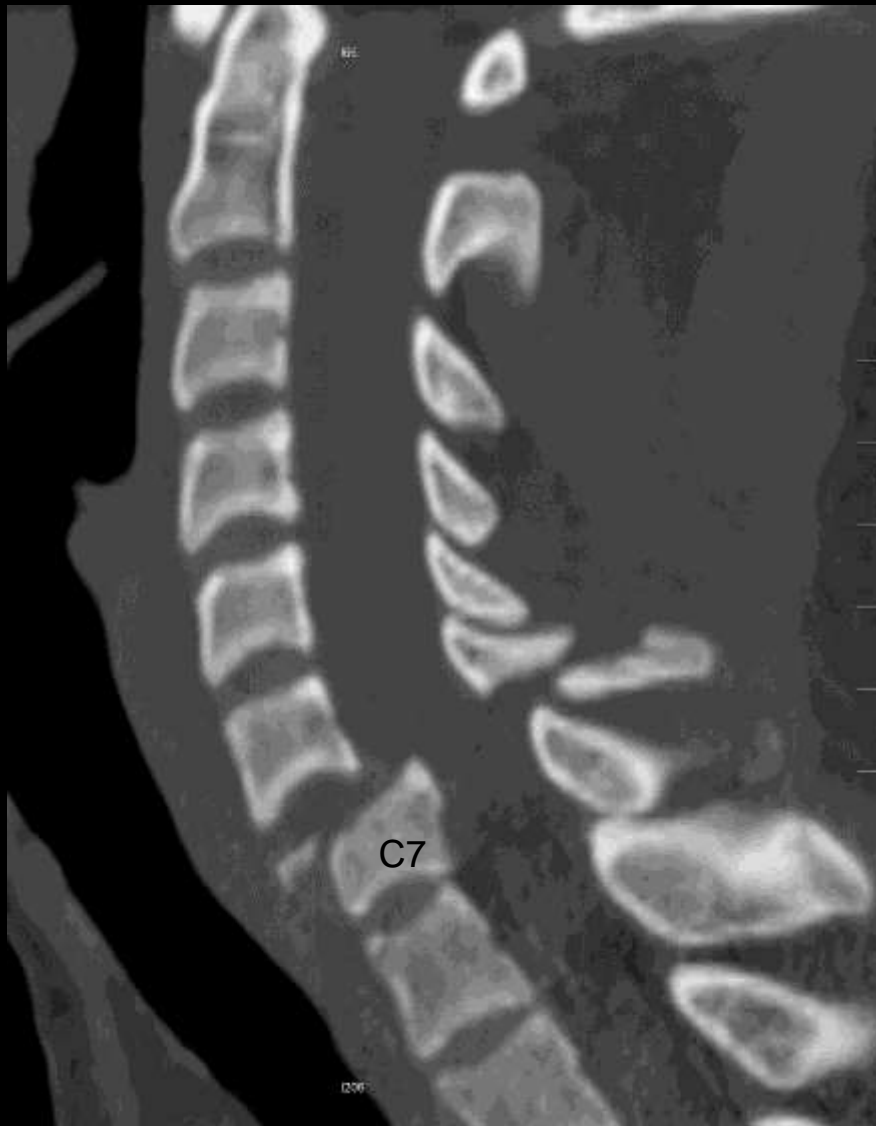Technique - MRI

- Poor visualization of fractures
- Good for soft tissue injury
- Good for spinal cord injury assessment
- Good for spinal cord injury prognosis
- Good for root avulsion



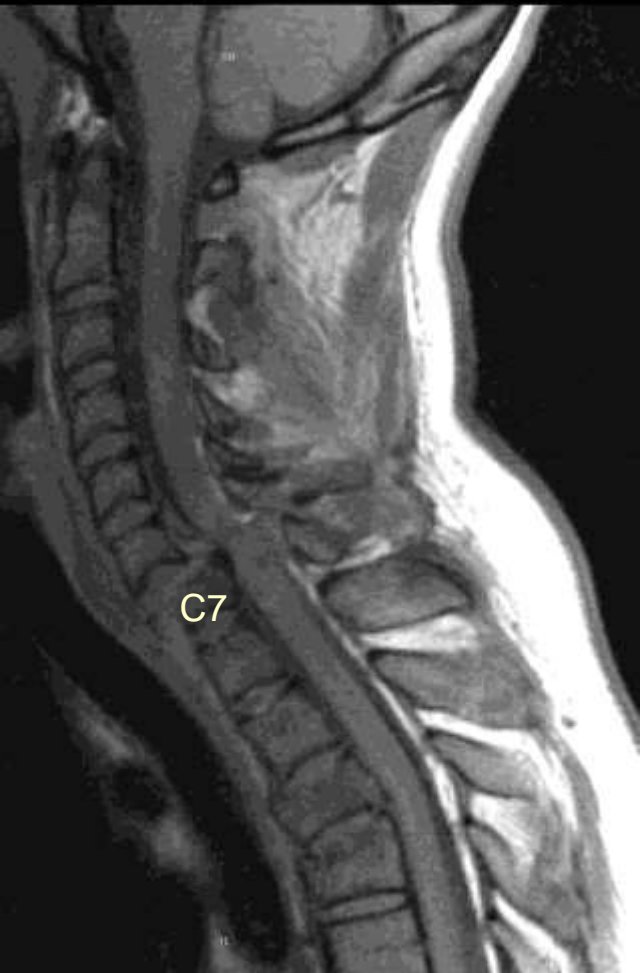Ankylosing spondylitis fracture

Technique - MRI

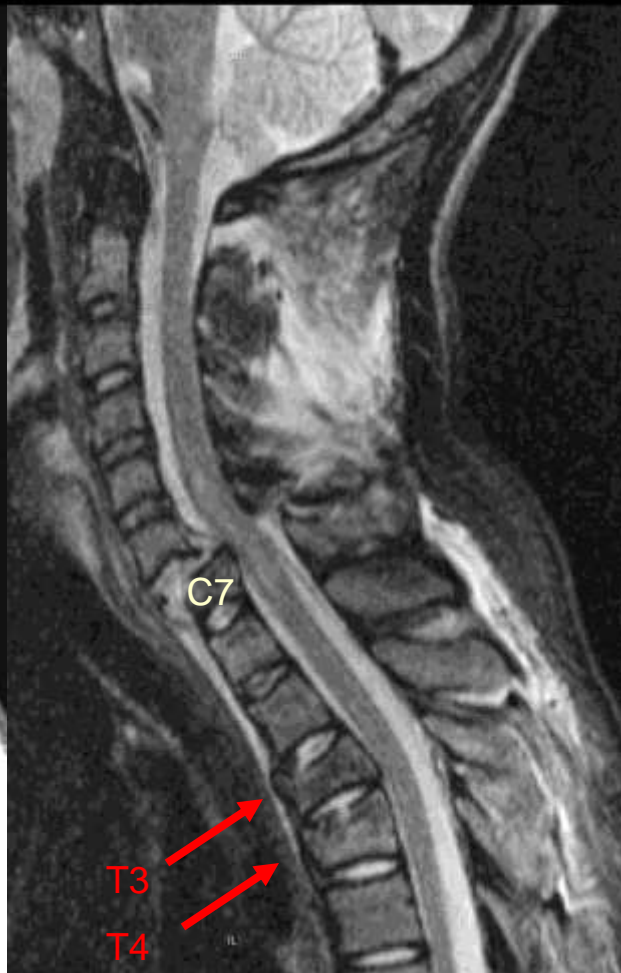


17M C6-7 Hyperflexion Injury

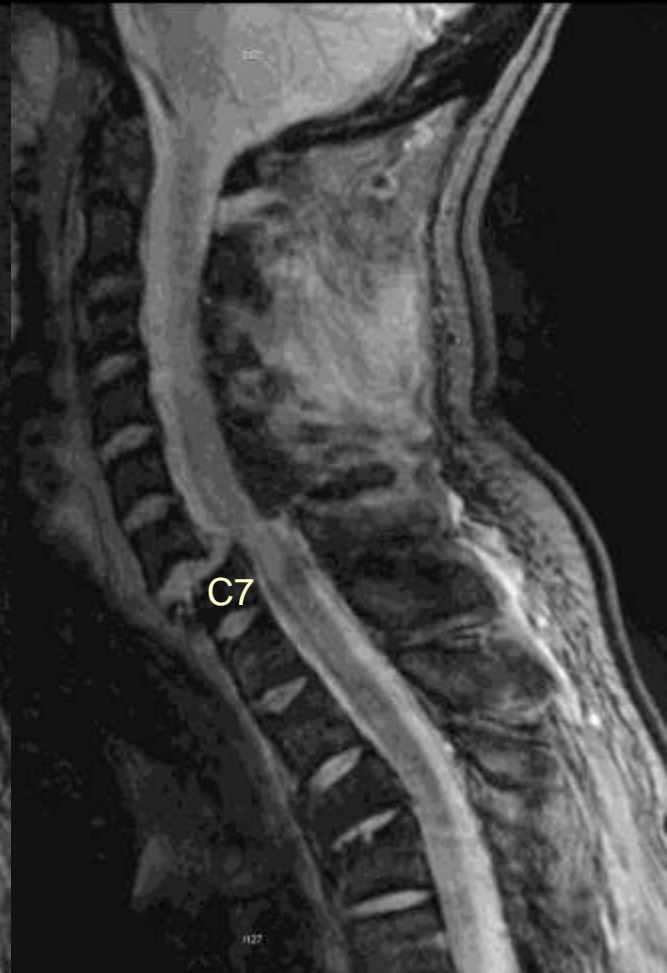Technique - MRI



Sag T1

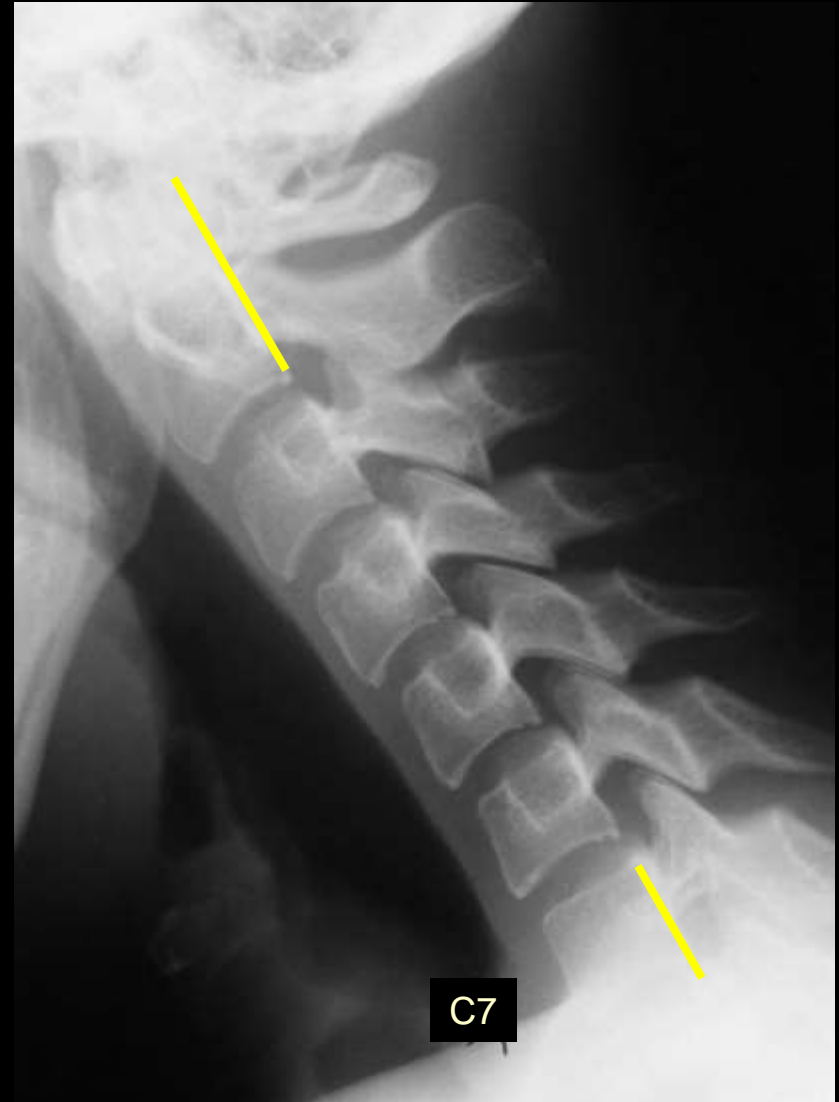
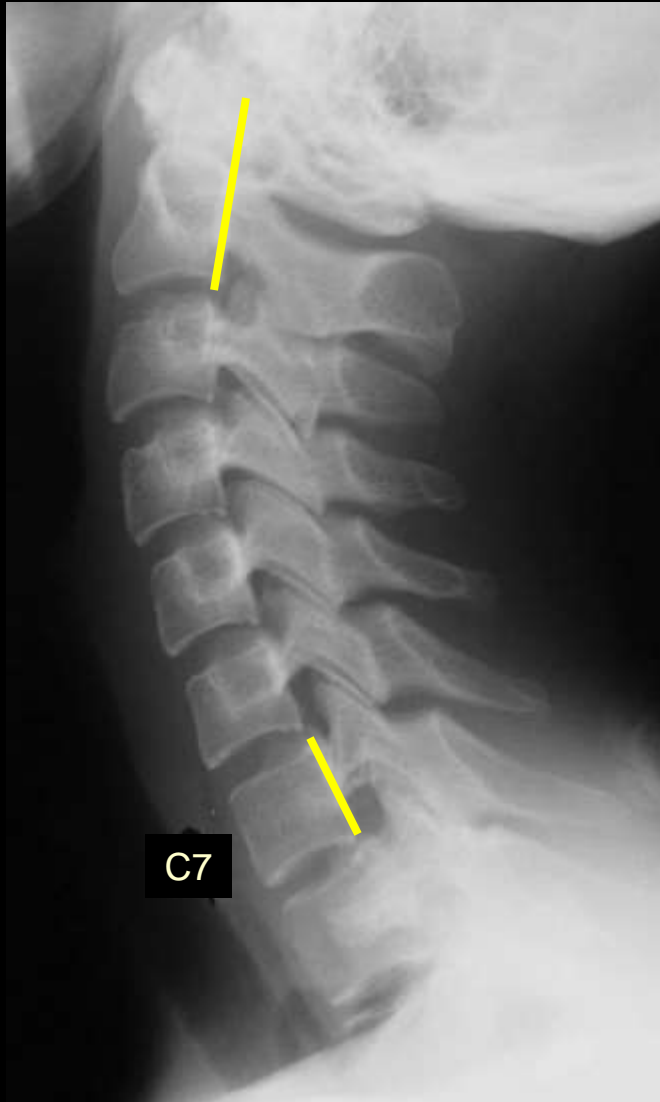
Sag T2FS



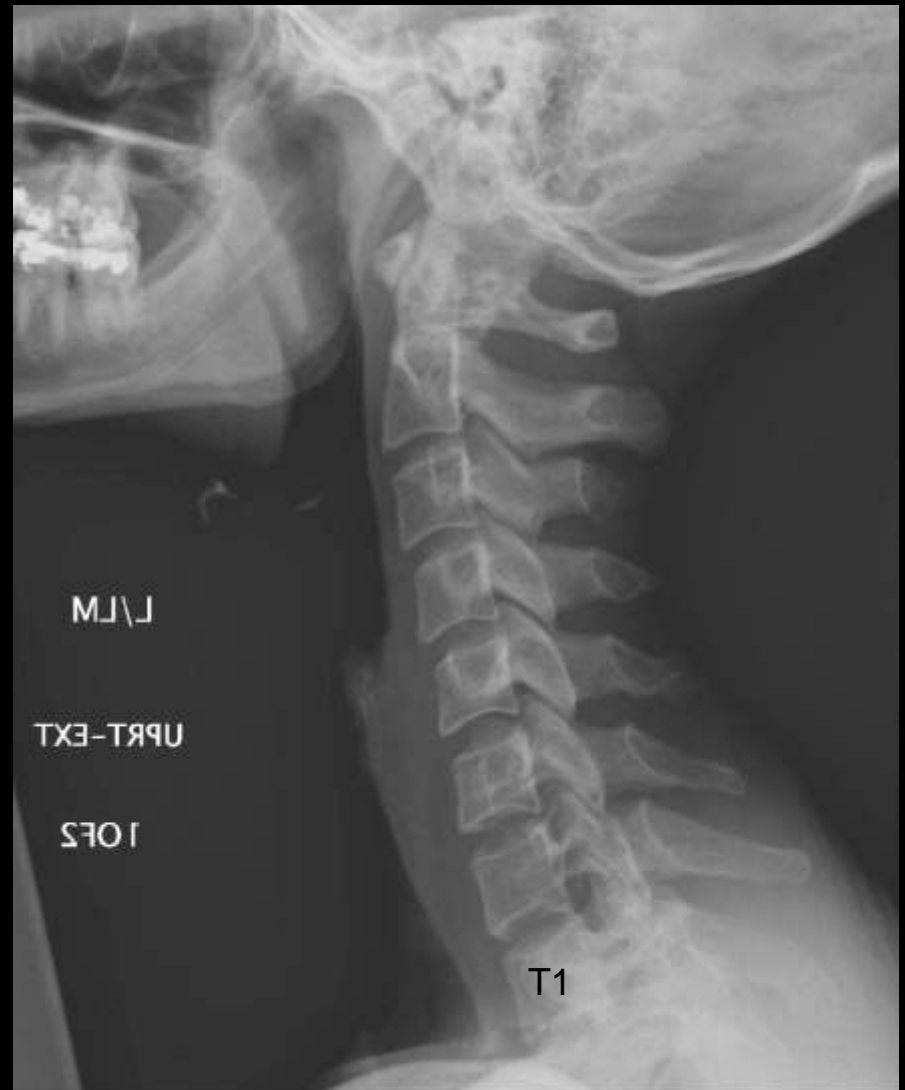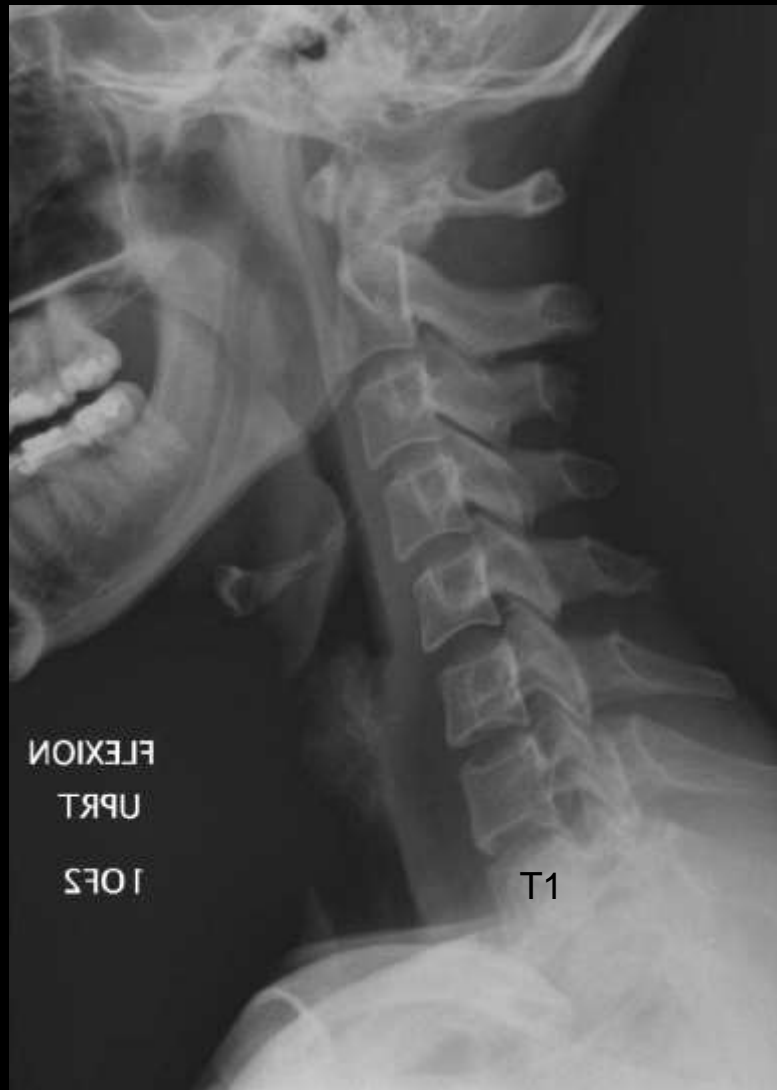Sag STIR

Technique - Flexion / Extension

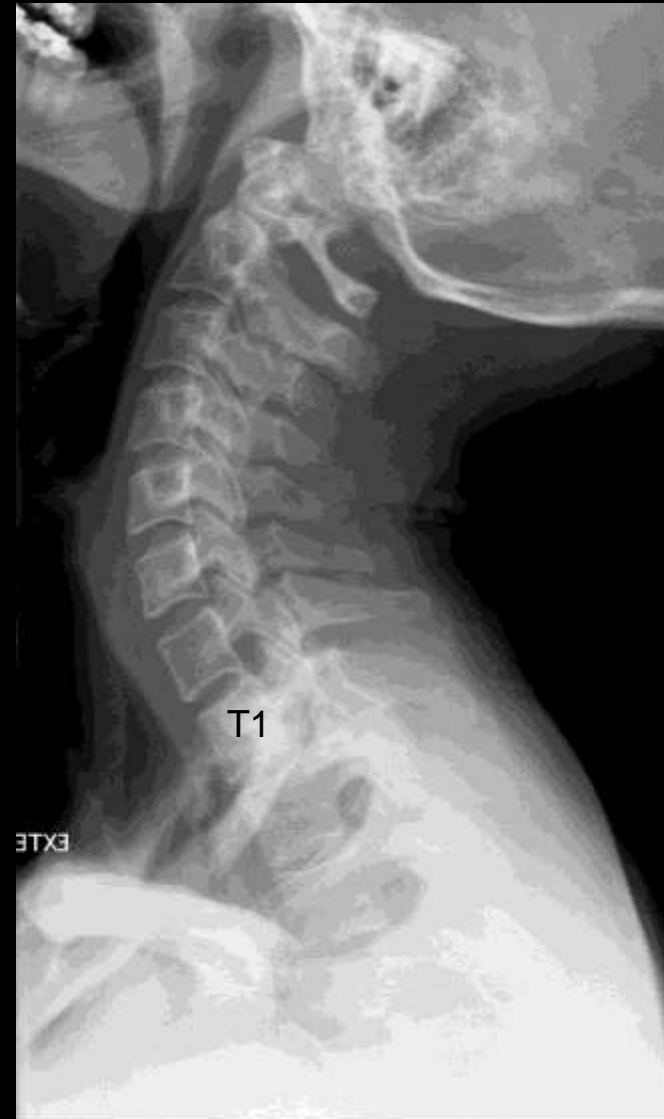
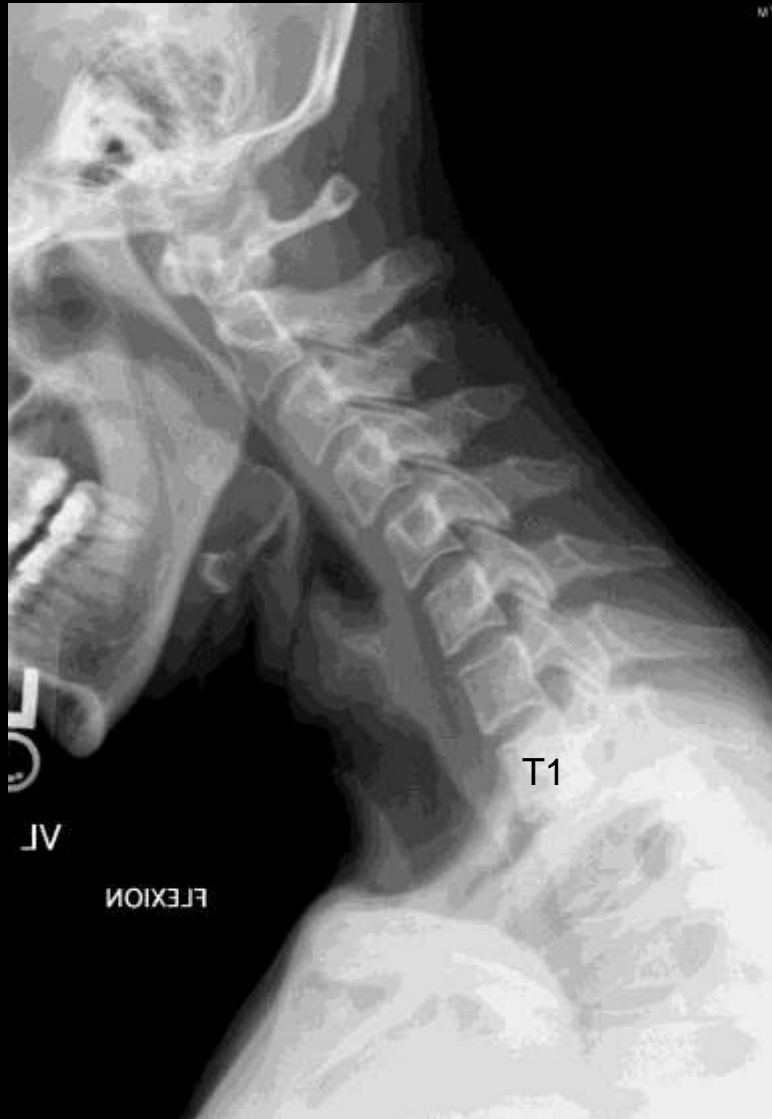
Open C1 posterior arch

Technique - Flexion / Extension



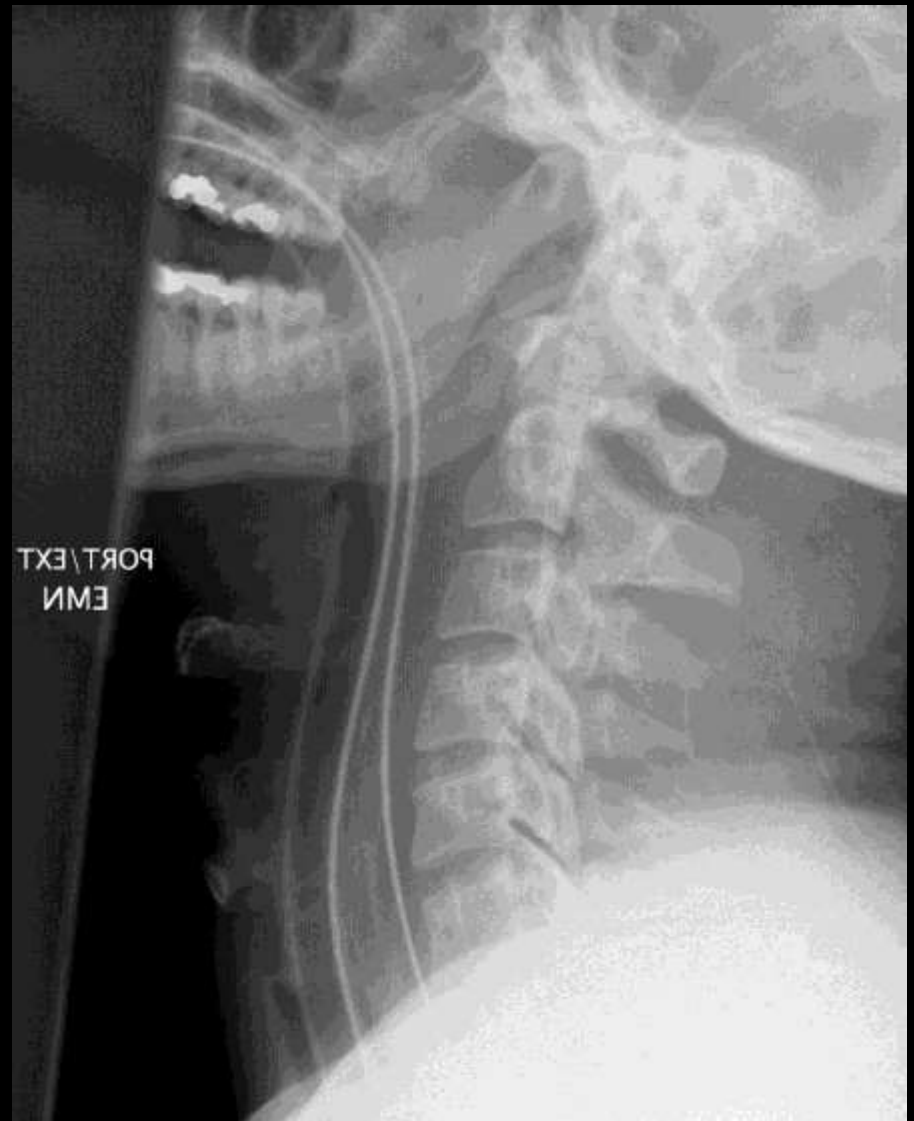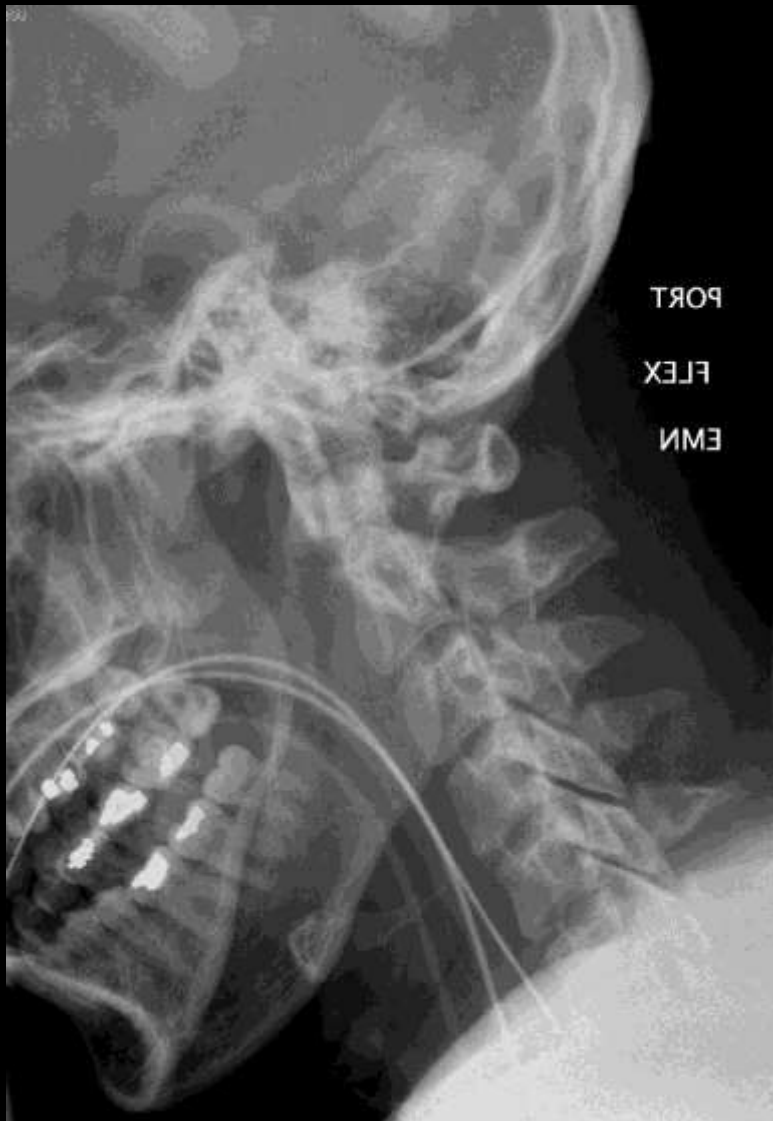Technique - Flexion / Extension



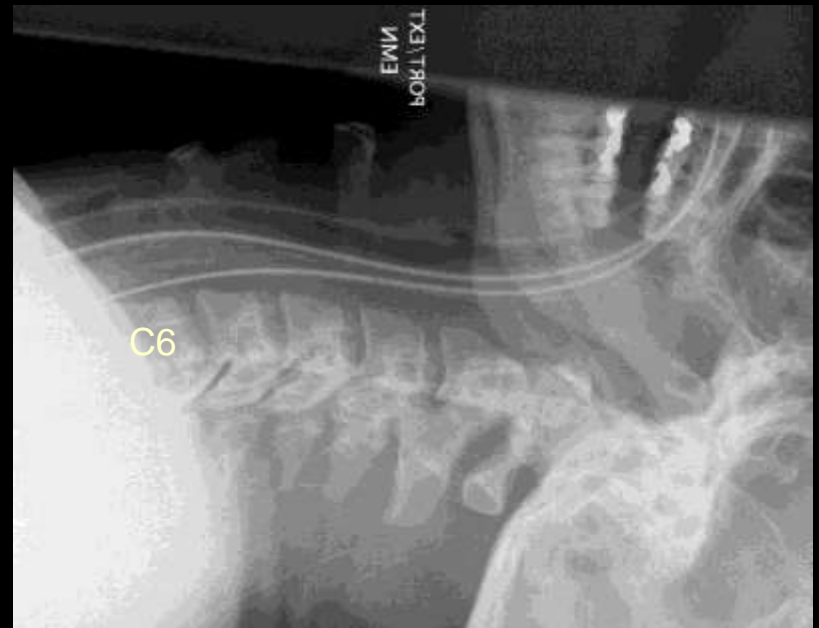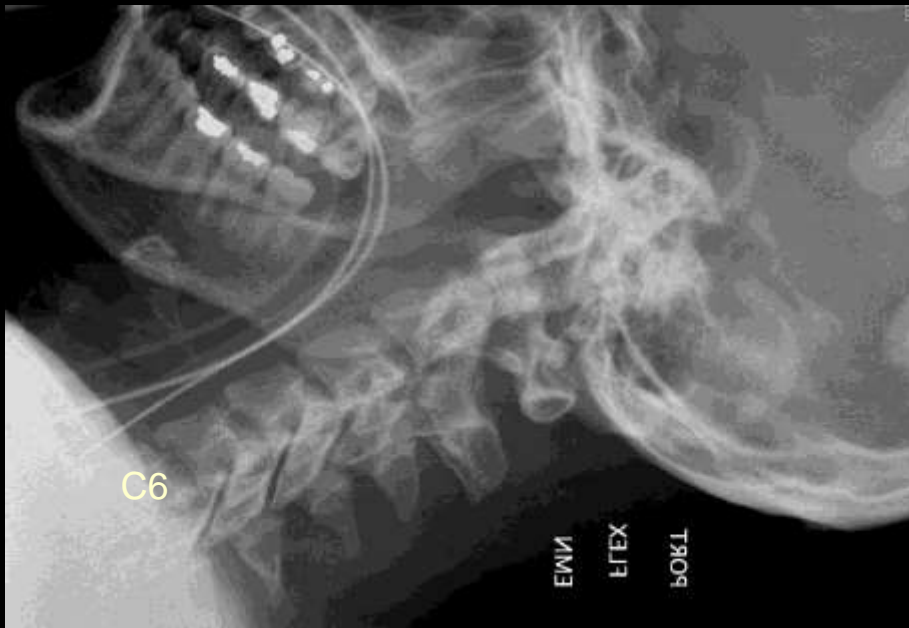
Flexion Extension - Supine

- All radiographic texts describe obtaining F/E views with the alert patient standing or sitting.
- There are no articles on obtaining flexion extension views in a supine patient.

Technique - Flex/Ext



Technique - Flex/Ext



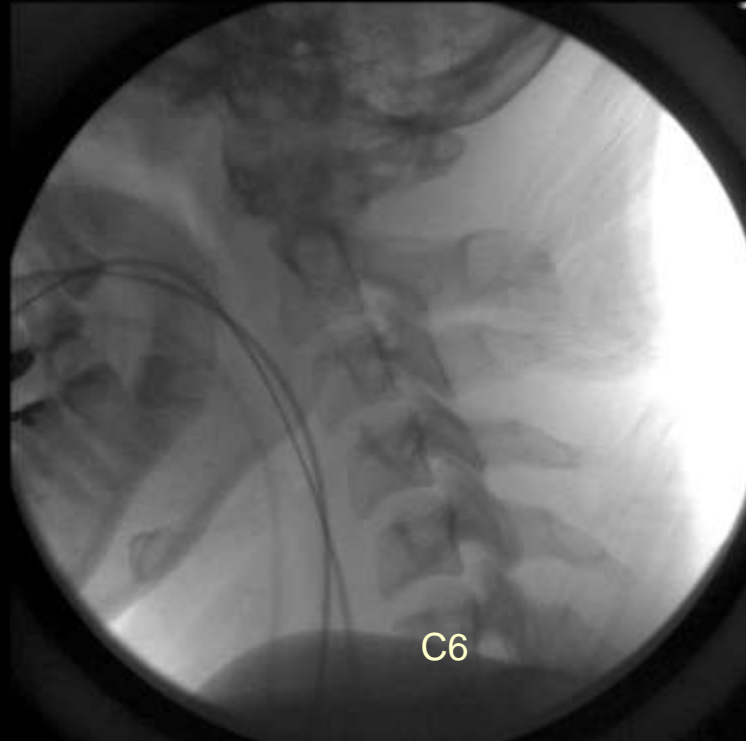Obtunded Flexion - Extension

- Do no harm

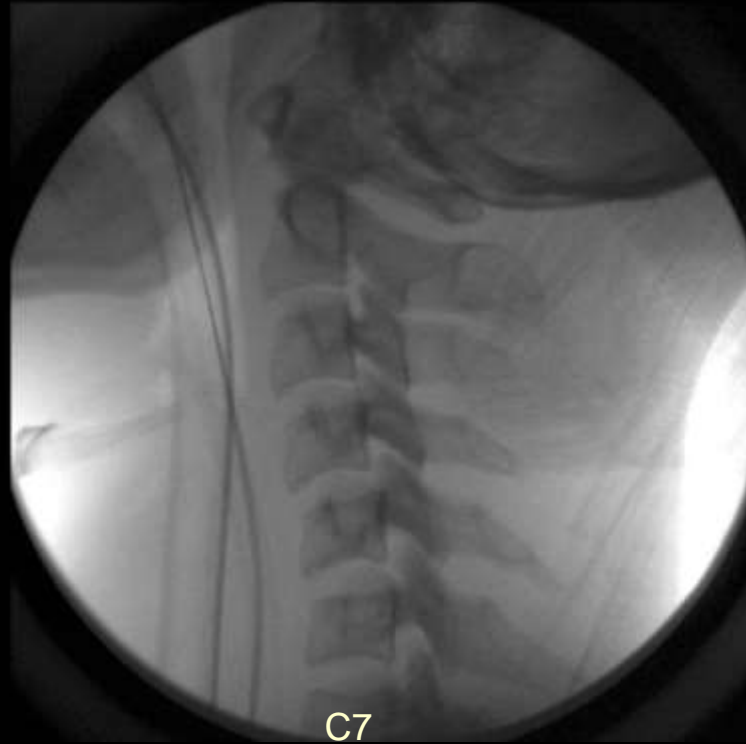Obtunded Flexion – Extension Dangers

- Causing paraplegia/quadraplegia
 - Can only see part of Cx spine
 - Could be causing a disc herniation
- Rise in ICP
 - I have seen rise to over 80 mmHg
- Rise in BP
 - I have seen rise to over 200 systolic

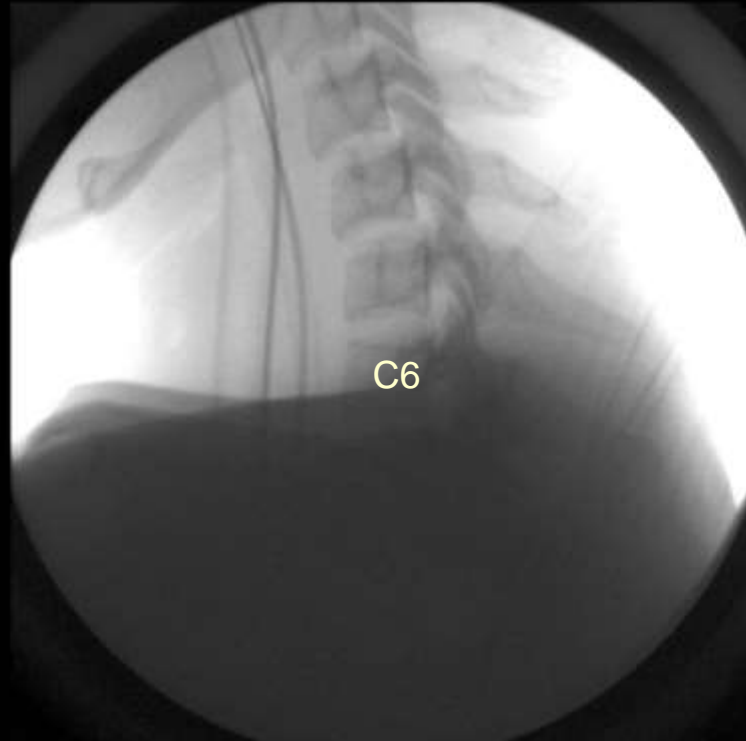Obtunded Flexion - Extension



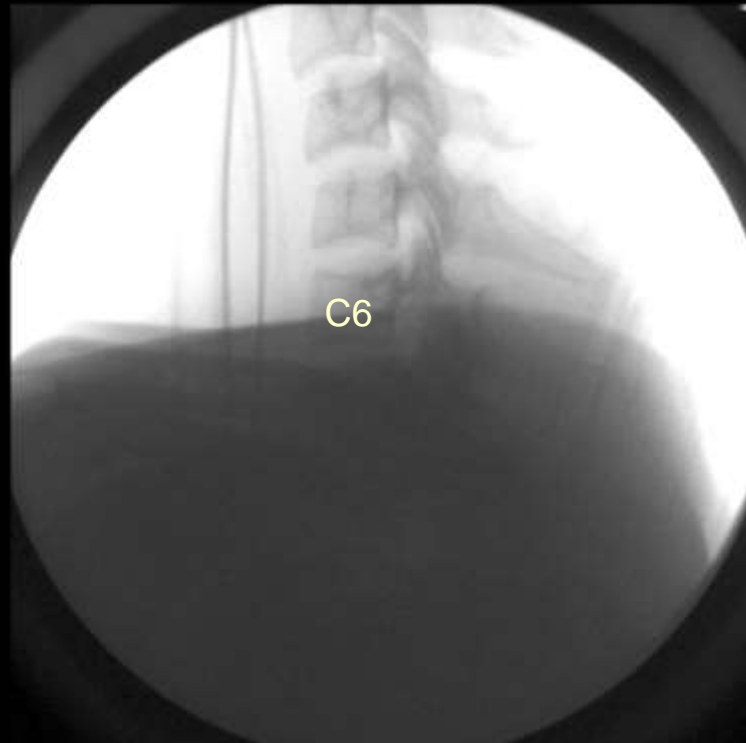Obtunded Flexion - Extension



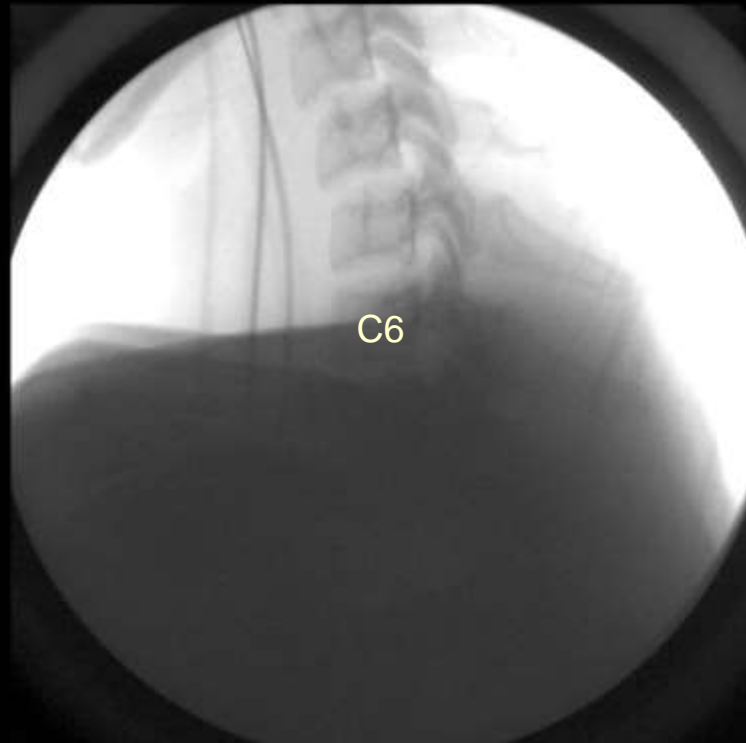Obtunded Flexion - Extension



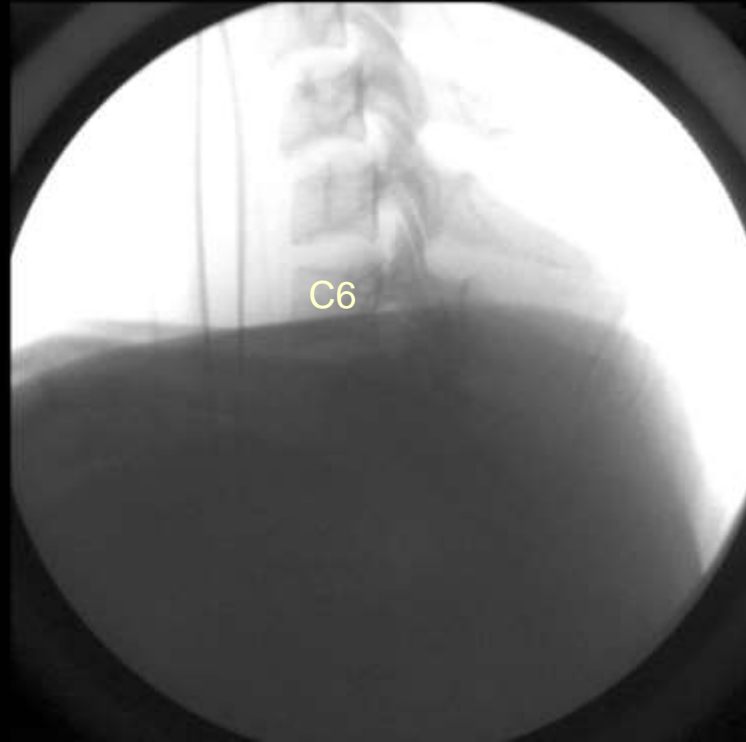Obtunded Flexion - Extension



Obtunded Flexion - Extension



Obtunded Flexion - Extension



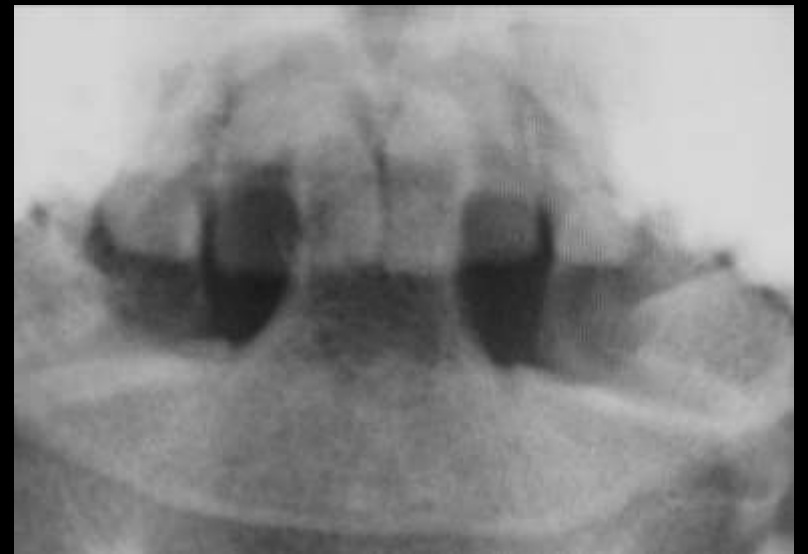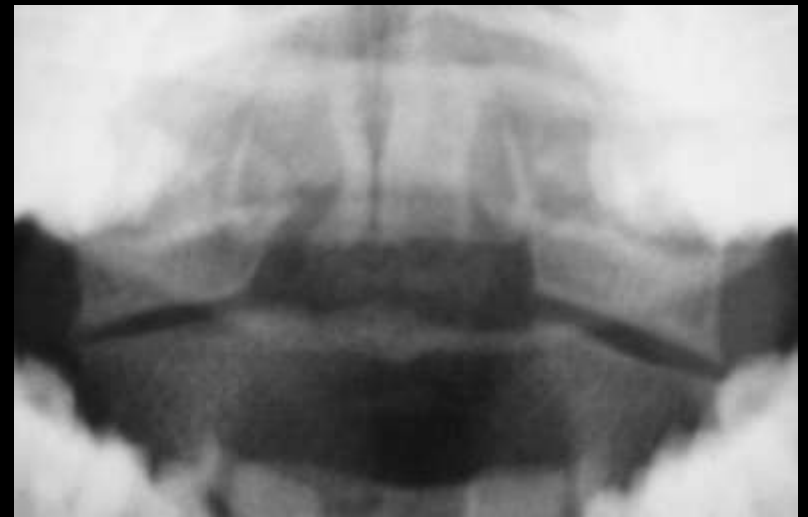
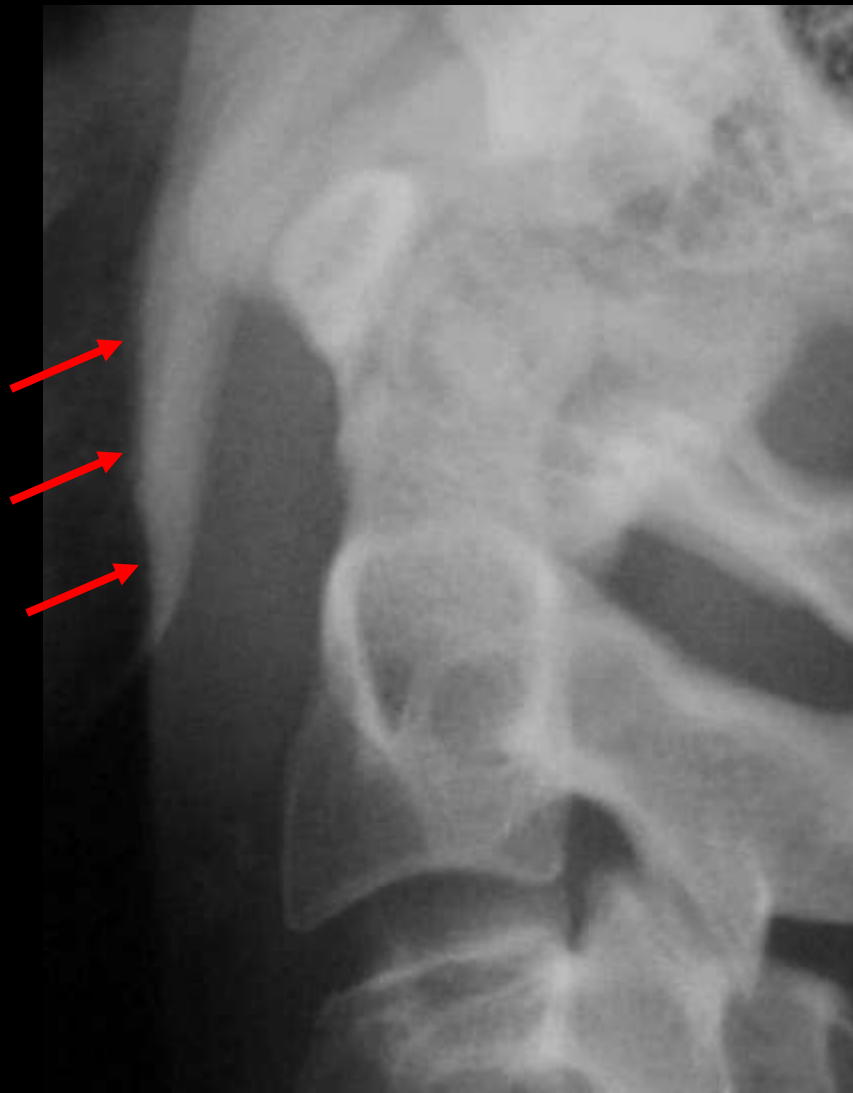
Obtunded Flexion - Extension

- I cannot find any reference to fluoroscopic passive flexion/extension studies finding an unstable ligamentous injury, without fracture, that needed to be surgically fixed.

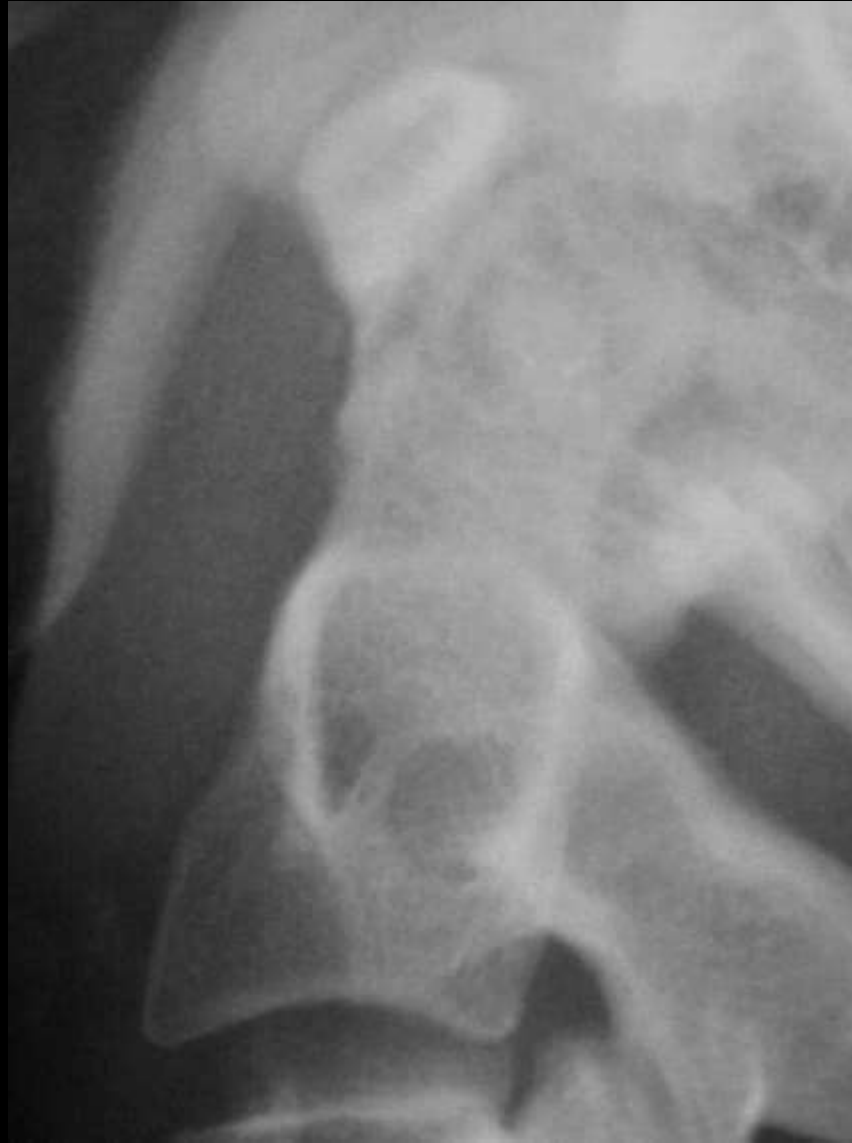Unconscious Patient

- In persons with decreased mental status, flexion/extension views in experienced hands can probably exclude instability in adults. This can be done at the bedside even in ITU. However, this method does not exclude significant soft tissue or spinal cord injuries, and **manipulation and mobilization can cause secondary spinal cord trauma. On this basis the practice is not recommended.**

Technique - Flex/Ext



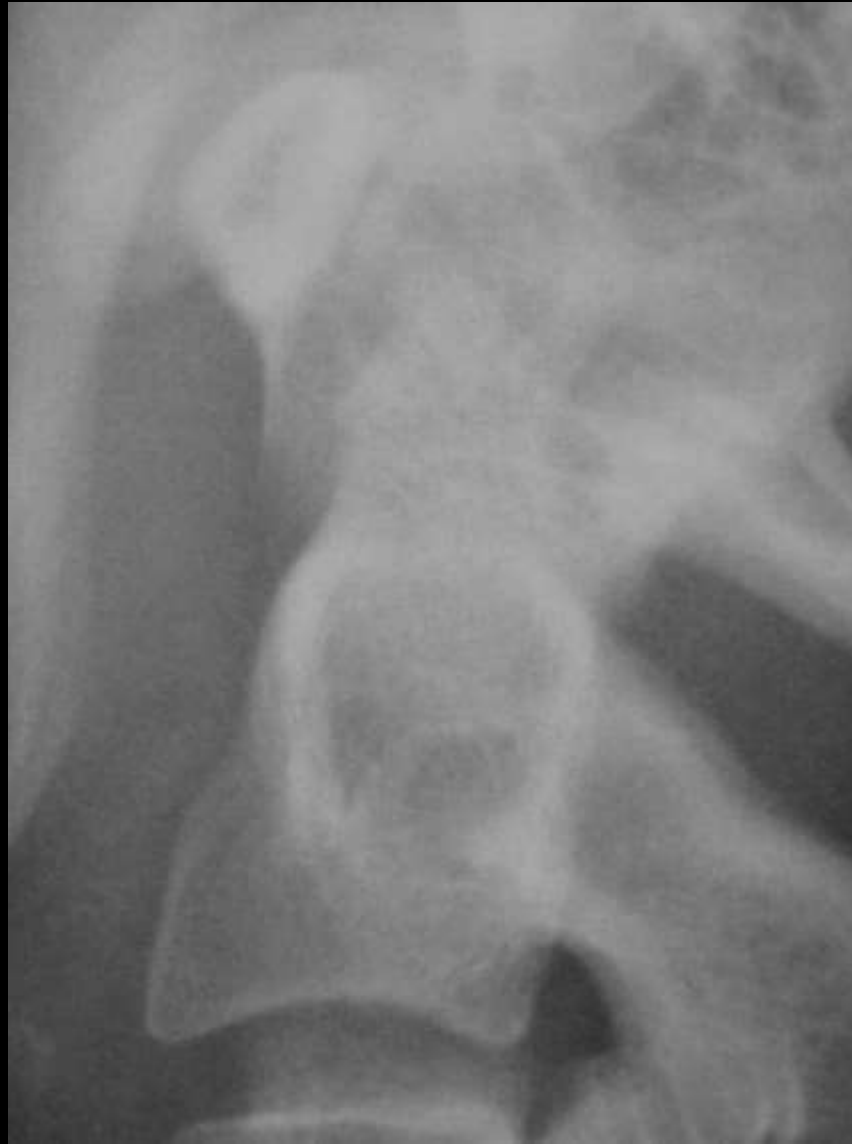Technique - Flex/Ext



Extension

Peg # hard to see 37M

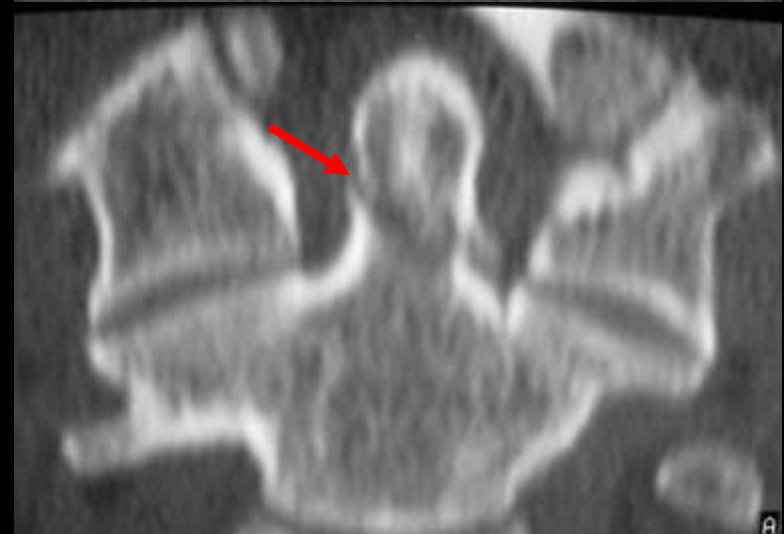
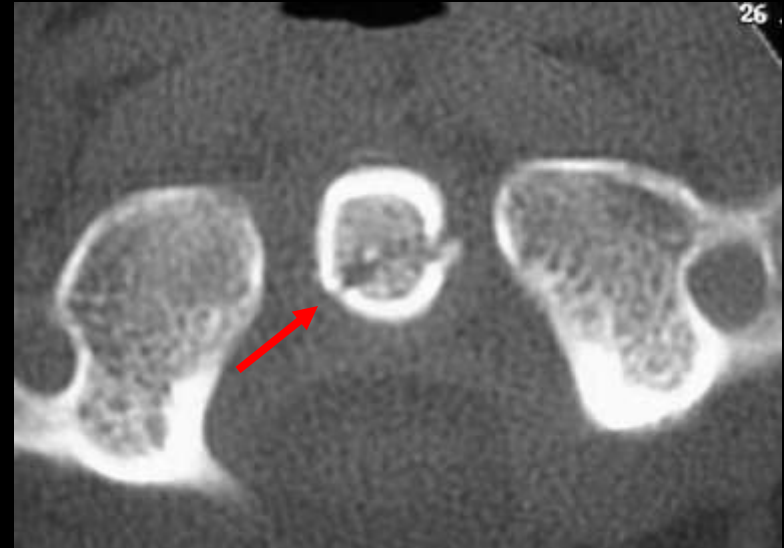
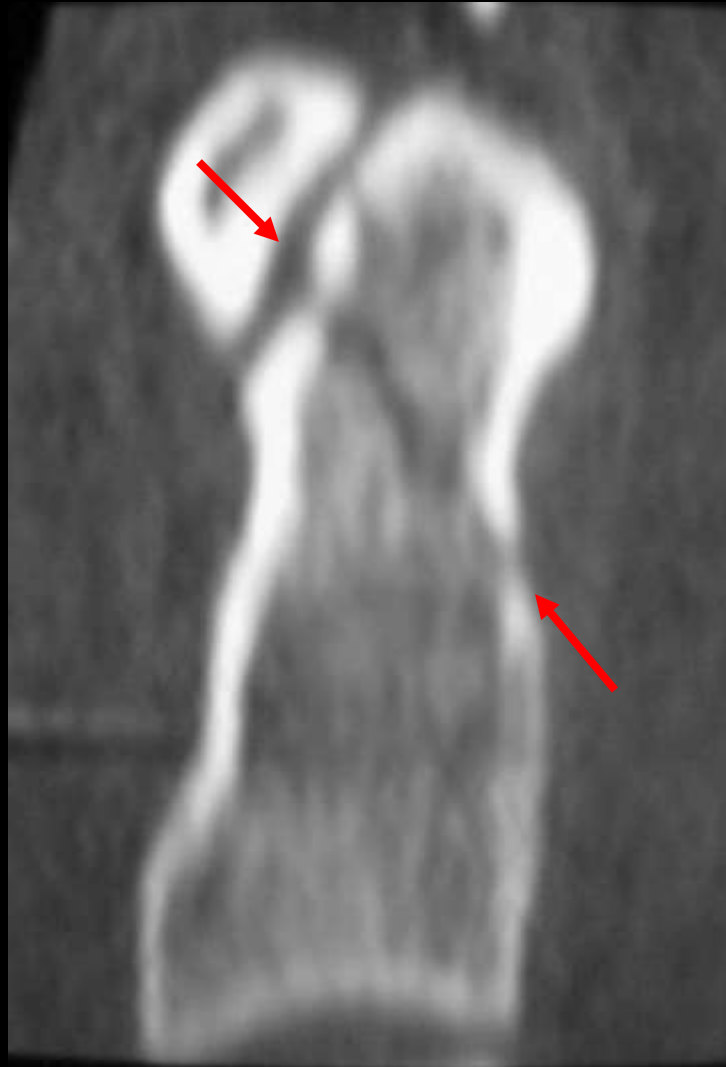Technique - Flex/Ext



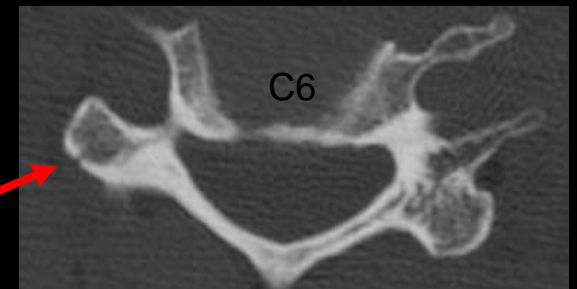
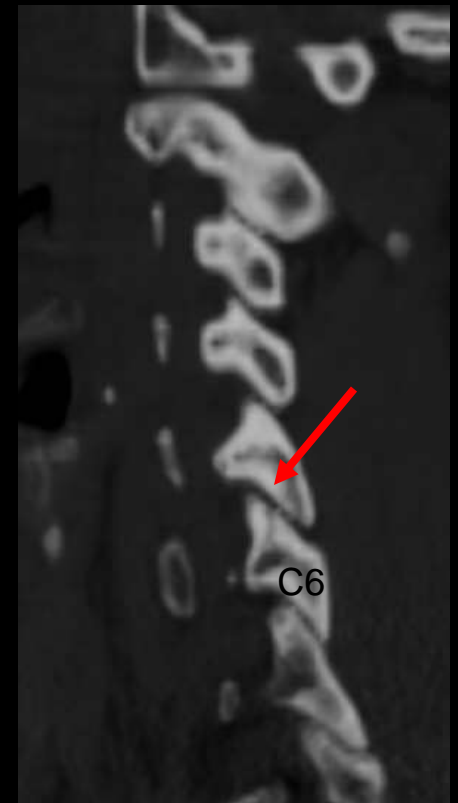
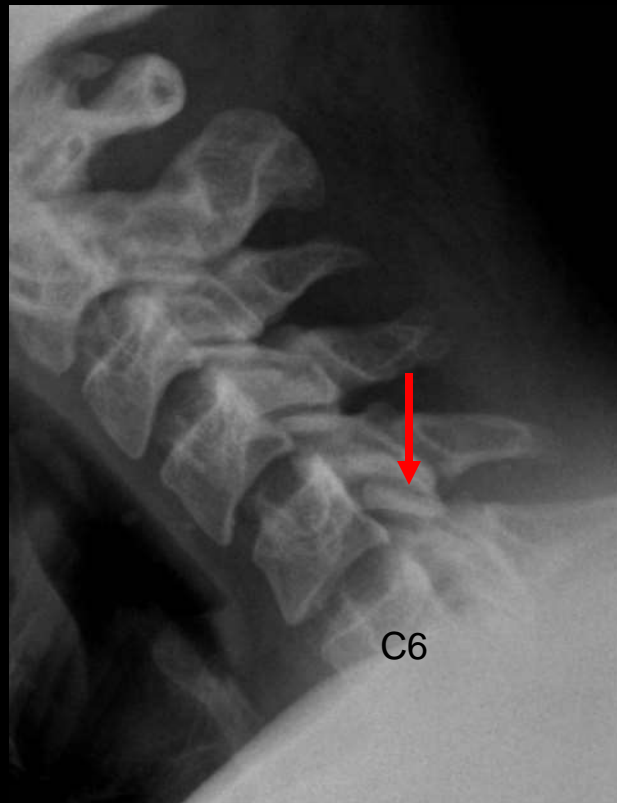
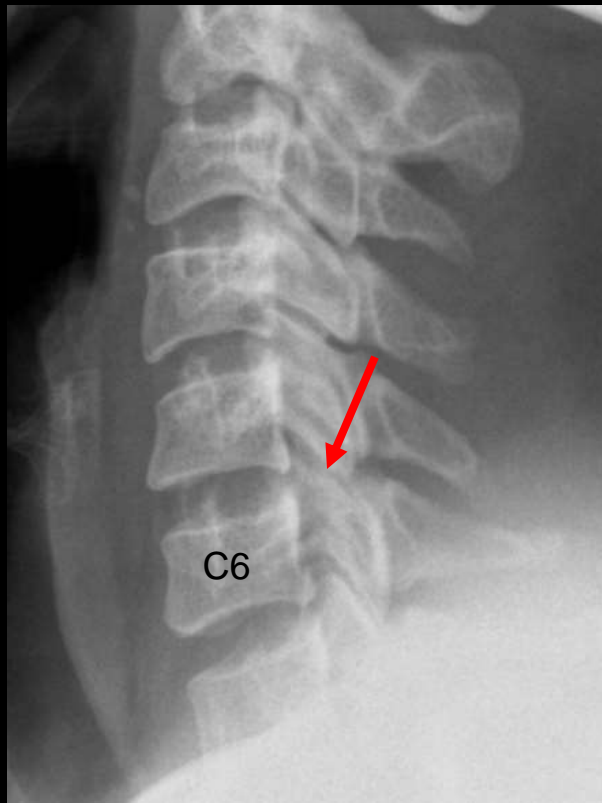
Flexion

Peg # hard to see 37M

Technique - Flex/Ext

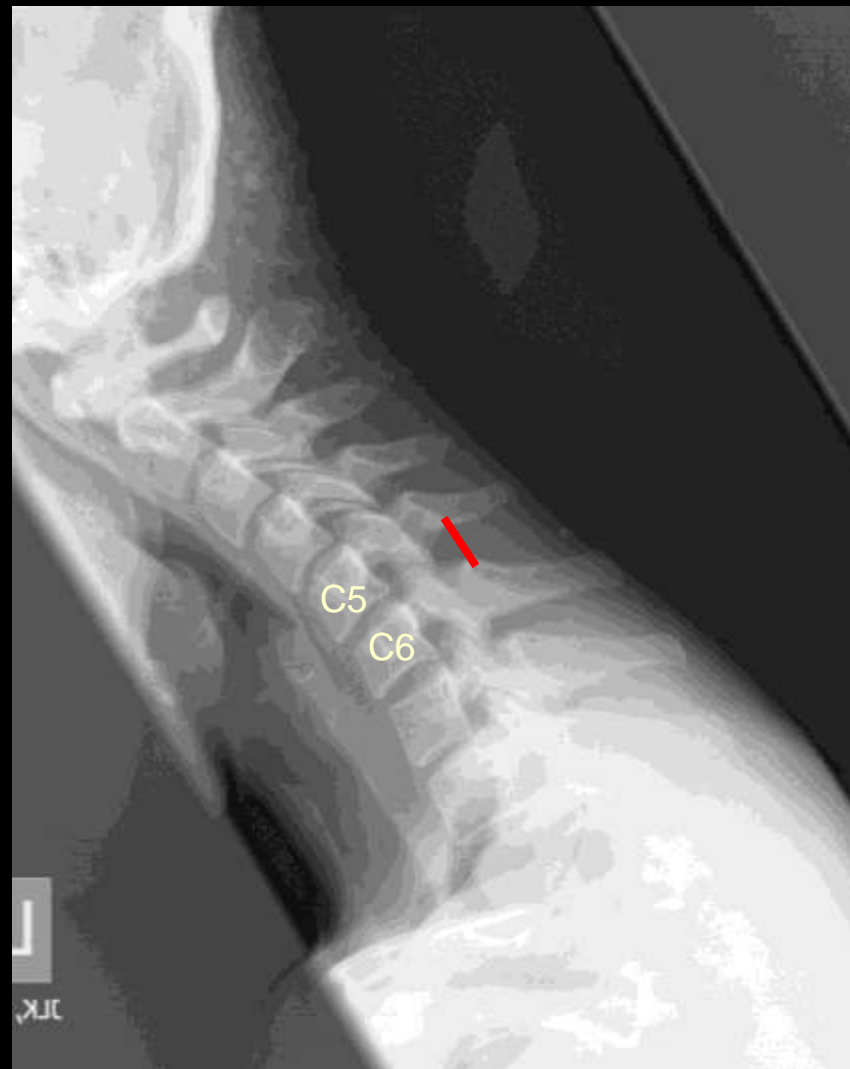
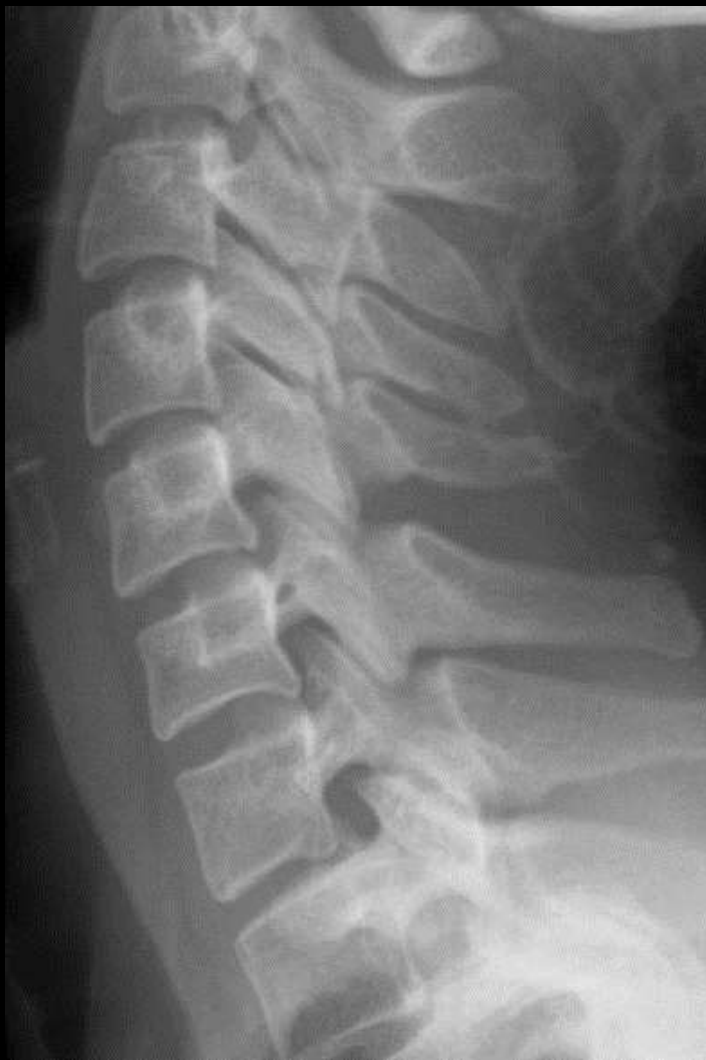
C6 fx with no motion on flex ext



C6 fx with no motion on flex ext 31M

Fixed C 5-6 alignment



Cx-Spine - Stability

- Instability is a function of ligamentous injury, or fracture pattern
- Can be inferred from radiographs for certain fracture patterns
- Not 100% accurate
 - Eg. Delayed flexion subluxation

Cx-Spine Stability

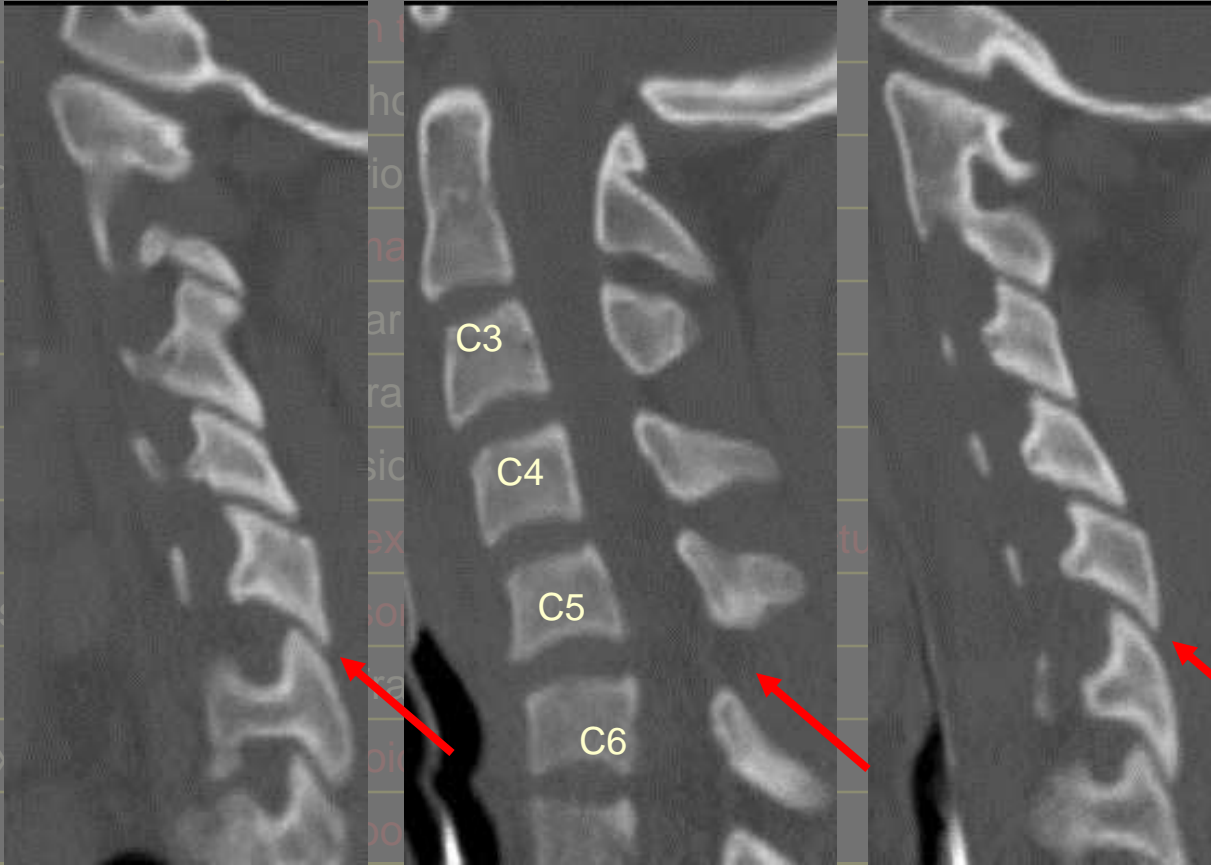
An unstable injury, is one which can progress and cause cord injury.

Flexion	Anterior Subluxation	Stable
	Unilateral facet dislocation	Stable
	Bilateral facet dislocation	Unstable
	Wedge compression fracture	Stable
	Flexion teardrop fracture	Unstable
	Clay-shoveler's fracture	Stable
Extension	Posterior arch C1 fracture	Stable
	Hangman's fracture	Unstable
	Laminar fracture	Stable
	Pillar fracture	Stable
	Extension teardrop fracture	Stable
	Hyperextension dislocation fracture	Unstable
Compression	Jefferson fracture	Unstable
	Burst fracture	Stable
Complex	Odontoid fractures	Unstable
	Atlantooccipital disassociation	Unstable

Cx-Spine Stability

An unstable injury, is one which can progress and cause cord injury.

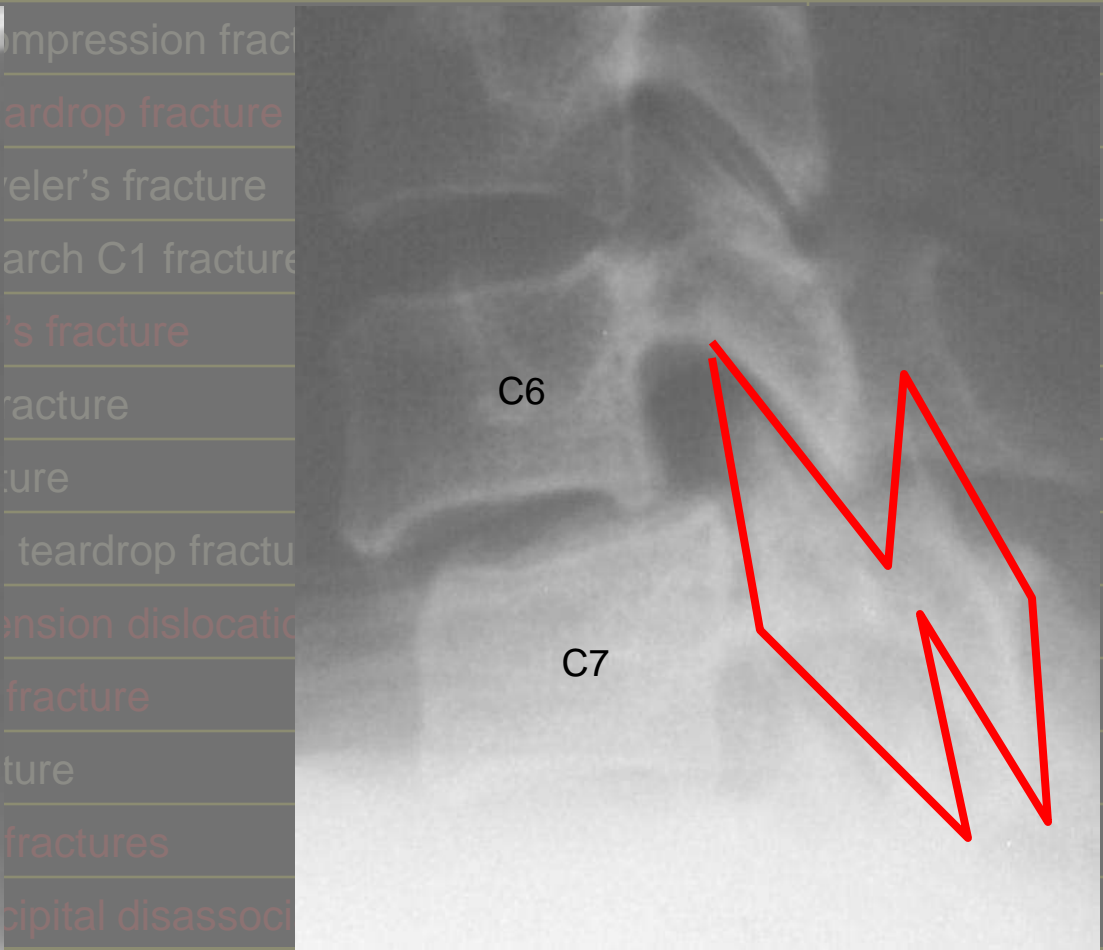
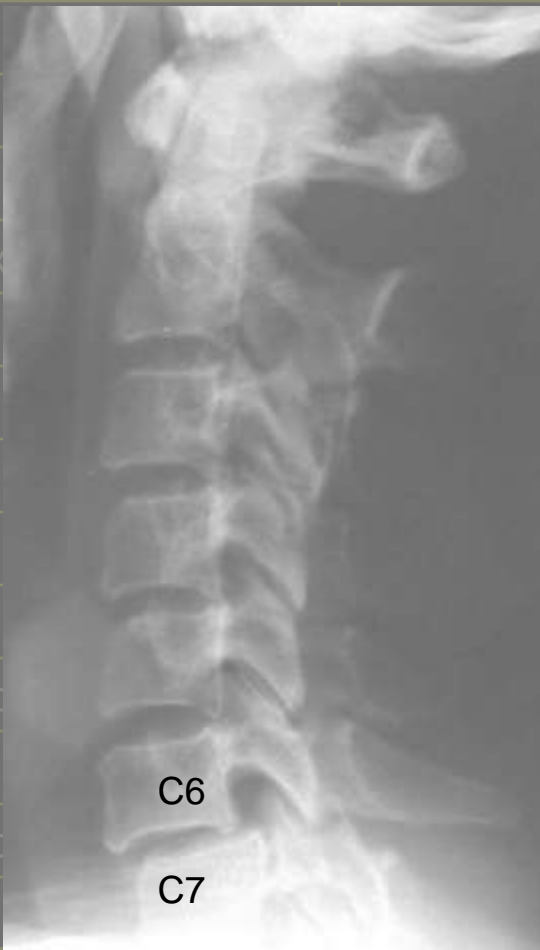Flexion	Anterior Subluxation	Stable
	Unilateral facet dislocation	Stable
	Bilateral facet dislocation	Unstable
	Wedge compression fracture	Stable
		Unstable
Extensio		Stable
		Stable
		Unstable
		Stable
		Stable
Compre		Unstable
		Unstable
Complex		Stable
		Unstable
		Unstable



Cx-Spine Stability

An unstable injury, is one which can progress and cause cord injury.

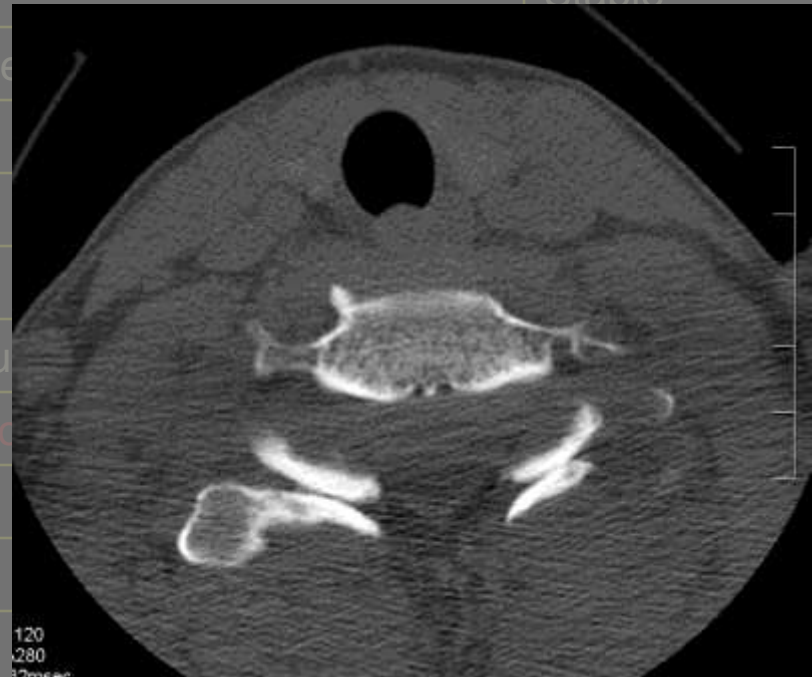
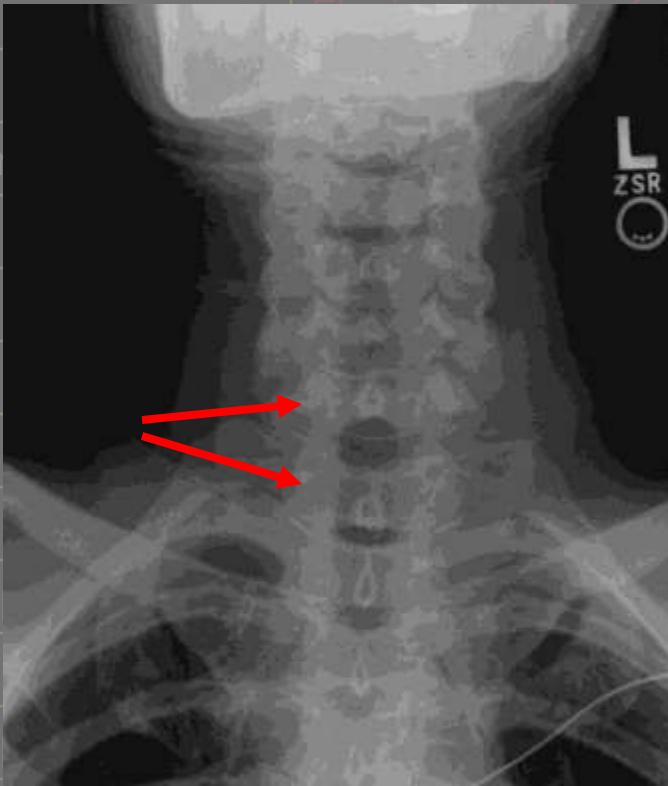
Flexion	Anterior Subluxation	Stable
	Unilateral facet dislocation	Stable
	Bilateral facet dislocation	Unstable



Cx-Spine Stability

An unstable injury, is one which can progress and cause cord injury.

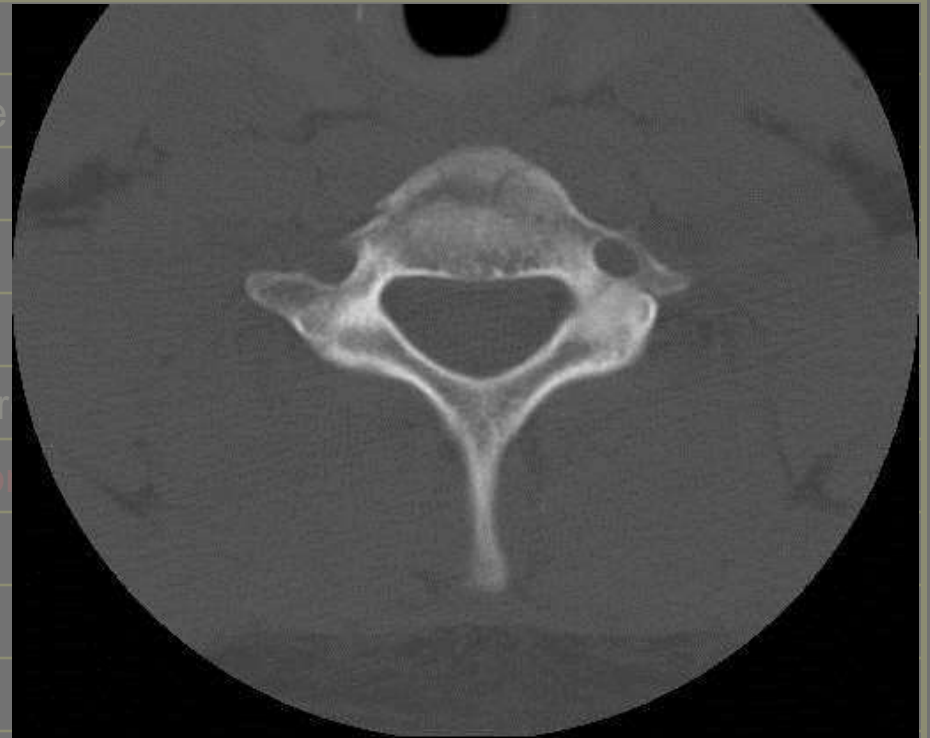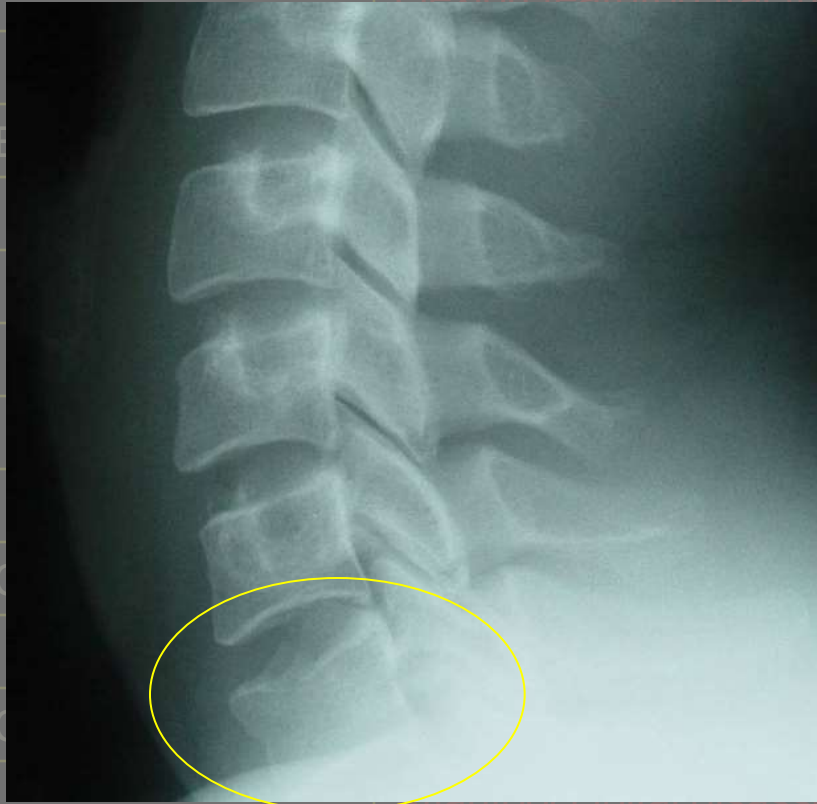
Flexion	Anterior Subluxation	Stable
	Unilateral facet dislocation	Stable
	Bilateral facet dislocation	Unstable
	Wedge compression fracture	Stable
	Extension fracture	Unstable
	Flexion fracture	Stable
Extension	Fracture	
Compression	Fracture	
Compression	Fracture	
	Atlantooccipital disassociation	
		C7-T1 Bifacet dislocations



Cx-Spine Stability

An unstable injury, is one which can progress and cause cord injury.

Flexion	Anterior Subluxation	Stable
	Unilateral facet dislocation	Stable
	Bilateral facet dislocation	Unstable
	Wedge compression fracture	Stable
	Flexion teardrop fracture	Unstable



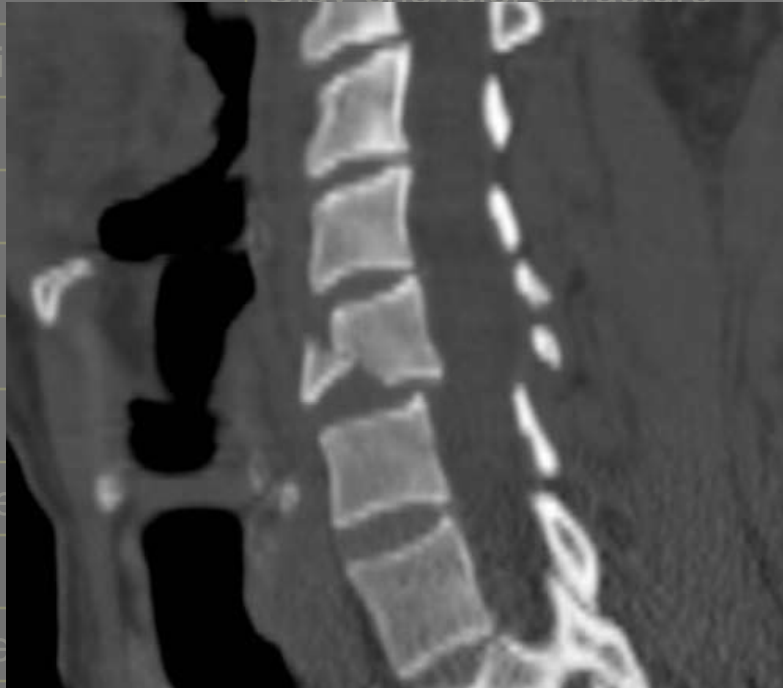
Atlantooccipital disassociation

Unstable

Cx-Spine Stability

An unstable injury, is one which can progress and cause cord injury.

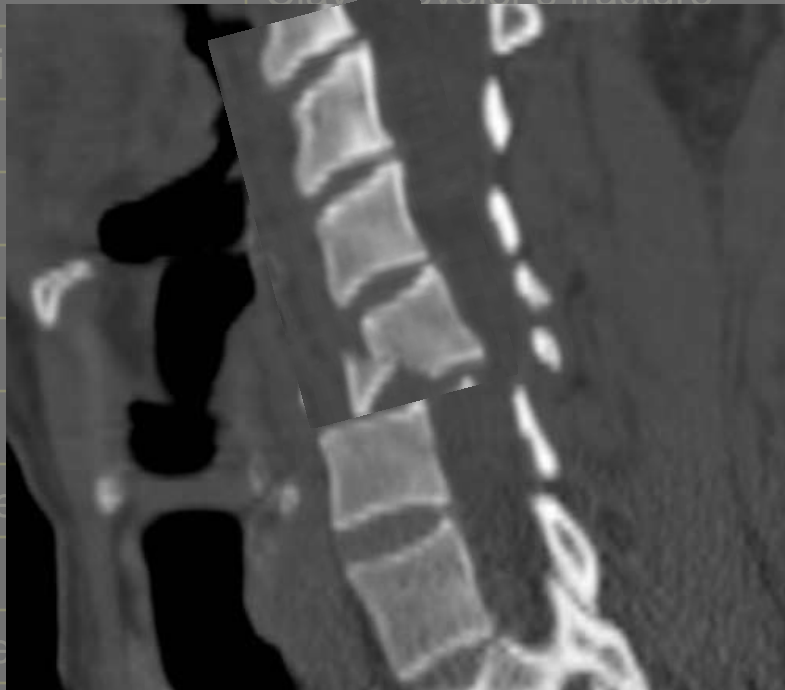Flexion	Anterior Subluxation	Stable
	Unilateral facet dislocation	Stable
	Bilateral facet dislocation	Unstable
	Wedge compression fracture	Stable
	Flexion teardrop fracture	Unstable
	Clay-shoveler's fracture	Stable
Extension		Stable
		Unstable
		Stable
		Stable
		Stable
	fracture	Unstable
Compression		Unstable
		Stable
Complete		Unstable
	Atlantooccipital disassociation	C5 flexion teardrop 38M



Cx-Spine Stability

An unstable injury, is one which can progress and cause cord injury.

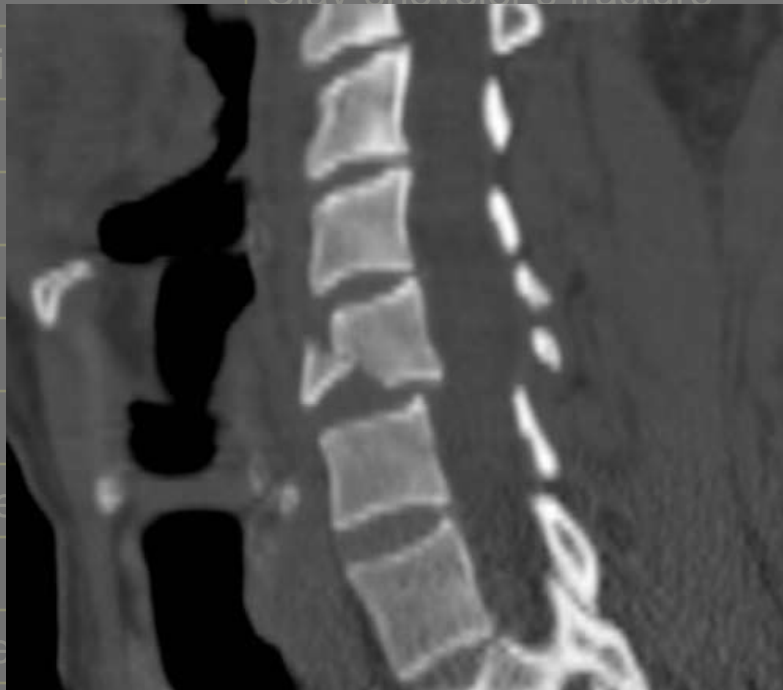Flexion	Anterior Subluxation	Stable
	Unilateral facet dislocation	Stable
	Bilateral facet dislocation	Unstable
	Wedge compression fracture	Stable
	Flexion teardrop fracture	Unstable
	Clay-shoveler's fracture	Stable
Extension		Stable
		Unstable
		Stable
		Stable
		Stable
	fracture	Unstable
Compression		Unstable
		Stable
Complete		Unstable
	Atlantooccipital disassociation	C5 flexion teardrop 38M



Cx-Spine Stability


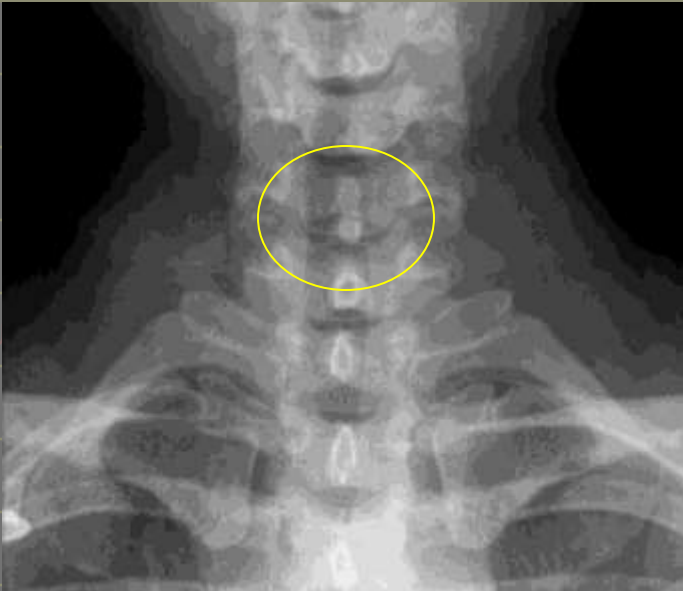
An unstable injury, is one which can progress and cause cord injury.

Flexion	Anterior Subluxation	Stable
	Unilateral facet dislocation	Stable
	Bilateral facet dislocation	Unstable
	Wedge compression fracture	Stable
	Flexion teardrop fracture	Unstable
	Clay-shoveler's fracture	Stable
Extension		Stable
		Unstable
		Stable
		Stable
		Stable
	fracture	Unstable
Compression		Unstable
		Stable
Complete		Unstable
	Atlantooccipital disassociation	C5 flexion teardrop 38M



Cx-Spine Stability

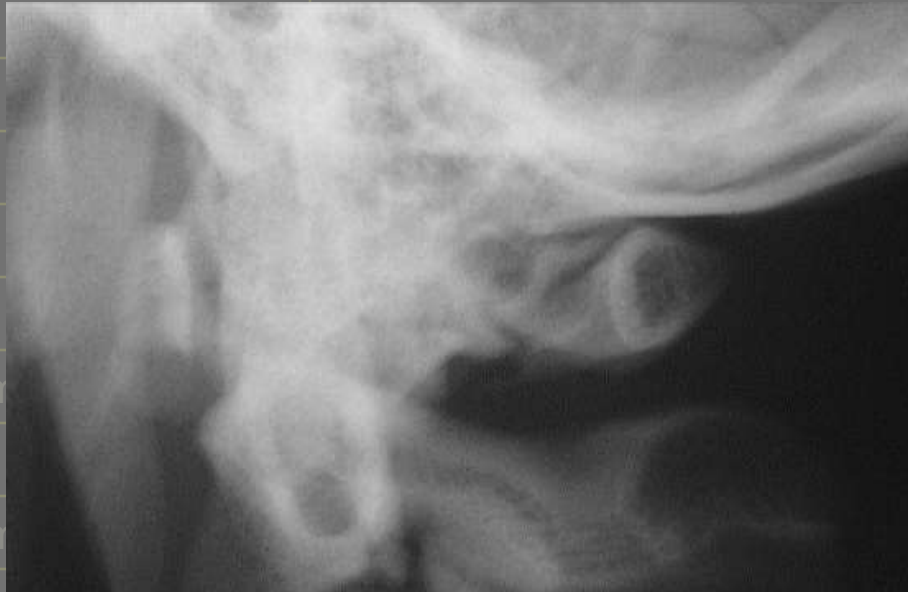An unstable injury, is one which can progress and cause cord injury.

Flexion	Anterior Subluxation	Stable
	Unilateral facet dislocation	Stable
	Bilateral facet dislocation	Unstable
	Wedge compression fracture	Stable
	Flexion teardrop fracture	Unstable
	Clay-shoveler's fracture	Stable
Extension	Posterior arch C1 fracture	Stable
		
	Atlantooccipital disassociation	Unstable

Cx-Spine Stability

An unstable injury, is one which can progress and cause cord injury.

Flexion	Anterior Subluxation	Stable
	Unilateral facet dislocation	Stable
	Bilateral facet dislocation	Unstable
	Wedge compression fracture	Stable
	Flexion teardrop fracture	Unstable
	Clay-shoveler's fracture	Stable
Extension	Posterior arch C1 fracture	Stable

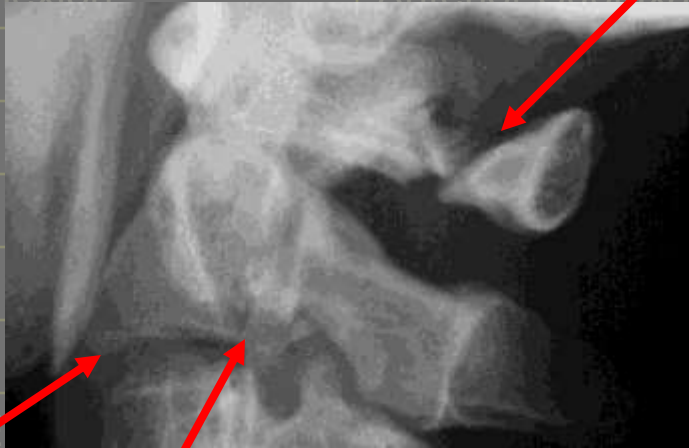

Atlantooccipital disassociation

Cx-Spine Stability

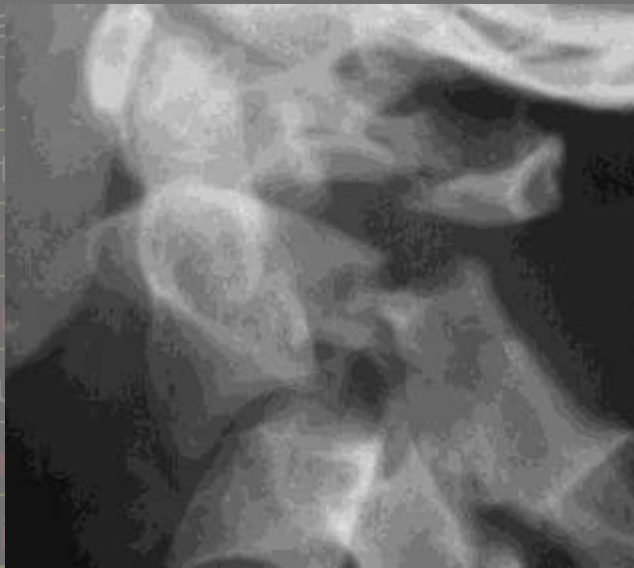An unstable injury, is one which can progress and cause cord injury.

Also C2 teardrop and C1 posterior arch suggesting hyperextension



Hangman's fracture

Unstable



Laminar fracture

Stable

Pillar fracture

Stable

Extension fracture

Stable

Hyperextension fracture

Unstable

Compression

Jefferson fracture

Unstable

Burst fracture

Stable

Complex

Odontoid fracture

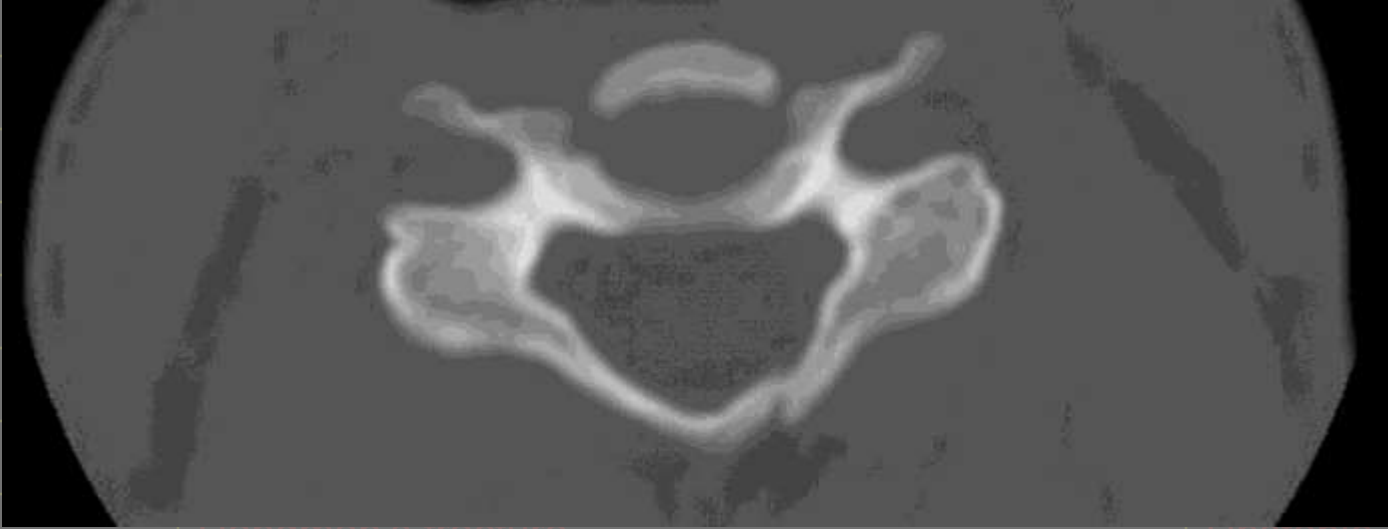
Unstable

Atlantooccipital

Unstable Posterior arch C1 Fr

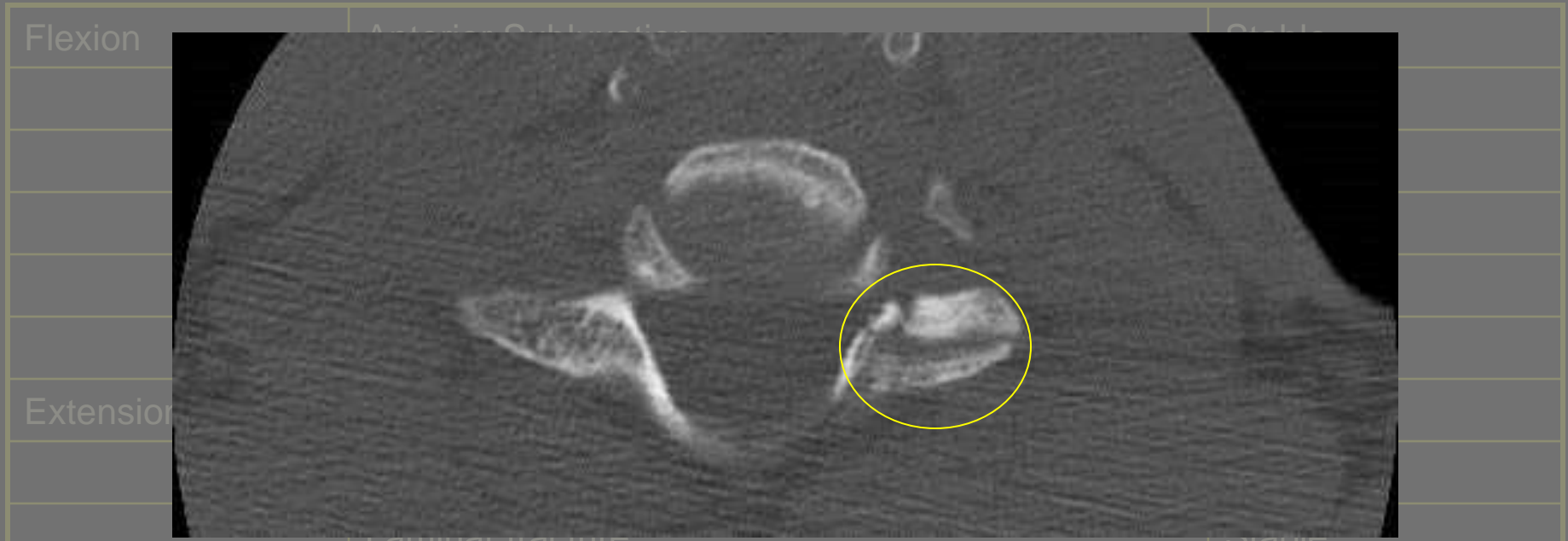
Cx-Spine Stability

An unstable injury, is one which can progress and cause cord injury.

Flexion		Unstable
Extension		Stable
	Laminar fracture	Stable
	Pillar fracture	Stable
	Extension teardrop fracture	Stable
	Hyperextension dislocation fracture	Unstable
Compression	Jefferson fracture	Unstable
	Burst fracture	Stable
Complex	Odontoid fractures	Unstable
	Atlantooccipital disassociation	Unstable

Cx-Spine Stability



An unstable injury, is one which can progress and cause cord injury.



Flexion	Anterior Subluxation	Stable
Extension	Lamina fracture	Stable
	Pillar fracture	Stable
	Extension teardrop fracture	Stable
	Hyperextension dislocation fracture	Unstable
Compression	Jefferson fracture	Unstable
	Burst fracture	Stable
Complex	Odontoid fractures	Unstable
	Atlantooccipital disassociation	Unstable



Cx-Spine Stability

An unstable injury, is one which can progress and cause cord injury.

Flexion		
Extension		
	Hyperextension dislocation fracture	Unstable
Compression	Jefferson fracture	Unstable
	Burst fracture	Stable
Complex	Odontoid fractures	Unstable
	Atlantooccipital disassociation	Unstable


Cx-Spine Stability

An unstable injury, is one which can progress and cause cord injury.

Flexion	Anterior Subluxation	Stable
	Unilateral facet dislocation	Stable
		
	Pillar fracture	Stable
	Extension teardrop fracture	Stable
	Hyperextension dislocation fracture	Unstable
Compression	Jefferson fracture	Unstable
	Burst fracture	Stable
Complex	Odontoid fractures	Unstable
	Atlantooccipital disassociation	

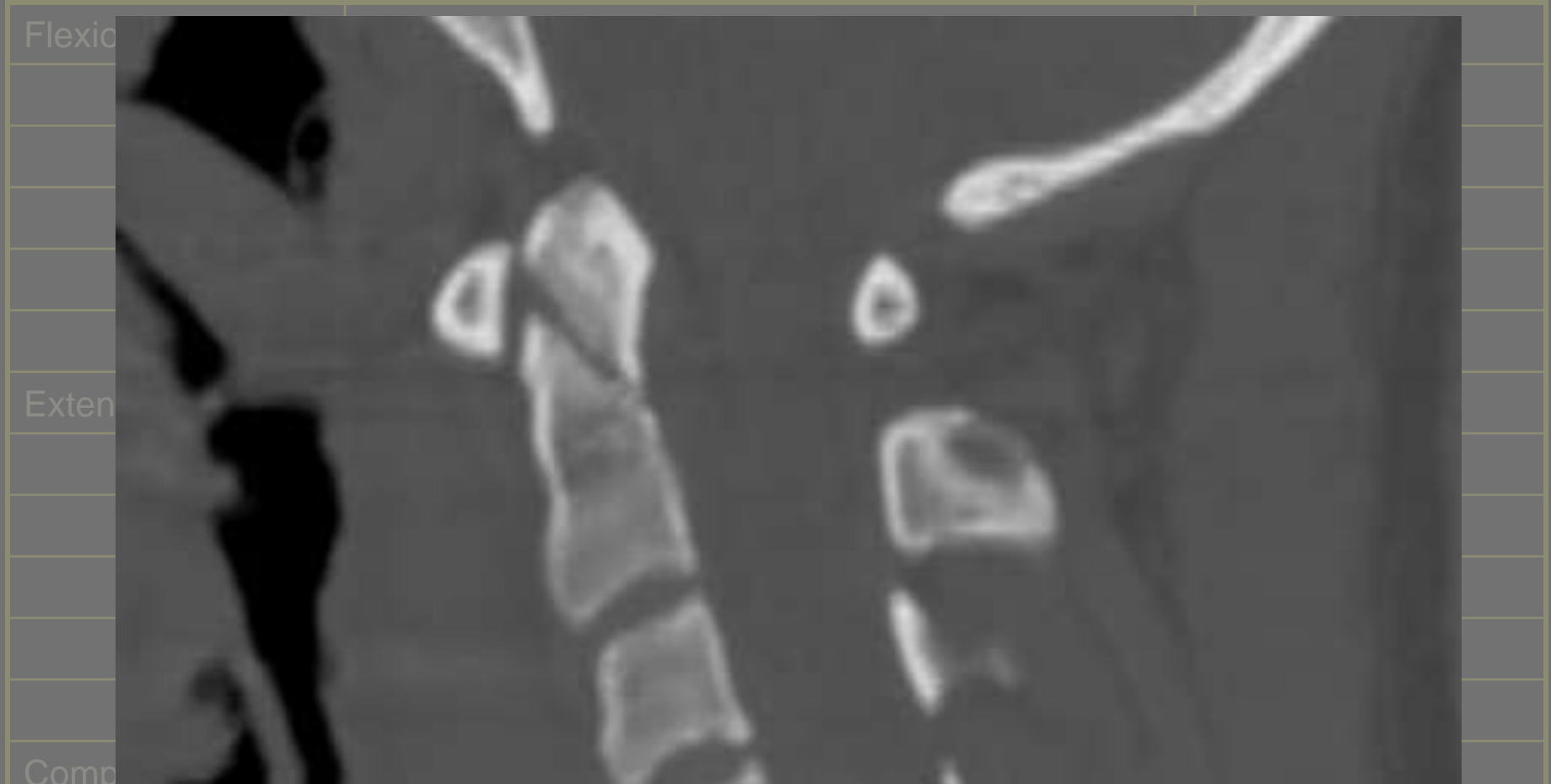Cx-Spine Stability

An unstable injury, is one which can progress and cause cord injury.

Flexion	Ante		Stable
	Unil		Stable
	Bilat		Unstable
	Wec		Stable
	Flex		Unstable
	Clay		Stable
Extension	Pos		Stable
	Han		Unstable
	Lam		Stable
	Pilla		Stable
	Exte		Stable
	Hyp		Unstable
Compression	Jefferson fracture		Unstable
	Burst fracture	Stable	
Complex	Odontoid fractures	Unstable	
	Atlantooccipital disassociation	Unstable	

Cx-Spine Stability

An unstable injury, is one which can progress and cause cord injury.



Burst fracture

Stable

Complex

Odontoid fractures

Unstable

Atlantooccipital disassociation

Unstable

22M MVA

Cx-Spine Stability

An unstable injury, is one which can progress and cause cord injury.

Flexion	Anterior Subluxation	Stable
		
Complex	Odontoid fractures	Unstable
	Atlantooccipital disassociation	Unstable

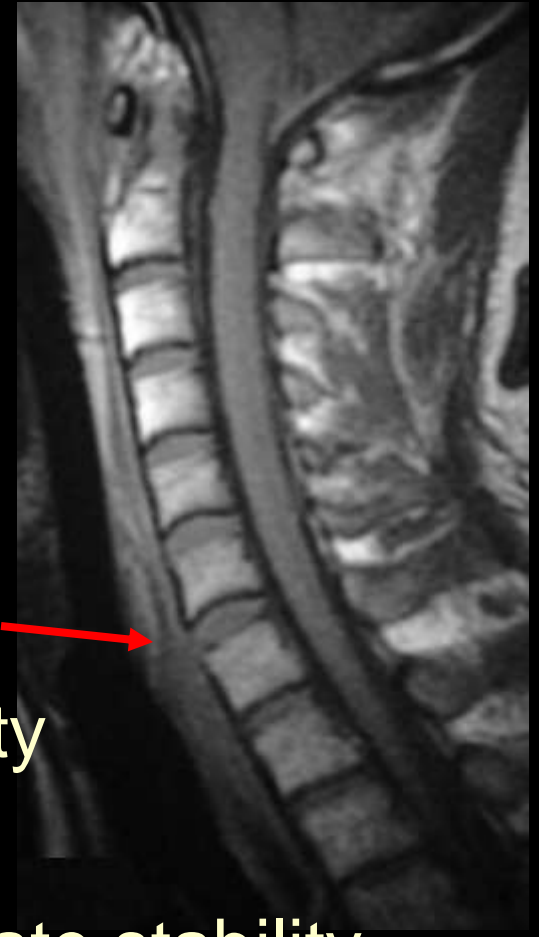Cx-Spine Stability

An unstable injury, is one which can progress and cause cord injury.

Flexion	Anterior Subluxation	Stable
	Unilateral facet dislocation	Stable
	Bilateral facet dislocation	Unstable
	Wedge compression fracture	Stable
	Flexion teardrop fracture	Unstable
	Clay-shoveler's fracture	Stable
Extension	Posterior arch C1 fracture	Stable
	Hangman's fracture	Unstable
	Laminar fracture	Stable
	Pillar fracture	Stable
	Extension teardrop fracture	Stable
	Hyperextension dislocation fracture	Unstable
Compression	Jefferson fracture	Unstable
	Burst fracture	Stable
Complex	Odontoid fractures	Unstable
	Atlantooccipital disassociation	Unstable

Cx-Spine - Stability

- MRI
 - Shows
 - Edema of soft tissues
 - Paravertebral hematoma
 - Ligamentous disruption
 - Still does not indicate instability
 - Negative study does not indicate stability

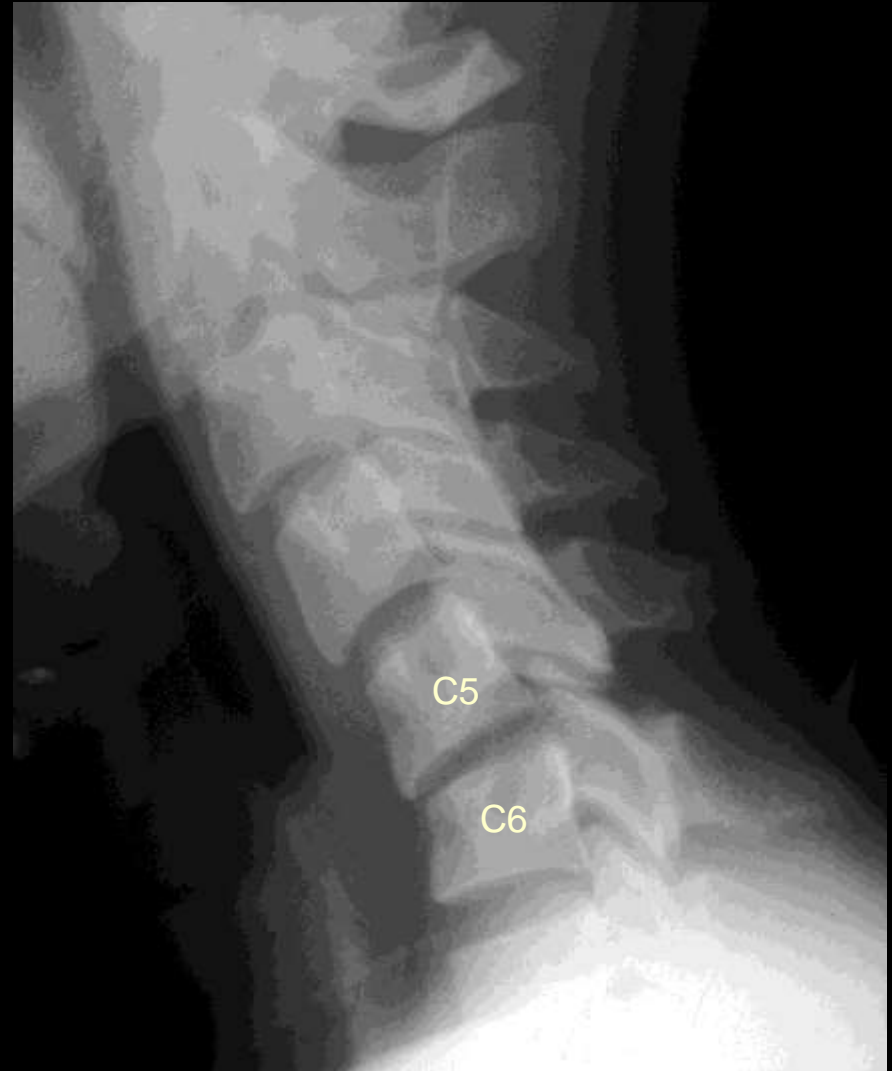

Cx-Spine - Stability

- Flexion Extension views
 - Patient should be erect
 - Should wait 2w for spasm to resolve
 - Must see to T1
 - Must move > 30 degrees

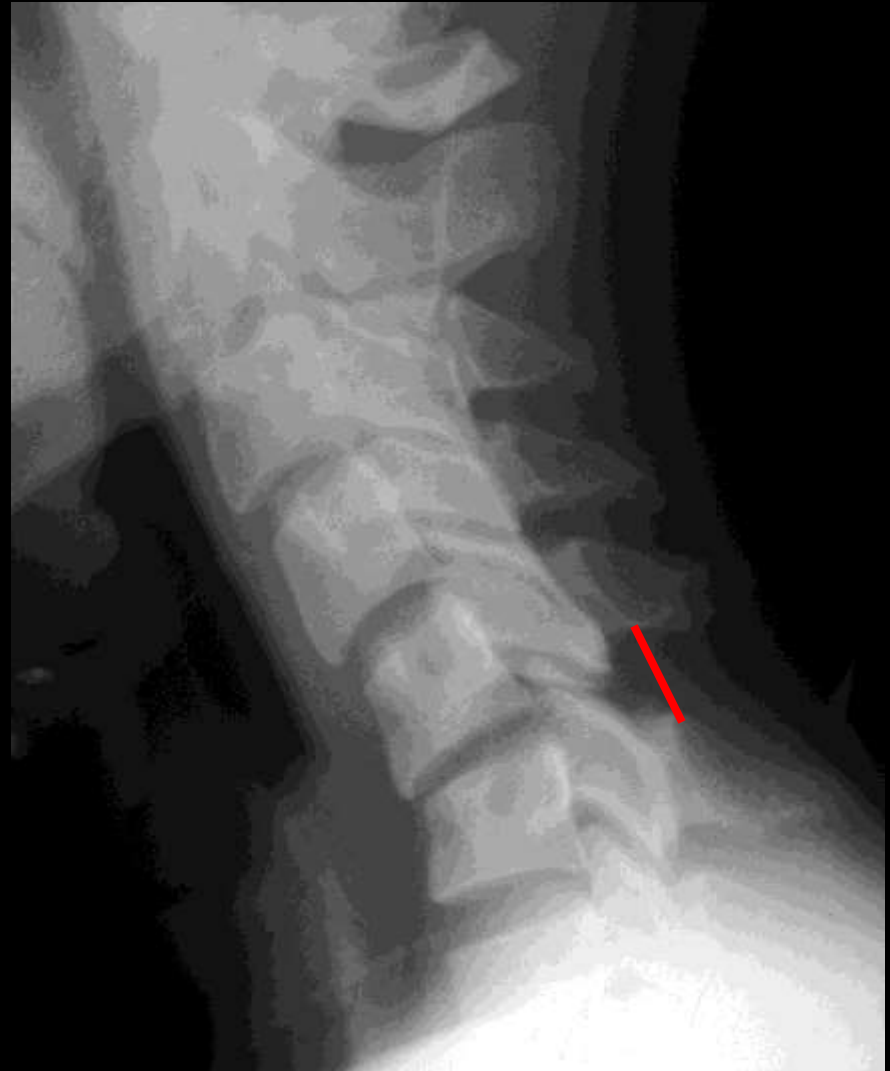Ligament injury

- Increased interlaminar distance
- Facet joint widening
- Focal kyphosis $>24^\circ$ on F/E
- Kyphosis $> 11^\circ$ compared to adjacent levels
- Incongruent disk space, posterior widening
- >3.5 mm anterolisthesis



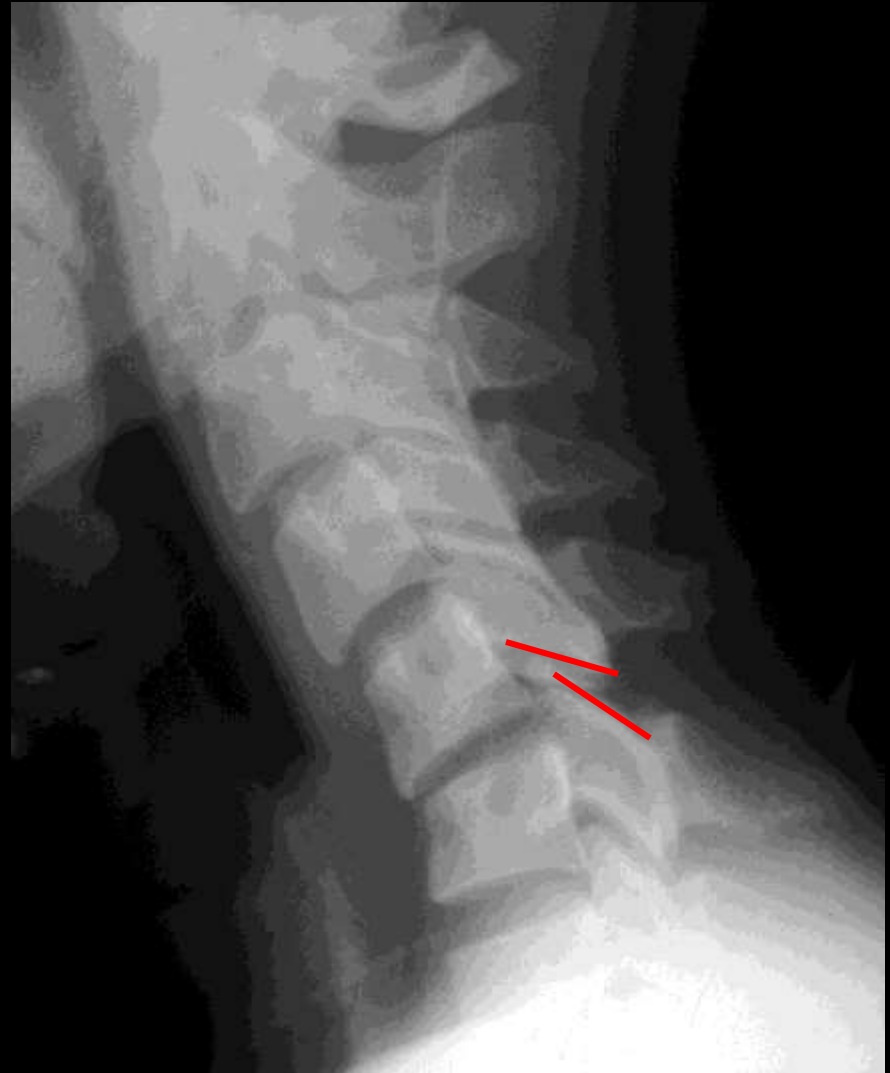Ligament injury

- Increased interlaminar distance
- Facet joint widening.
- Focal kyphosis $>24^\circ$ on F/E
- Kyphosis $> 11^\circ$ compared to adjacent levels
- Incongruent disk space, posterior widening
- >3.5 mm anterolisthesis



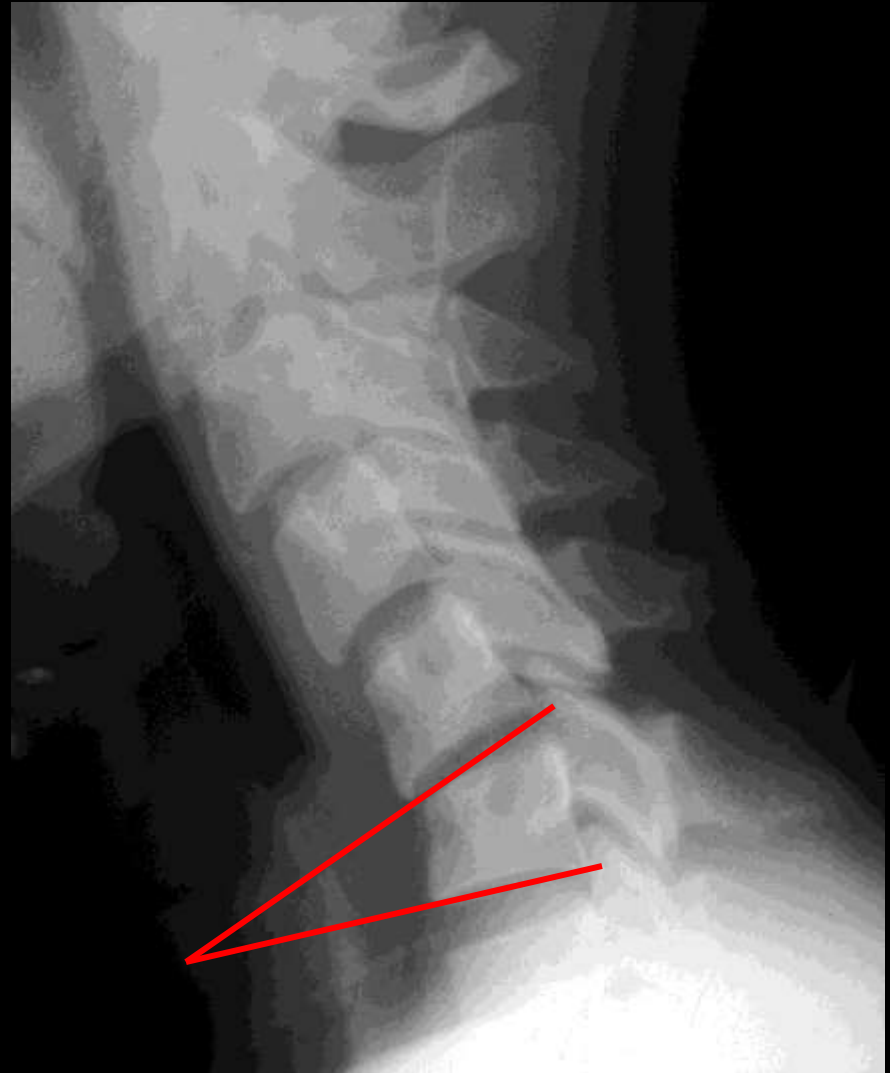Ligament injury

- Increased interlaminar distance
- Facet joint widening
- Focal kyphosis $>24^\circ$ on F/E.
- Kyphosis $> 11^\circ$ compared to adjacent levels
- Incongruent disk space, posterior widening
- >3.5 mm anterolisthesis



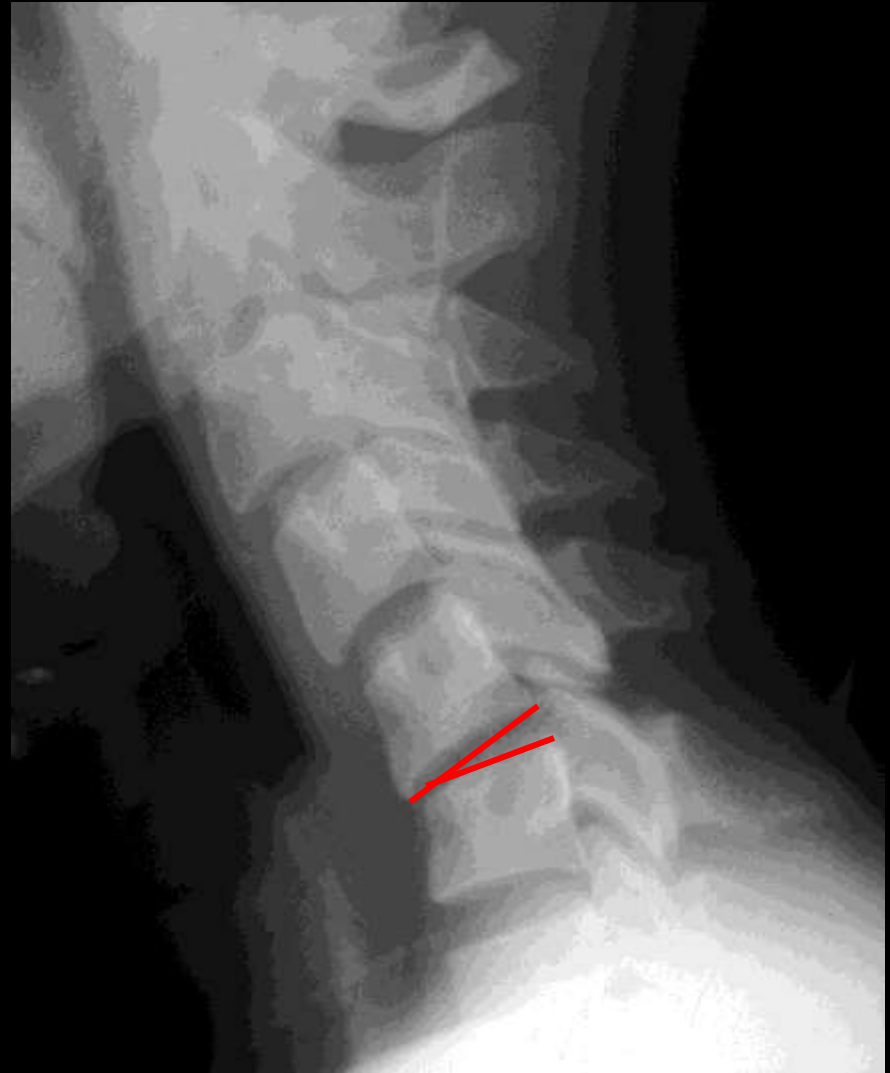Ligament injury

- Increased interlaminar distance
- Facet joint widening
- Focal kyphosis $>24^\circ$ on F/E
- Kyphosis $> 11^\circ$ compared to adjacent levels
- Incongruent disk space, posterior widening.
- >3.5 mm anterolisthesis



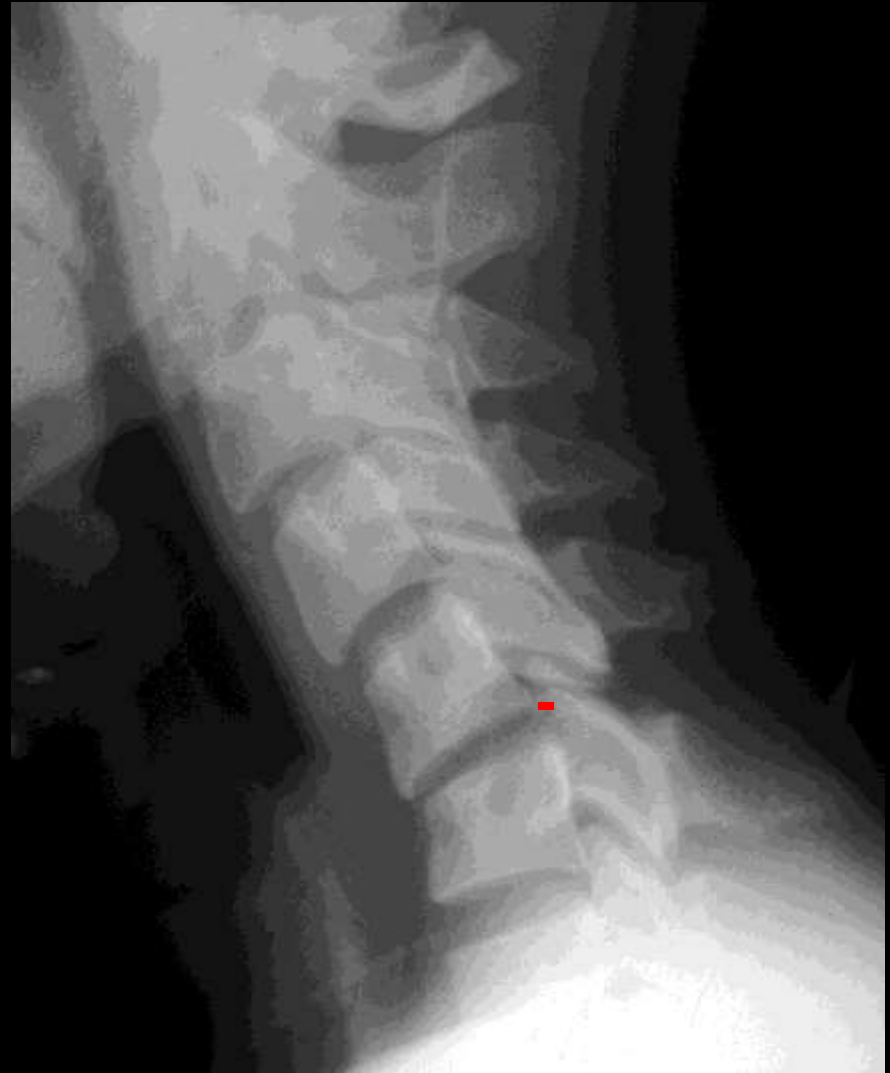Ligament injury

- Increased interlaminar distance
- Facet joint widening
- Focal kyphosis $>24^\circ$ on F/E
- Kyphosis $> 11^\circ$ compared to adjacent levels
- Incongruent disk space, posterior widening
- >3.5 mm anterolisthesis.



Ligament injury

- Increased interlaminar distance
- Facet joint widening
- Focal kyphosis $>24^\circ$ on F/E
- Kyphosis $> 11^\circ$ compared to adjacent levels
- Incongruent disk space, posterior widening
- >3.5 mm anterolisthesis

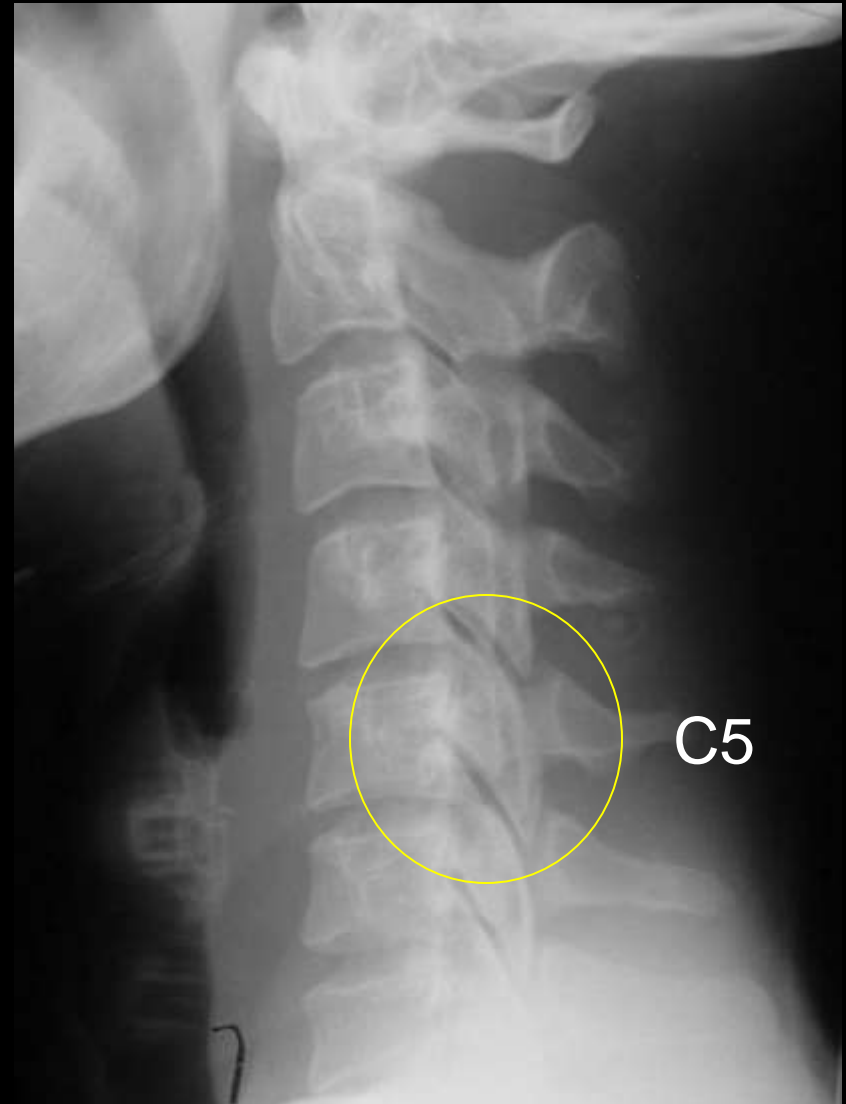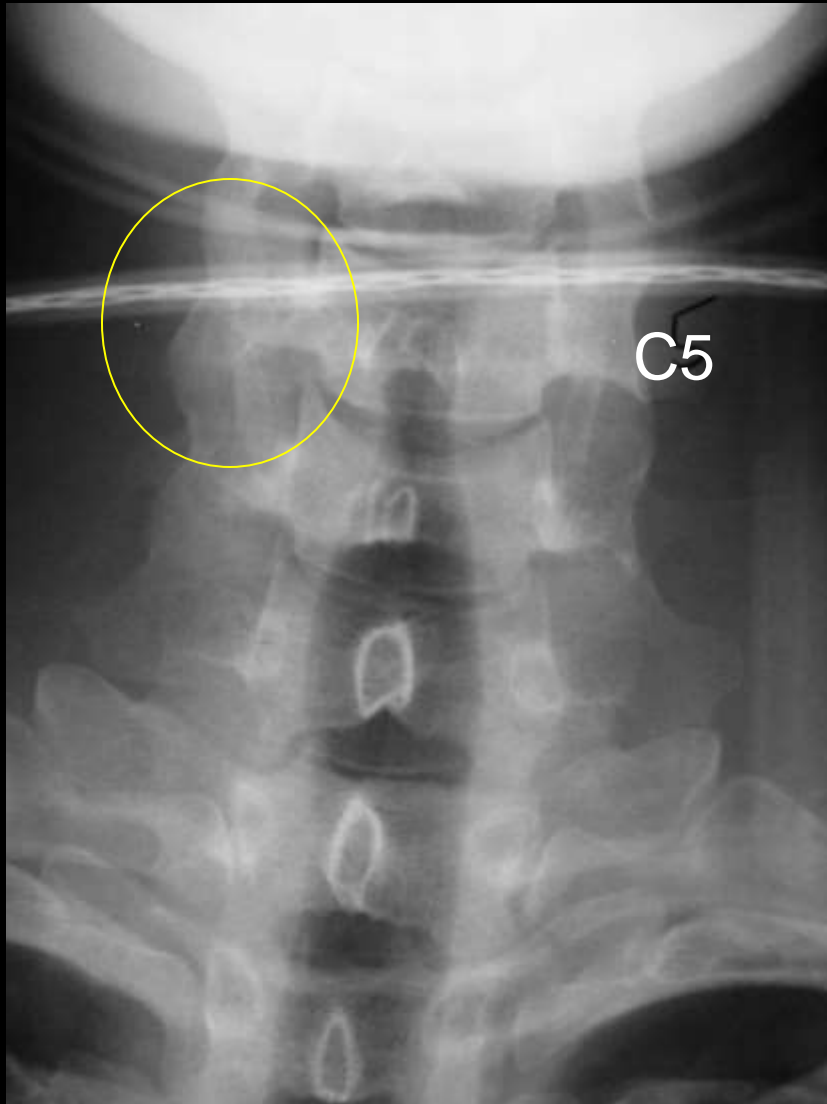


White/Panjabi - C-spine Instability

- White & Panjabi criteria:
 - Anterior elements destroyed = 2
 - Posterior elements destroyed = 2
- Flexion/Extension
 - Sagittal translation > 3.5 mm or 20% of vertebra = 2
 - Sagittal plane rotation >24° =2
- Resting x-rays
 - Sagittal translation > 3.5 mm or 20% of vertebra = 2
 - Sagittal rotation > 11° = 2
 - Abnormal disc narrowing = 1
 - Narrow canal <13mm or Pavlov's ratio <.8 =1
 - - Positive stretch test = 2
 - Cord damage = 2
 - Root damage = 1
 - Dangerous loads anticipated = 1
- Unstable if total score > 5



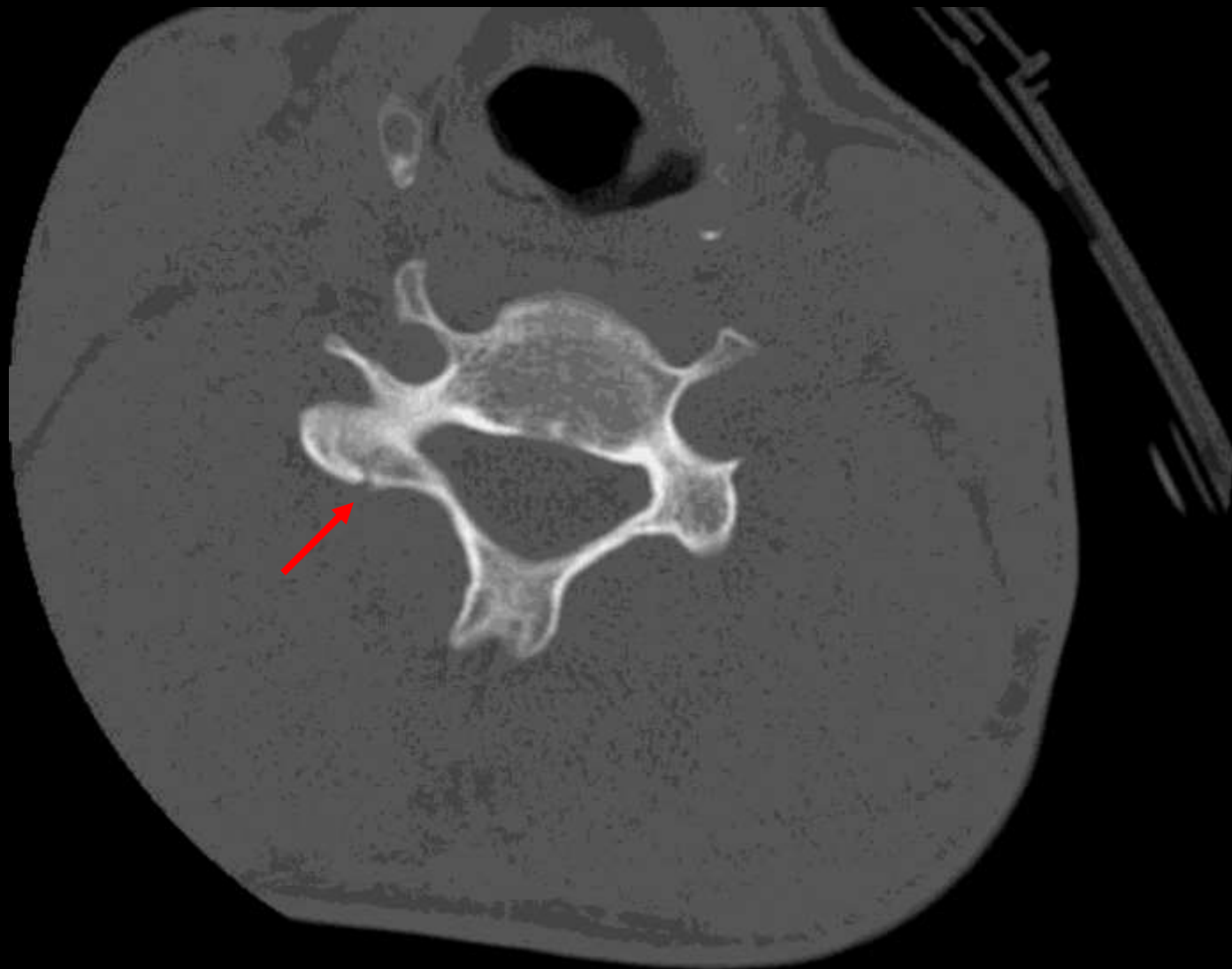Comparing Techniques



1+5+5+5

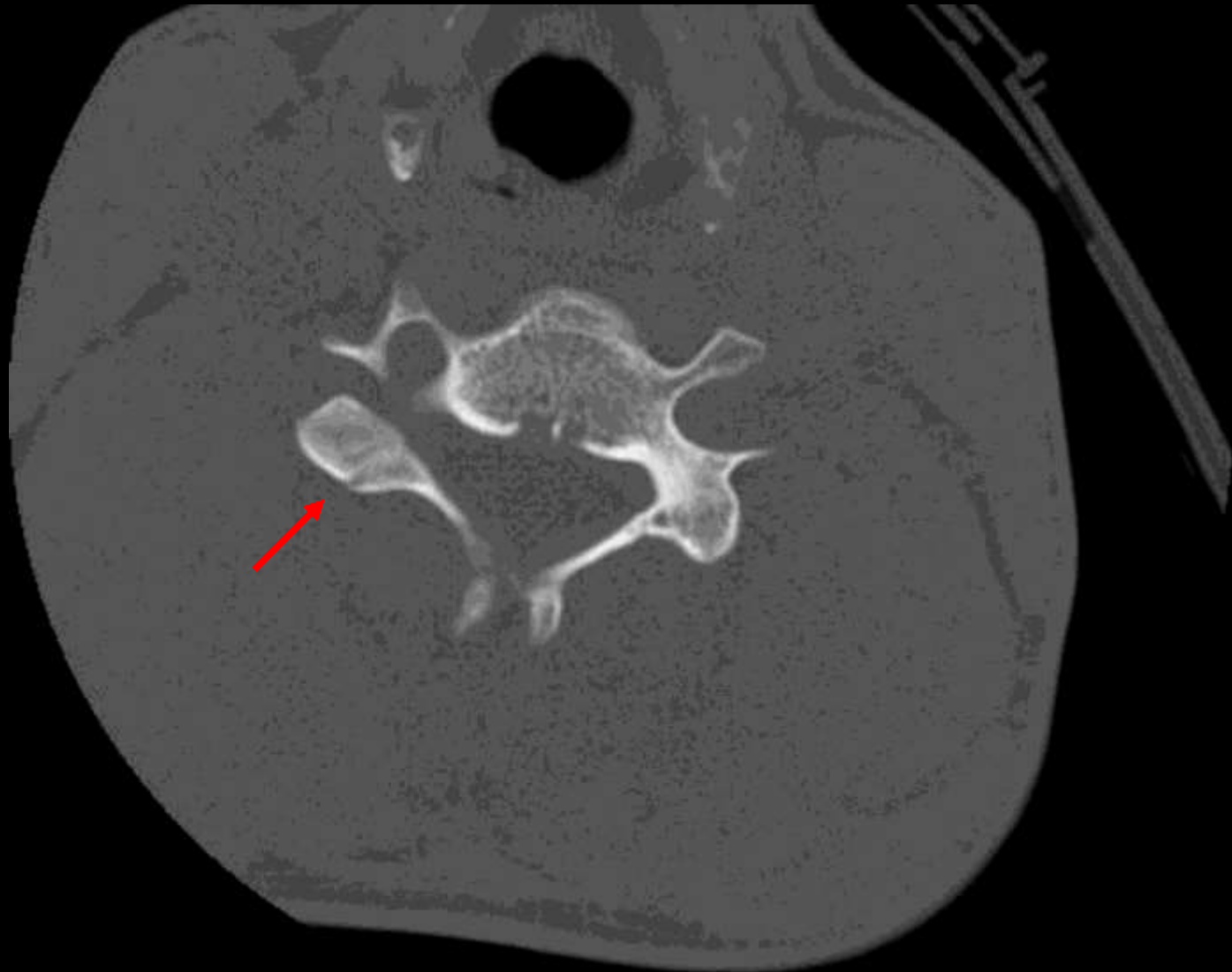
C5 inferior facet Fracture not seen on X-ray

Comparing Techniques



C5

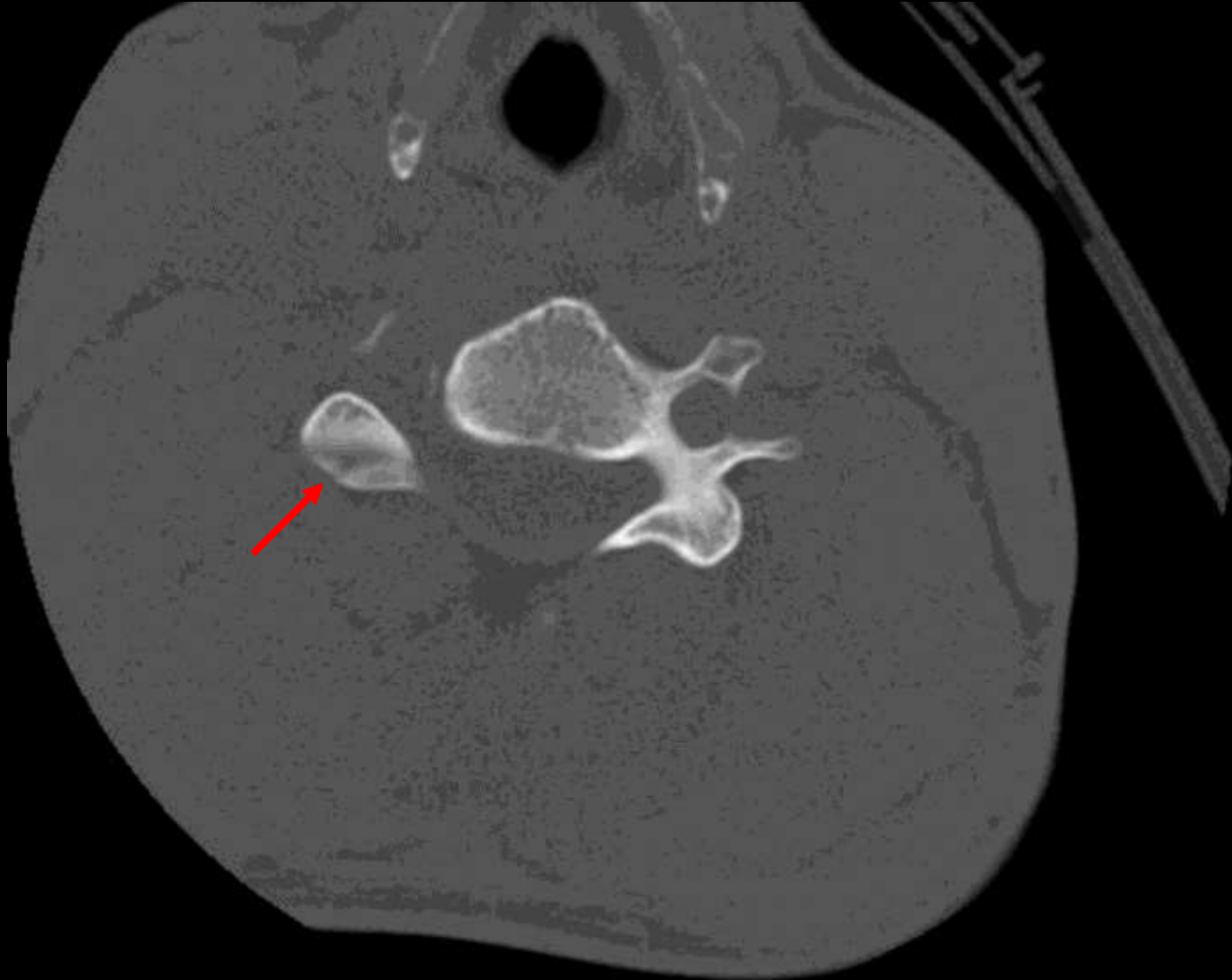Comparing Techniques



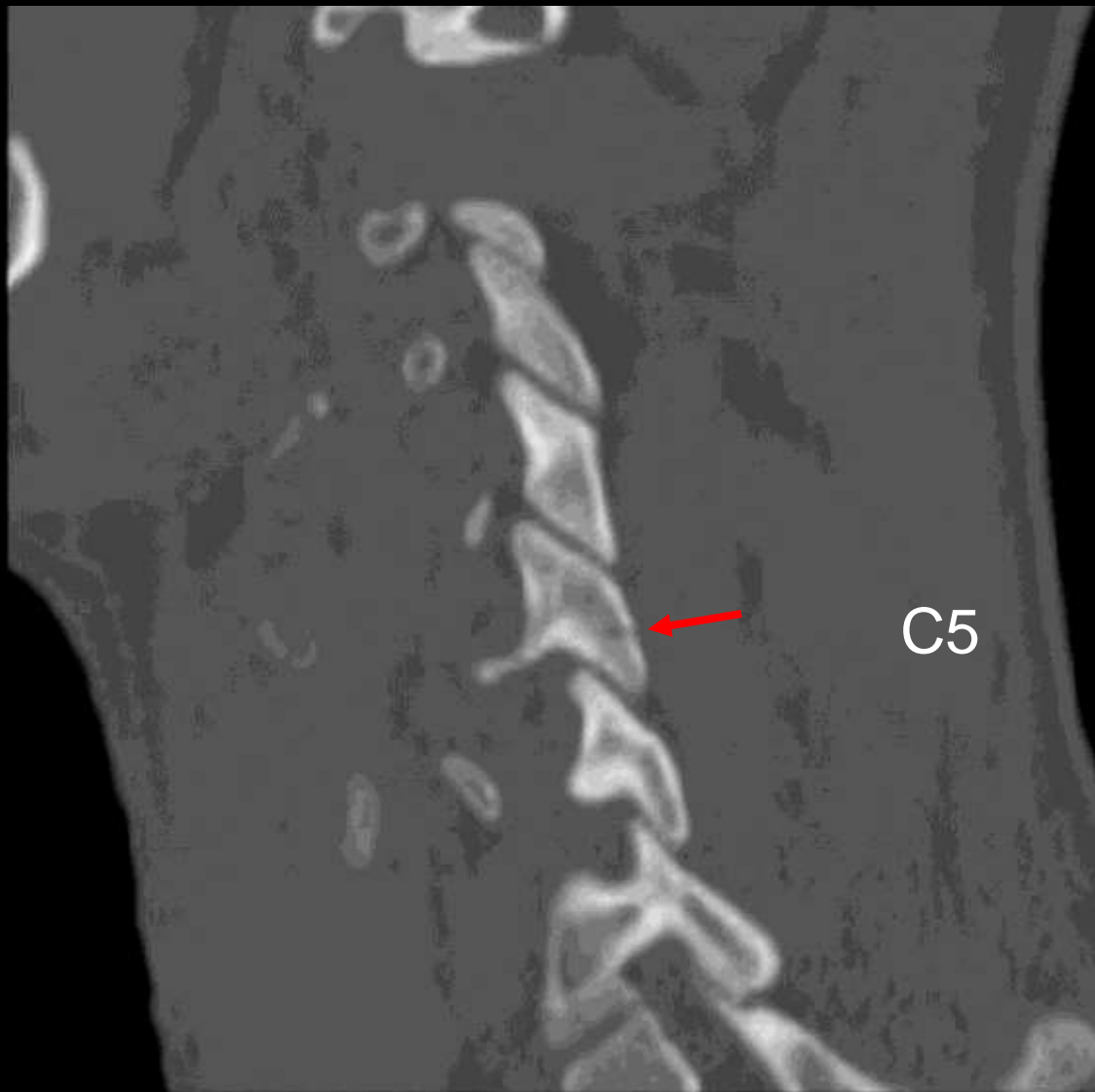C5

C5 inferior facet Fracture not seen on X-ray

Comparing Techniques

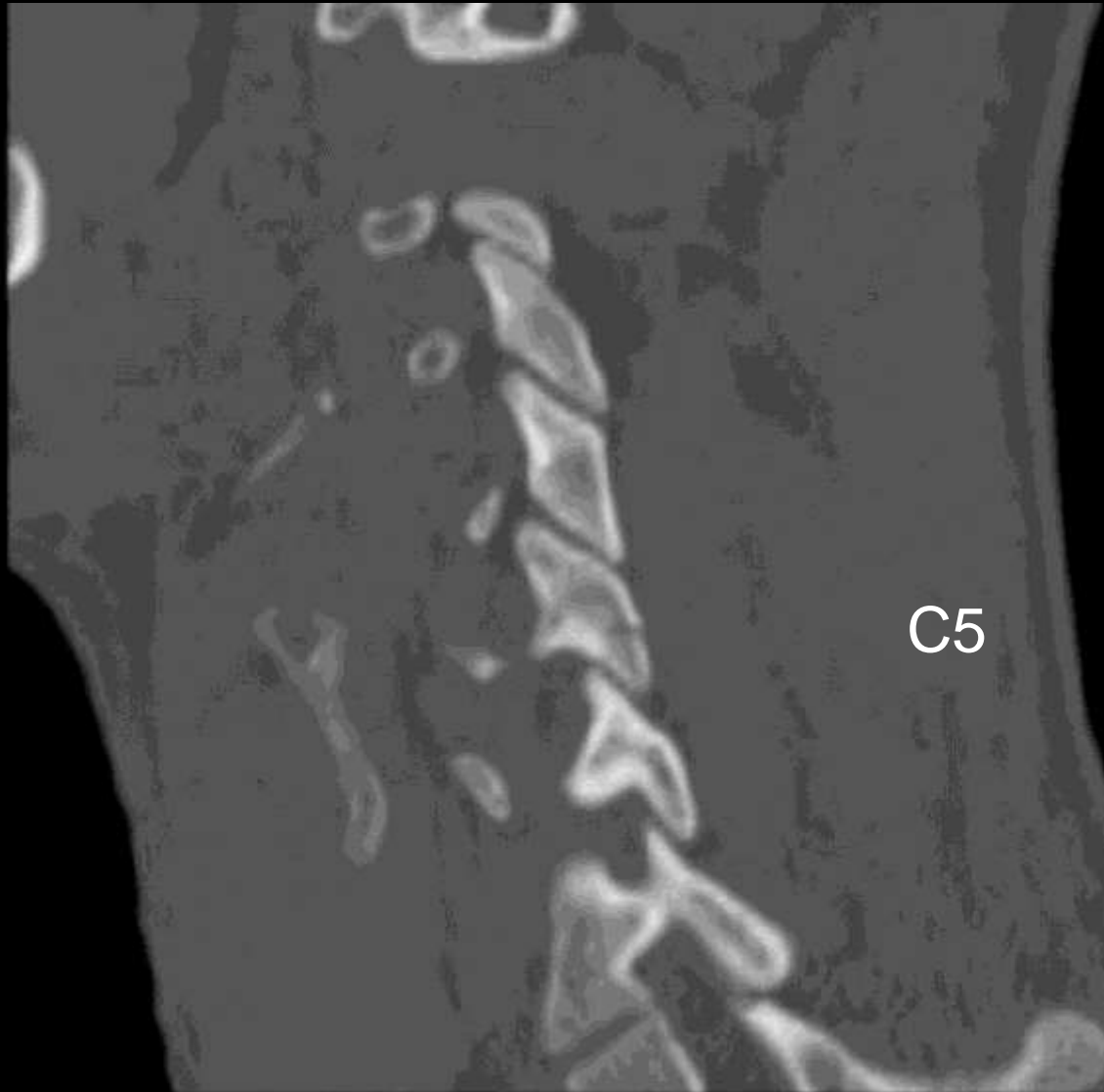

Comparing Techniques



C5 inferior facet Fracture not seen on X-ray

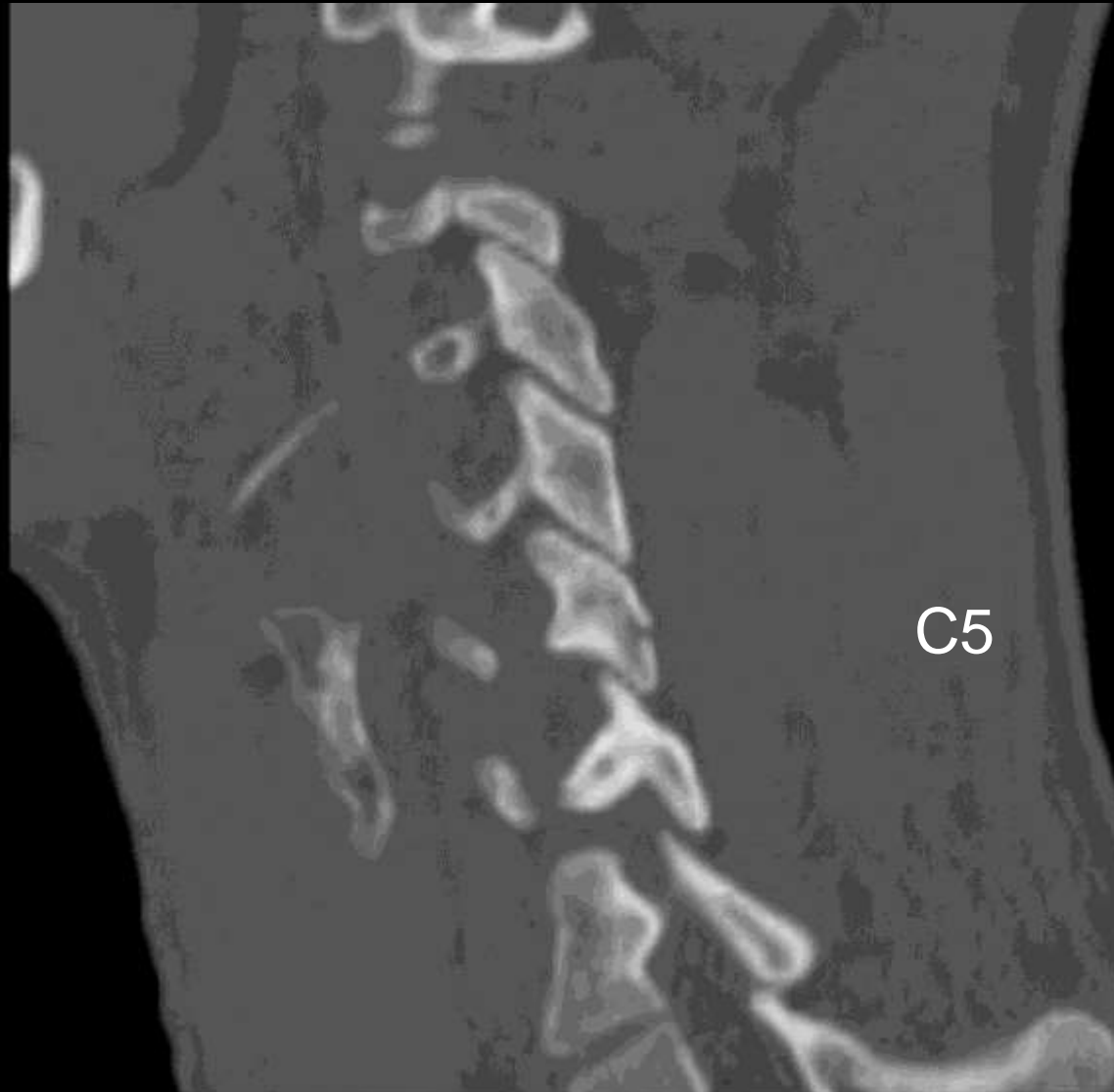Comparing Techniques



C5

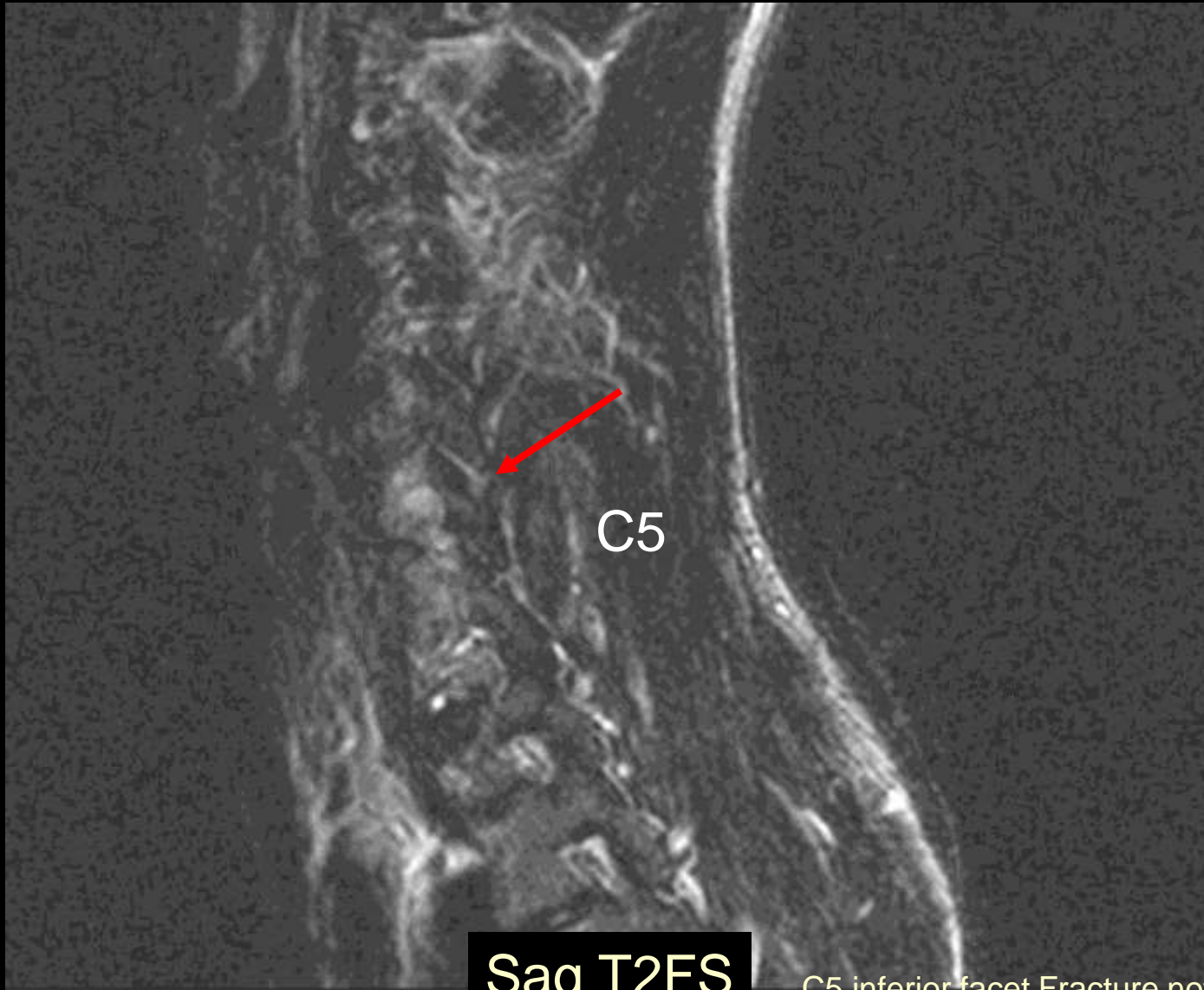
C5 inferior facet Fracture not seen on X-ray

Comparing Techniques



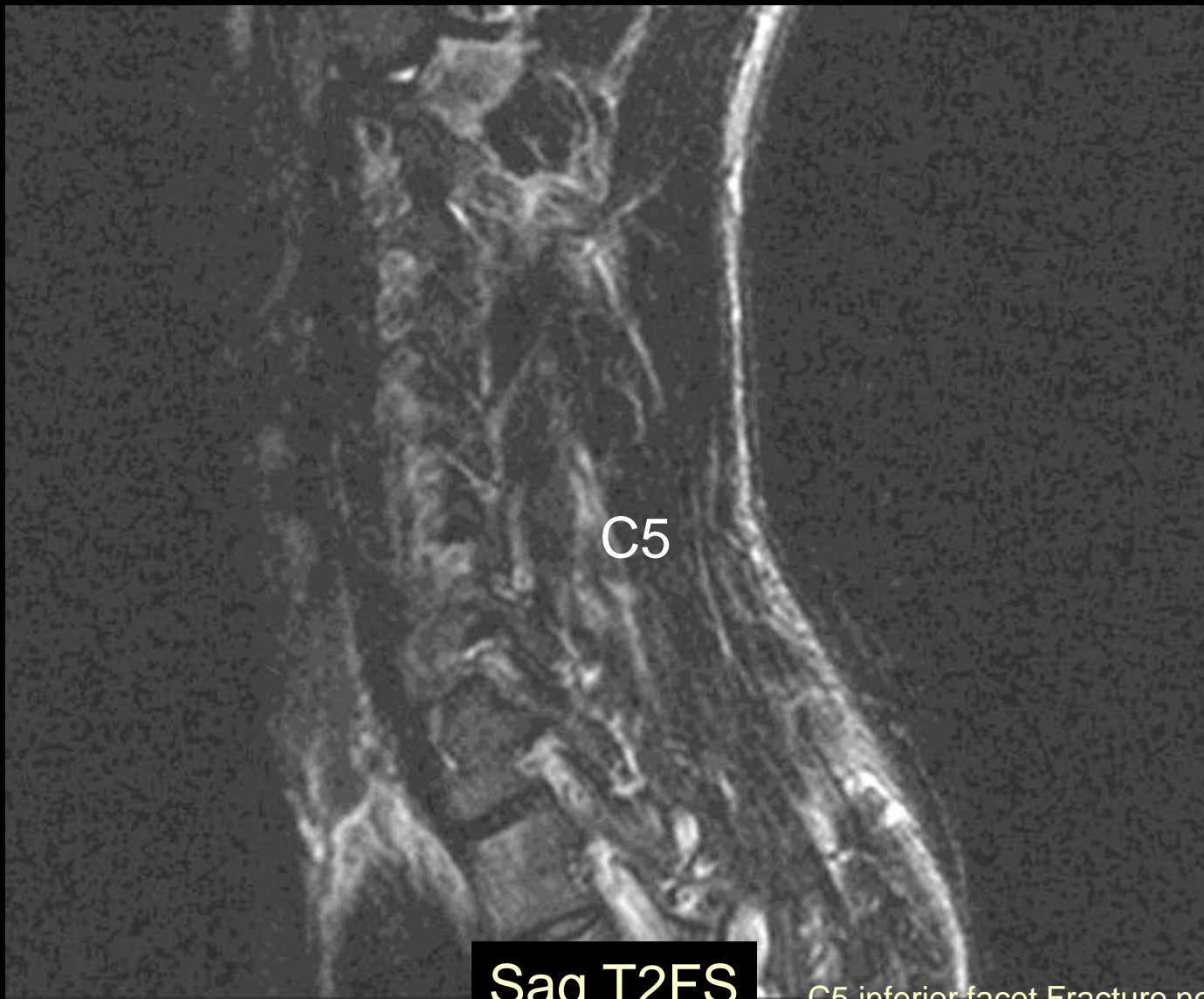C5 inferior facet Fracture not seen on X-ray

Comparing Techniques



C5 inferior facet Fracture not seen on X-ray

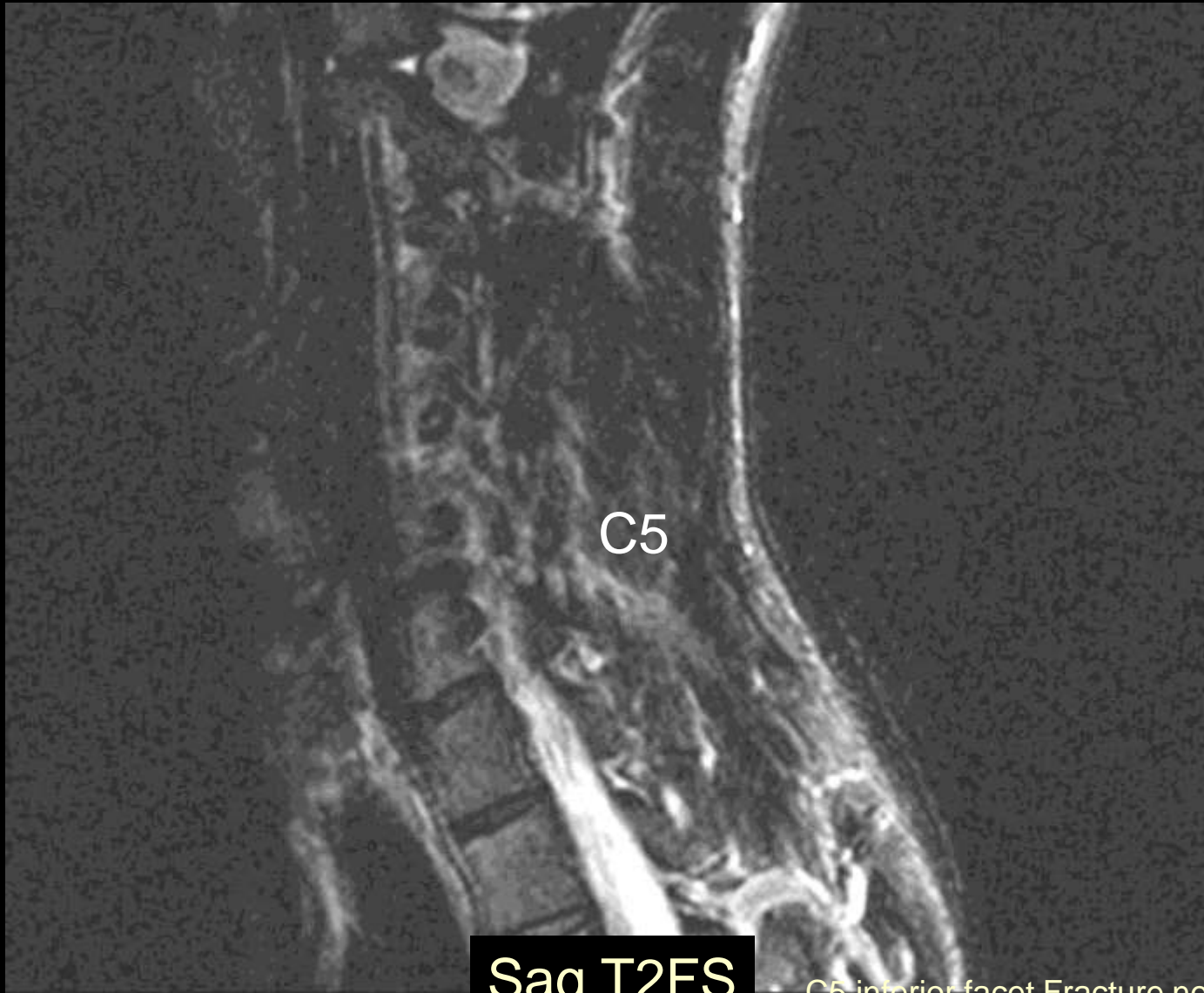Comparing Techniques



Sag T2FS

C5 inferior facet Fracture not seen on X-ray

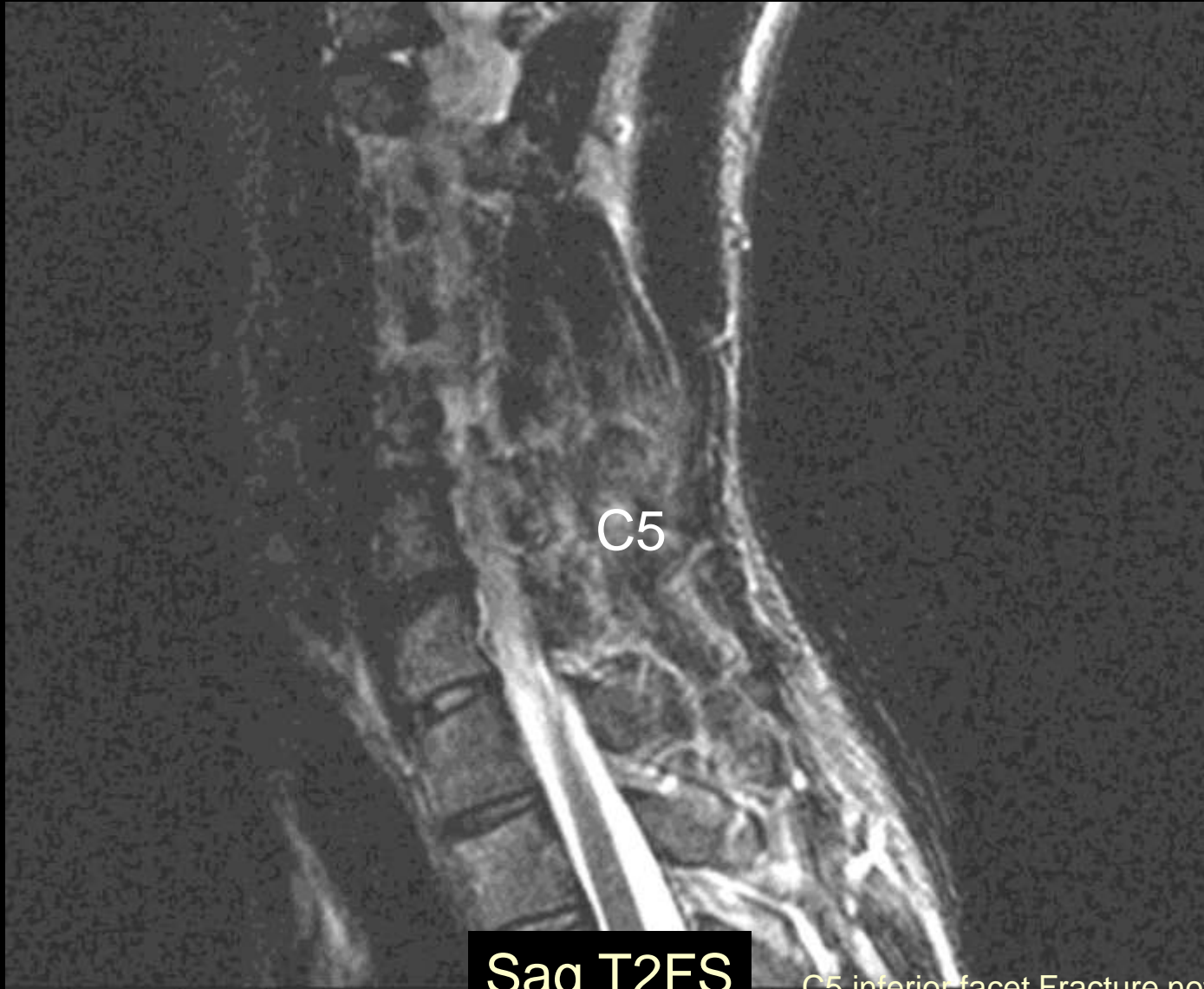Comparing Techniques



Sag T2FS

C5 inferior facet Fracture not seen on X-ray

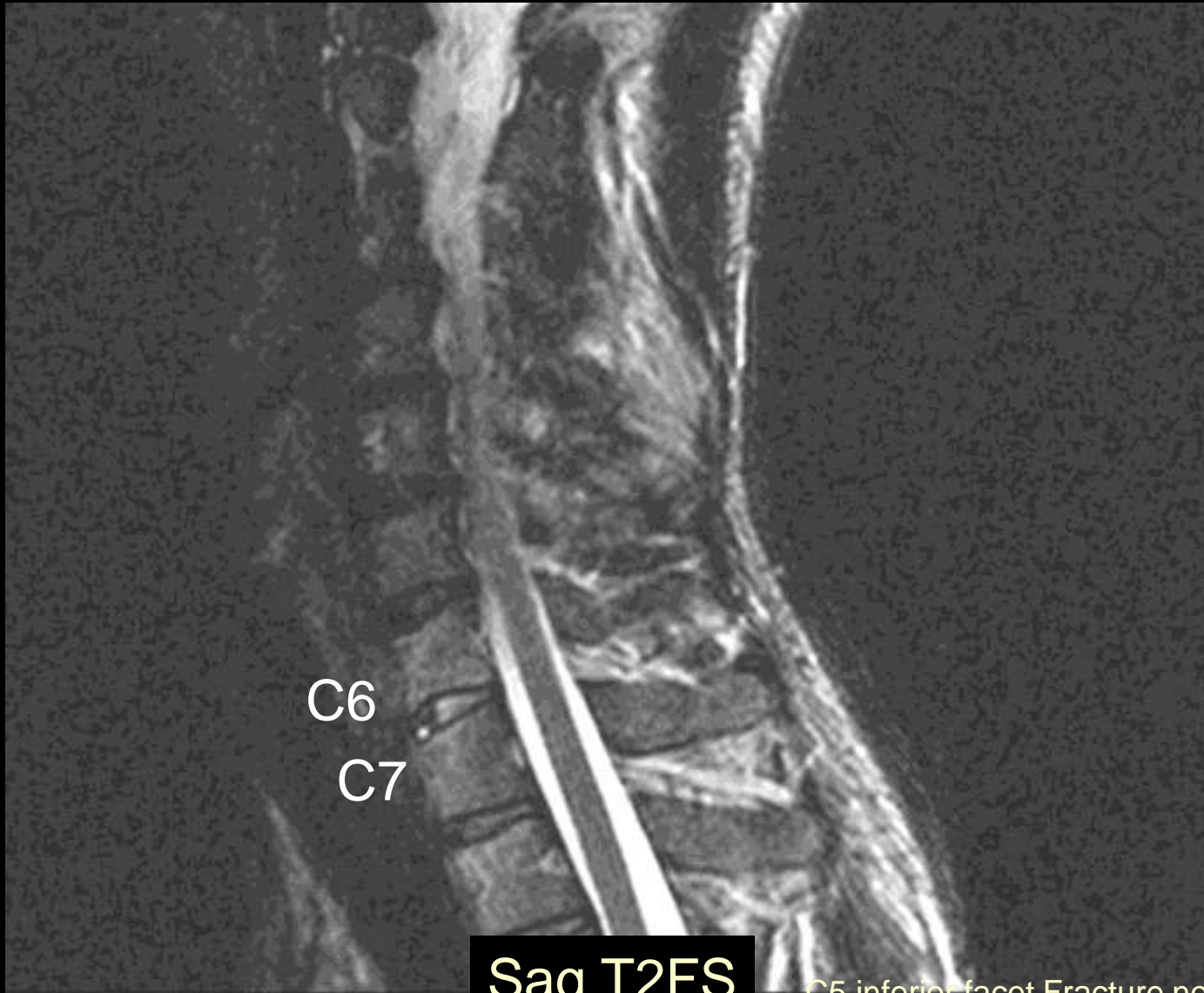Comparing Techniques



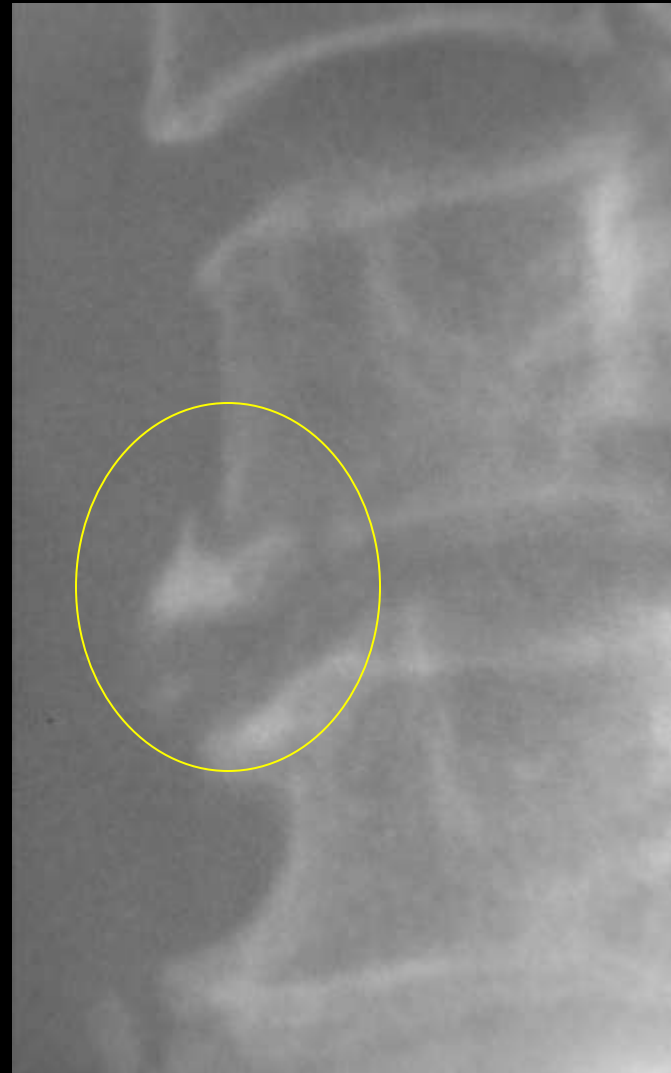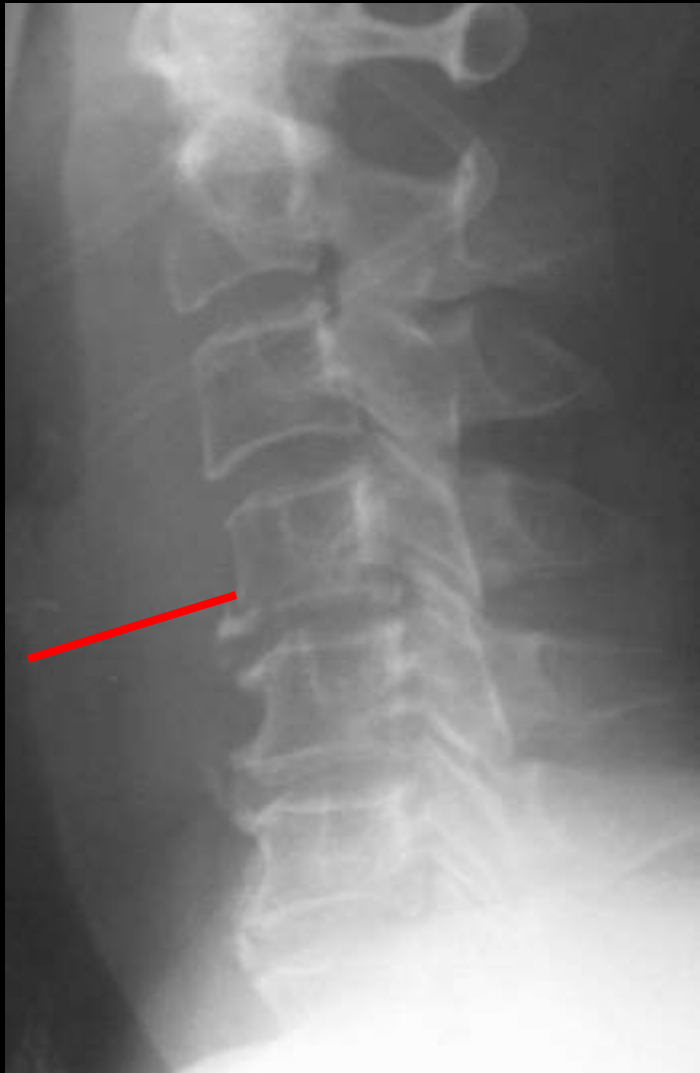Sag T2FS

C5 inferior facet Fracture not seen on X-ray

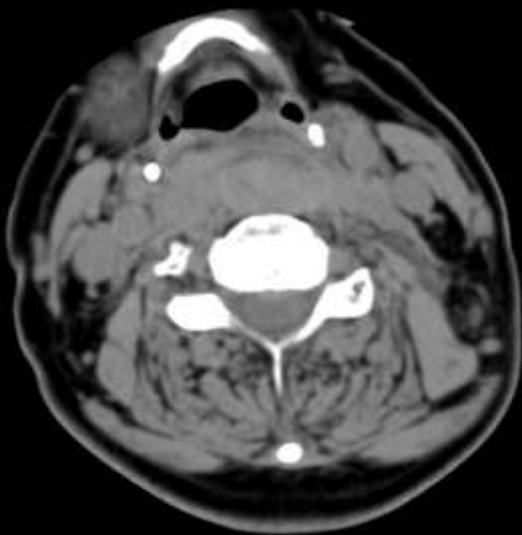
Comparing Techniques



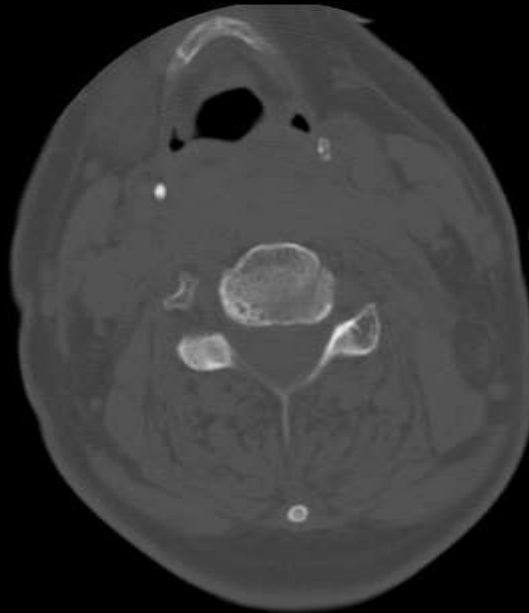
Comparing Techniques



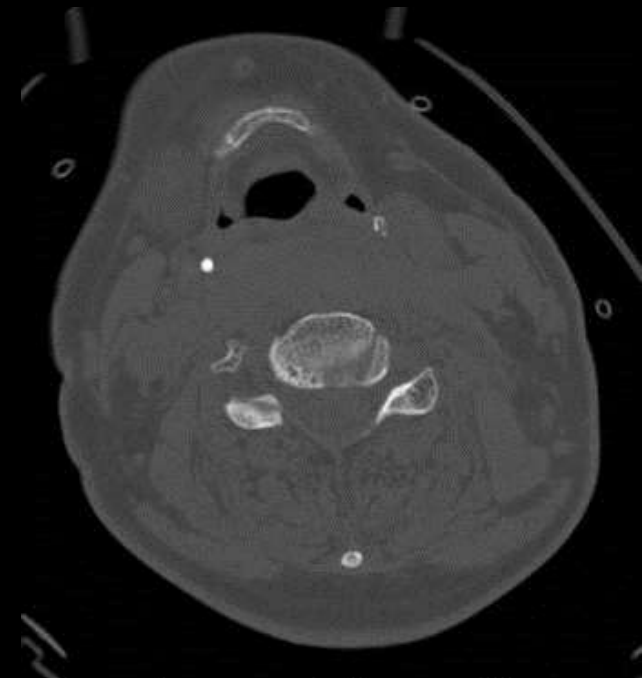
Comparing Techniques



2.5 Soft tissue window

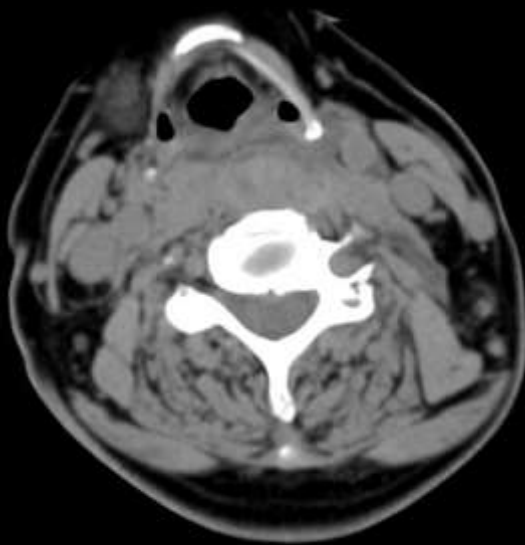


2.5 bone

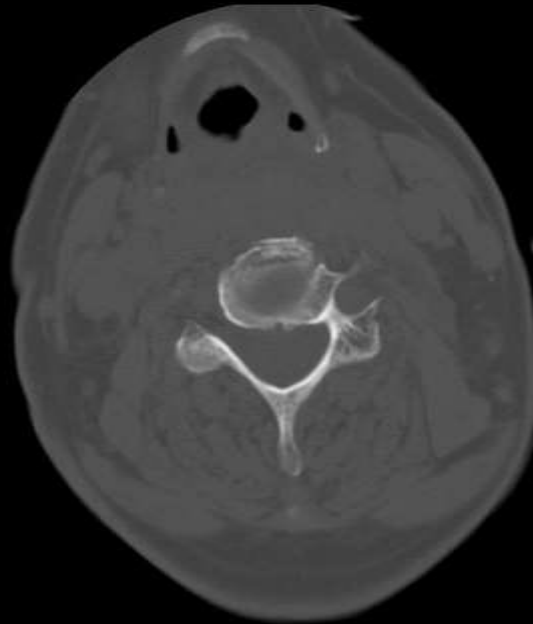


1.25 bone

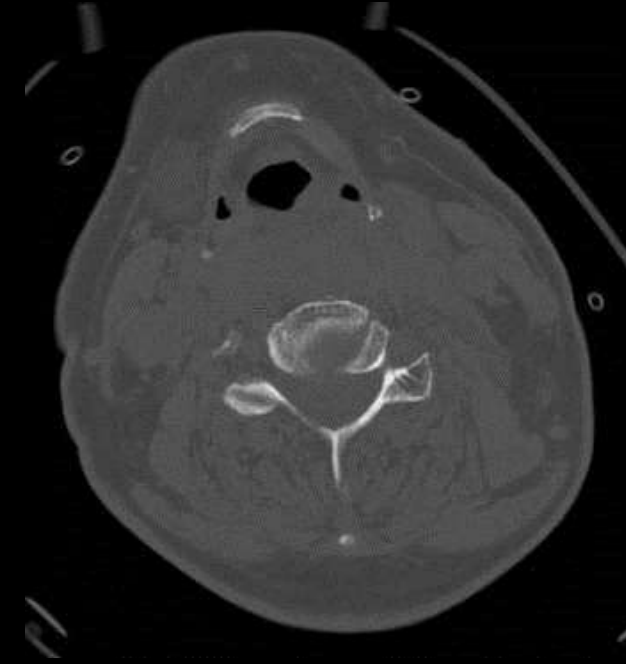
Comparing Techniques



2.5 Soft tissue window

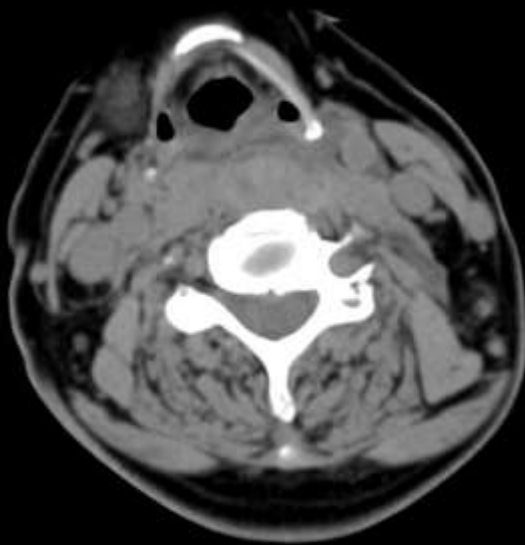


2.5 bone

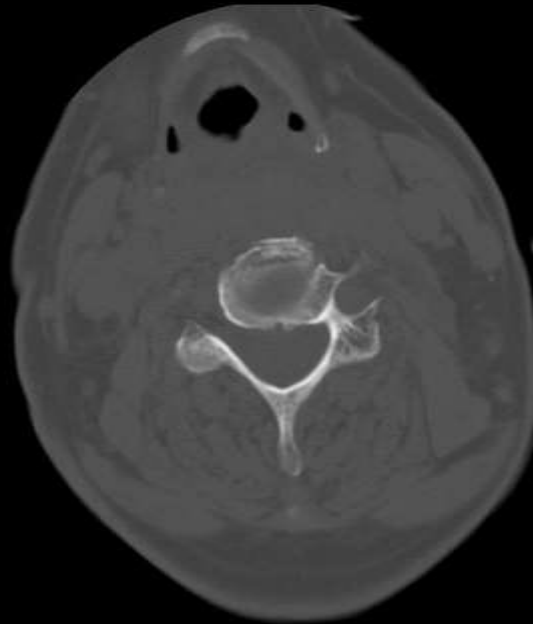


1.25 bone

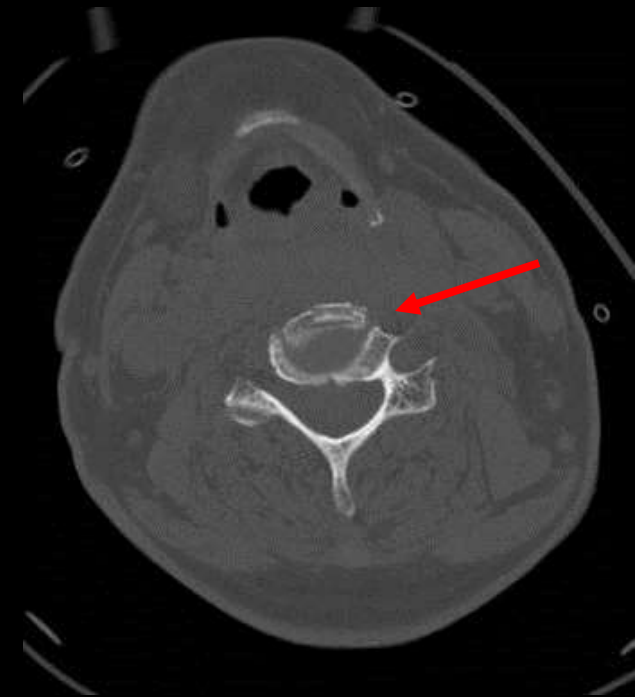Comparing Techniques



2.5 Soft tissue window

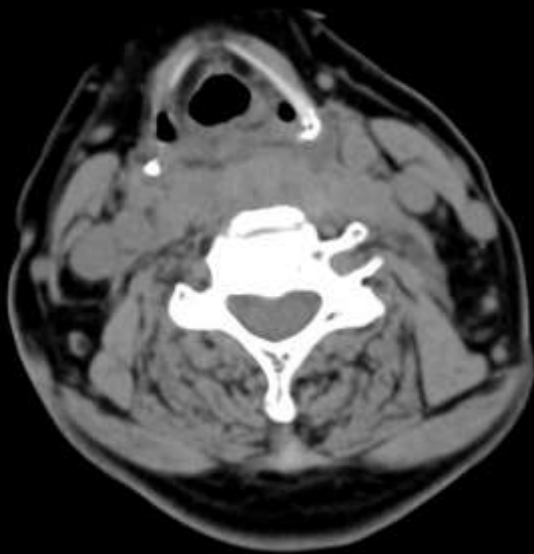


2.5 bone

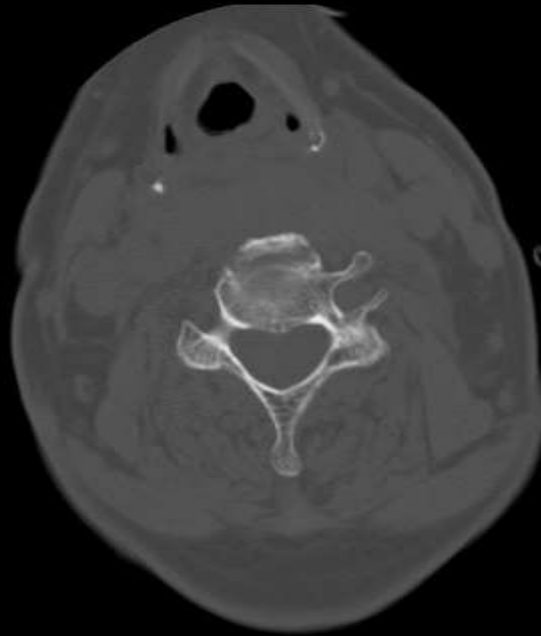


1.25 bone

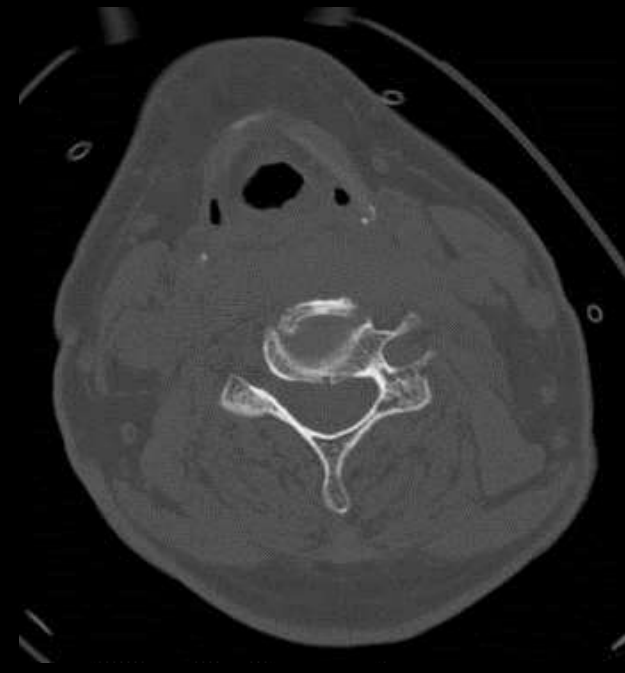
Comparing Techniques



2.5 Soft tissue window

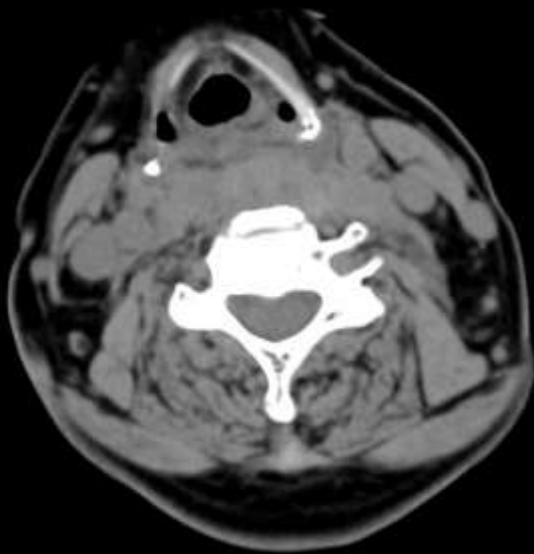


2.5 bone

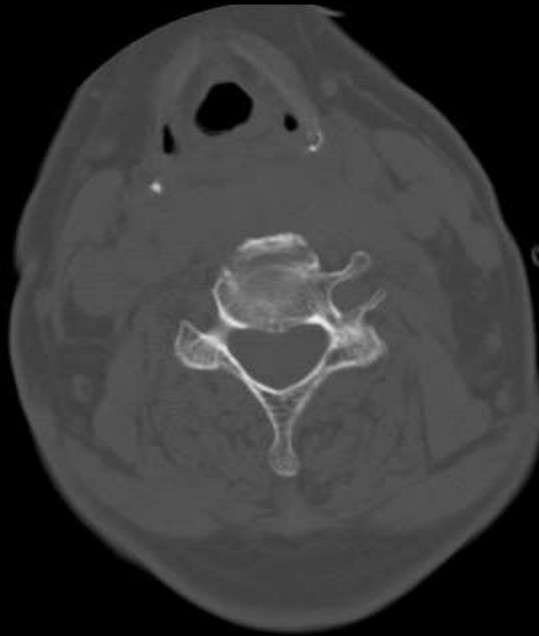


1.25 bone

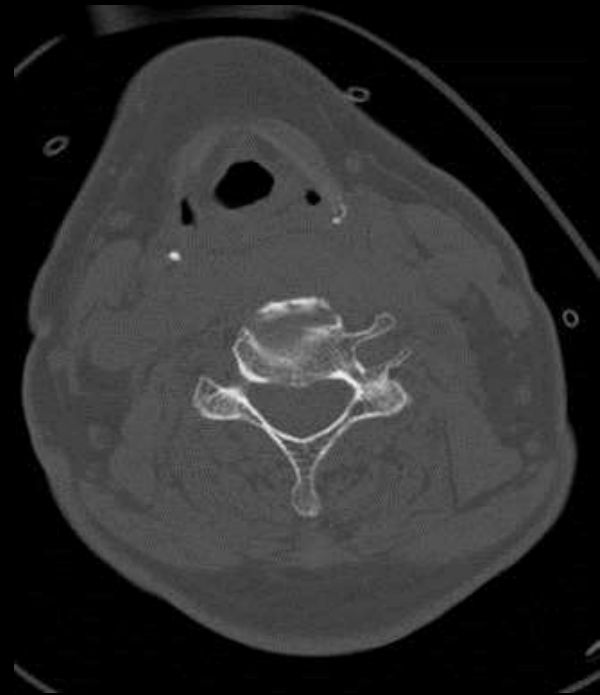
Comparing Techniques



2.5 Soft tissue window

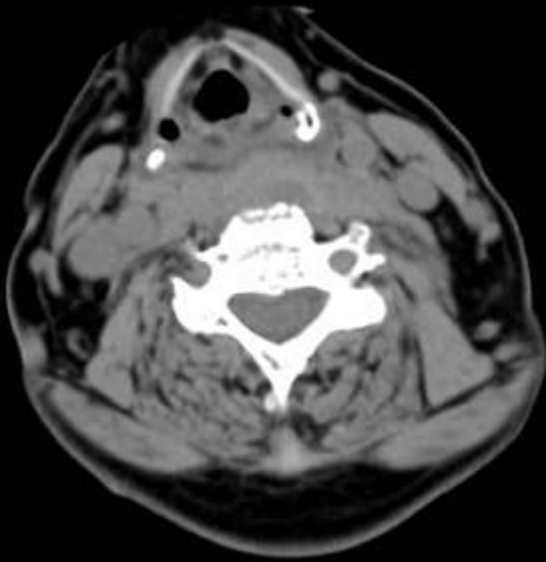


2.5 bone

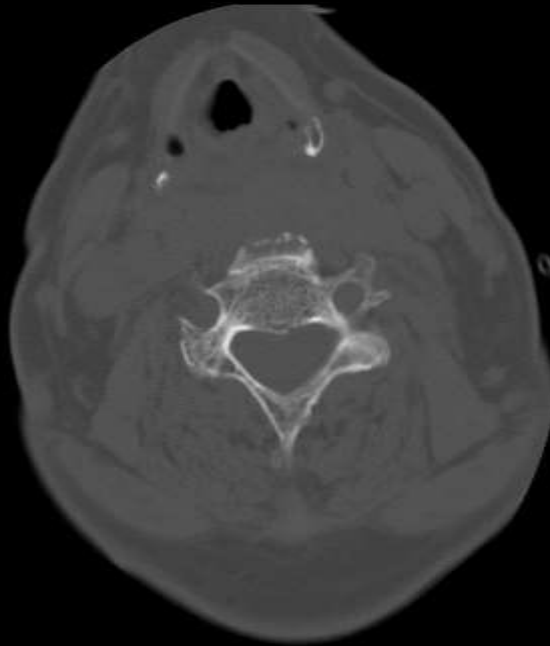


1.25 bone

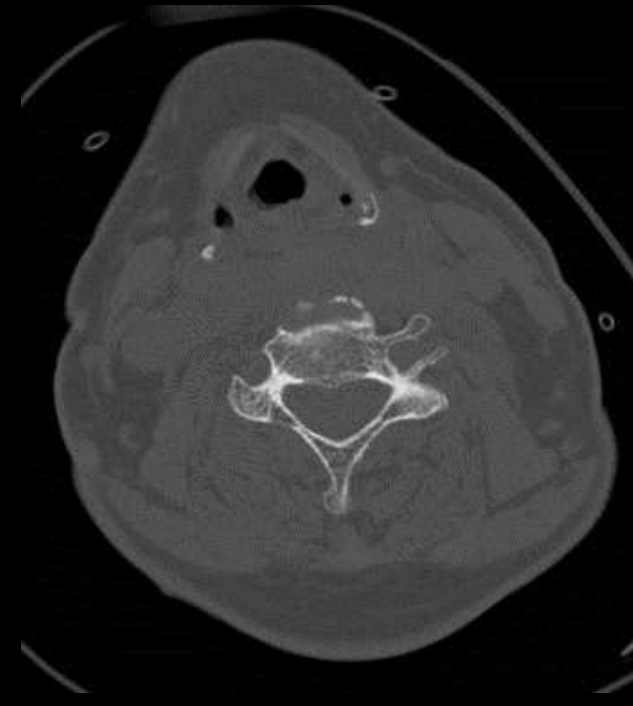
Comparing Techniques



2.5 Soft tissue window

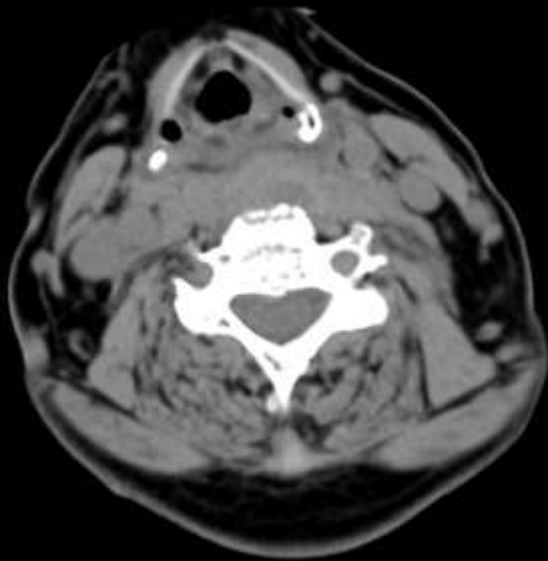


2.5 bone

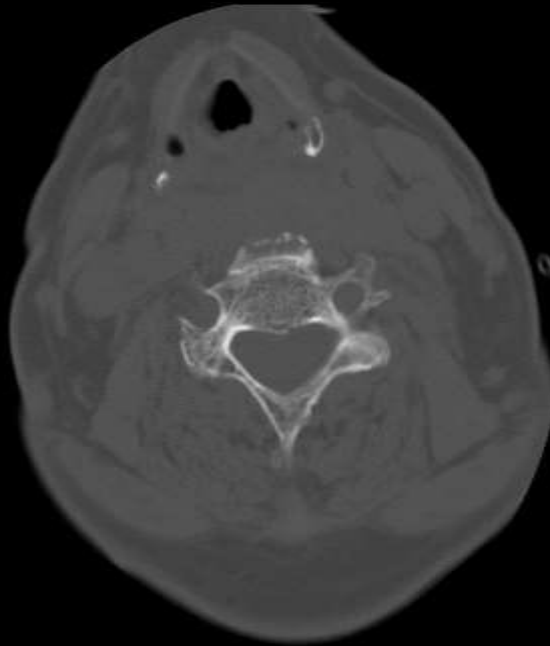


1.25 bone

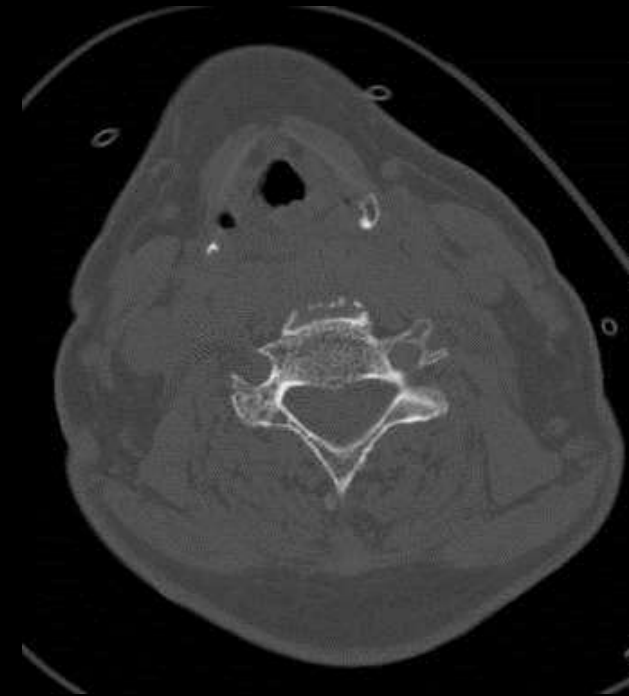
Comparing Techniques



2.5 Soft tissue window

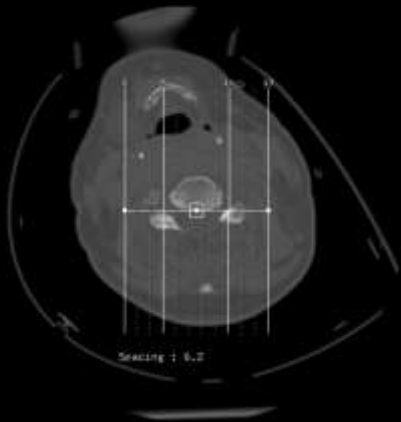


2.5 bone

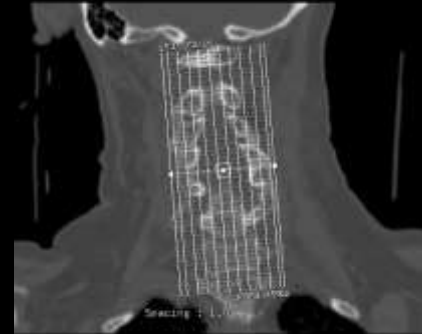

1.25 bone

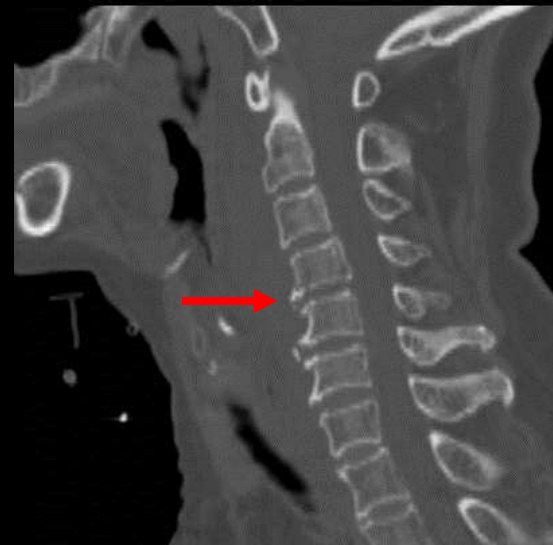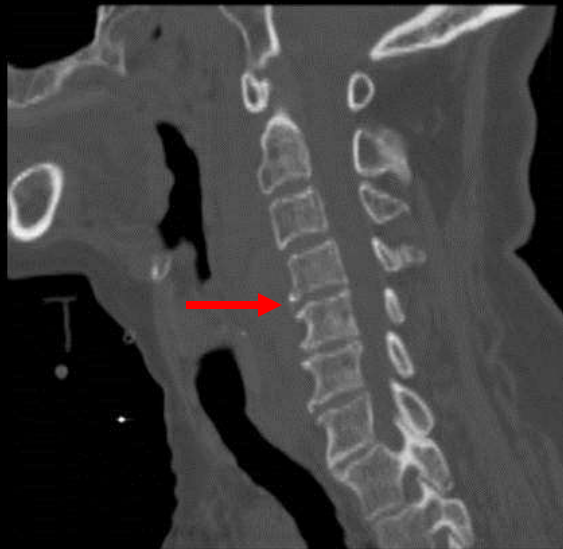Comparing Techniques



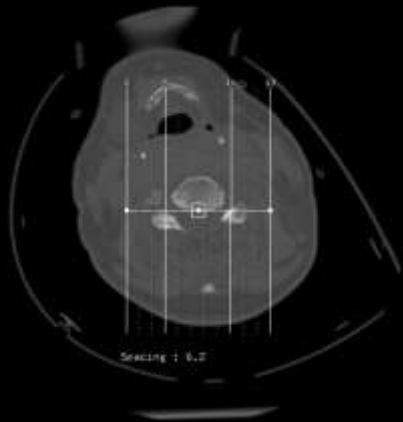
6.2mm



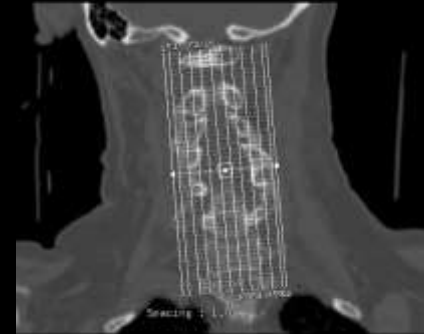
1mm



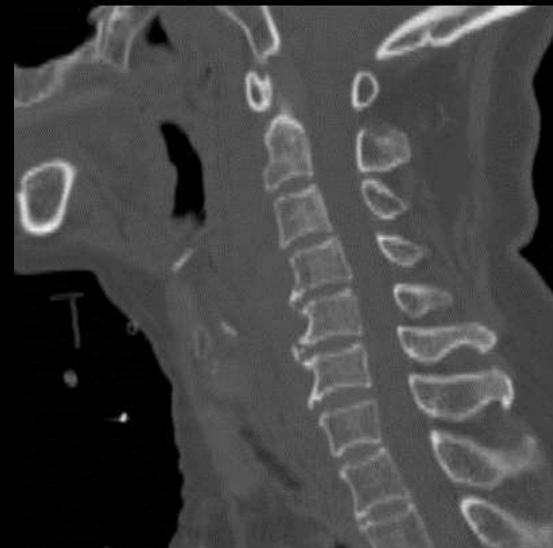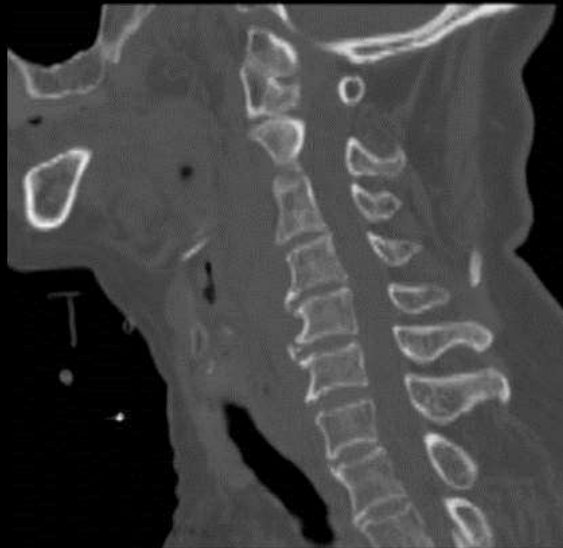Comparing Techniques



6.2mm

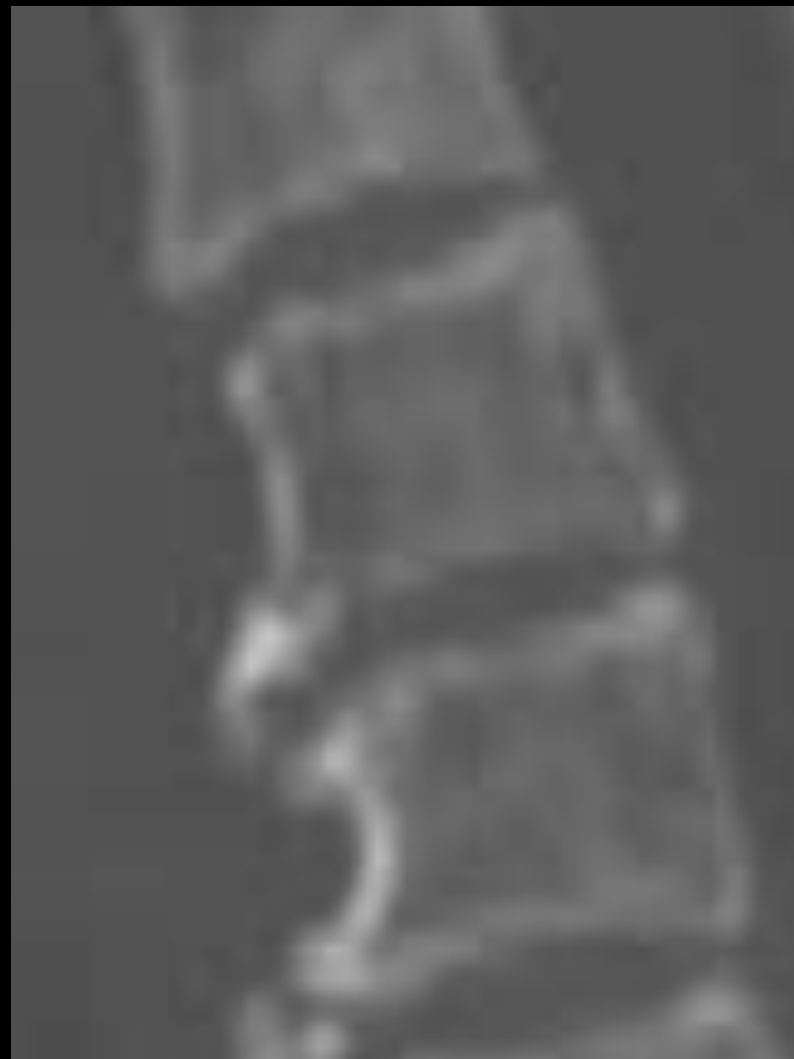
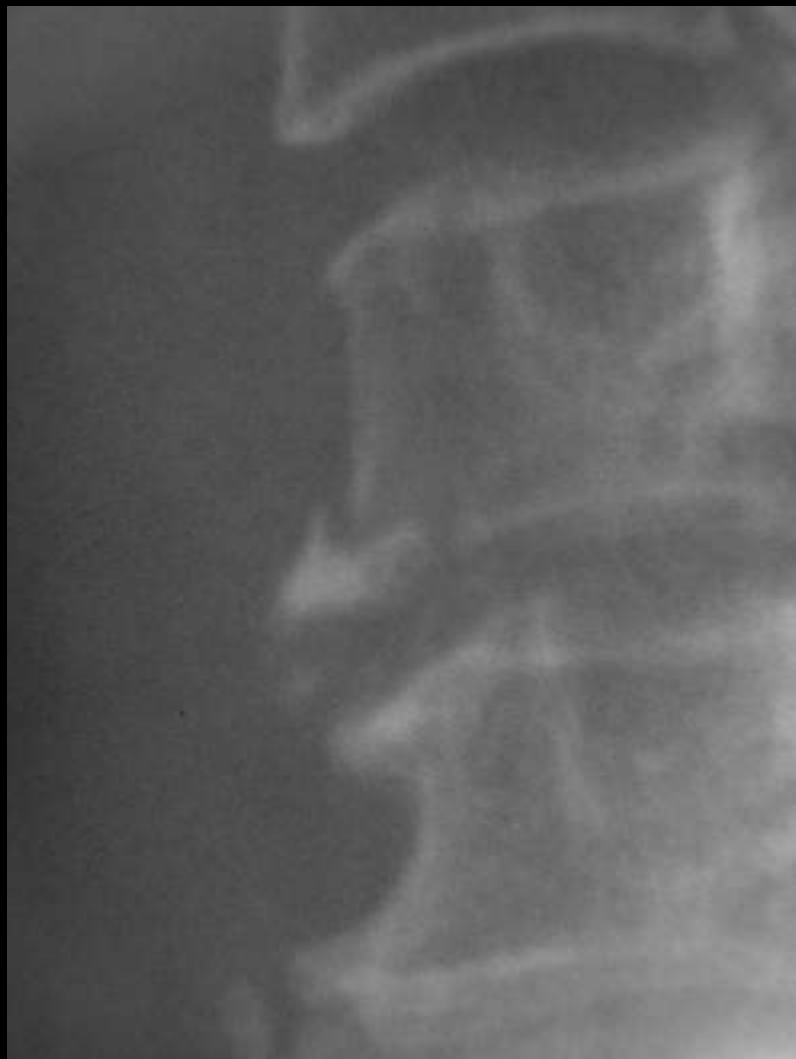
1mm



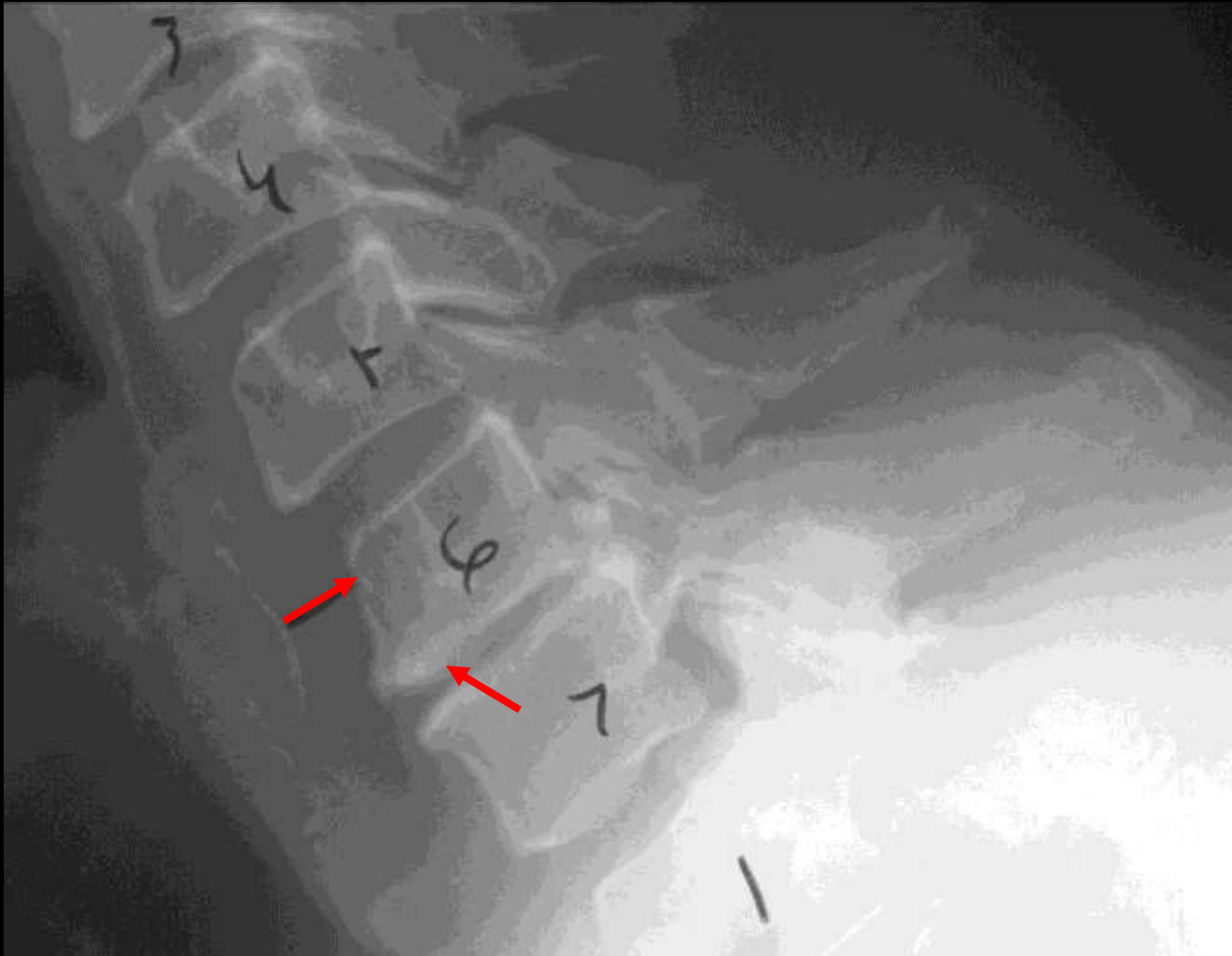
66F Whiplash. C4 Extension Teardrop, Best seen on Plain Films

Comparing Techniques

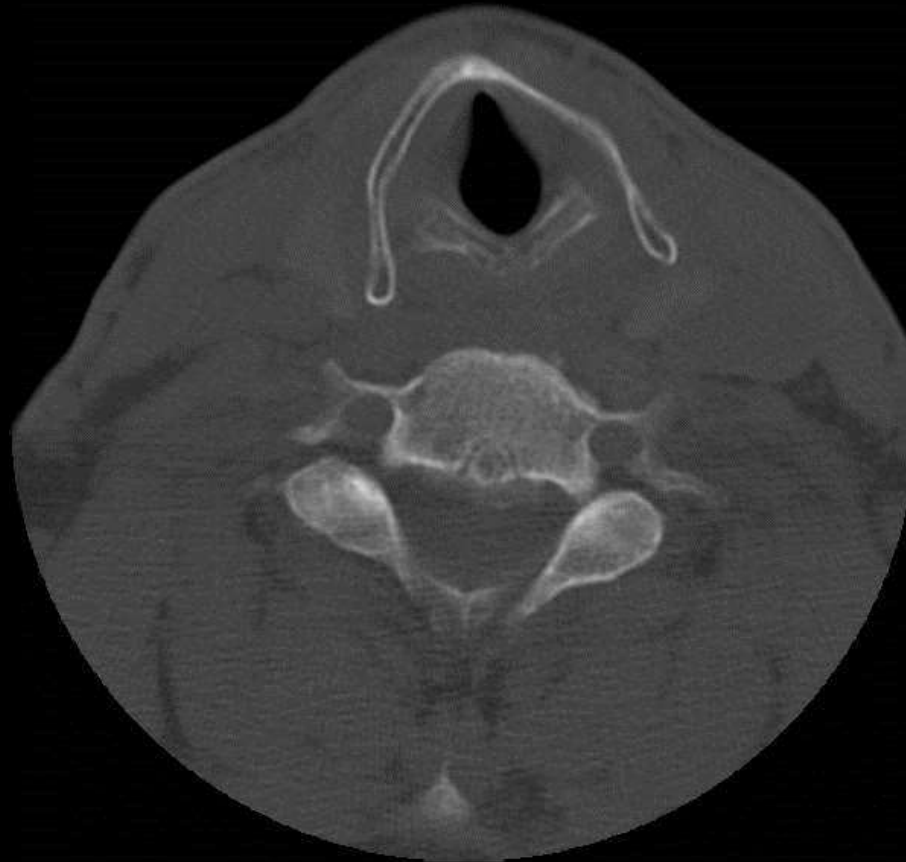

66F Whiplash. C4 Extension Teardrop, Best seen on Plain Films

Comparing Techniques



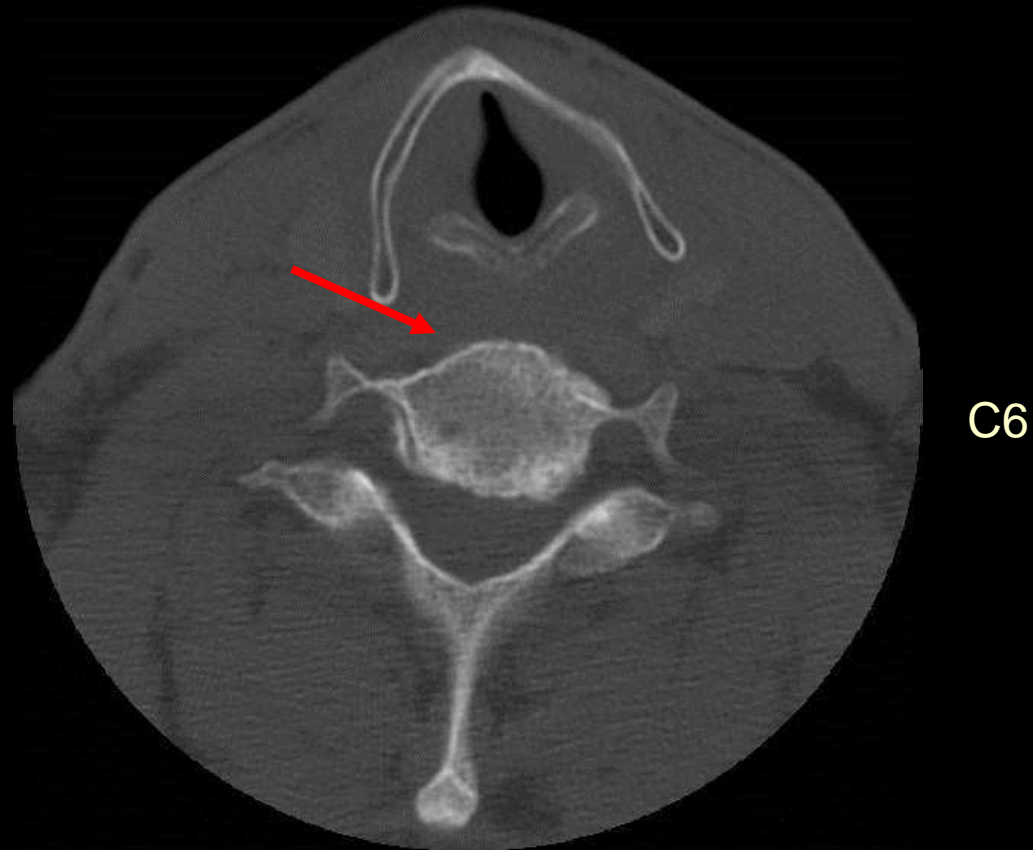Comparing Techniques



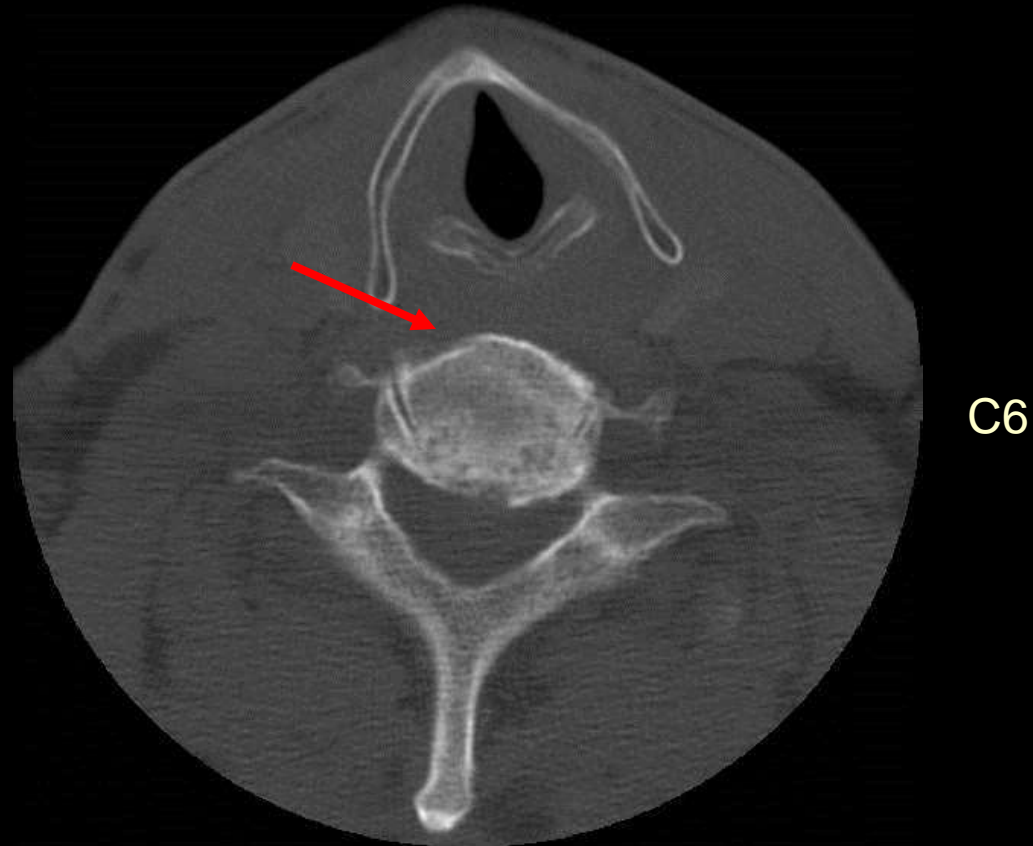
C6

3/1mm

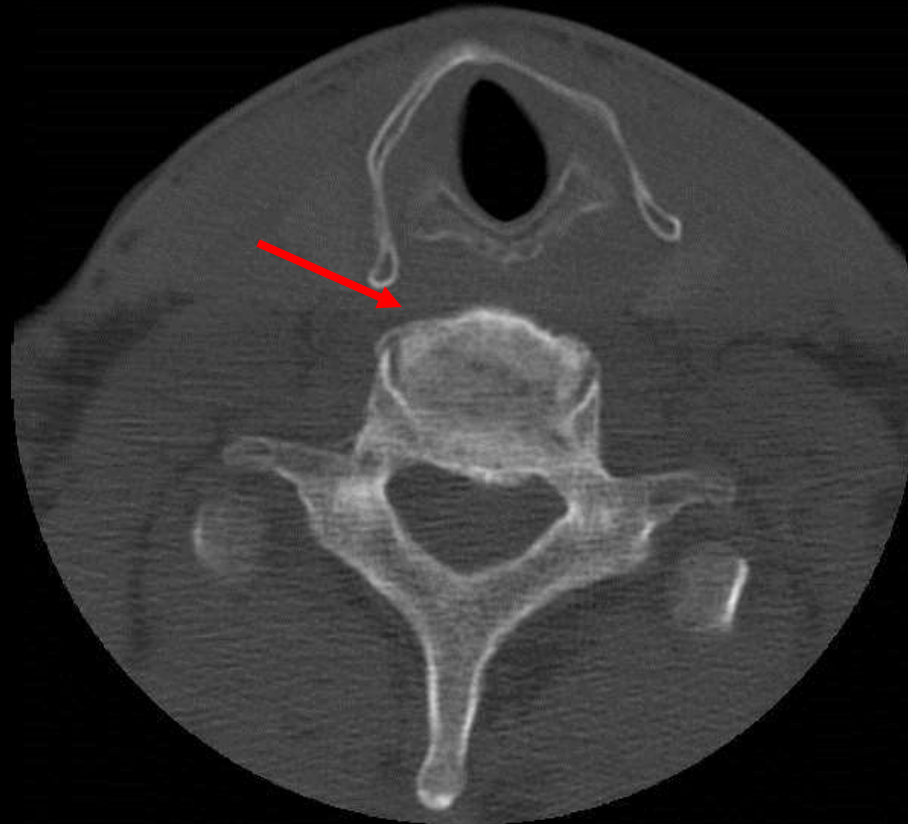
Comparing Techniques



Comparing Techniques

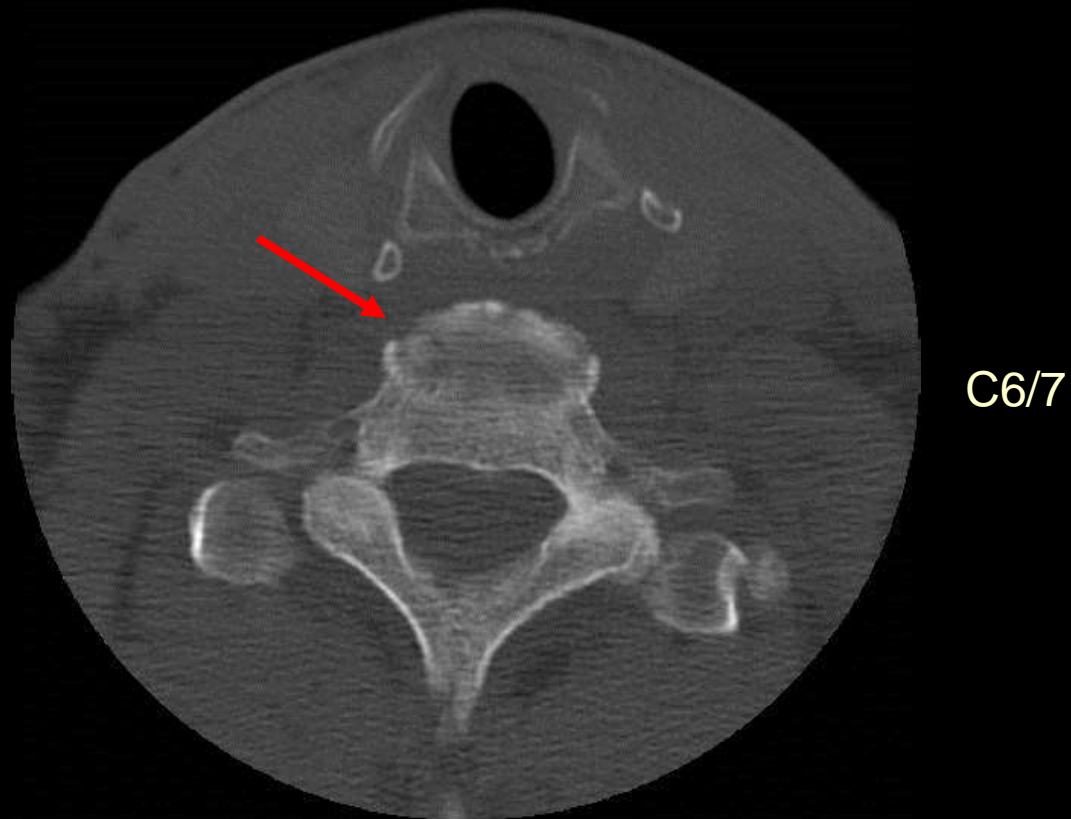


Comparing Techniques

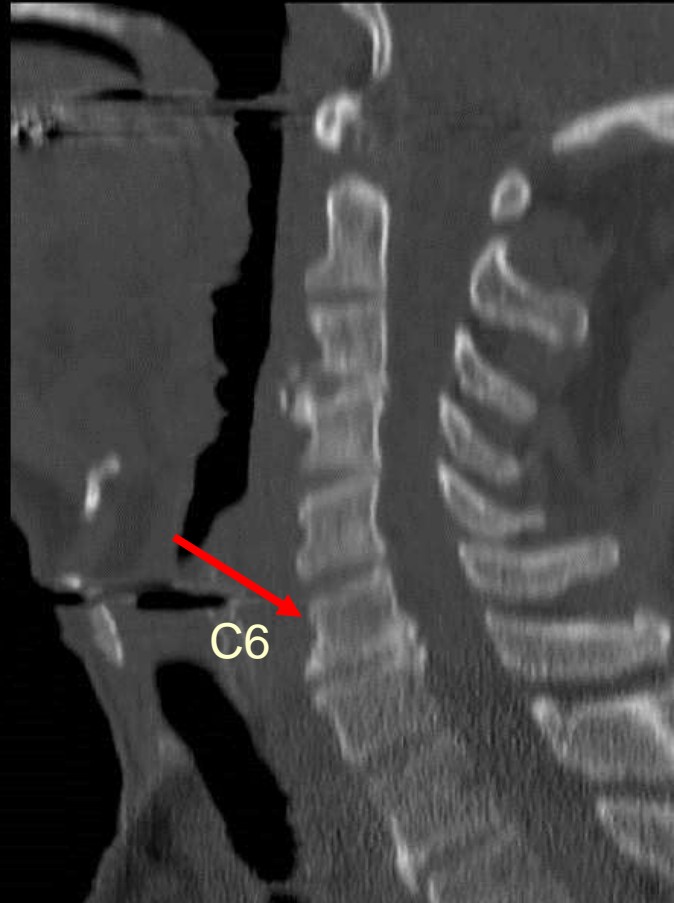


C6

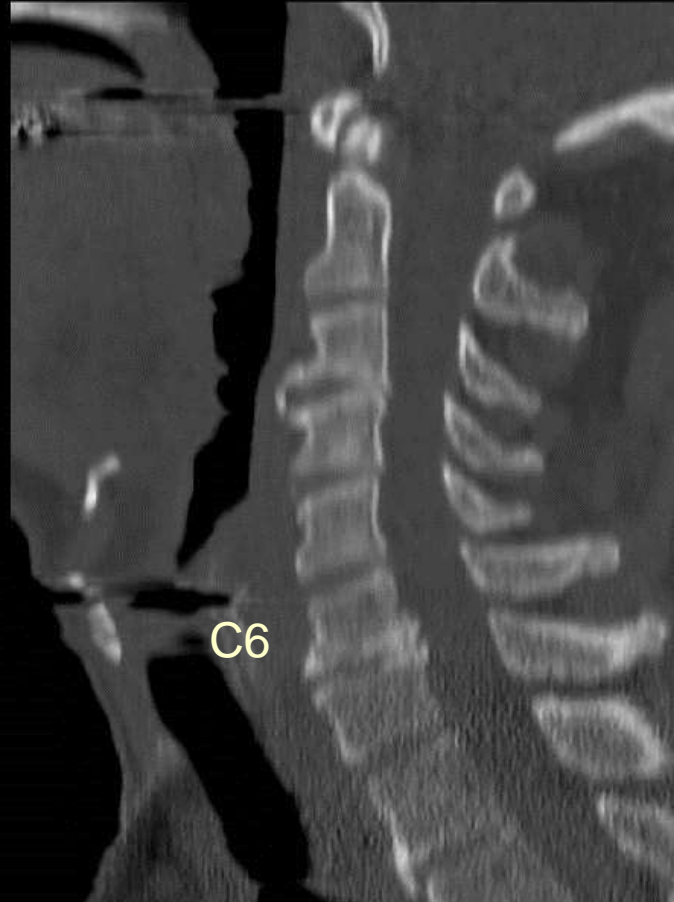
Comparing Techniques



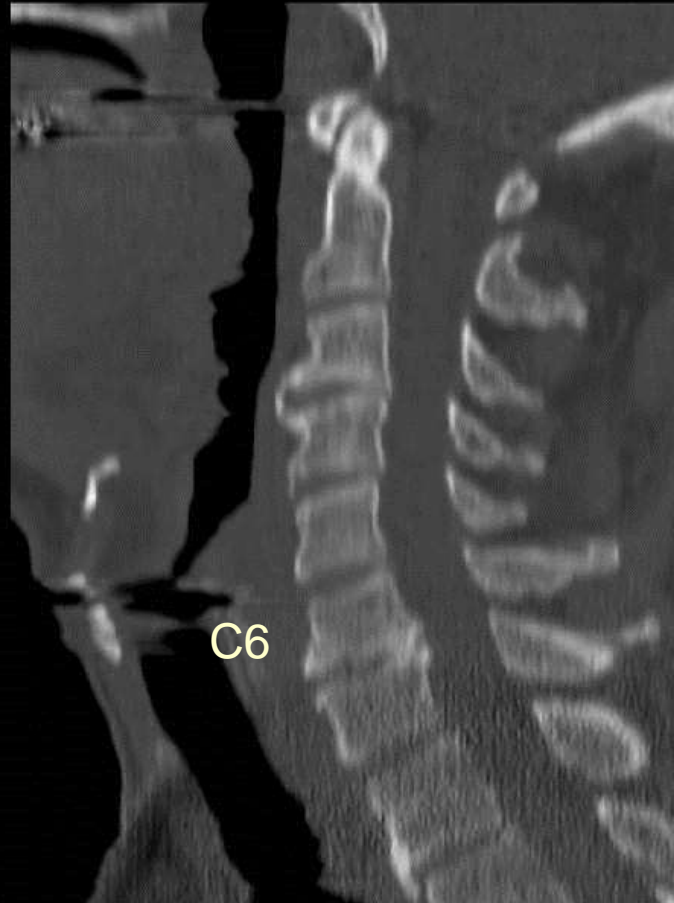
Comparing Techniques



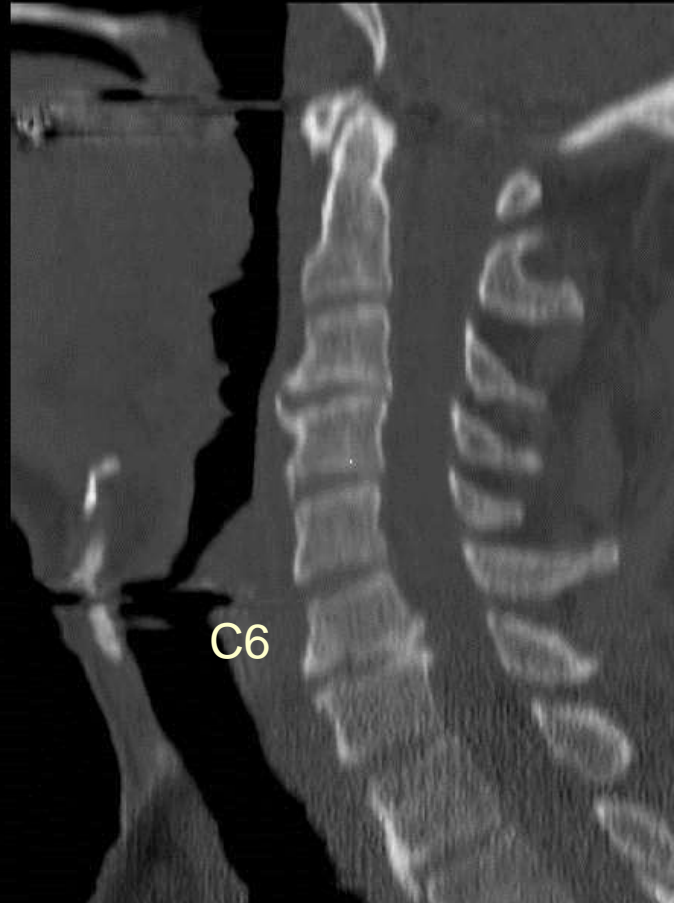
Comparing Techniques



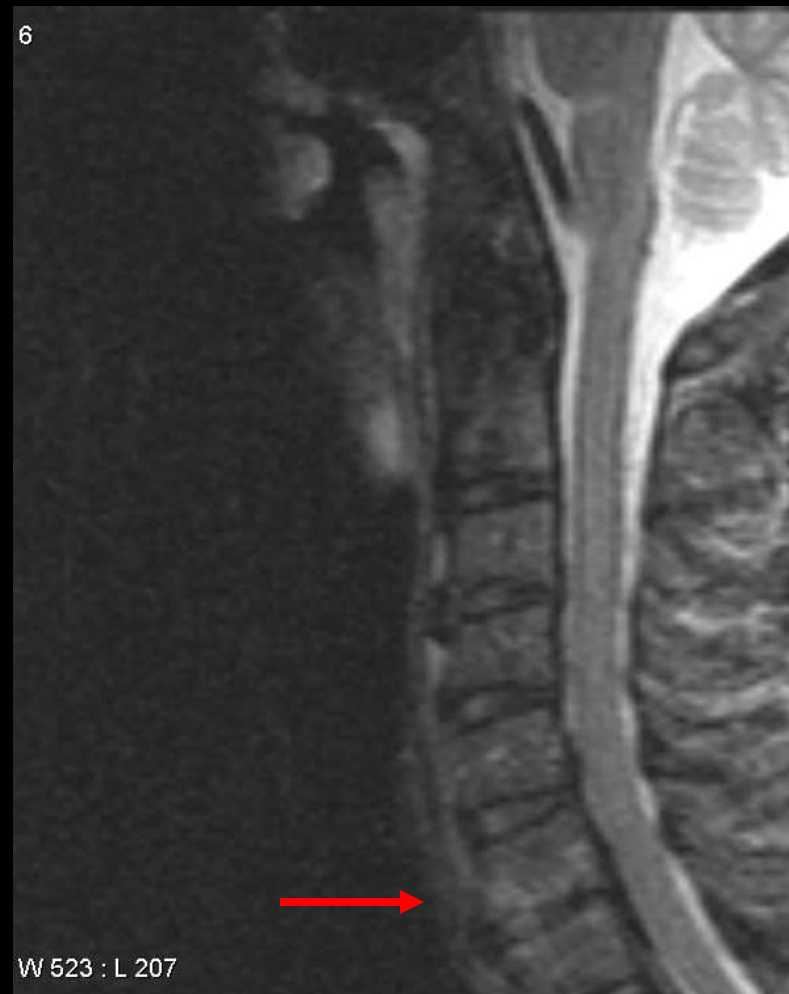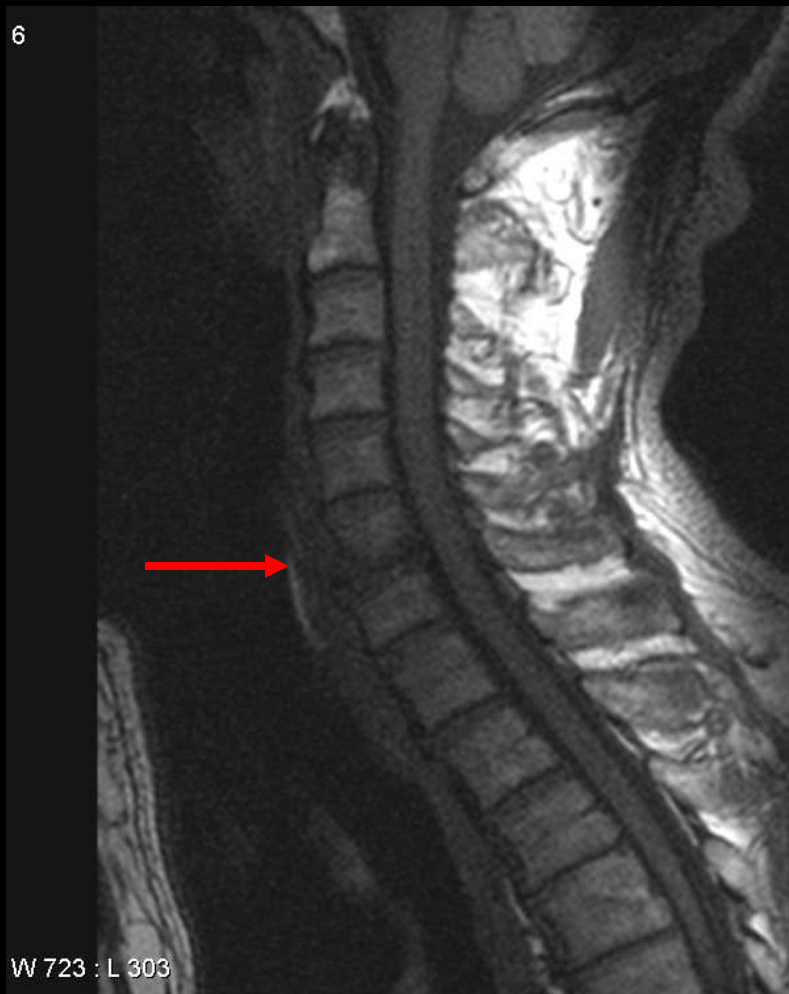
Comparing Techniques



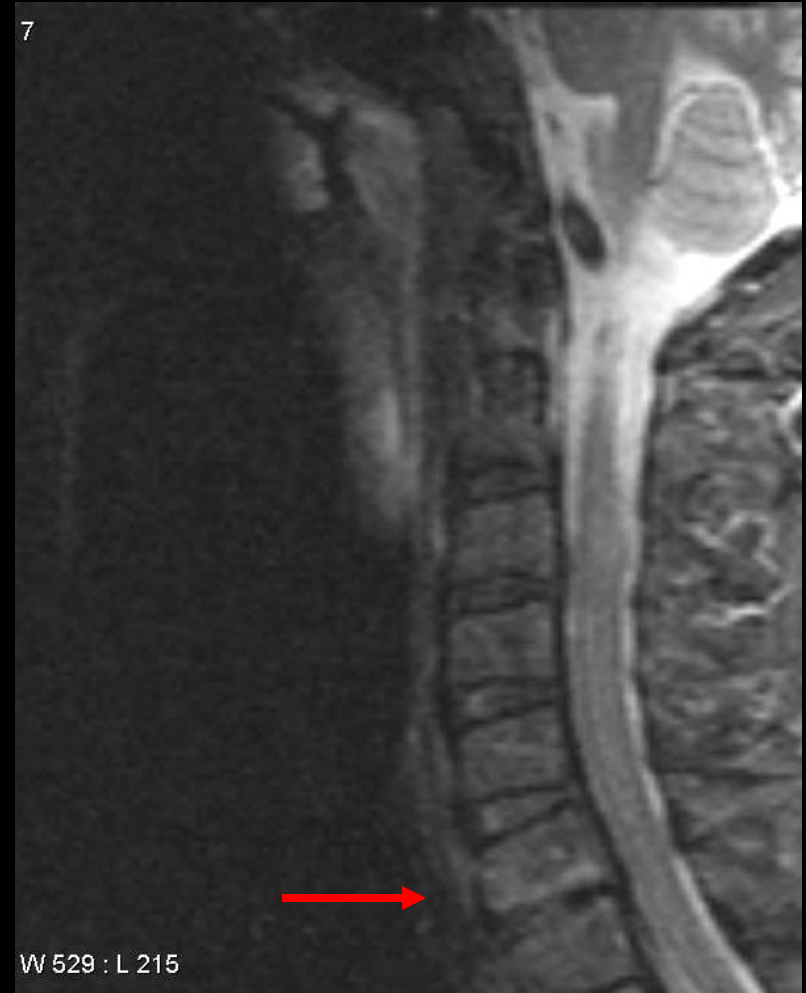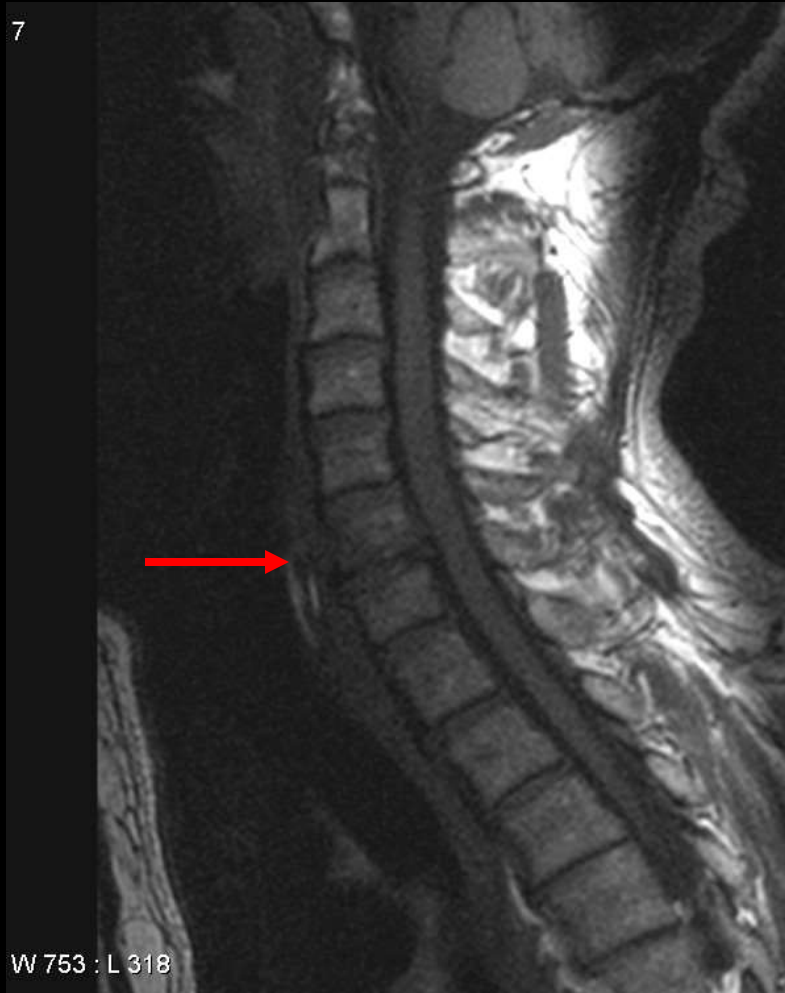Comparing Techniques



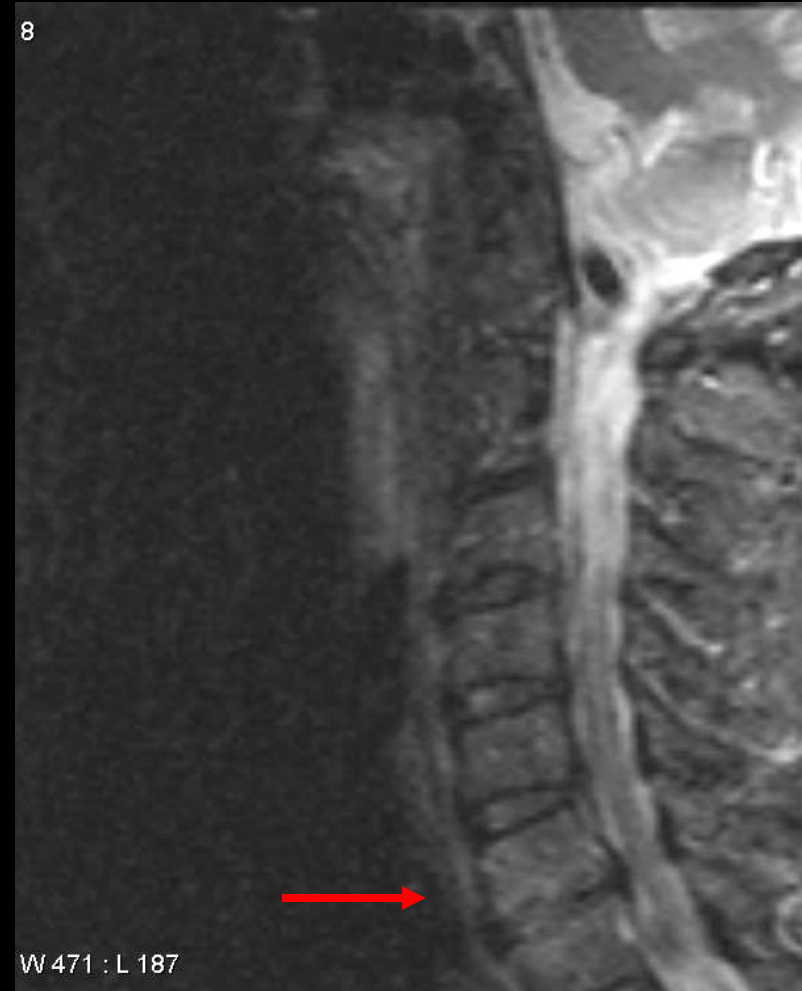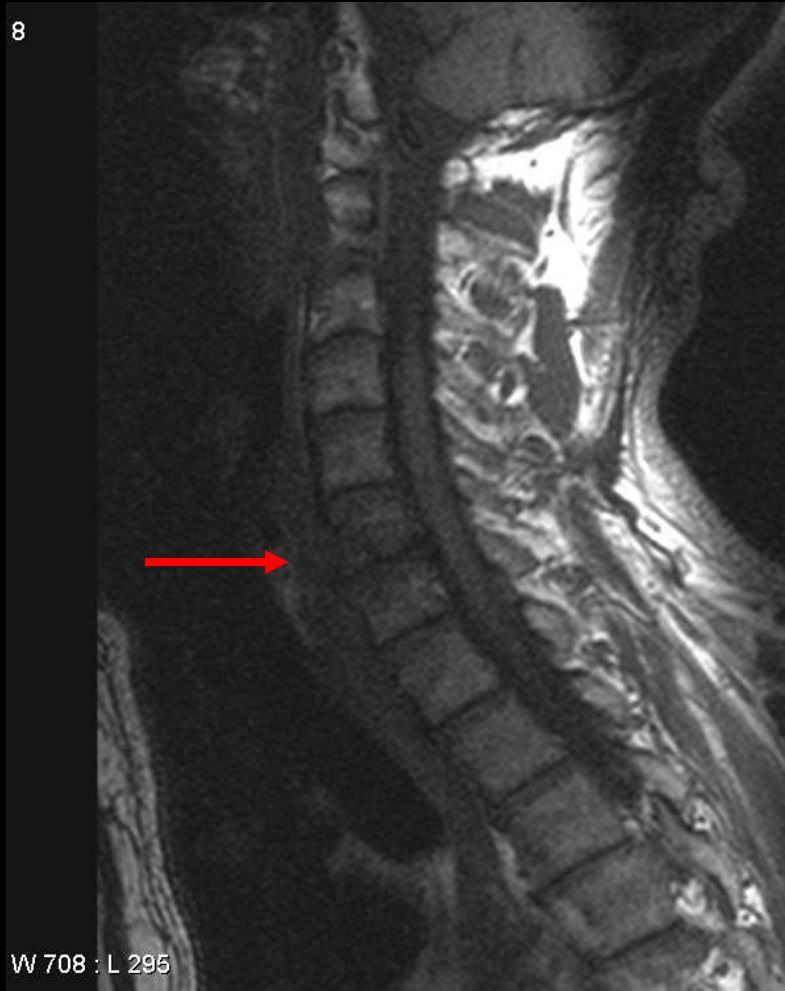Comparing Techniques



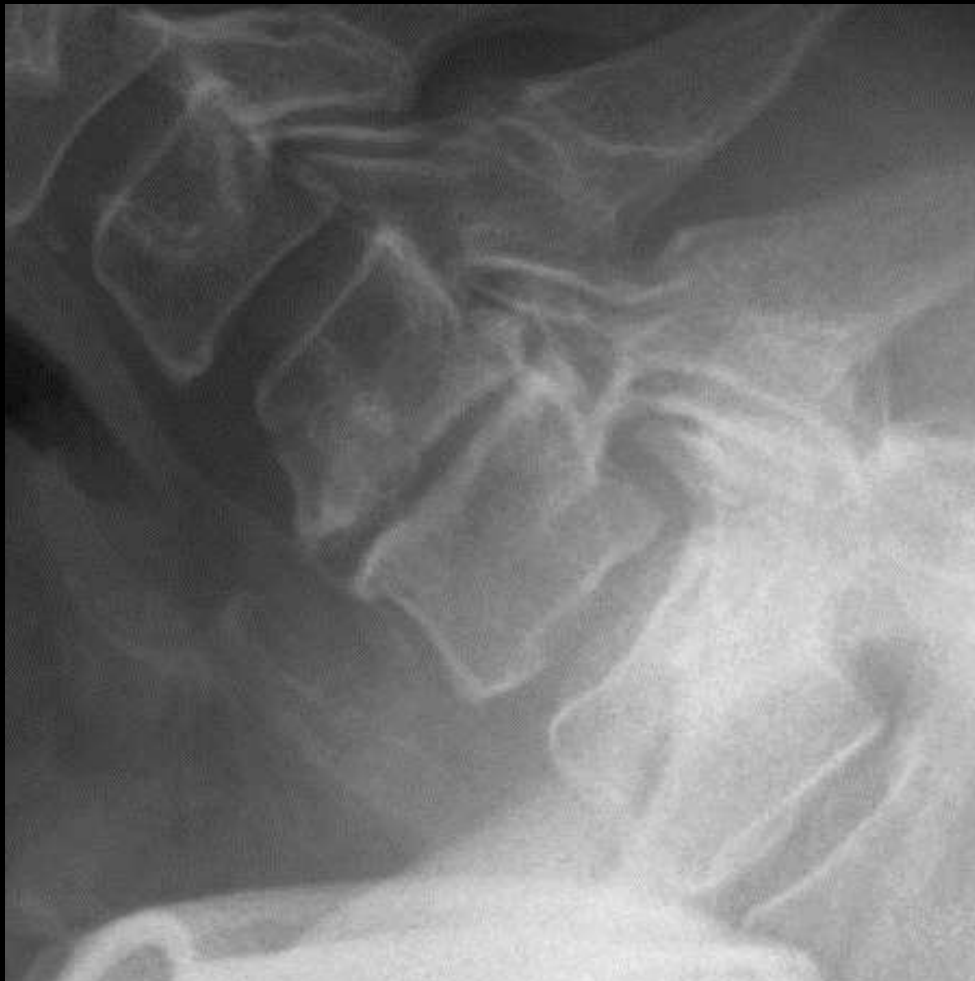Comparing Techniques



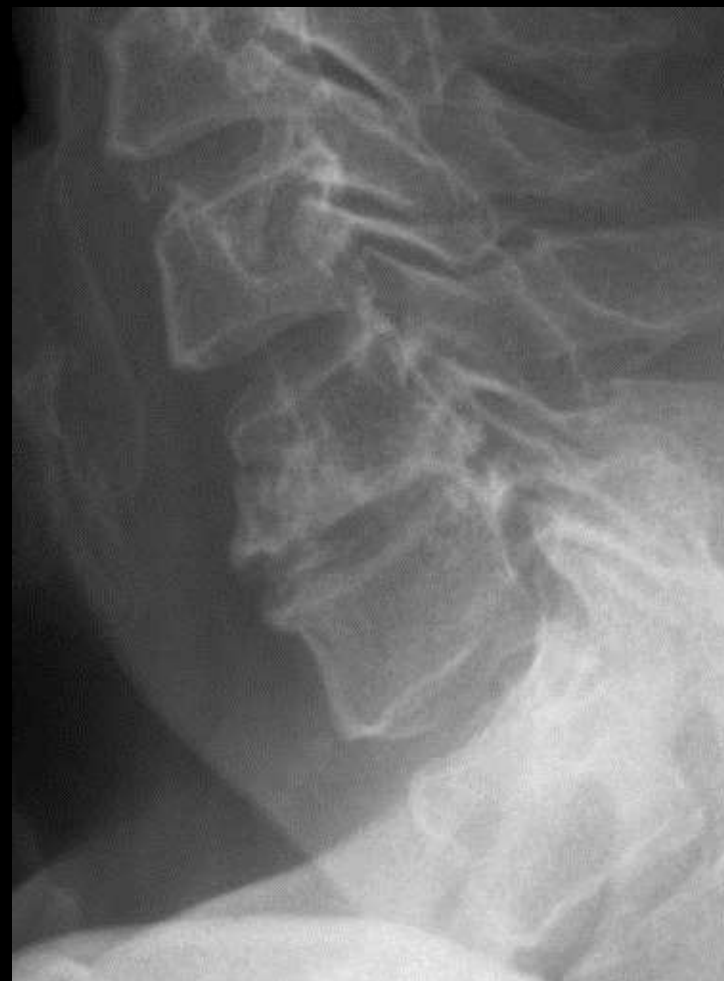Comparing Techniques



Comparing Techniques



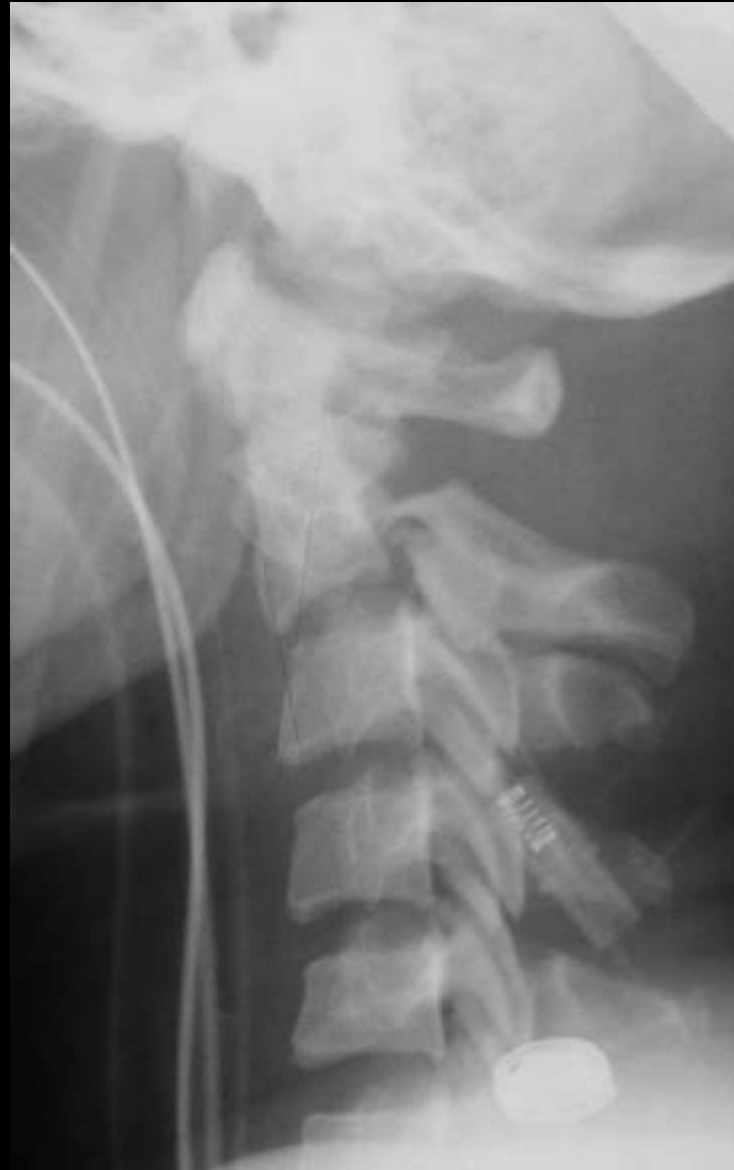6w later



58M Trauma. C6 Fx poorly seen on CT

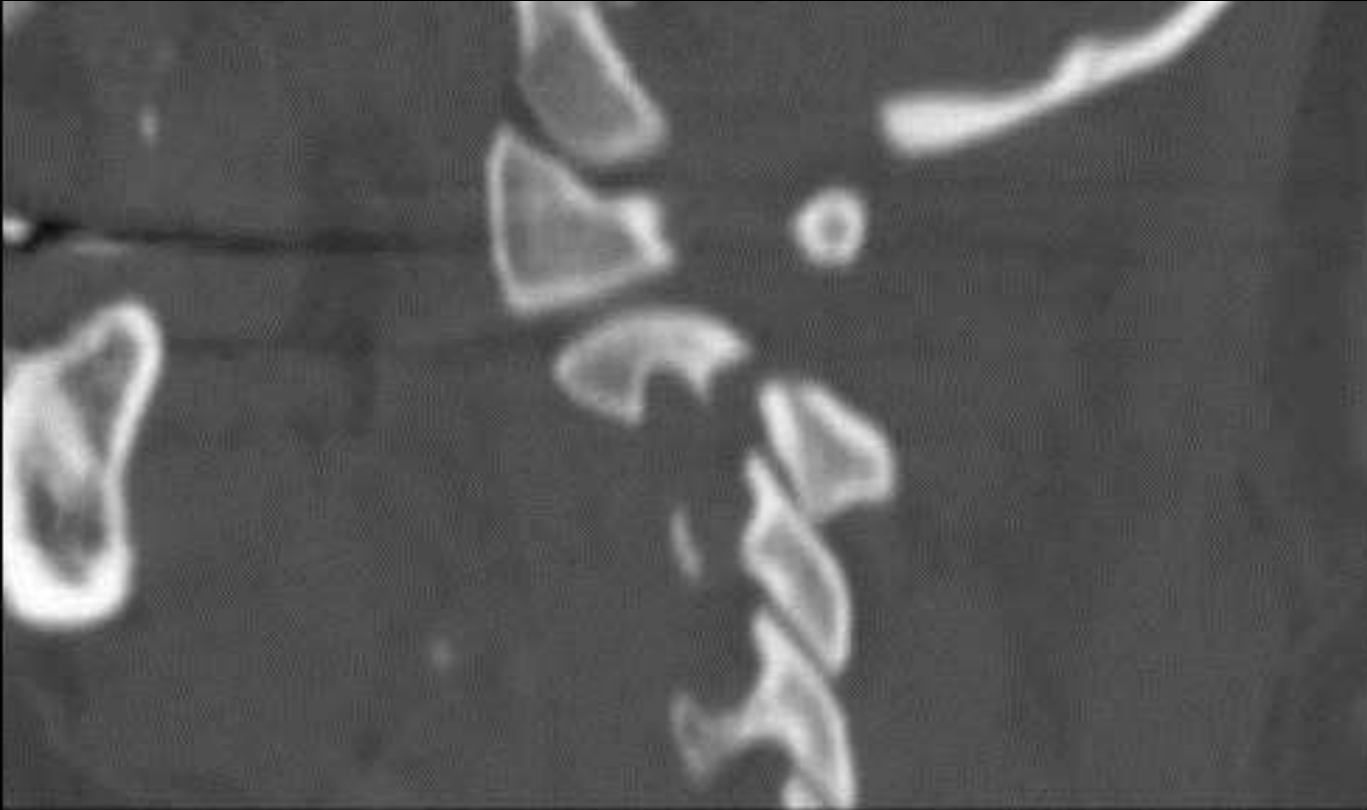Comparing Techniques

Effendi II easier to see on X-ray



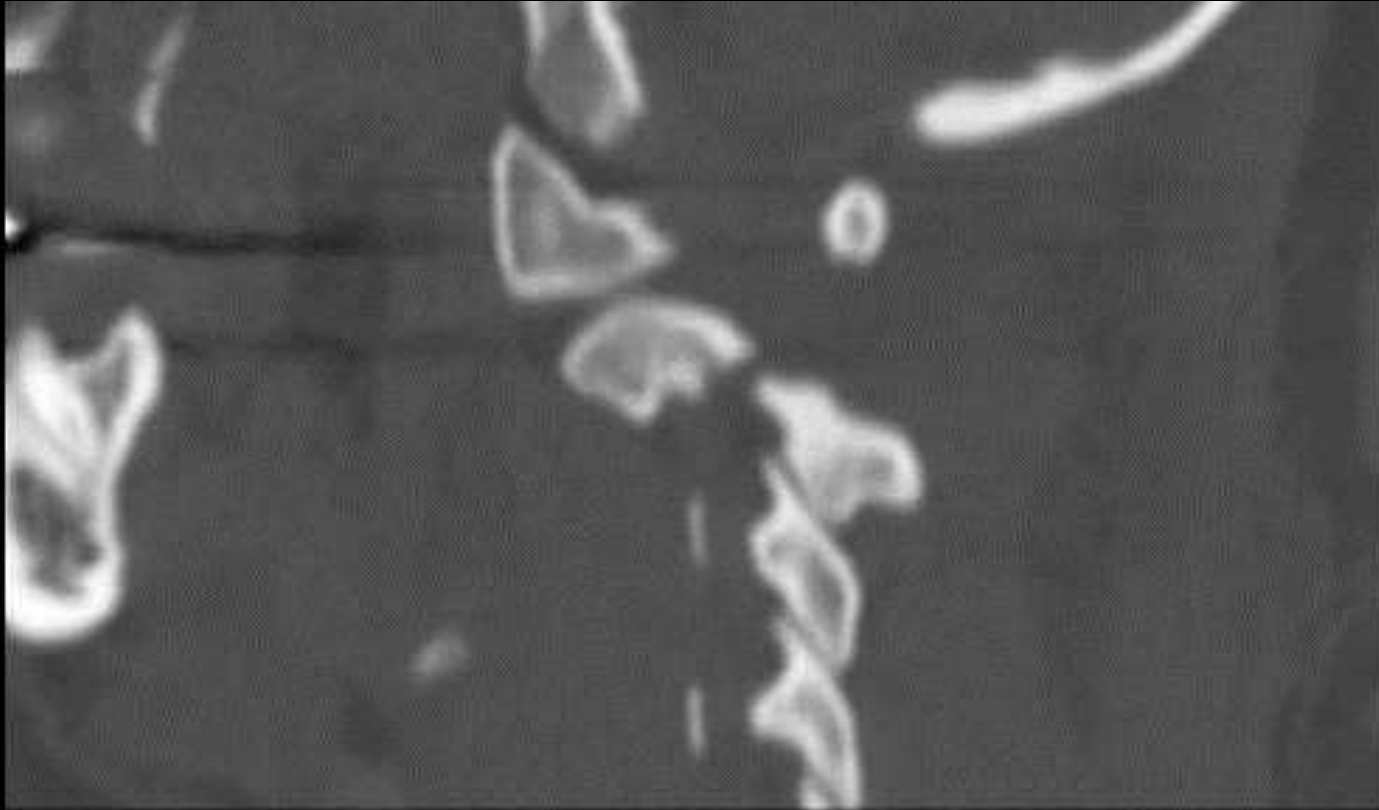
Comparing Techniques

Effendi II easier to see on X-ray



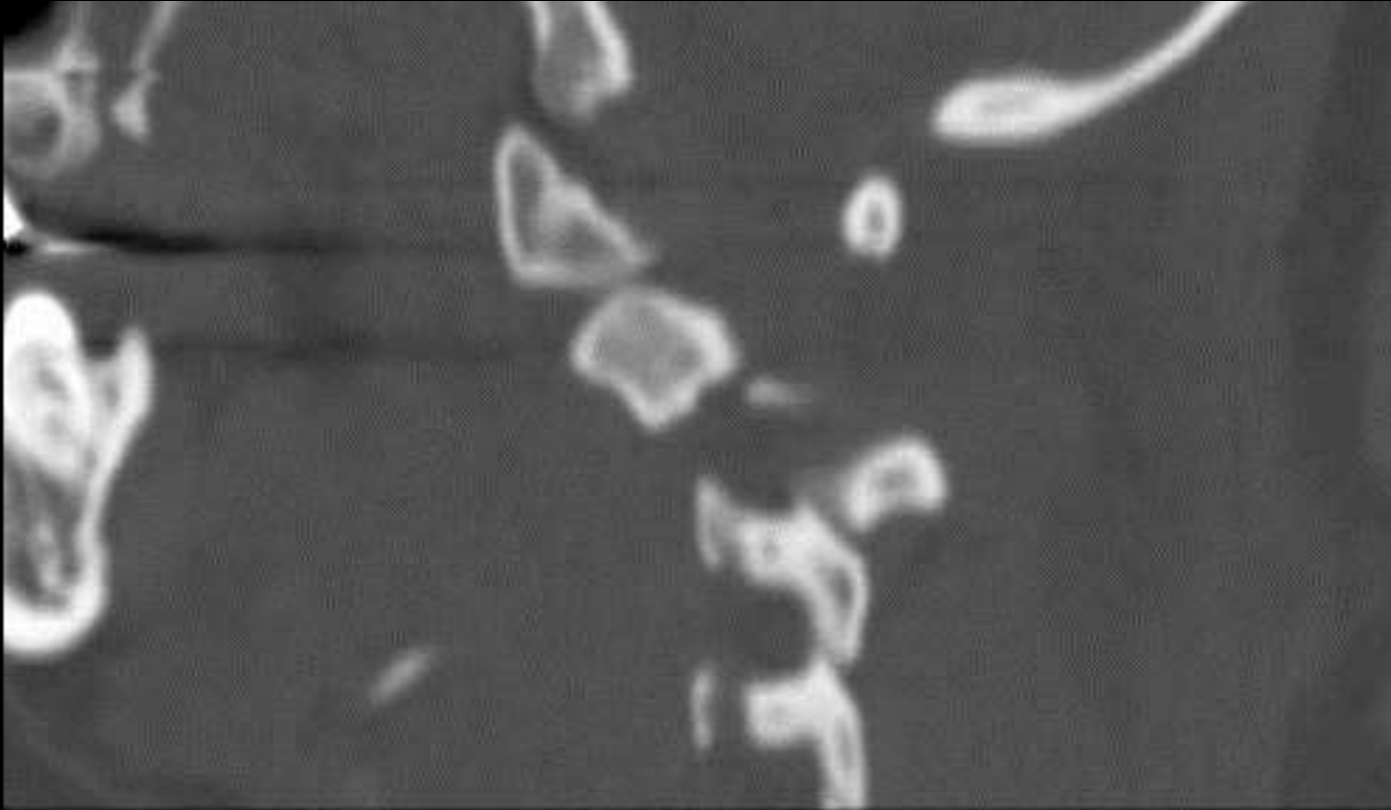
Comparing Techniques

Effendi II easier to see on X-ray



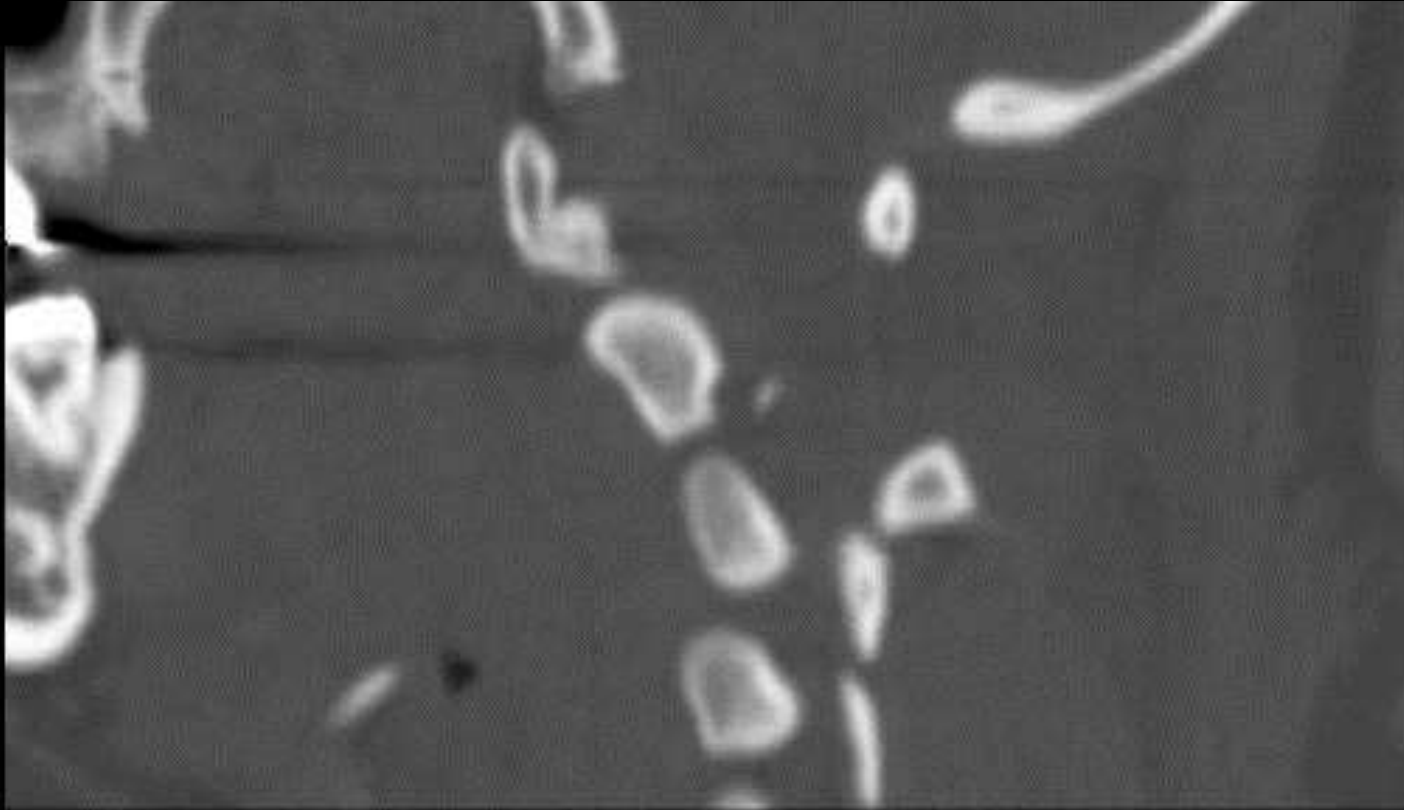
Comparing Techniques

Effendi II easier to see on X-ray



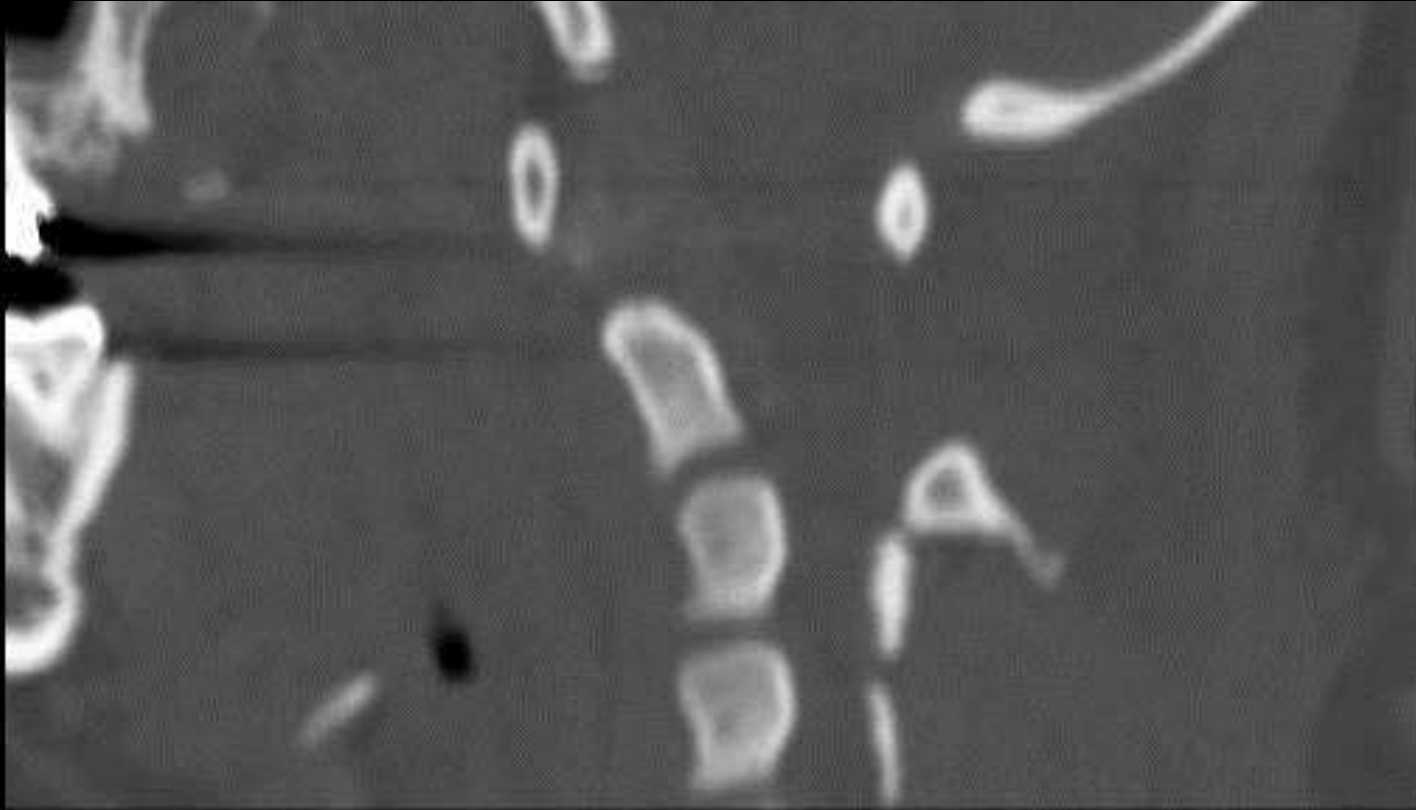Comparing Techniques

Effendi II easier to see on X-ray



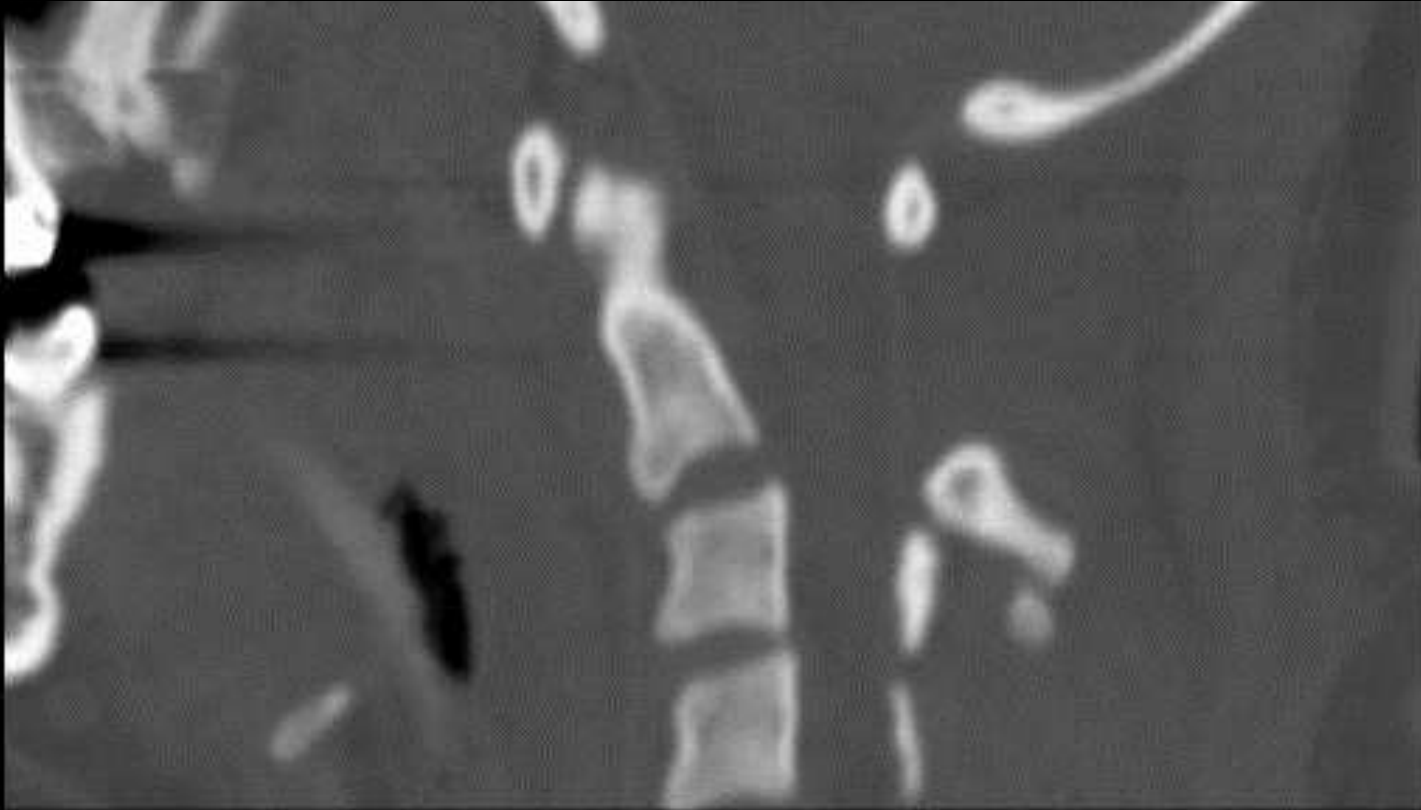Comparing Techniques

Effendi II easier to see on X-ray



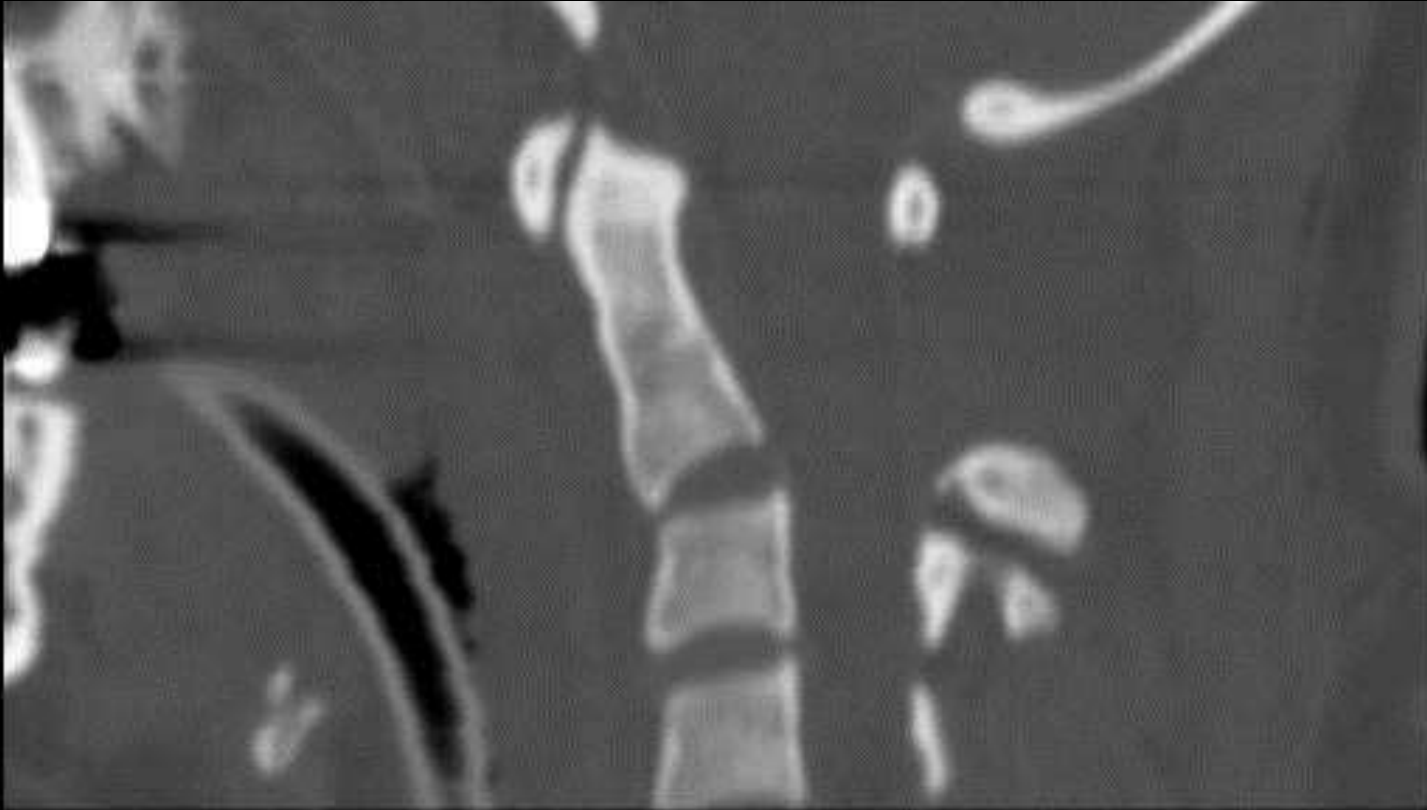Comparing Techniques

Effendi II easier to see on X-ray



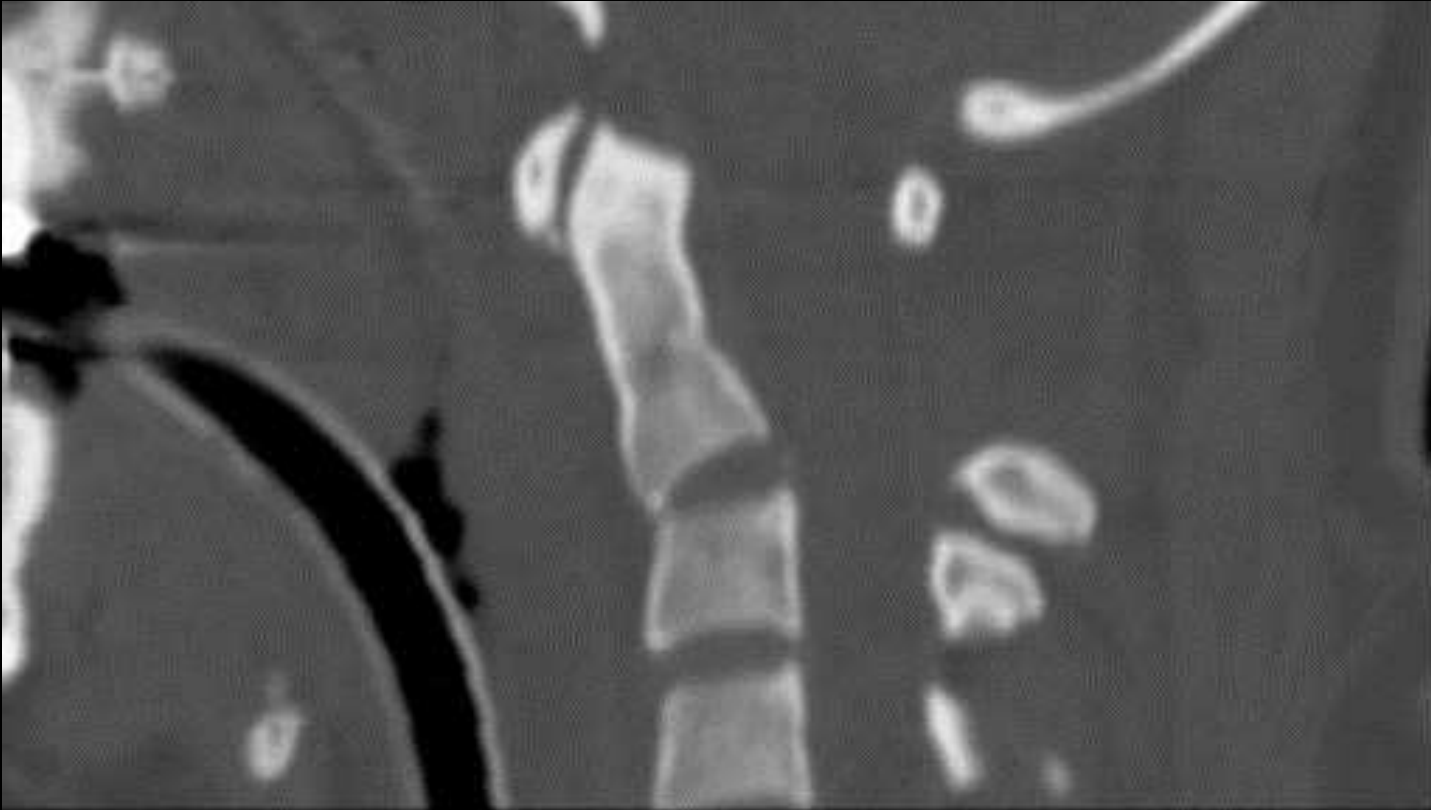Comparing Techniques

Effendi II easier to see on X-ray



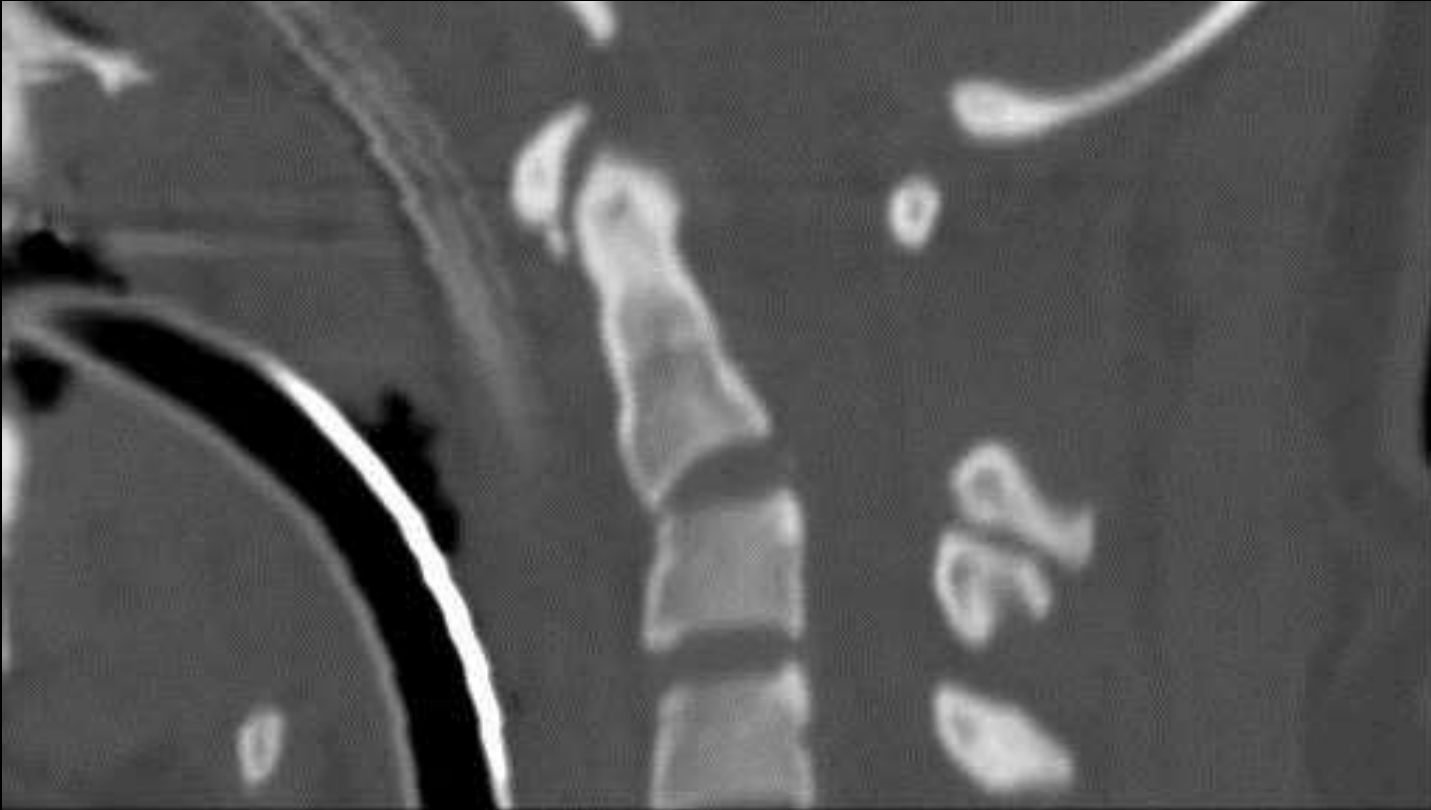
Comparing Techniques

Effendi II easier to see on X-ray



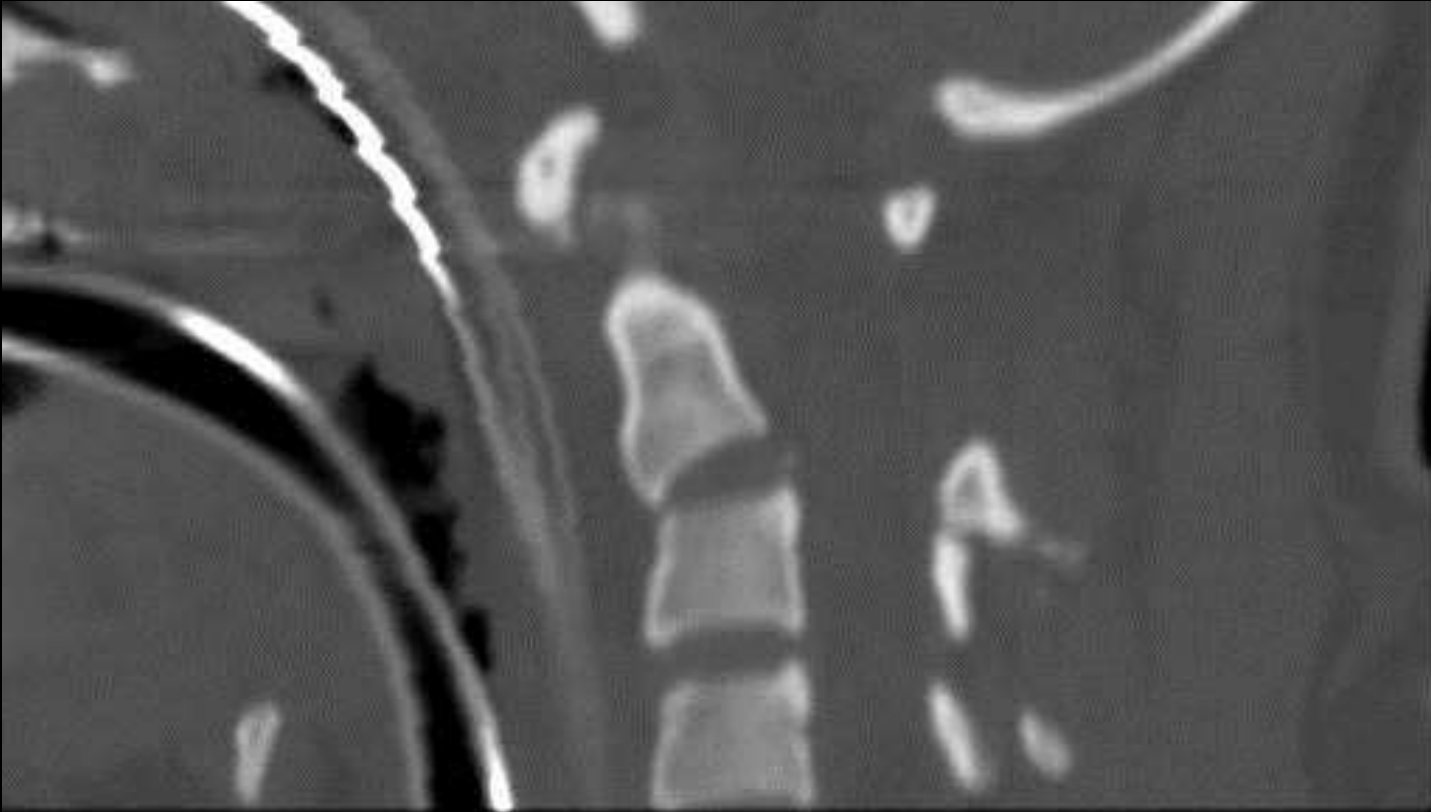
Comparing Techniques

Effendi II easier to see on X-ray



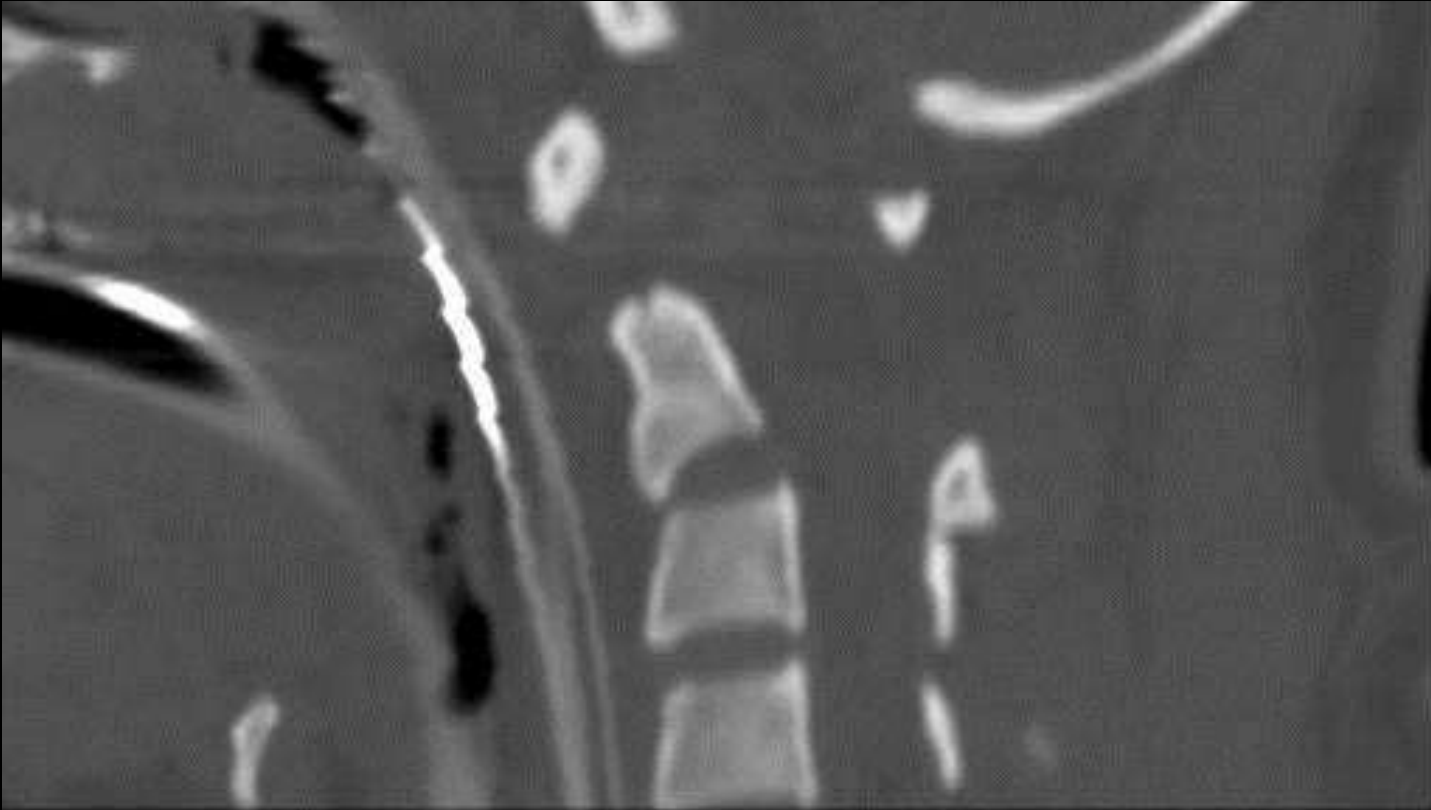Comparing Techniques

Effendi II easier to see on X-ray



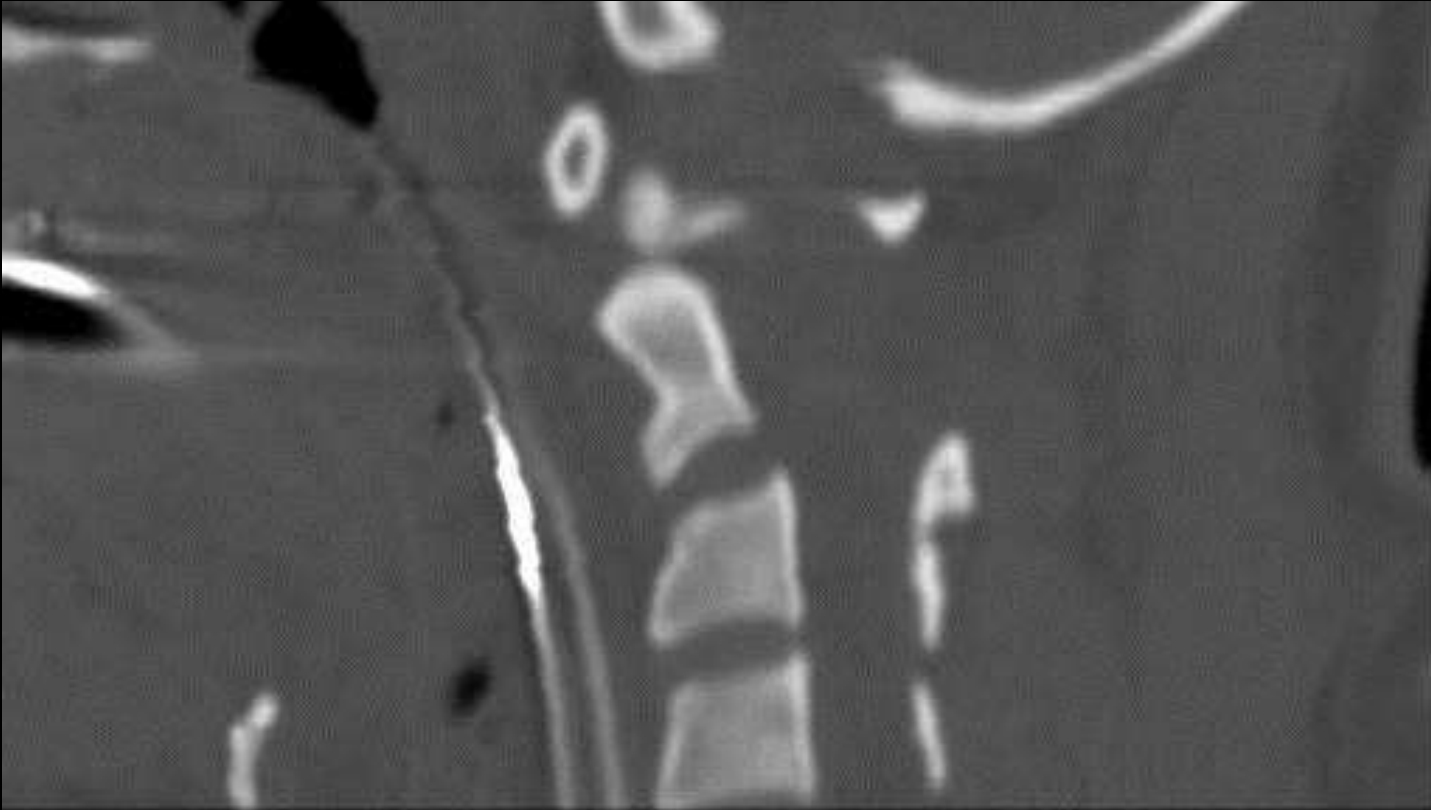Comparing Techniques

Effendi II easier to see on X-ray



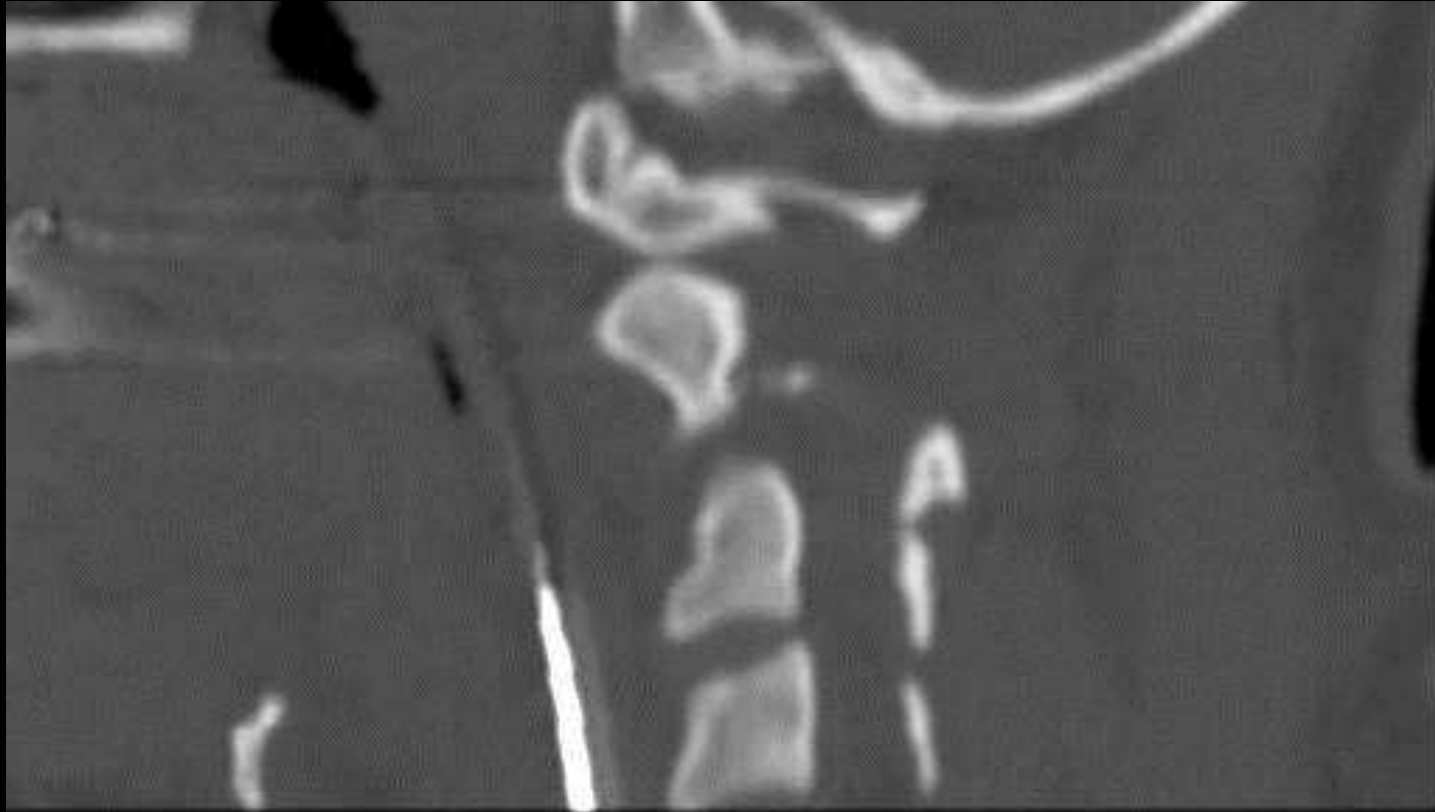Comparing Techniques

Effendi II easier to see on X-ray



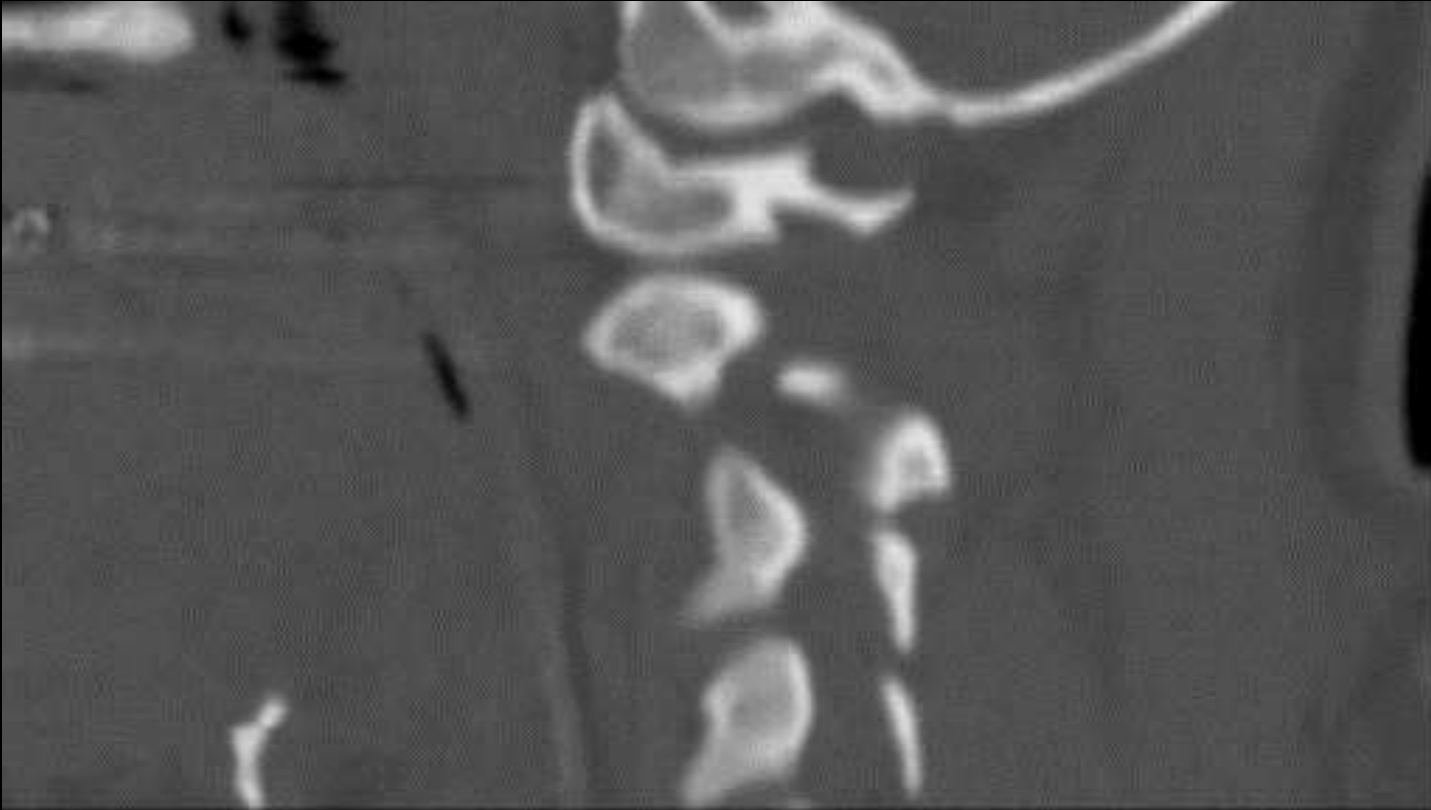Comparing Techniques

Effendi II easier to see on X-ray



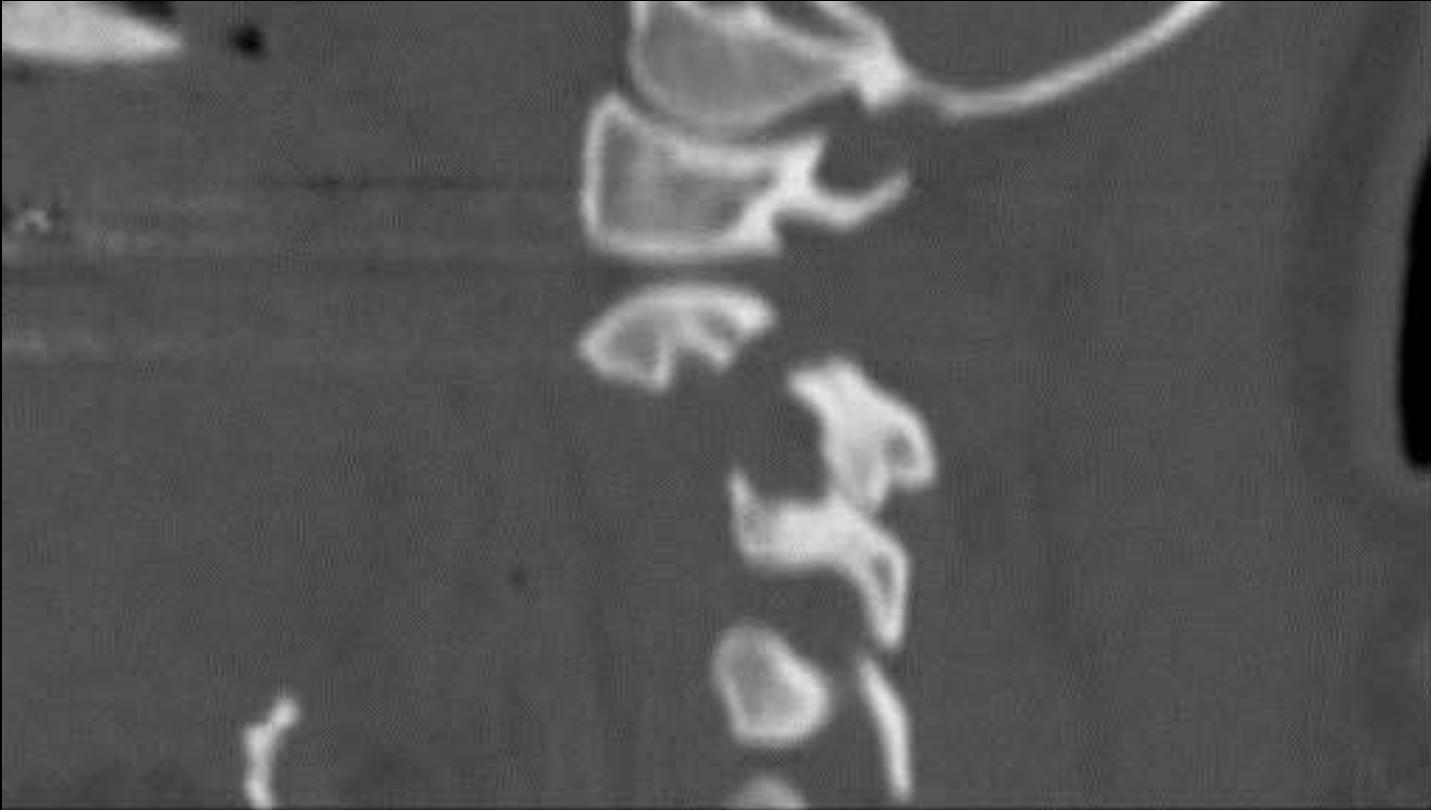Comparing Techniques

Effendi II easier to see on X-ray



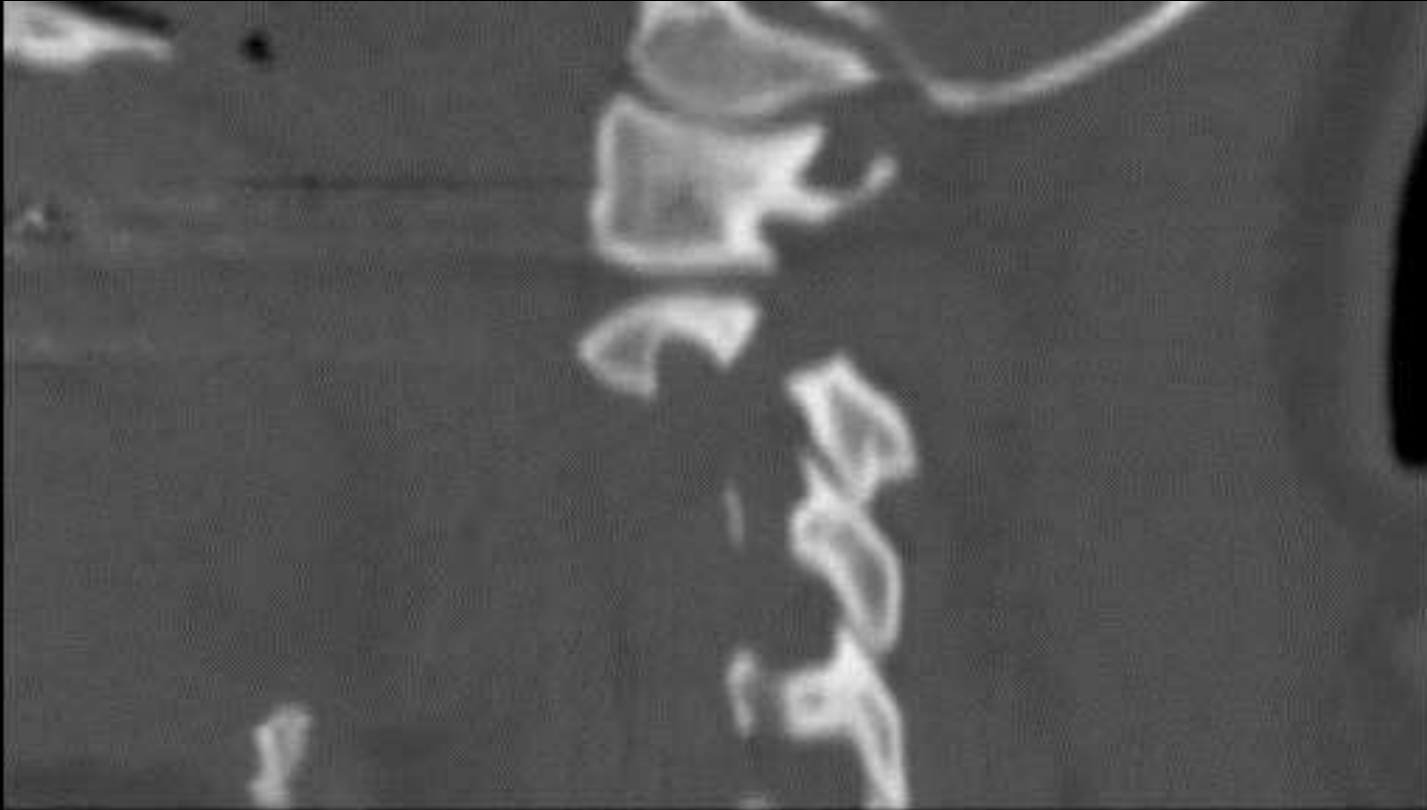Comparing Techniques

Effendi II easier to see on X-ray



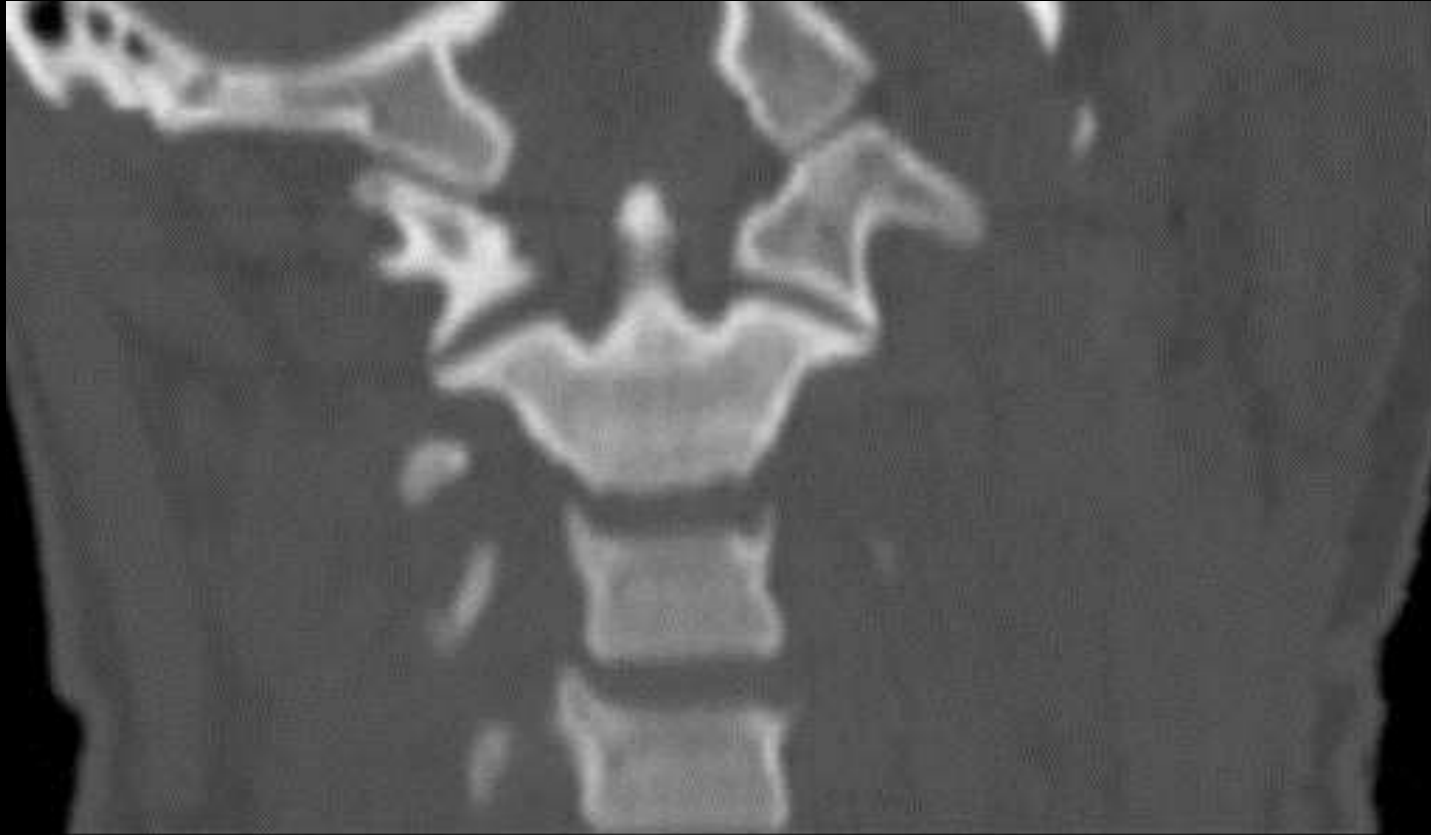Comparing Techniques

Effendi II easier to see on X-ray



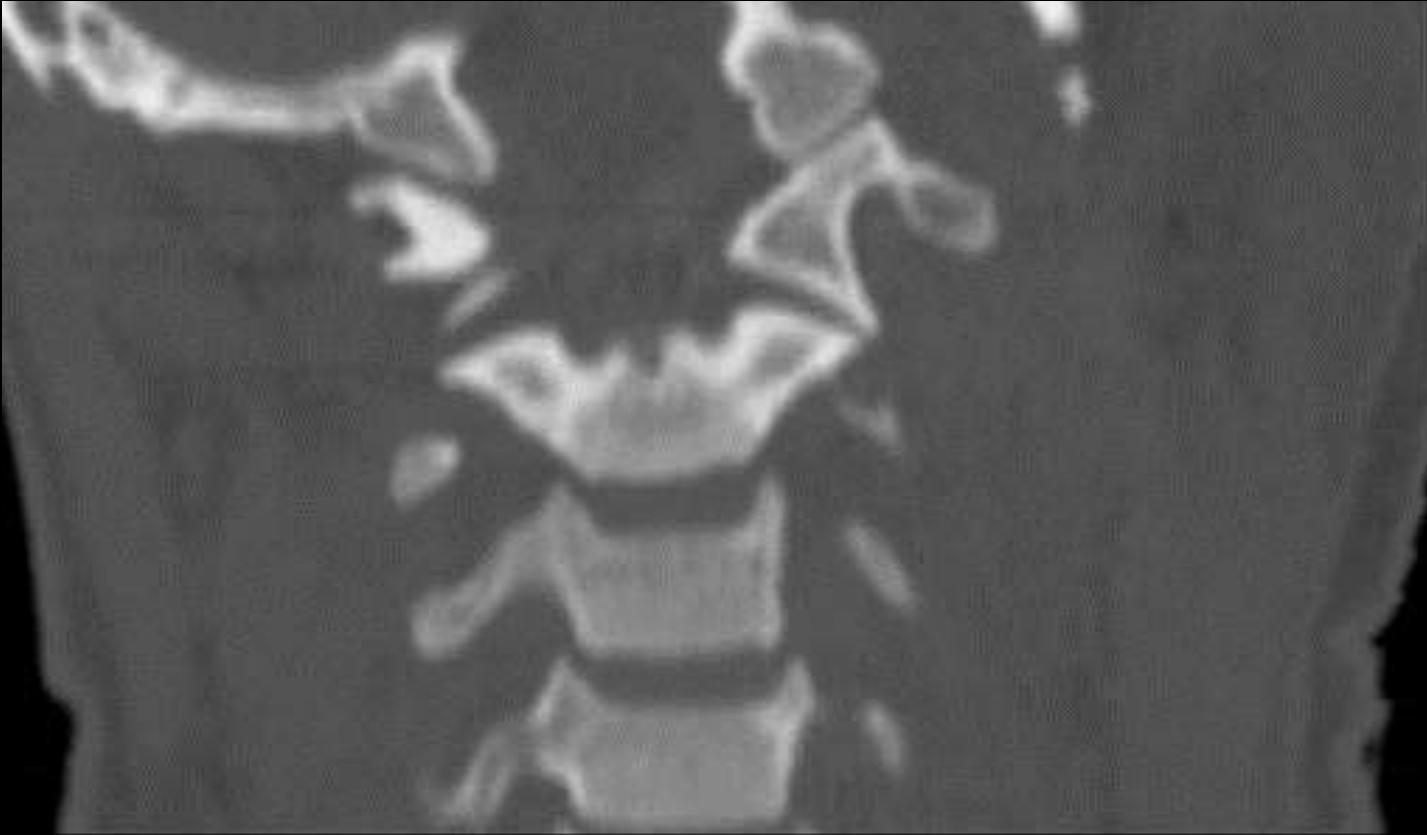Comparing Techniques

Effendi II easier to see on X-ray



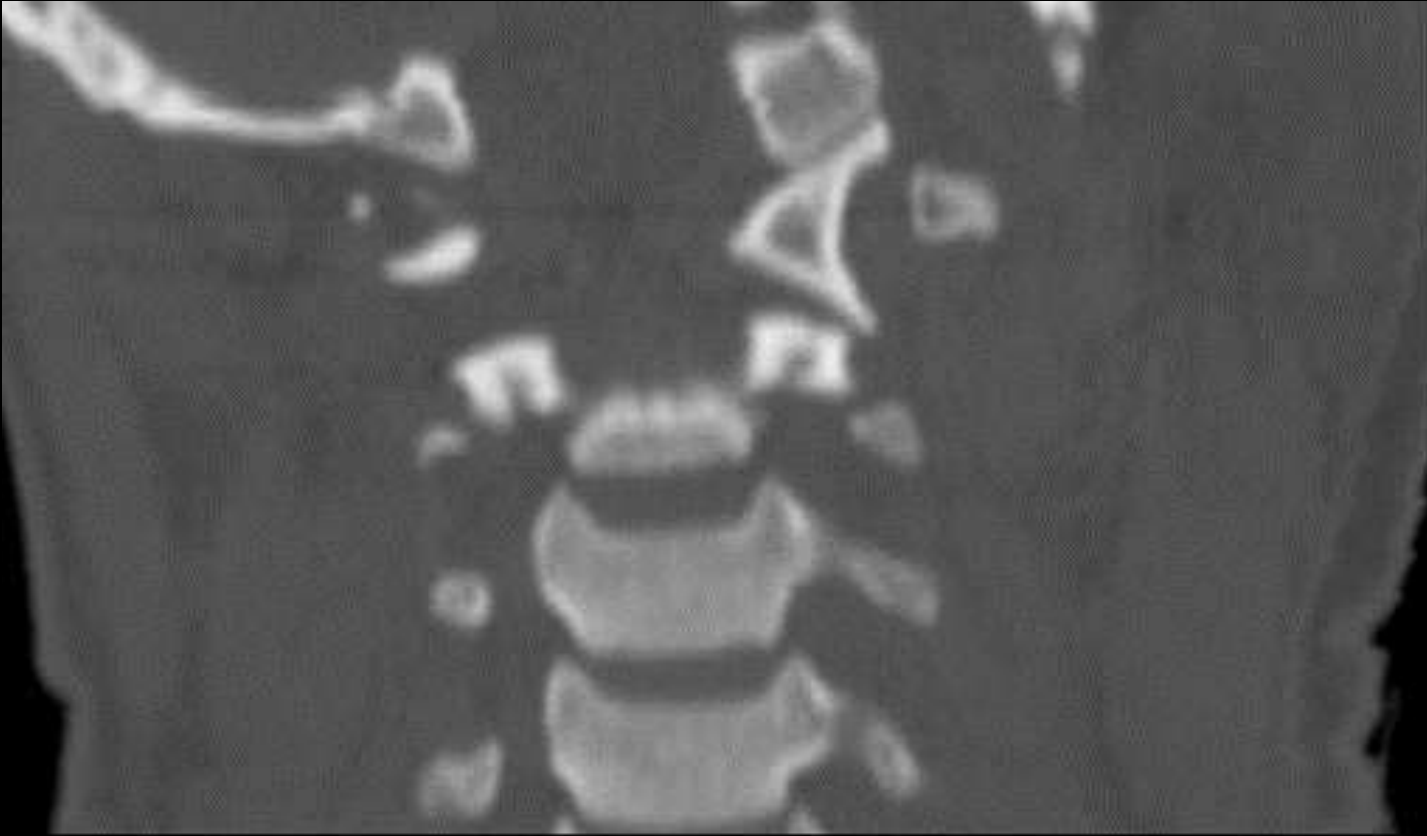Comparing Techniques

Effendi II easier to see on X-ray



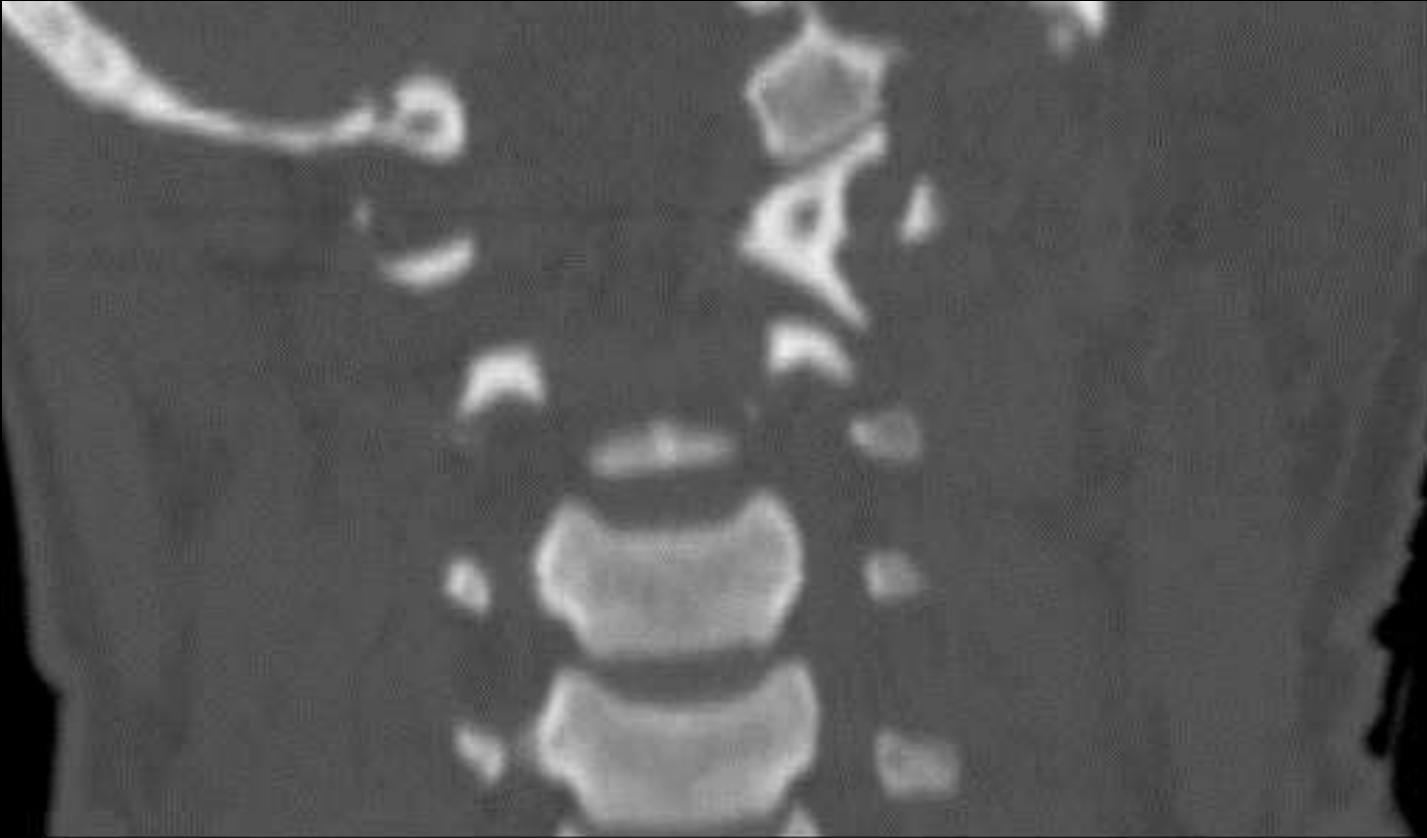
Comparing Techniques

Effendi II easier to see on X-ray



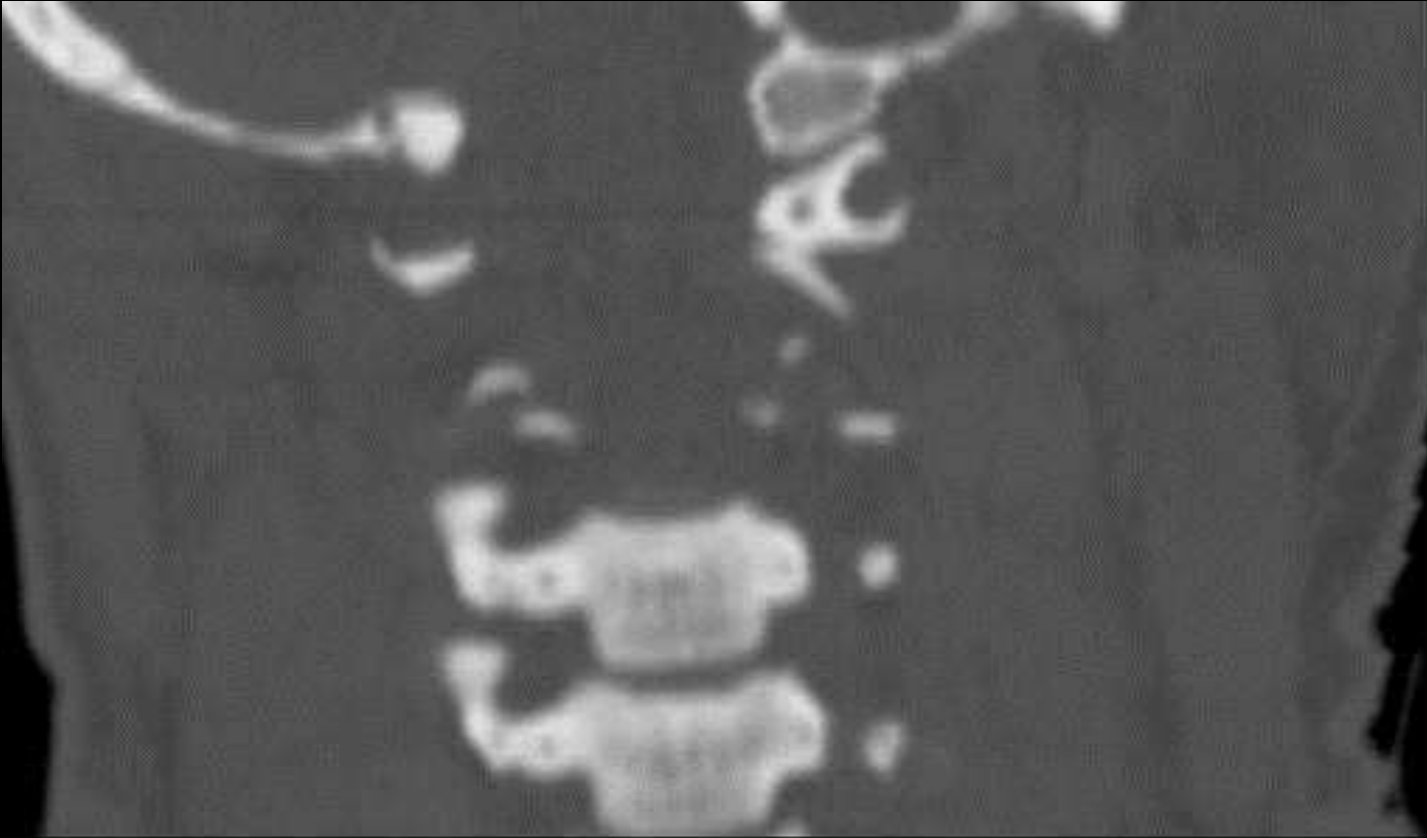Comparing Techniques

Effendi II easier to see on X-ray



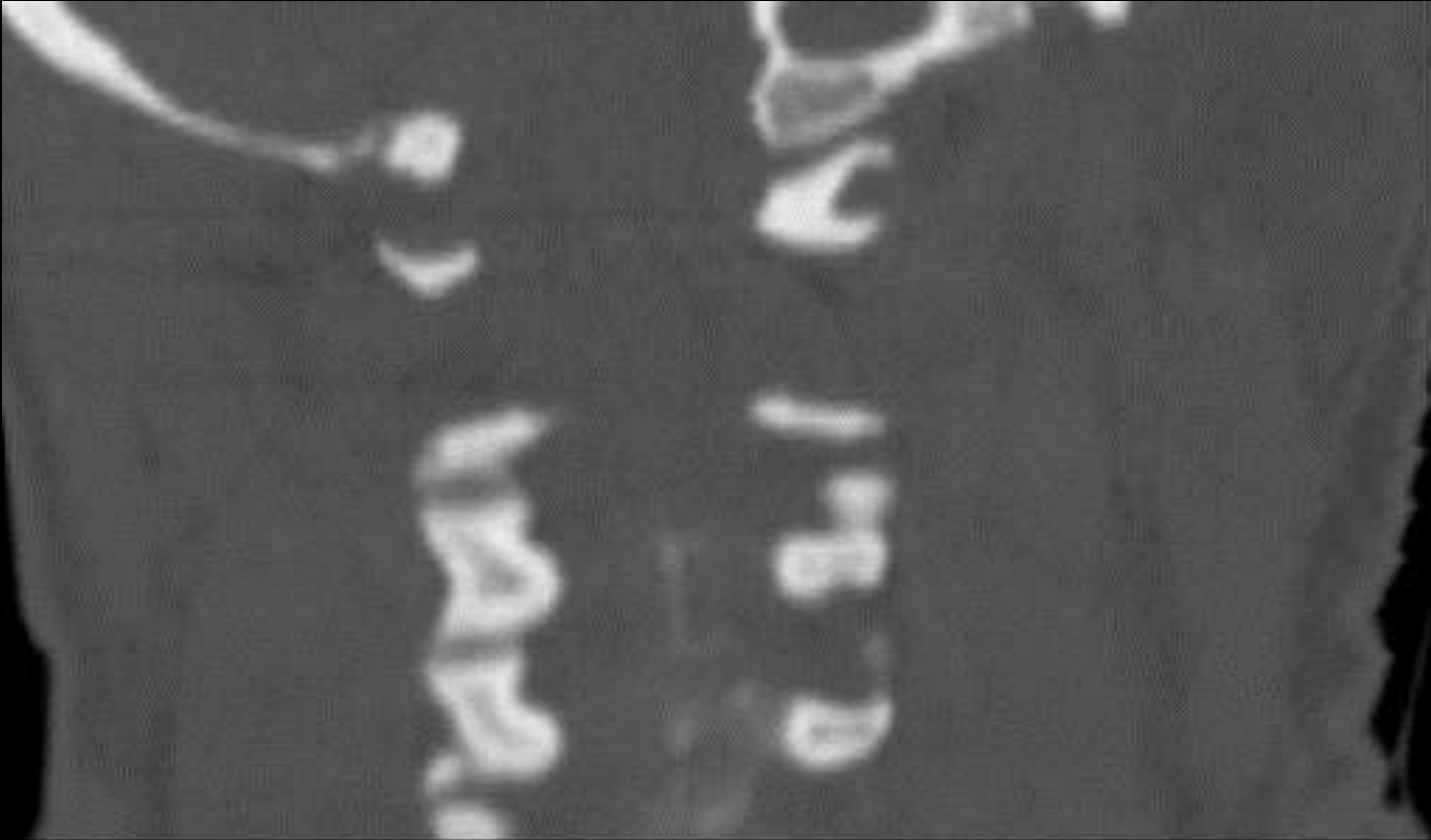Comparing Techniques

Effendi II easier to see on X-ray



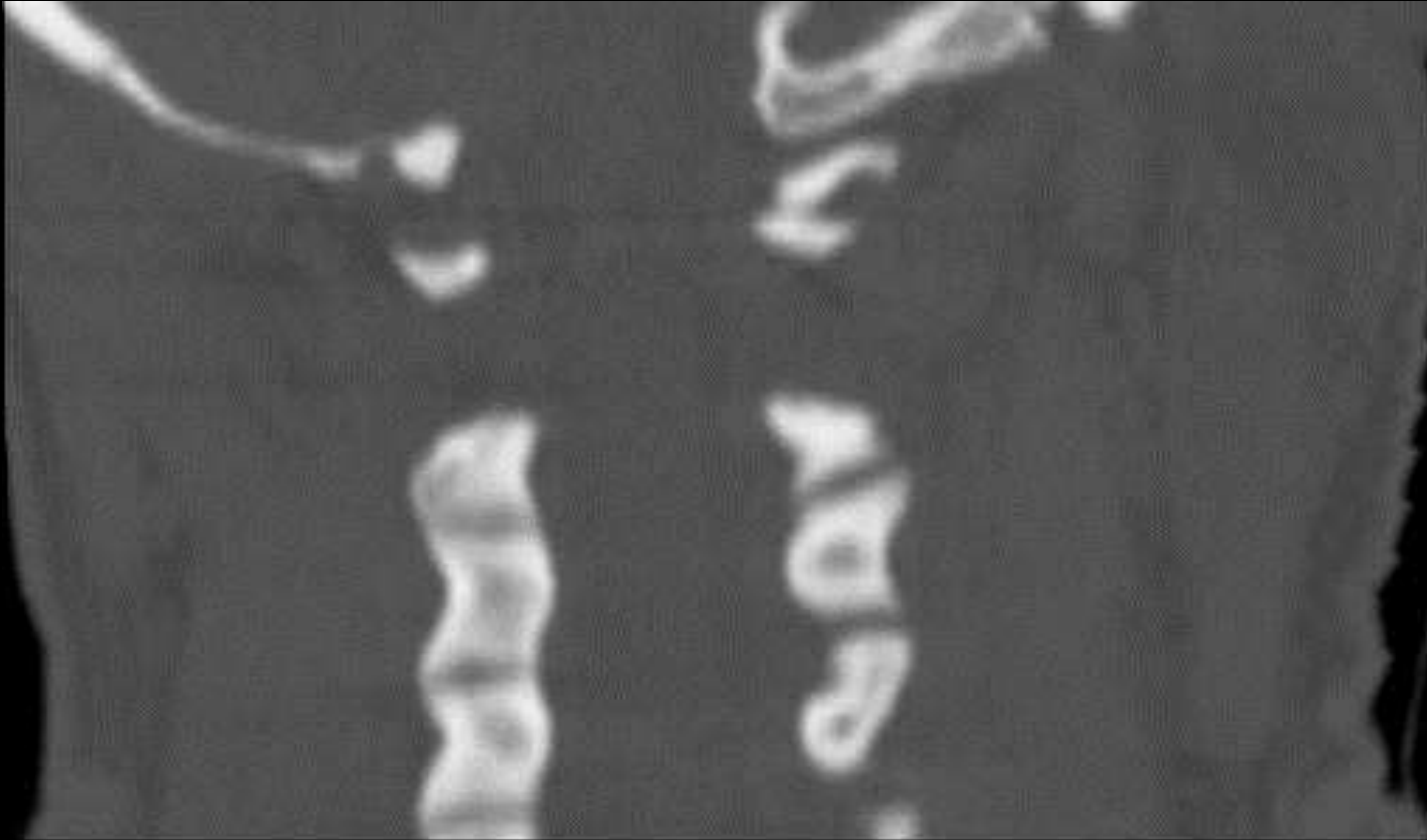Comparing Techniques

Effendi II easier to see on X-ray



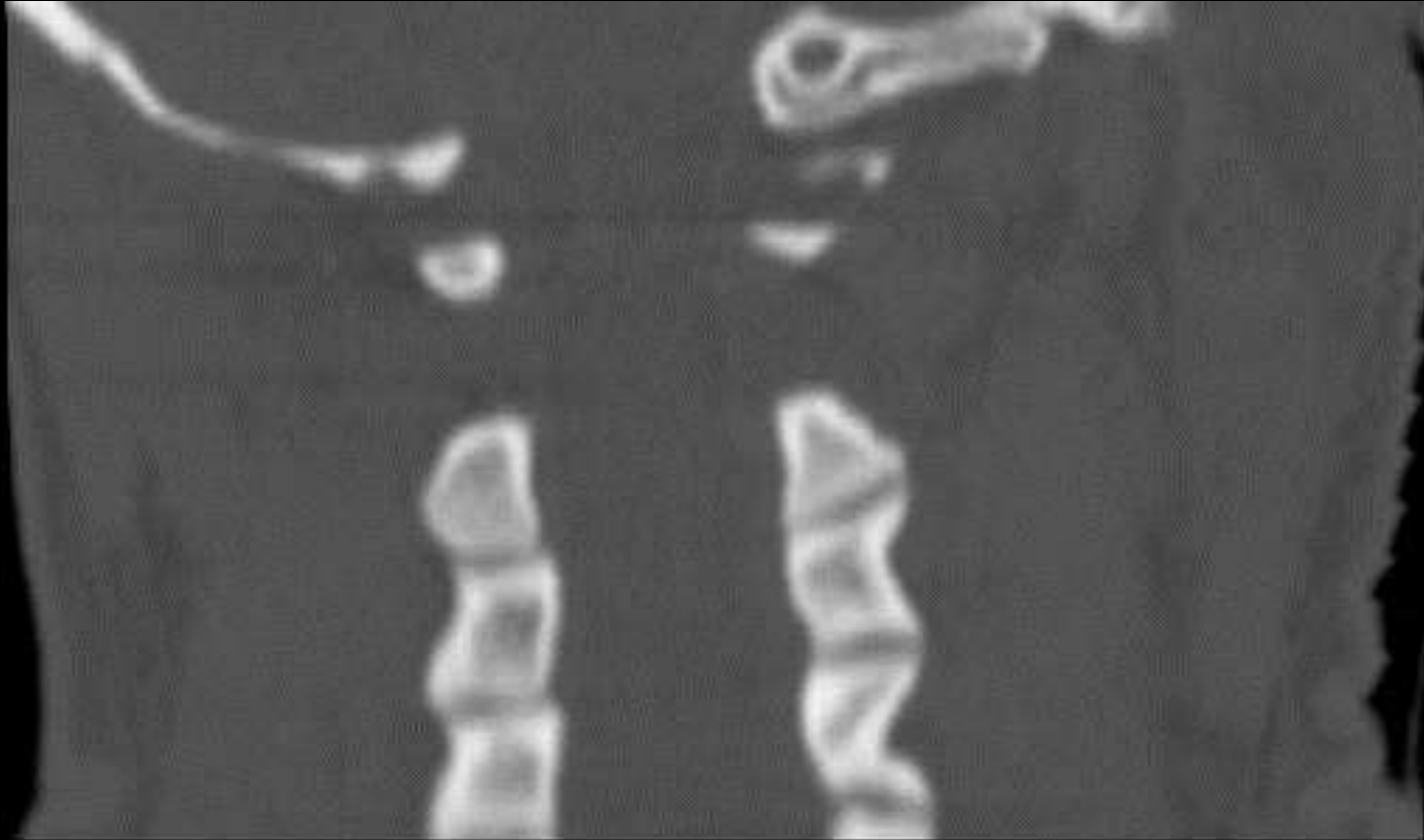Comparing Techniques

Effendi II easier to see on X-ray



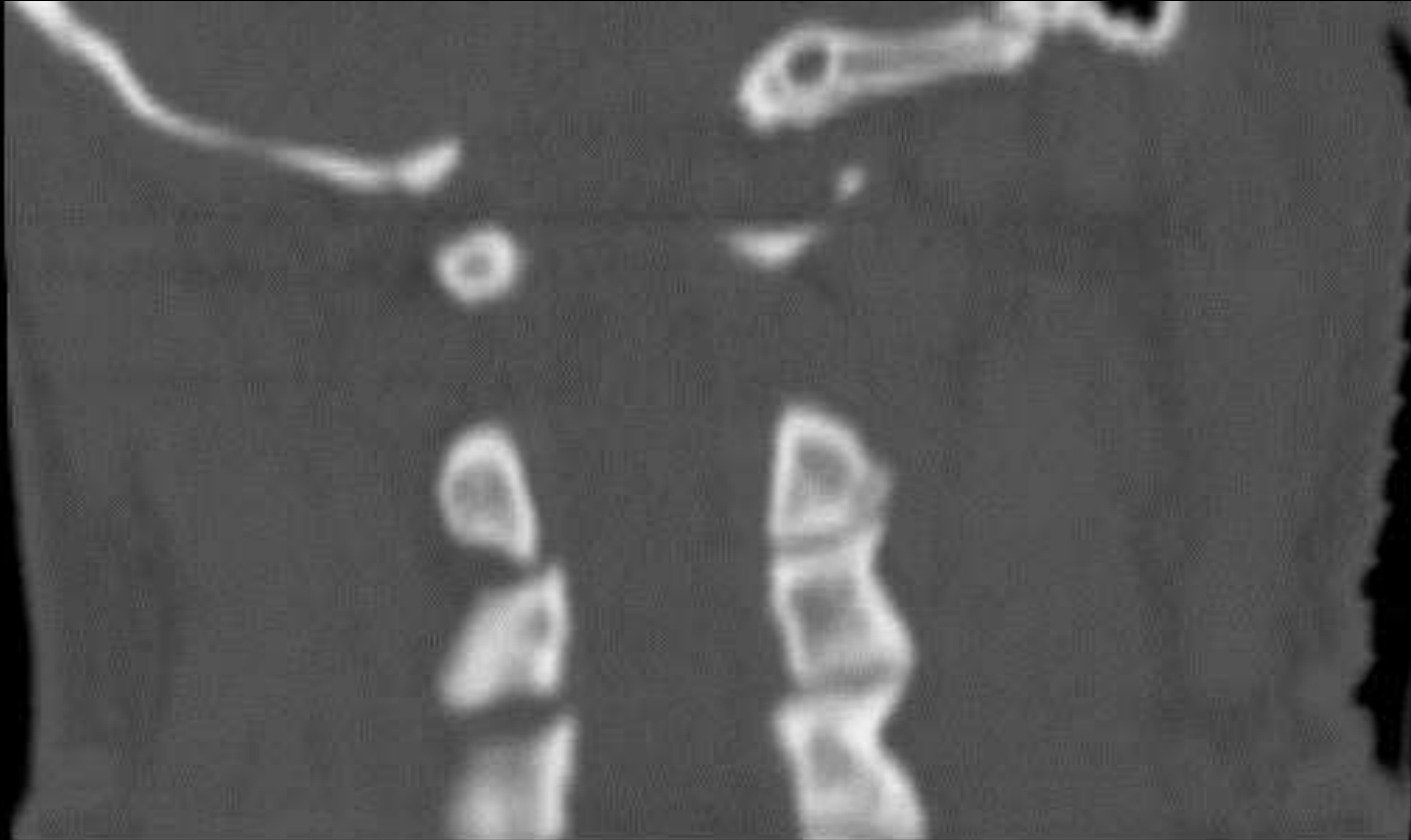
Comparing Techniques

Effendi II easier to see on X-ray



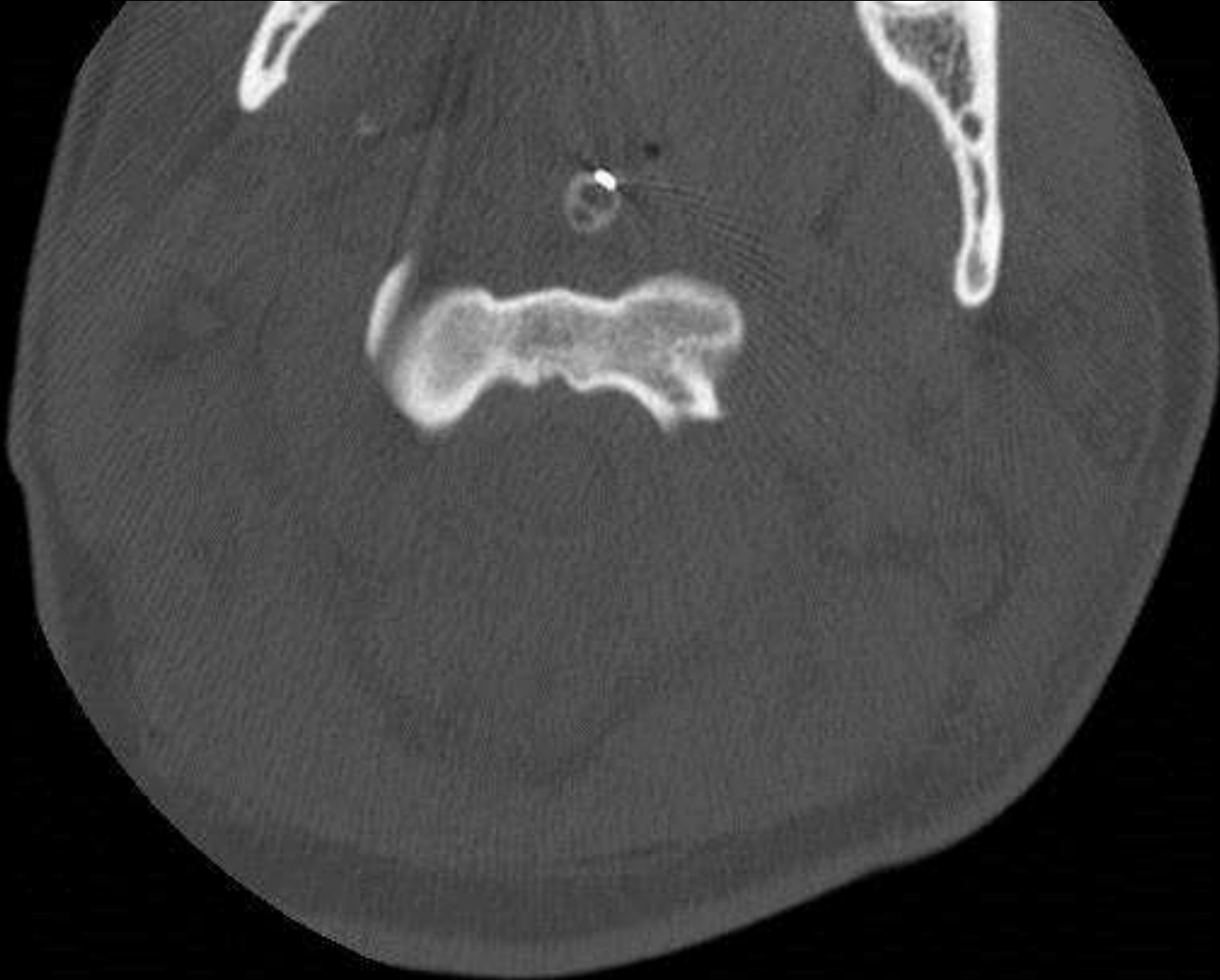
Comparing Techniques

Effendi II easier to see on X-ray



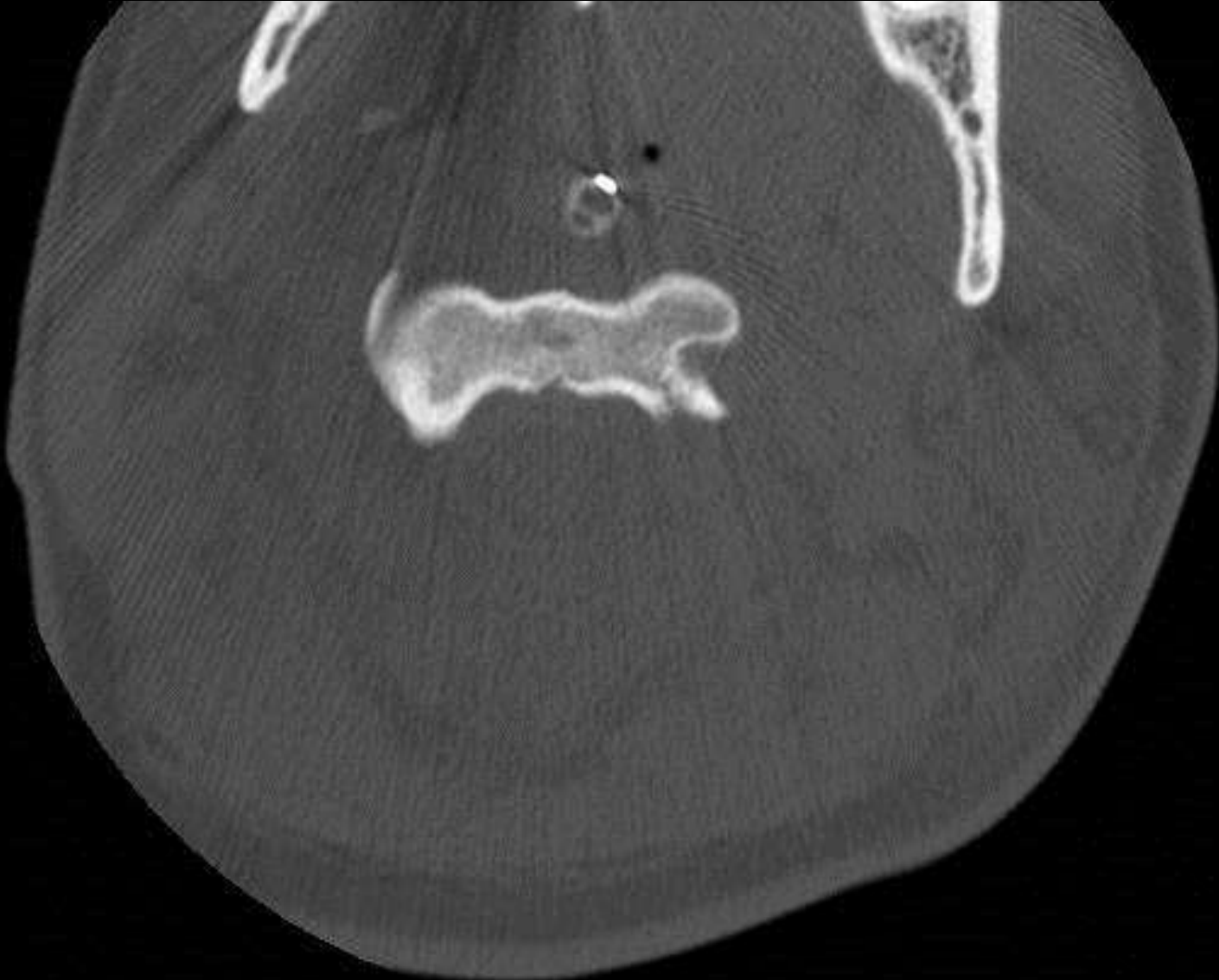Comparing Techniques

Effendi II easier to see on X-ray



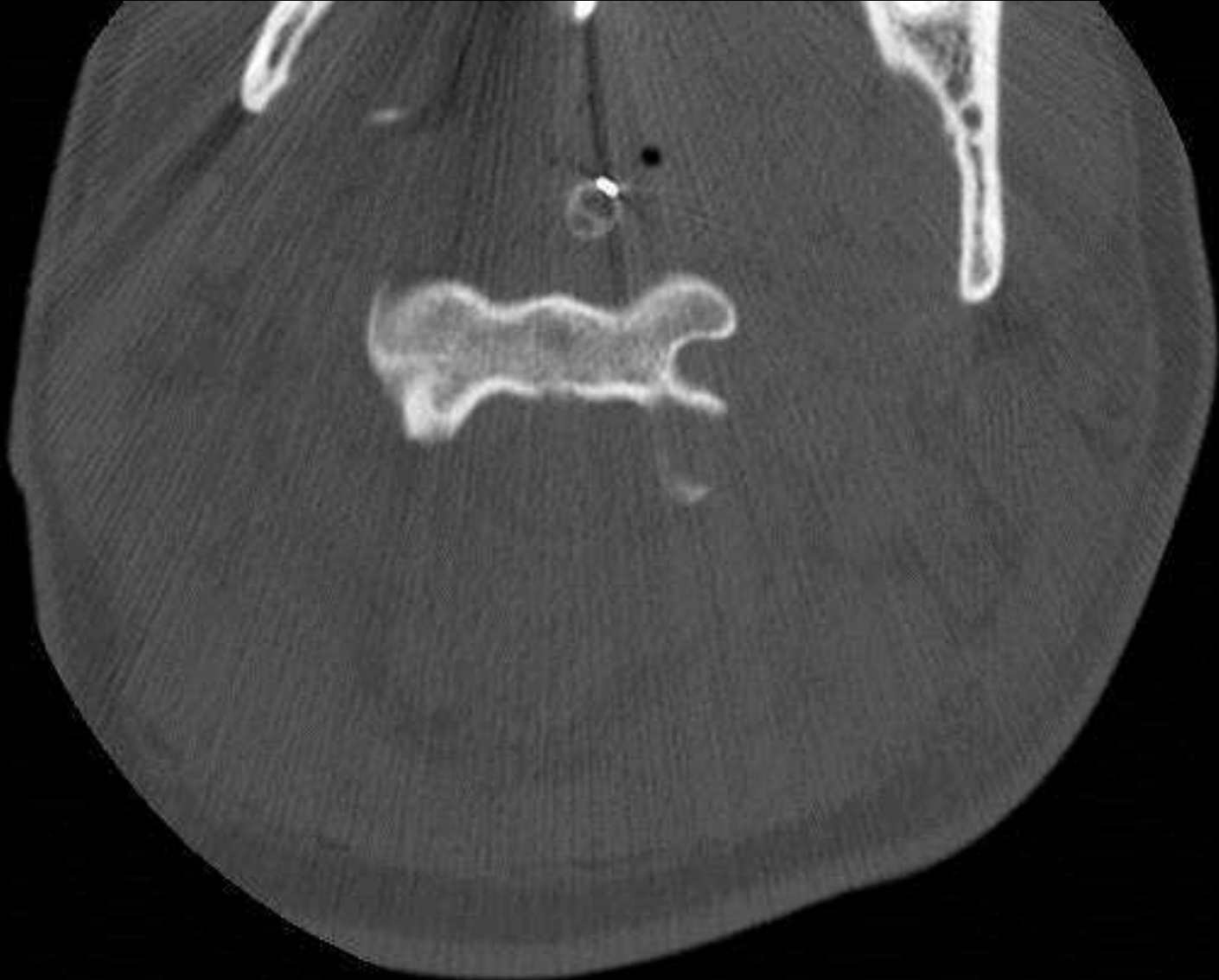
Comparing Techniques

Effendi II easier to see on X-ray



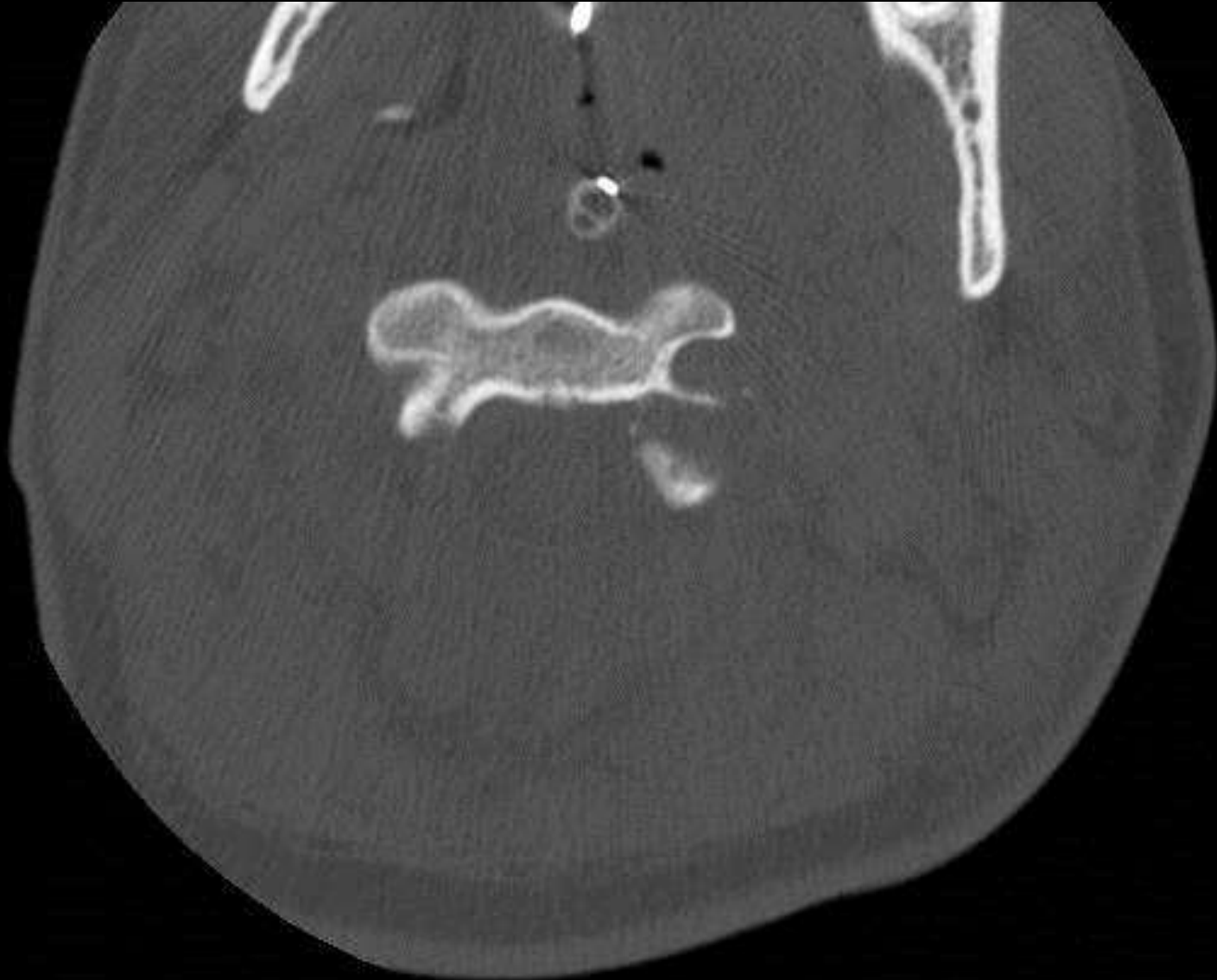Comparing Techniques

Effendi II easier to see on X-ray



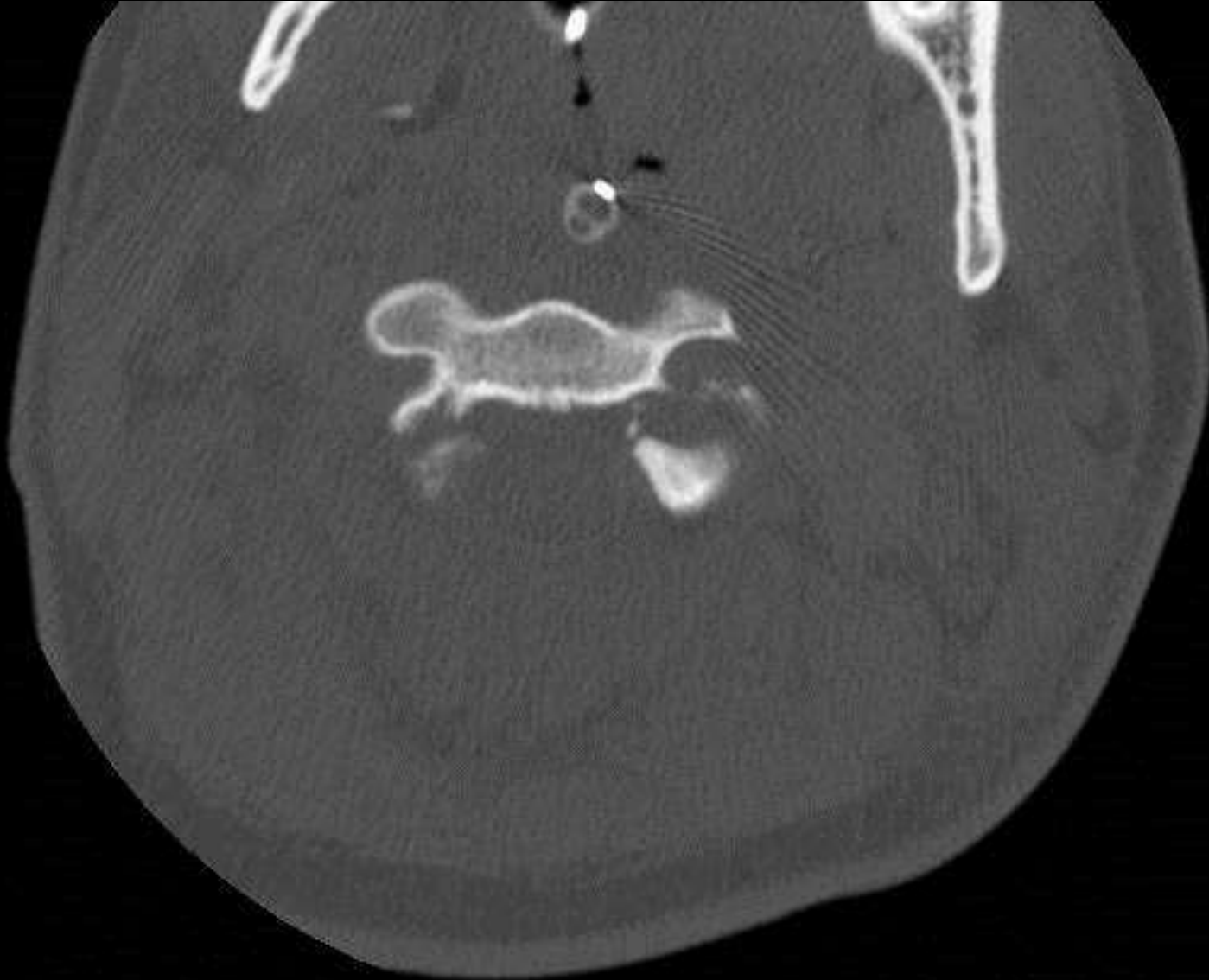Comparing Techniques

Effendi II easier to see on X-ray



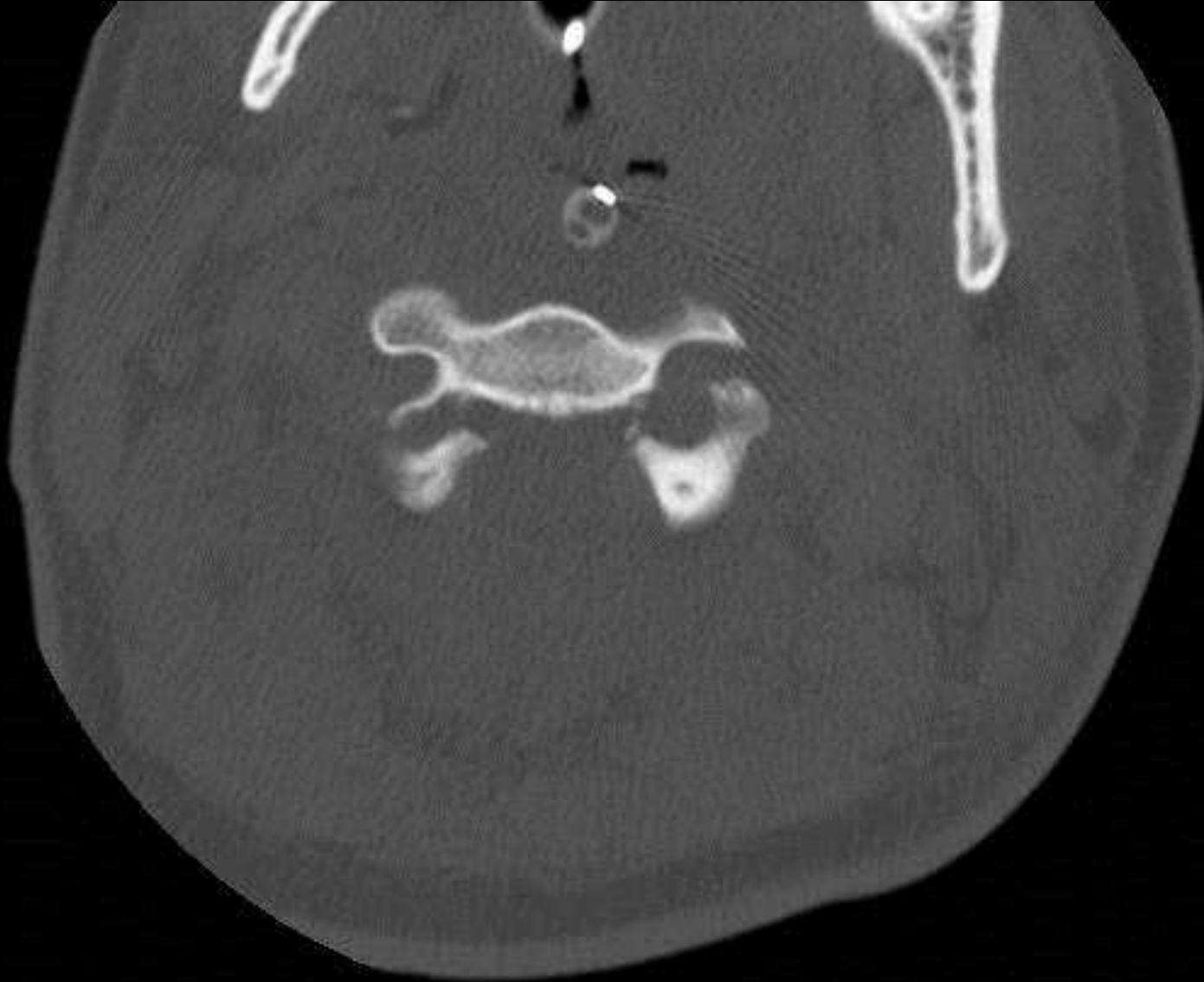Comparing Techniques

Effendi II easier to see on X-ray



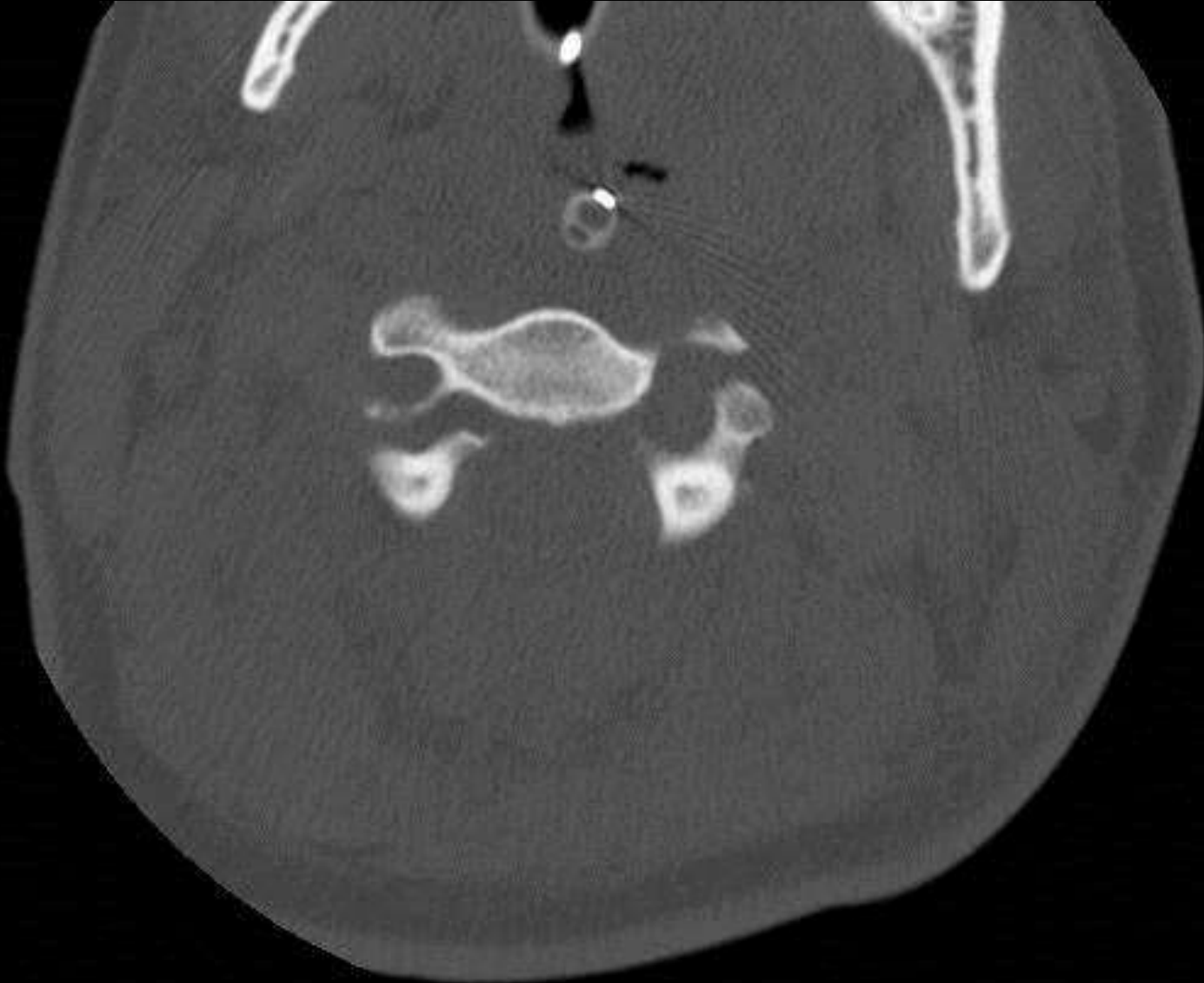Comparing Techniques

Effendi II easier to see on X-ray



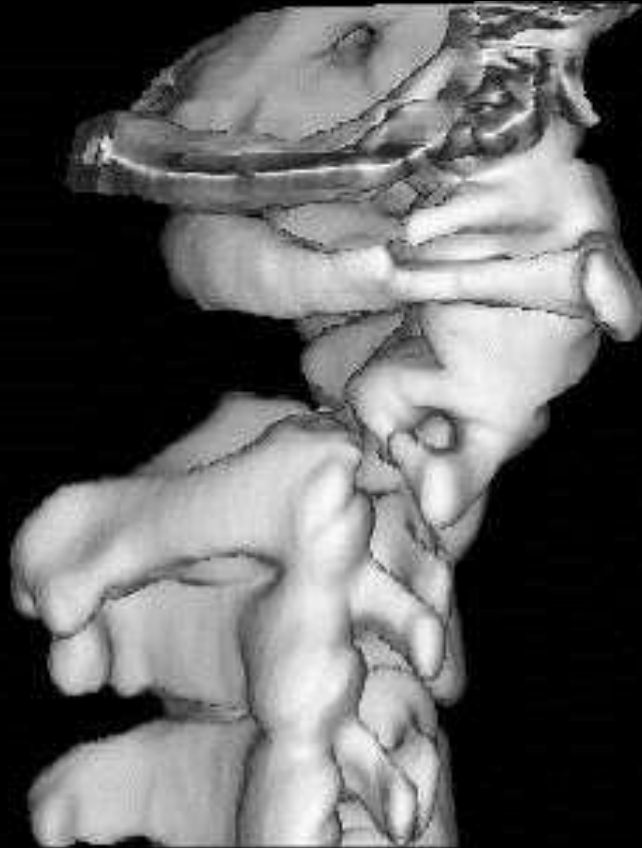
Comparing Techniques

Effendi II easier to see on X-ray



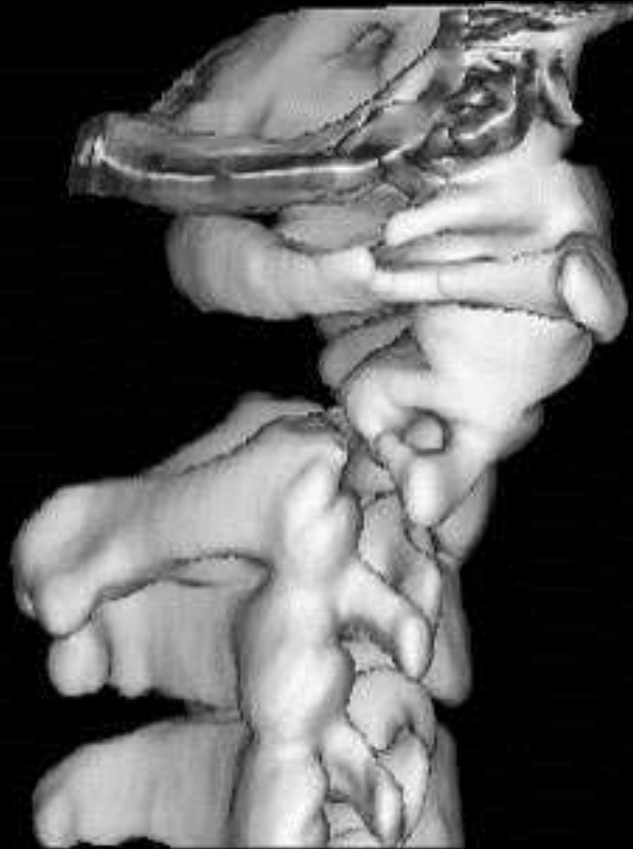
Comparing Techniques

Effendi II easier to see on X-ray



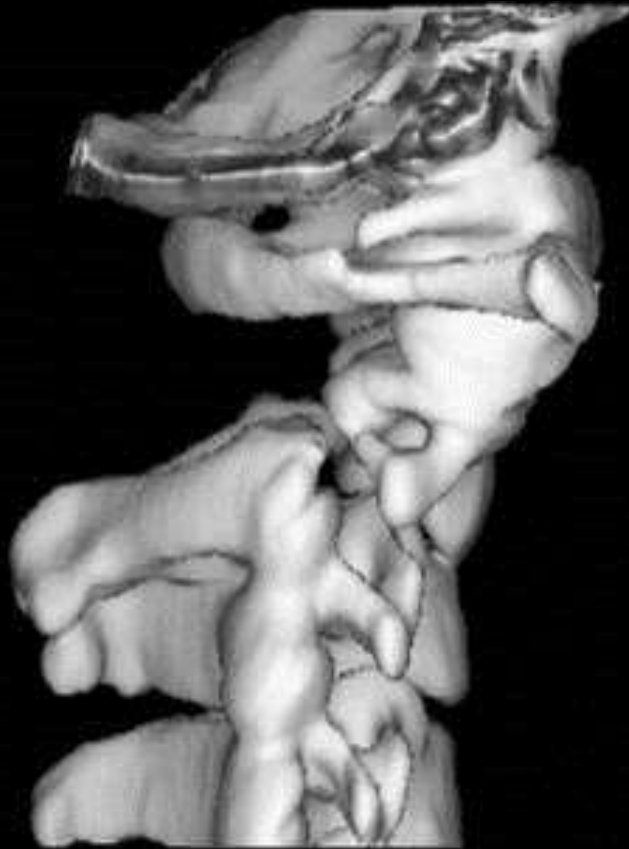Comparing Techniques

Effendi II easier to see on X-ray



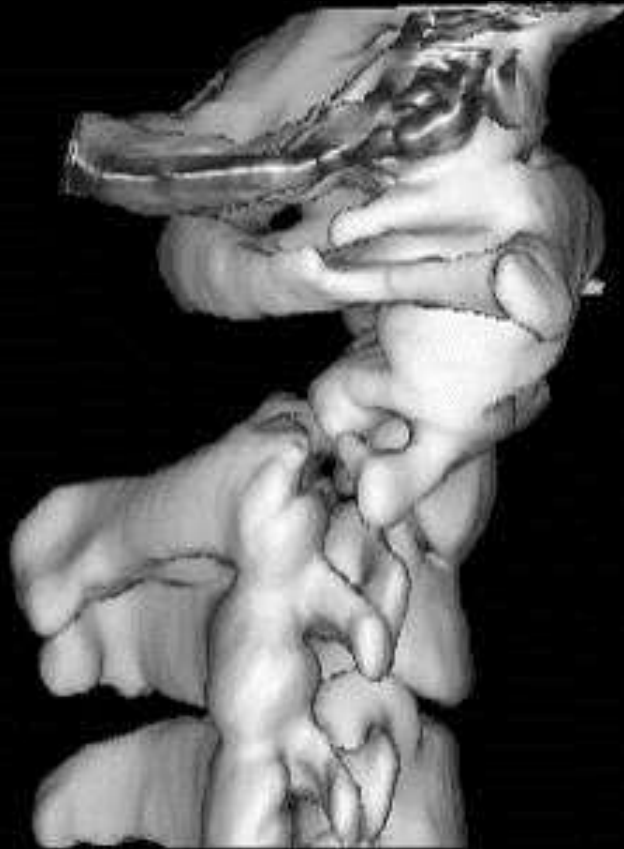
Comparing Techniques

Effendi II easier to see on X-ray



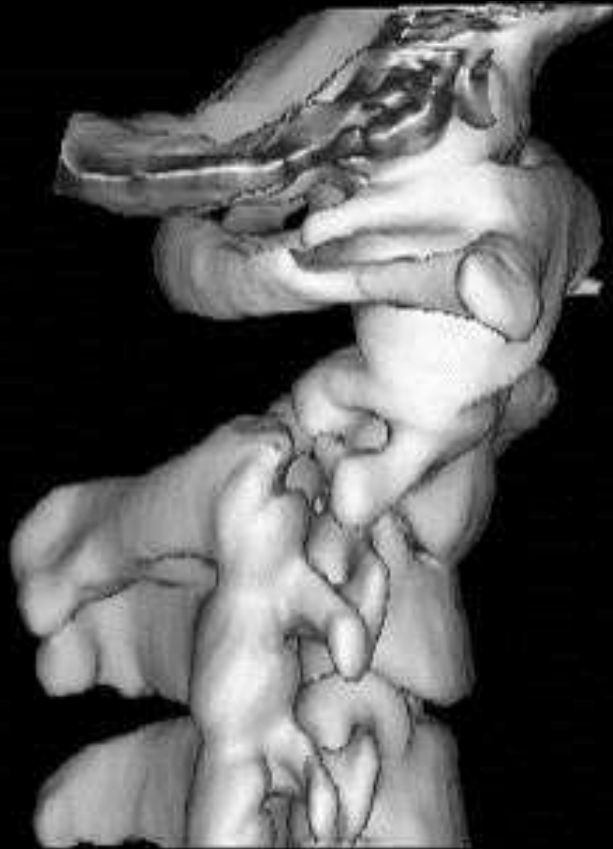Comparing Techniques

Effendi II easier to see on X-ray

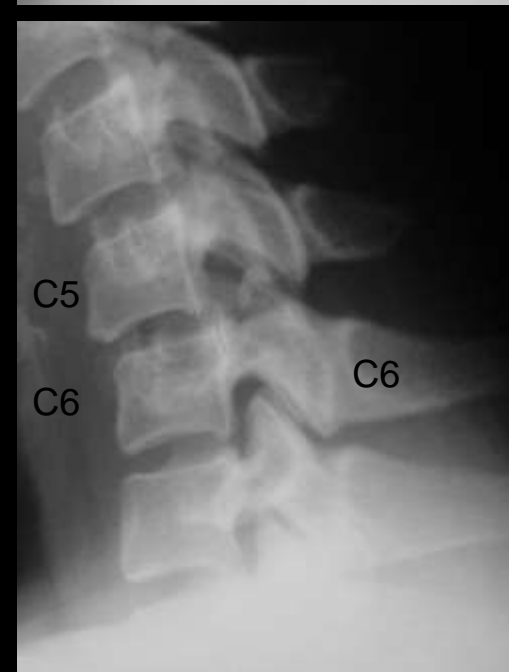
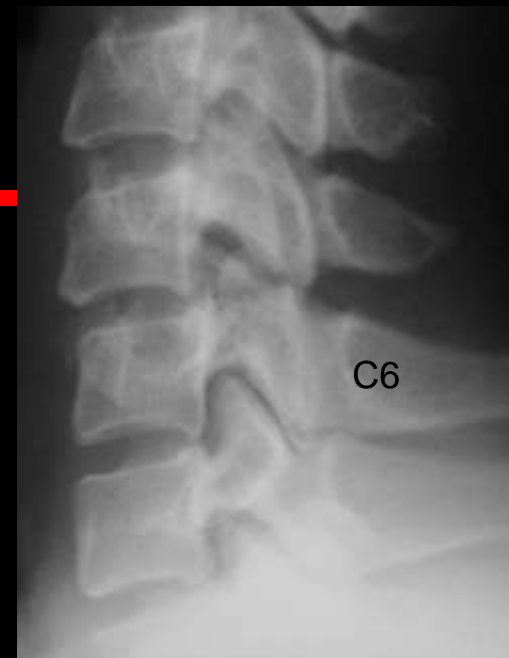
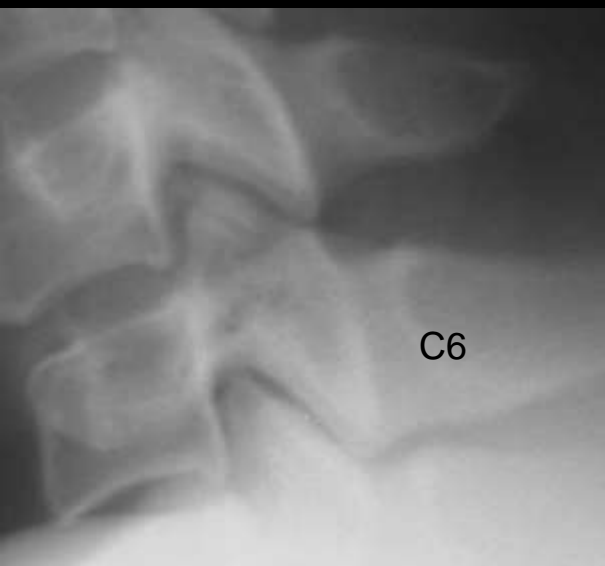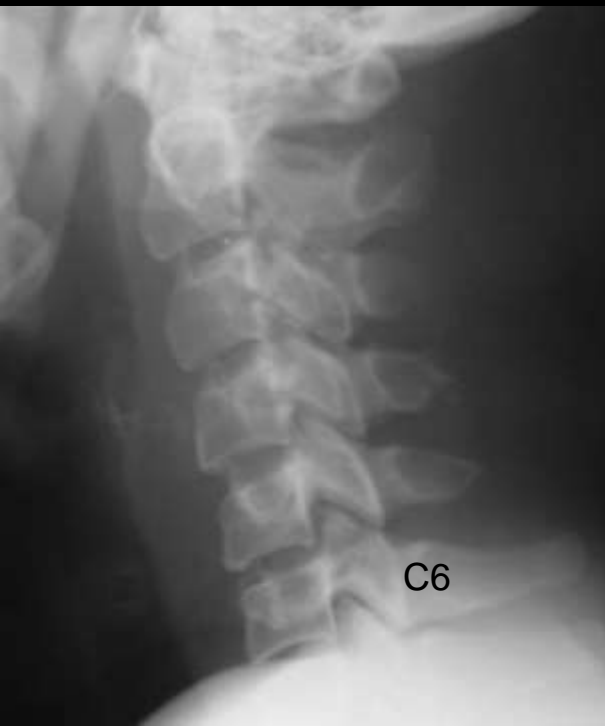Comparing Techniques

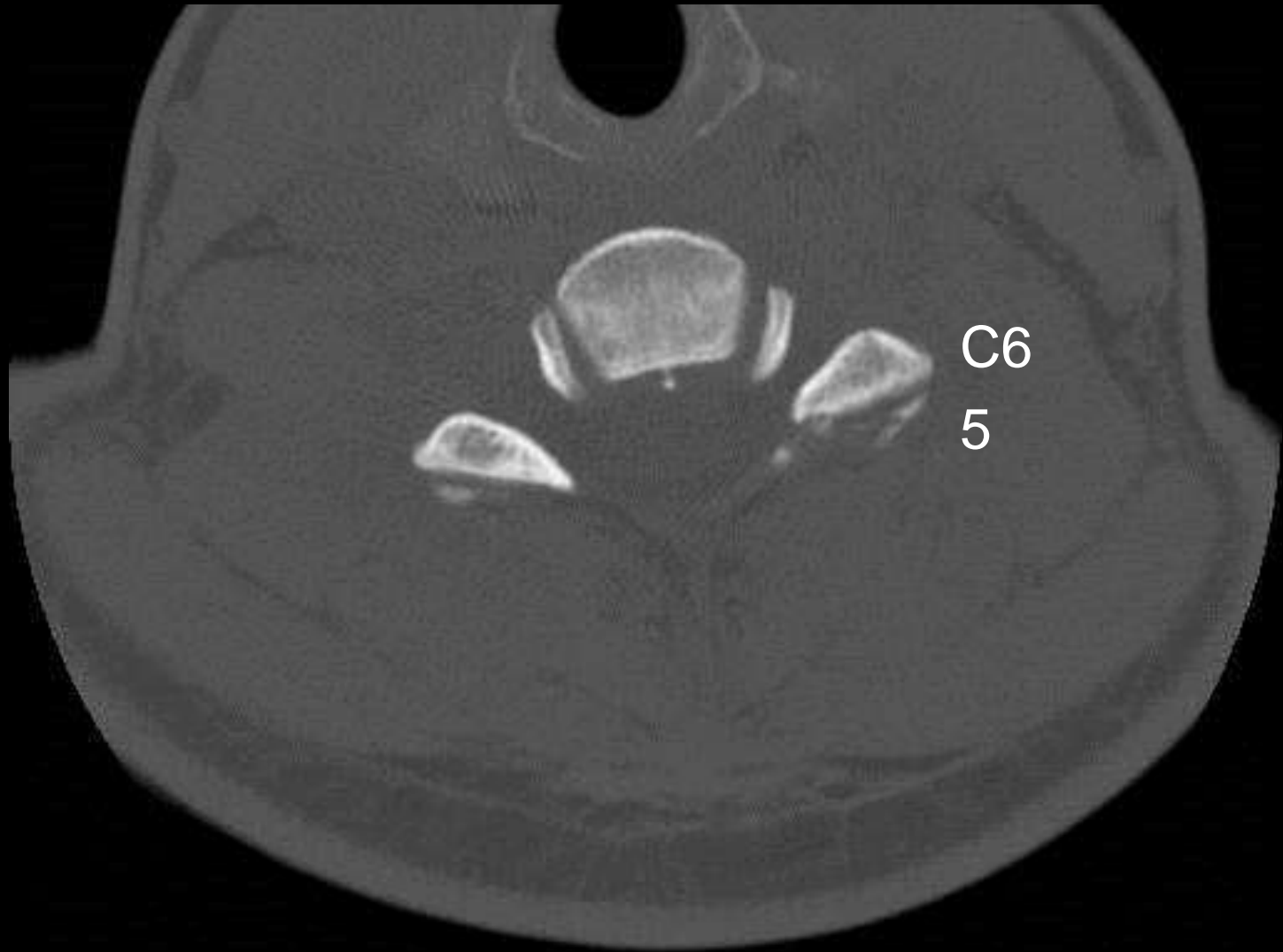
Effendi II easier to see on X-ray



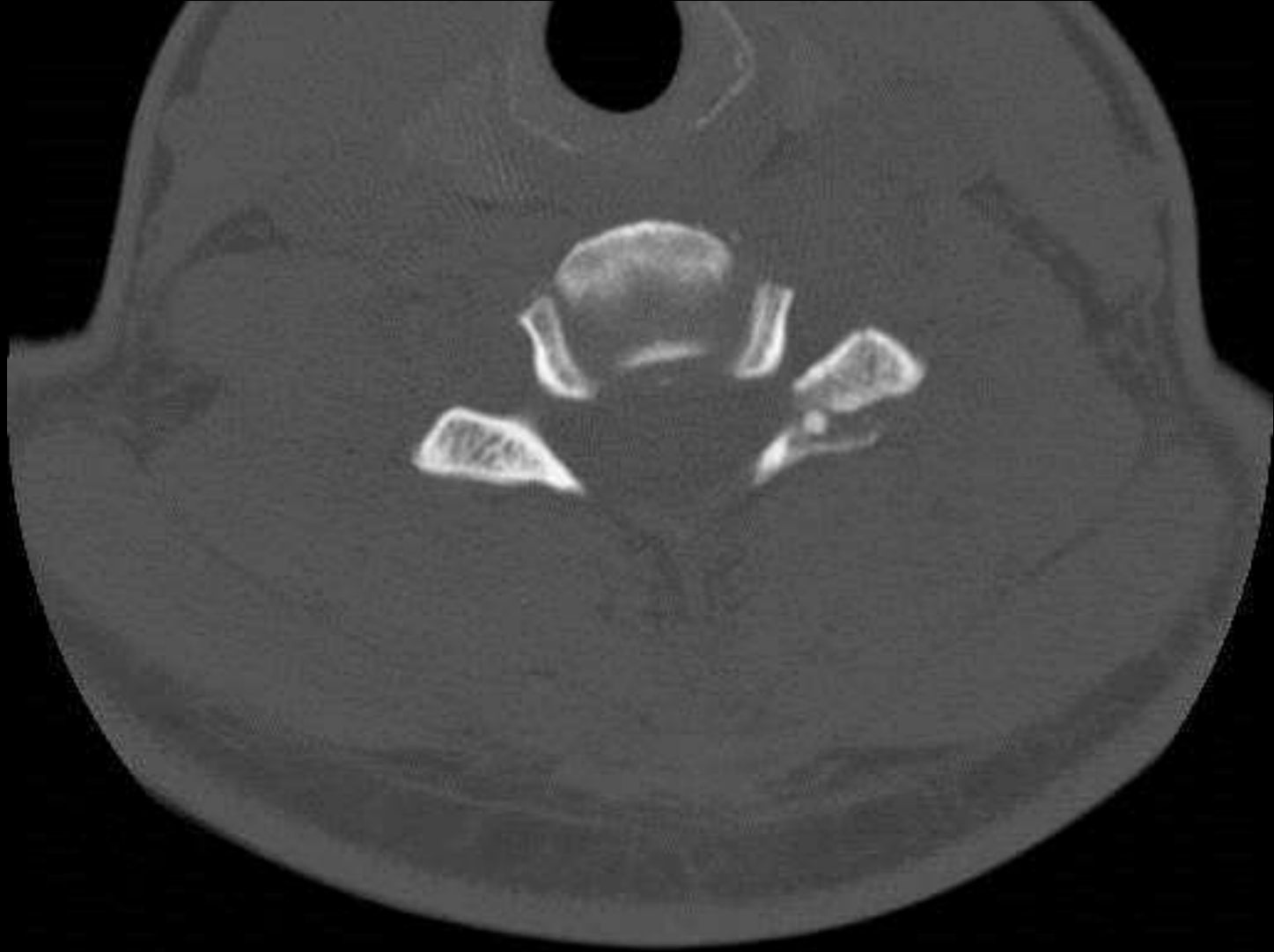Technique Follow up



Technique - Follow up

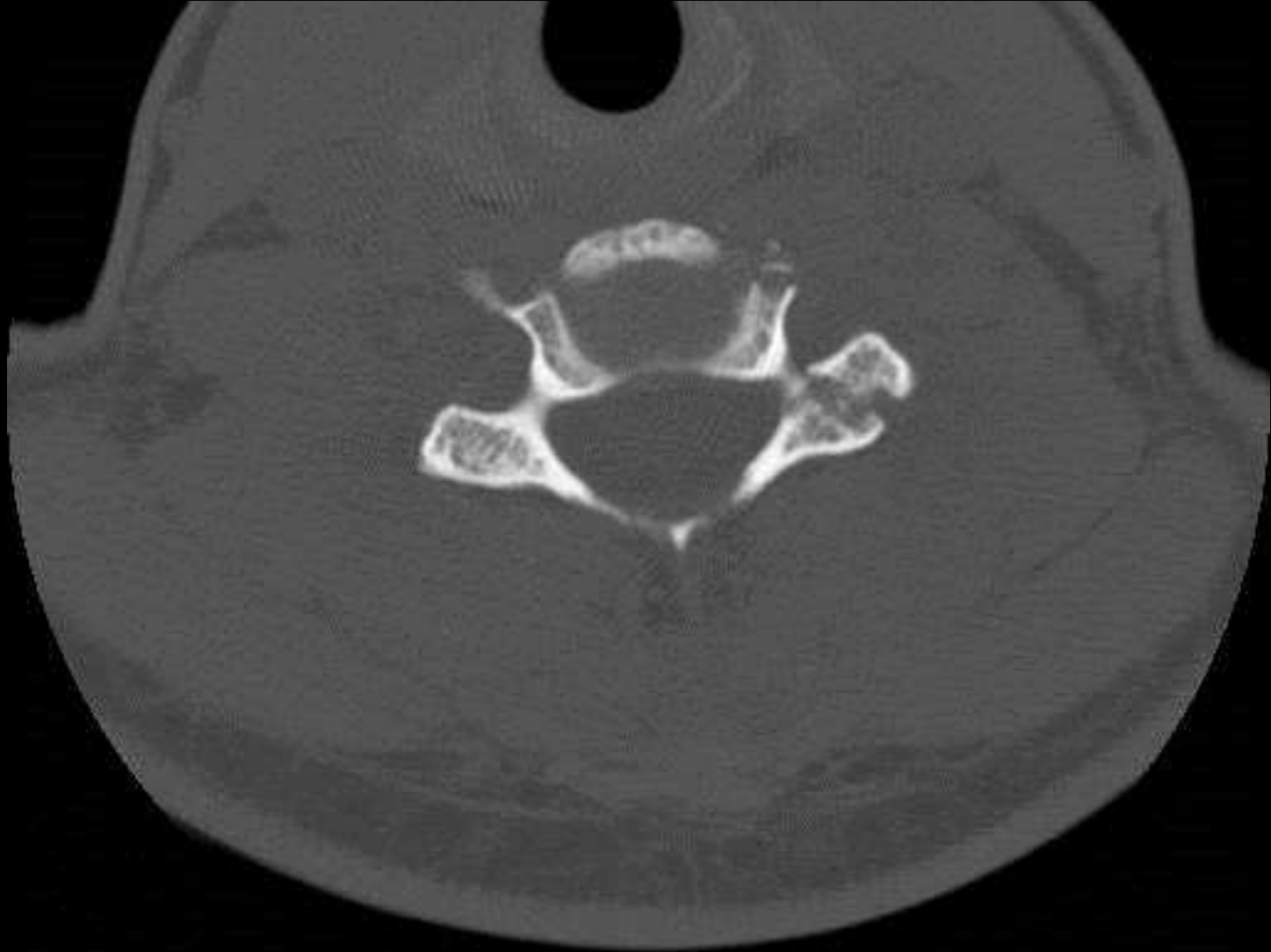


Technique - Follow up

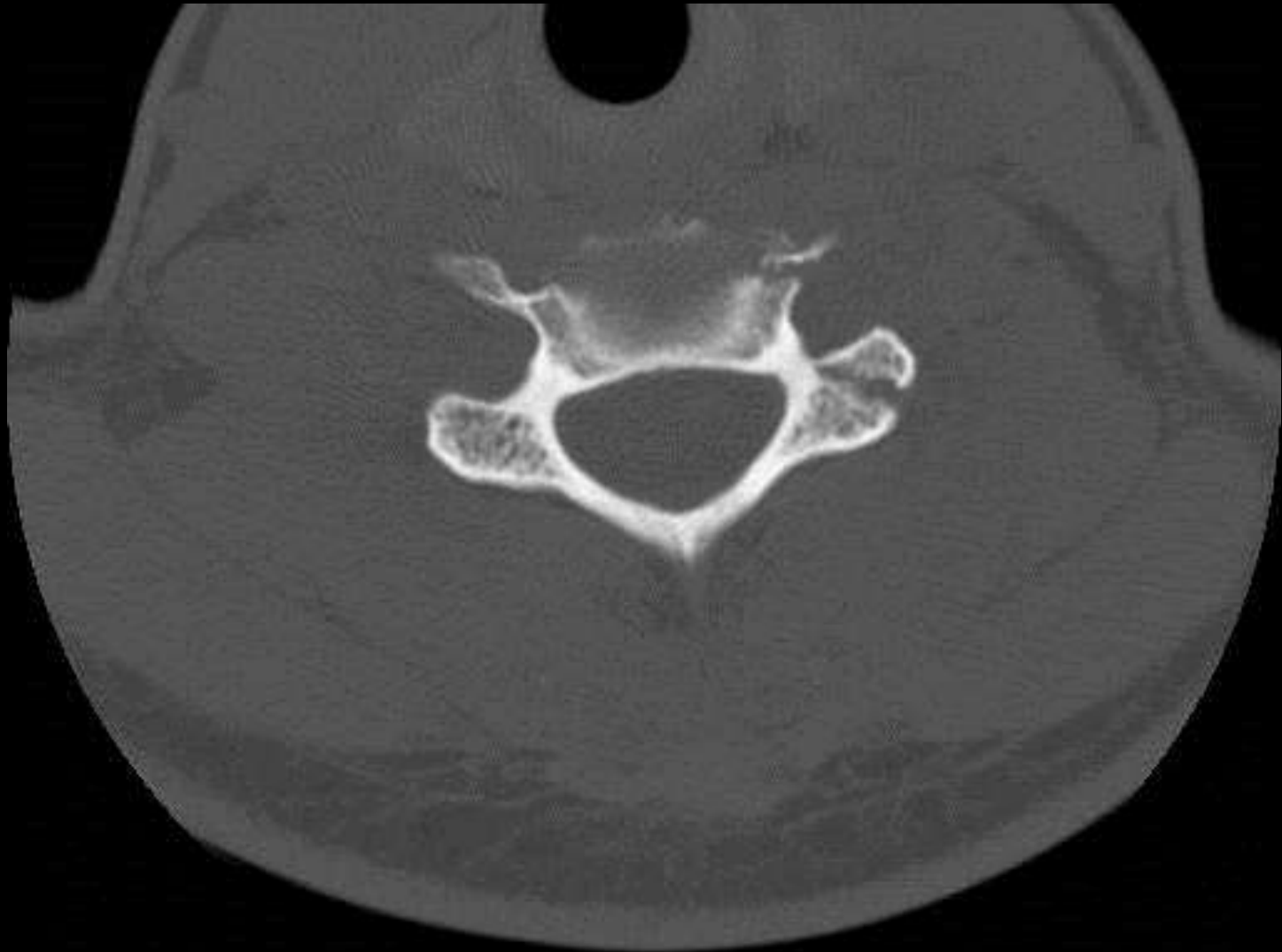

28F Left C6 superior facet fracture seen on F/U F/E

Technique - Follow up

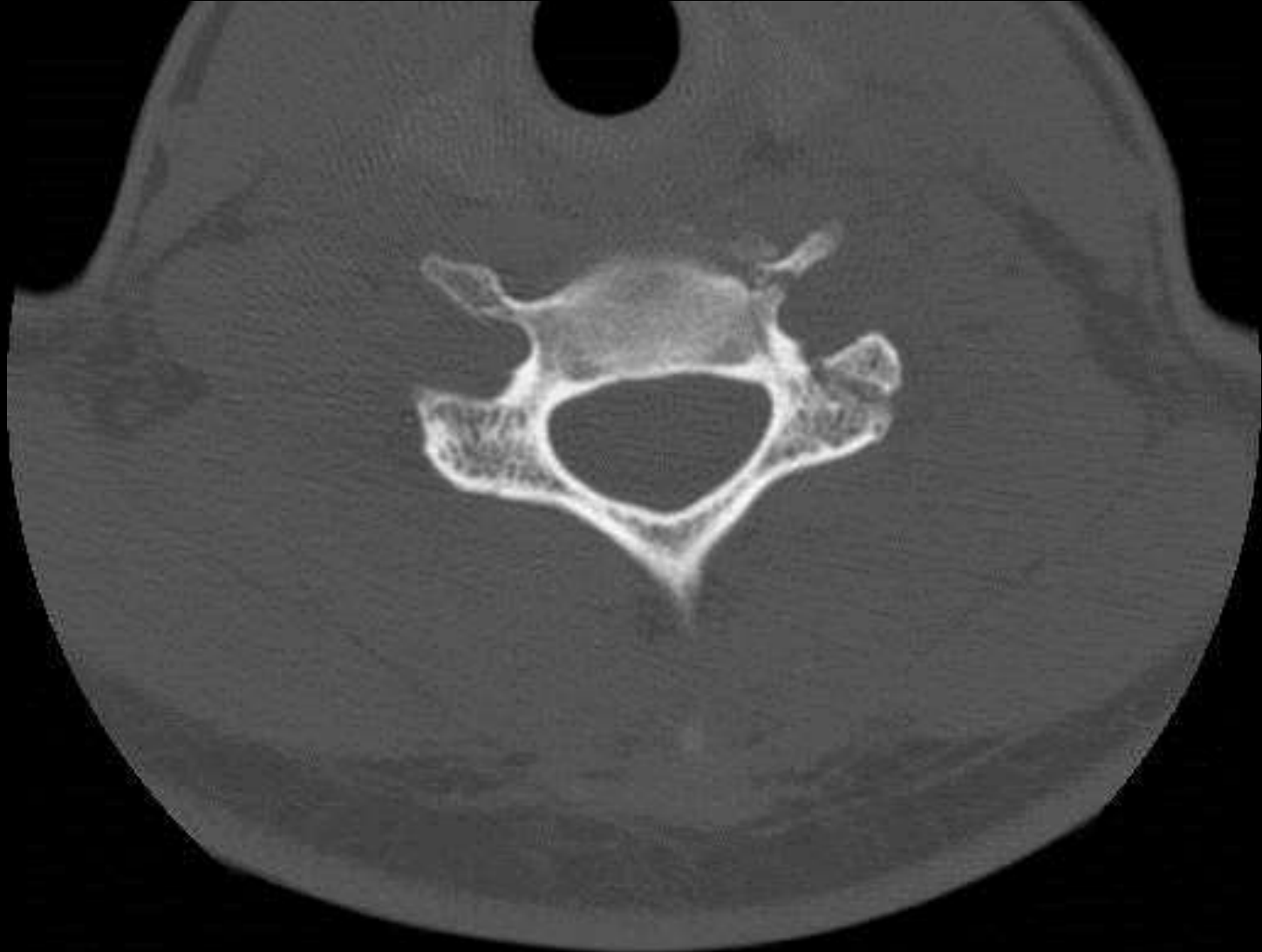

Technique - Follow up

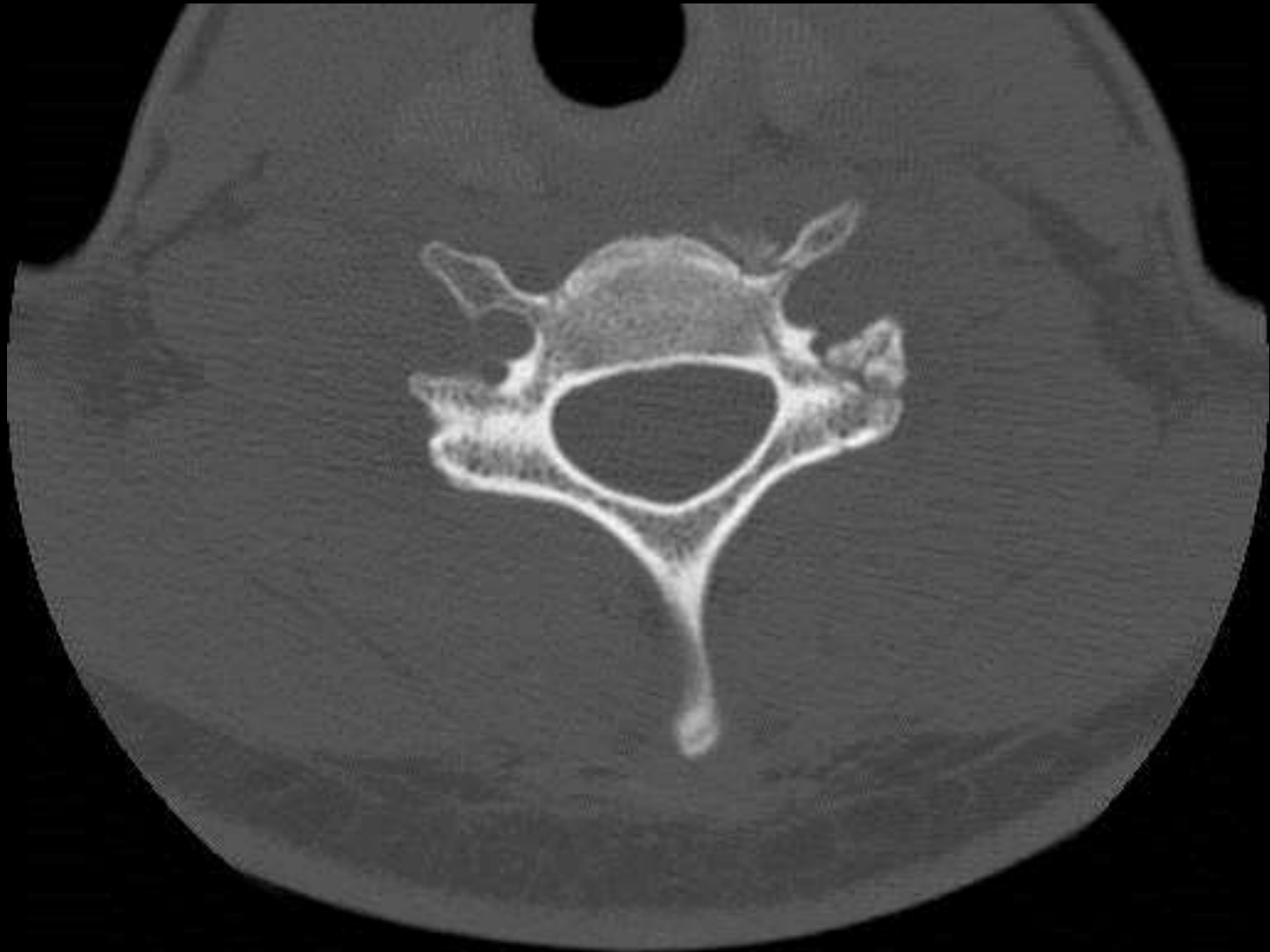

28F Left C6 superior facet fracture seen on F/U F/E

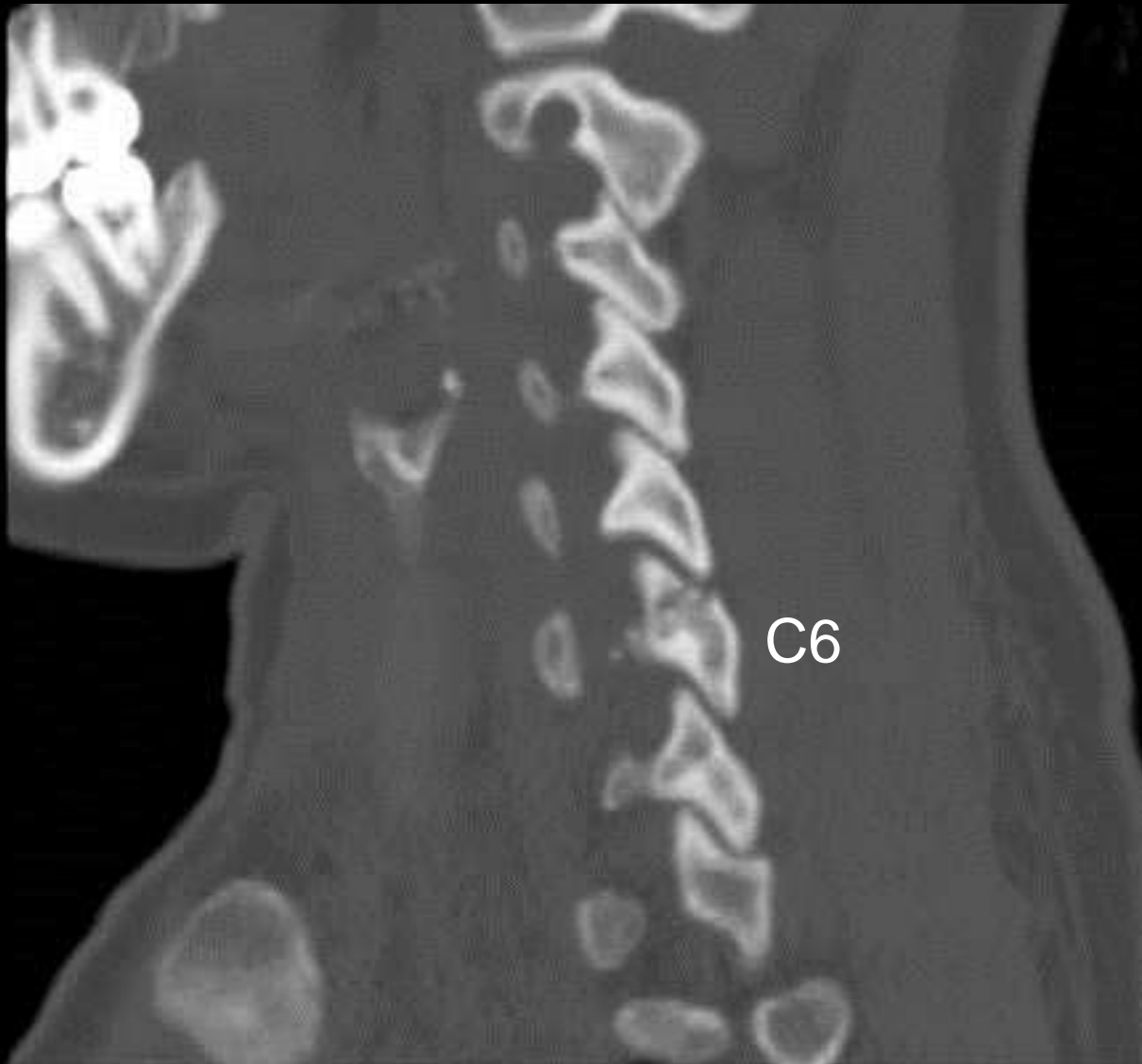
Technique - Follow up



Technique - Follow up



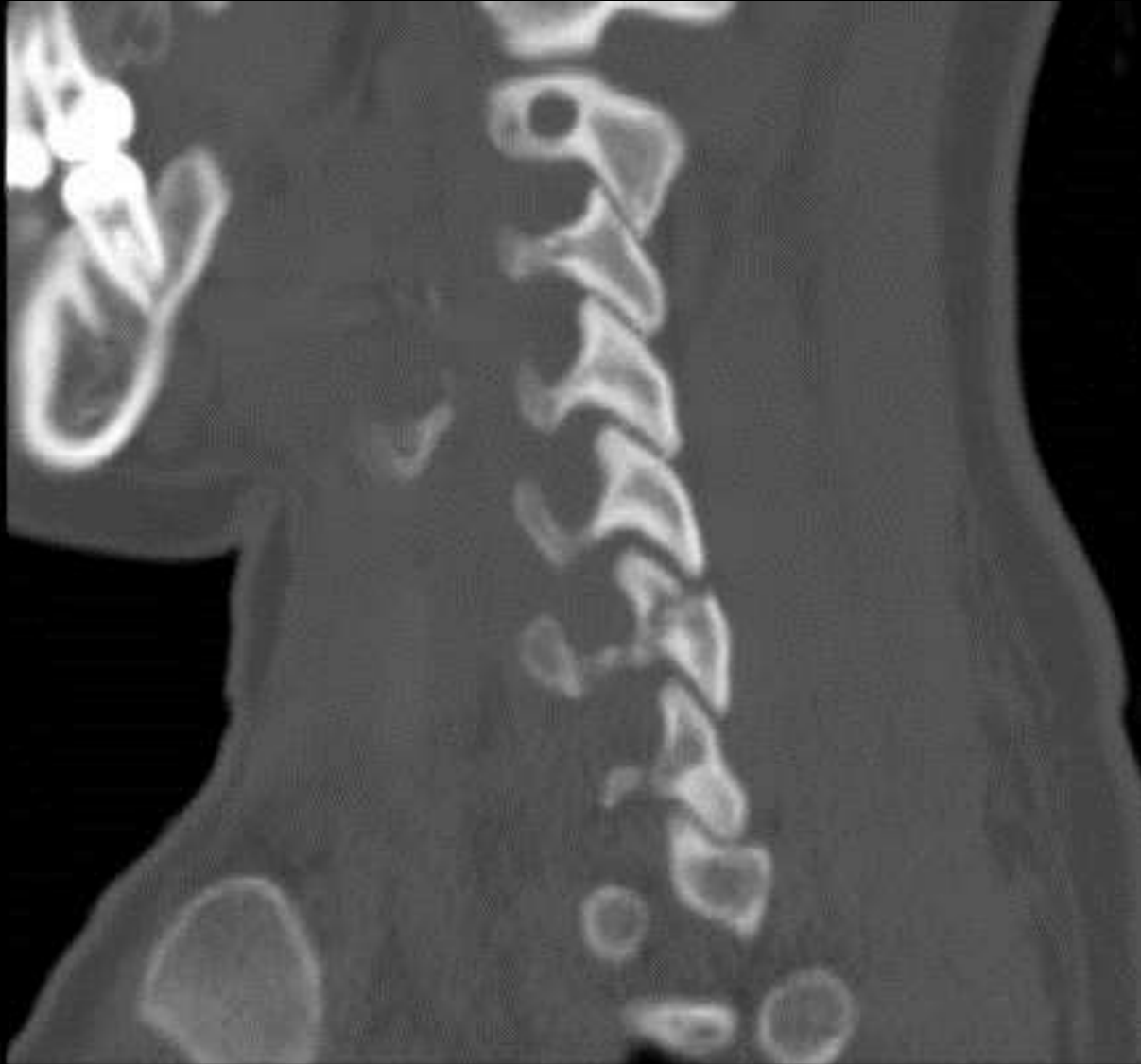Technique - Follow up



C6

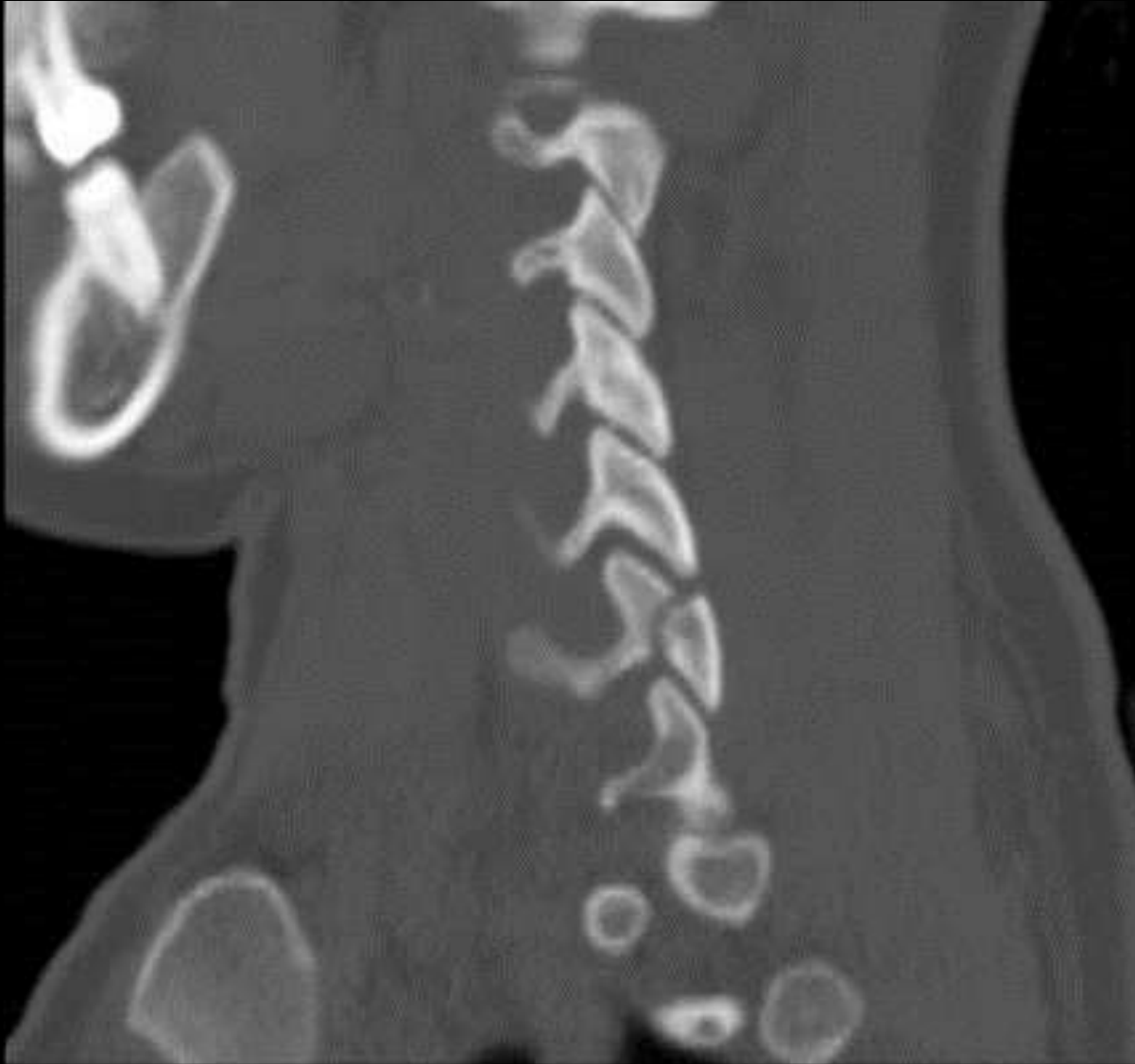28F Left C6 superior facet fracture seen on F/U F/E

Technique - Follow up



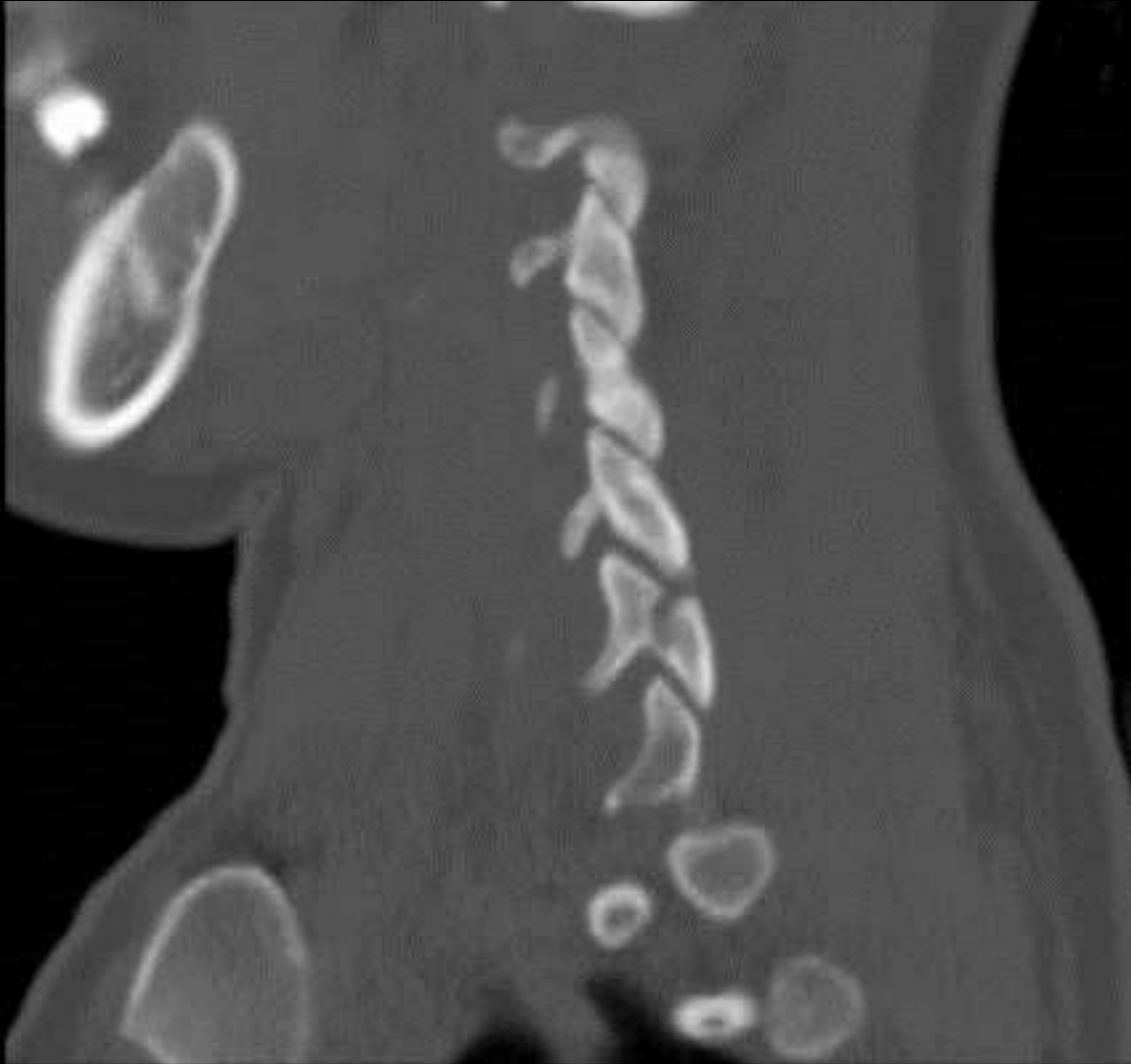28F Left C6 superior facet fracture seen on F/U F/E

Technique - Follow up



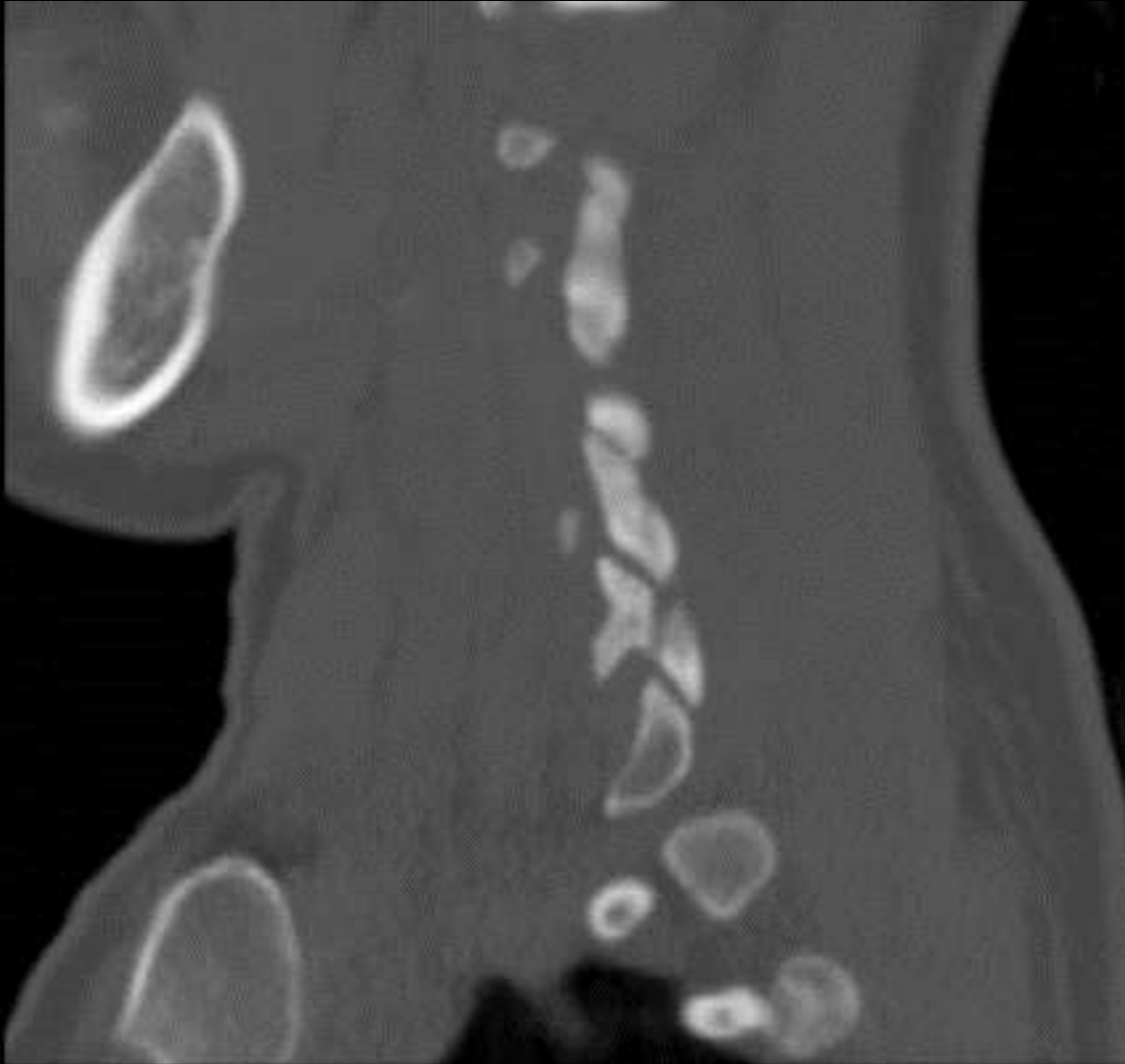28F Left C6 superior facet fracture seen on F/U F/E

Technique - Follow up



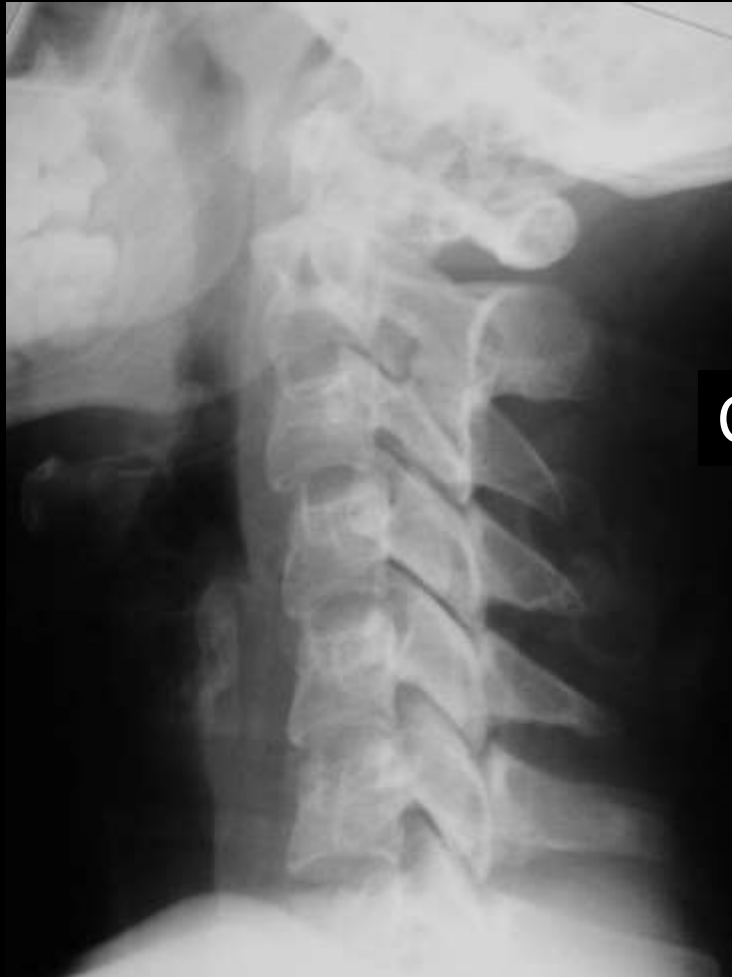28F Left C6 superior facet fracture seen on F/U F/E

Technique - Follow up

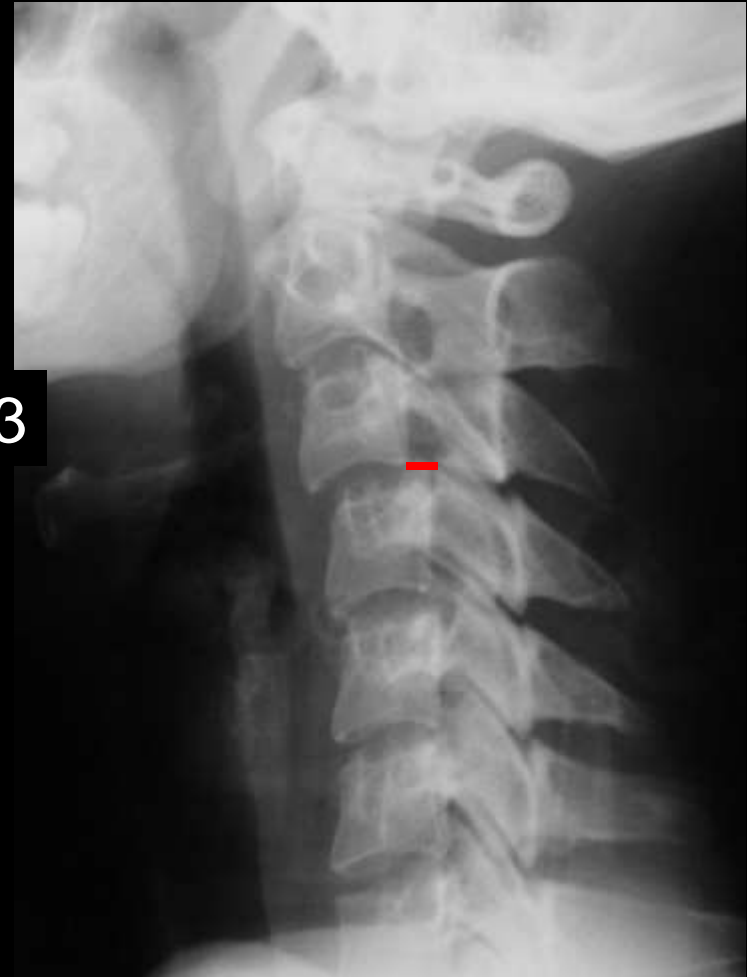

28F Left C6 superior facet fracture seen on F/U F/E

Technique - Follow up



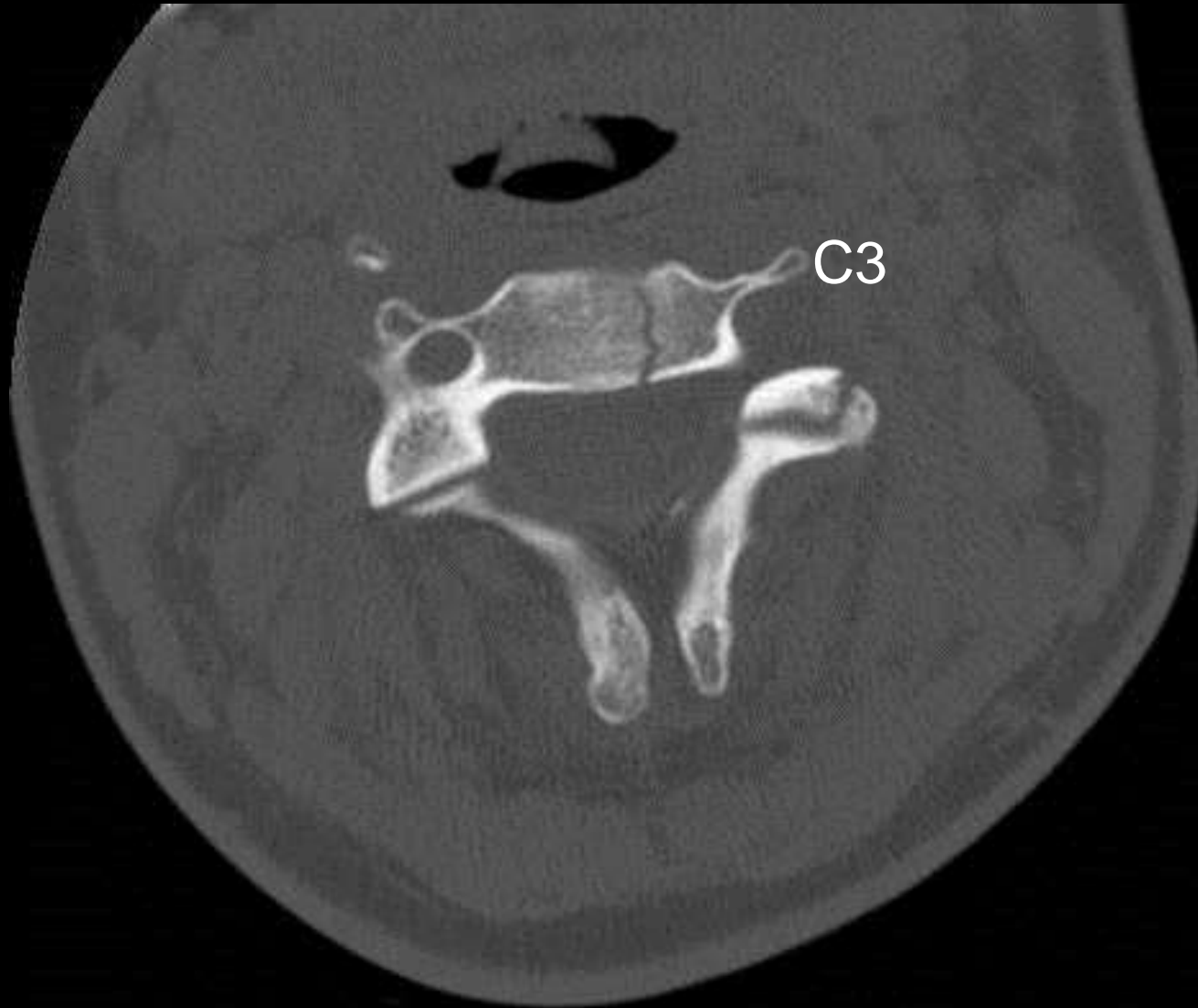
Nov 21



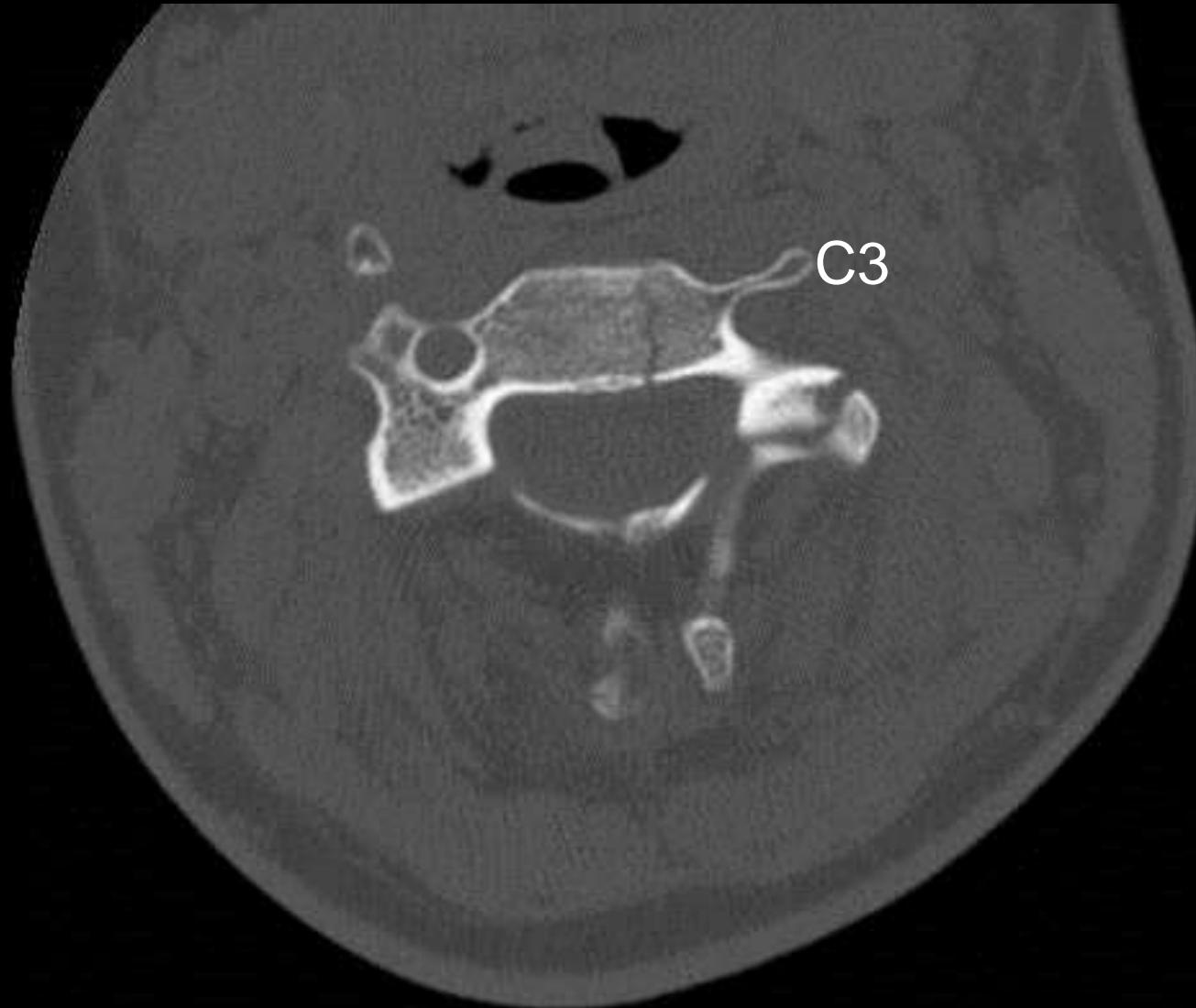
Dec5

C3

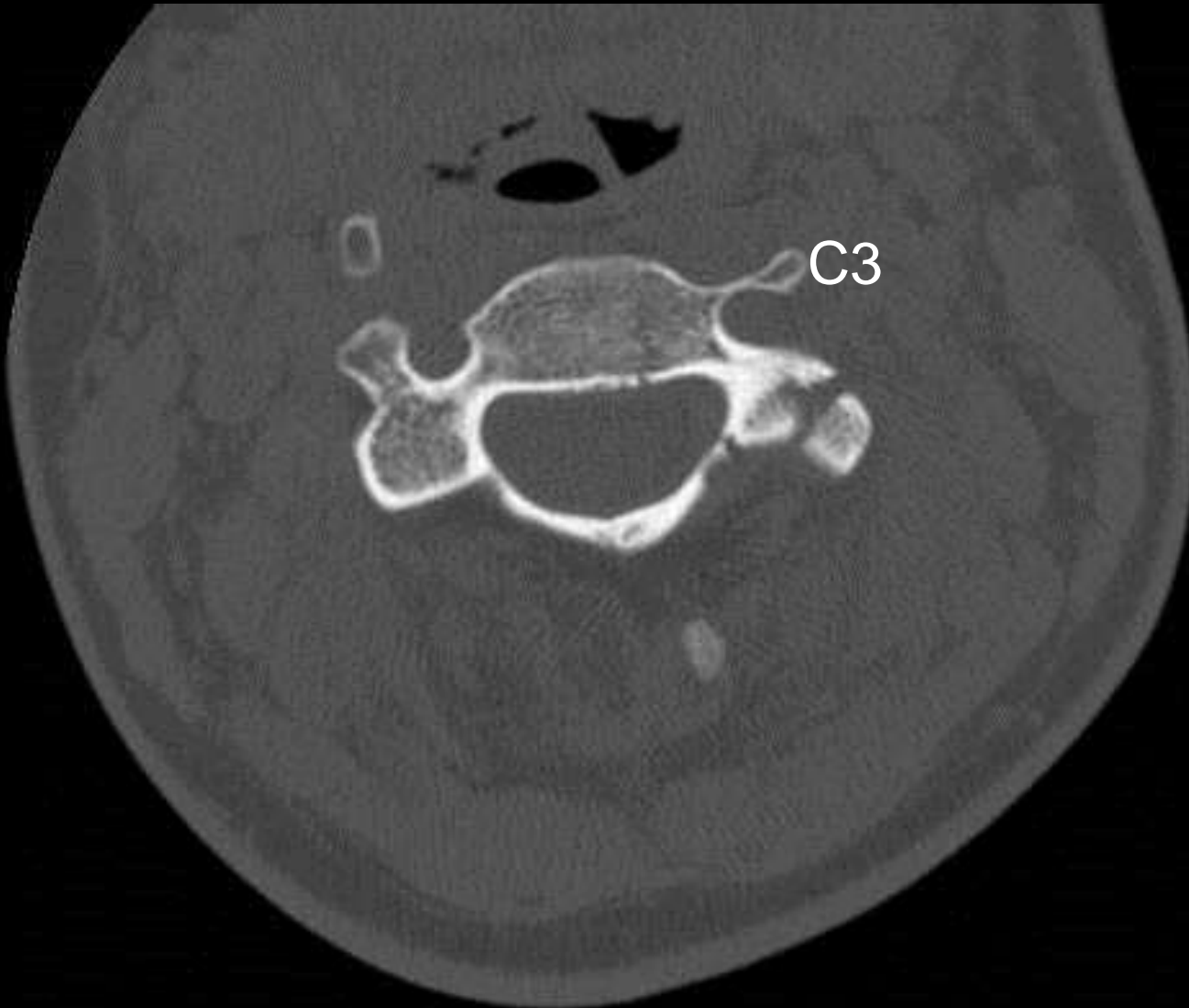
Technique - Follow up



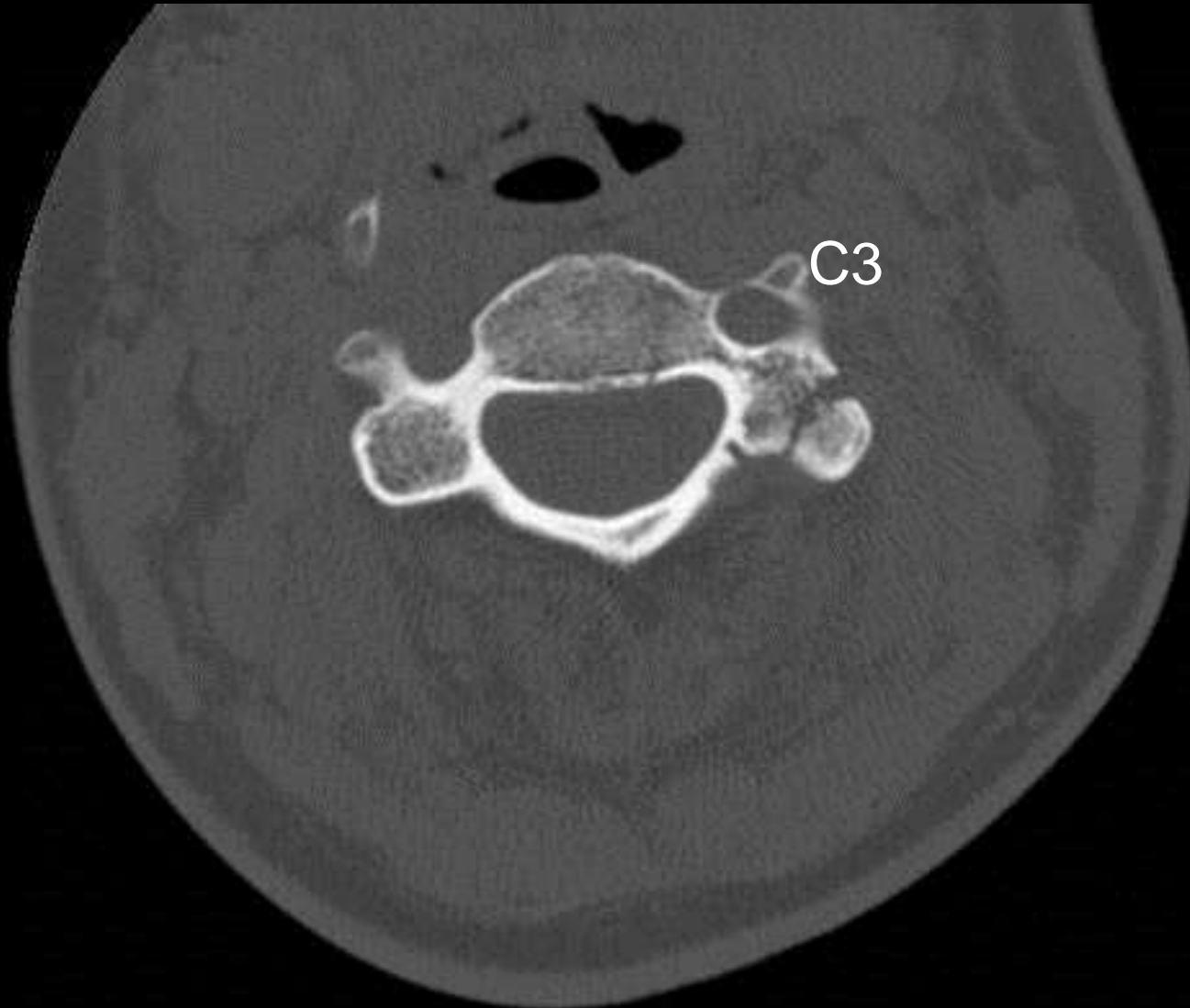
Technique - Follow up



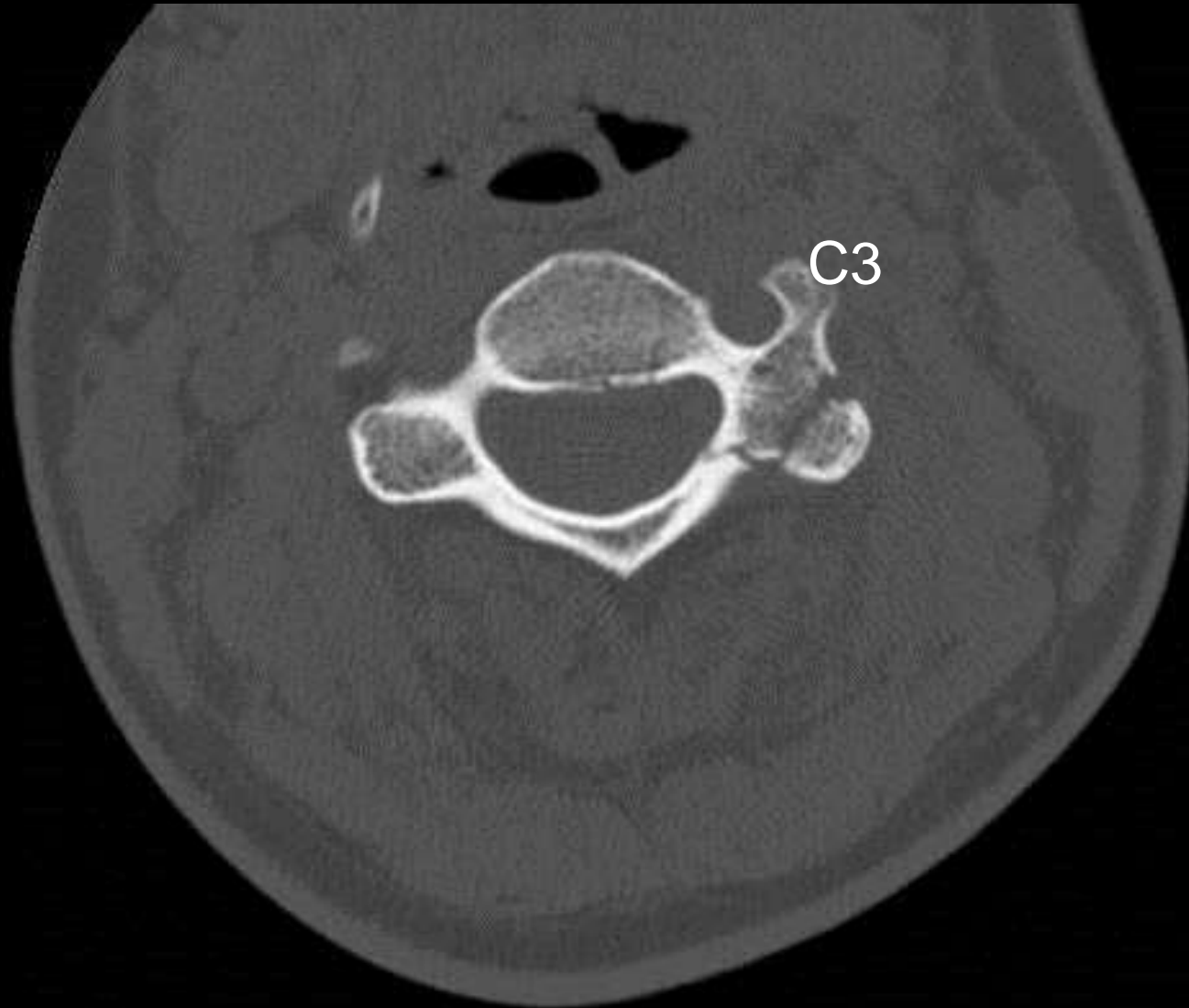
Technique - Follow up



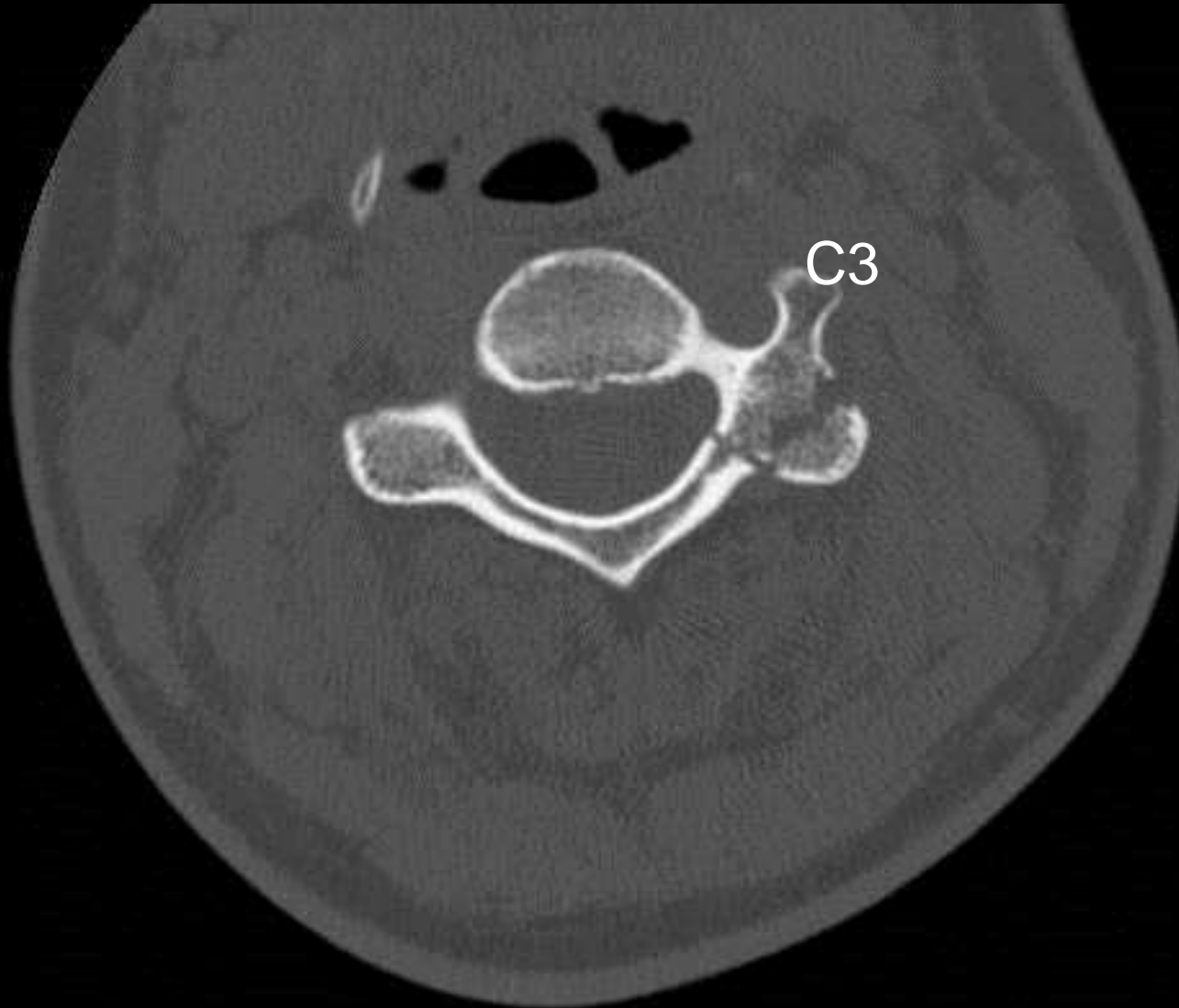
Technique - Follow up



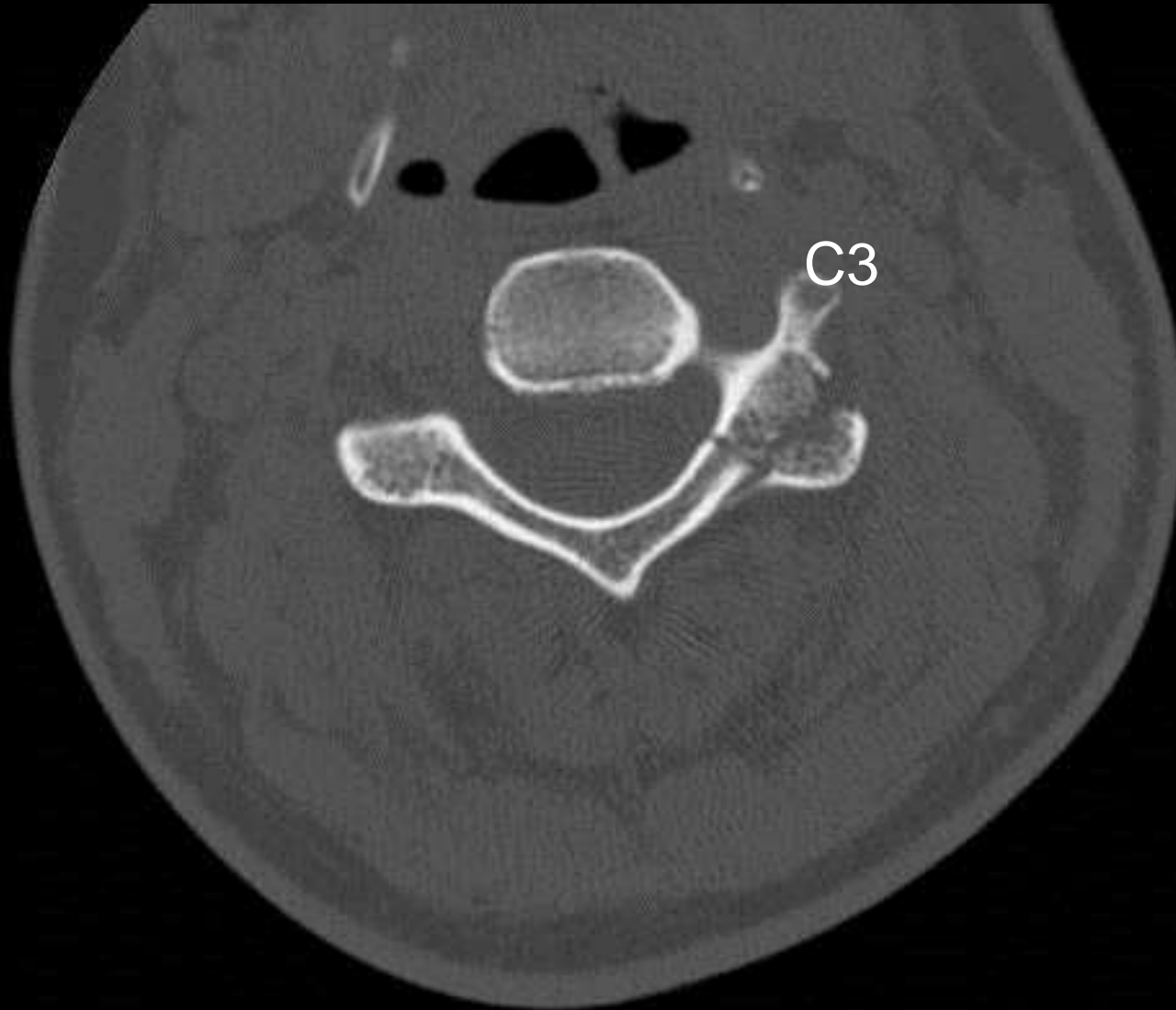
Technique - Follow up



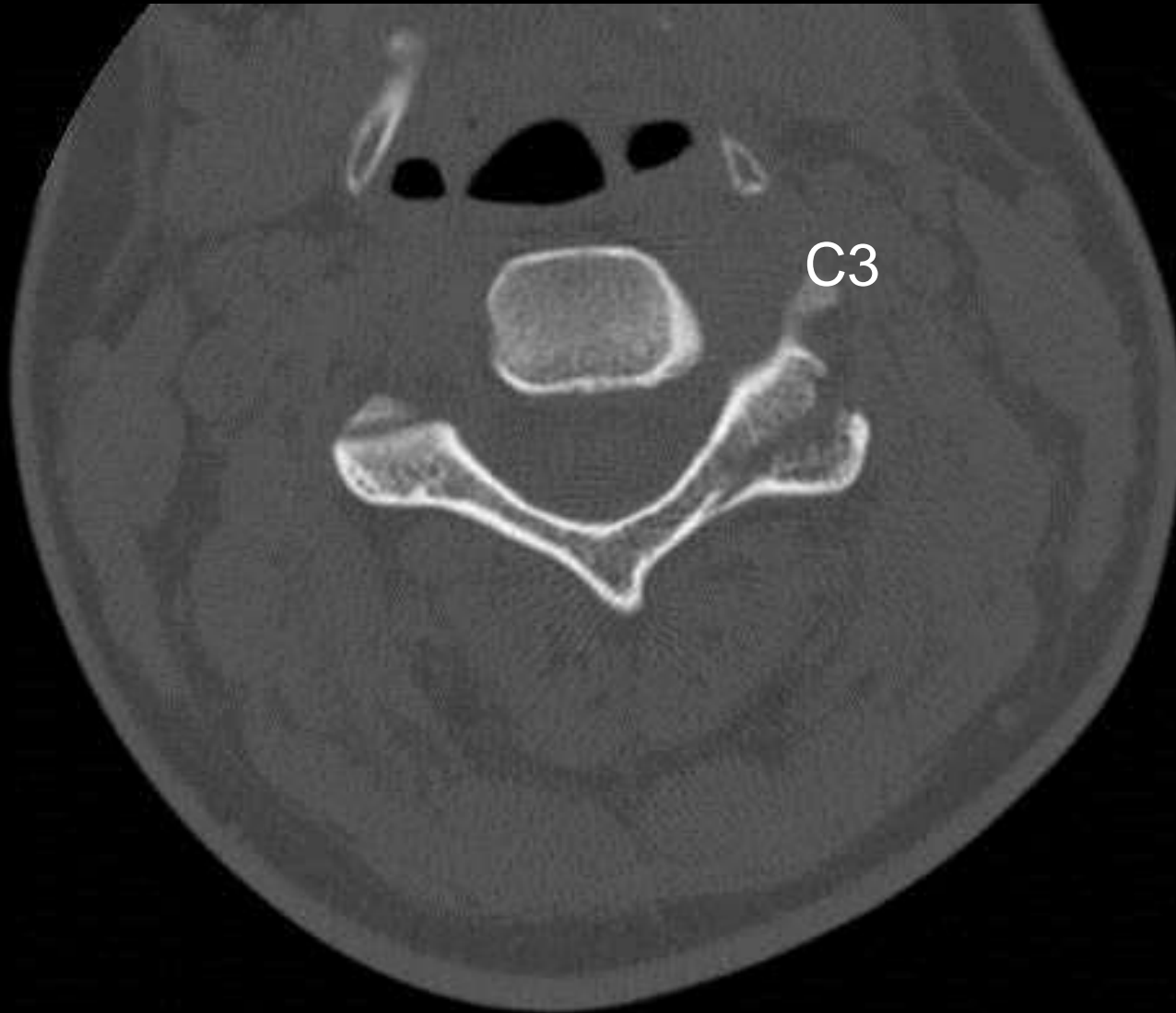
Technique - Follow up



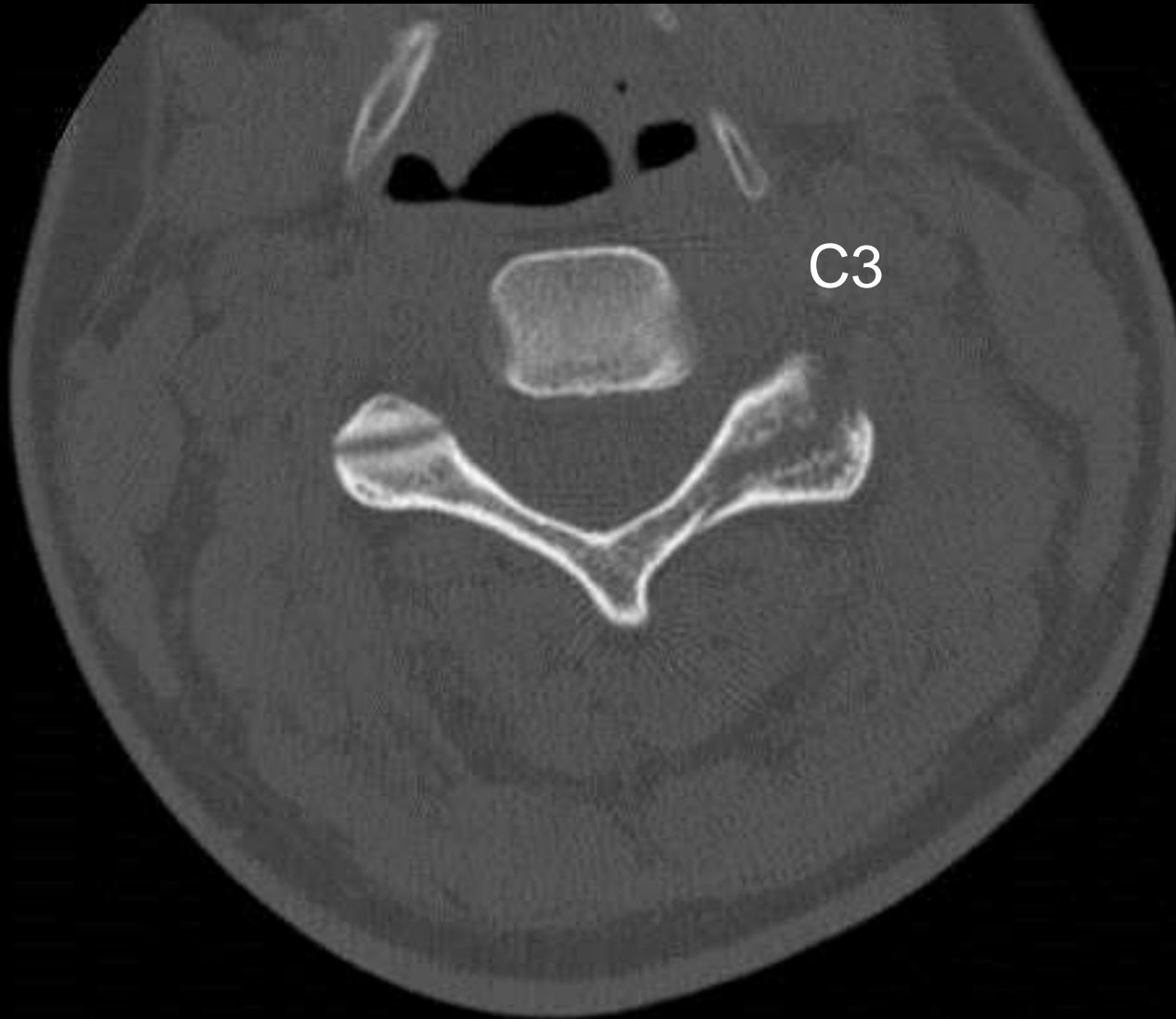
Technique - Follow up



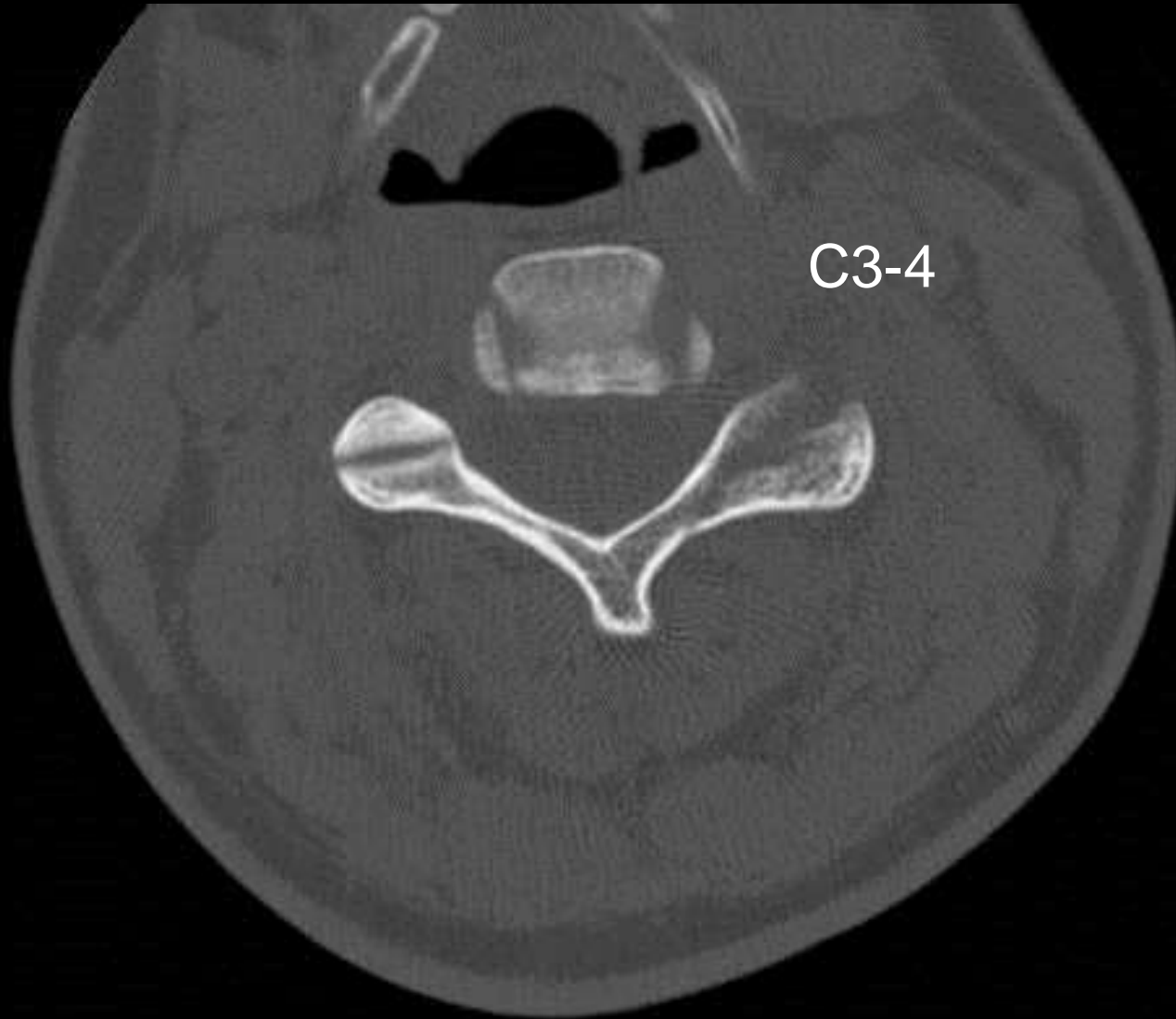
Technique - Follow up



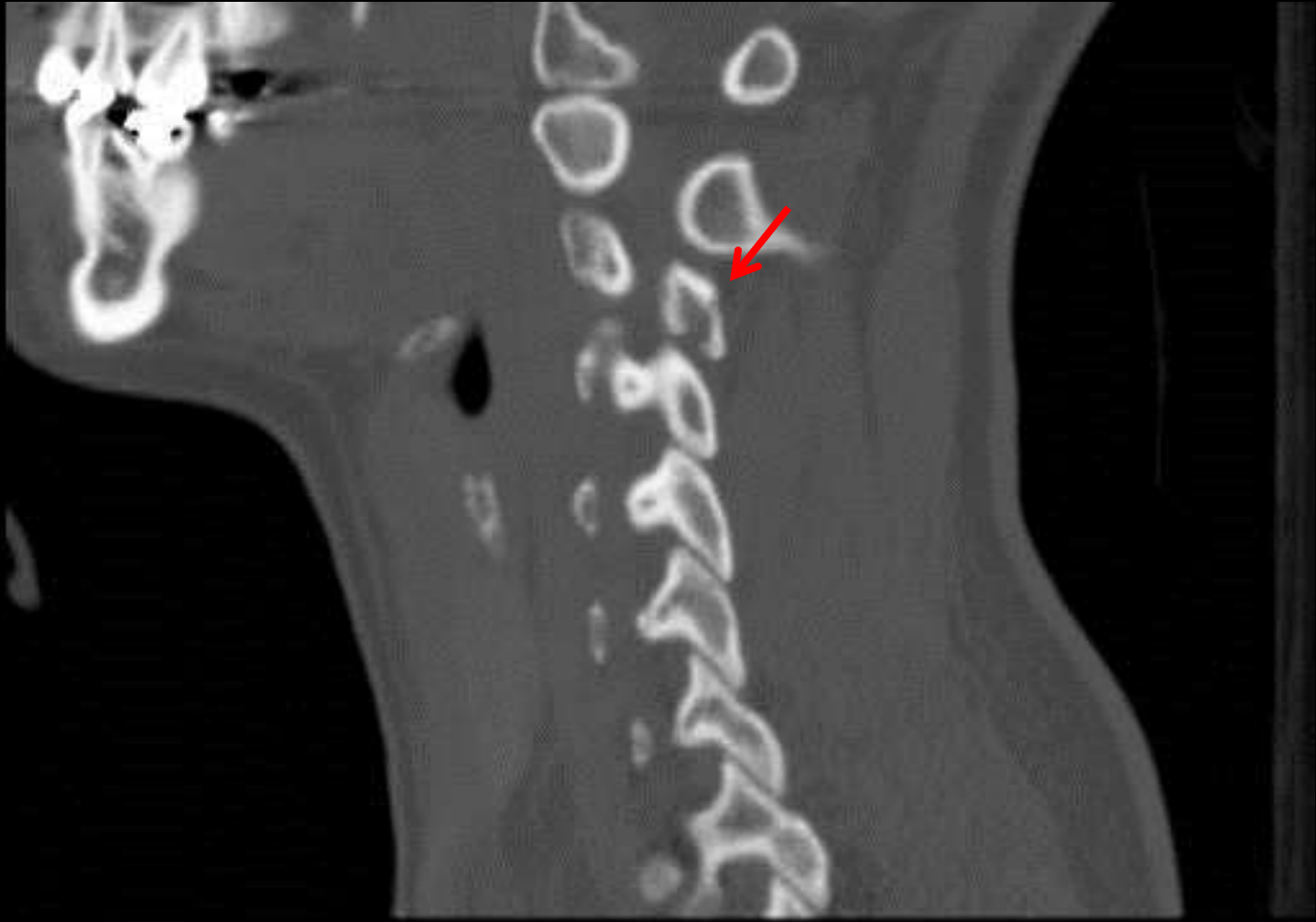
Technique - Follow up



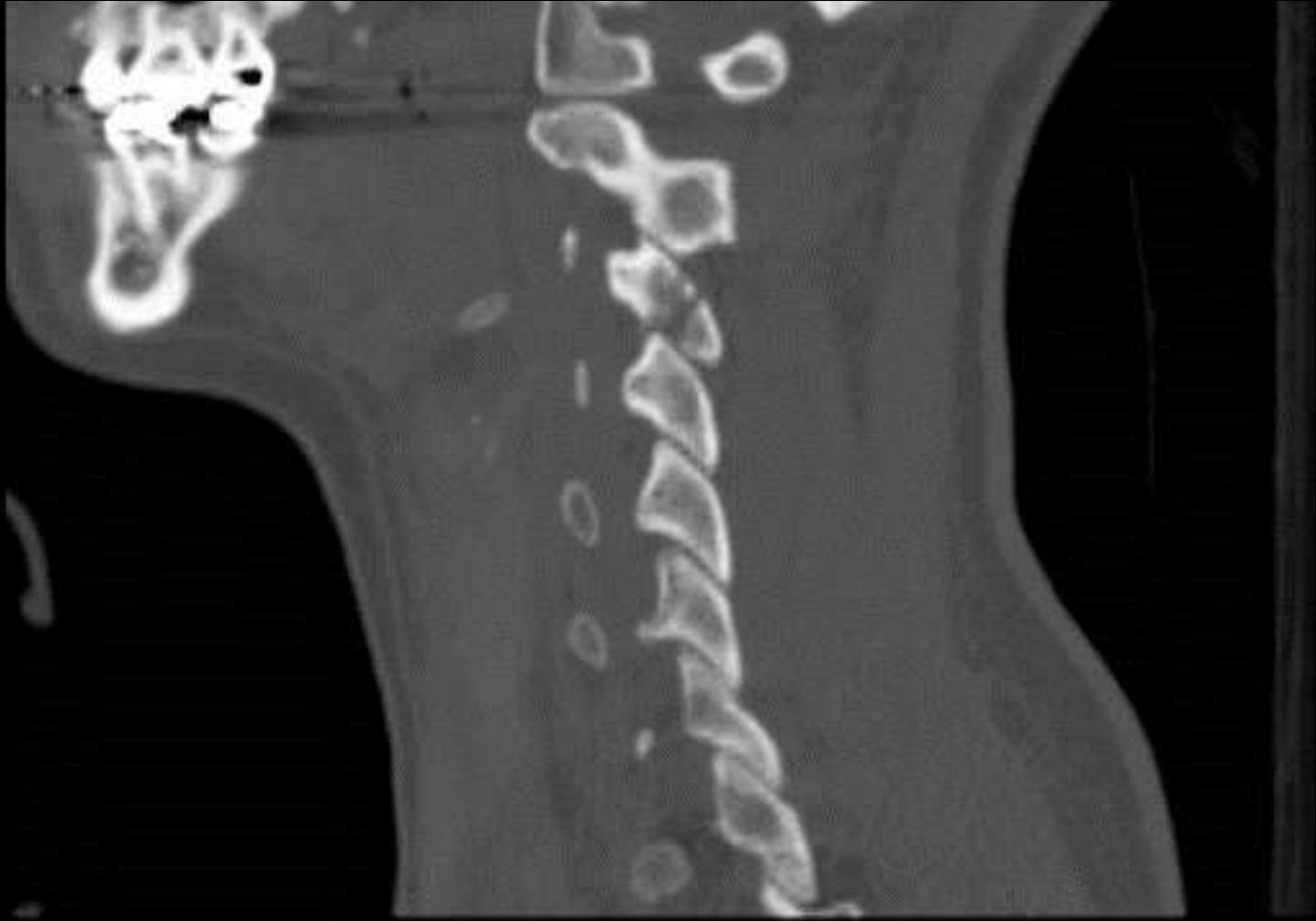Technique - Follow up



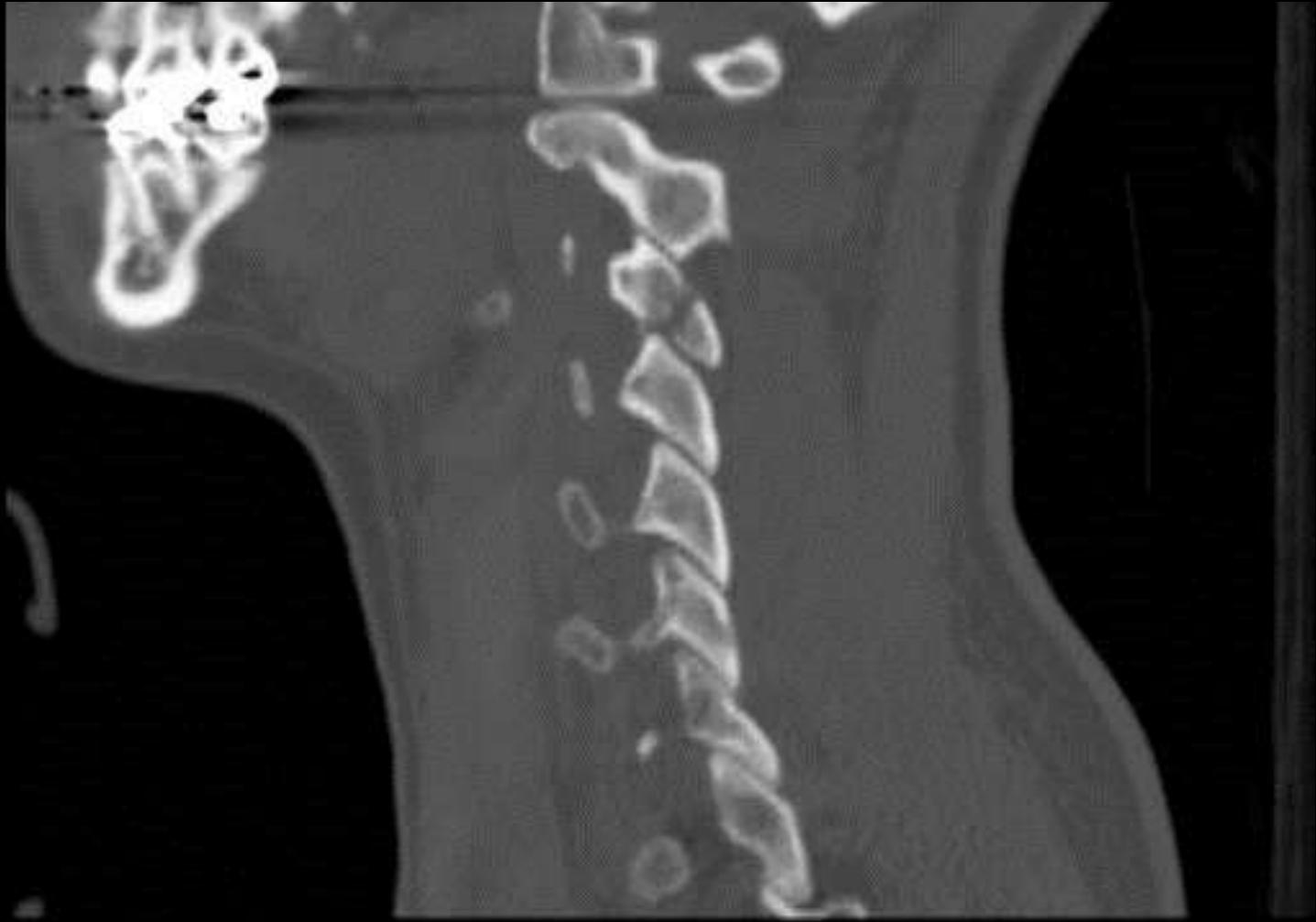
Technique - Follow up



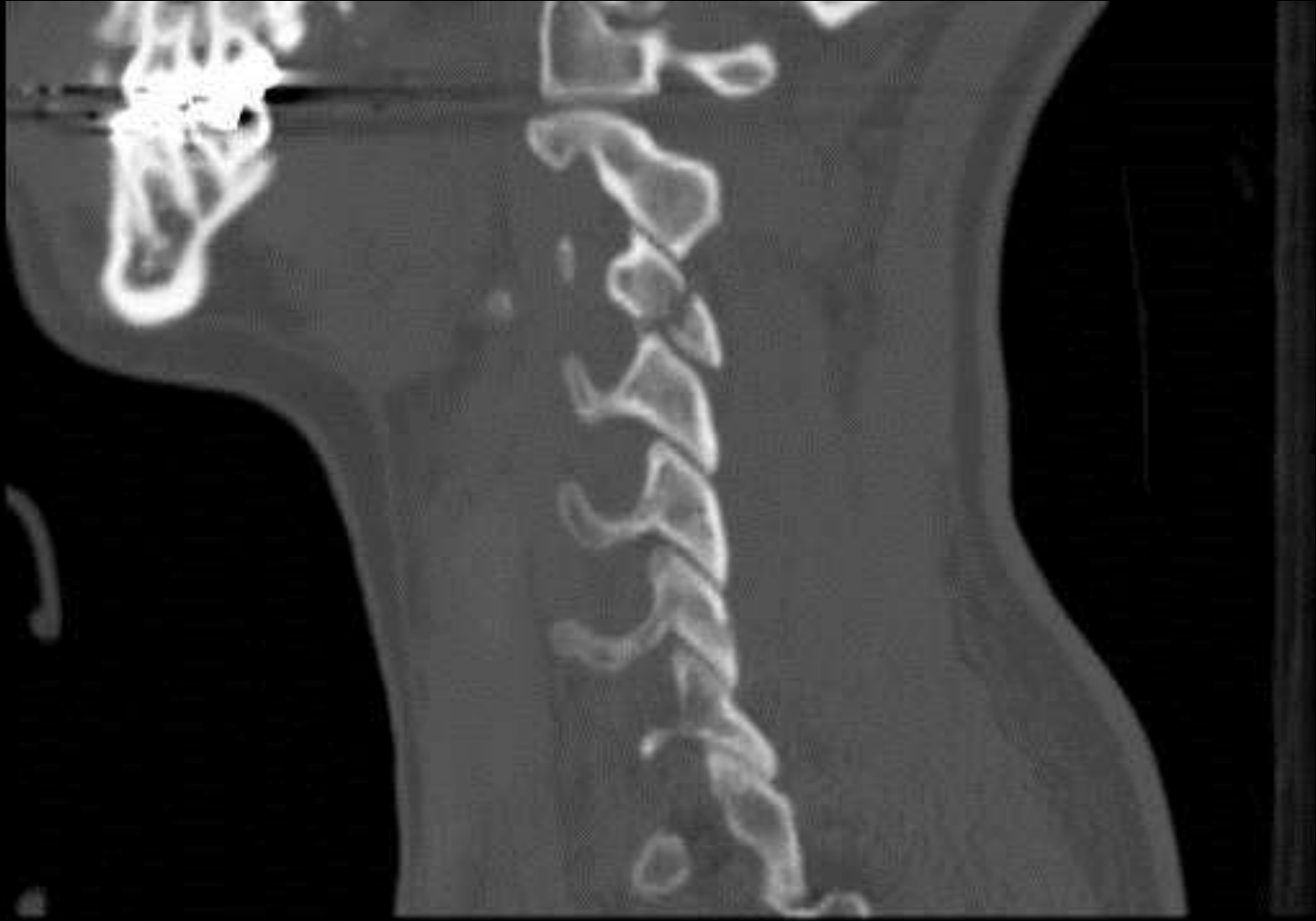Technique - Follow up



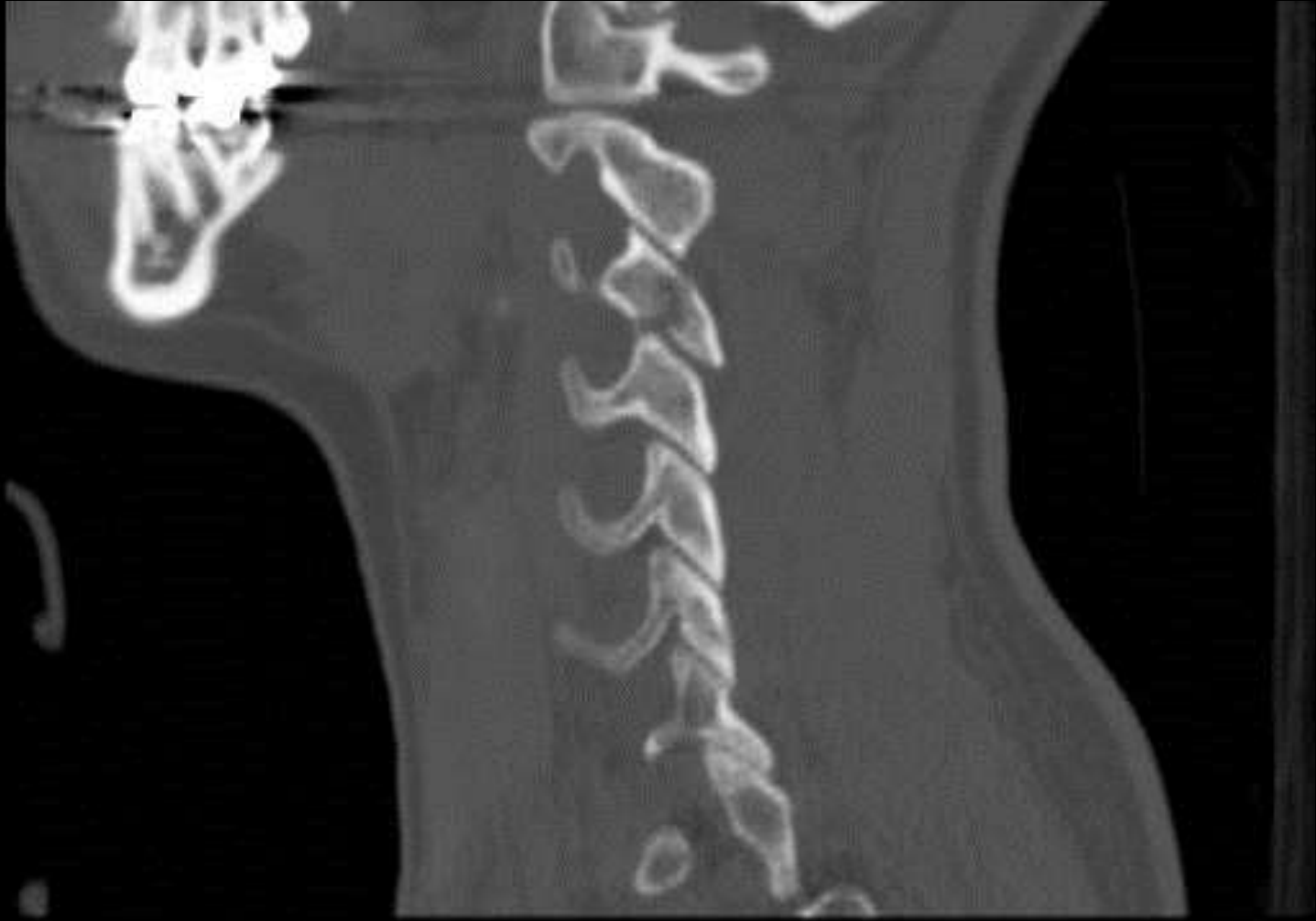Technique - Follow up



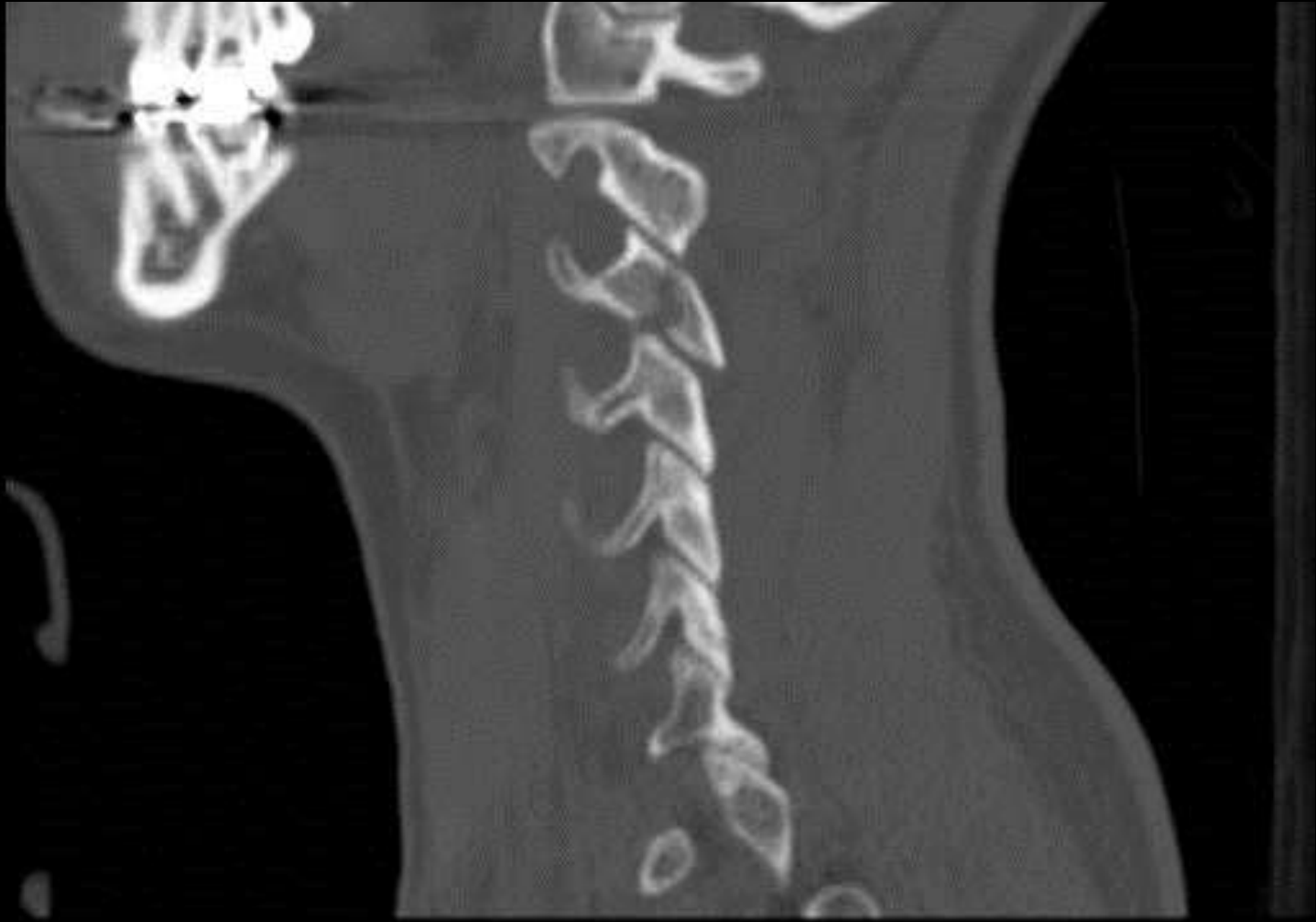Technique - Follow up



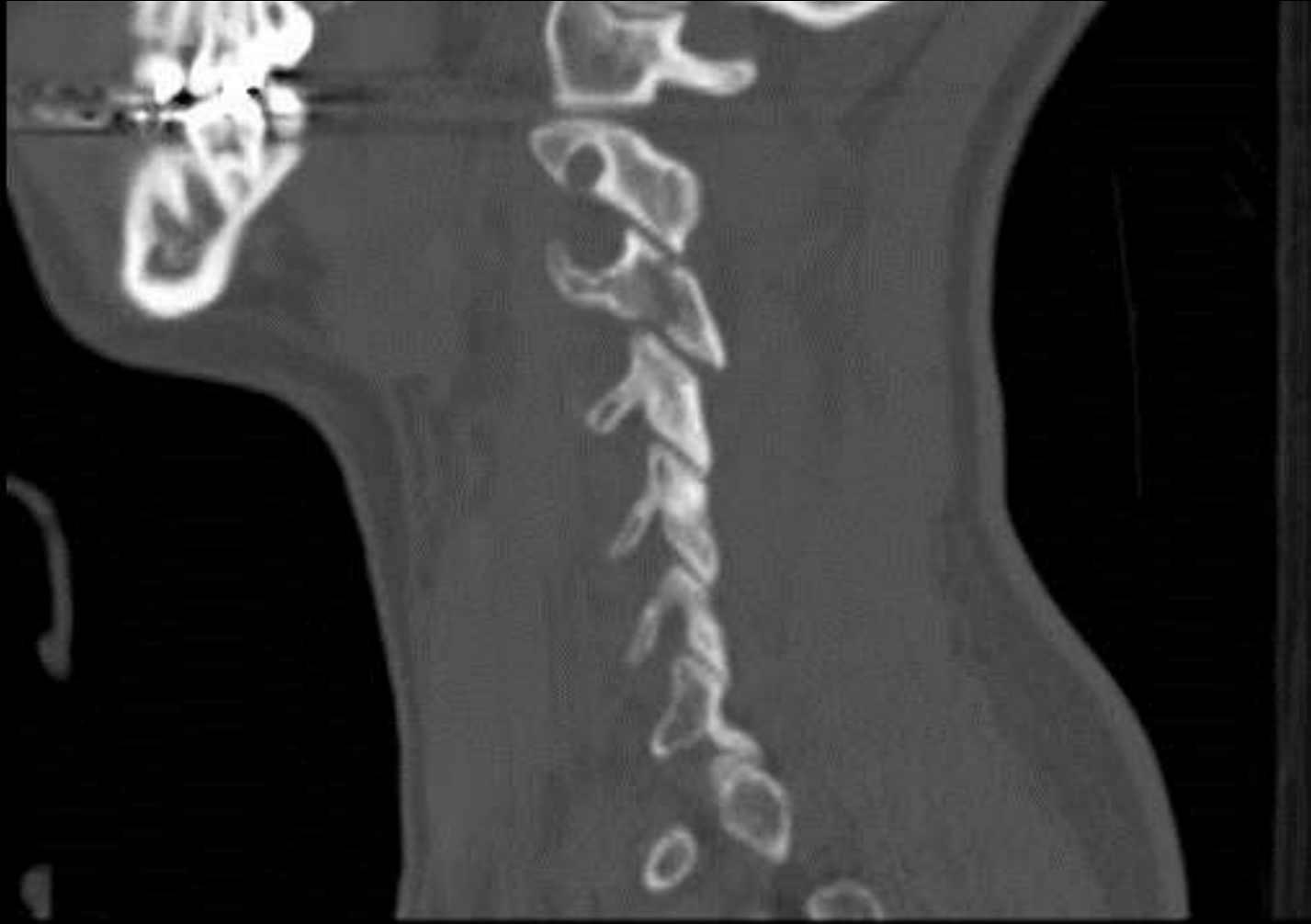Technique - Follow up



Technique - Follow up



Technique - Follow up

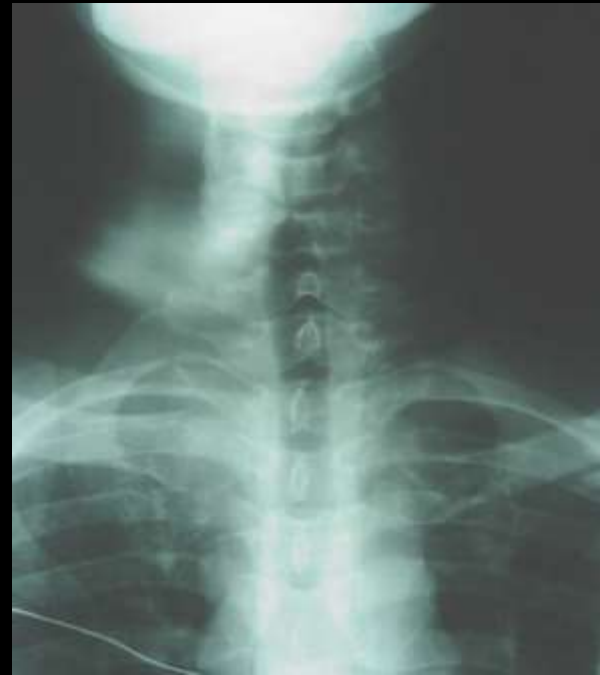



Lake Wanaka NZ

Reading Algorithm

- Soft tissues first, so you don't forget
- Bony alignment
- Facet joint alignment
- Look at common sites of fractures
- Find the second fracture
- Fluid levels
- Ribs, skull, **clavicles** etc
- Lines and tubes

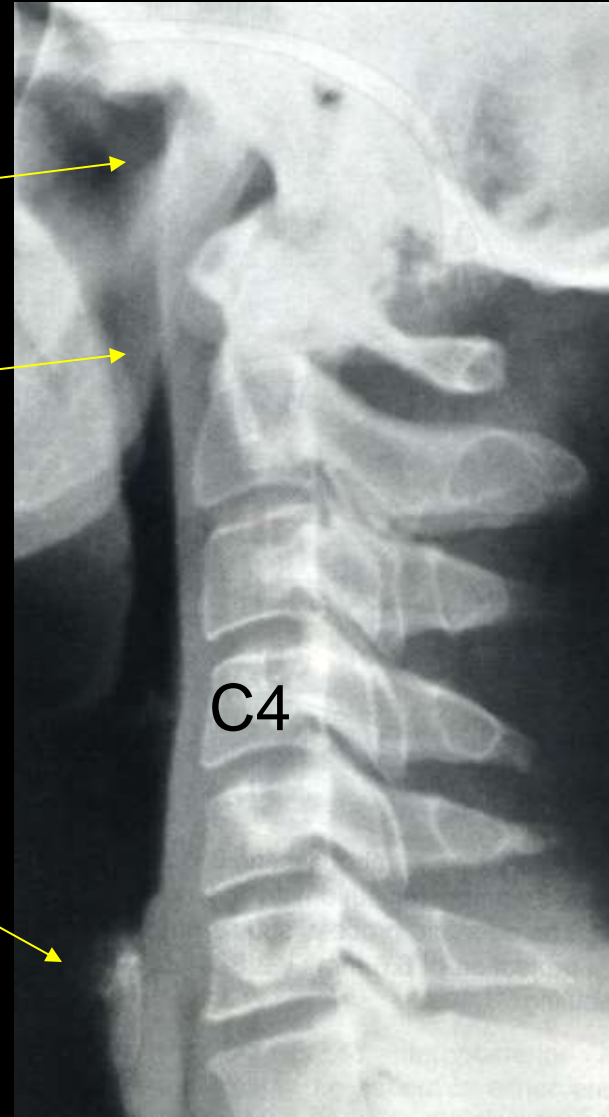

Reading Algorithm

Soft Tissues

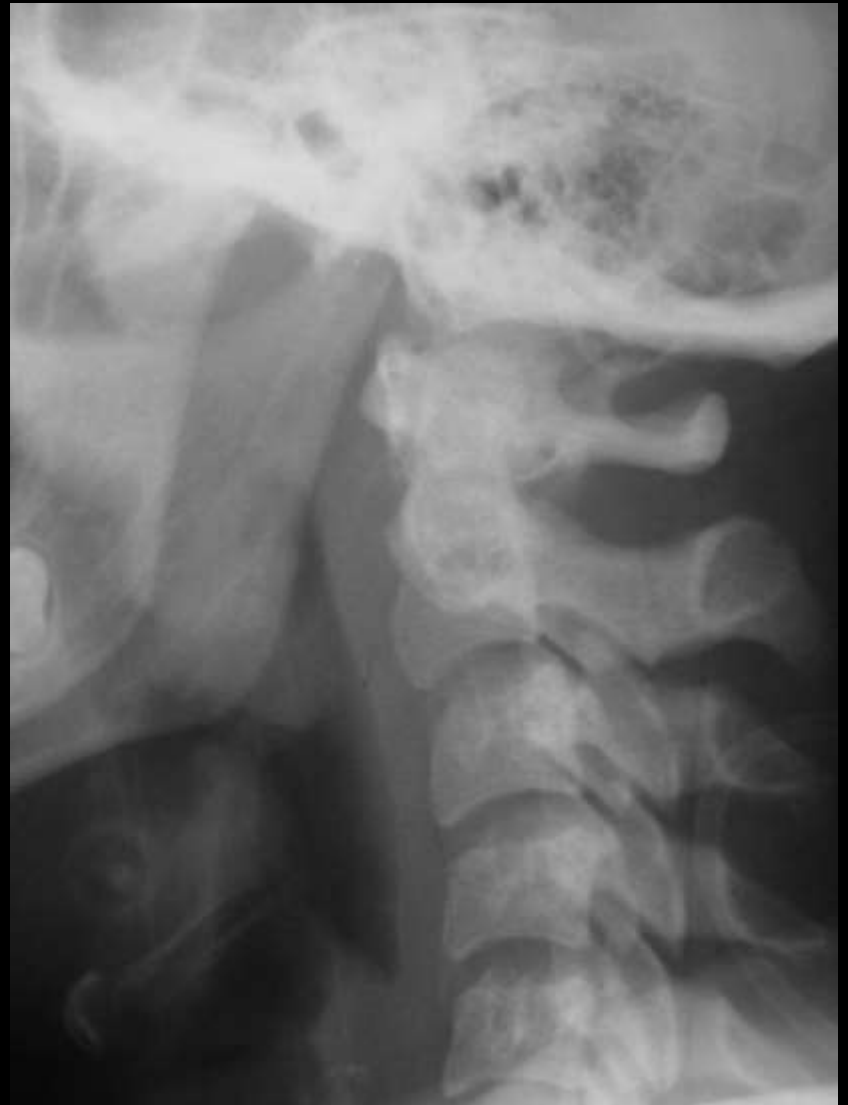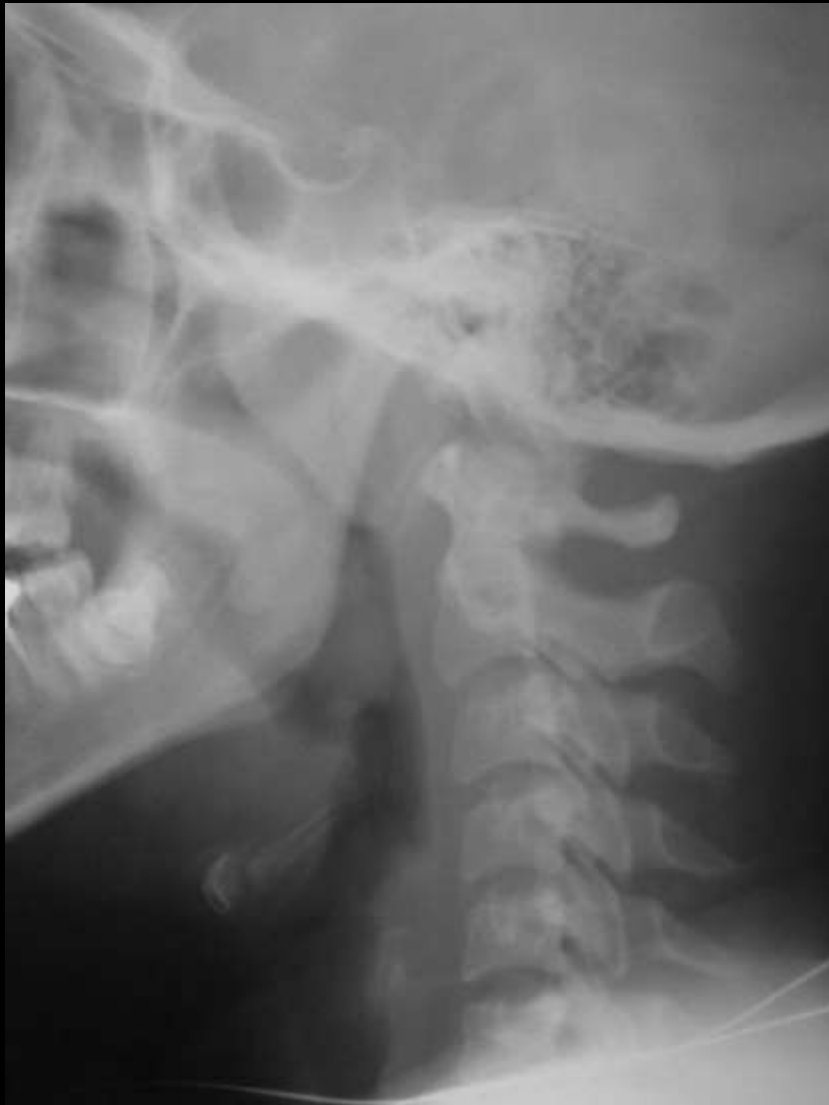Maximum Allowable Thickness

- Nasopharyngeal space (C1) - 10 mm (adult)
- Retropharyngeal space (C2 - C4) - 5-7 mm
- Retrotracheal space (C5 - C7)
 - 14 mm (children)
 - 22 mm (adults)

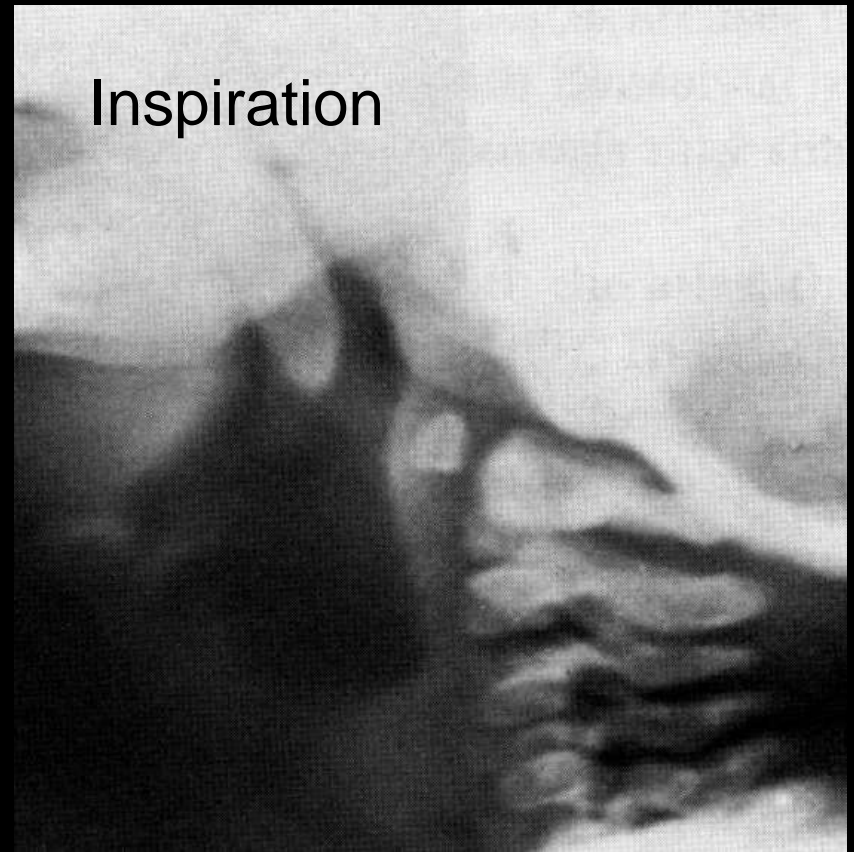
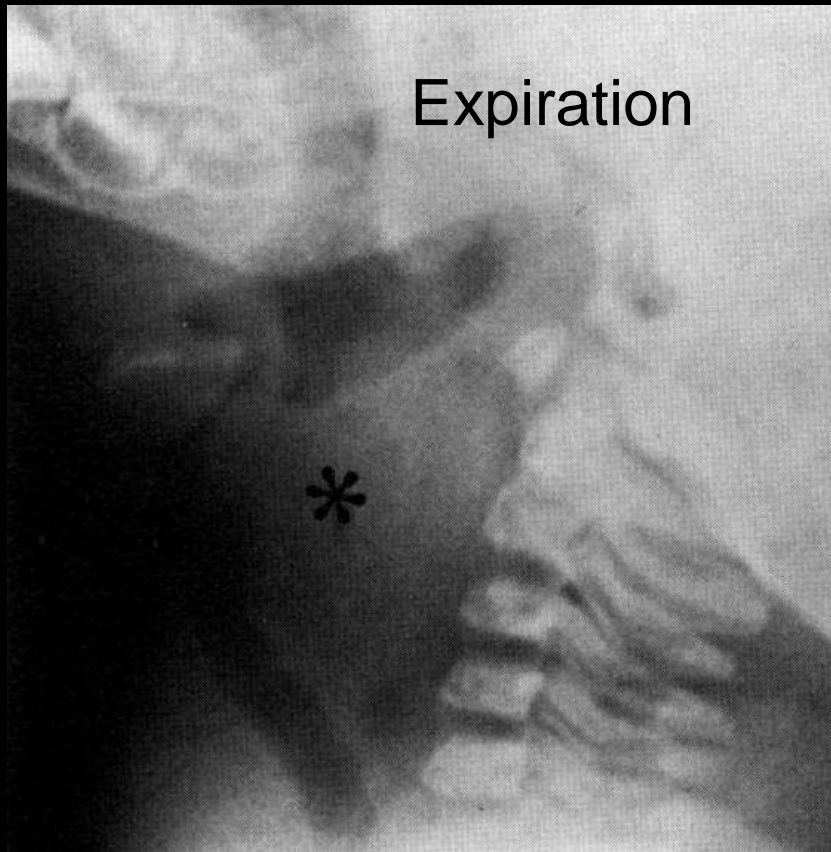


Reading Algorithm - Soft Tissues

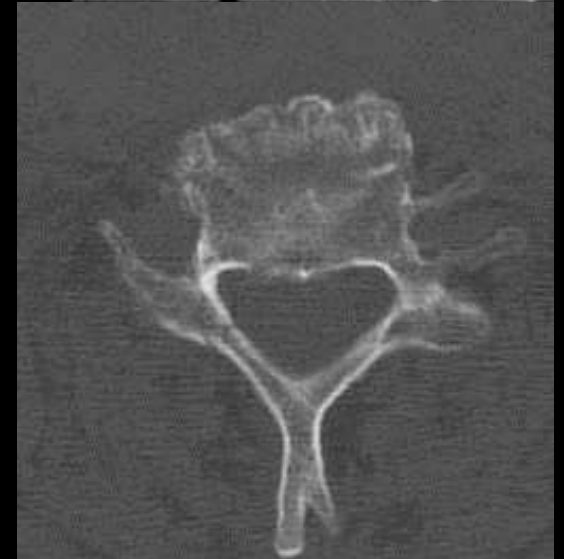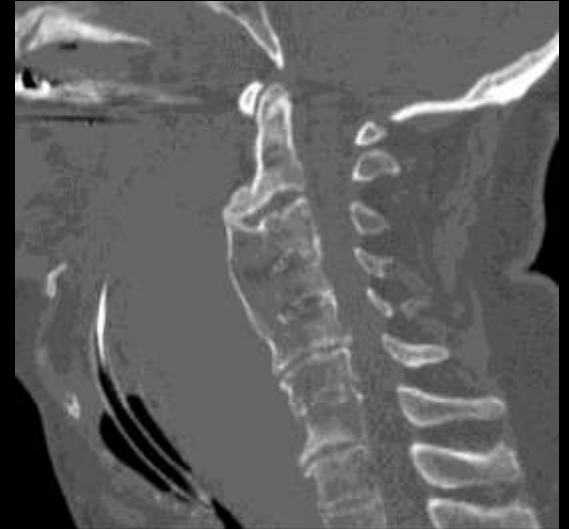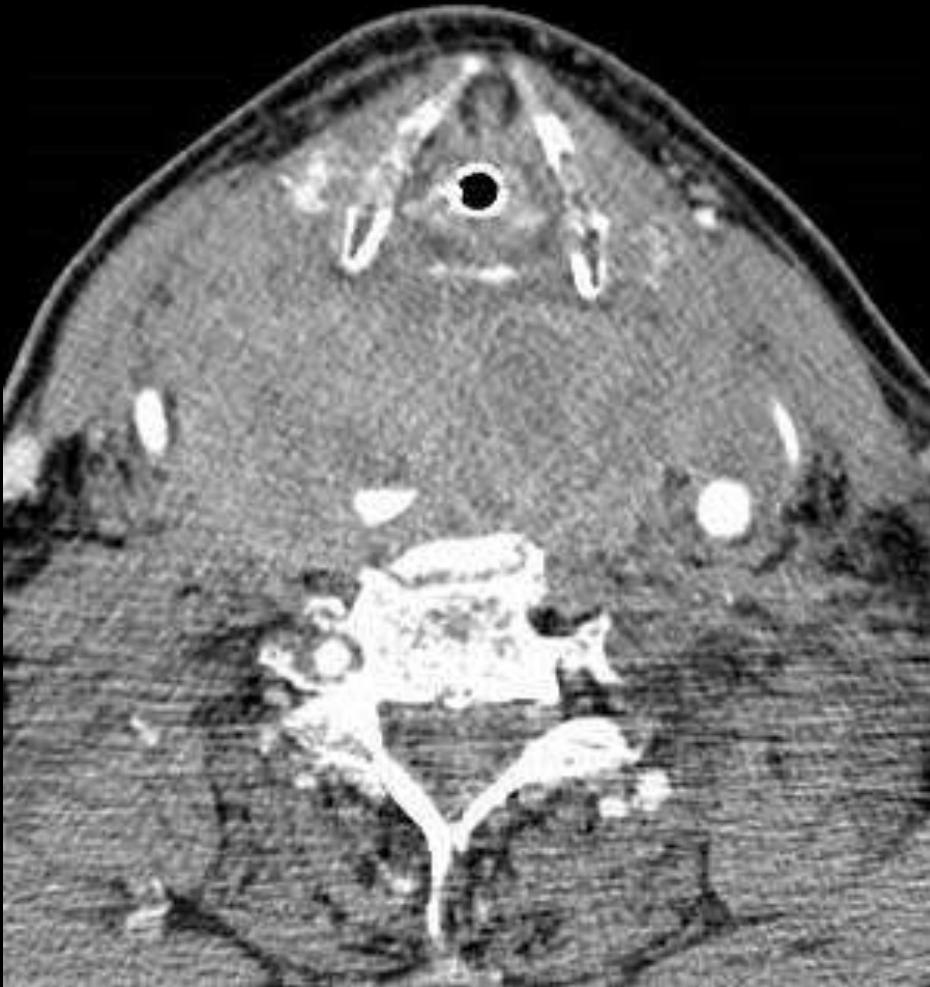Adenoids



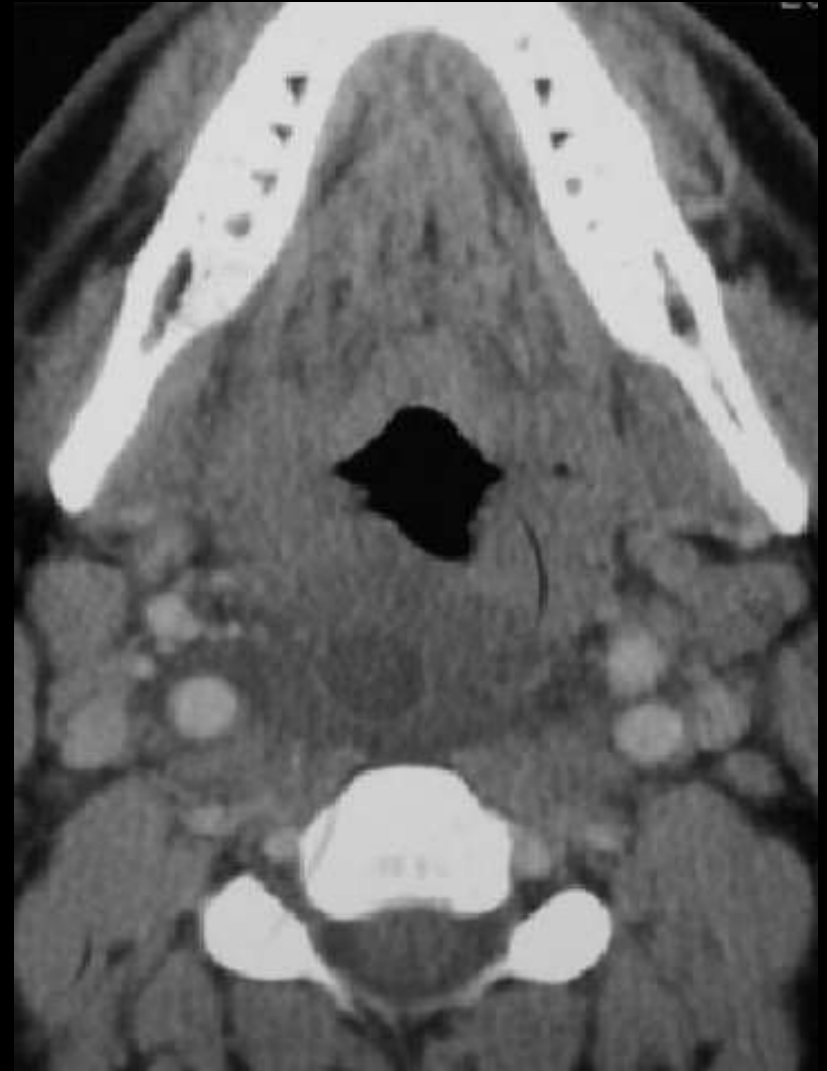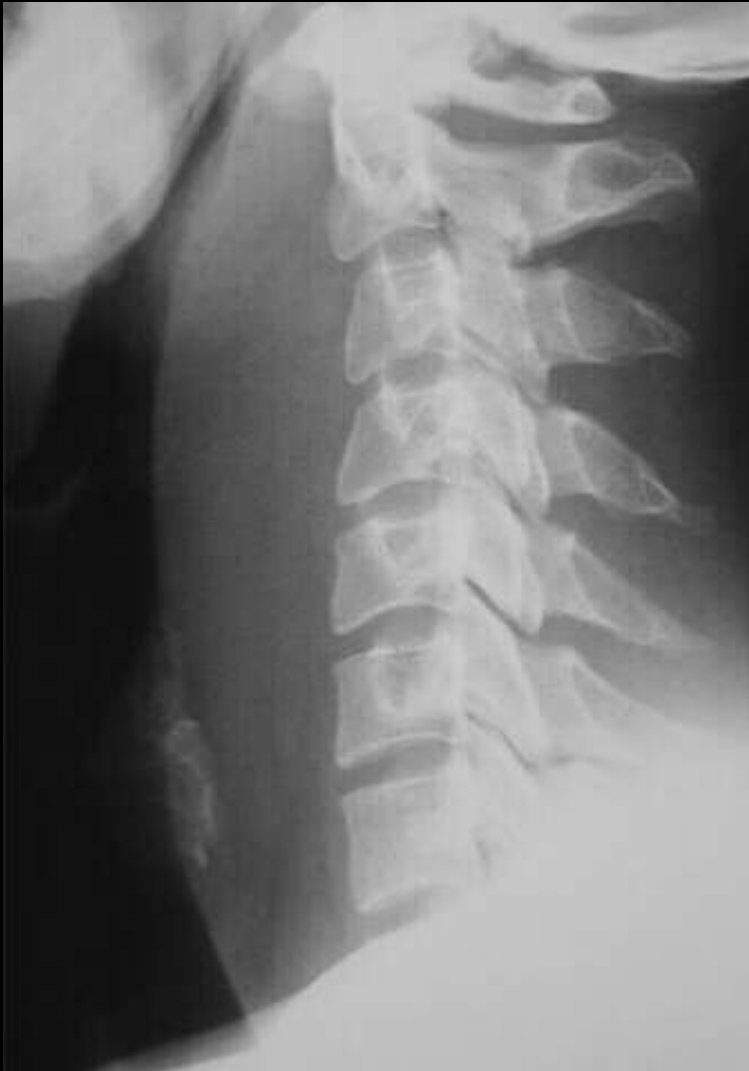Retropharyngeal Soft Tissues



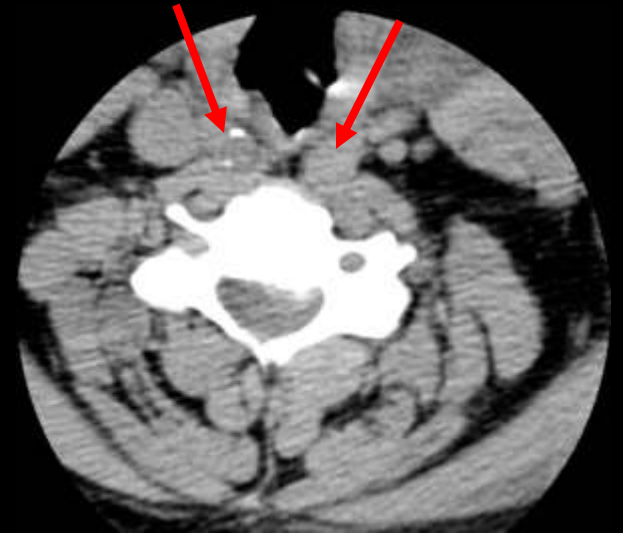
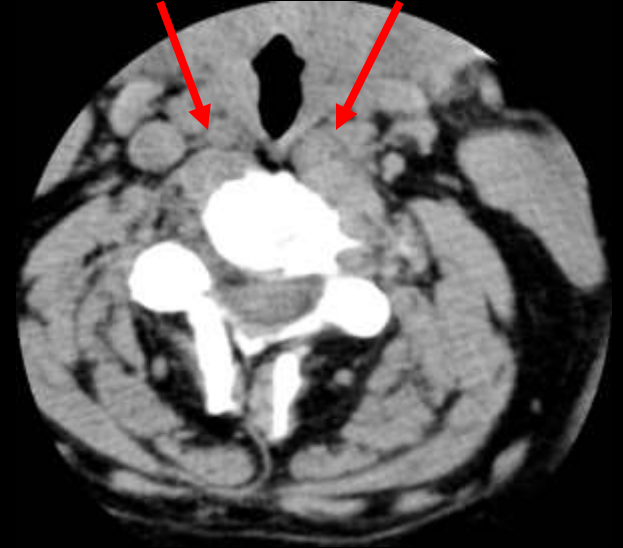
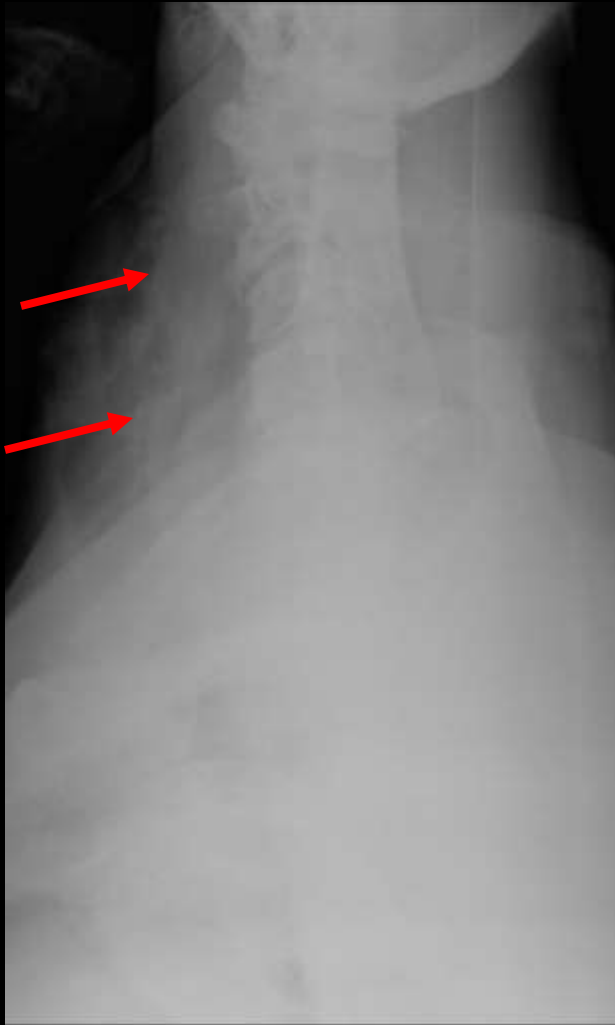Cx hematoma



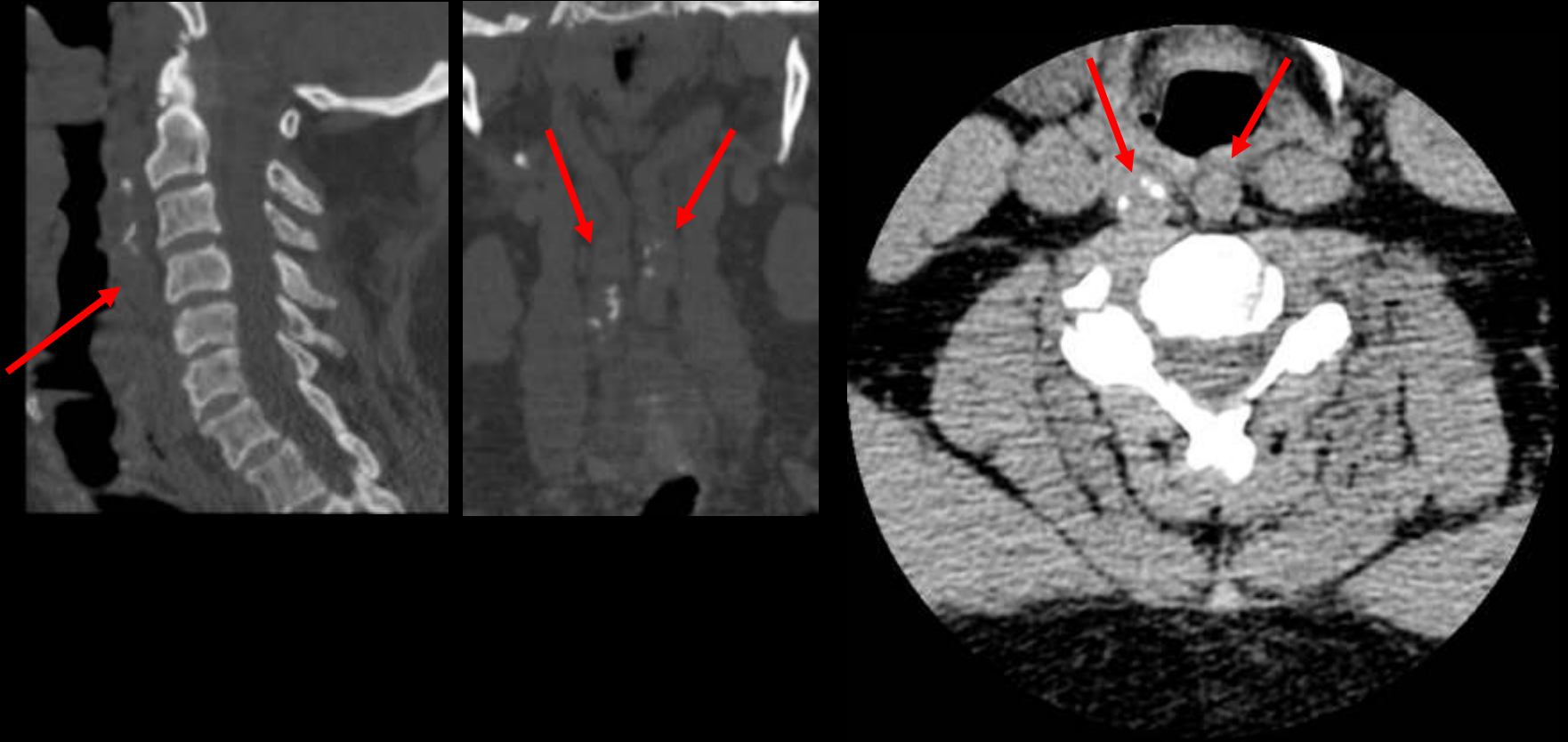
Retropharyngeal Abscess



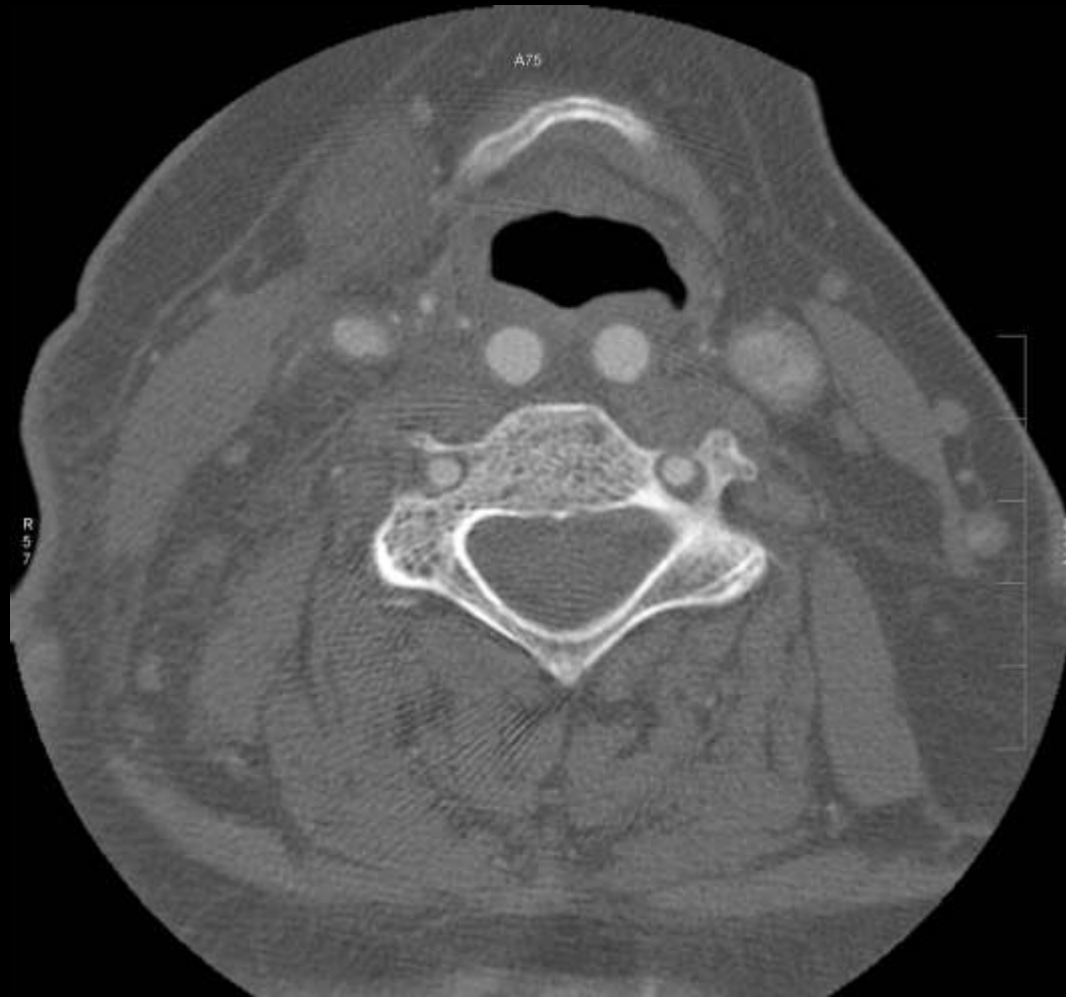Prevertebral carotids



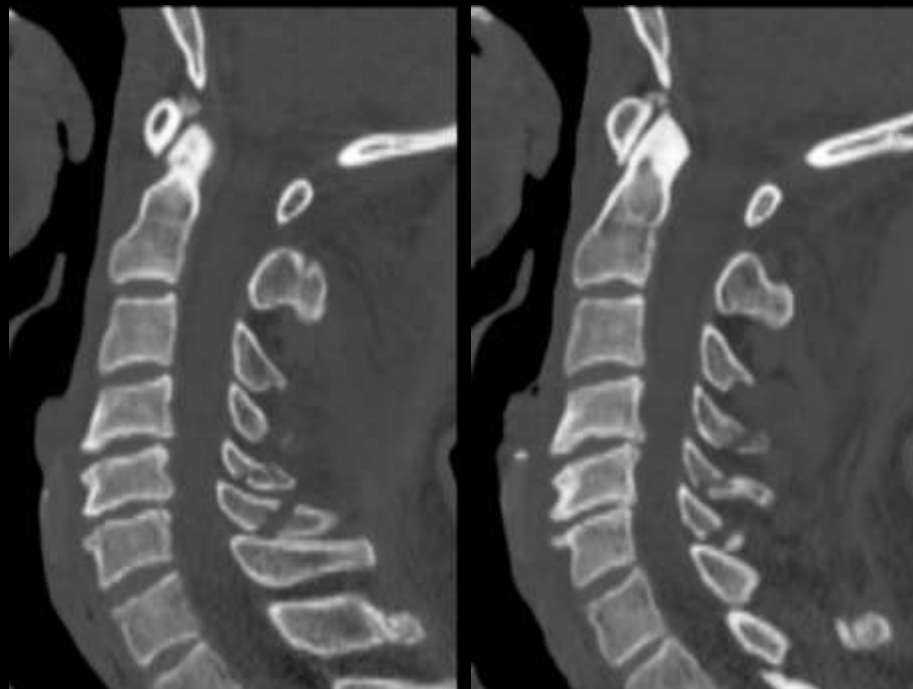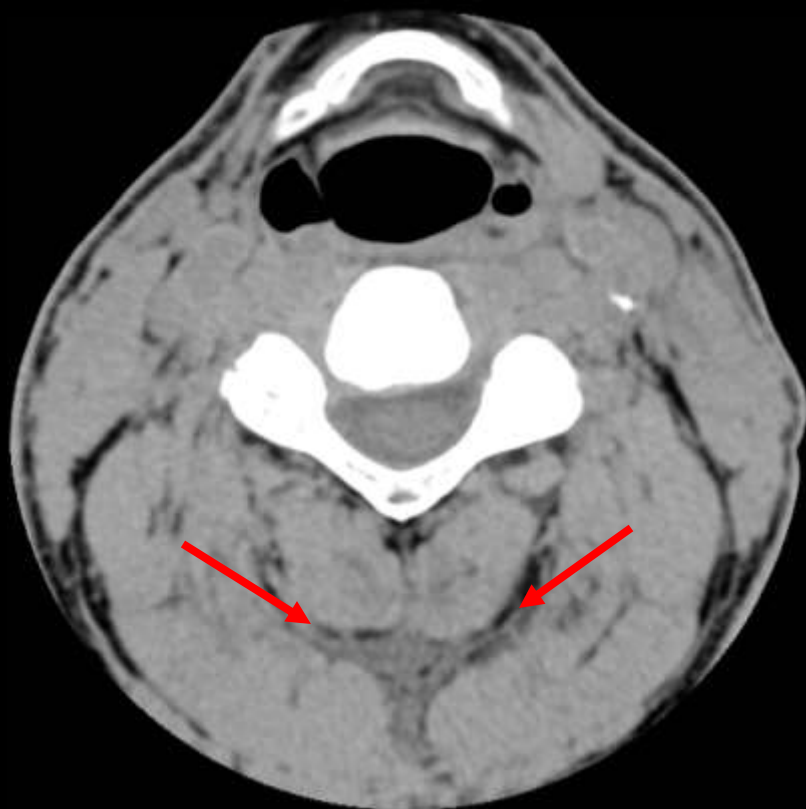
Prevertebral carotids



Prevertebral carotids

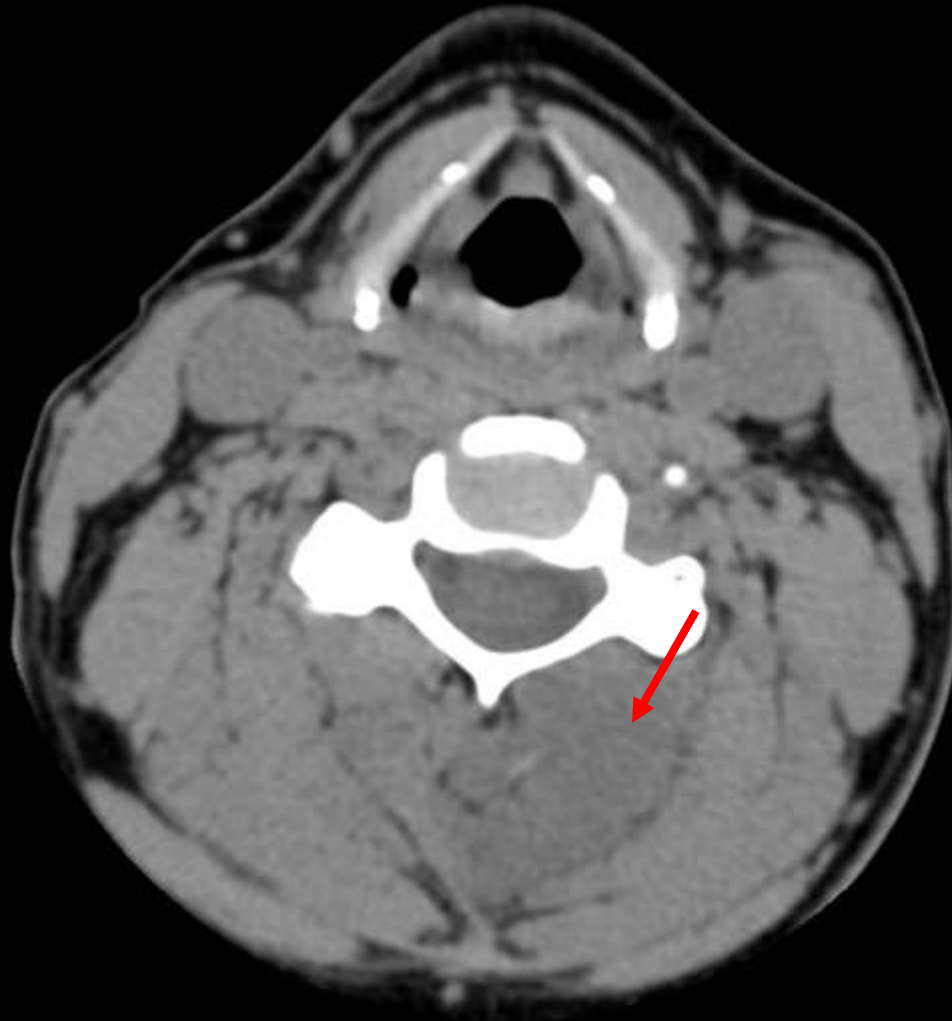


Paraspinal muscle hematoma



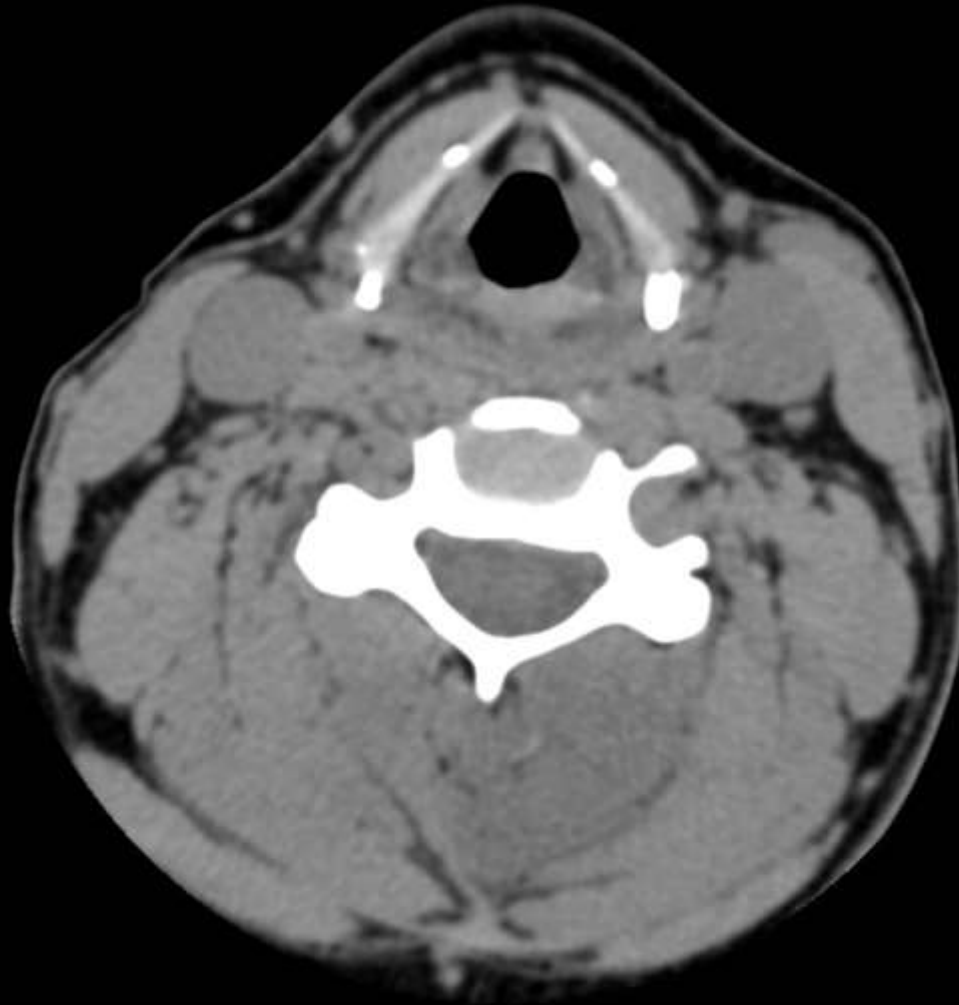Semispinalis muscle hematoma

64



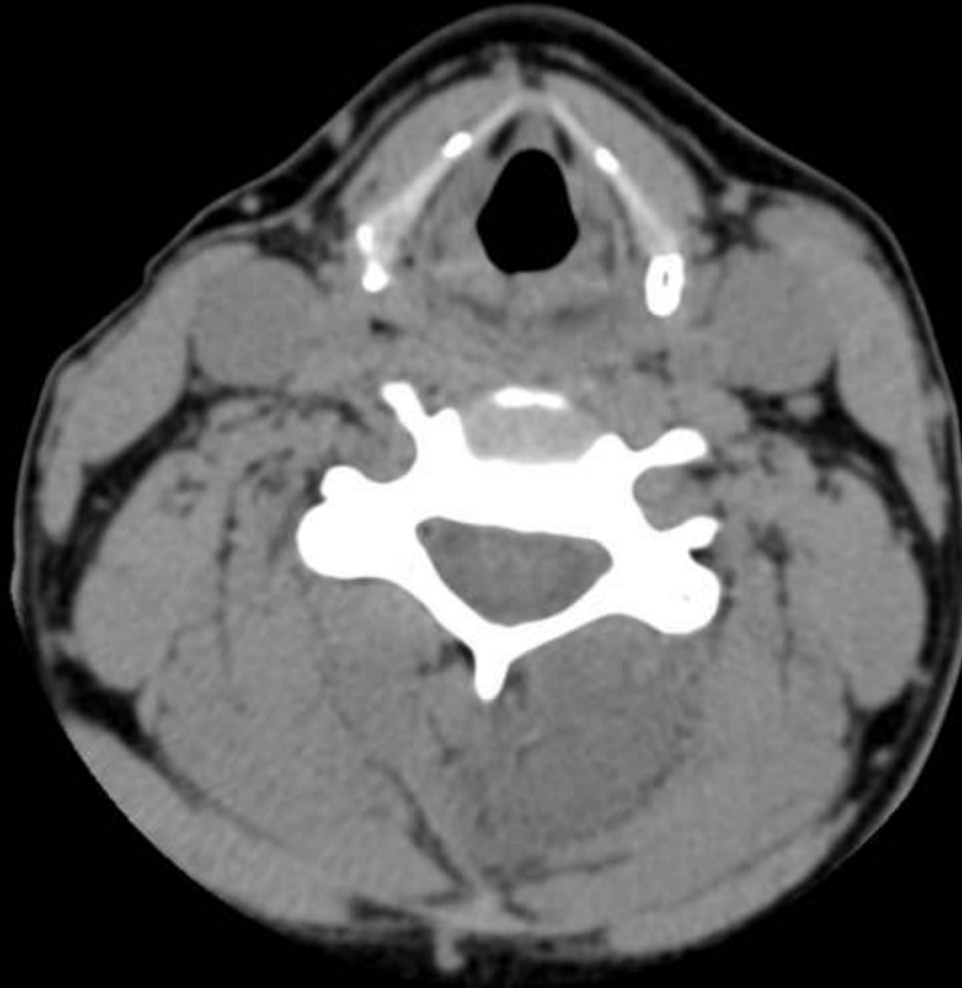Semispinalis muscle hematoma

65

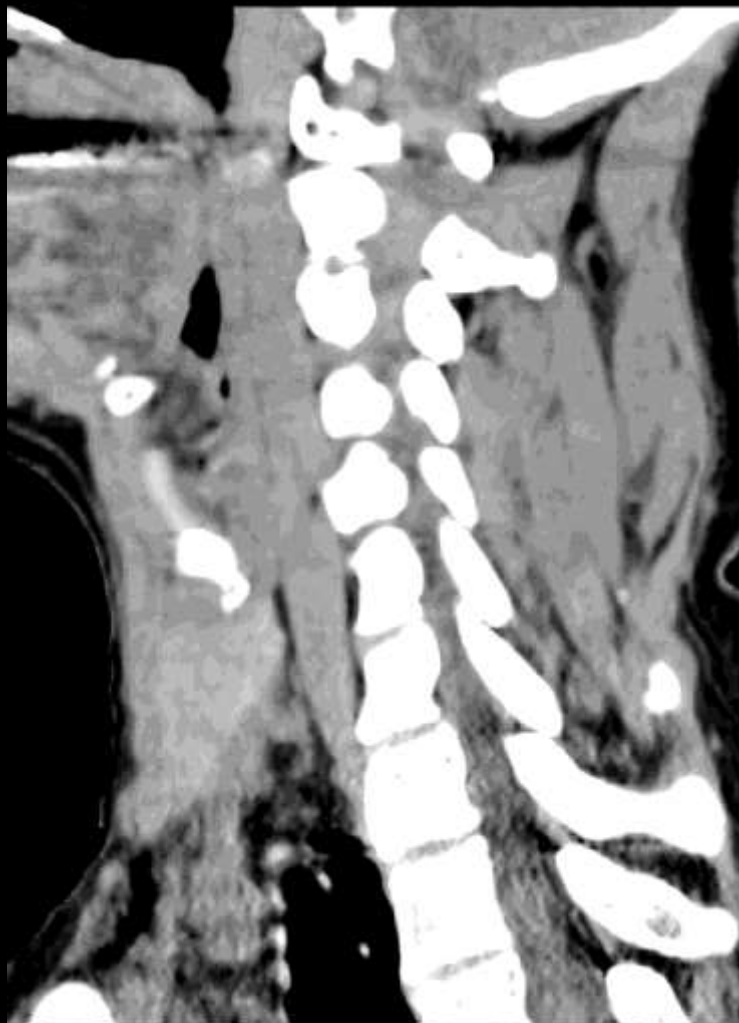

Semispinalis muscle hematoma

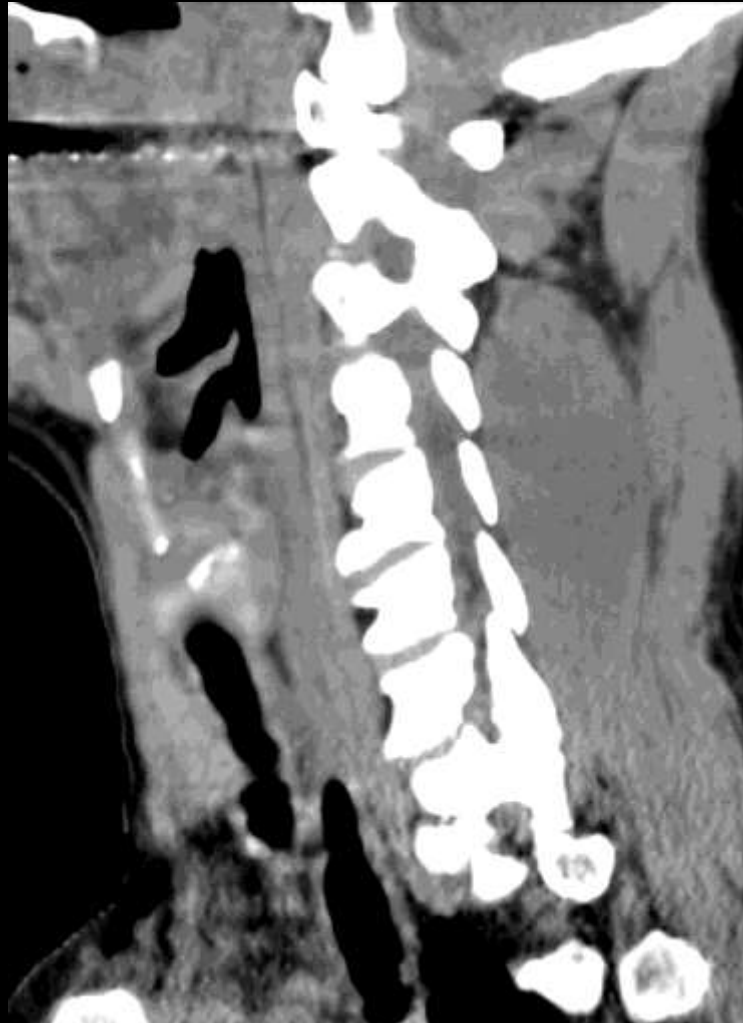66



Semispinalis muscle hematoma



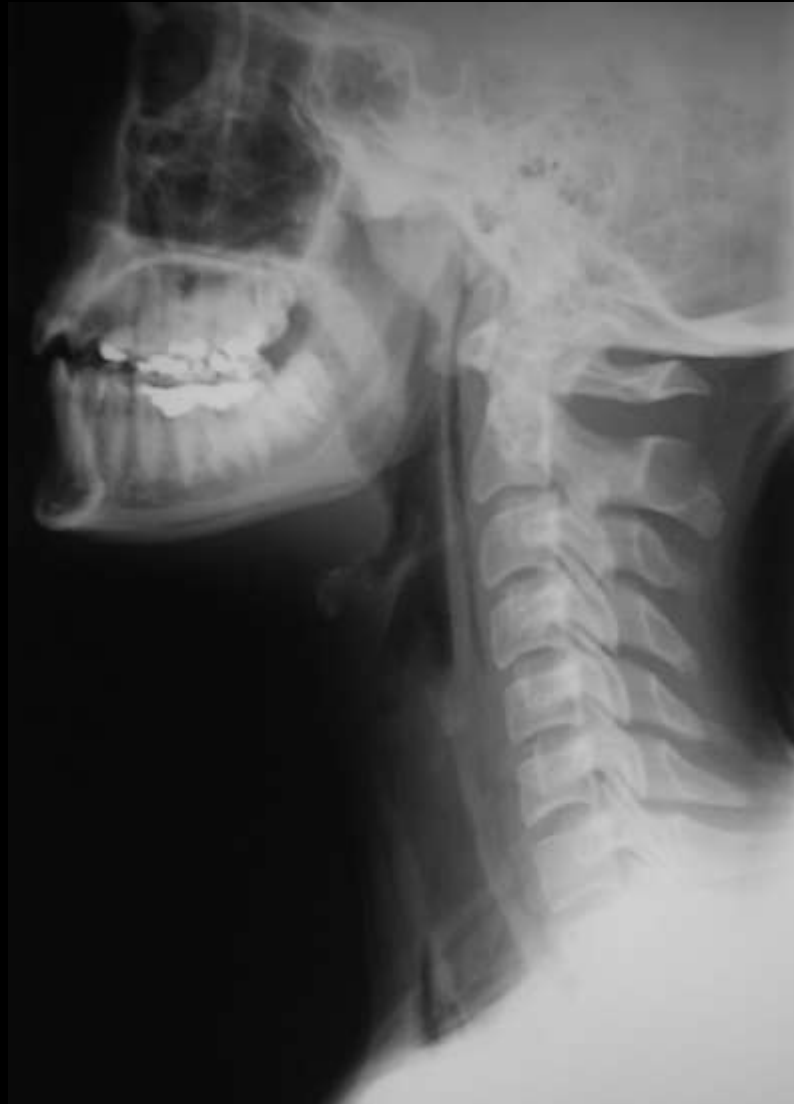Right



Left

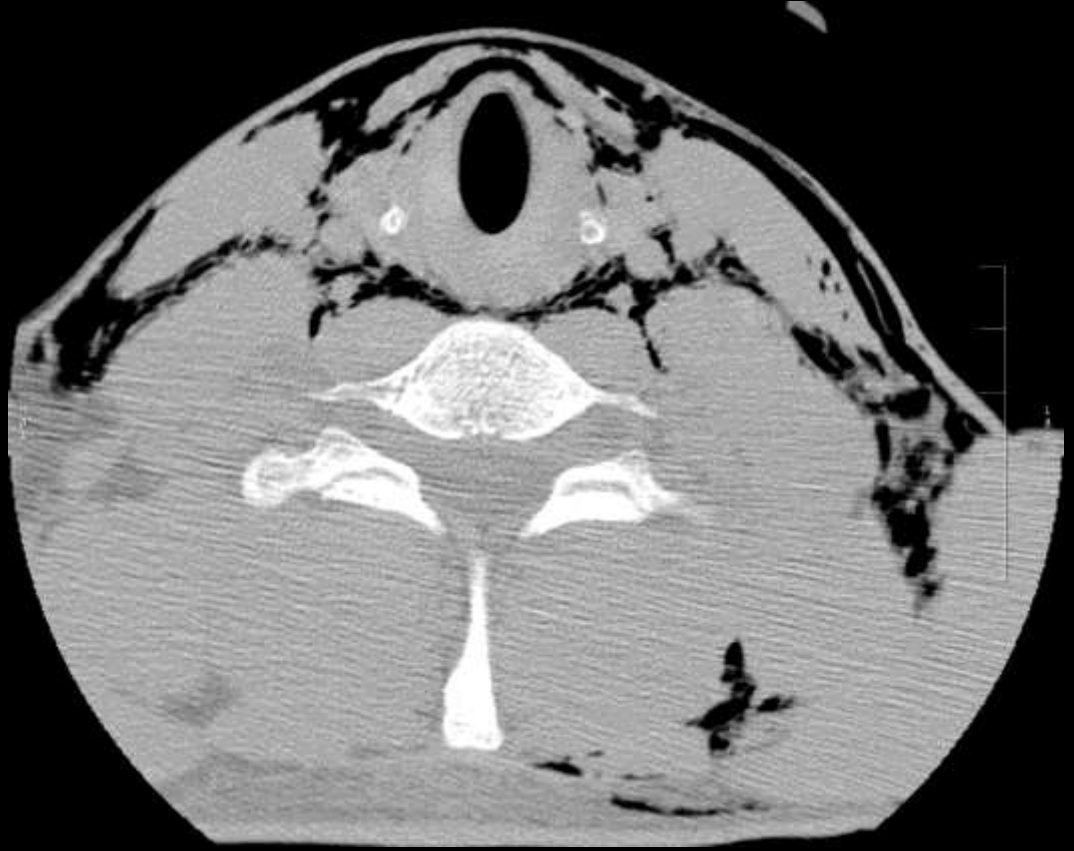
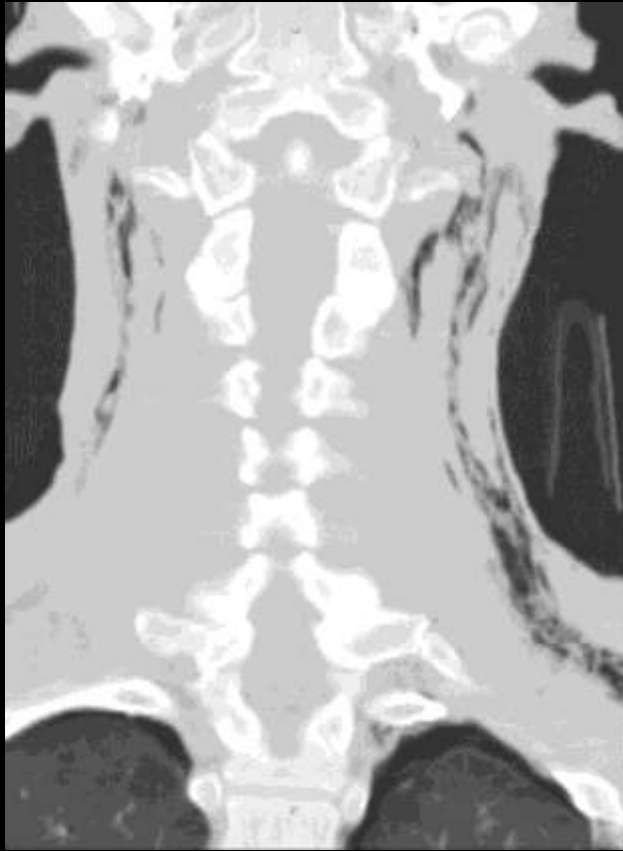Reading Algorithm - Soft Tissues

Soft Tissue Gas

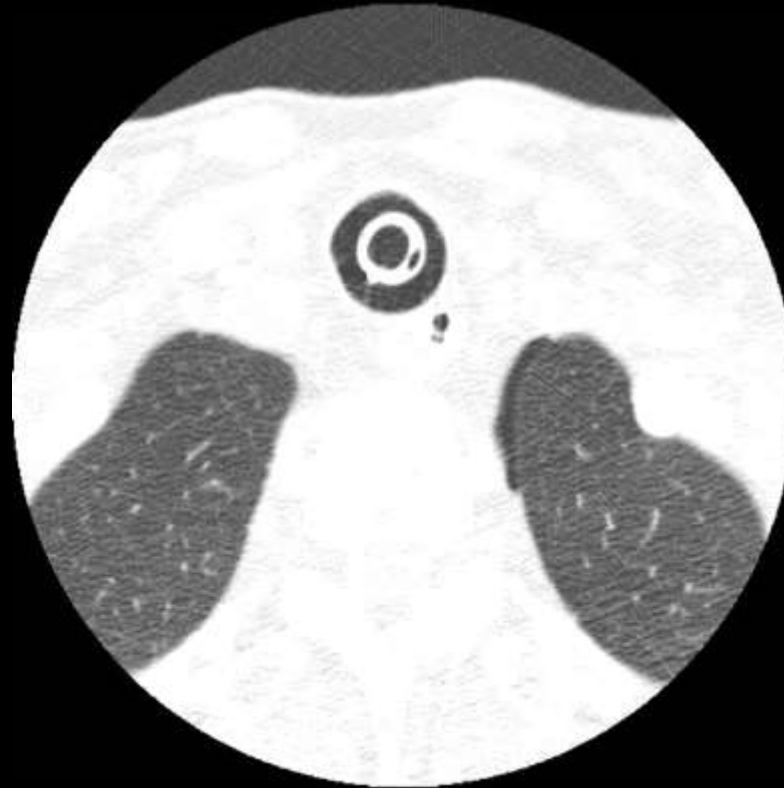

From pneumomediastinum

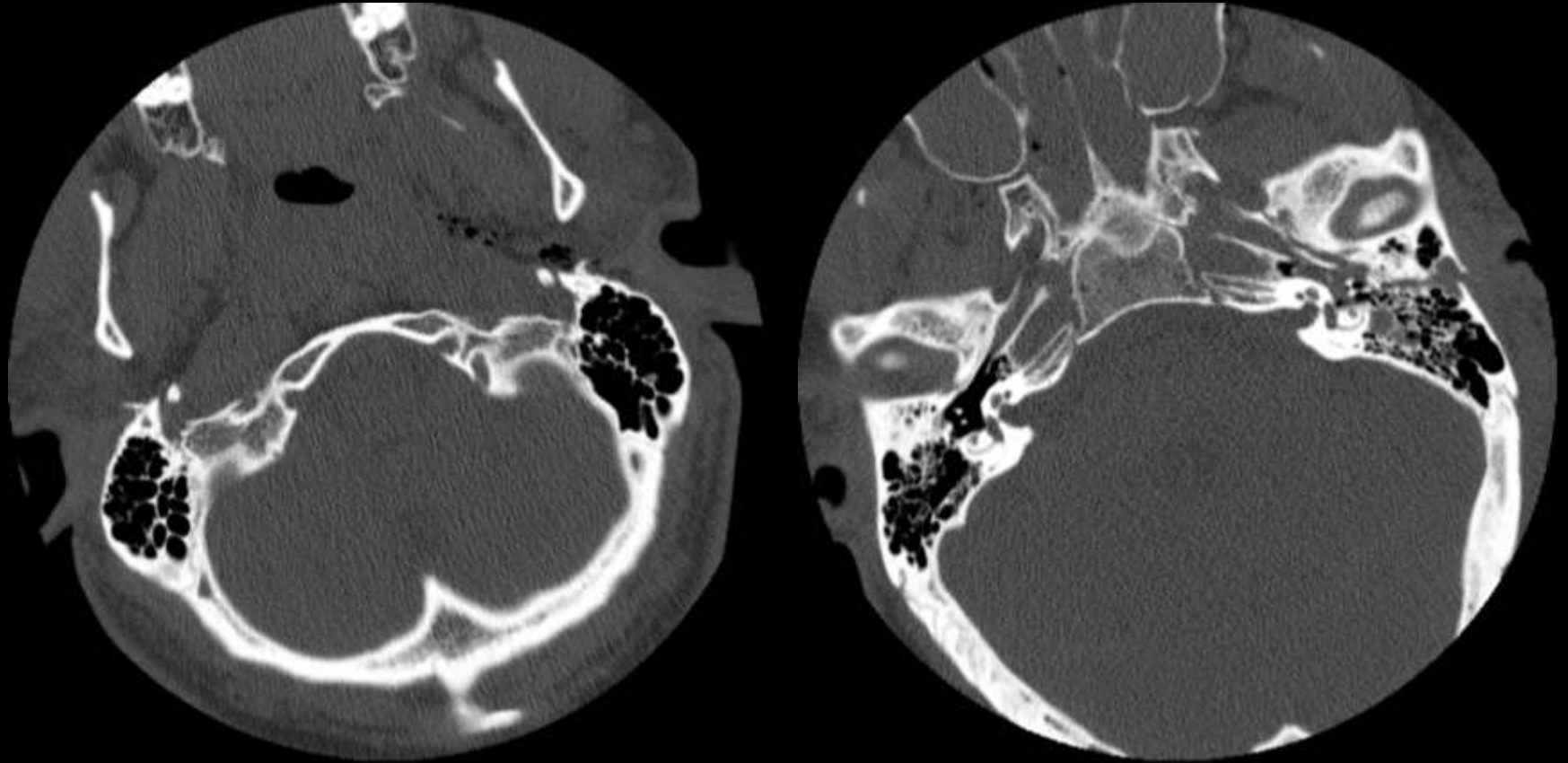
Pneumothorax and ST emphysema



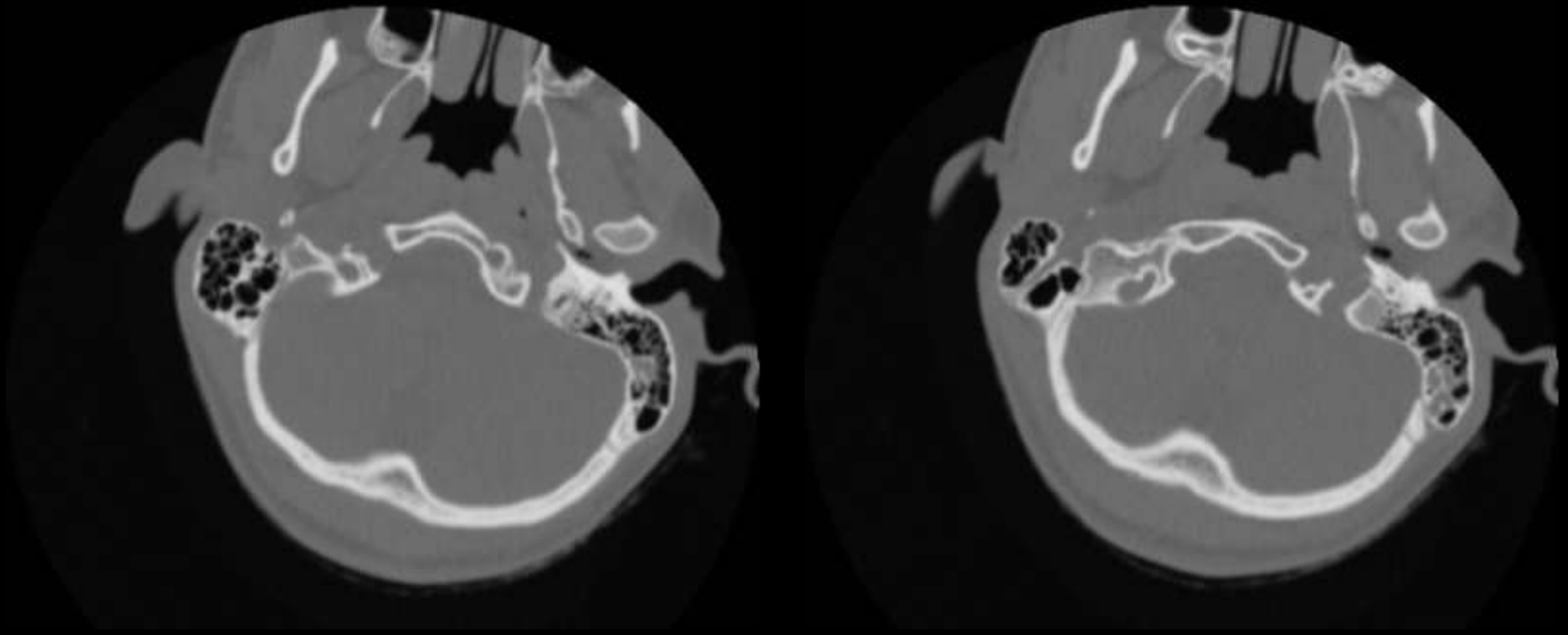
Always check for Pneumothorax



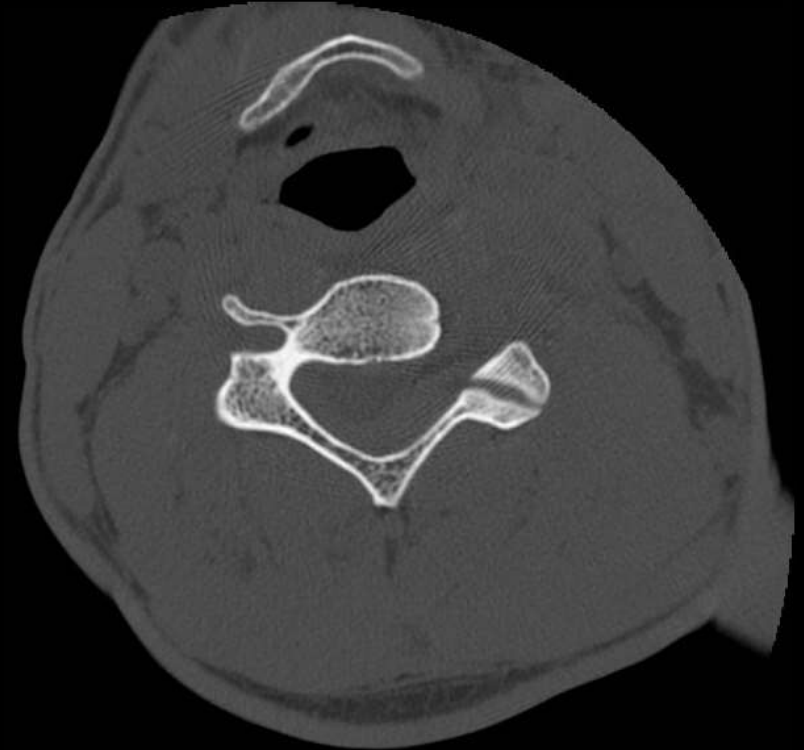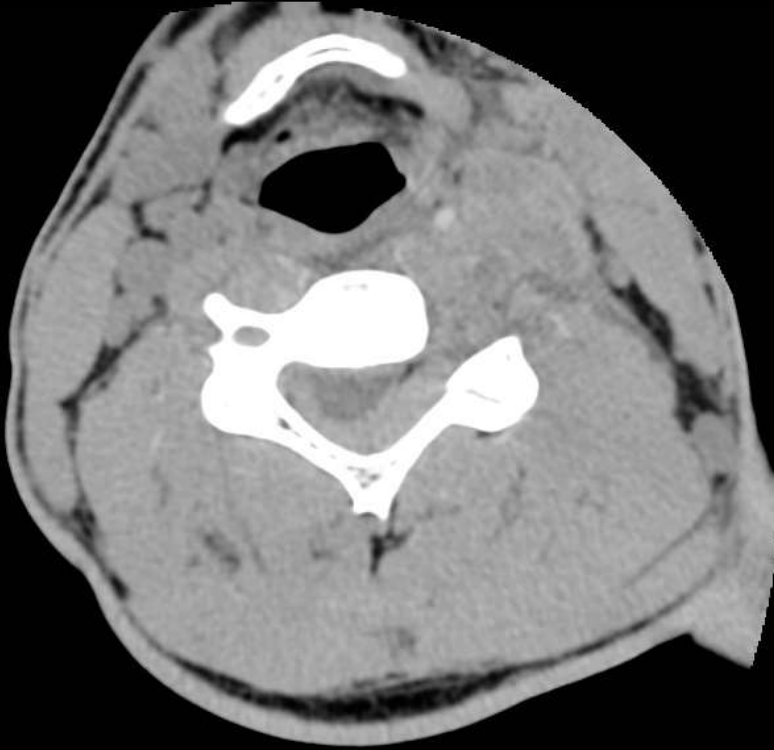
Skull Fracture ST emphysema



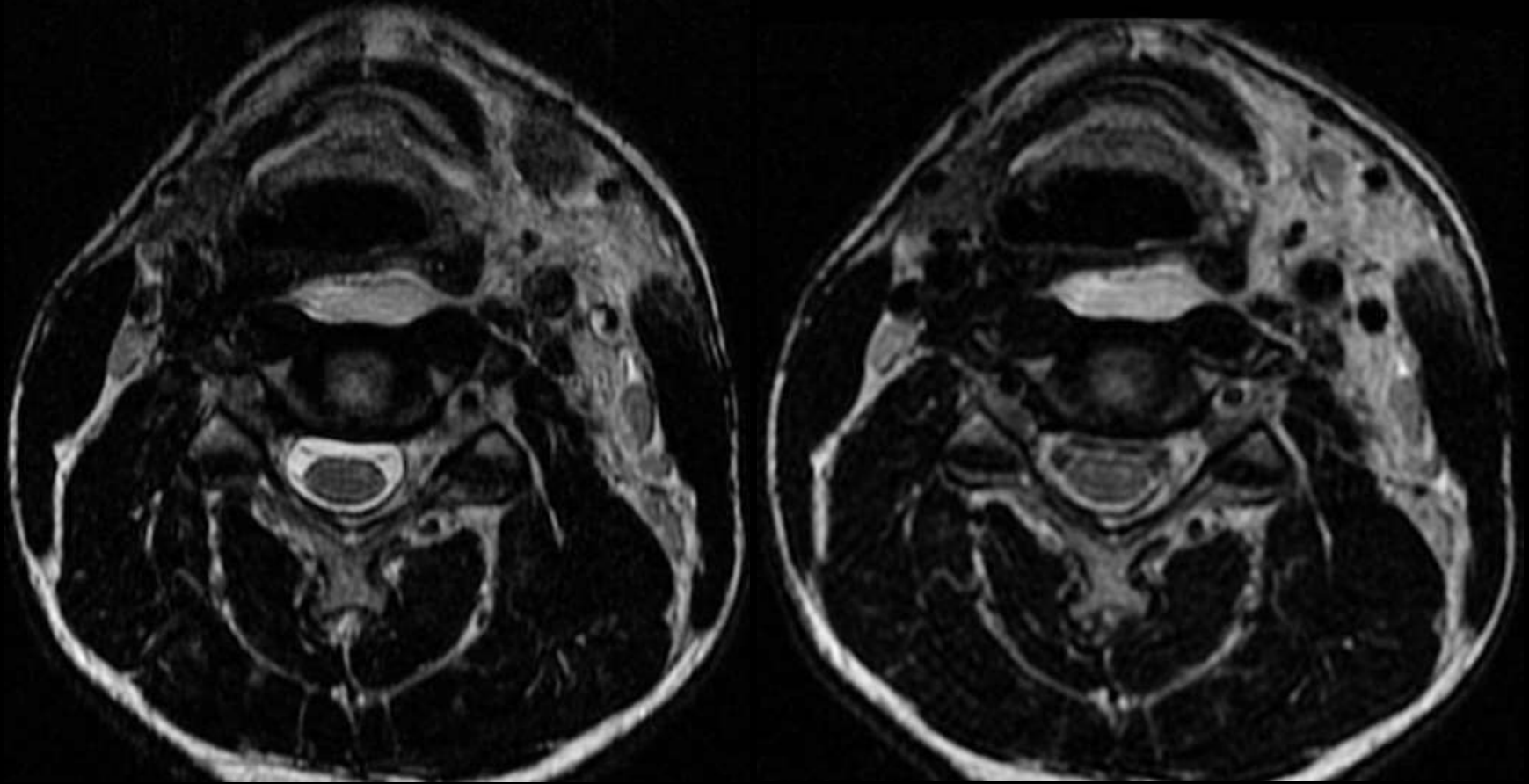
Skull Fracture ST emphysema



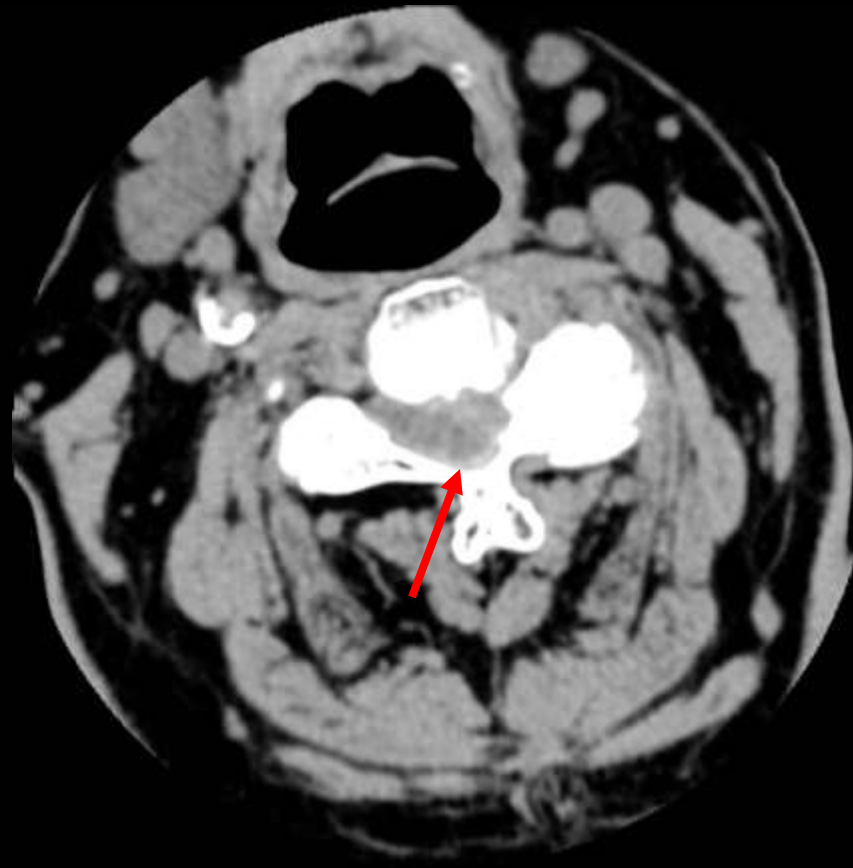
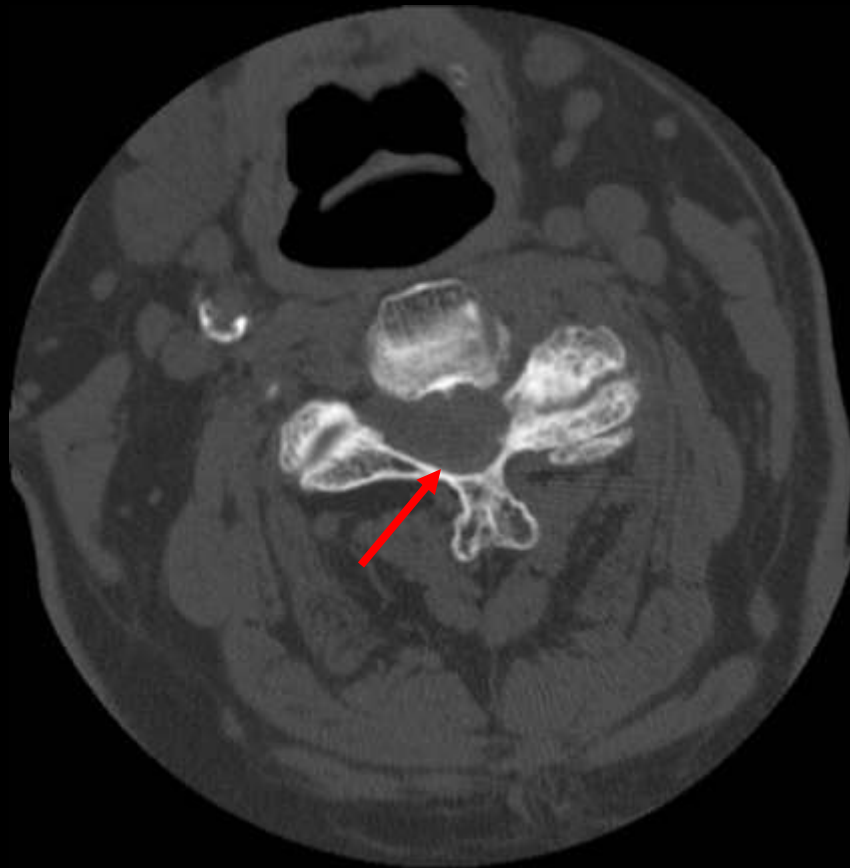
Epidural blood



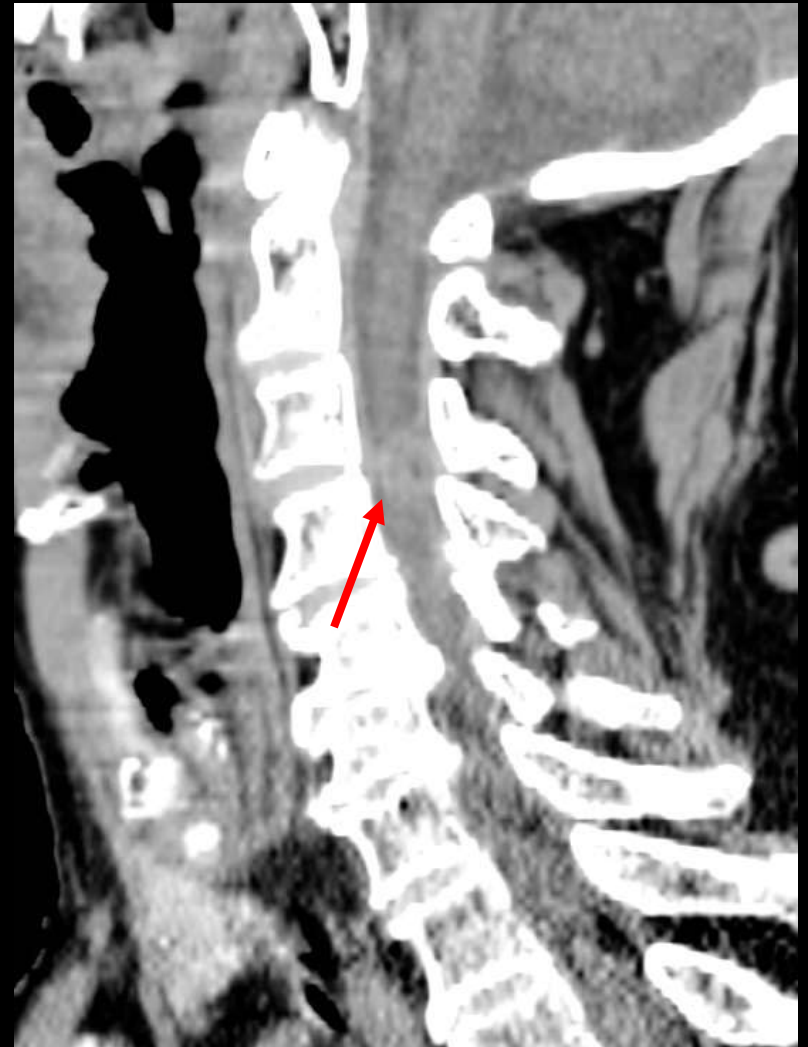
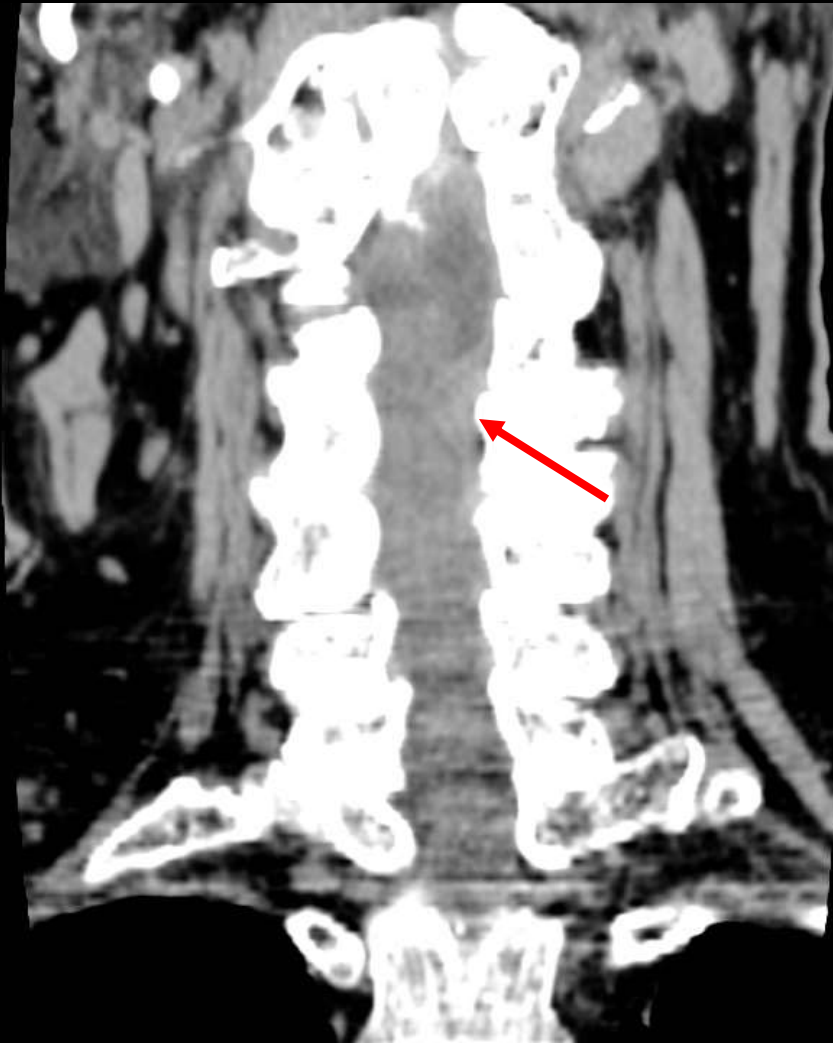
Epidural blood



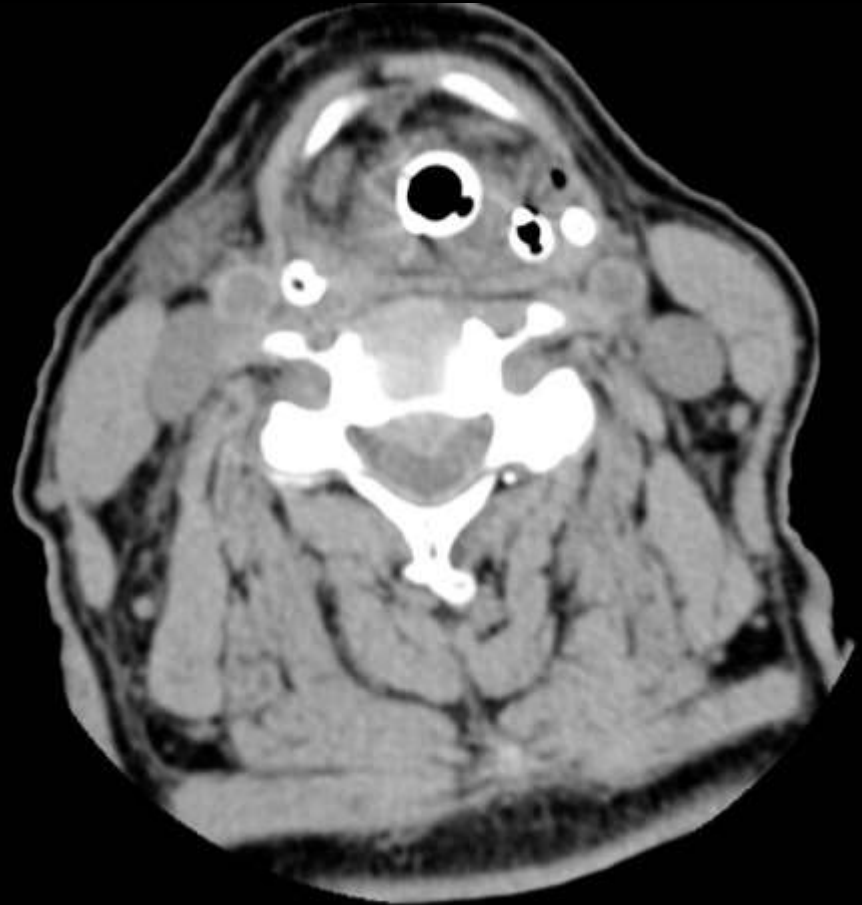
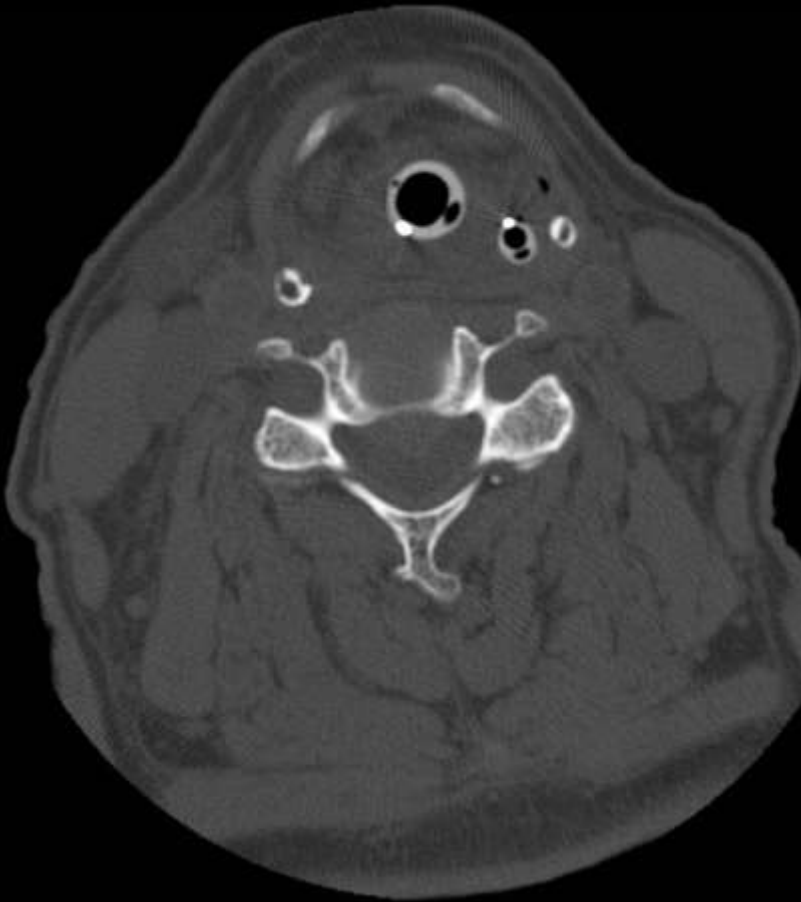
C3-4 synovial cyst



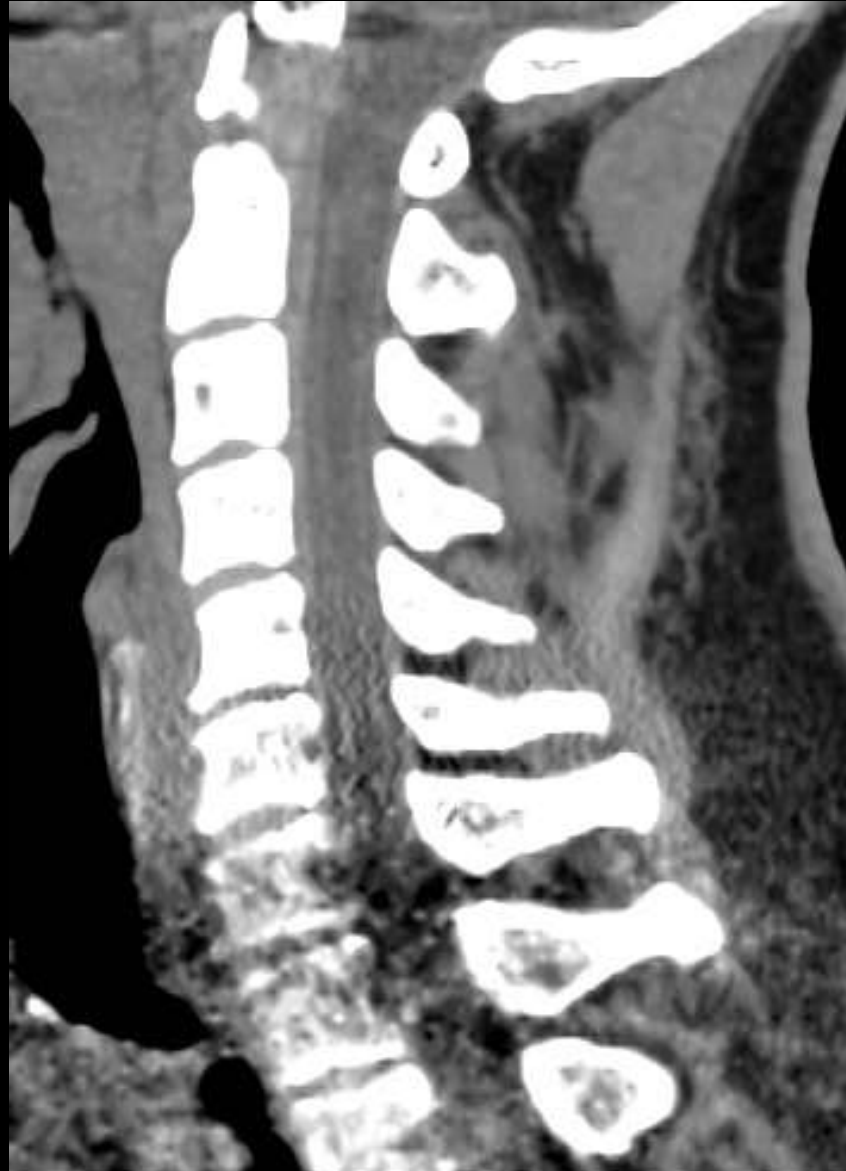C3-4 synovial cyst



C4-5 disc extrusion

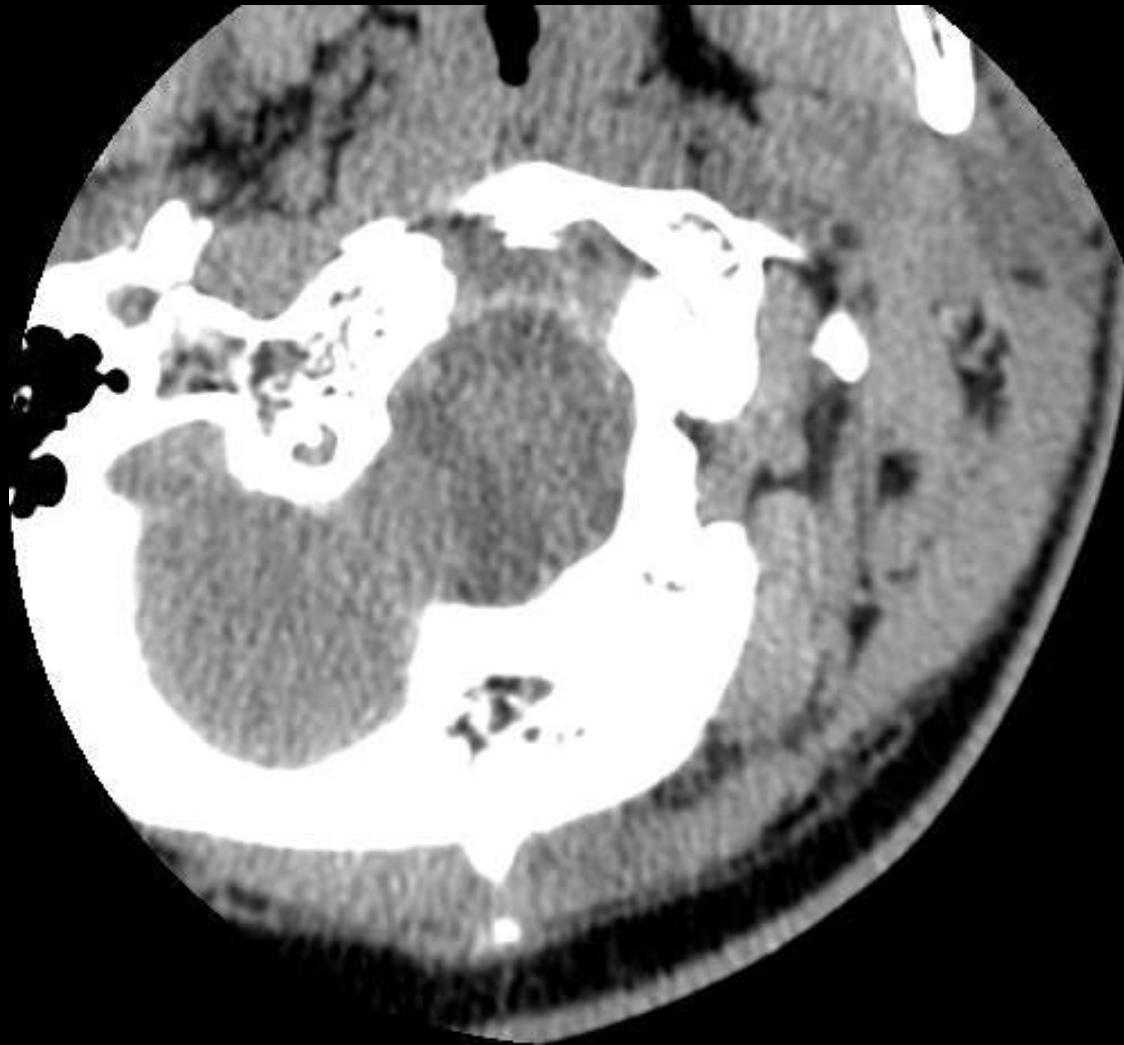


Syrinx

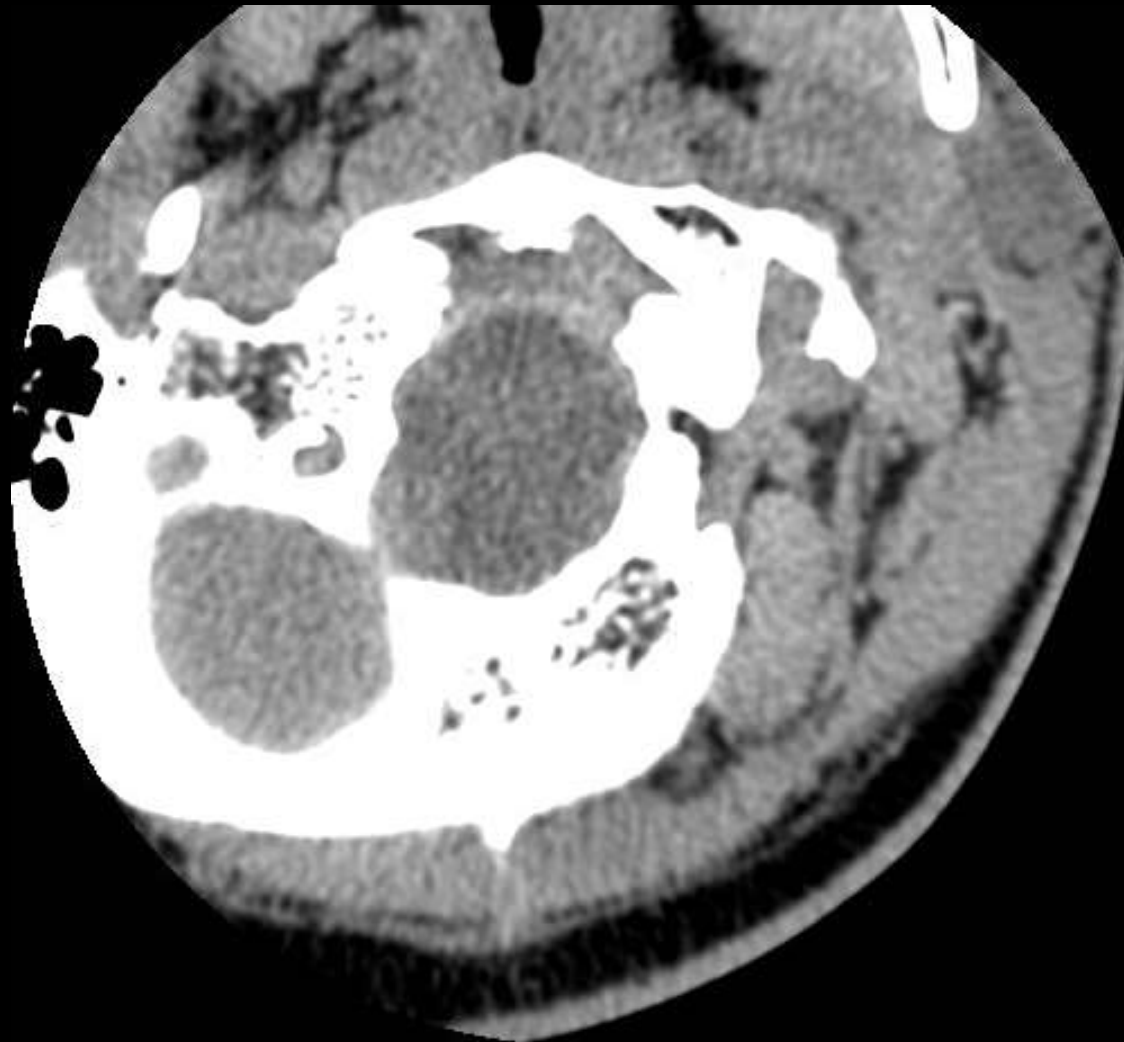


Syrinx on CT 51M multiple falls

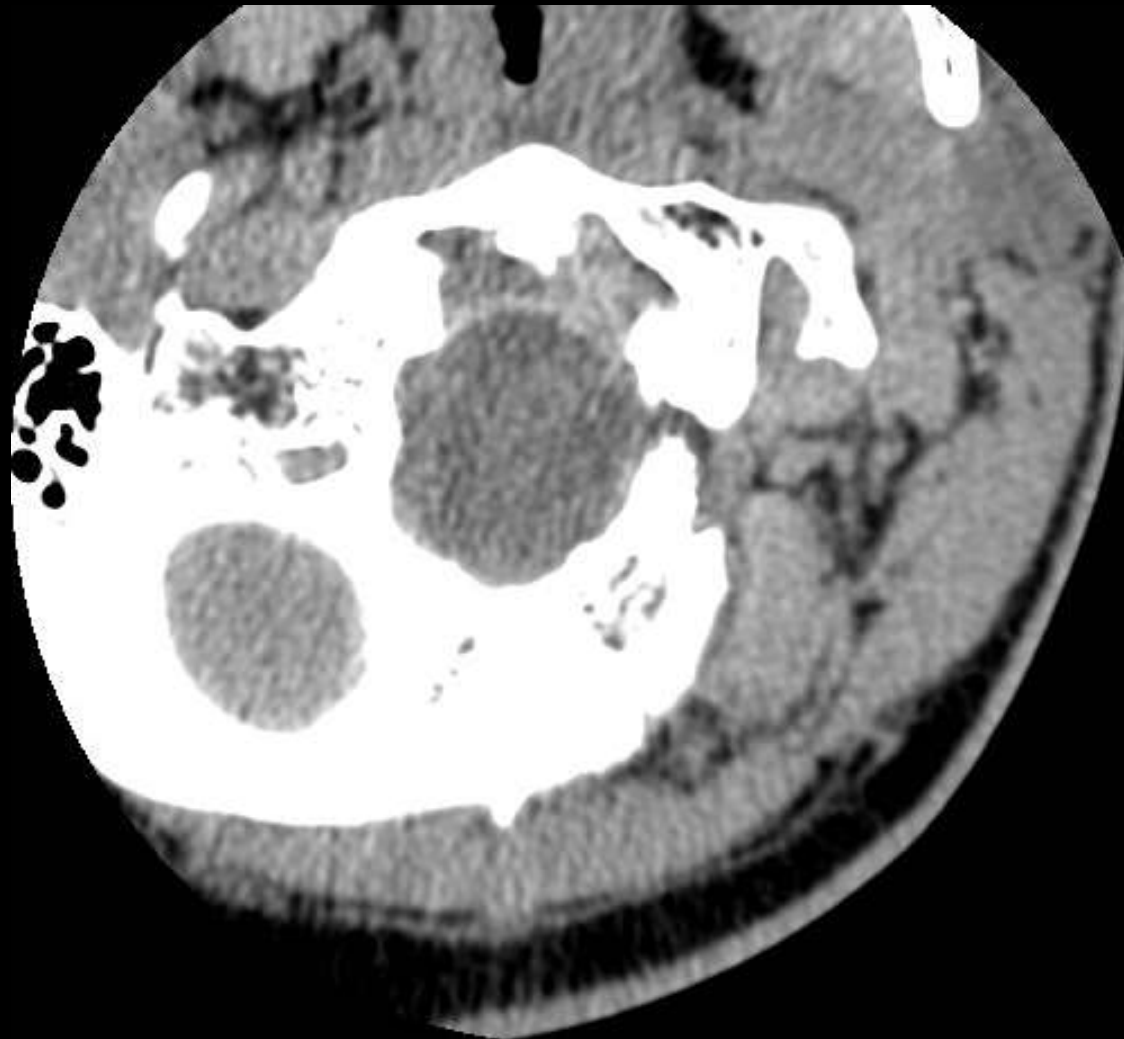
Syrinx



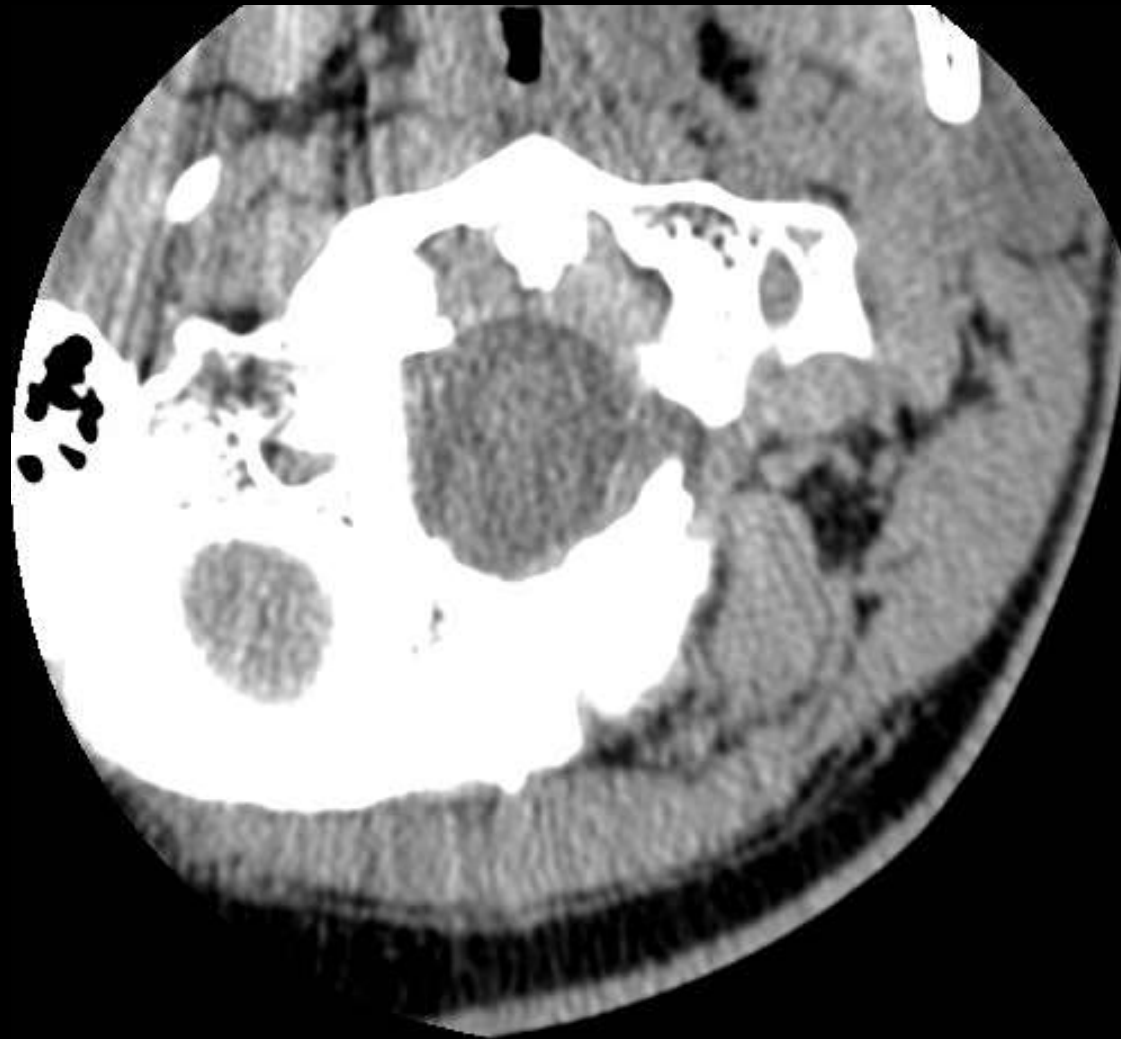
Syrinx



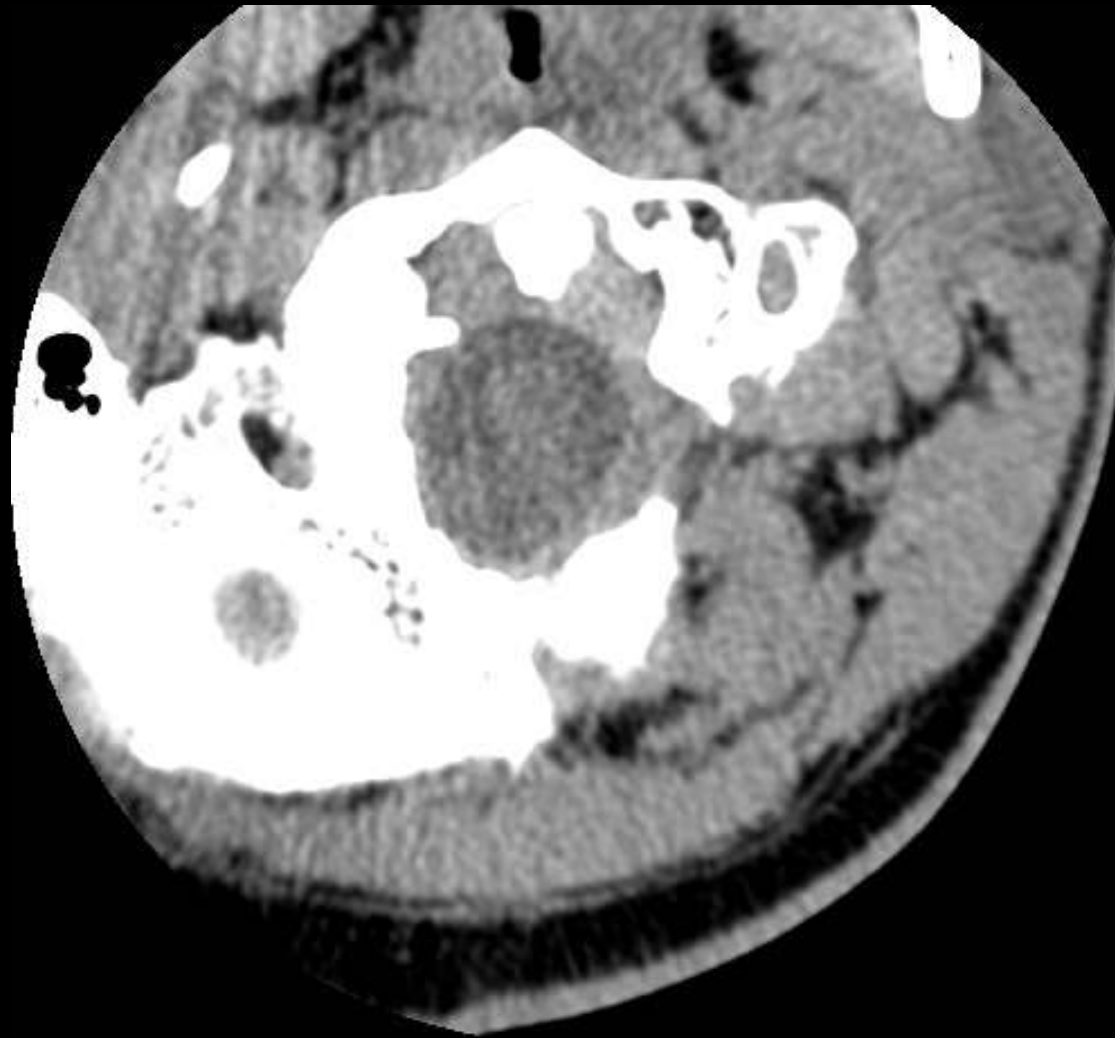
Syrinx



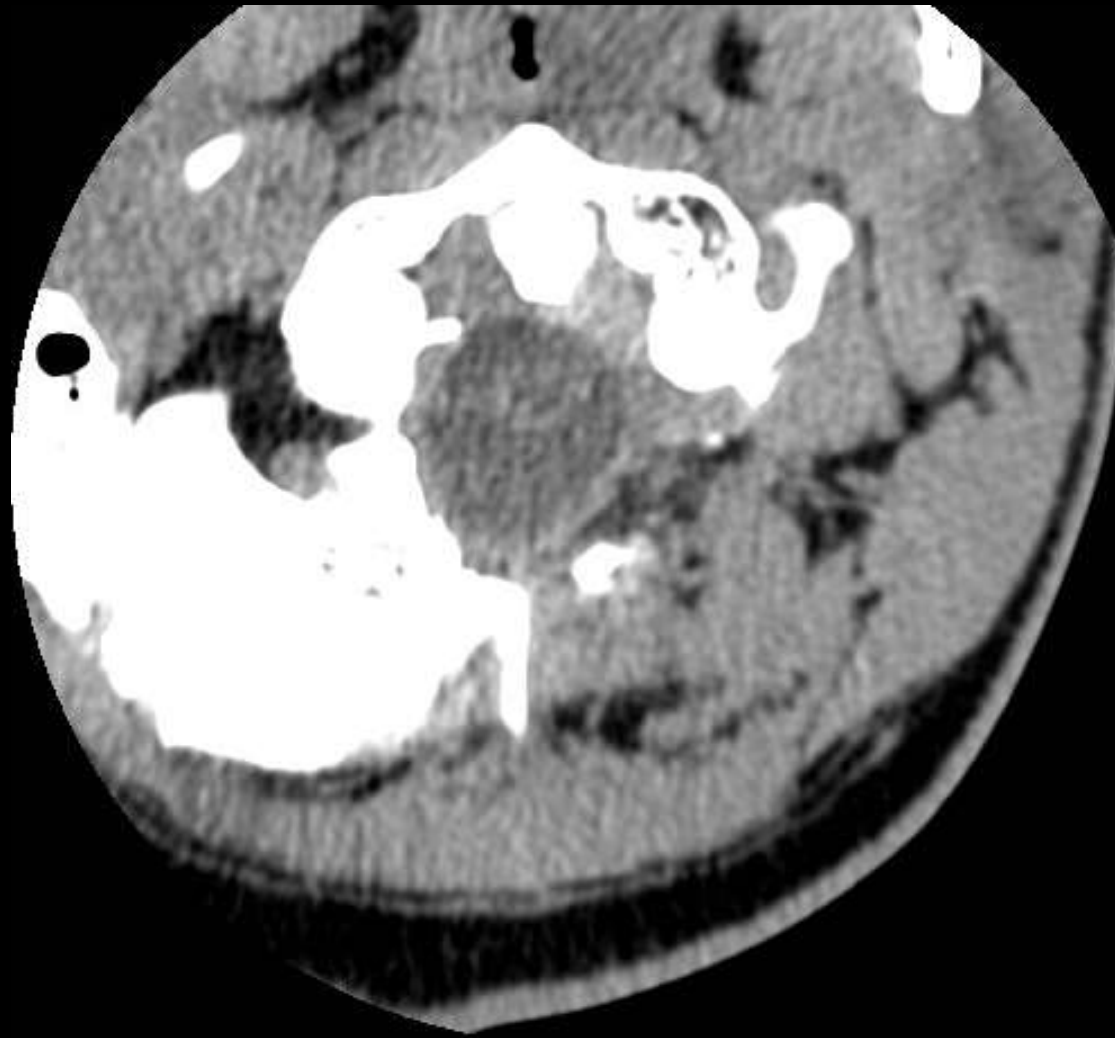
Syrinx



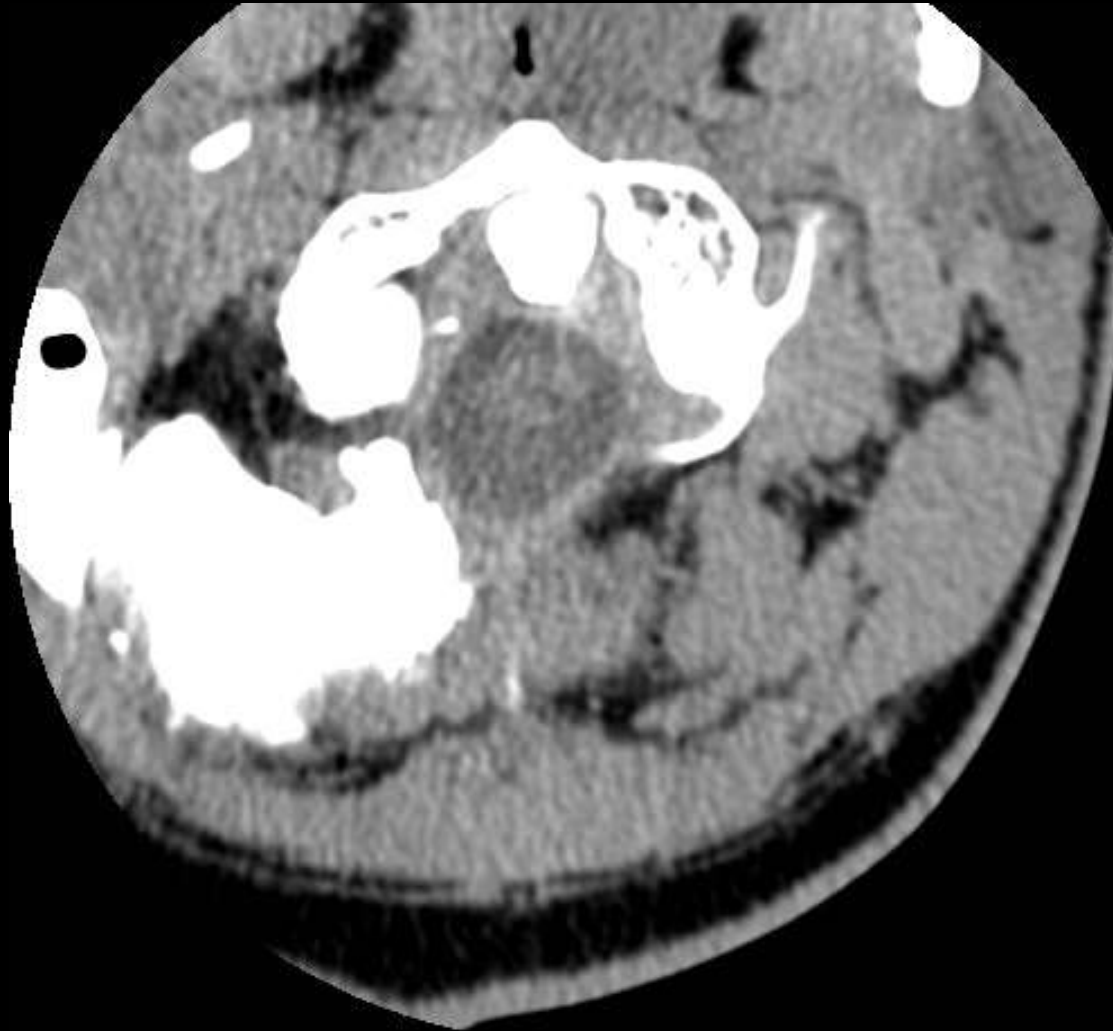
Syrinx



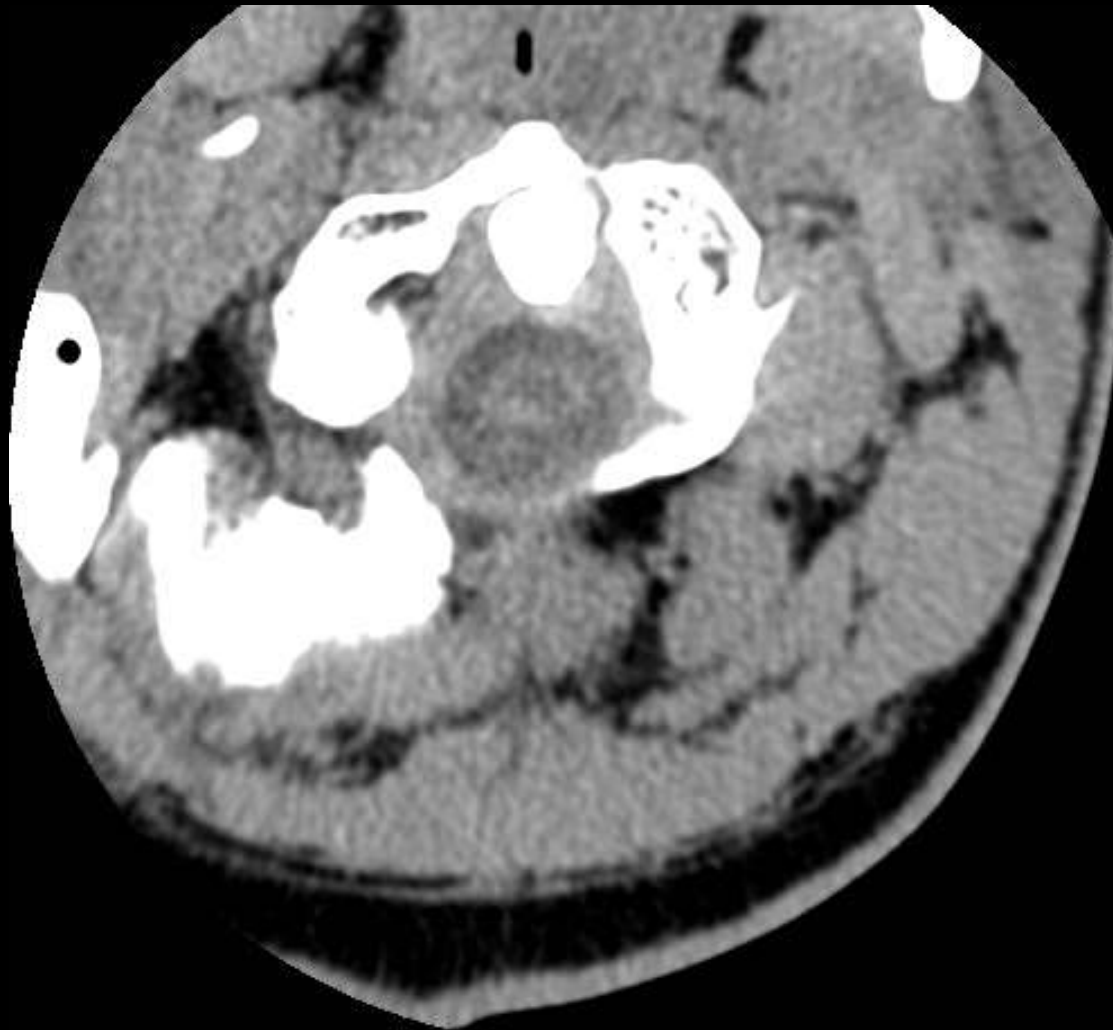
Syrinx



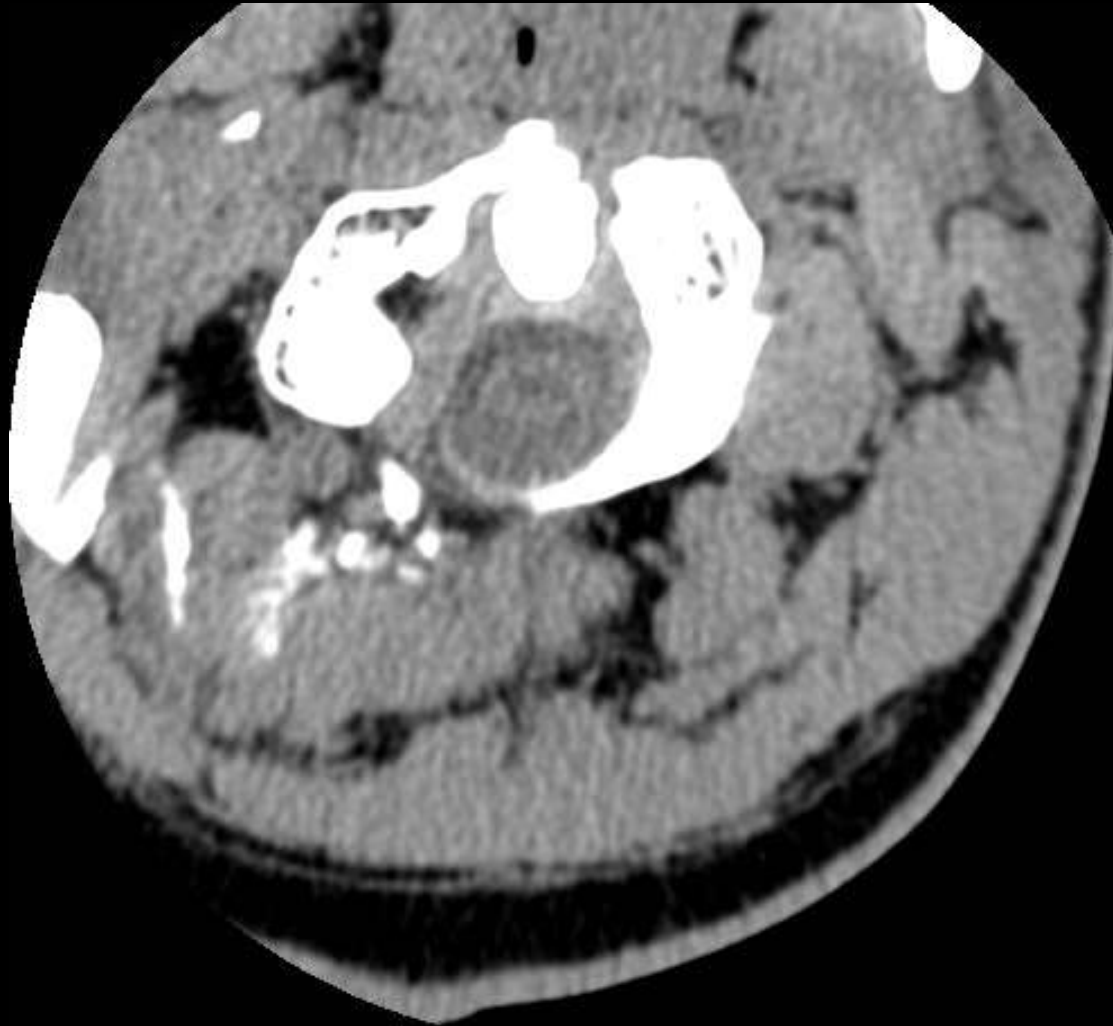
Syrinx



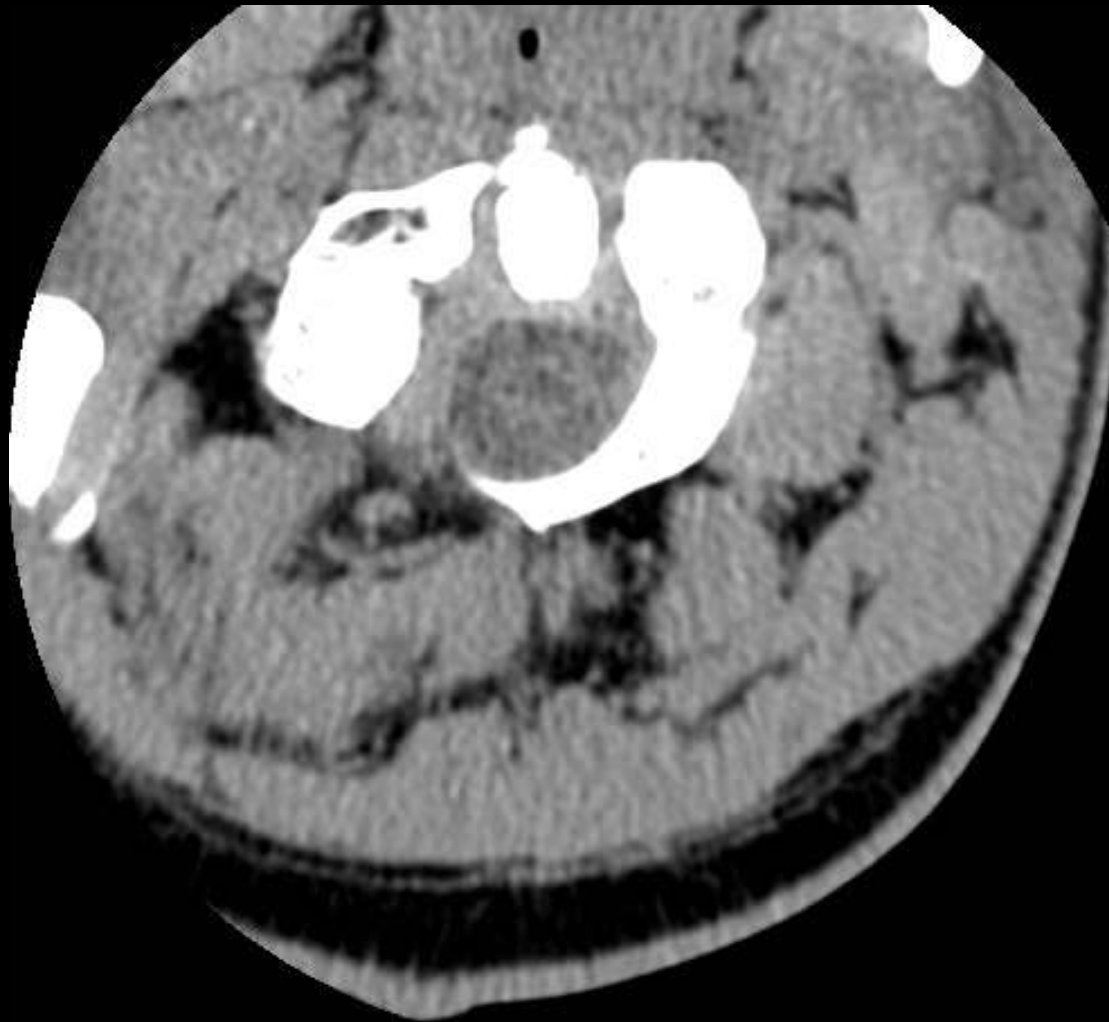Syrinx



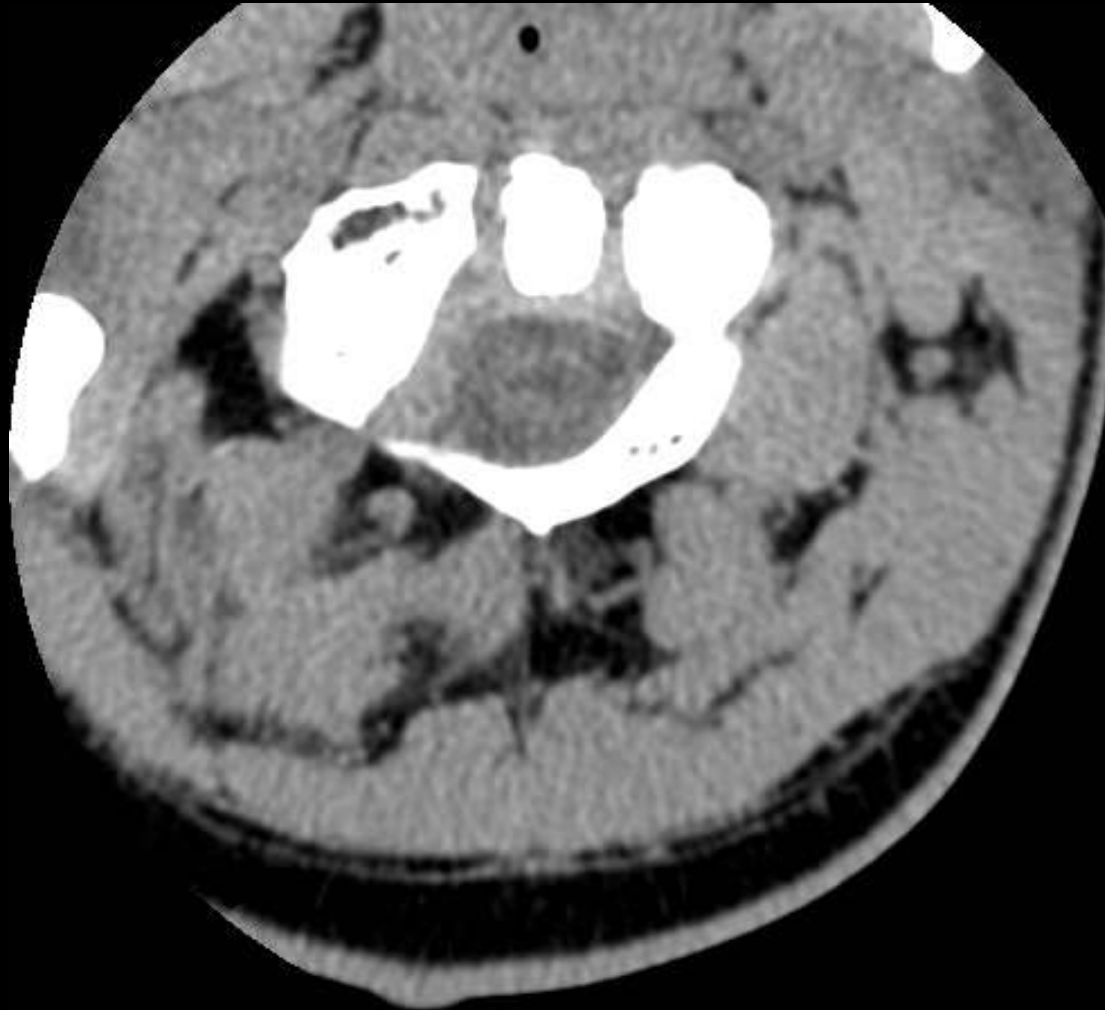Syrinx



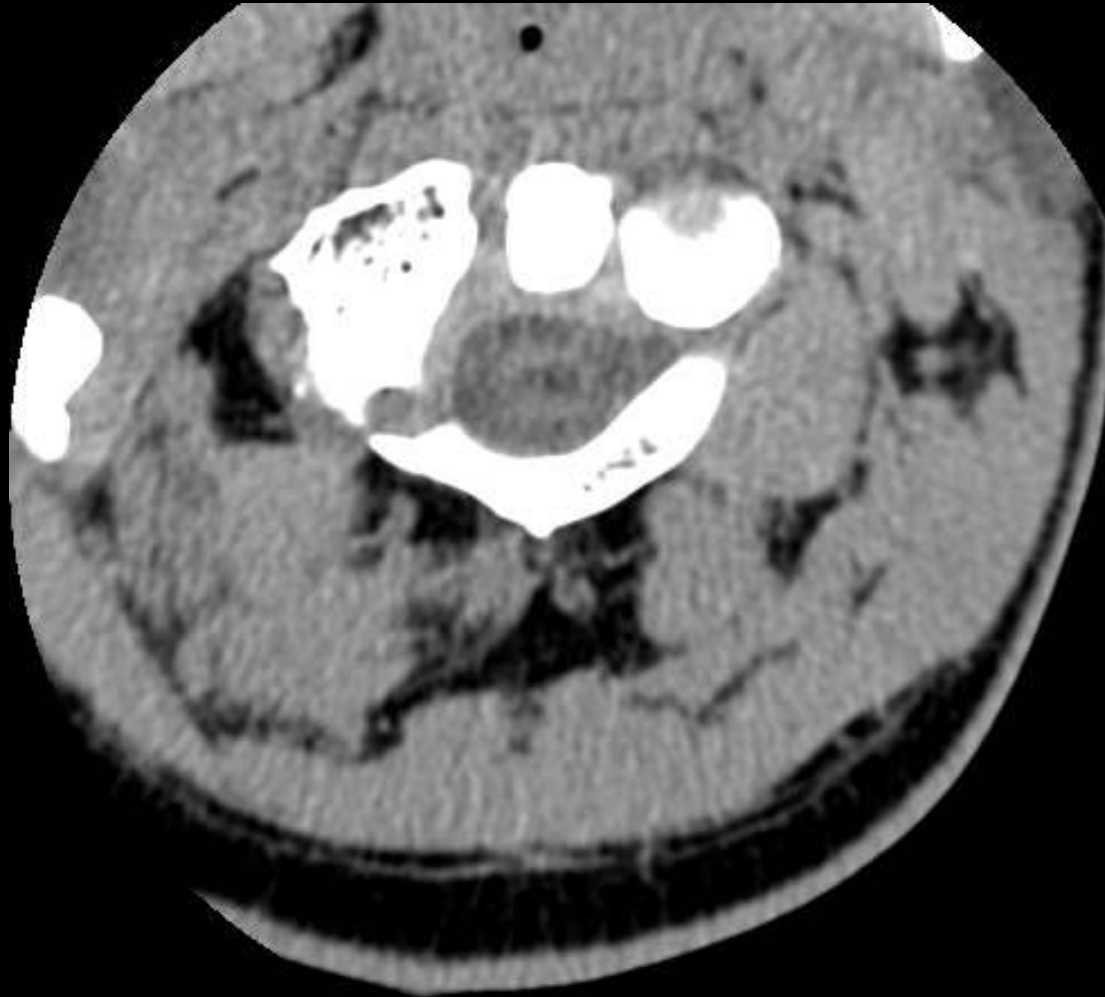Syrinx



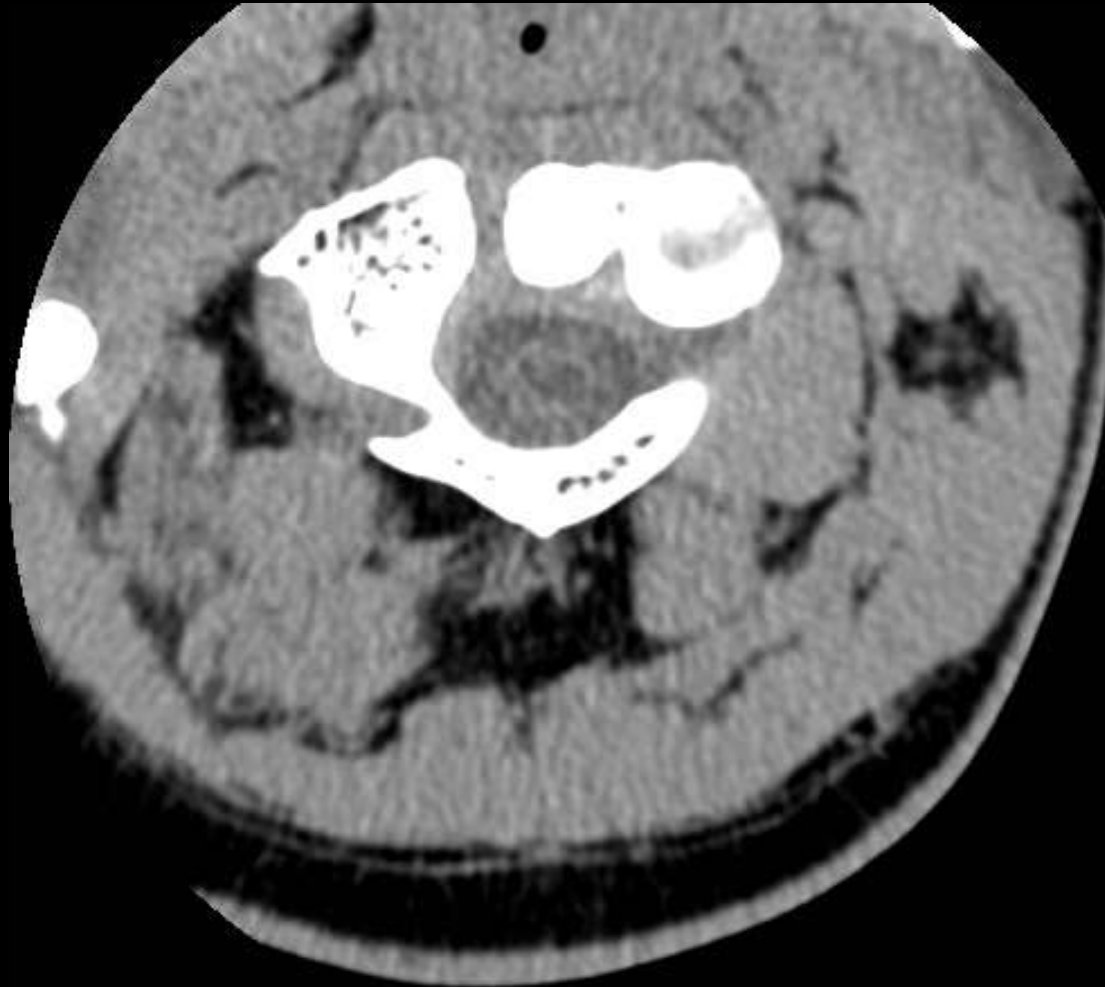
Syrinx



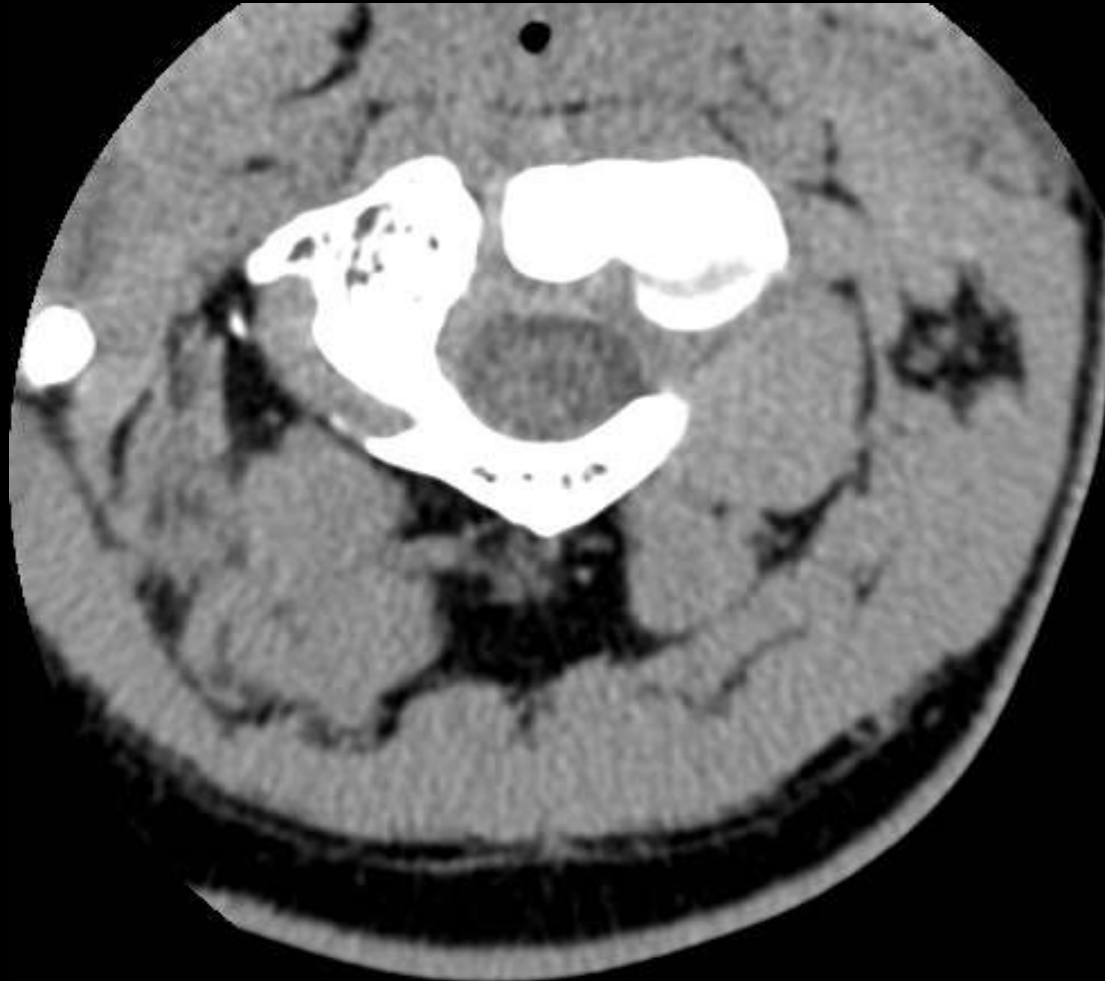Syrinx



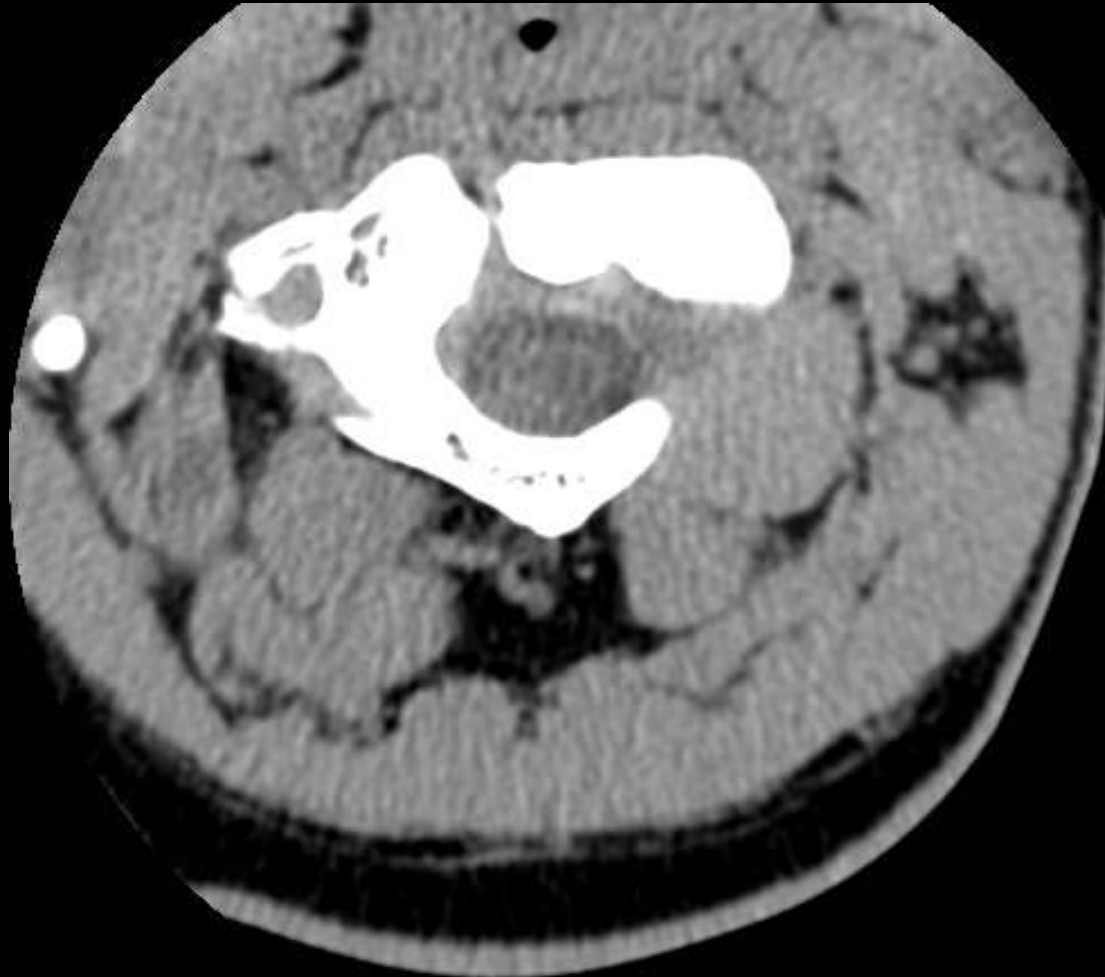Syrinx



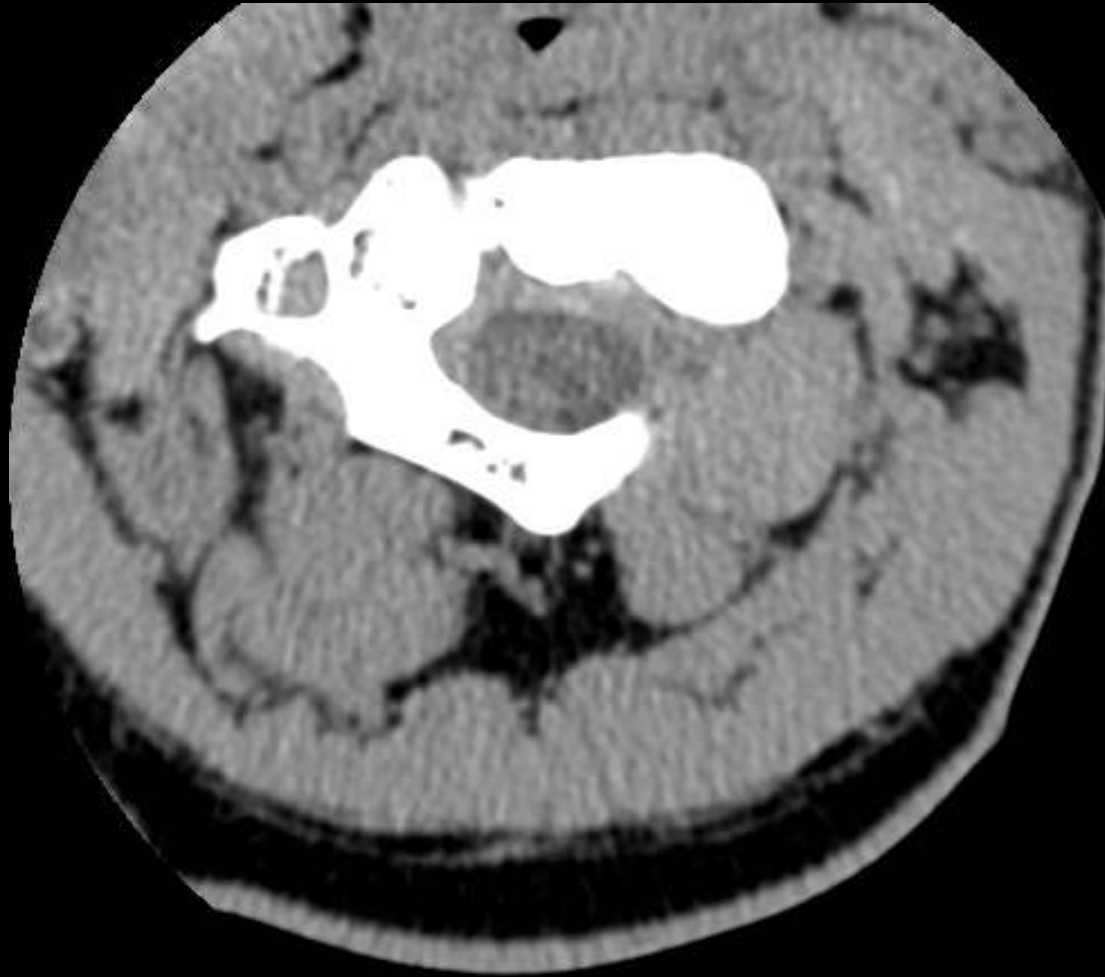Syrinx



Syrinx

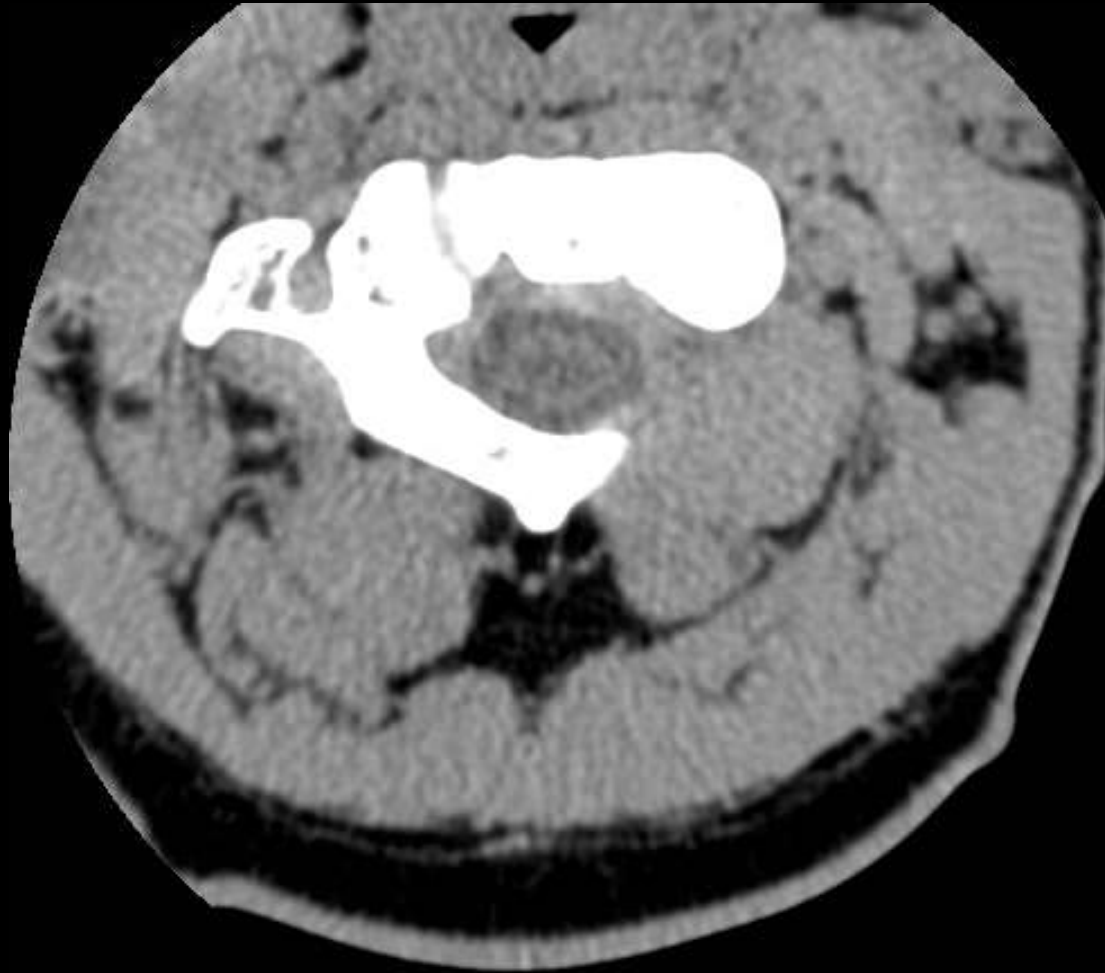

Syrinx



Reading Algorithm - Soft Tissues

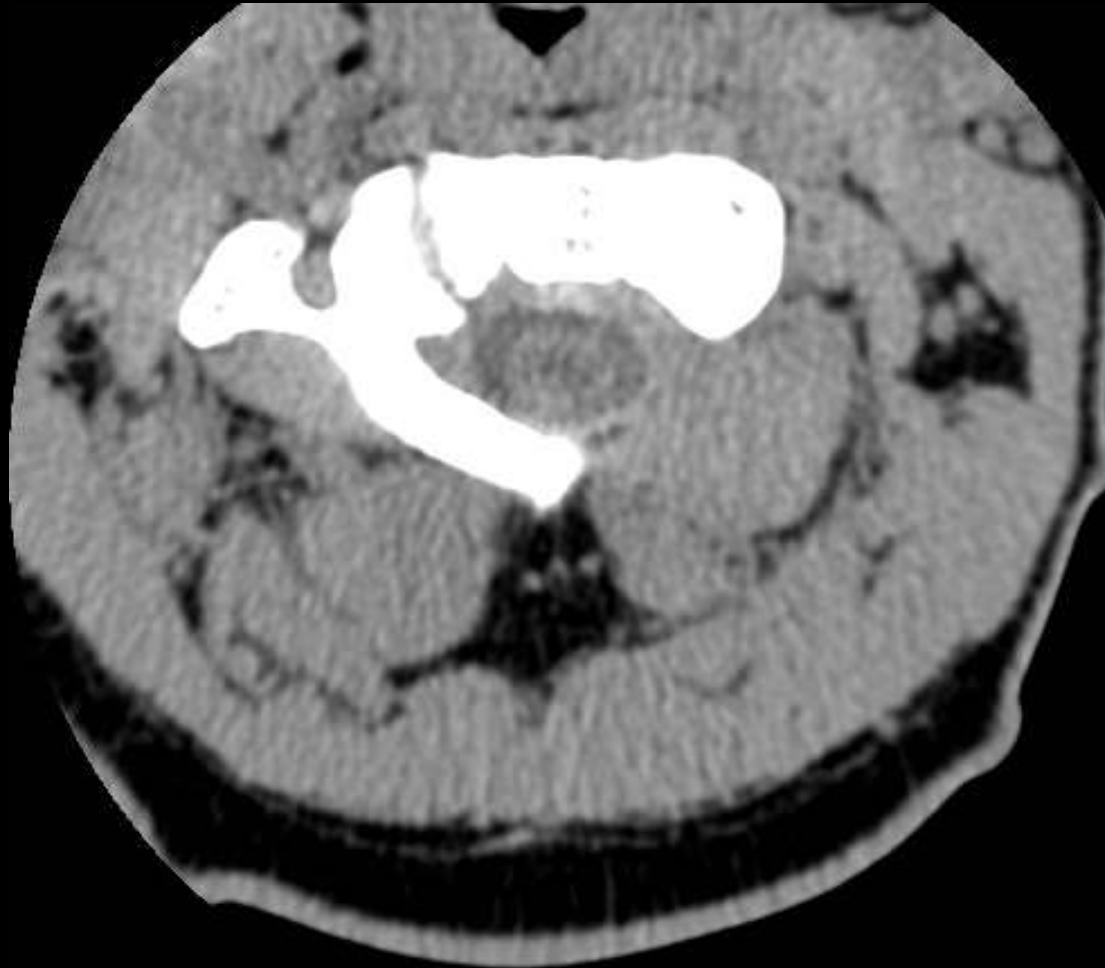Syrinx



Syrinx on CT 51M multiple falls

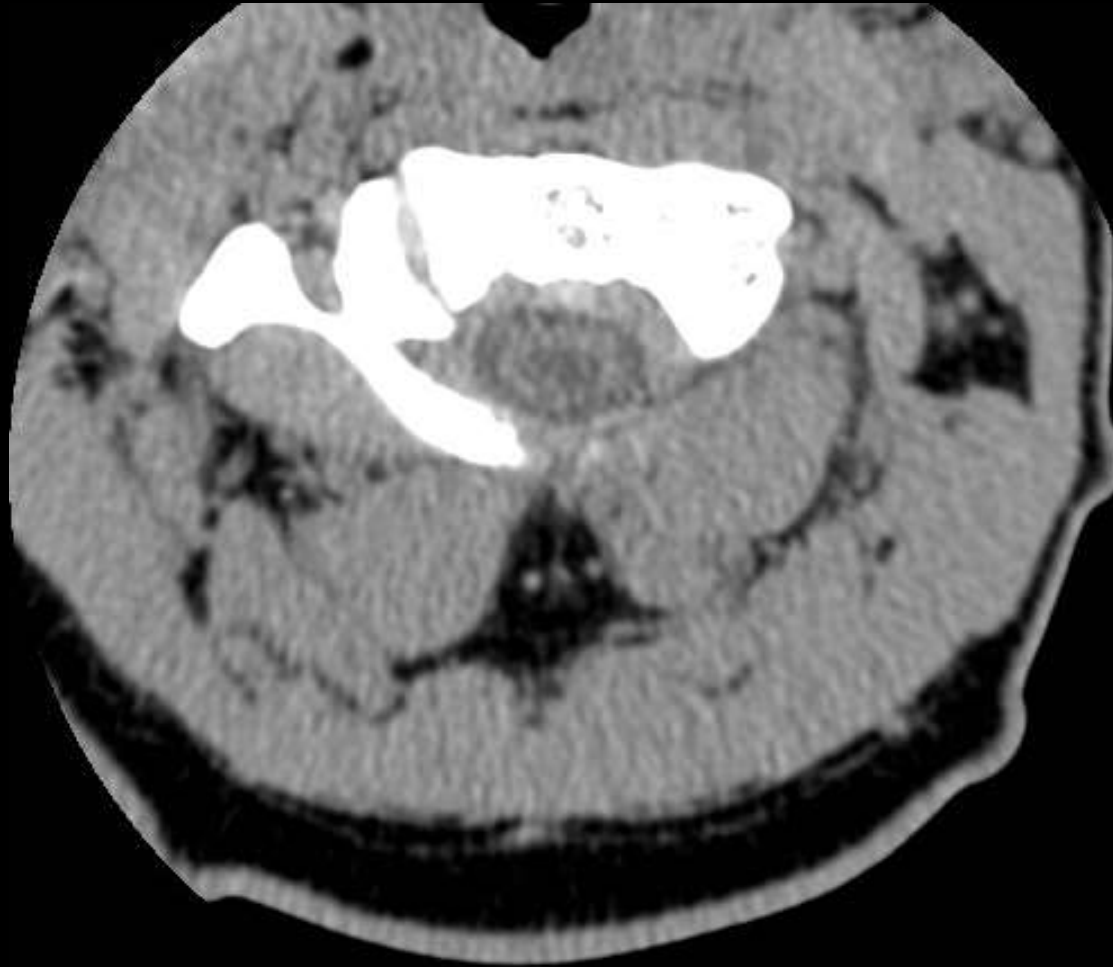Reading Algorithm - Soft Tissues

Syrinx

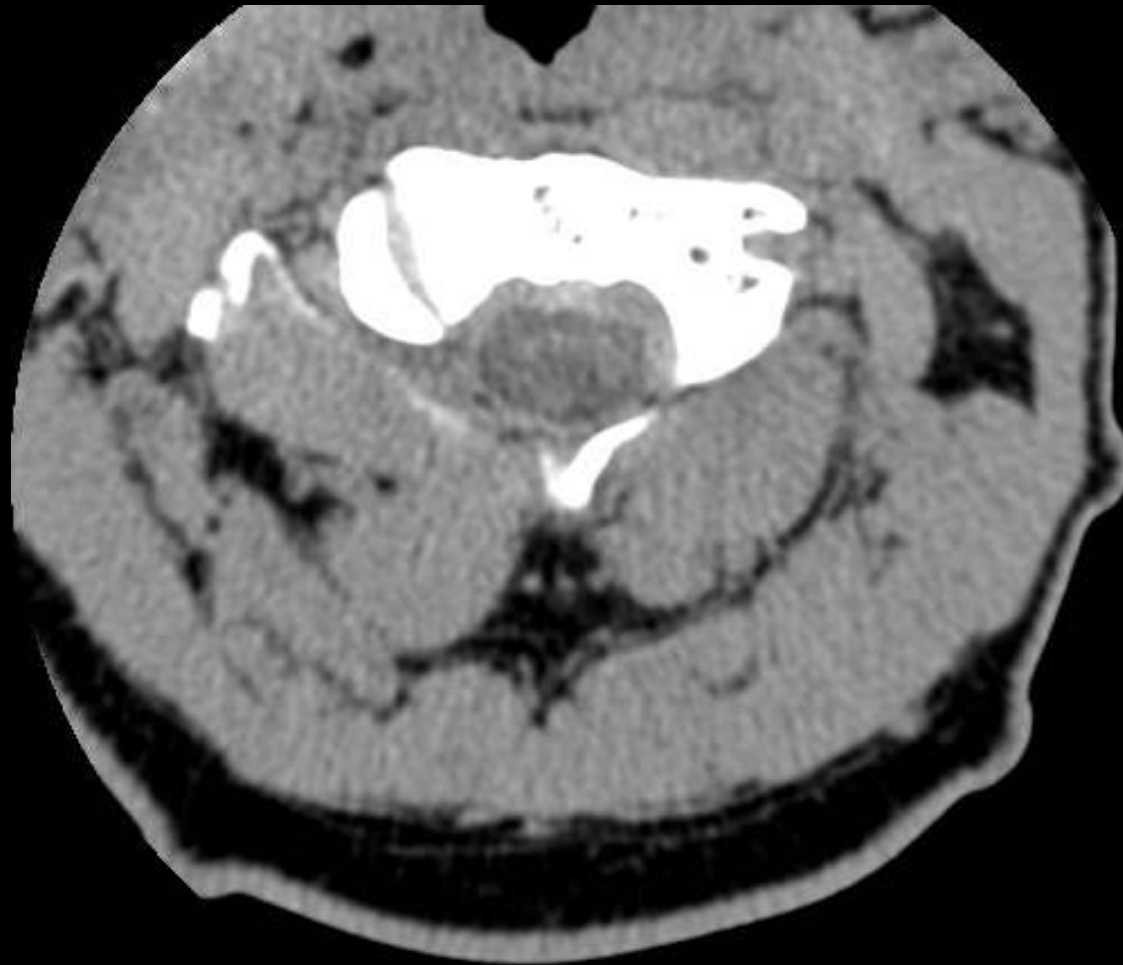

Syrinx on CT 51M multiple falls

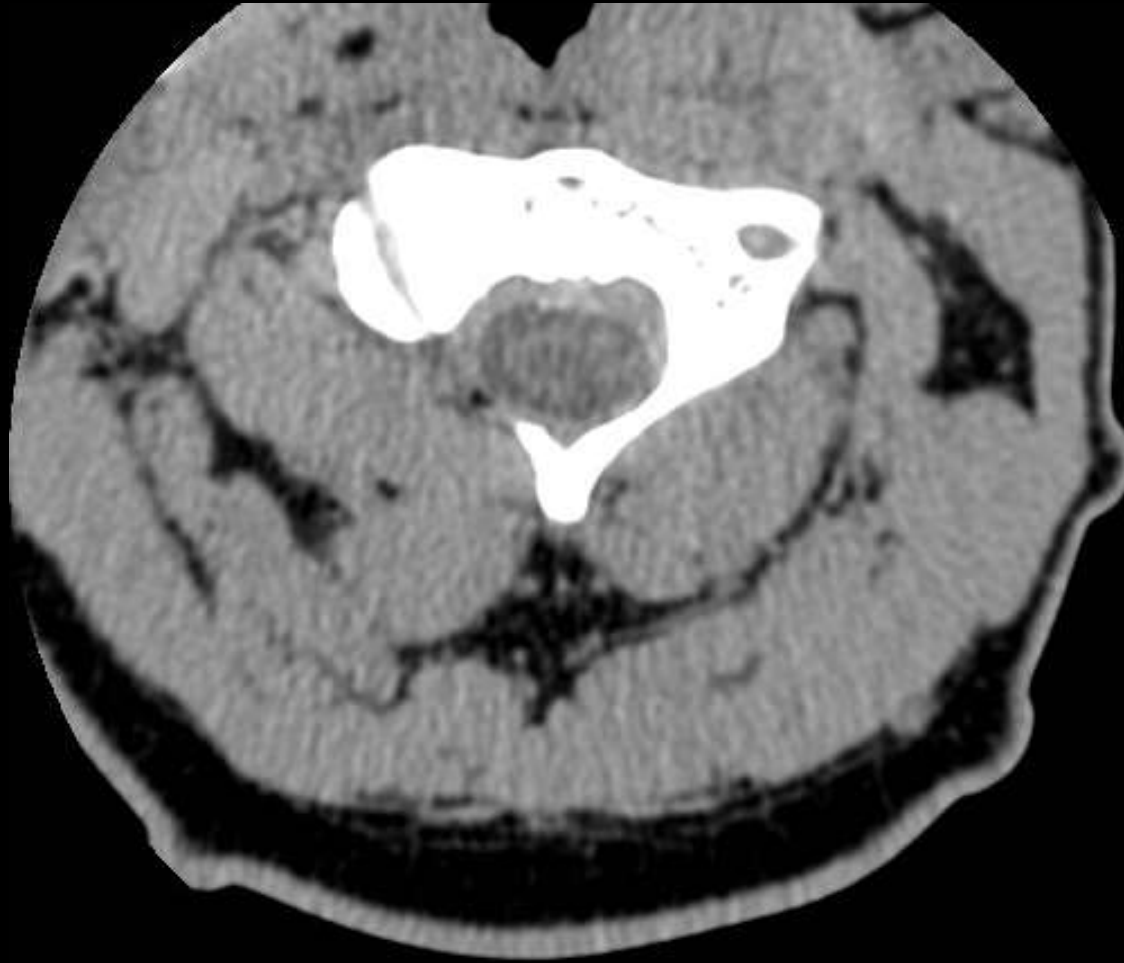Syrinx



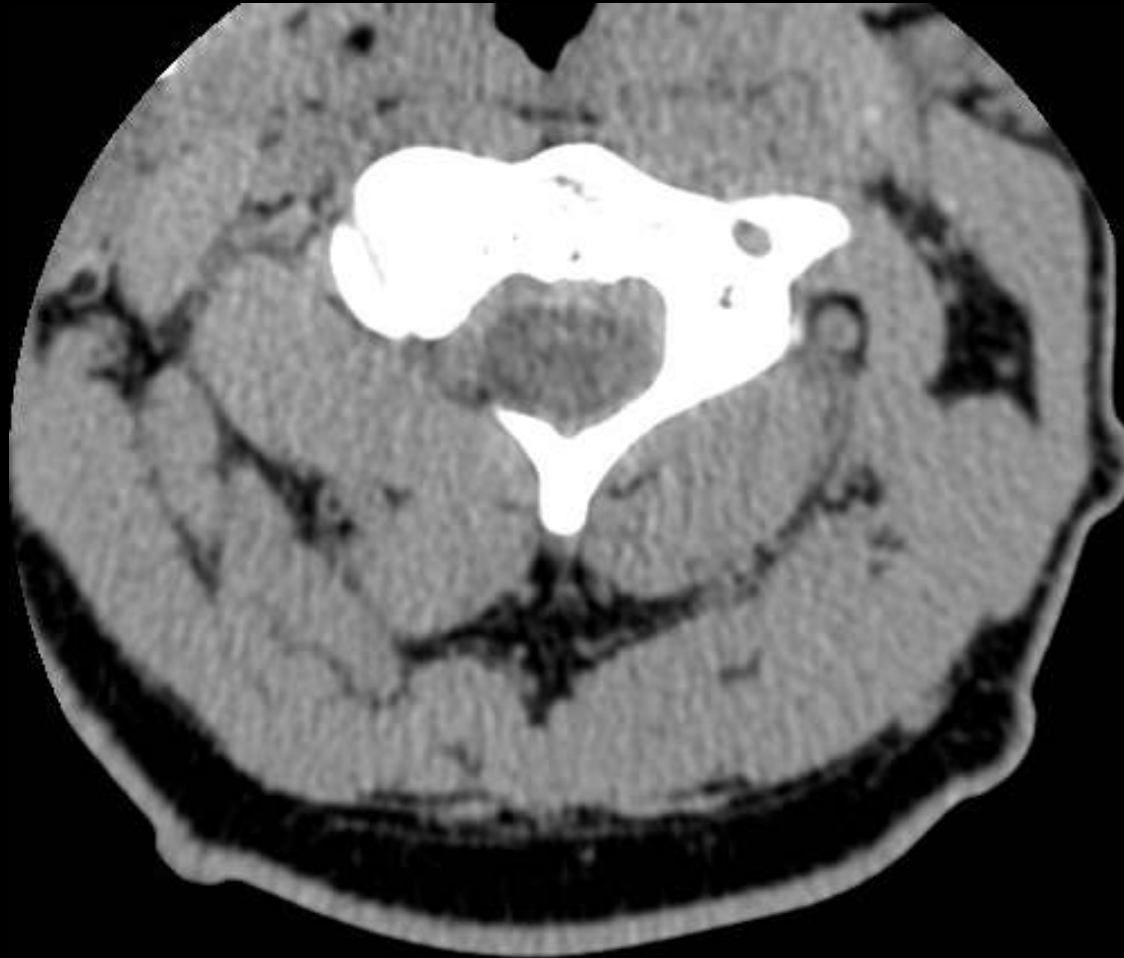
Syrinx



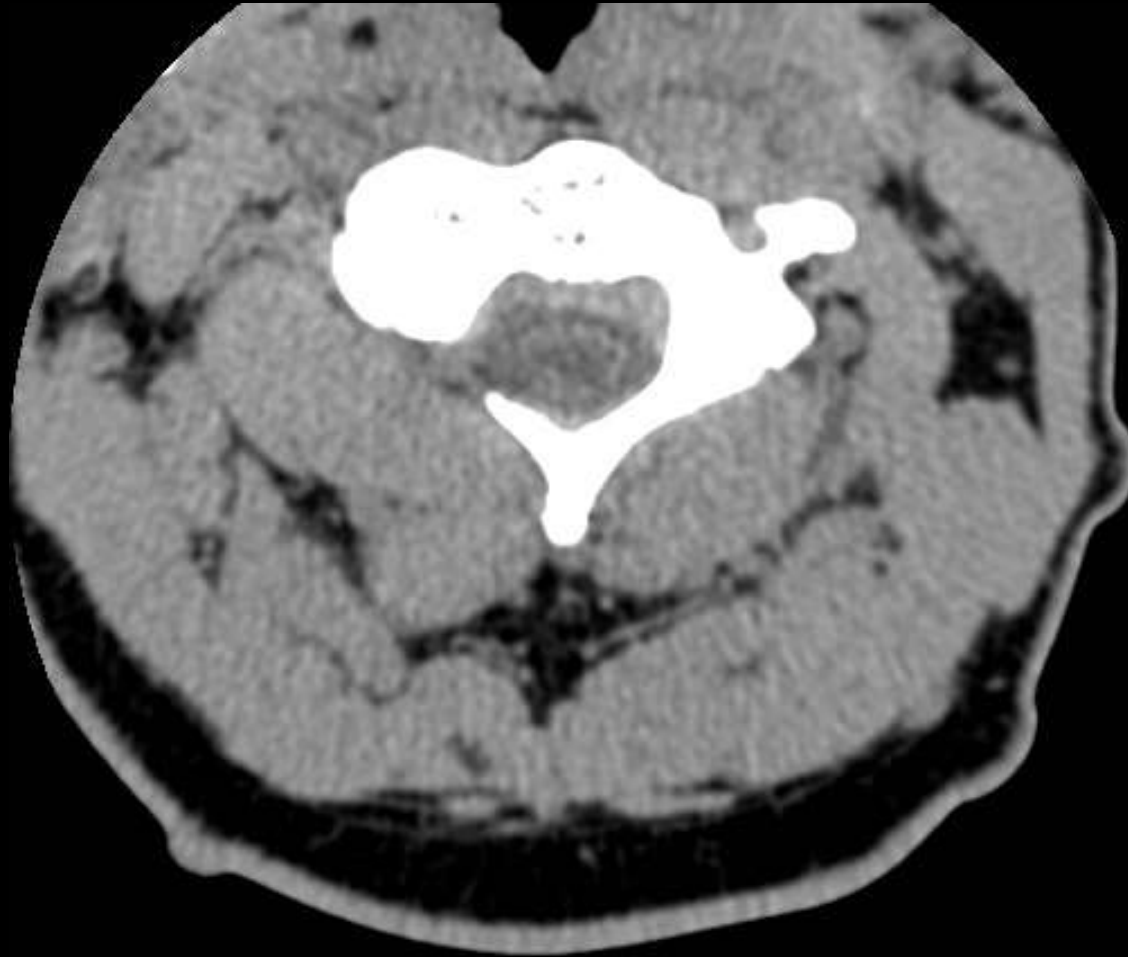
Syrinx



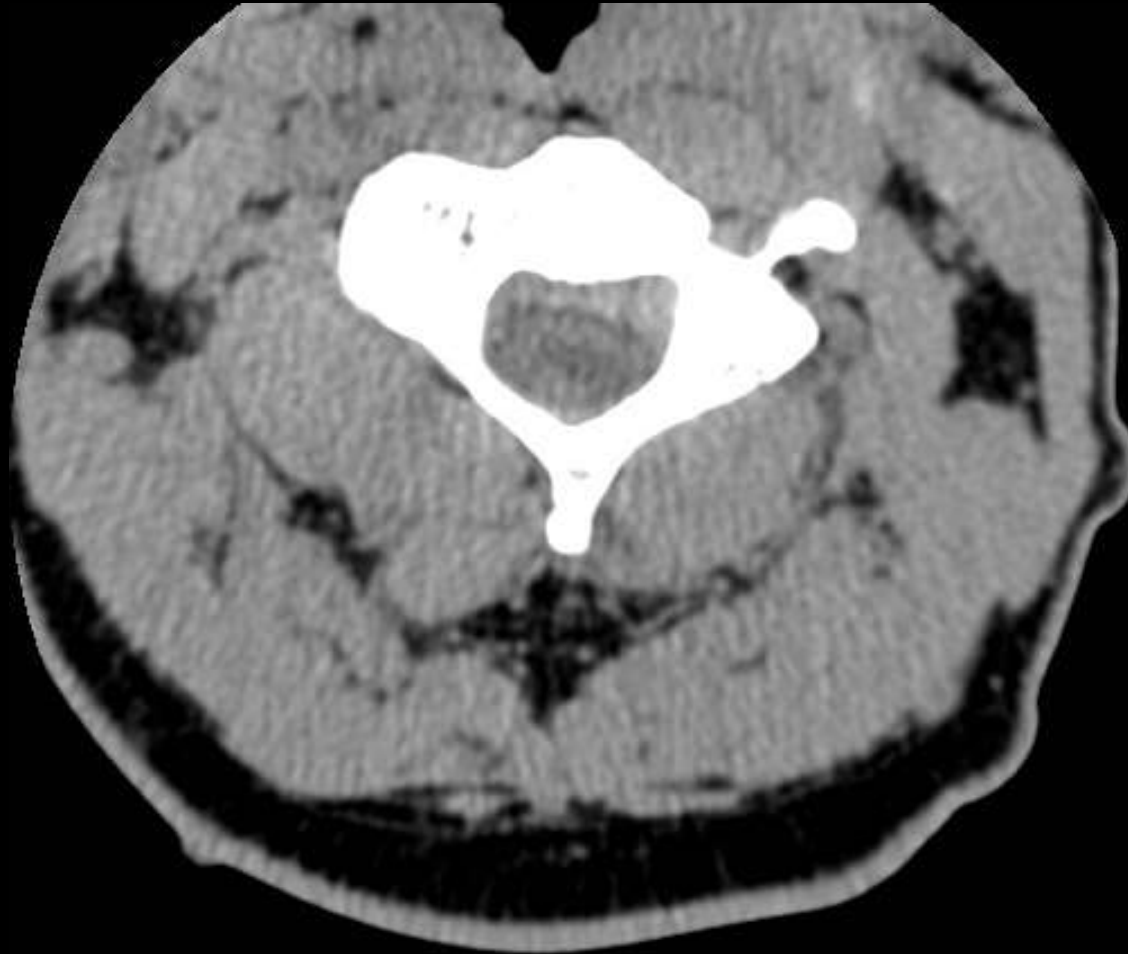
Syrinx



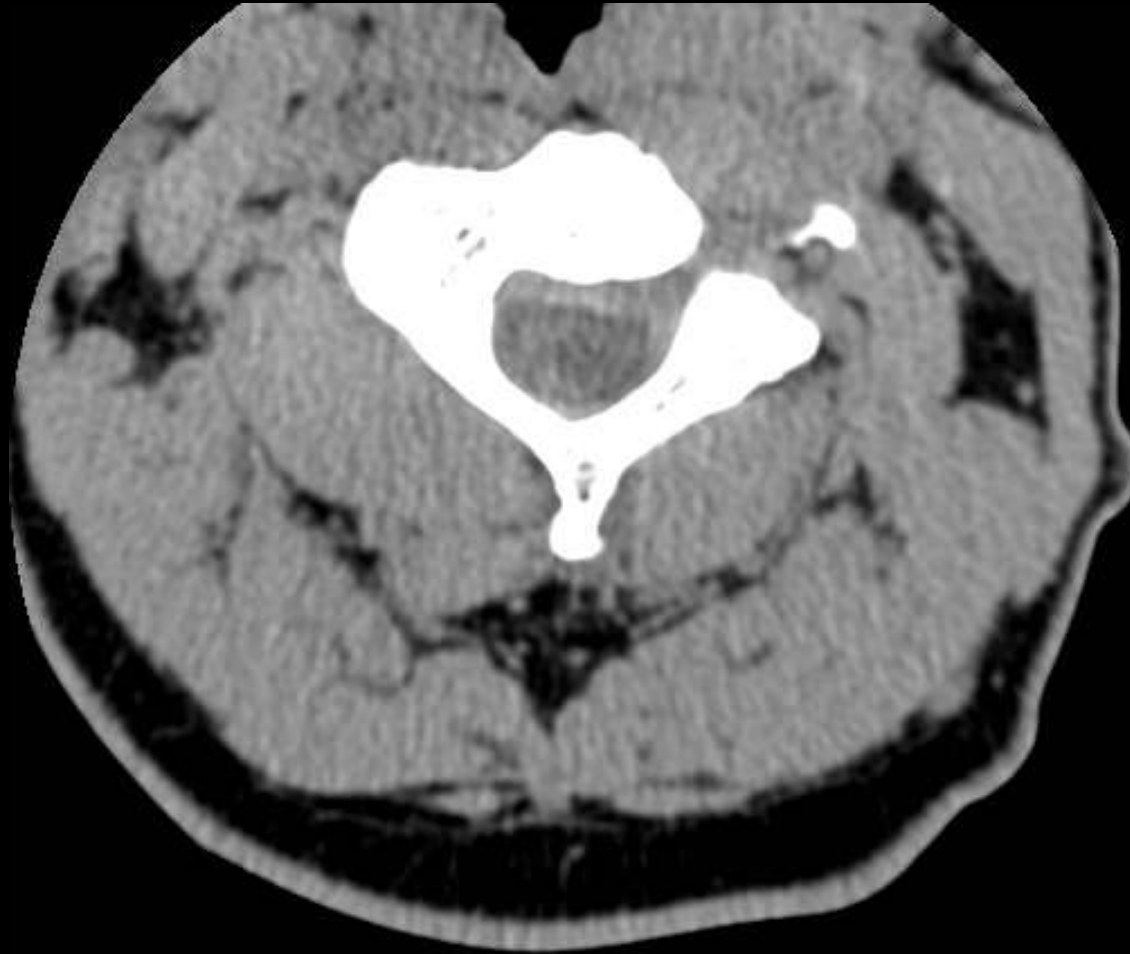Syrinx



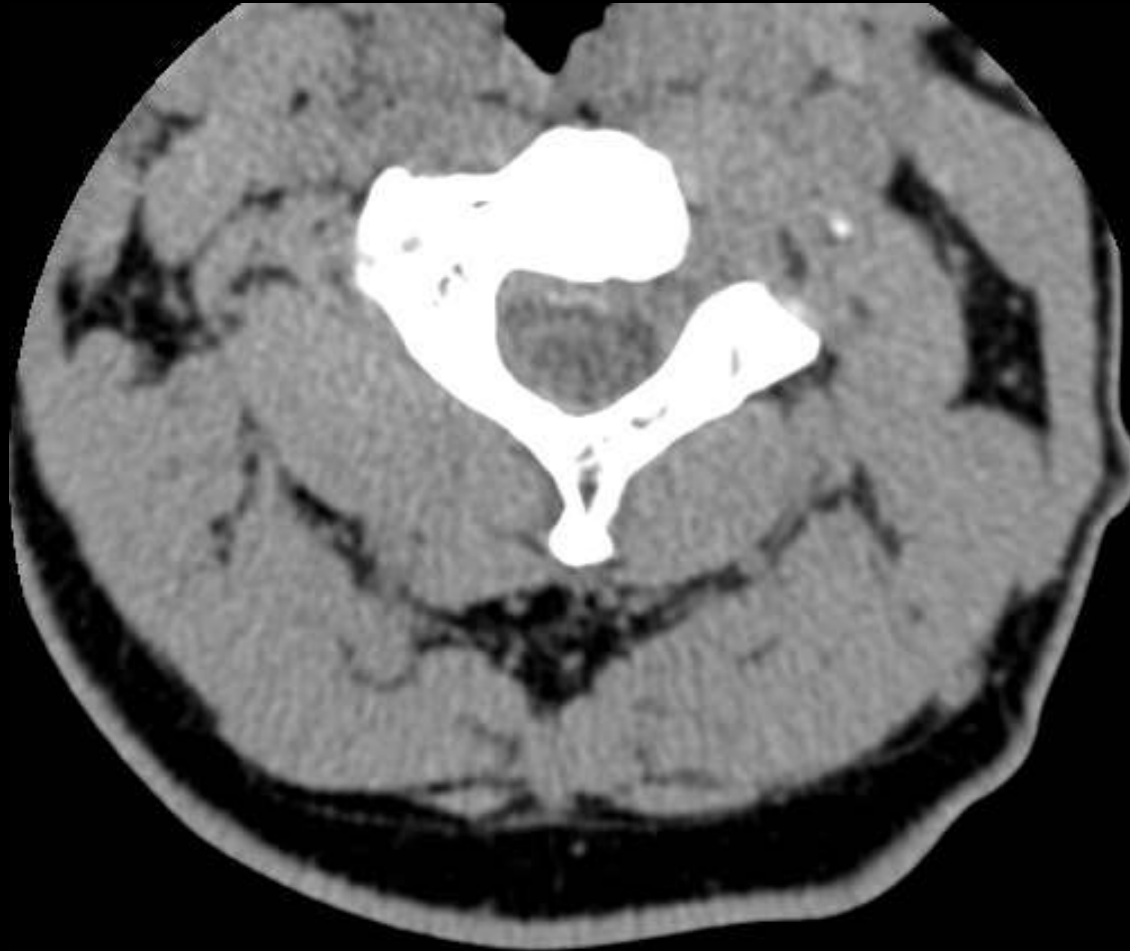Syrinx



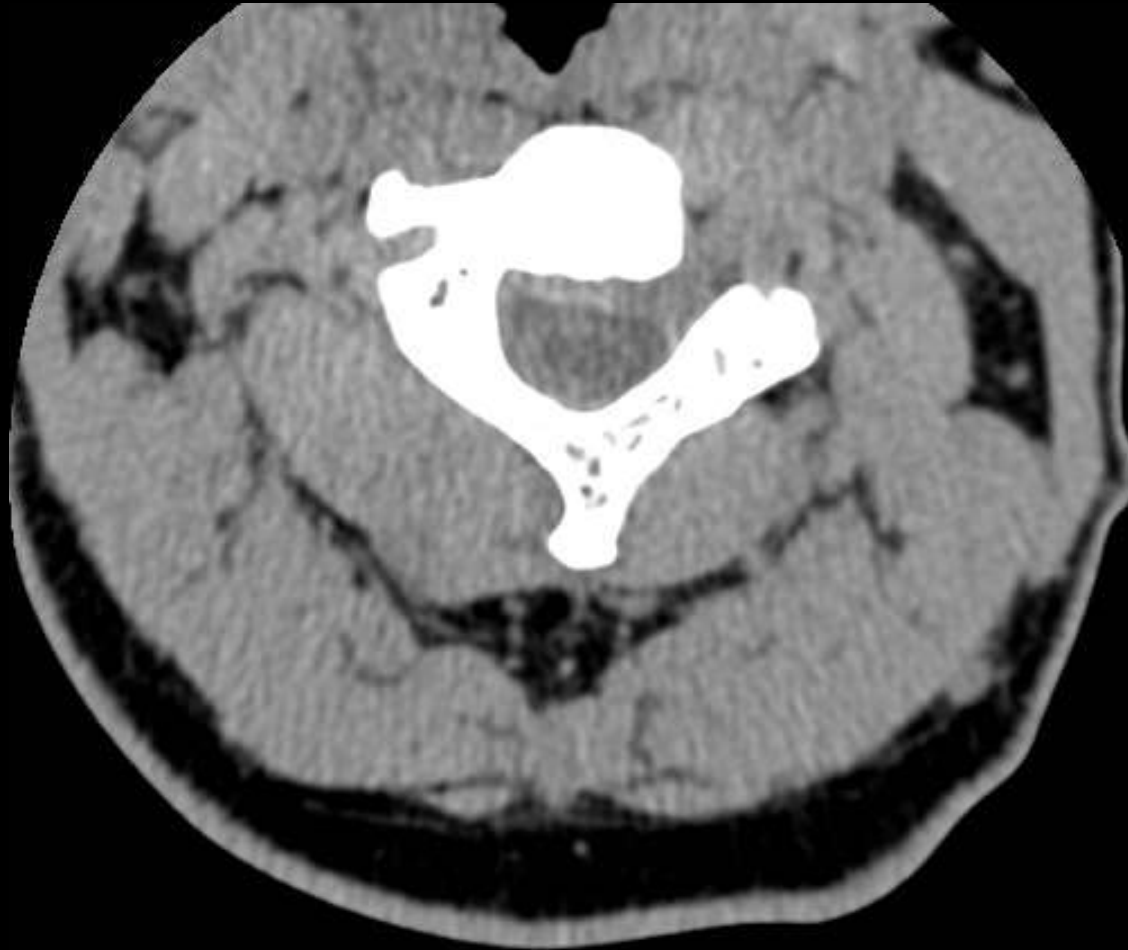Syrinx



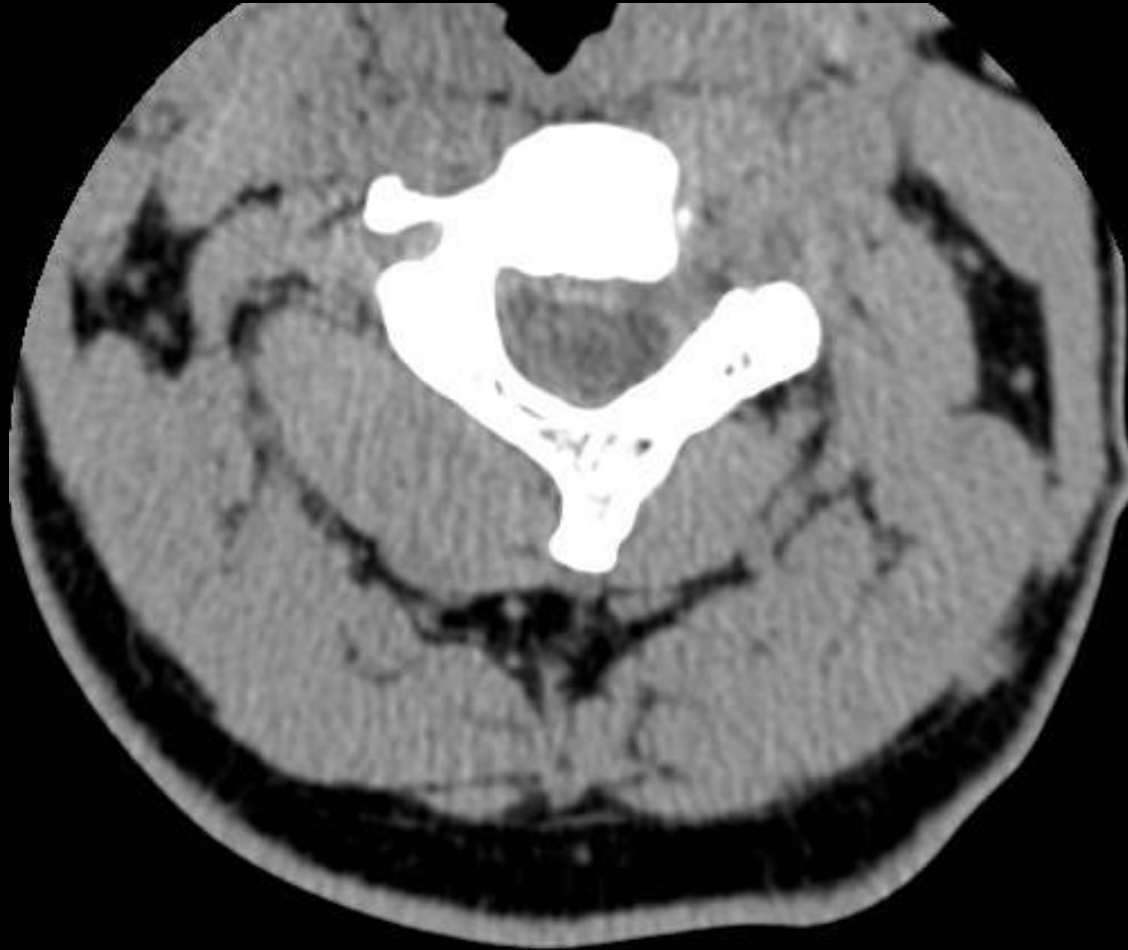Syrinx



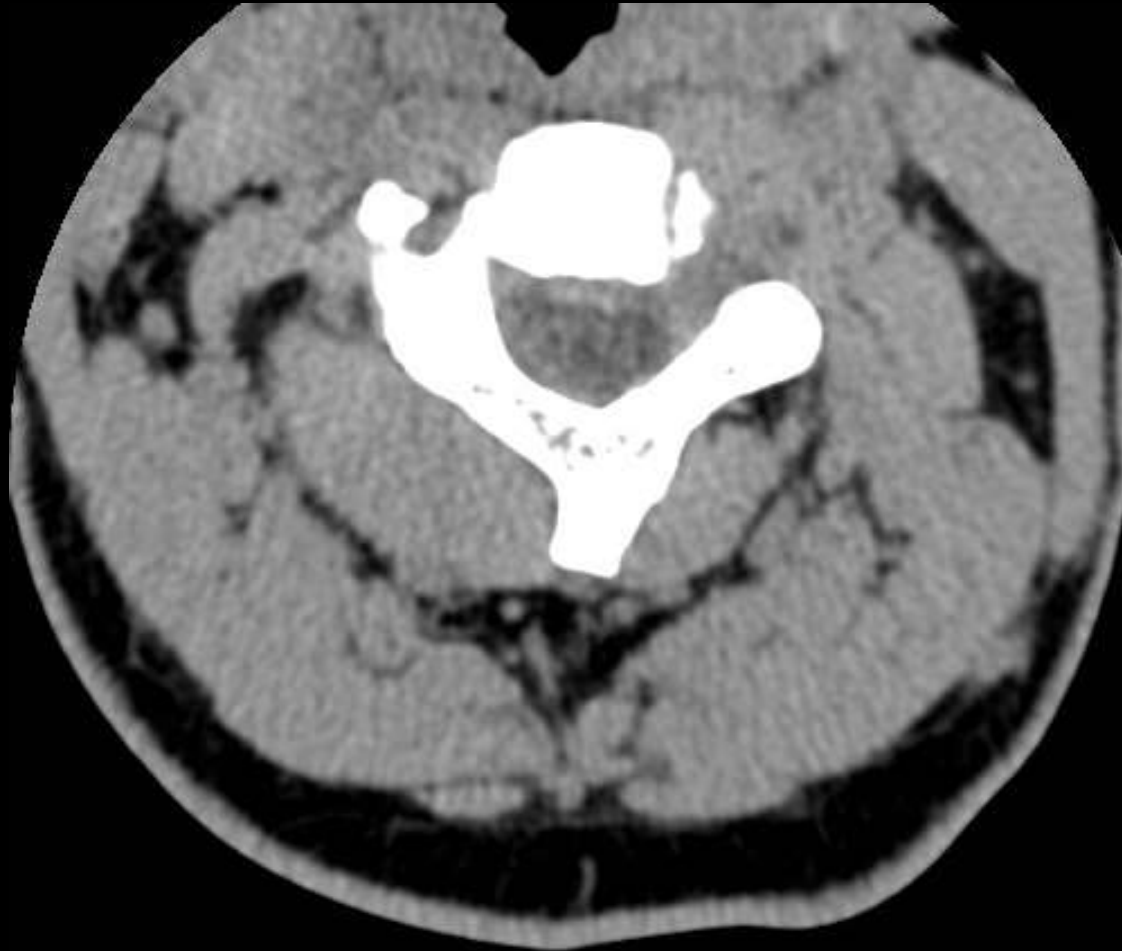Syrinx



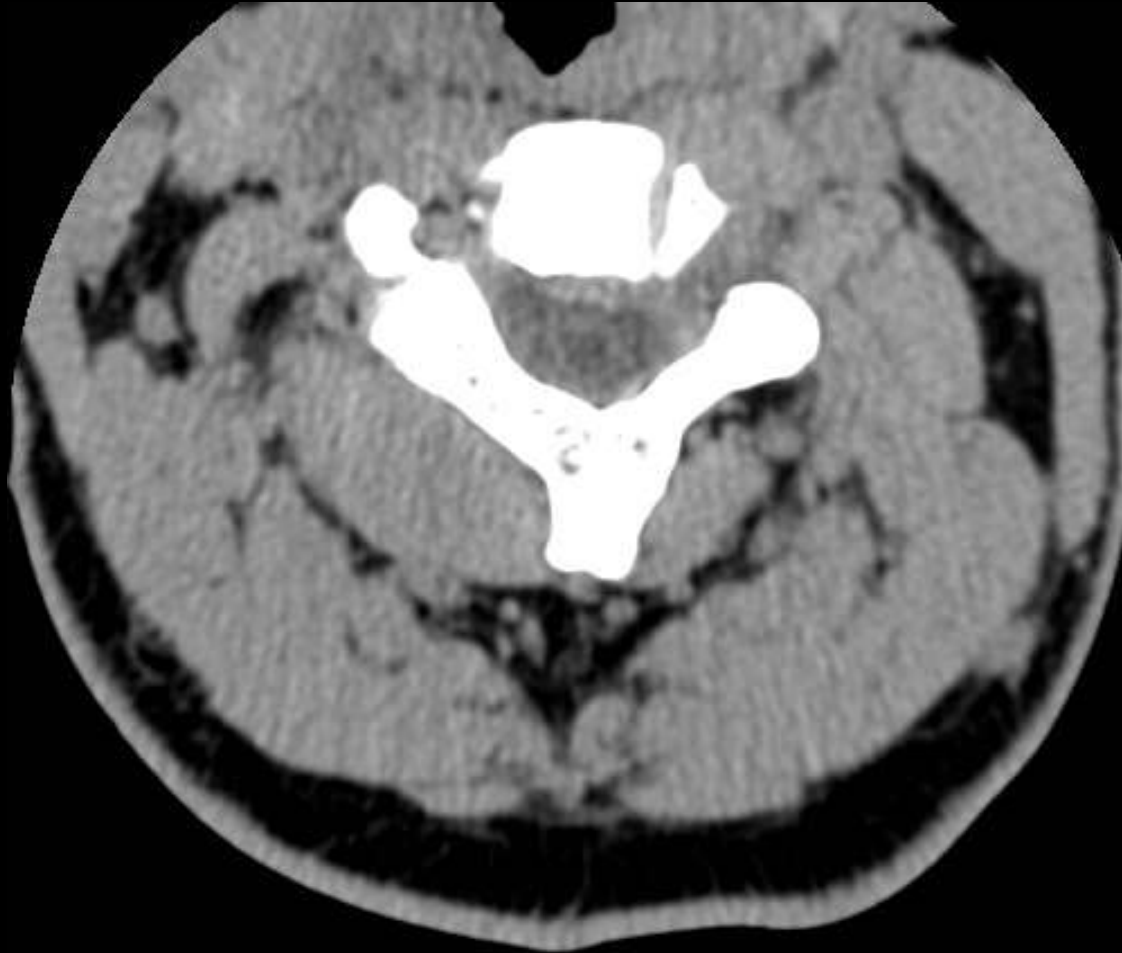Syrinx



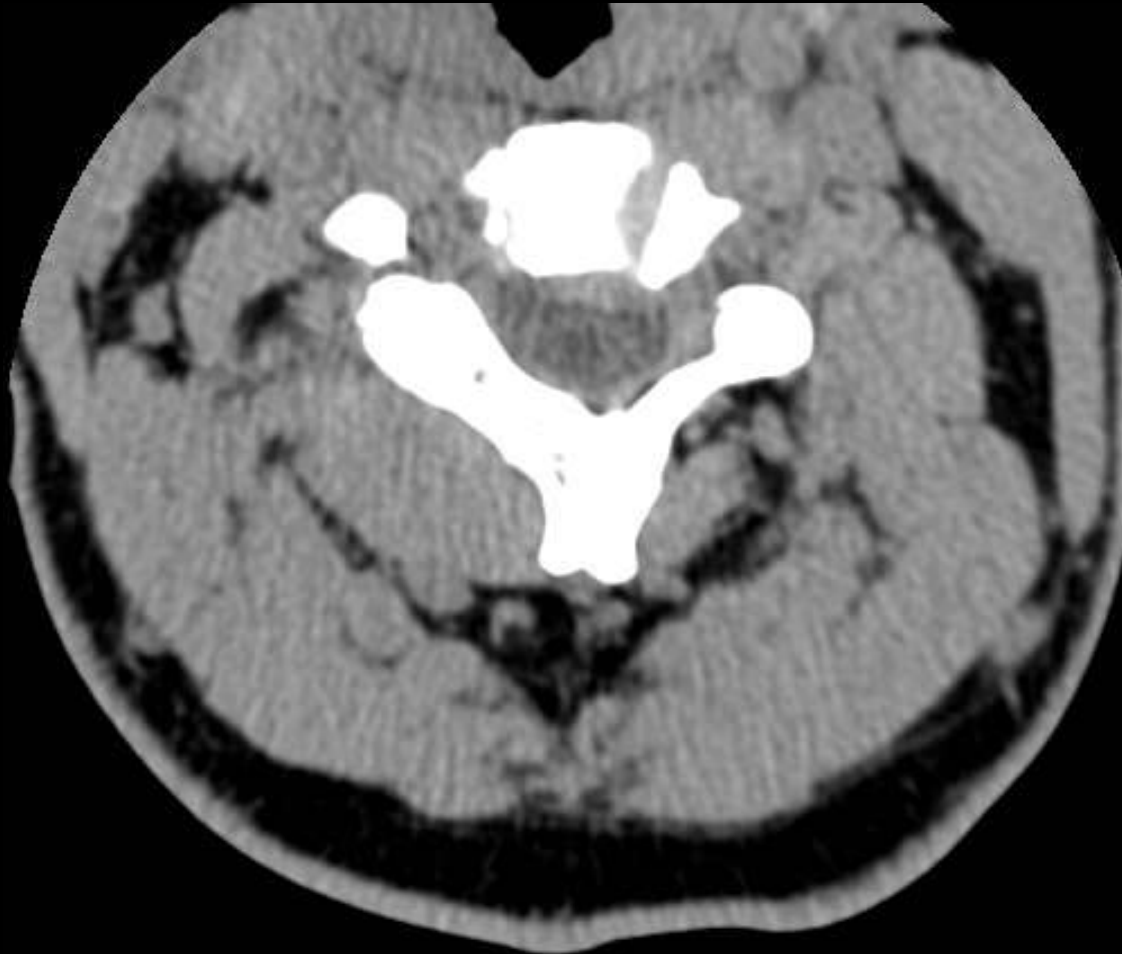Syrinx



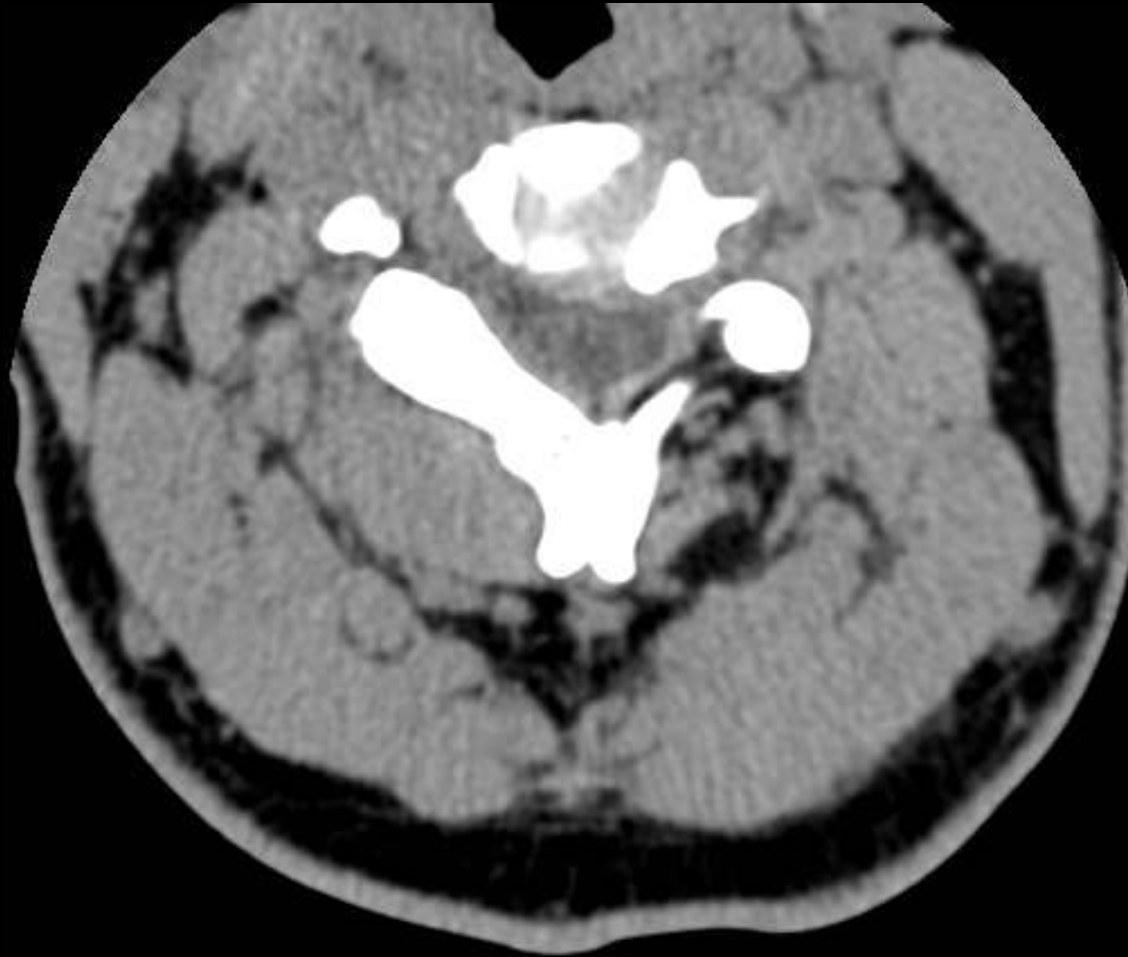Syrinx



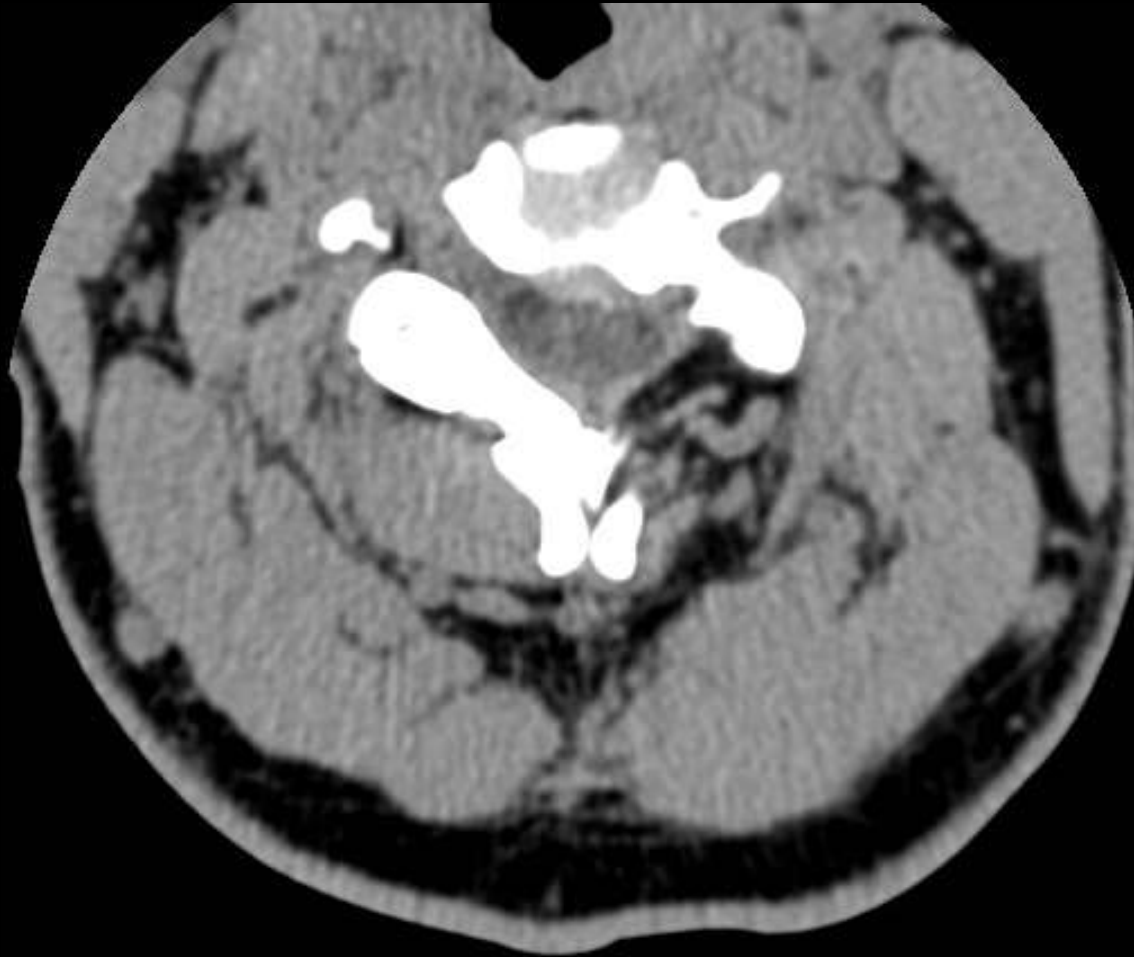Syrinx



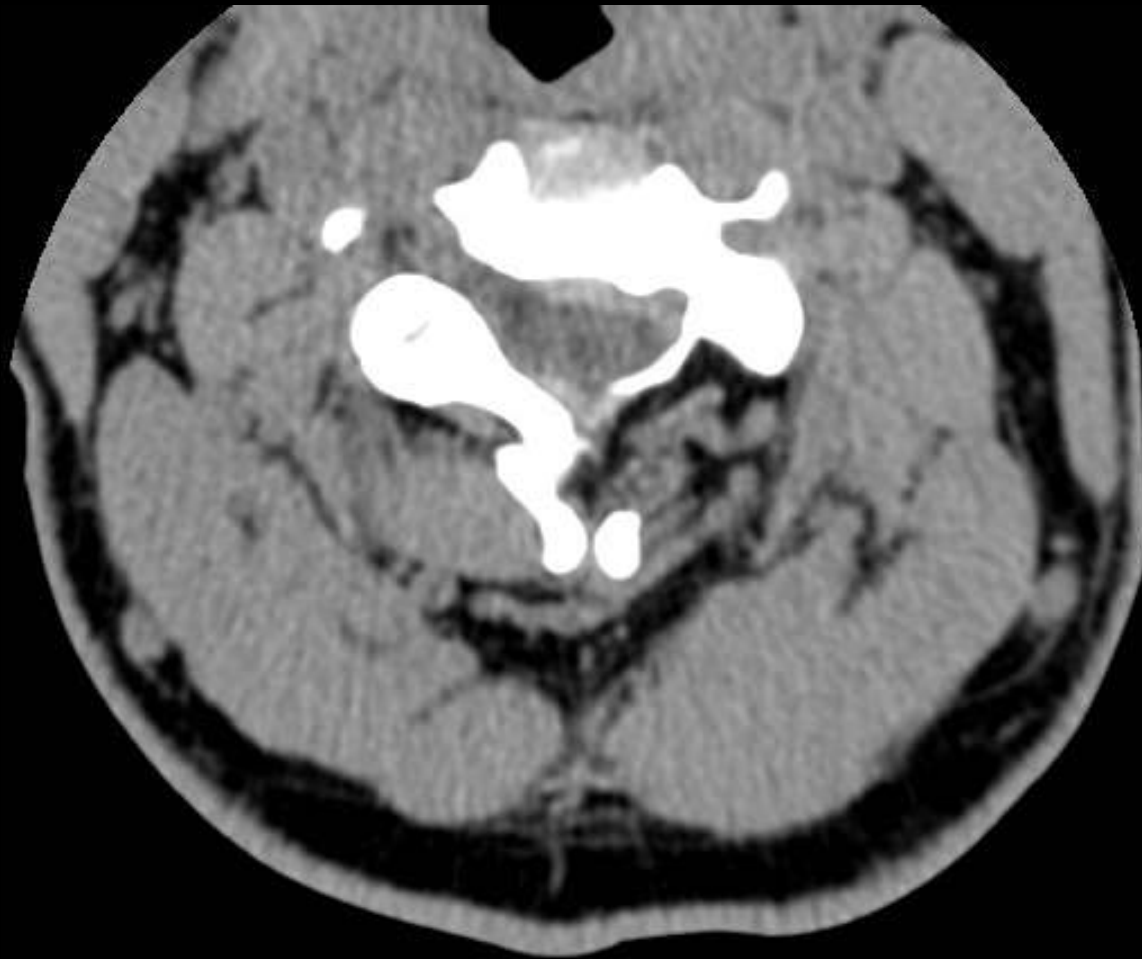Syrinx



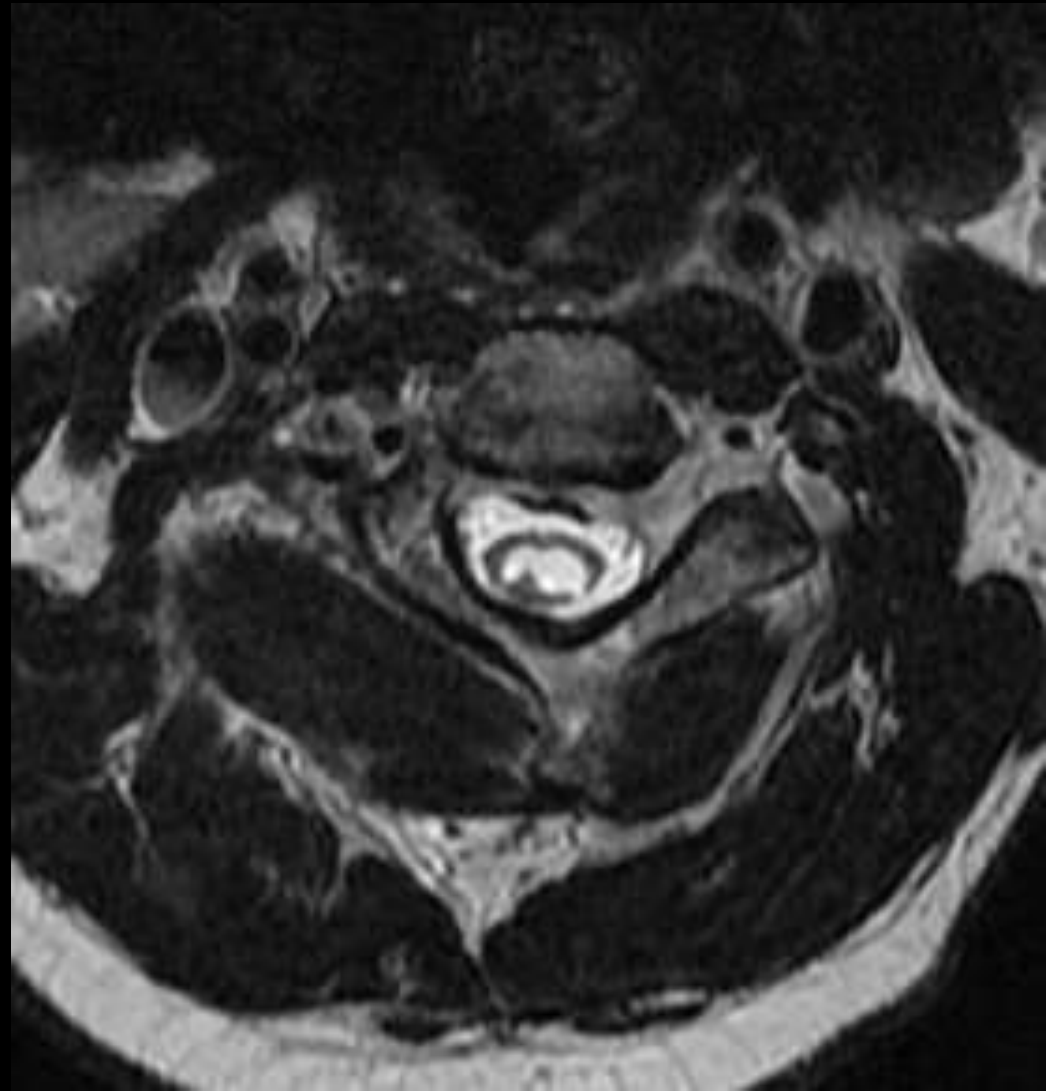
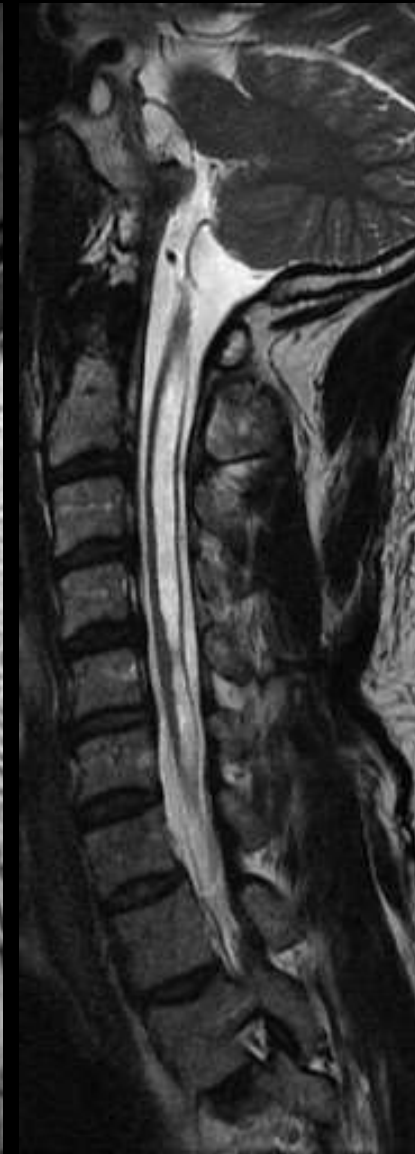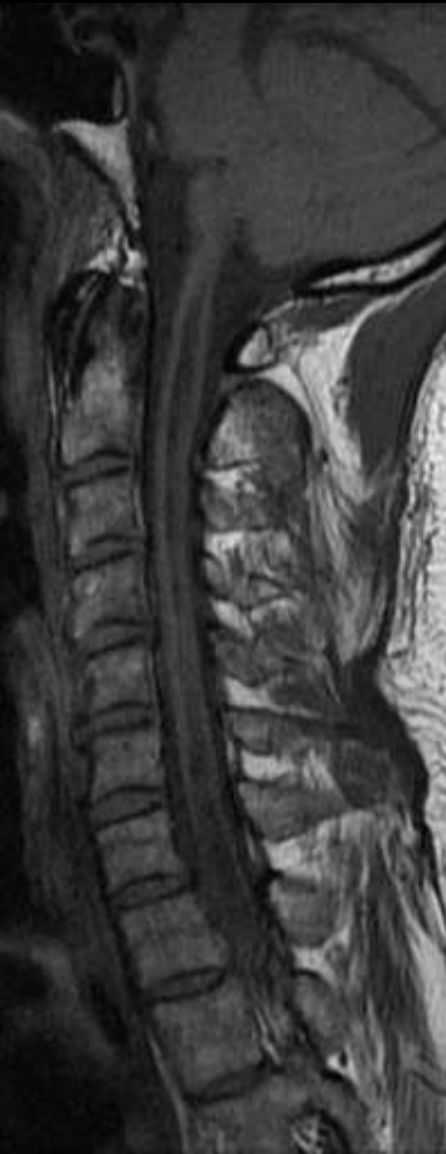Syrinx



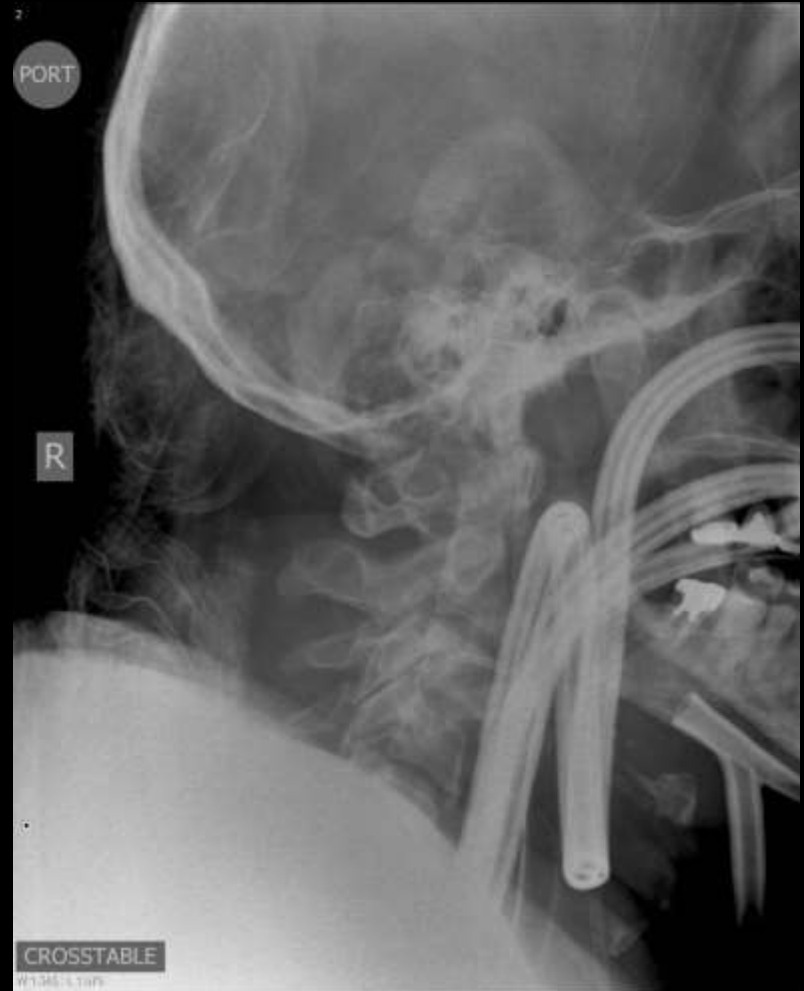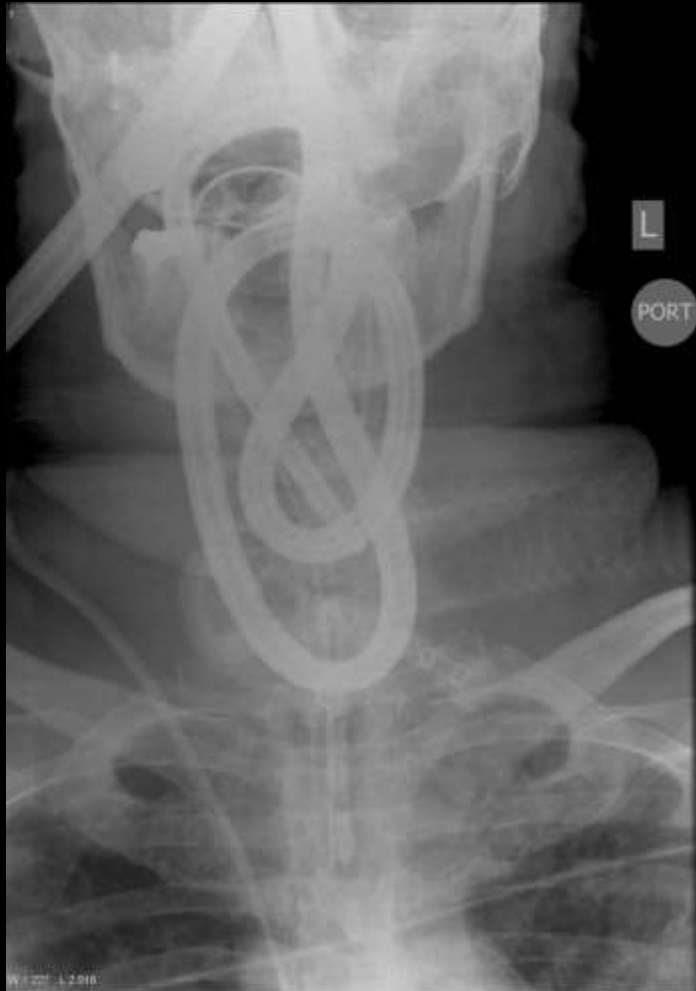Syrinx



Syrinx

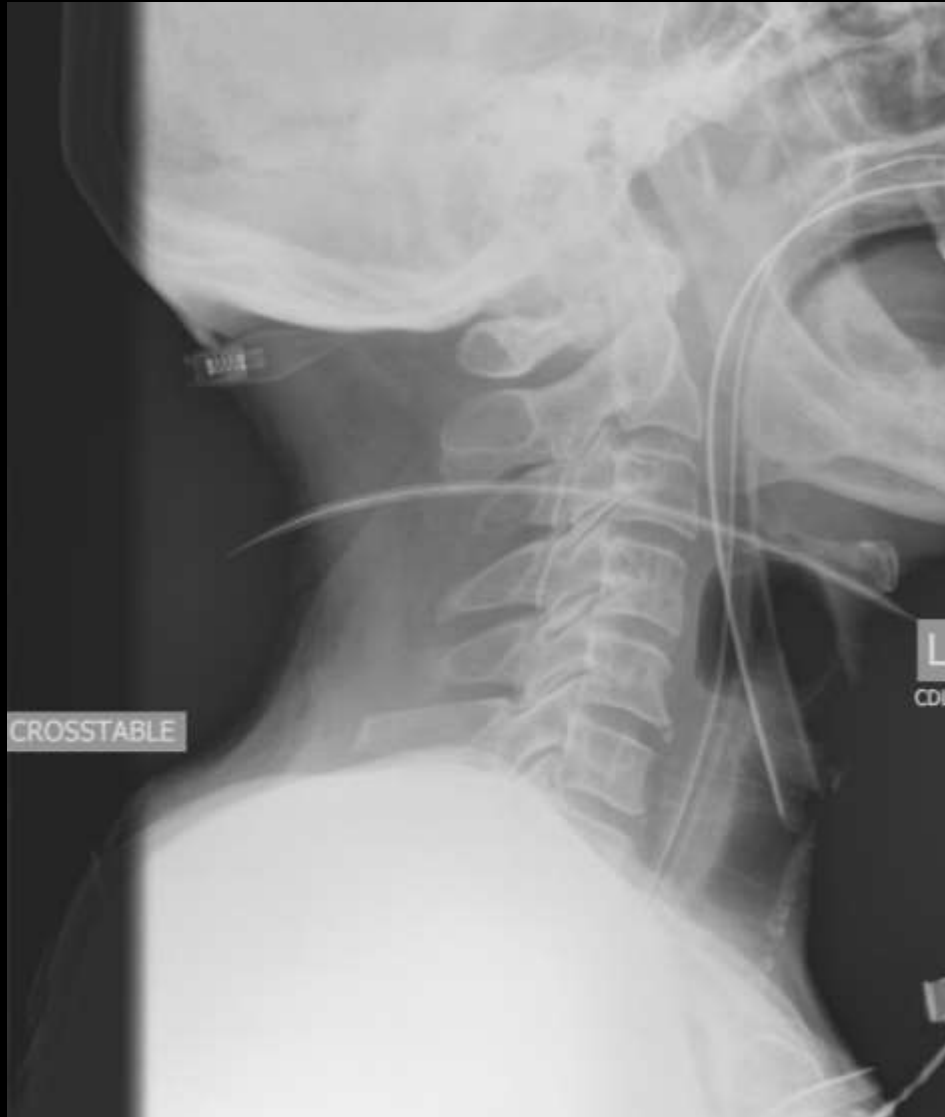

Pharynx



Reading Algorithm - Soft Tissues

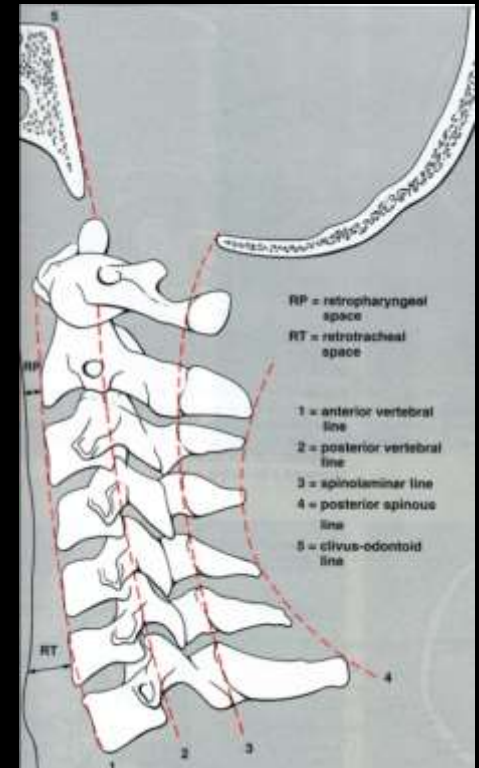
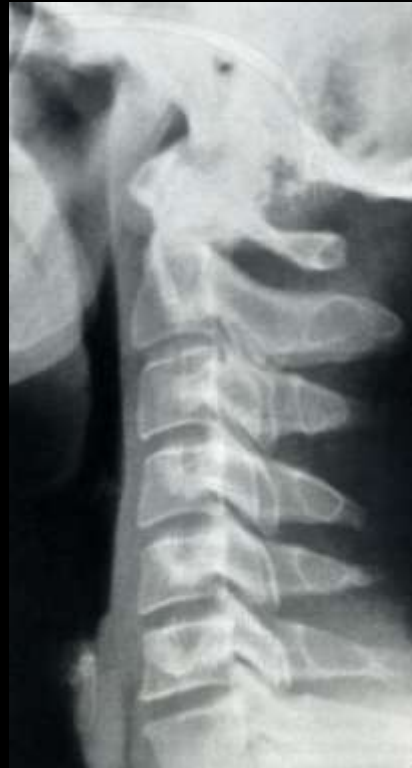Laryngopharynx



Reading Algorithm – Bony alignment

Life Lines

1. Anterior vertebral body line
2. Posterior vertebral body line
3. Spinolamina line
4. Posterior spinous process line



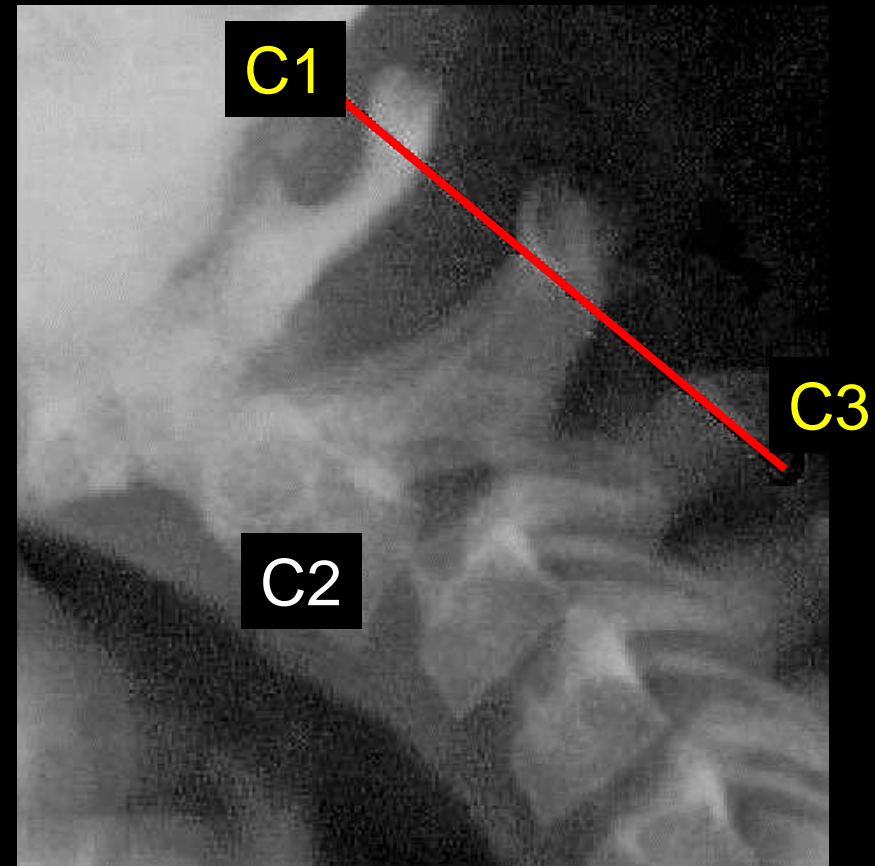
Evaluate C1-C2 Area

Adults: <3mm

Child: <5mm

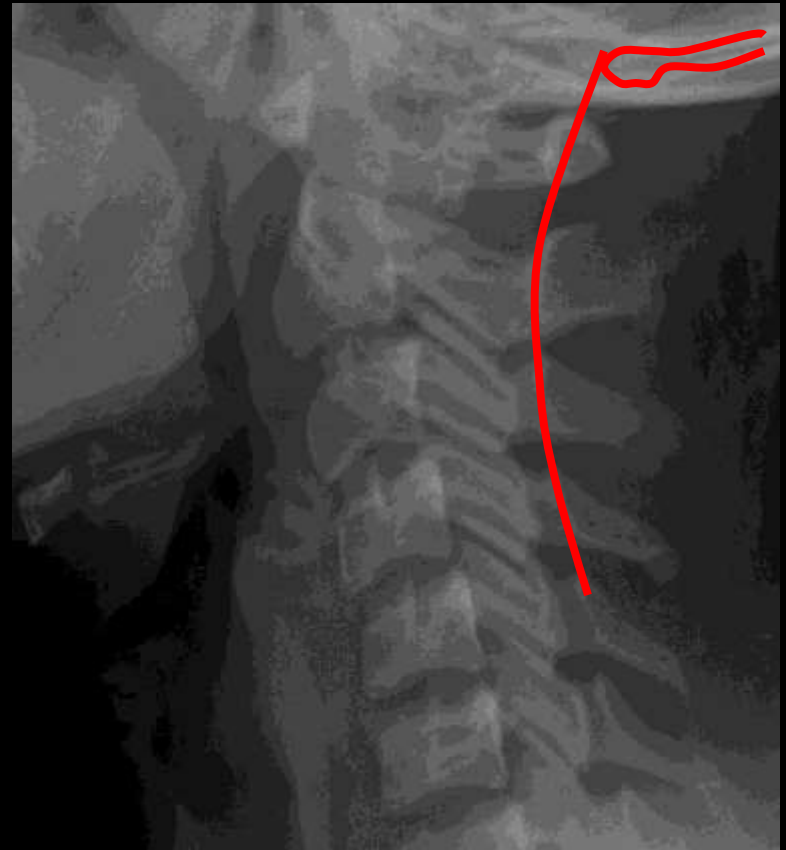
Pseudo (physiologic) Subluxation

- In children
- Ligament laxity
- Check Posterior Spinal (cervical) Line
- More than 2-3mm offset (C2 SLL anterior to PSL) must be considered traumatic.



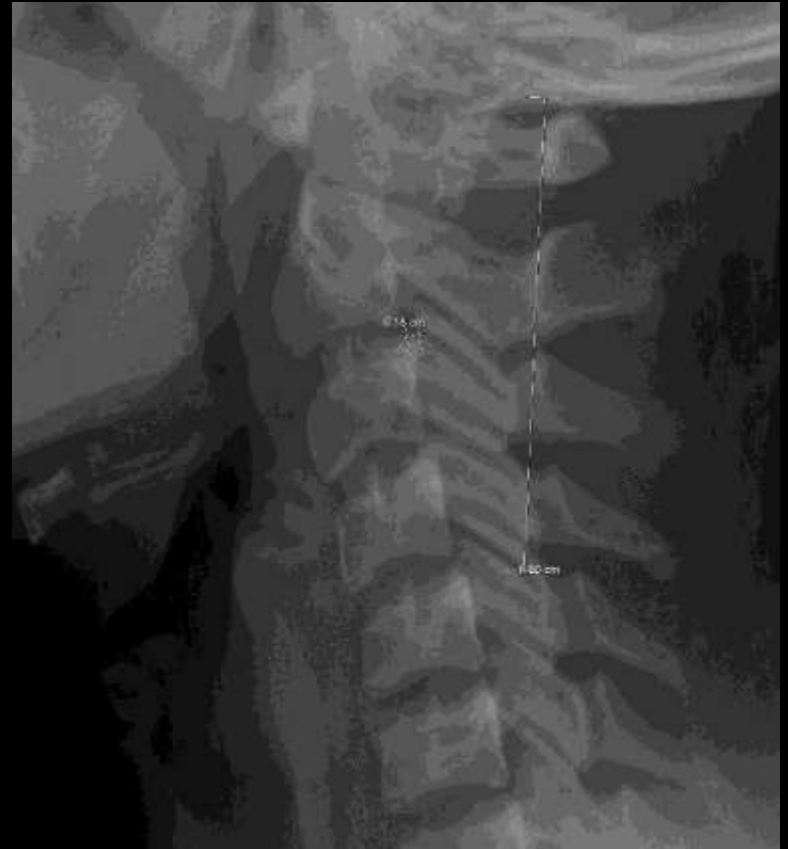Pseudo (physiologic) Subluxation

- In children
- Ligament laxity
- Check Posterior Spinal (cervical) Line
- More than 2-3mm offset (C2 SLL anterior to PSL) must be considered traumatic.



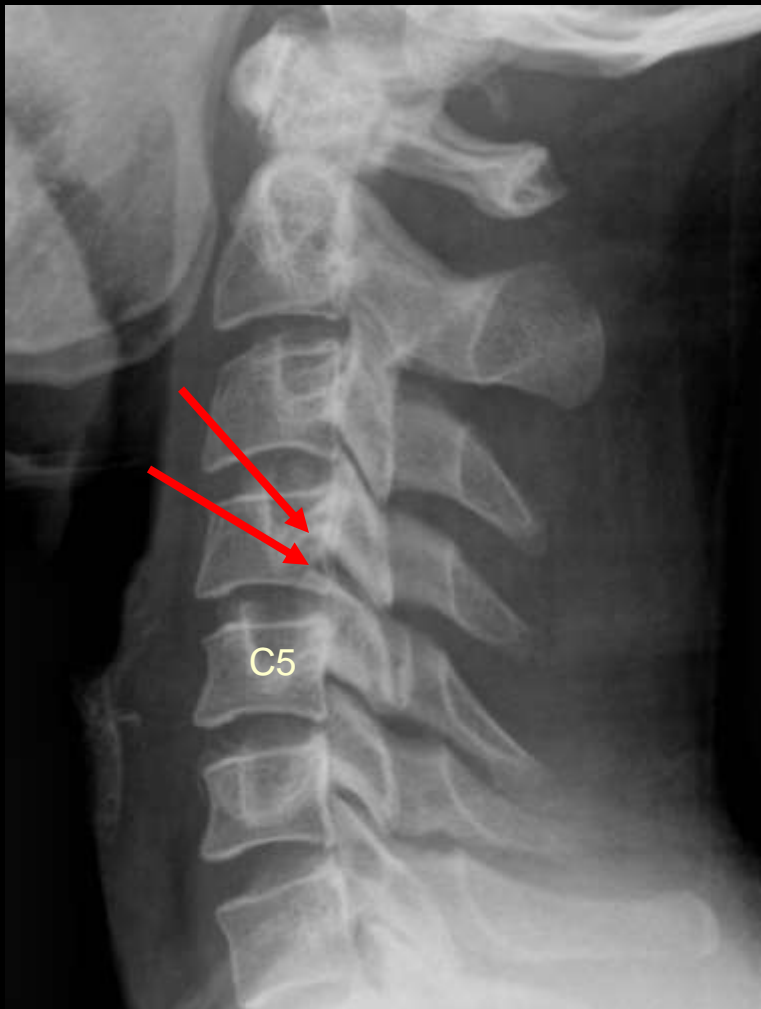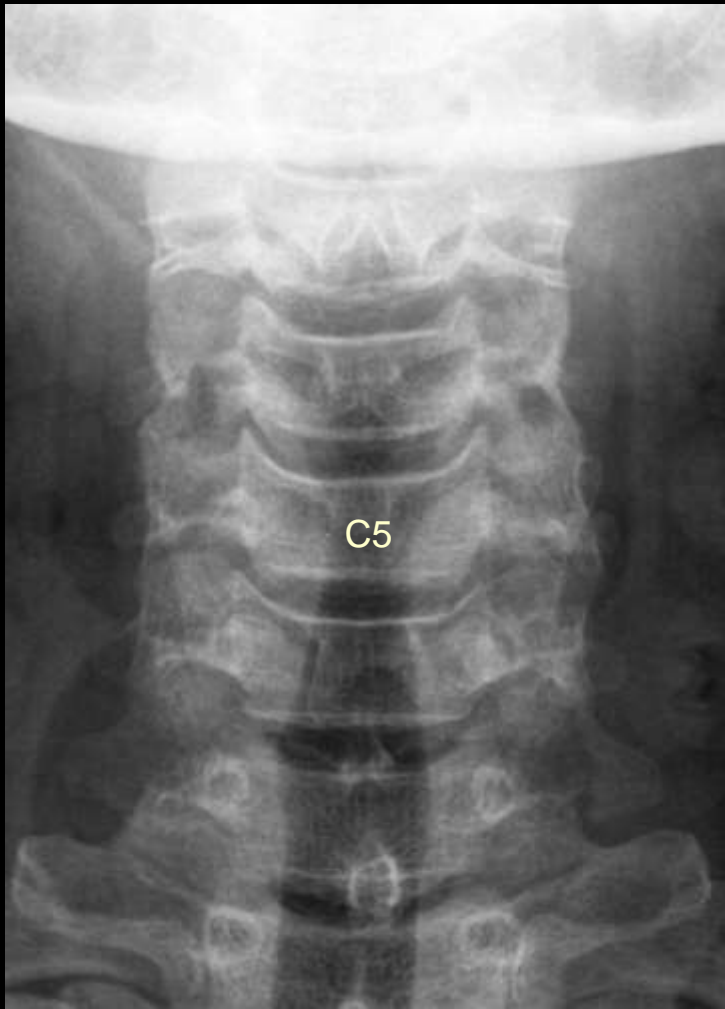Pseudo (physiologic) Subluxation

- In children
- Ligament laxity
- Check Posterior Spinal (cervical) Line
- More than 2-3mm offset (C2 SLL anterior to PSL) must be considered traumatic.



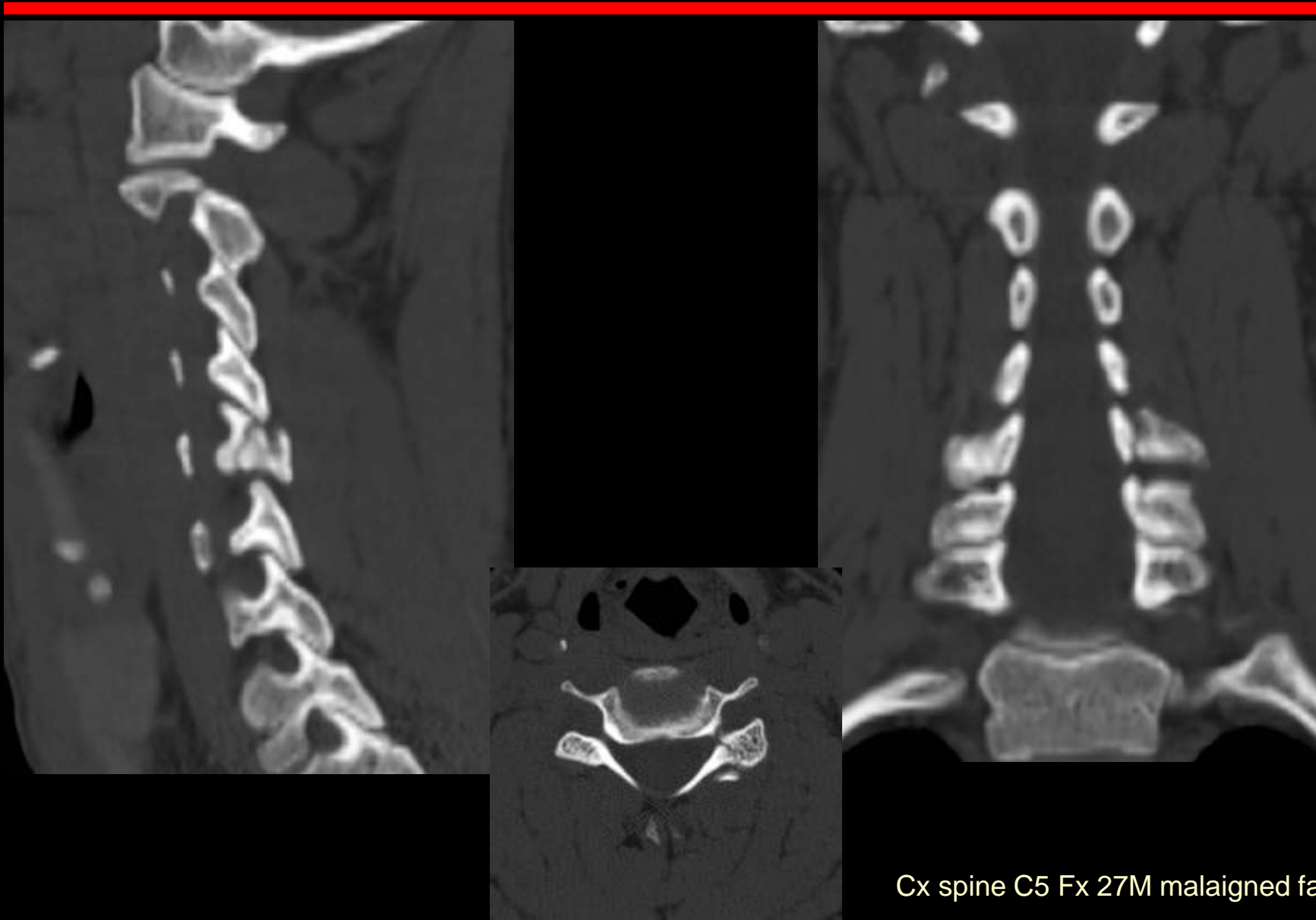
Reading Algorithm – Bony alignment

Life Lines



Cx spine C5 Fx 27M malaligned facets

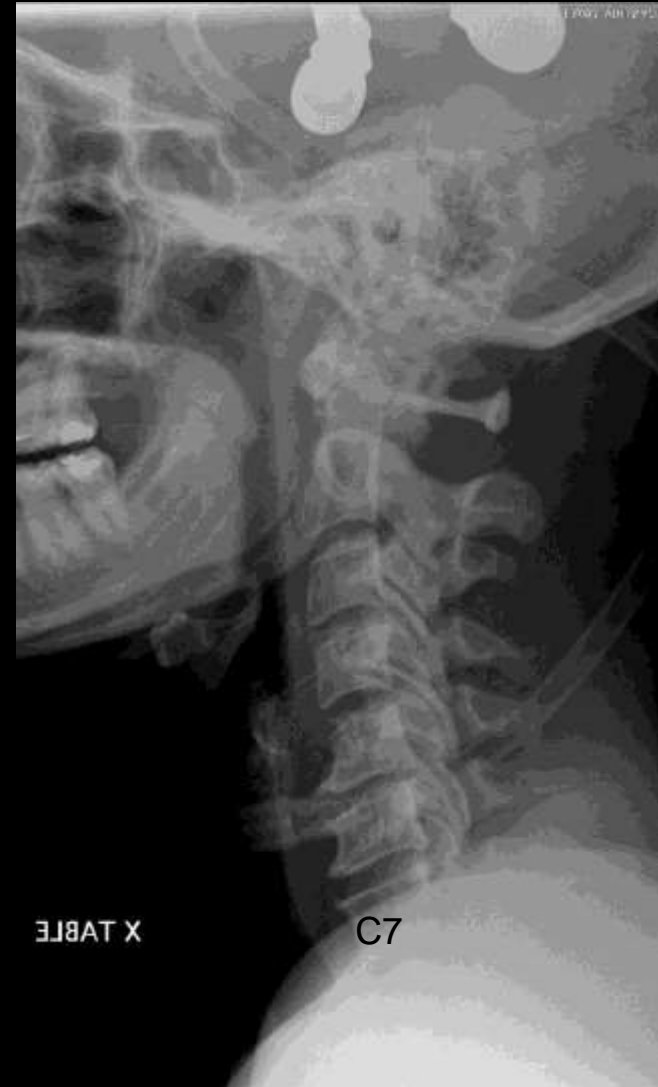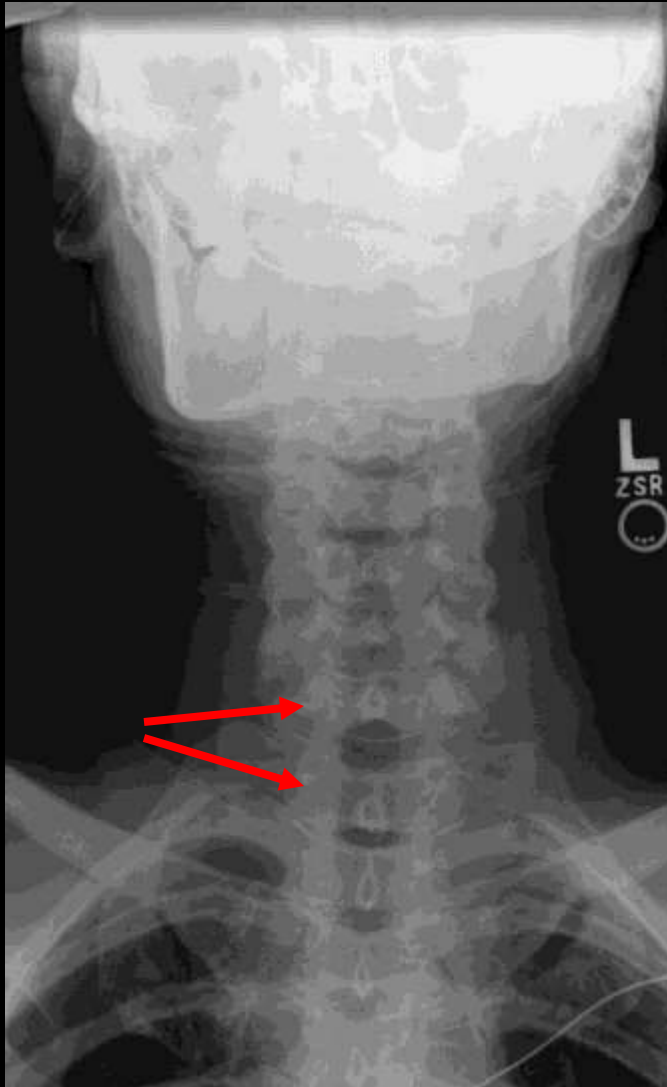
Reading Algorithm – Bony alignment
Life Lines



Cx spine C5 Fx 27M malaligned facets

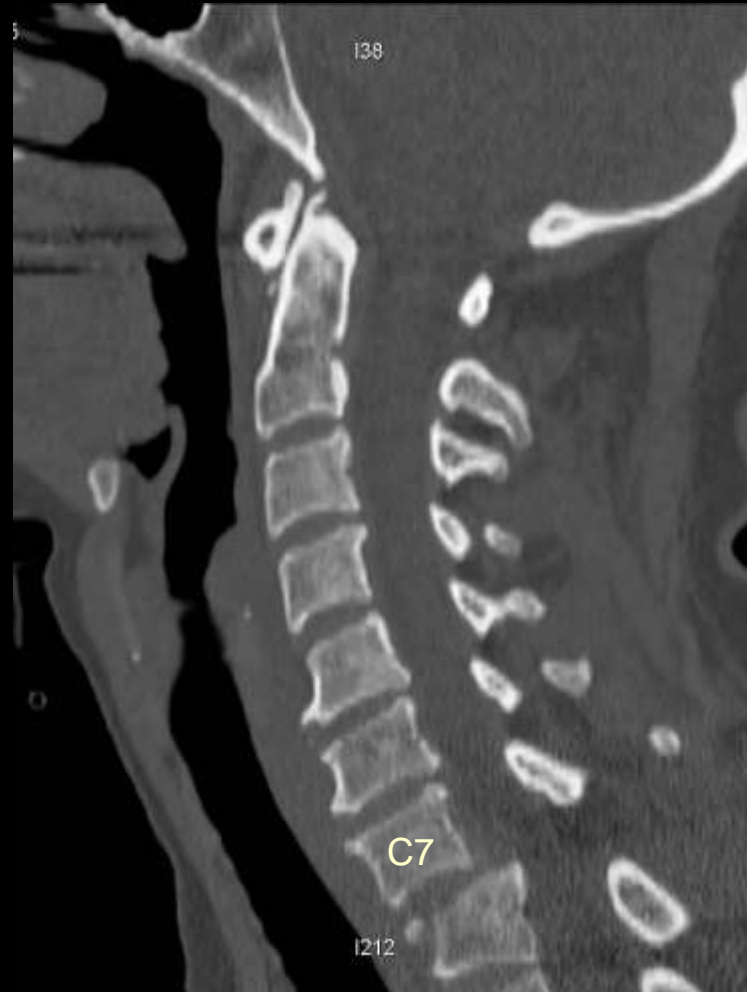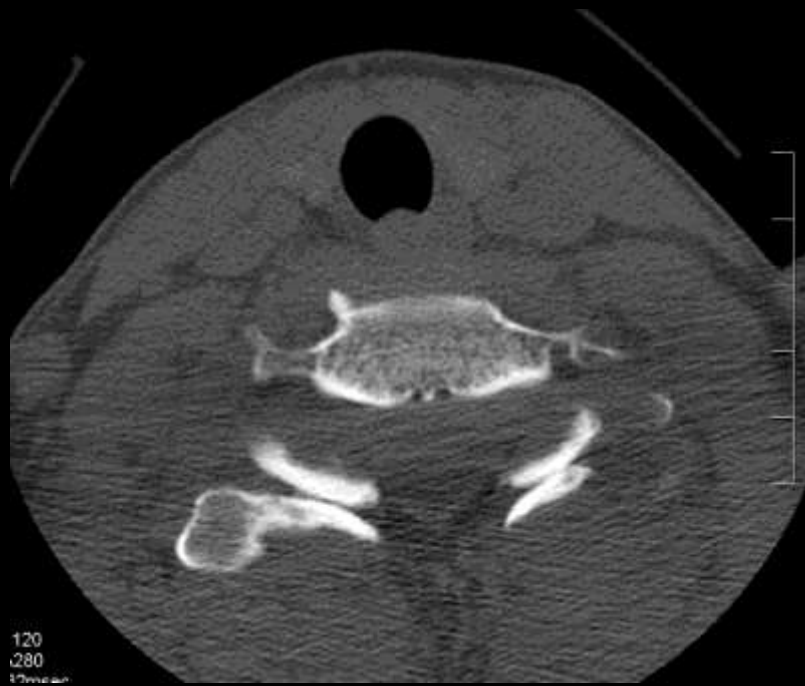
Reading Algorithm – Bony alignment

Life Lines



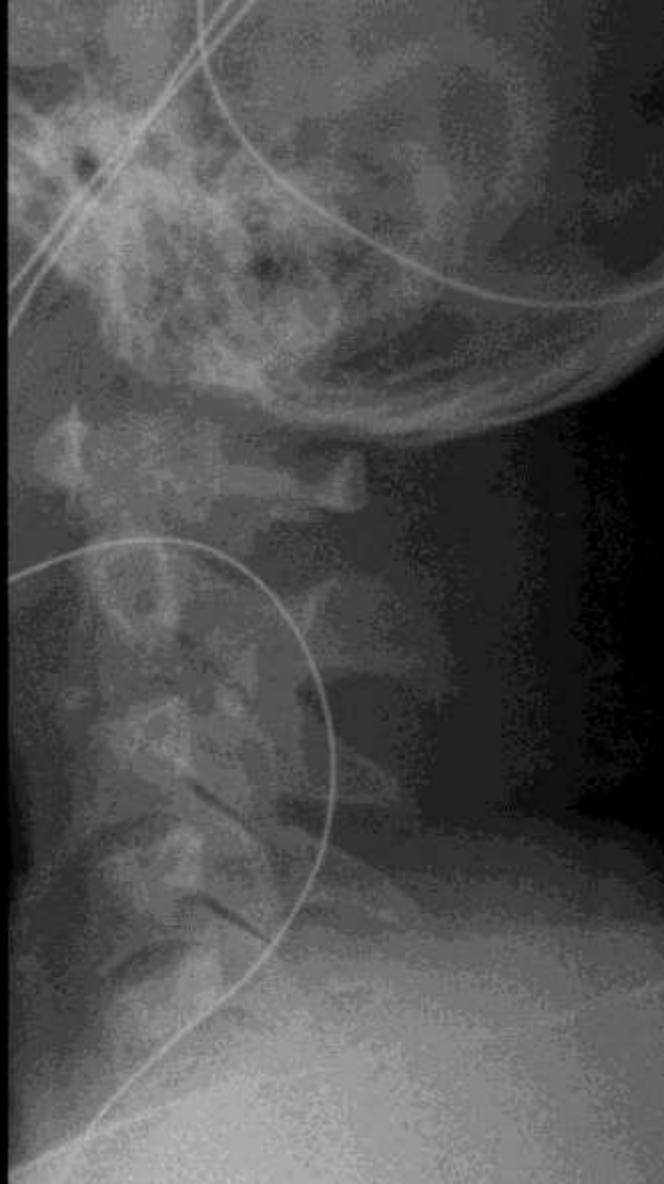Reading Algorithm – Bony alignment

Life Lines

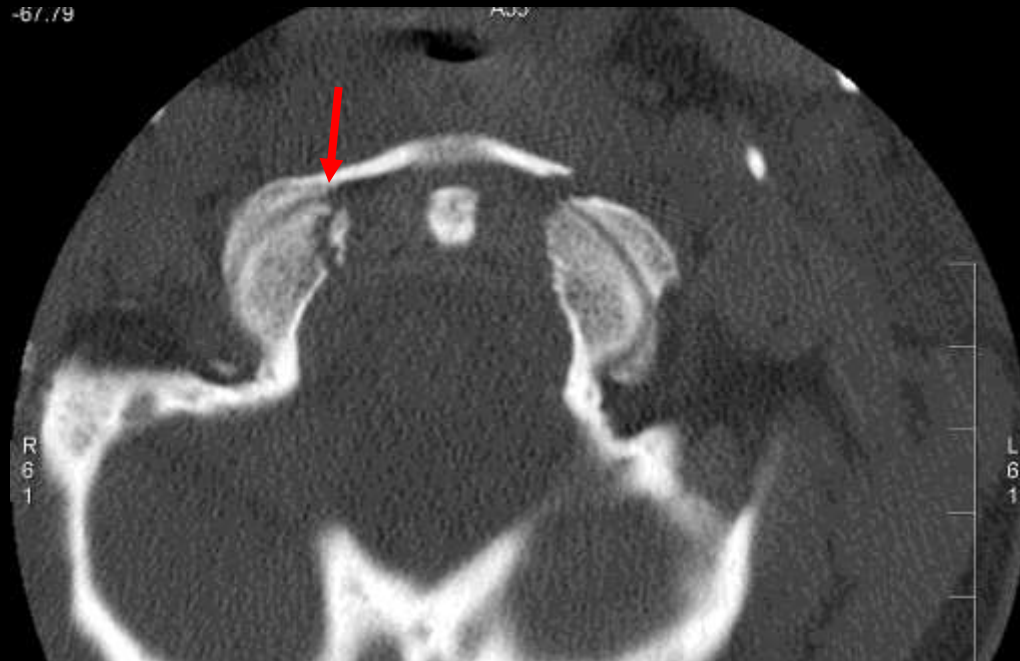


Reading Algorithm – Find the second fracture

Occiput, C1, C2 and C6-7 fxs



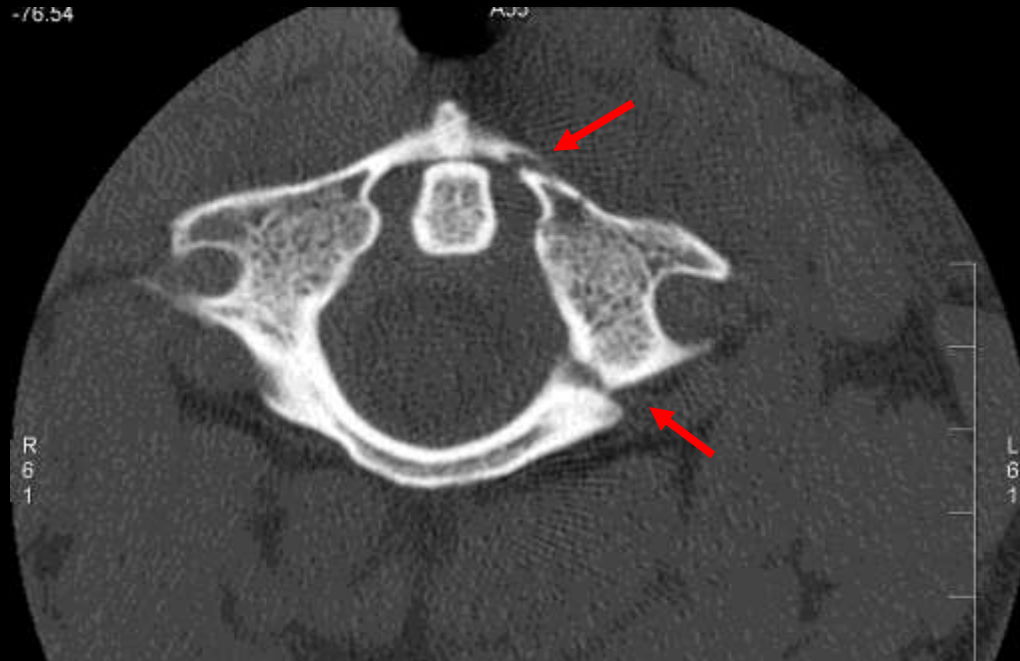Reading Algorithm – Find the second fracture
Occiput, C1, C2 and C6-7 fxs



Occiput Fx

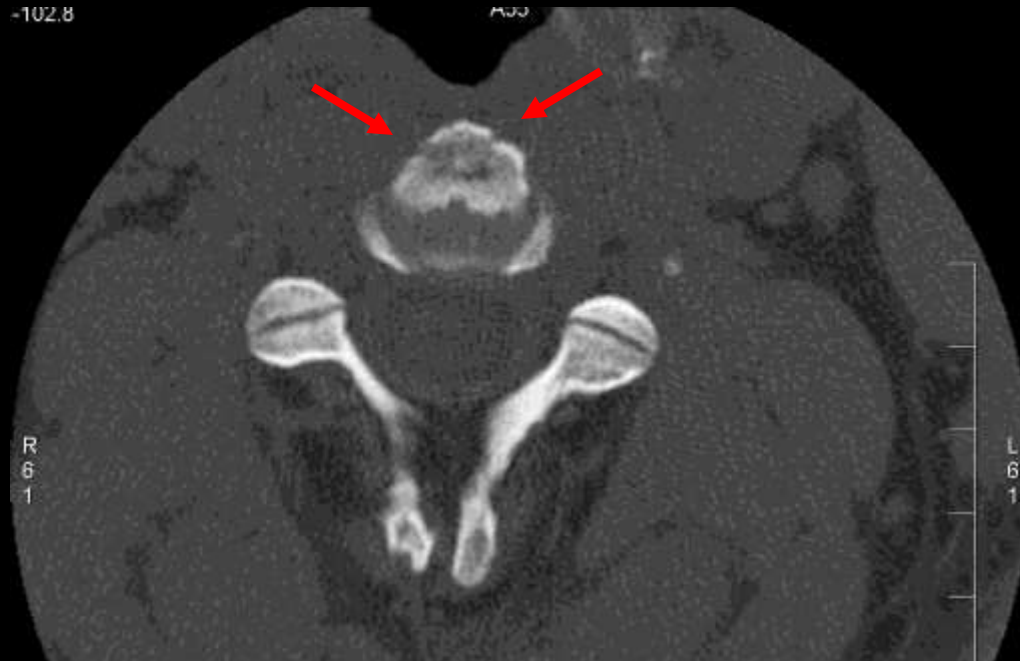Reading Algorithm – Find the second fracture

Occiput, C1, C2 and C6-7 fxs



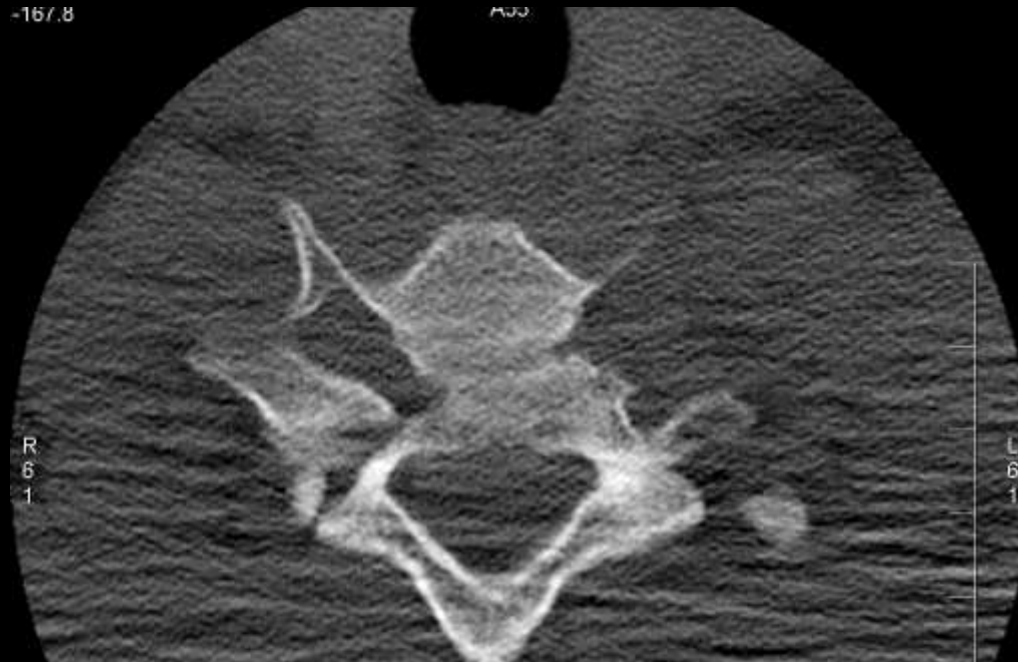C1 Fx

Reading Algorithm – Find the second fracture
Occiput, C1, C2 and C6-7 fxs



C2 Fx

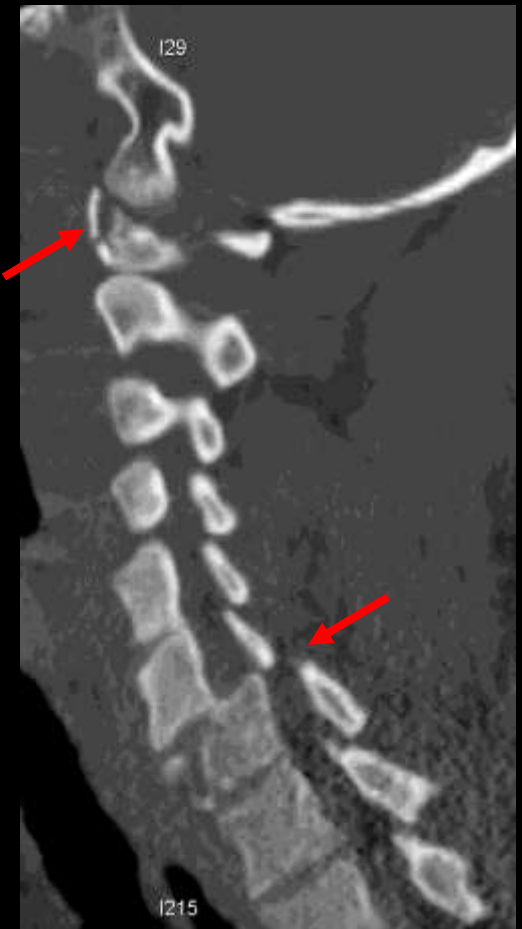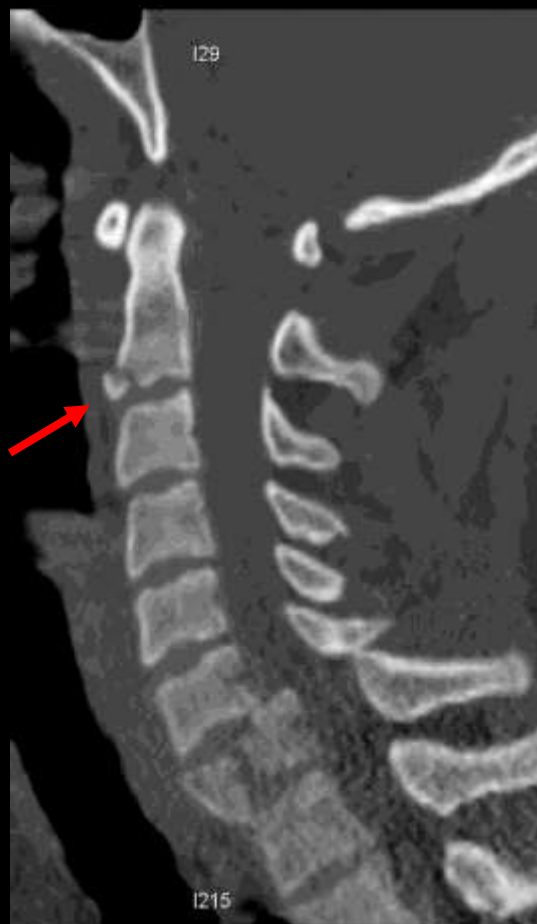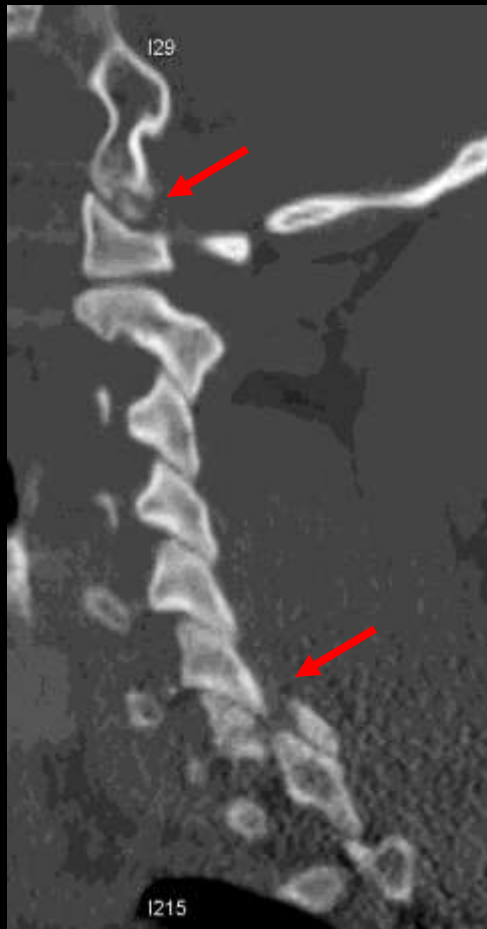
Reading Algorithm – Find the second fracture
Occiput, C1, C2 and C6-7 fxs



C6-7 Fx Dis

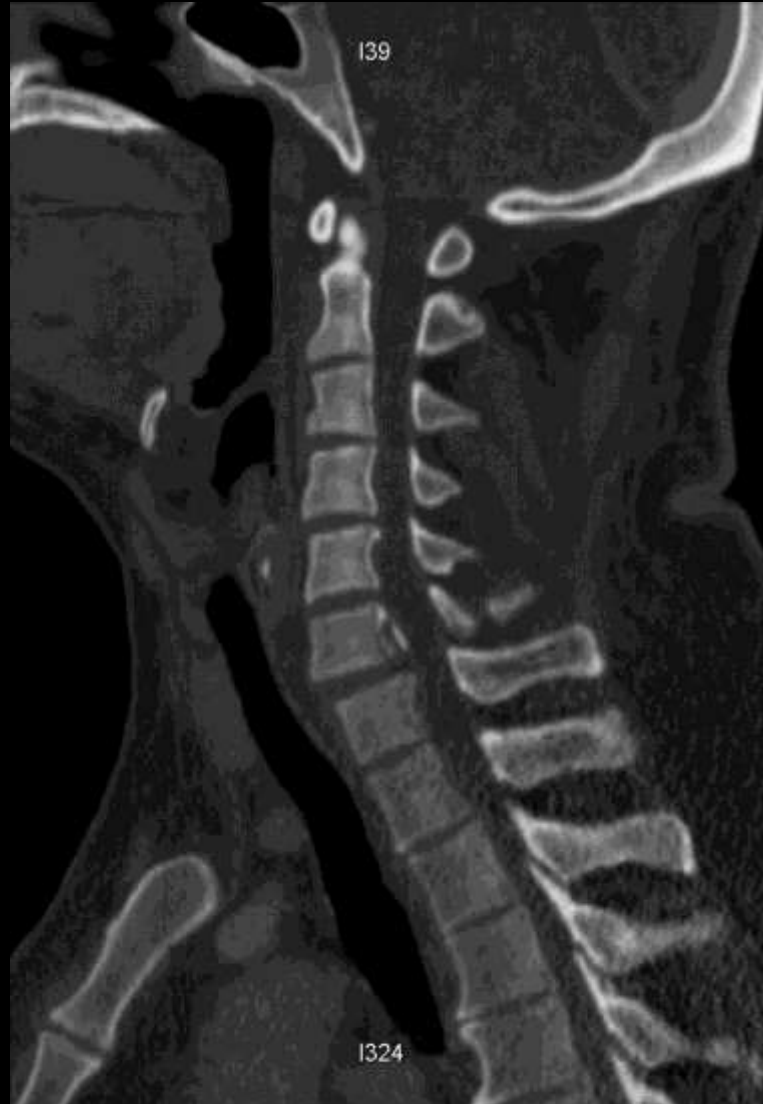Reading Algorithm – Find the second fracture

Occiput, C1, C2 and C6-7 fxs



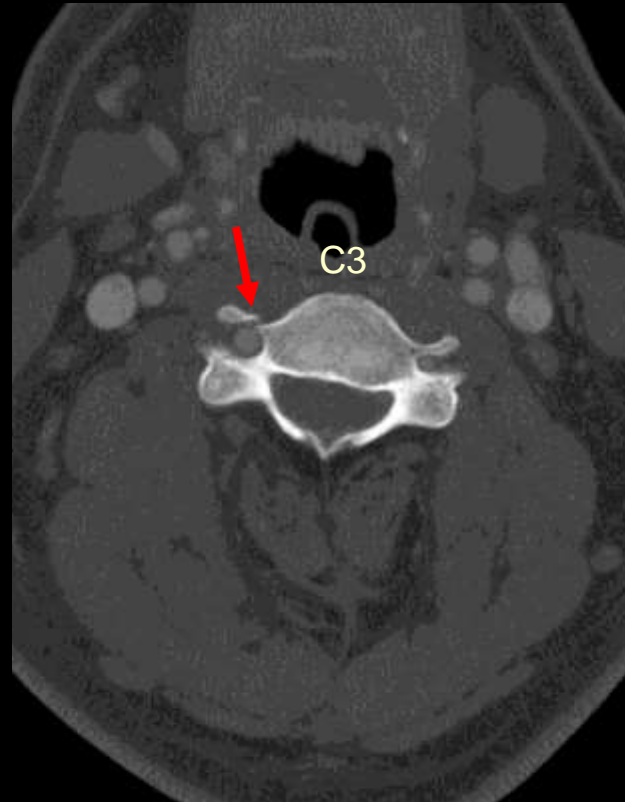
Reading Algorithm – Find the second fracture

C3,4,5,6,7 fxs



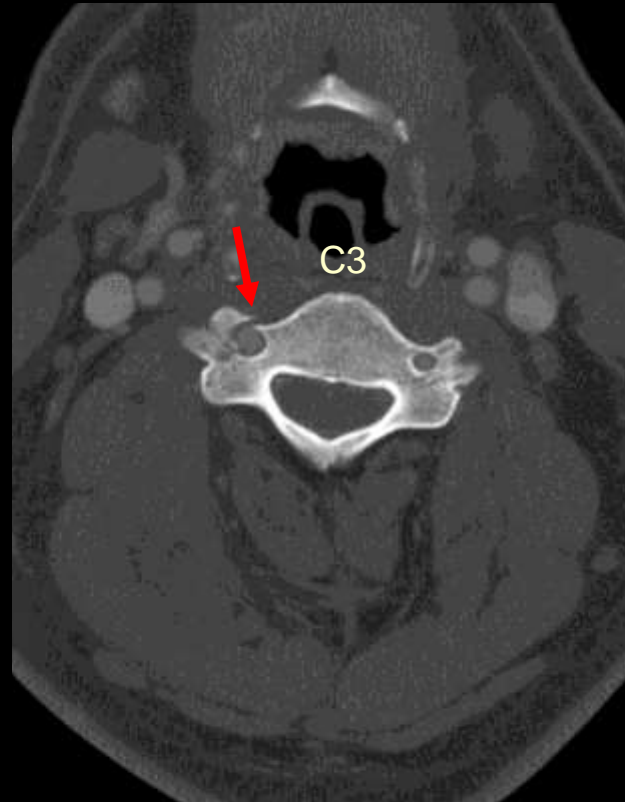Reading Algorithm – Find the second fracture

C3,4,5,6,7 fxs



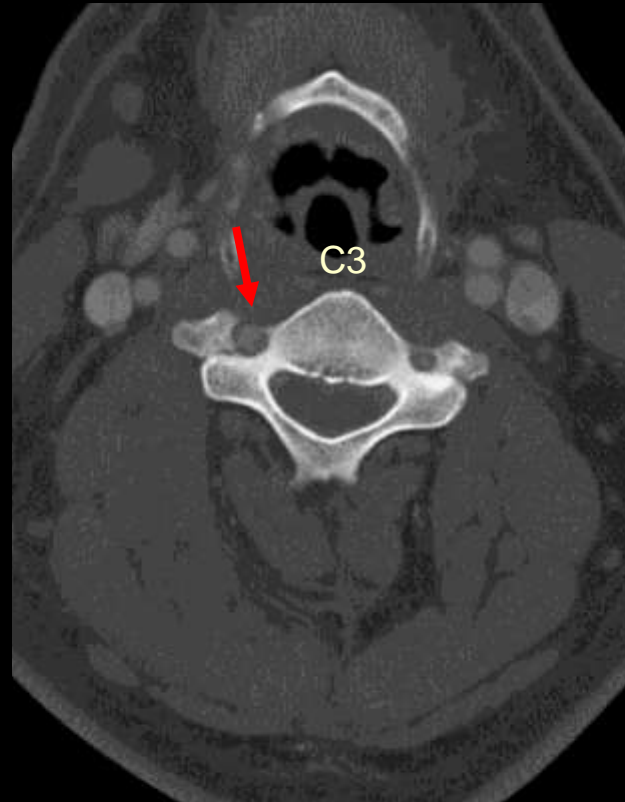
Reading Algorithm – Find the second fracture

C3,4,5,6,7 fxs



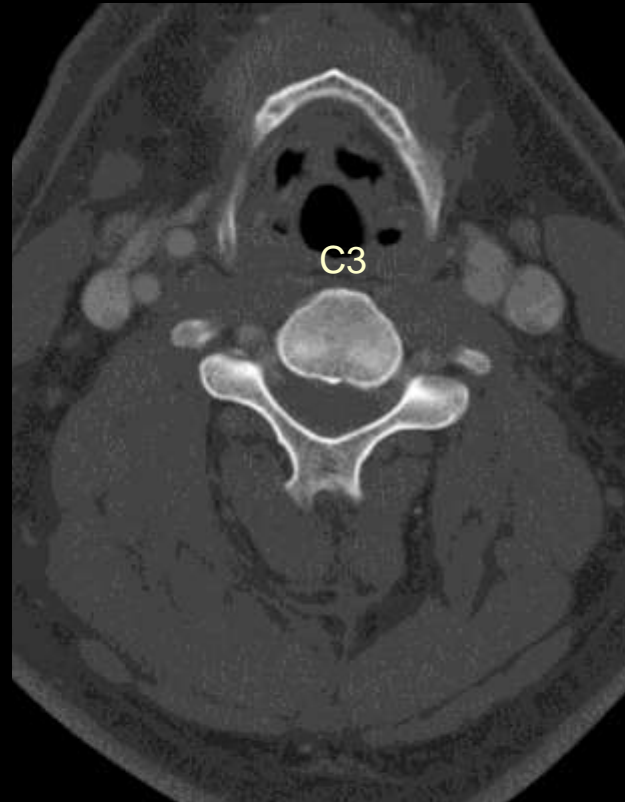Reading Algorithm – Find the second fracture

C3,4,5,6,7 fxs



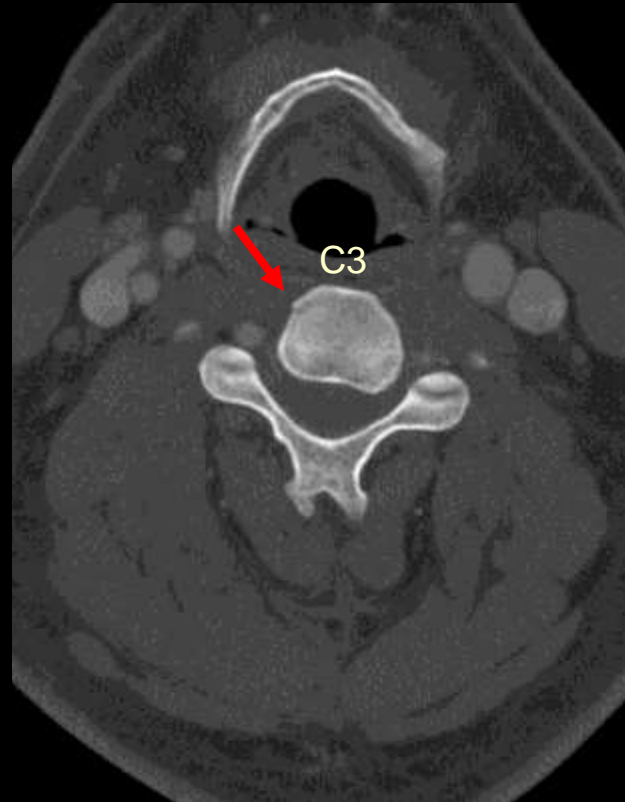
Reading Algorithm – Find the second fracture

C3,4,5,6,7 fxs



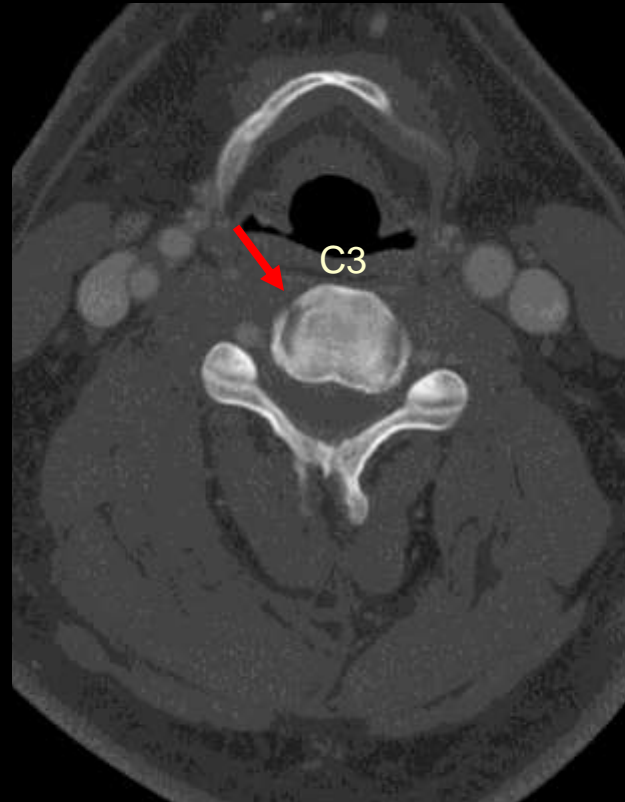
Reading Algorithm – Find the second fracture

C3,4,5,6,7 fxs



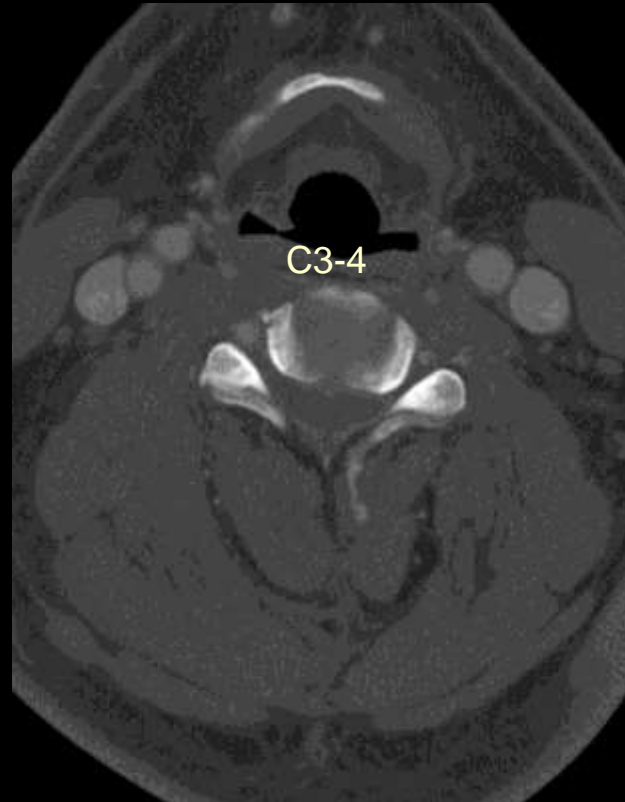
Reading Algorithm – Find the second fracture

C3,4,5,6,7 fxs



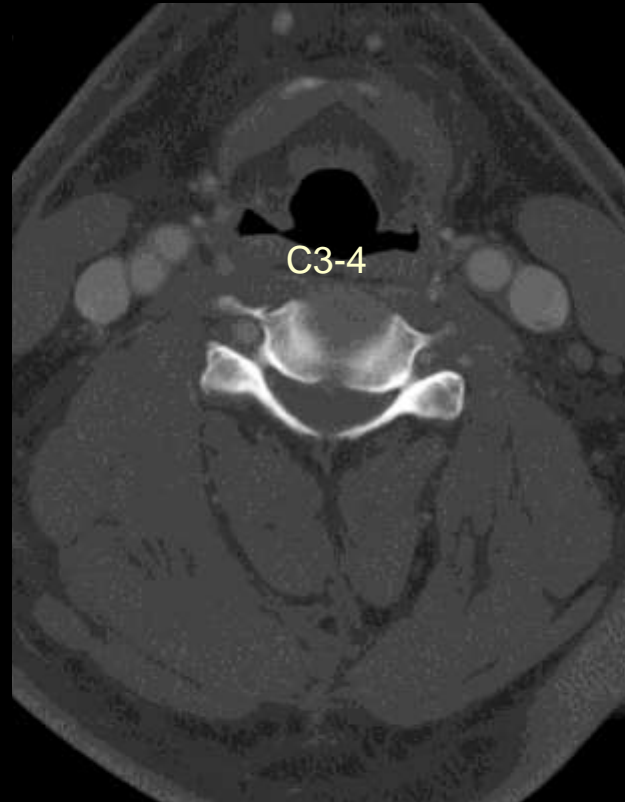
Reading Algorithm – Find the second fracture

C3,4,5,6,7 fxs



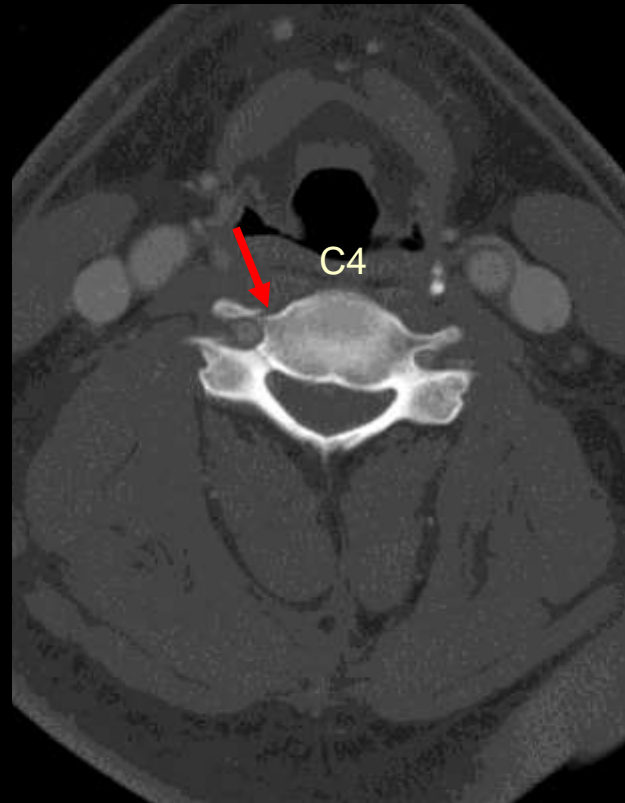
Reading Algorithm – Find the second fracture

C3,4,5,6,7 fxs



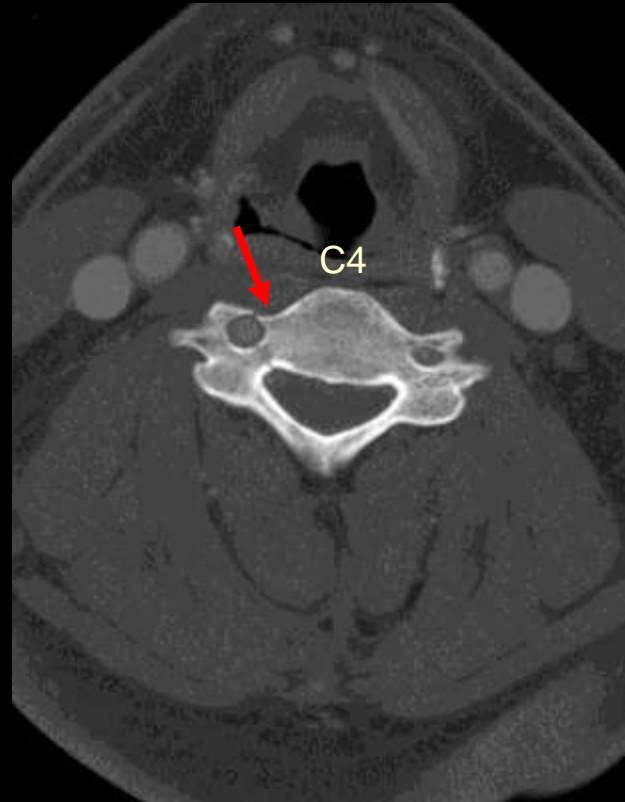
Reading Algorithm – Find the second fracture

C3,4,5,6,7 fxs



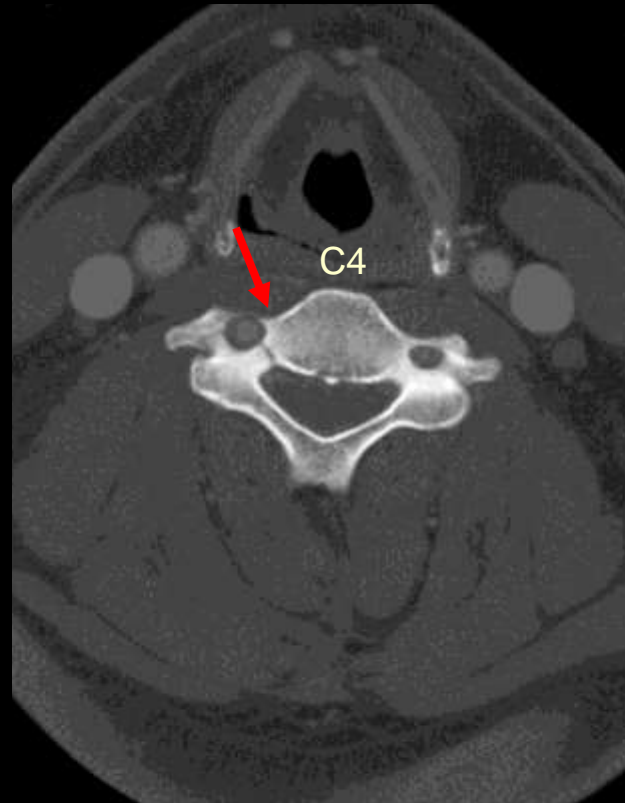
Reading Algorithm – Find the second fracture

C3,4,5,6,7 fxs



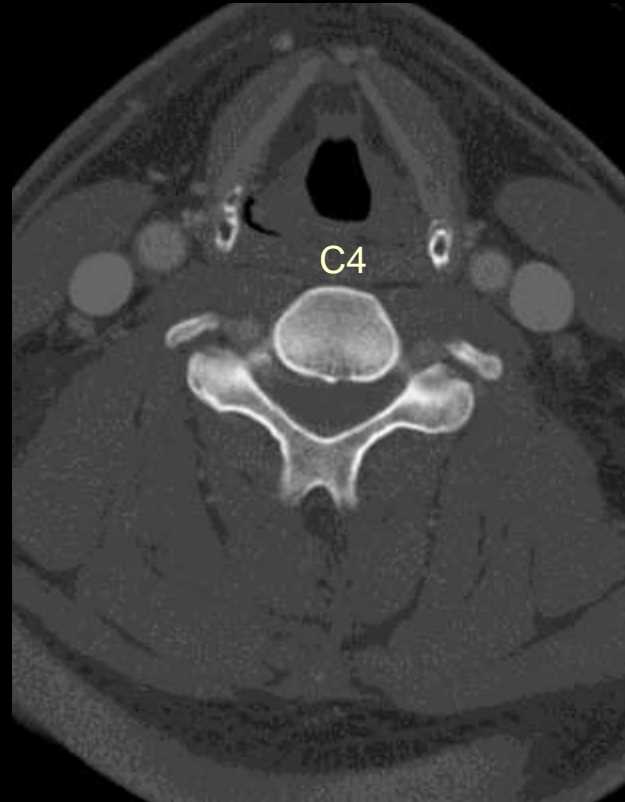
Reading Algorithm – Find the second fracture

C3,4,5,6,7 fxs



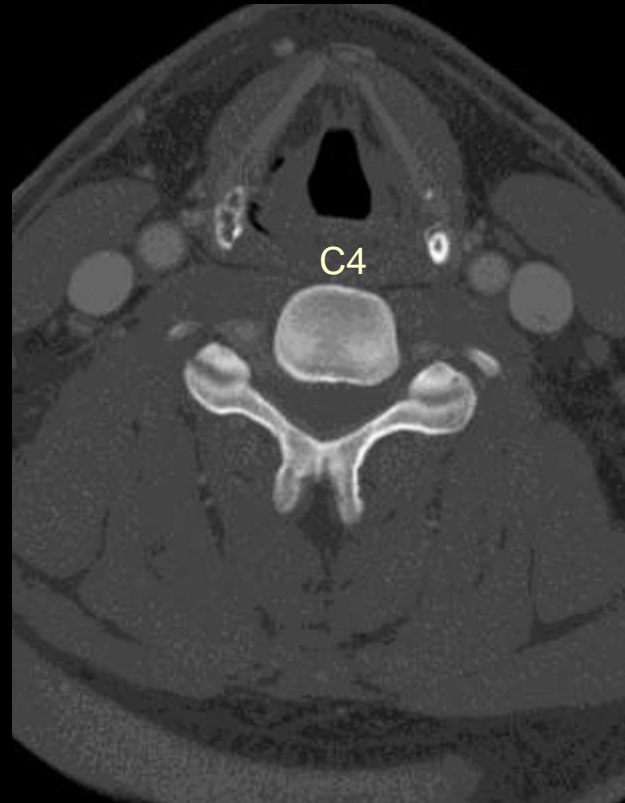
Reading Algorithm – Find the second fracture

C3,4,5,6,7 fxs



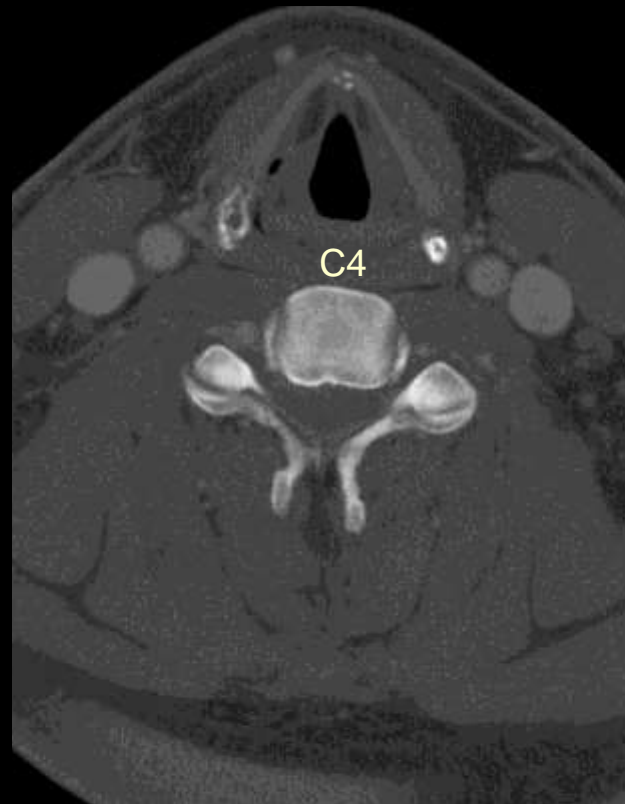Reading Algorithm – Find the second fracture

C3,4,5,6,7 fxs



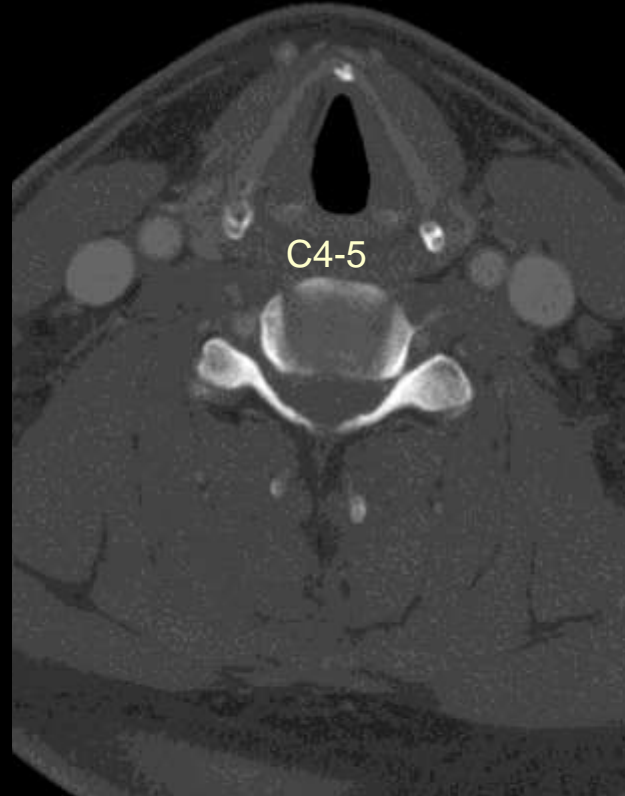
Reading Algorithm – Find the second fracture

C3,4,5,6,7 fxs



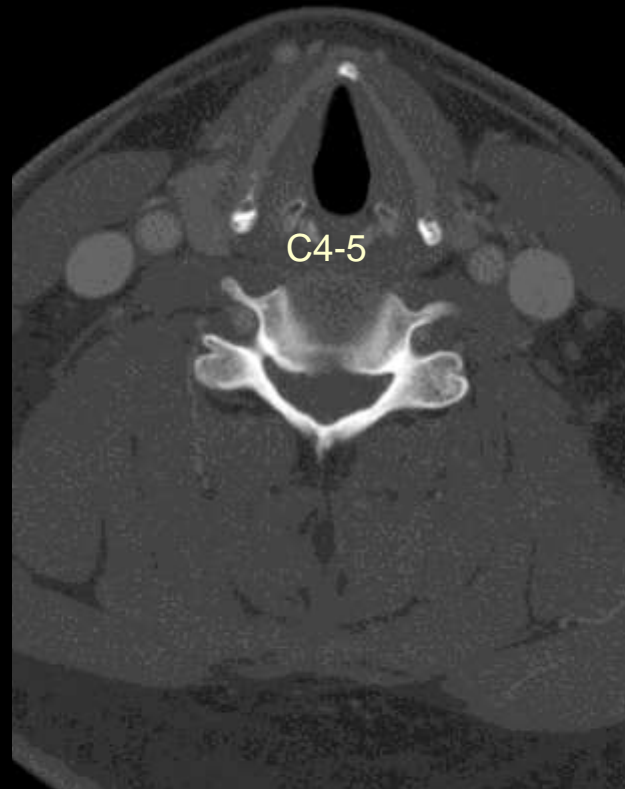Reading Algorithm – Find the second fracture

C3,4,5,6,7 fxs



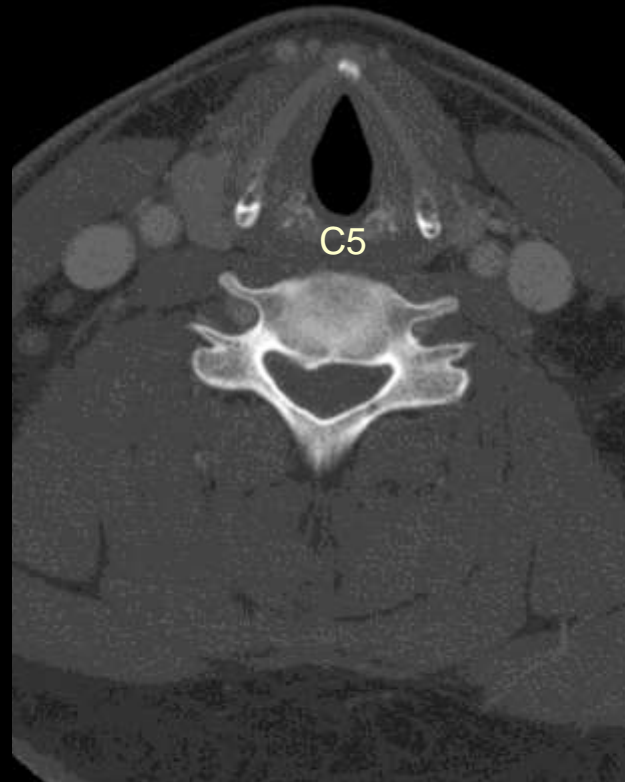Reading Algorithm – Find the second fracture

C3,4,5,6,7 fxs



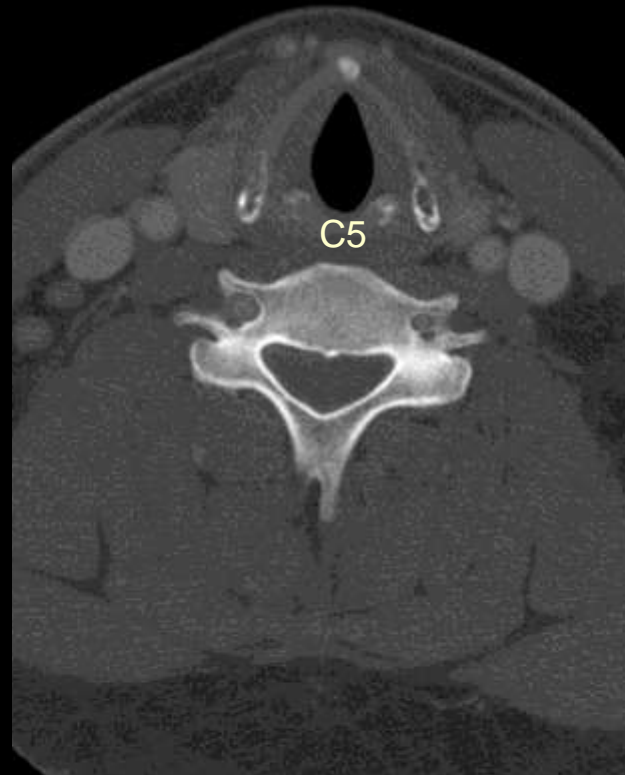Reading Algorithm – Find the second fracture

C3,4,5,6,7 fxs



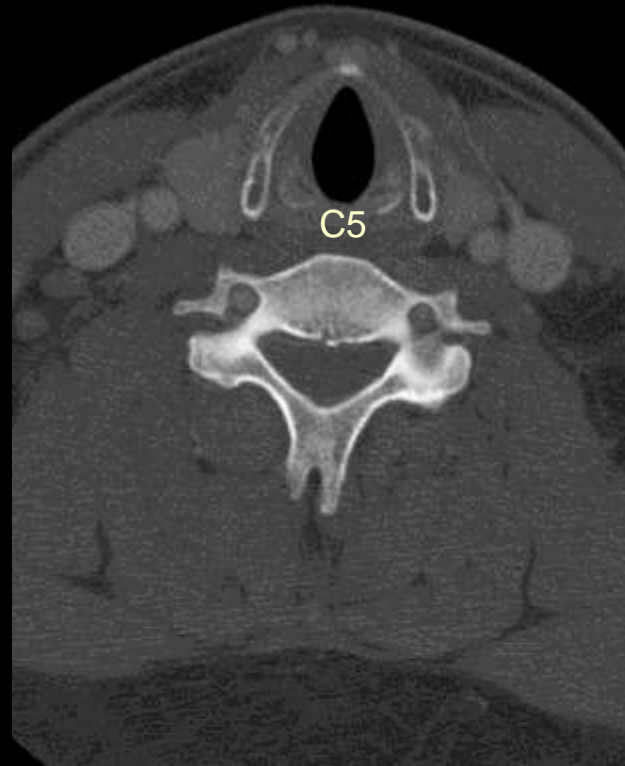Reading Algorithm – Find the second fracture

C3,4,5,6,7 fxs



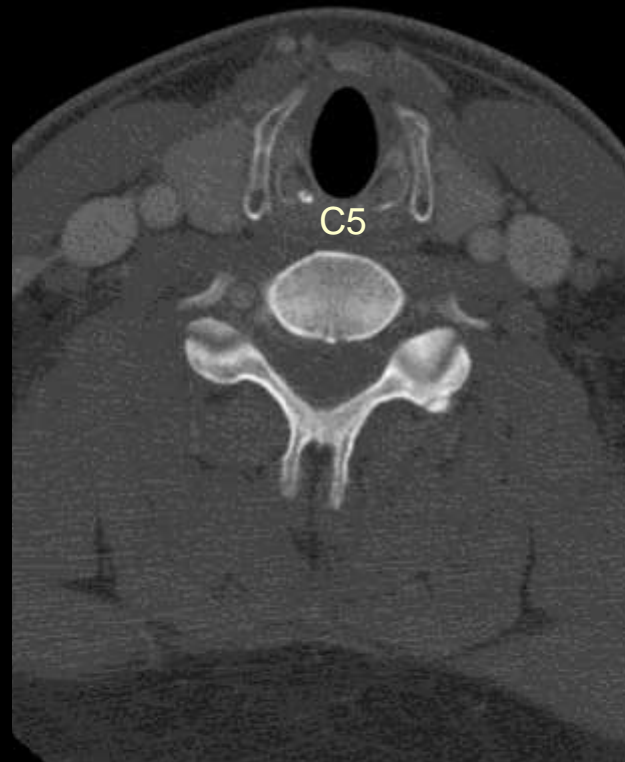
Reading Algorithm – Find the second fracture

C3,4,5,6,7 fxs



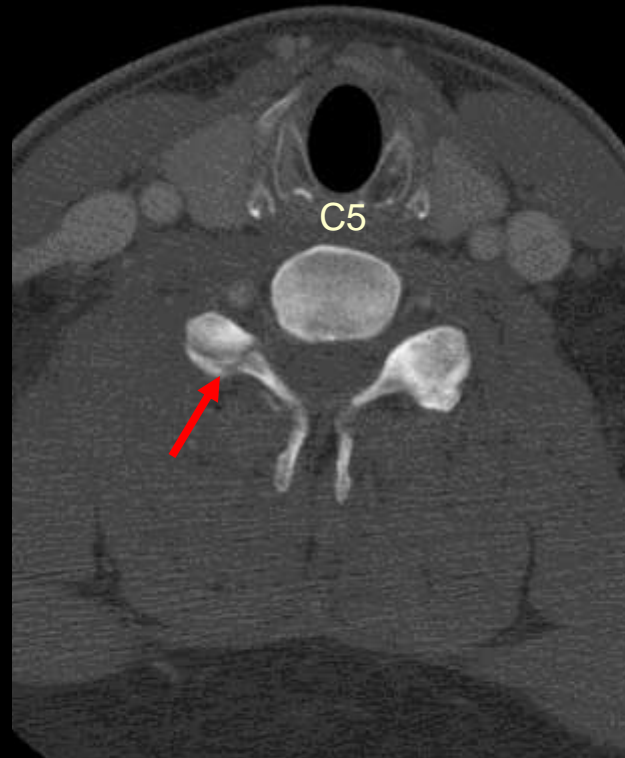
Reading Algorithm – Find the second fracture

C3,4,5,6,7 fxs



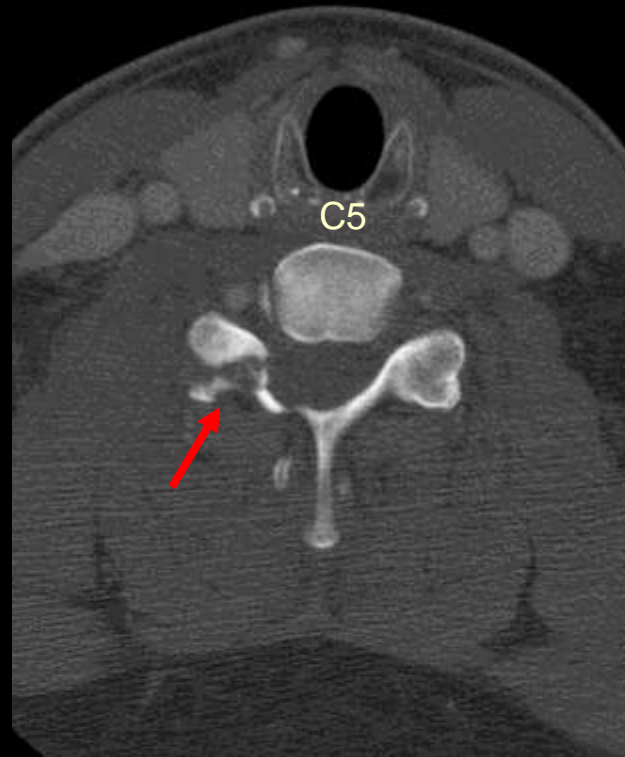
Reading Algorithm – Find the second fracture

C3,4,5,6,7 fxs



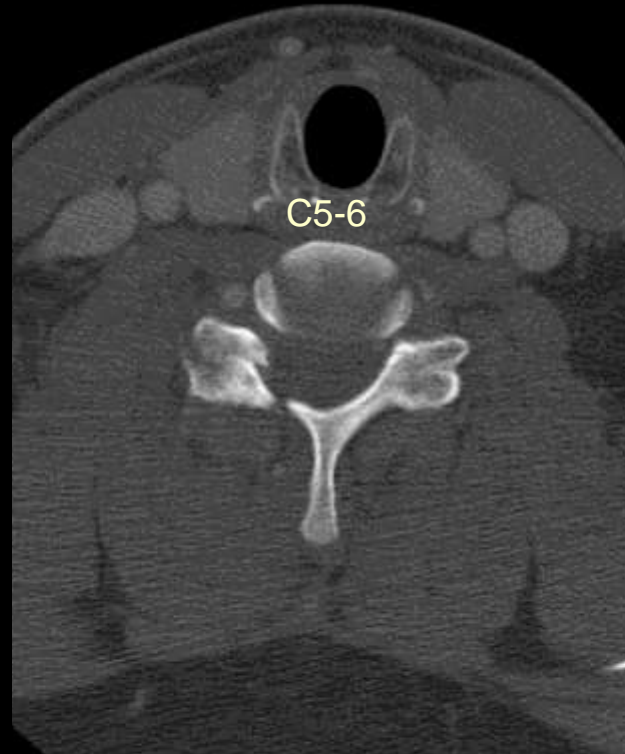
Reading Algorithm – Find the second fracture

C3,4,5,6,7 fxs



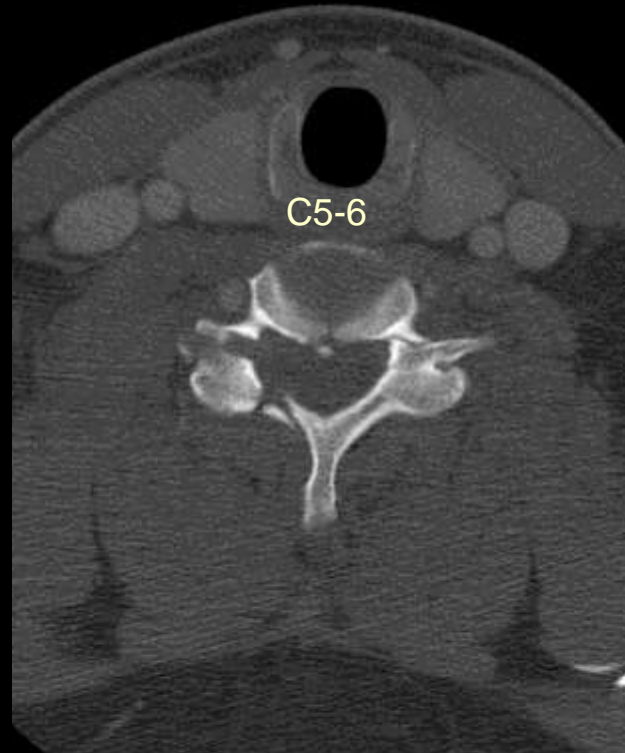
Reading Algorithm – Find the second fracture

C3,4,5,6,7 fxs



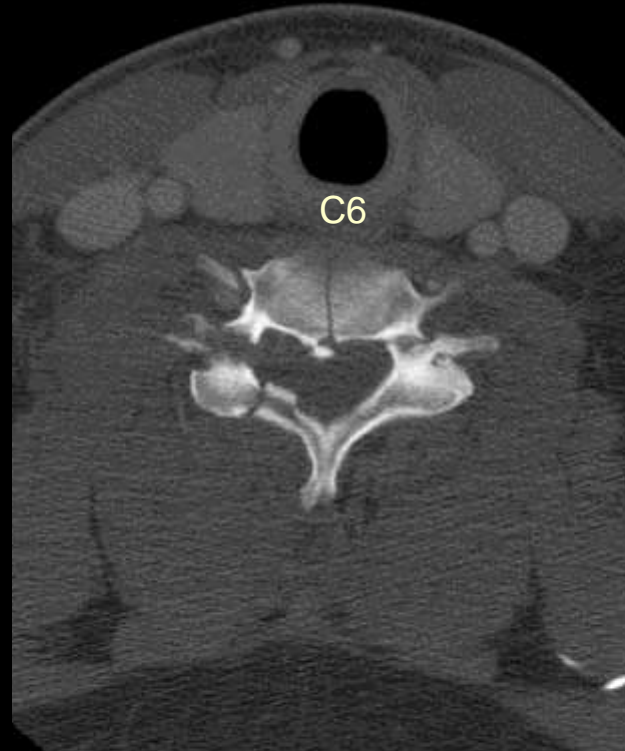
Reading Algorithm – Find the second fracture

C3,4,5,6,7 fxs



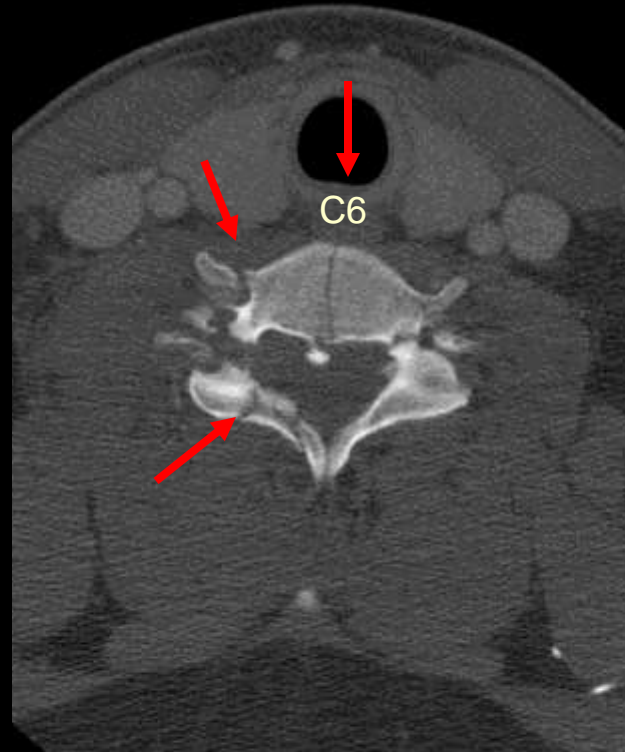
Reading Algorithm – Find the second fracture

C3,4,5,6,7 fxs



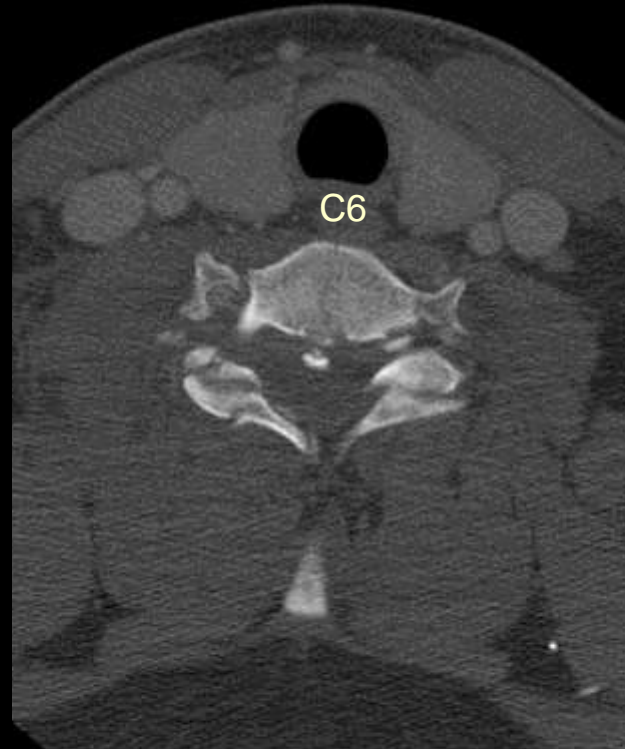Reading Algorithm – Find the second fracture

C3,4,5,6,7 fxs



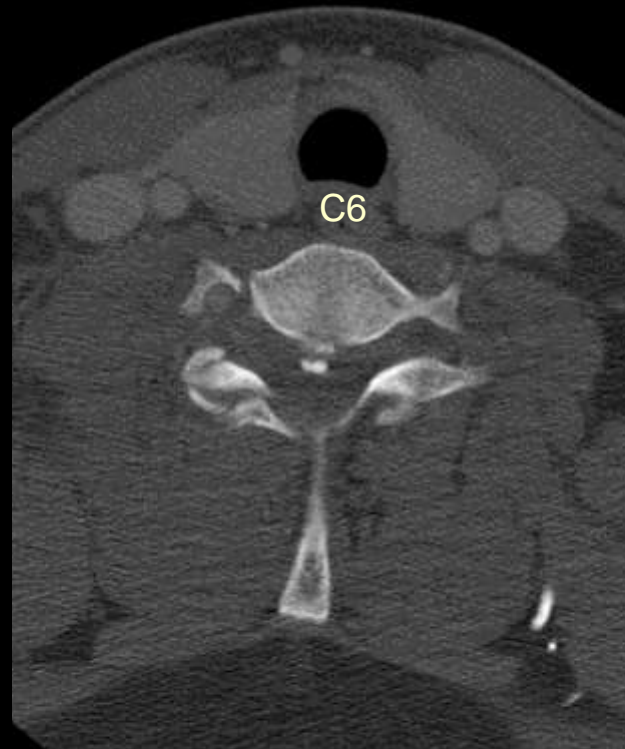Reading Algorithm – Find the second fracture

C3,4,5,6,7 fxs



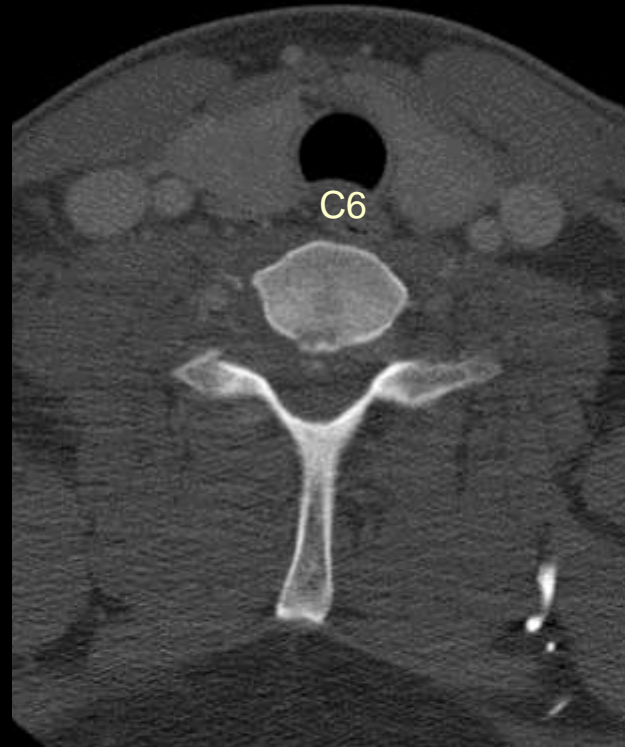
Reading Algorithm – Find the second fracture

C3,4,5,6,7 fxs



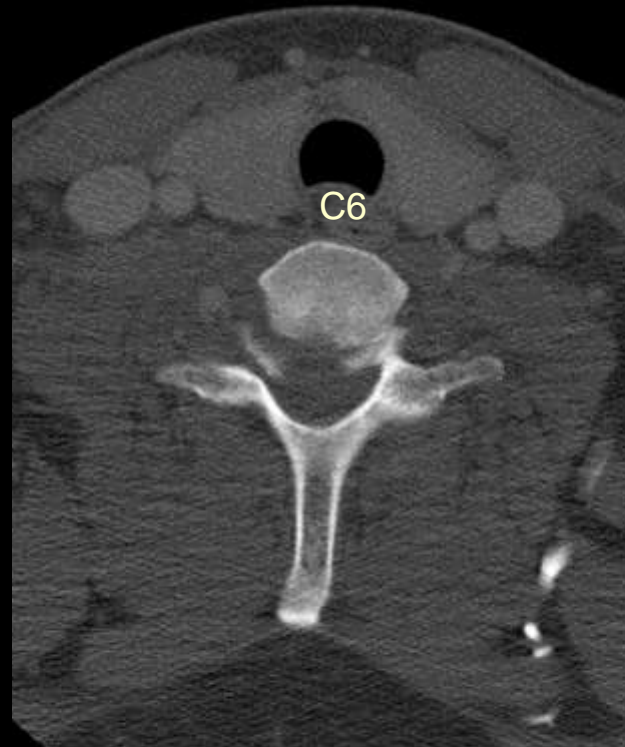Reading Algorithm – Find the second fracture

C3,4,5,6,7 fxs



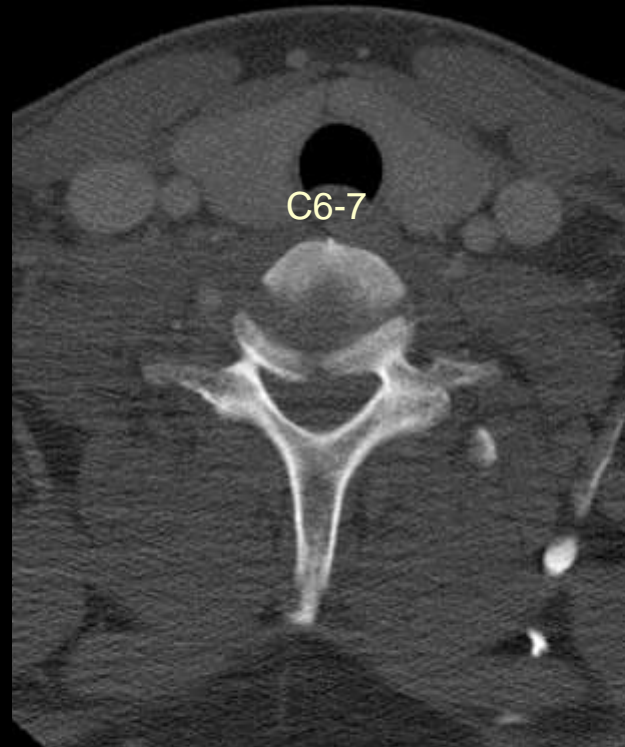
Reading Algorithm – Find the second fracture

C3,4,5,6,7 fxs



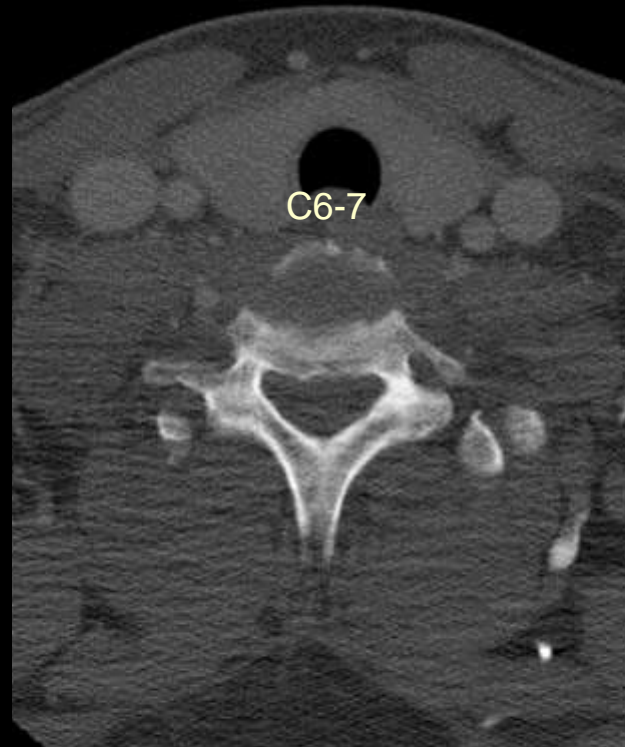
Reading Algorithm – Find the second fracture

C3,4,5,6,7 fxs



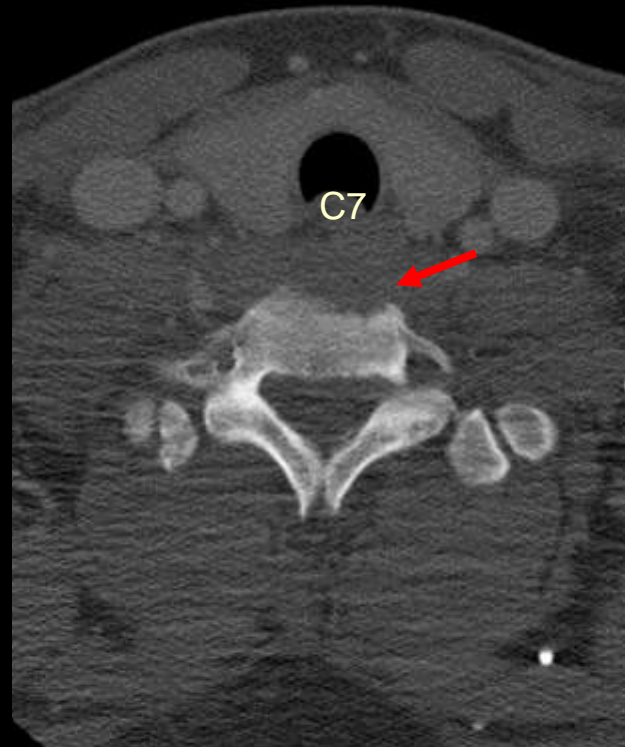
Reading Algorithm – Find the second fracture

C3,4,5,6,7 fxs



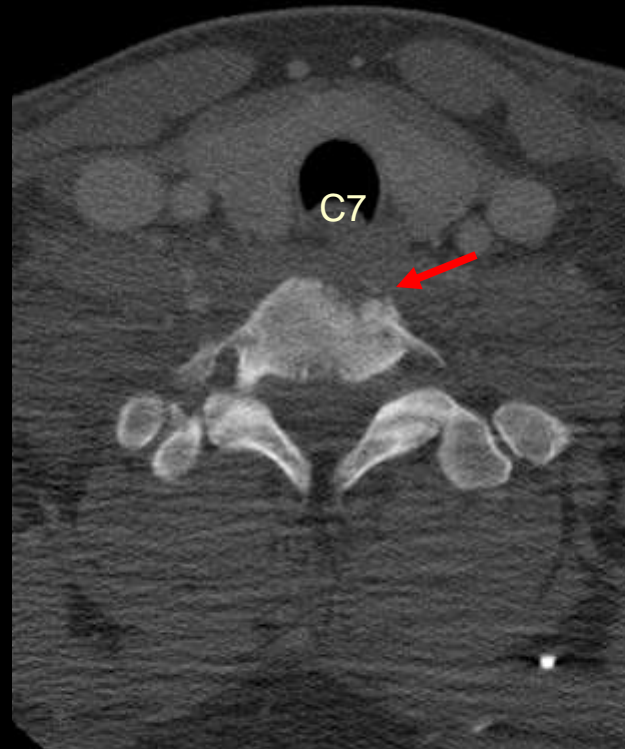
Reading Algorithm – Find the second fracture

C3,4,5,6,7 fxs

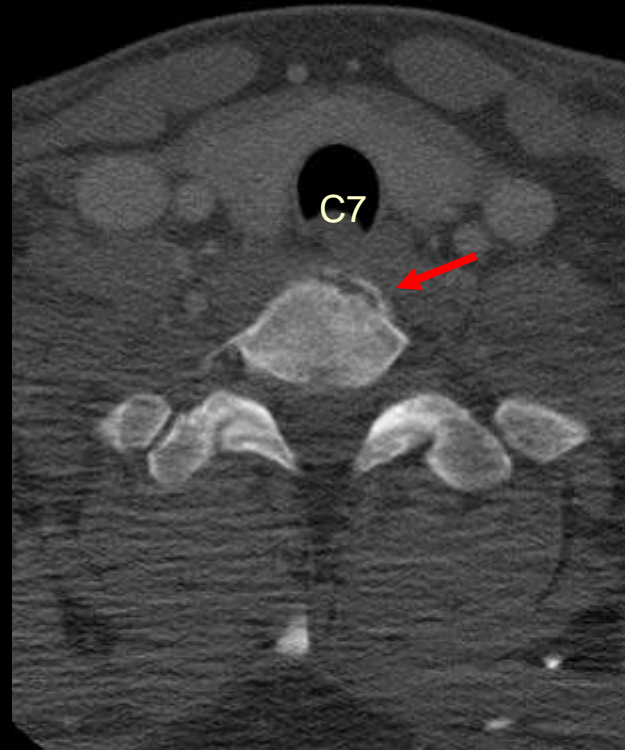


Reading Algorithm – Find the second fracture

C3,4,5,6,7 fxs

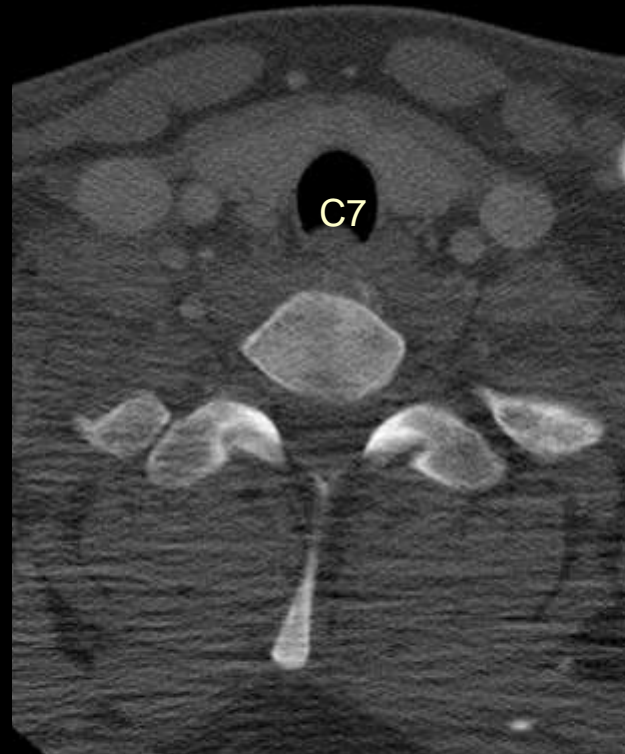


Reading Algorithm – Find the second fracture
C3,4,5,6,7 fxs

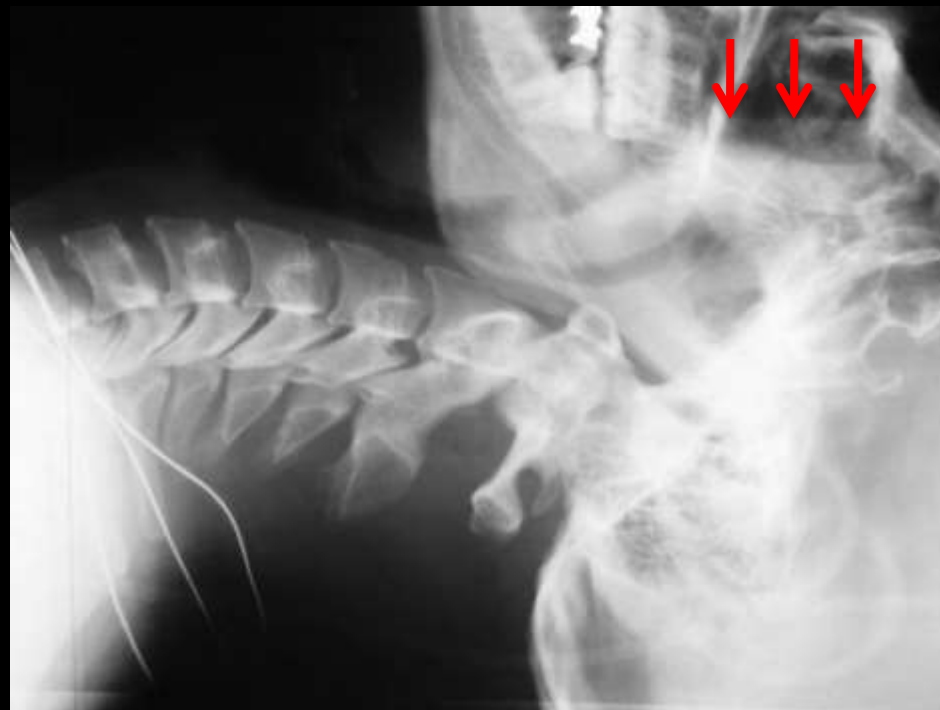
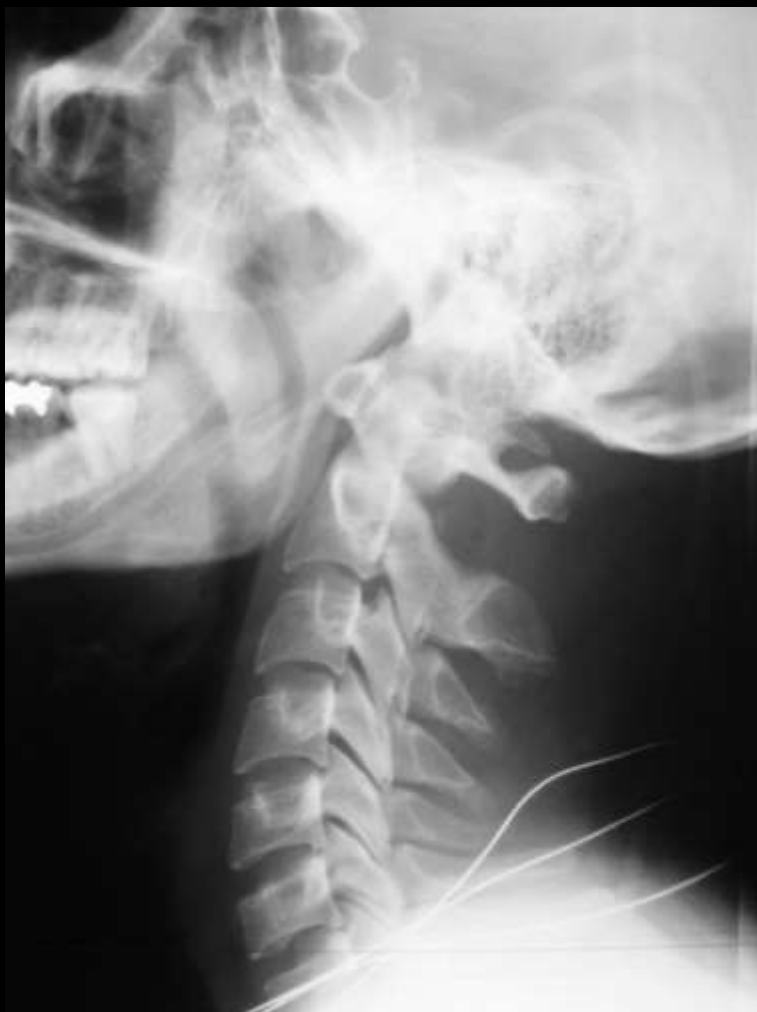

Reading Algorithm – Find the second fracture

C3,4,5,6,7 fxs

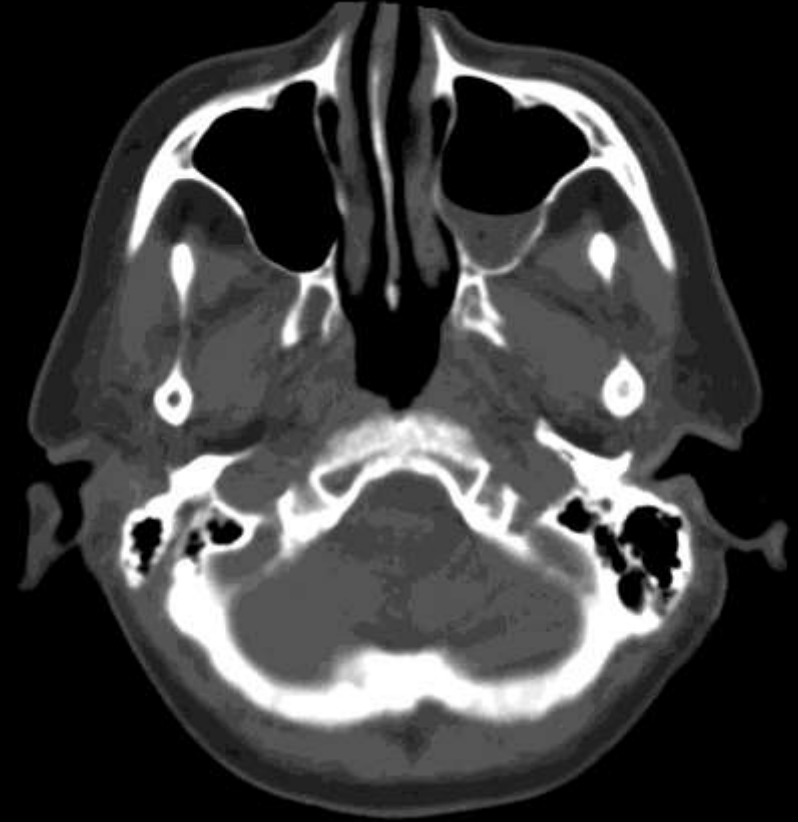
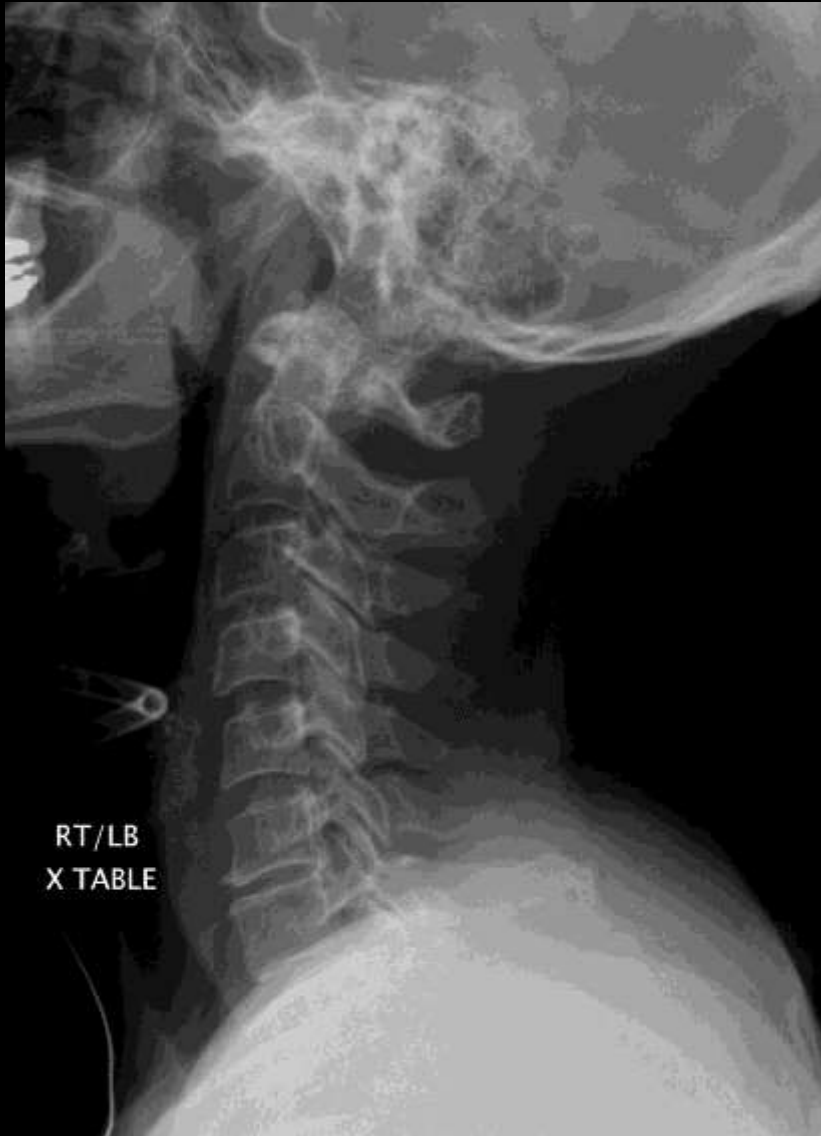

Facial Fx with fluid level on Cx spine



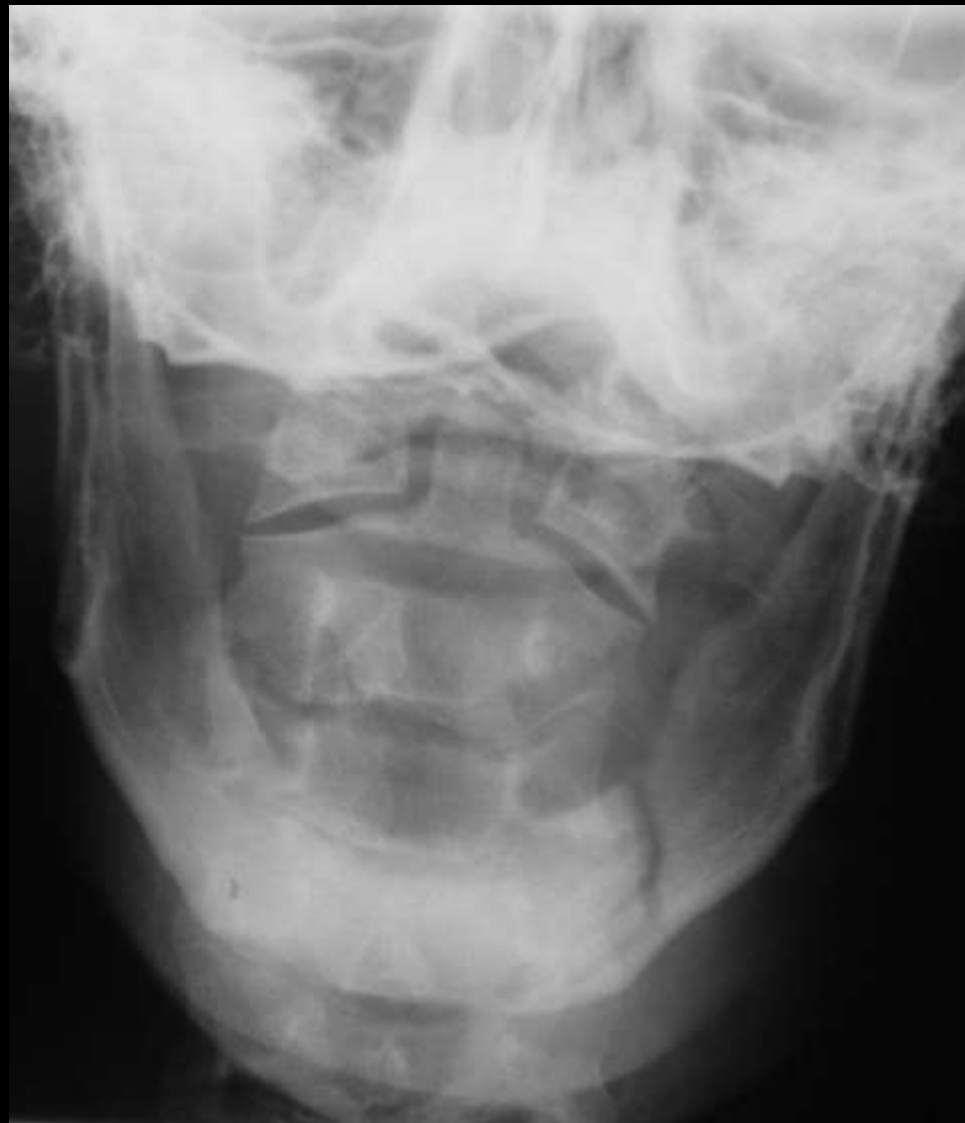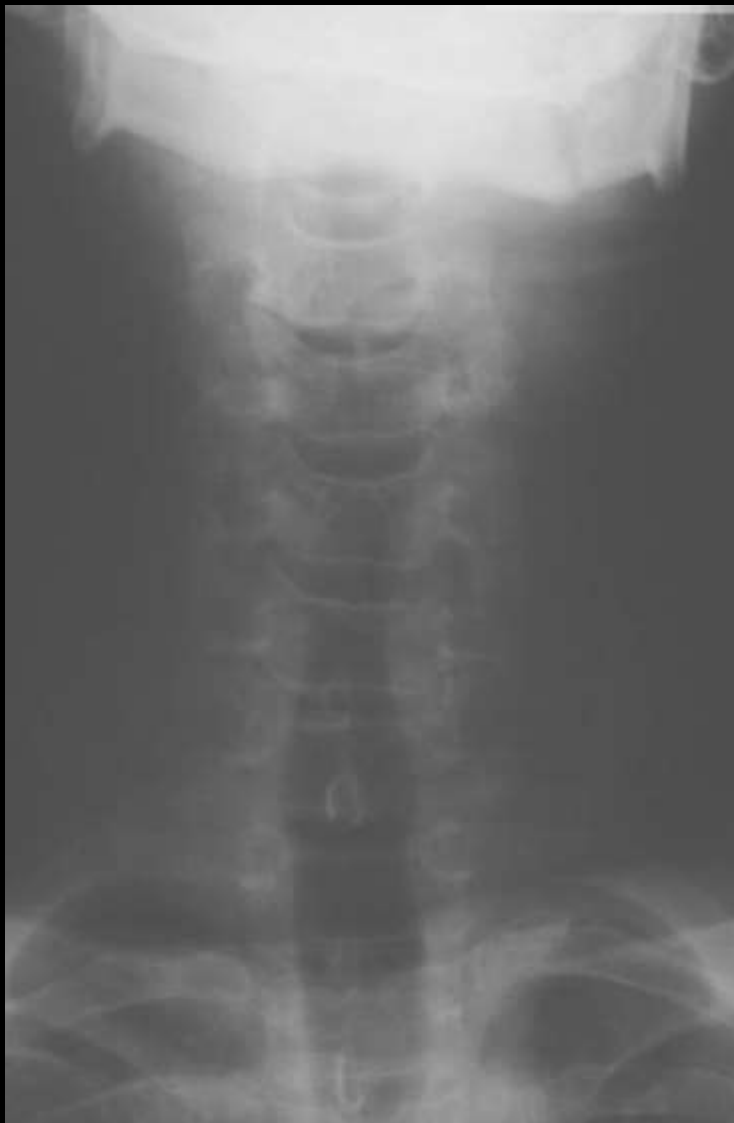Reading Algorithm – Adjacent Structures

Antral Fluid level on Cx spine



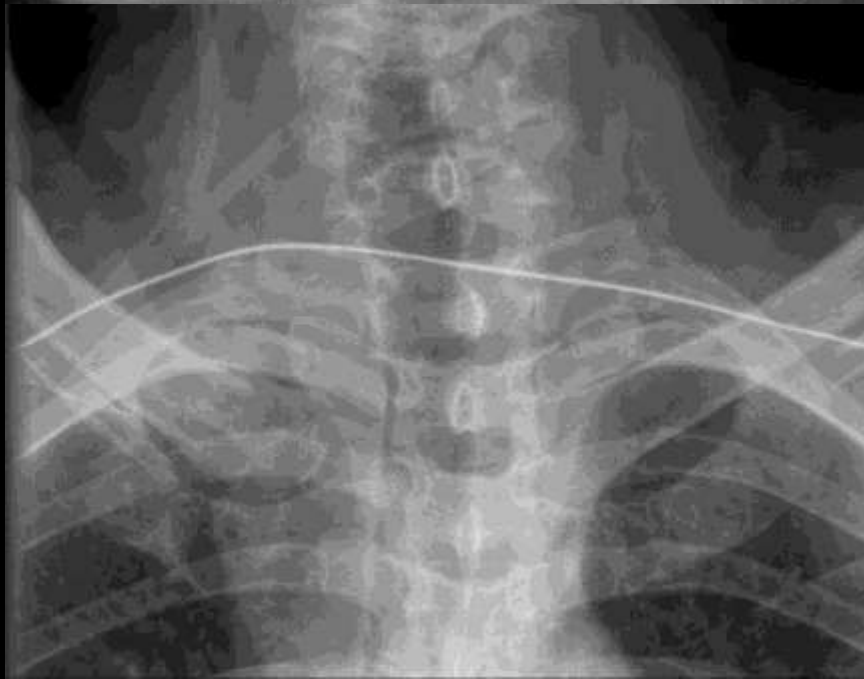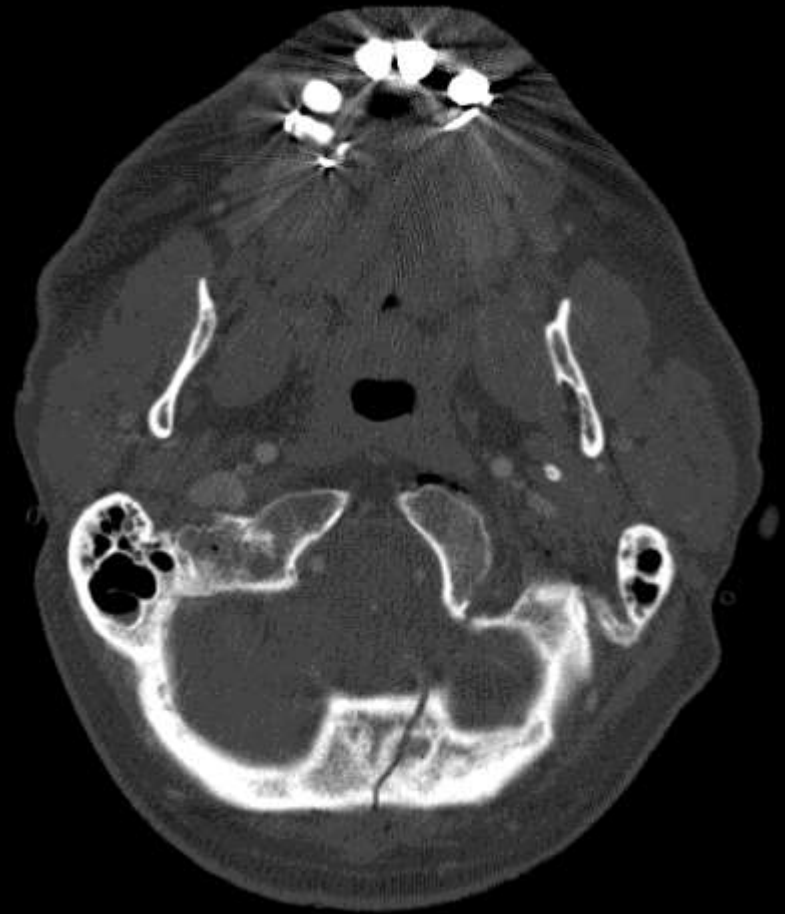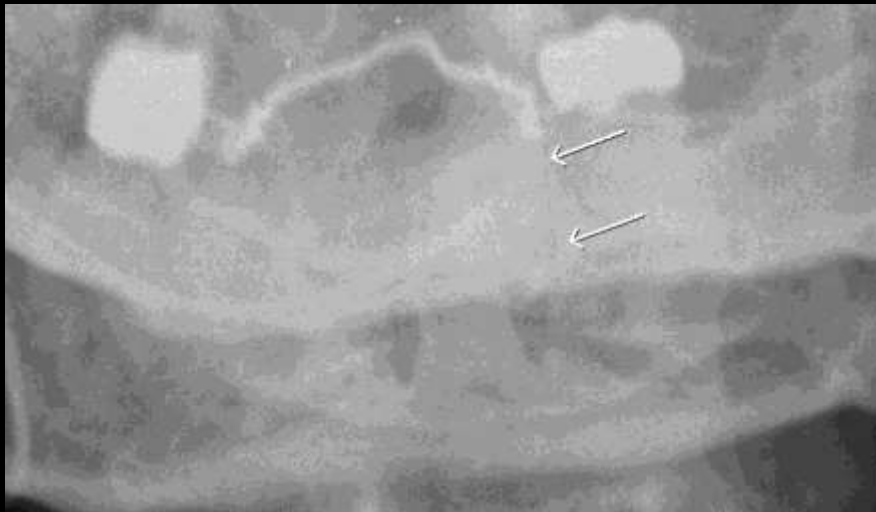Reading Algorithm

Adjacent Structures



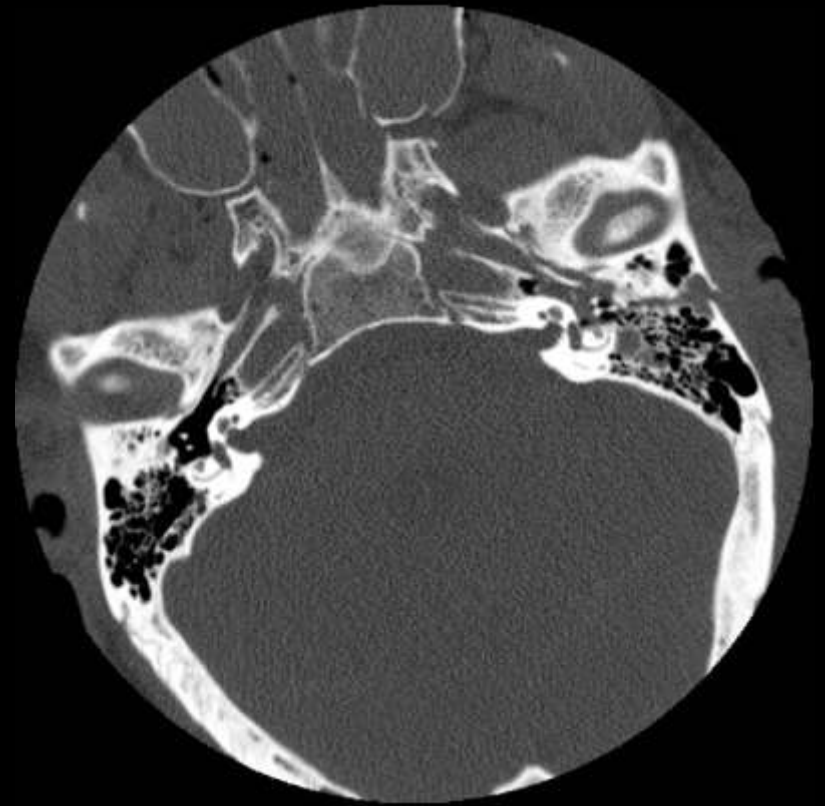
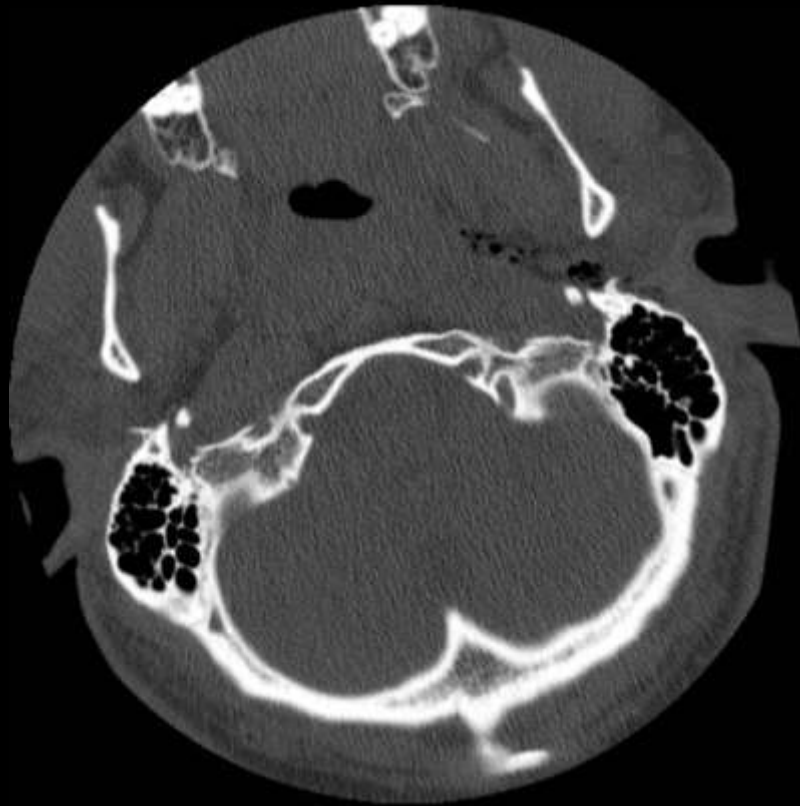Reading Algorithm

Adjacent Structures



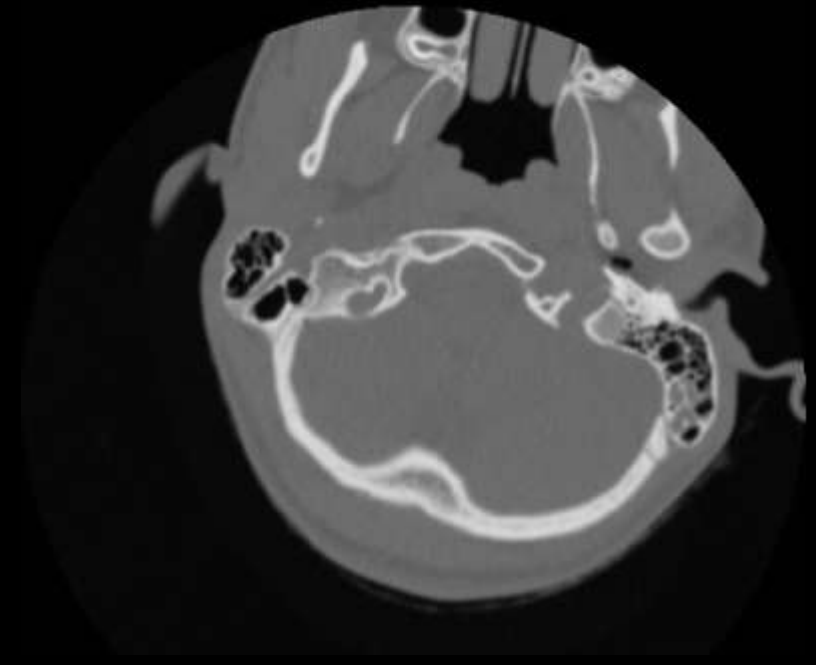
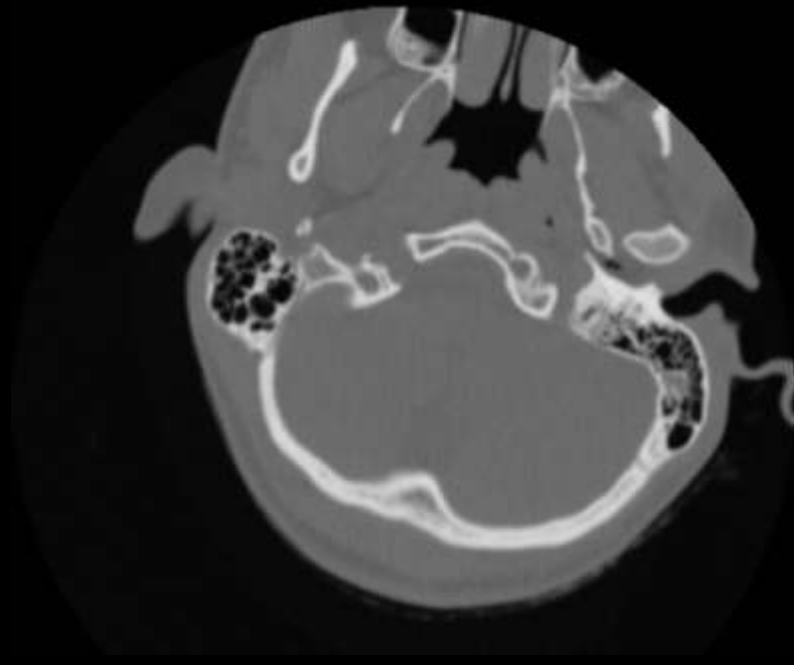
Reading Algorithm

Adjacent Structures



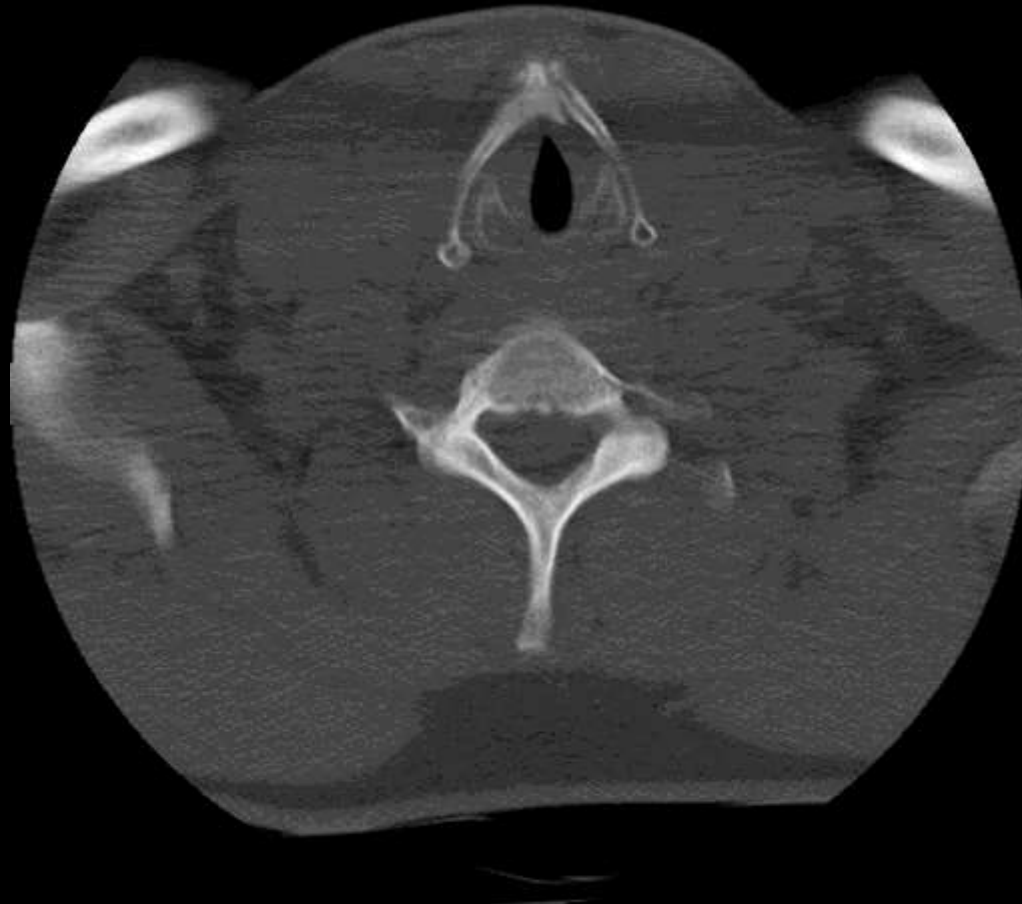Reading Algorithm

Adjacent Structures



Reading Algorithm

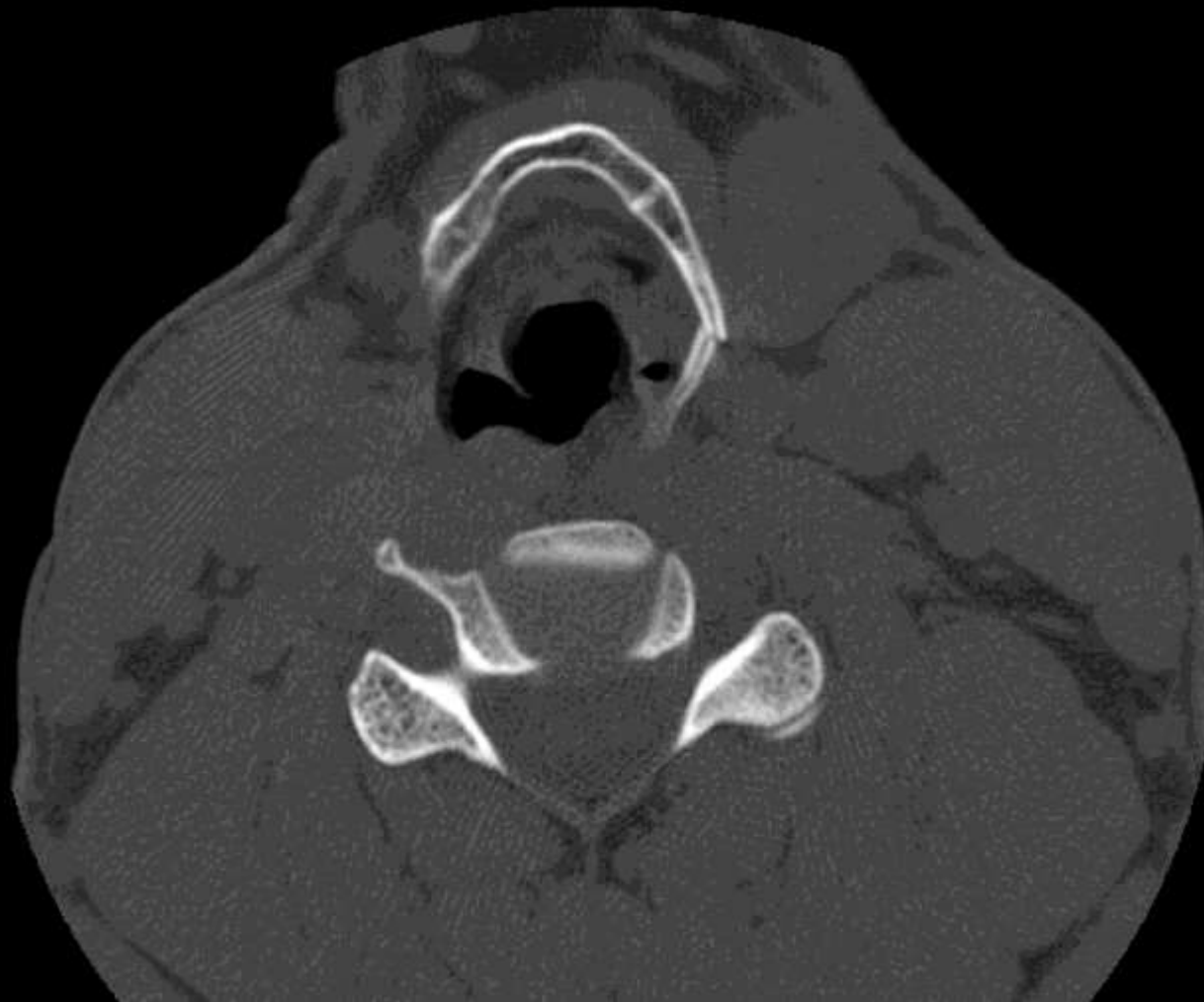Adjacent Structures



W 2000 : L 500

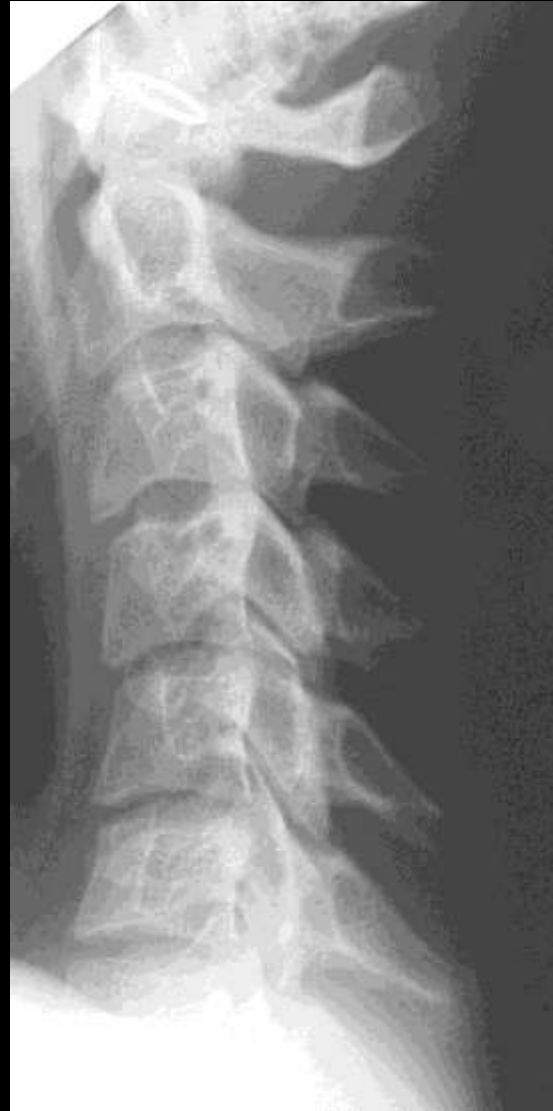Reading Algorithm

Adjacent Structures



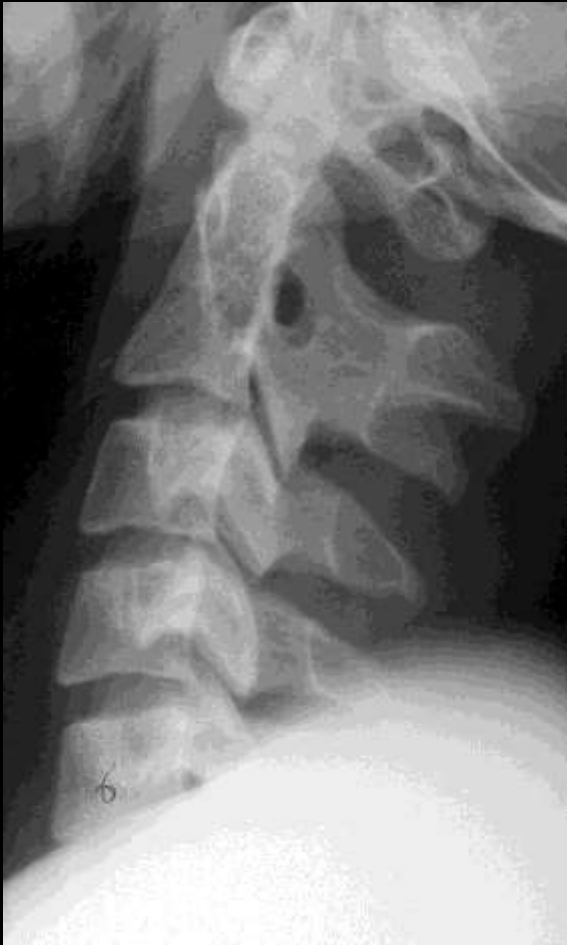

Predisposing Factors

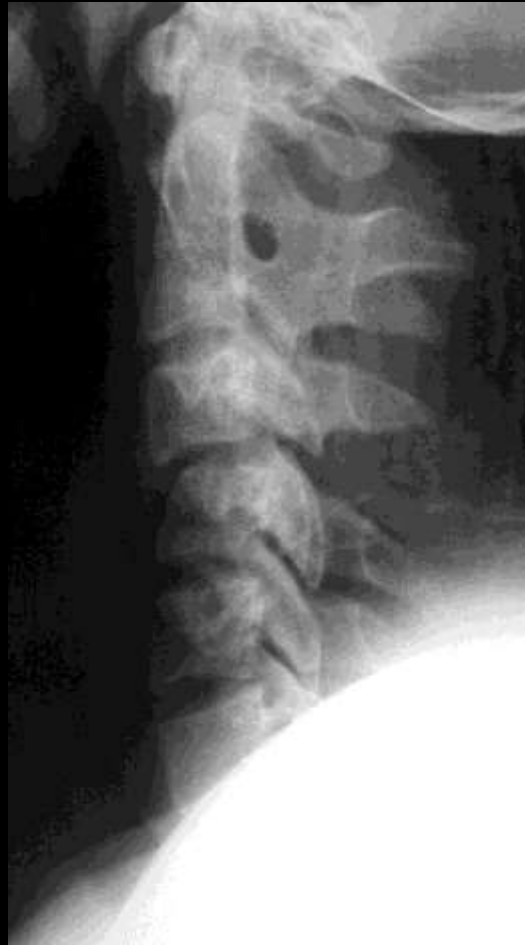

Predisposing Factors

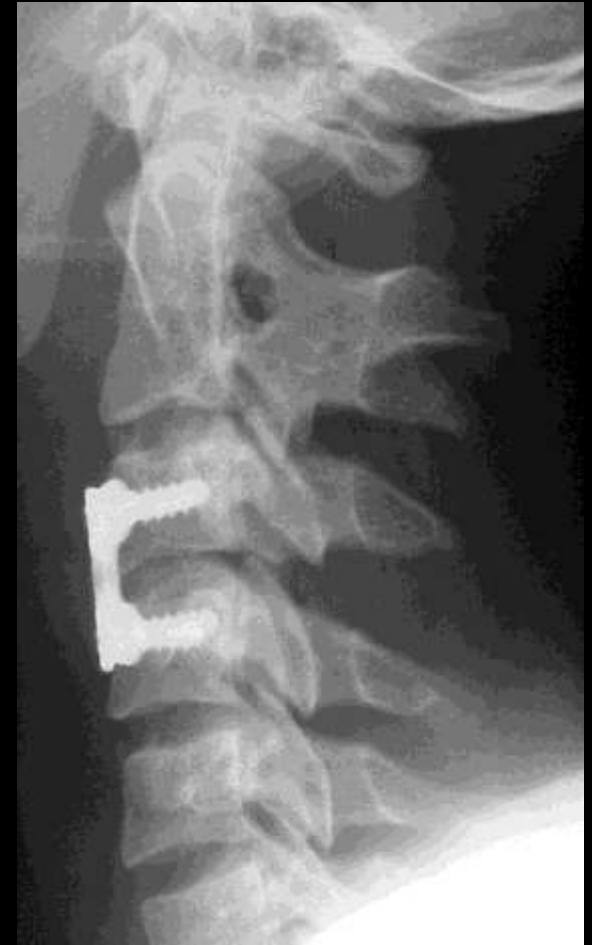Congenital Fusion



Presentation



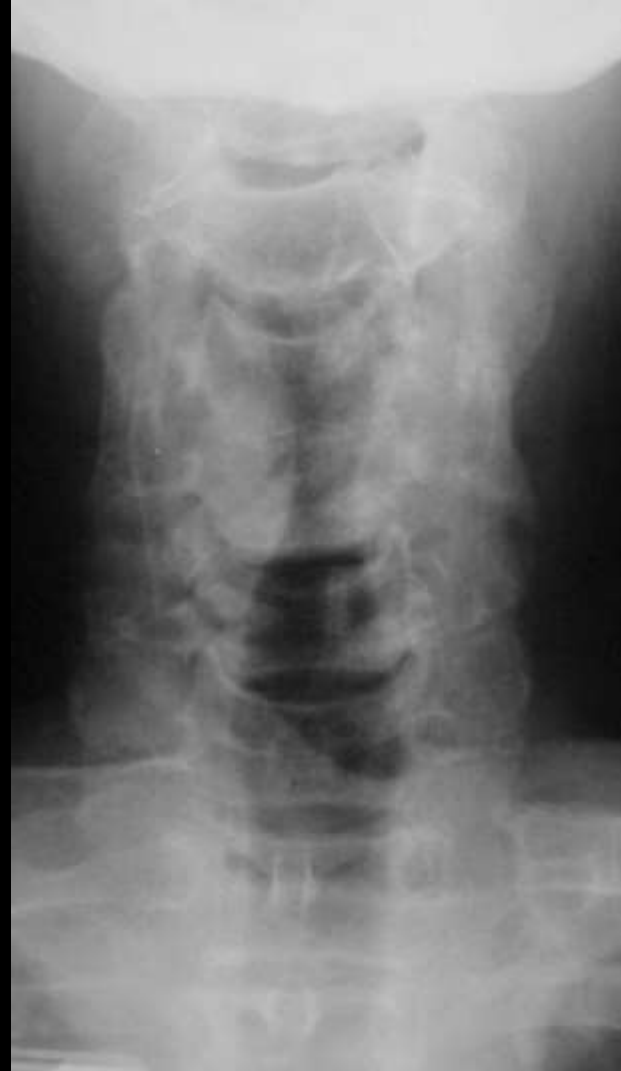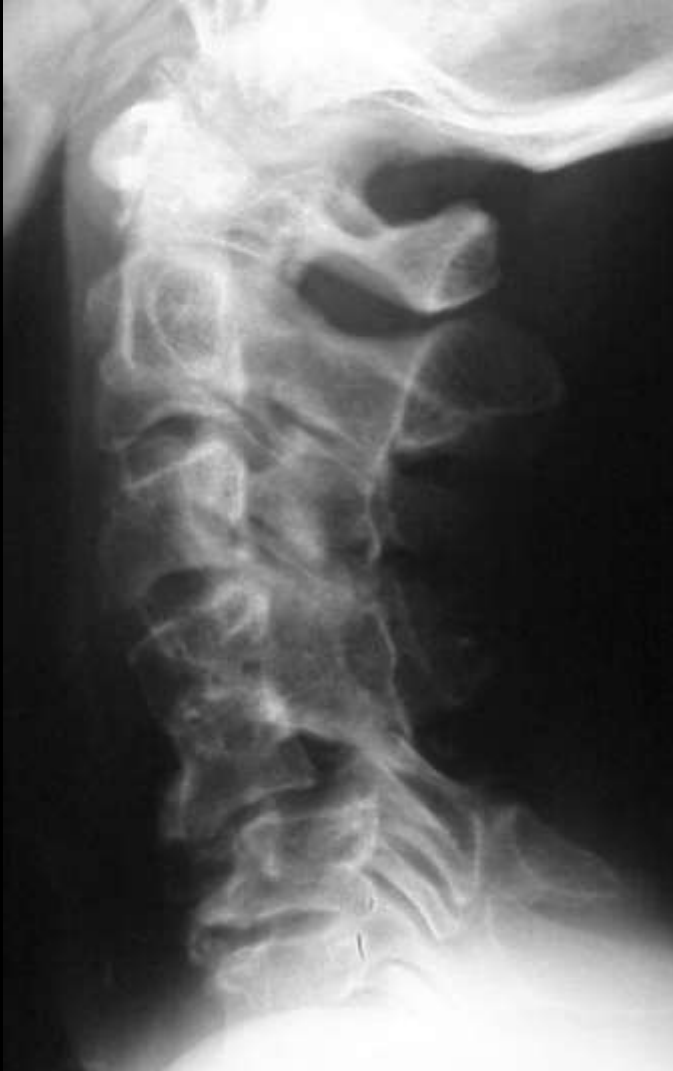Follow up



Rx

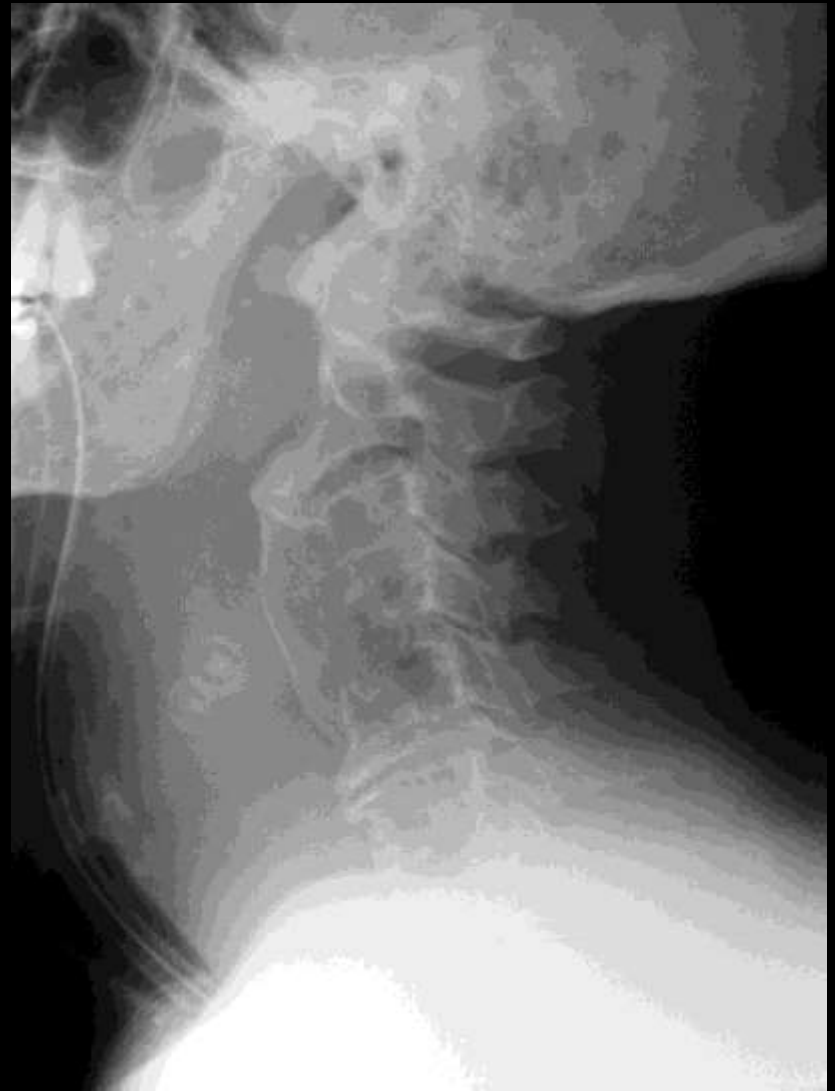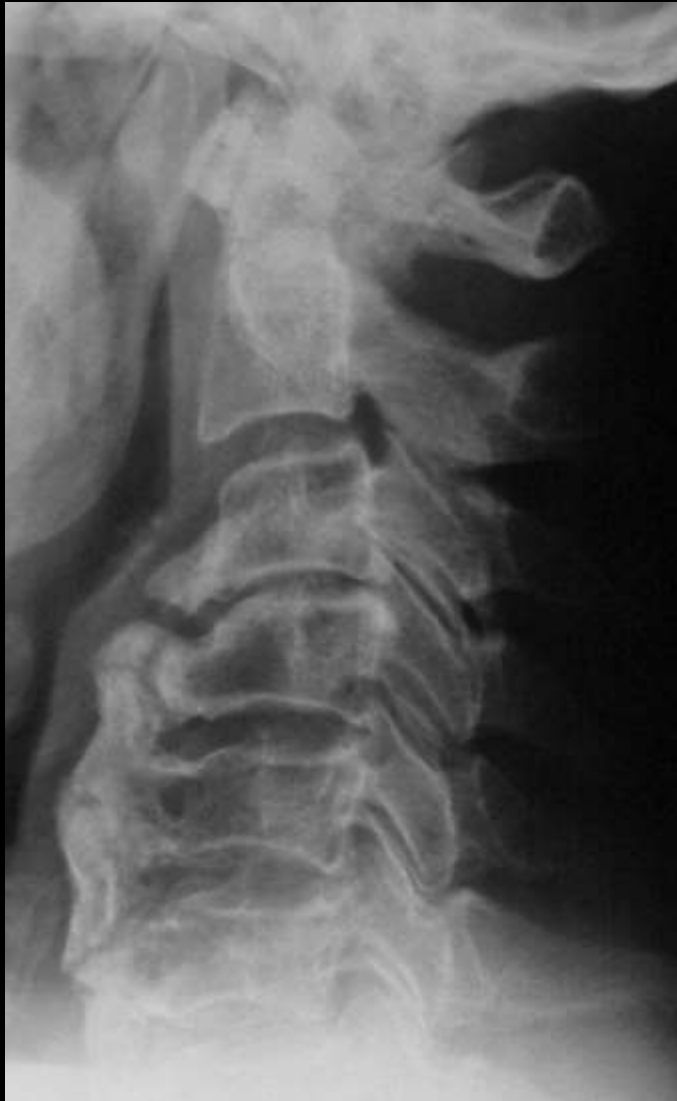Delayed flexion subluxation C4-5

Predisposing Factors
Klippel Feil



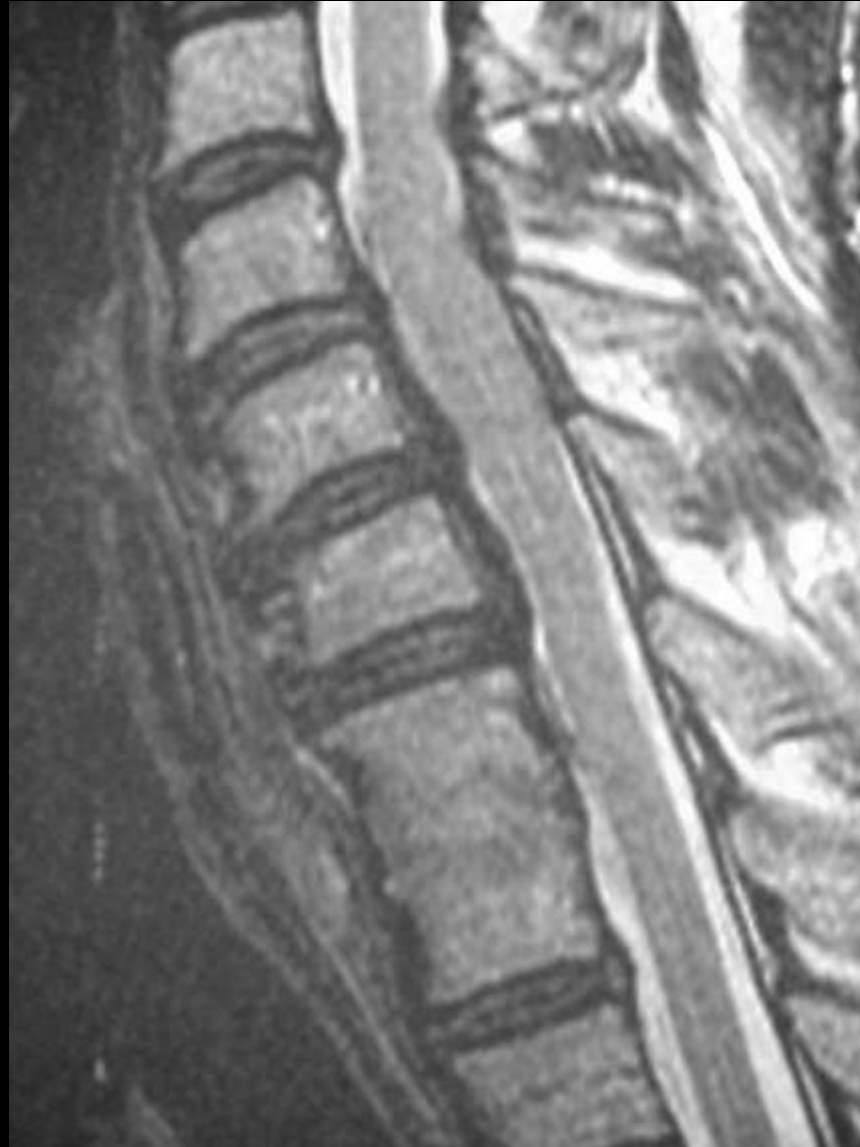Predisposing Factors

DISH

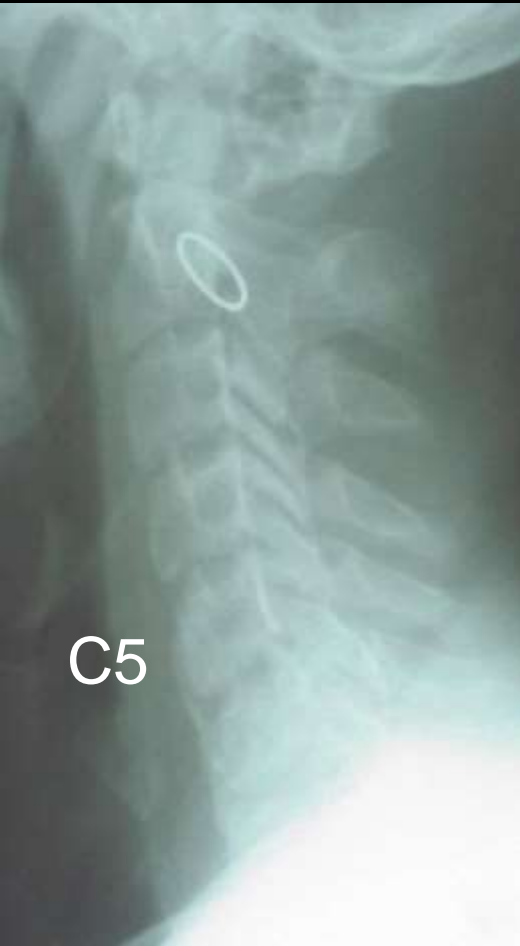

Predisposing Factors

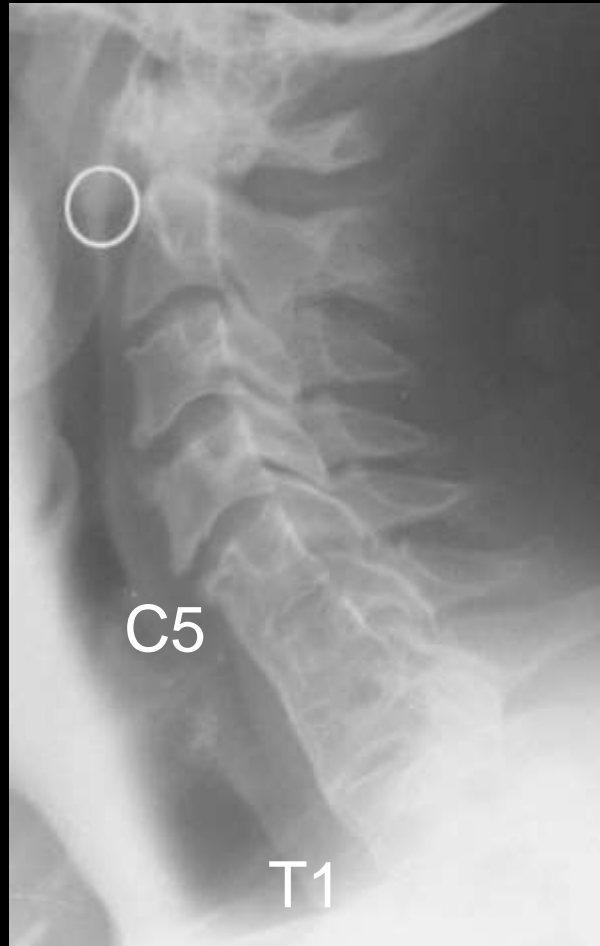OPLL



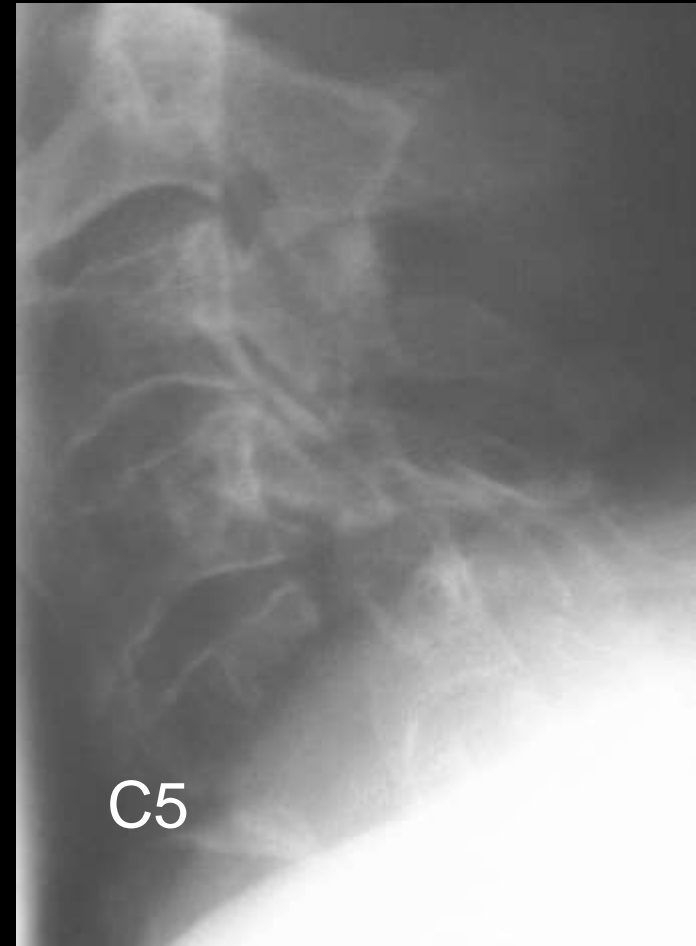Predisposing Factors Post Traumatic Fusion



1971



1972

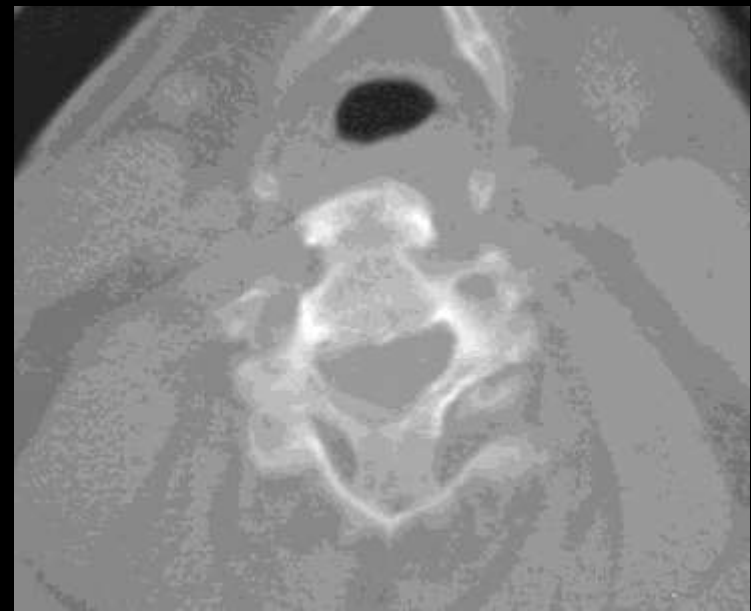
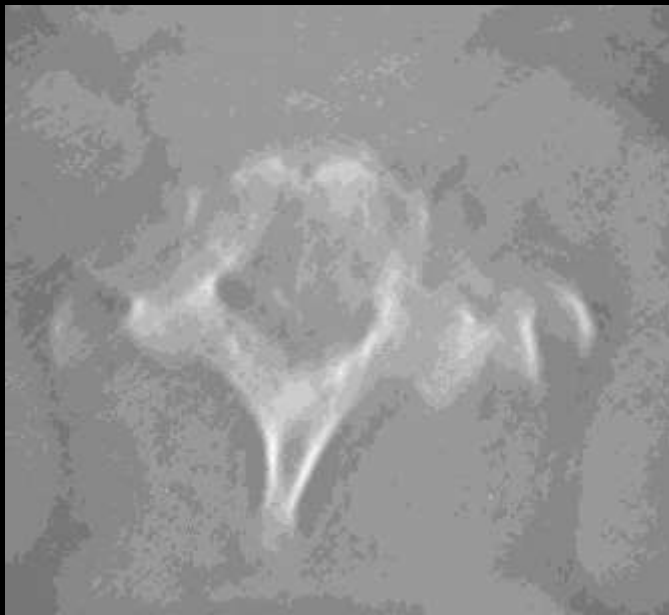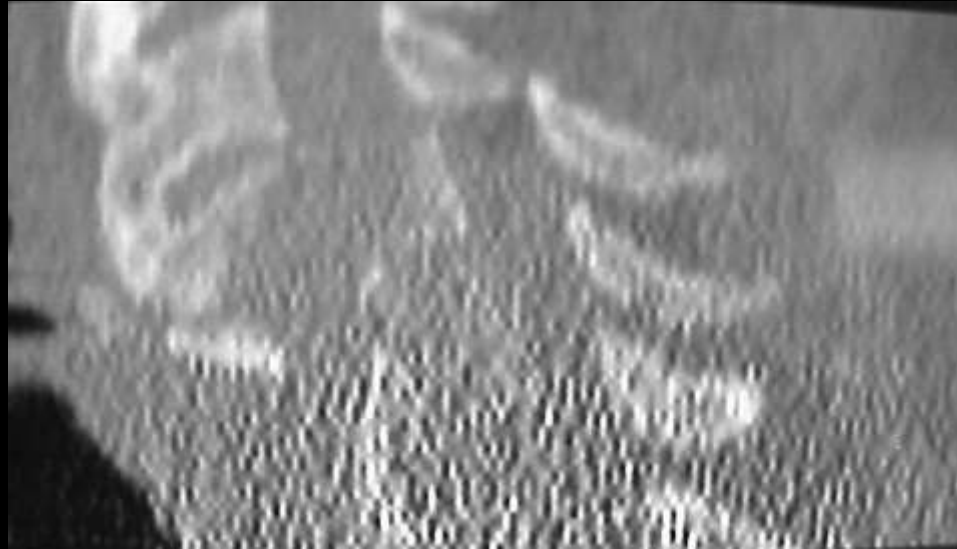


2000

51M

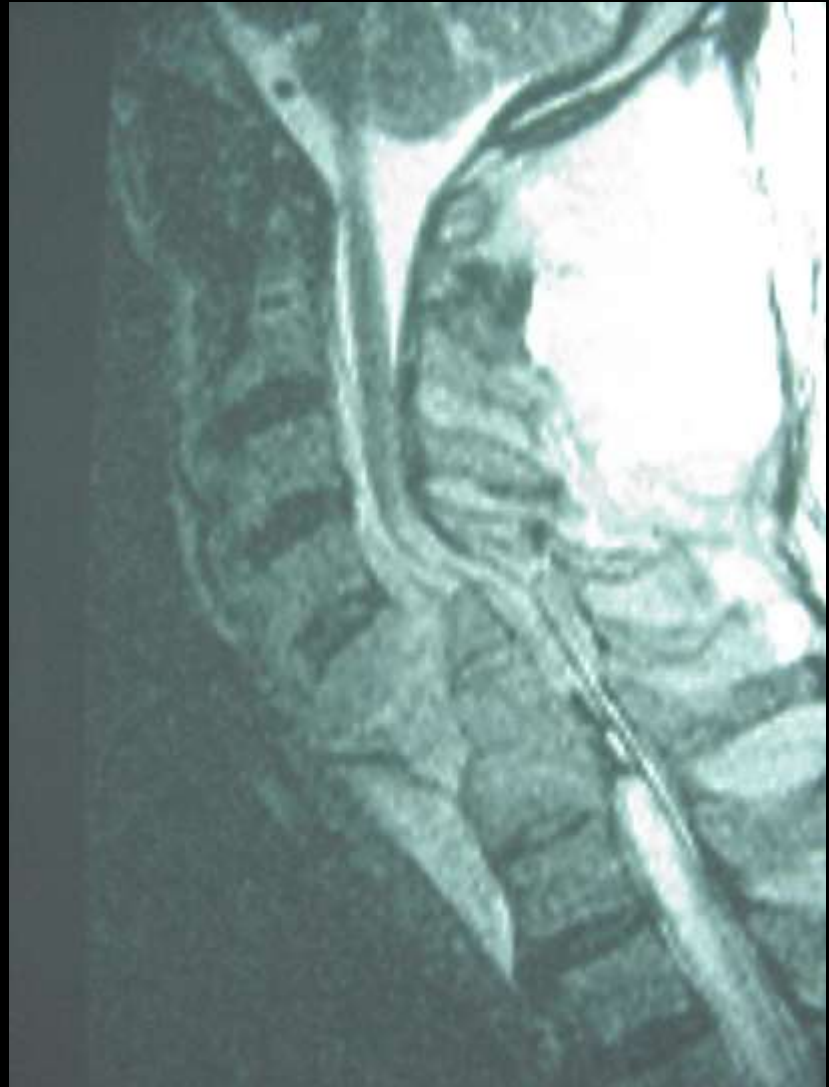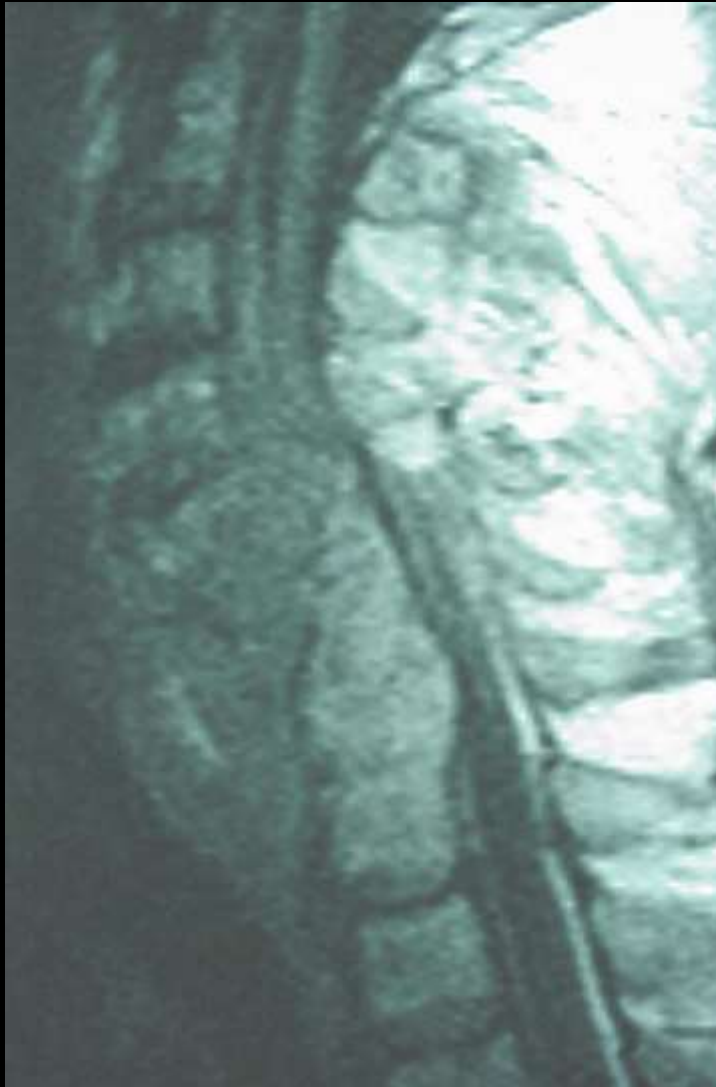
Predisposing Factors

Post Traumatic Fusion



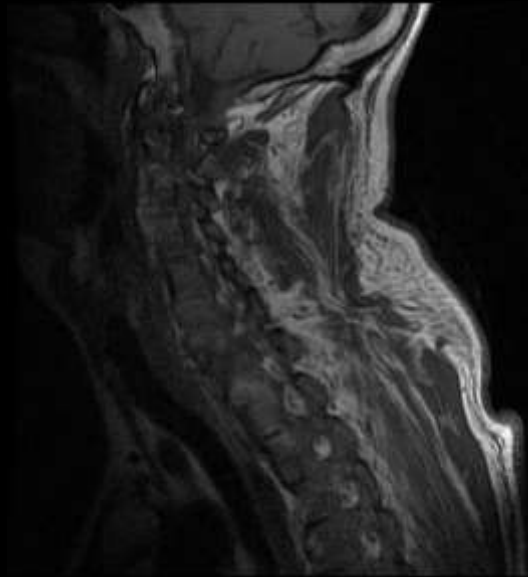
Predisposing Factors

Post Traumatic Fusion

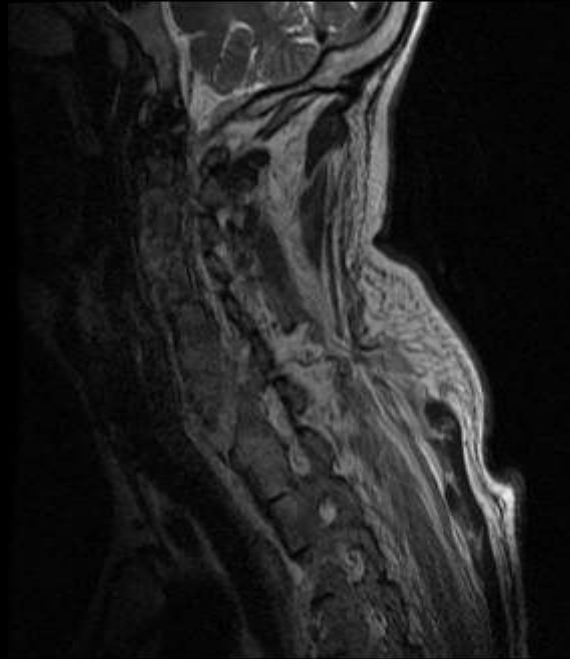


Predisposing Factors

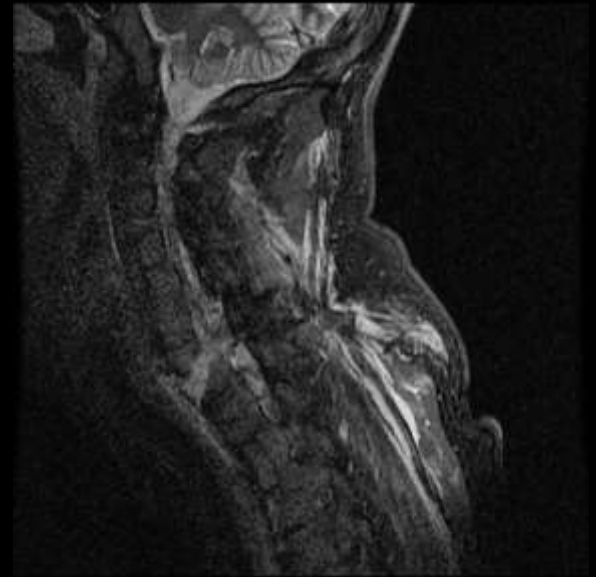
Ankylosing Spondylitis



Sag T1



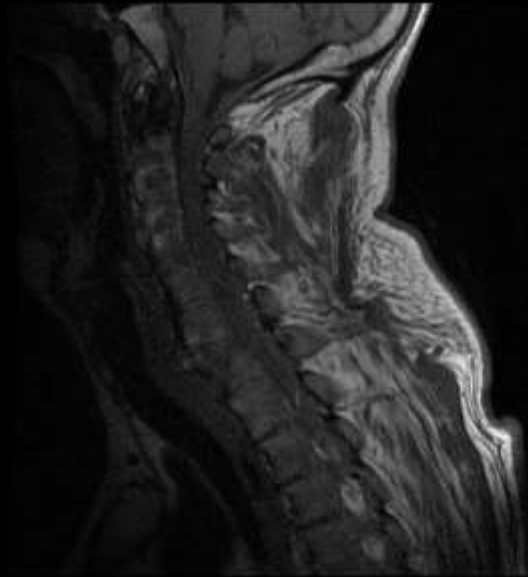
Sag T2



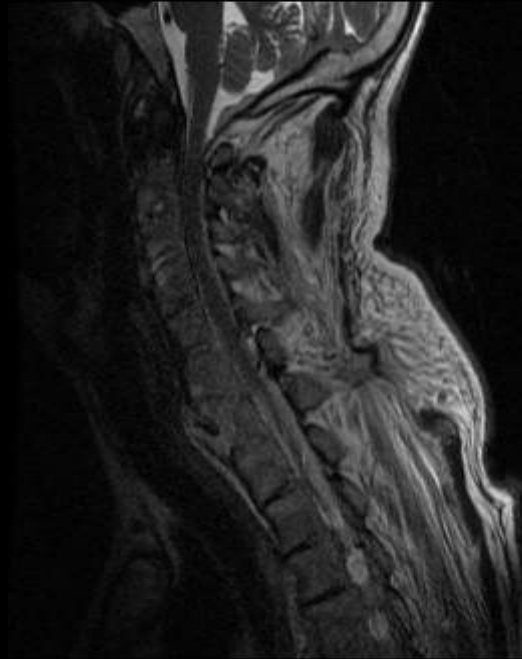Sag T2FS

Predisposing Factors

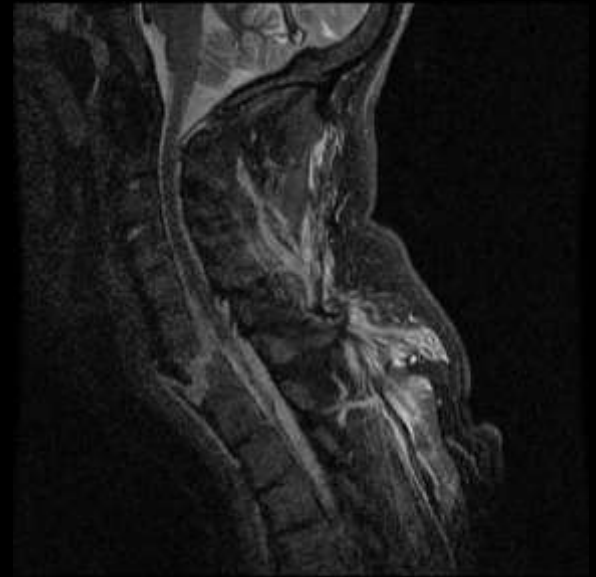Ankylosing Spondylitis



Sag T1



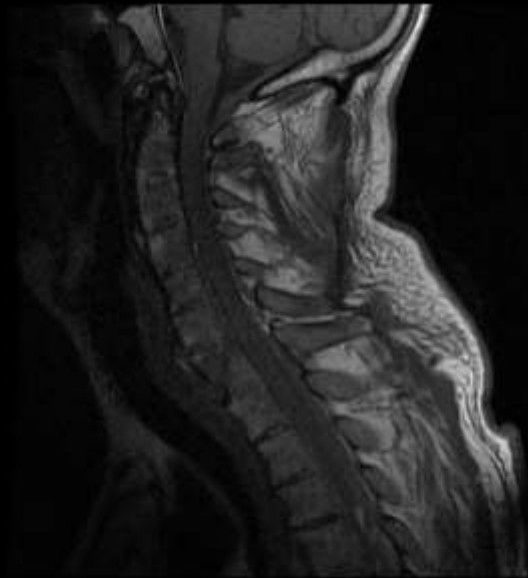Sag T2



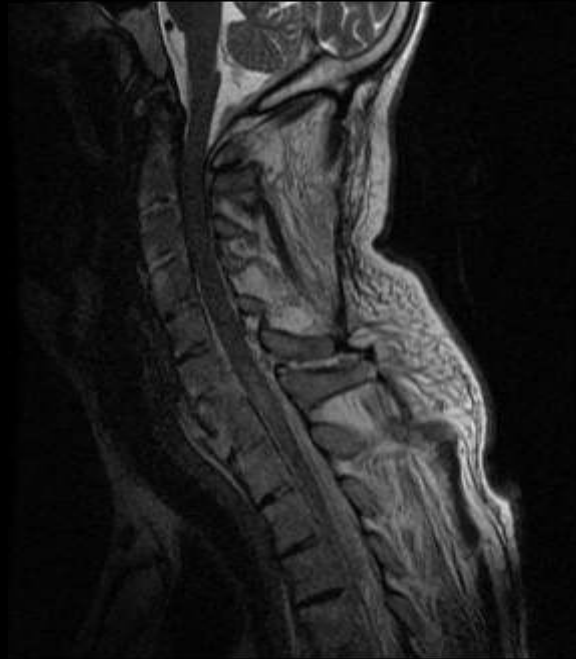Sag T2FS

Predisposing Factors

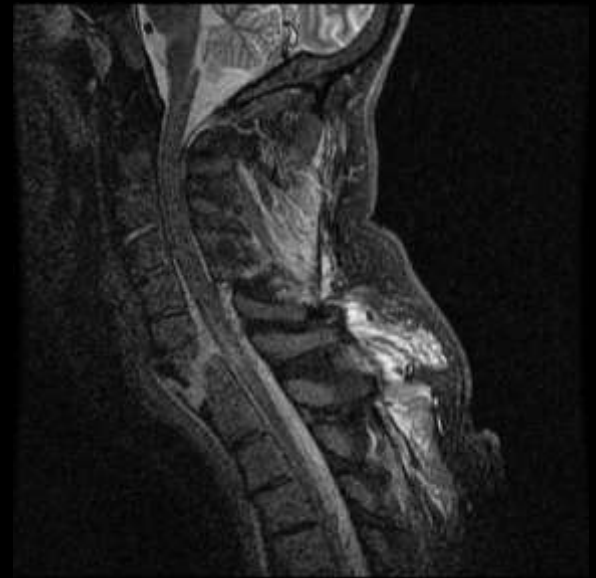
Ankylosing Spondylitis



Sag T1



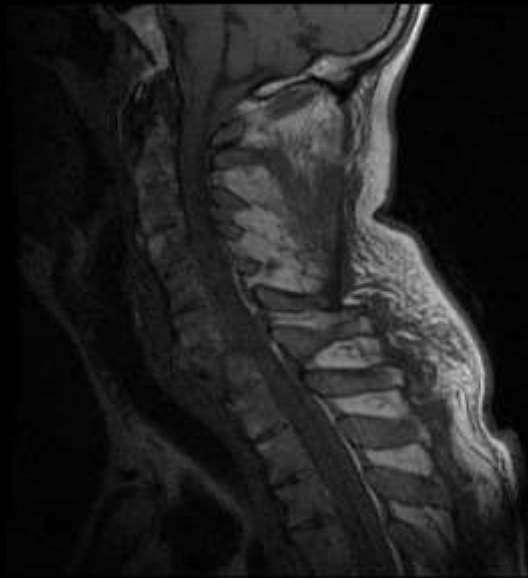Sag T2



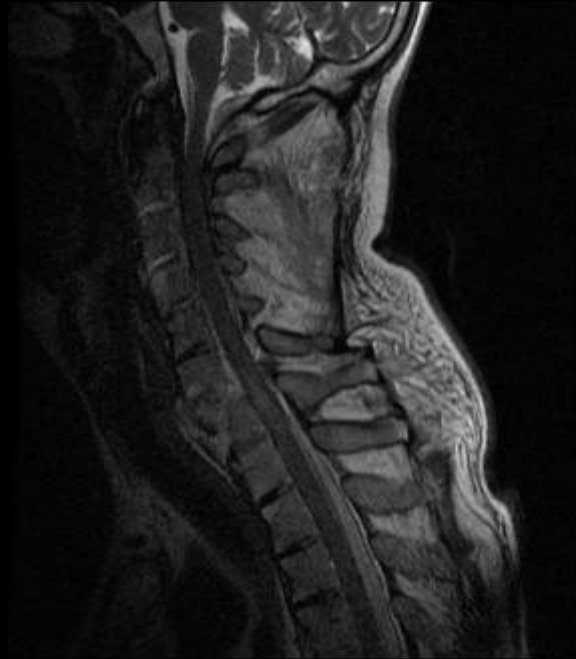Sag T2FS

Predisposing Factors

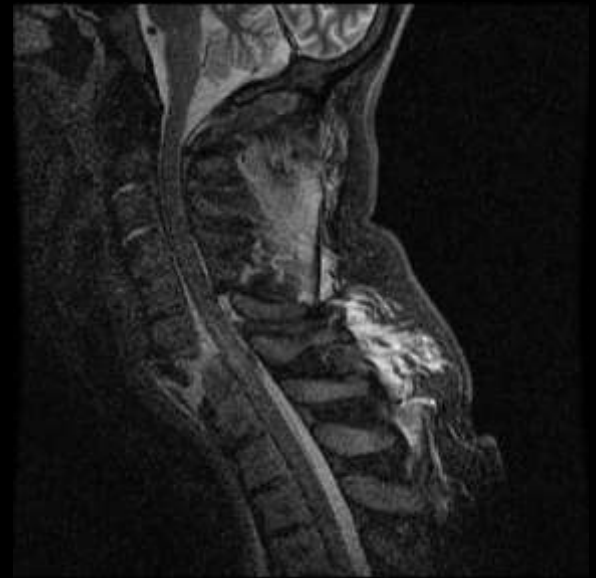
Ankylosing Spondylitis



Sag T1



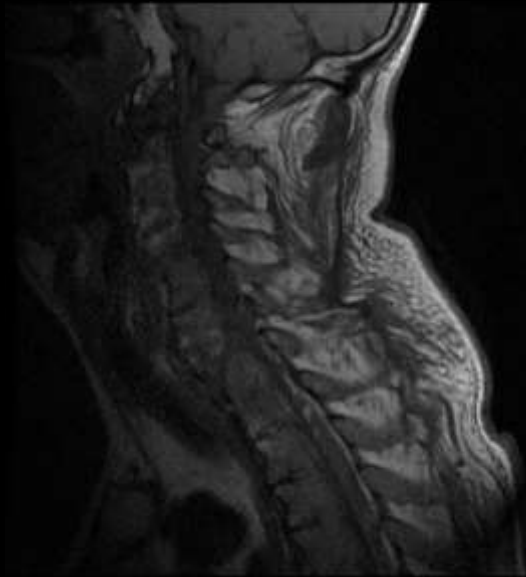
Sag T2



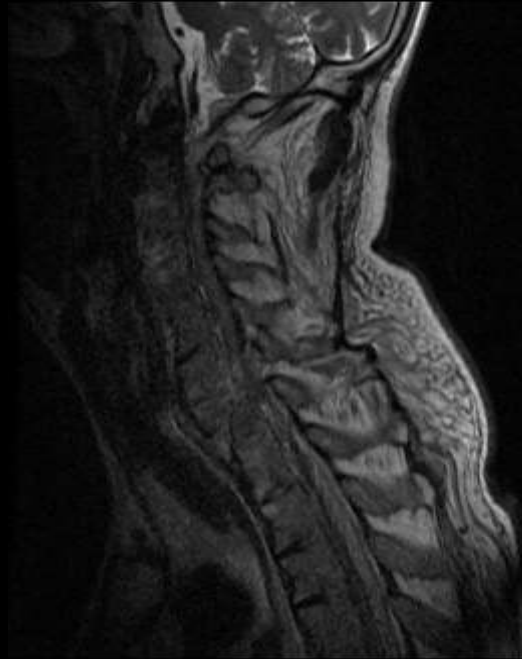Sag T2FS

Predisposing Factors

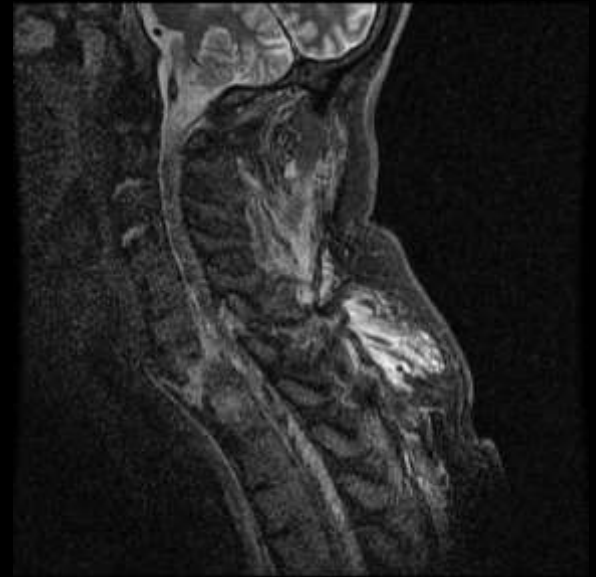
Ankylosing Spondylitis



Sag T1



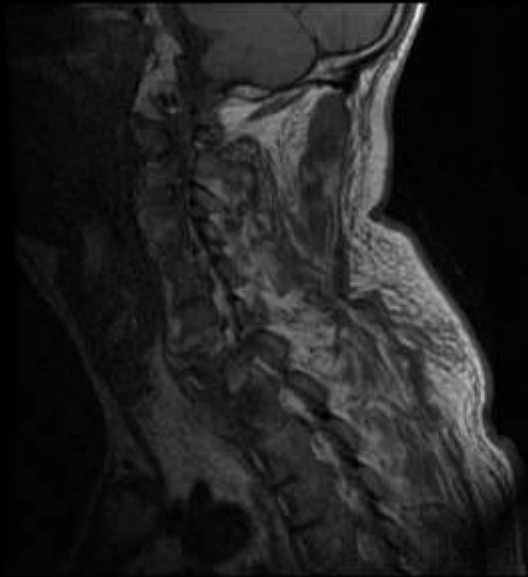
Sag T2



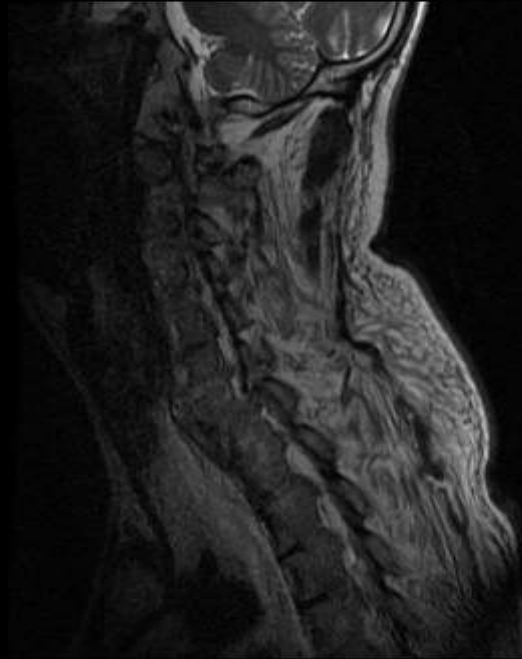
Sag T2FS

Predisposing Factors

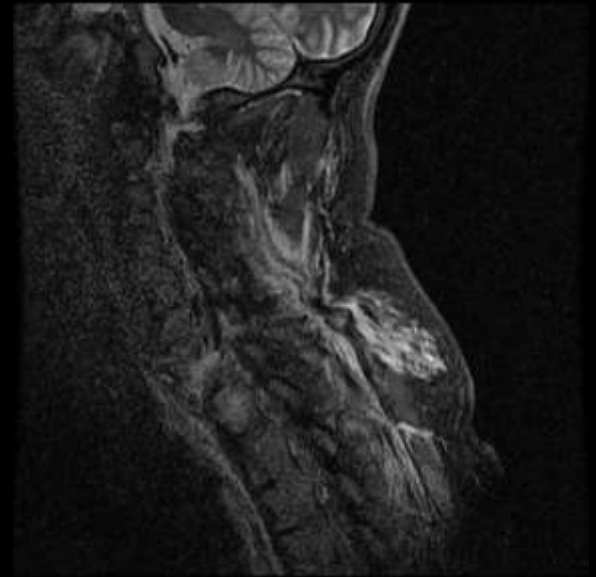
Ankylosing Spondylitis



Sag T1



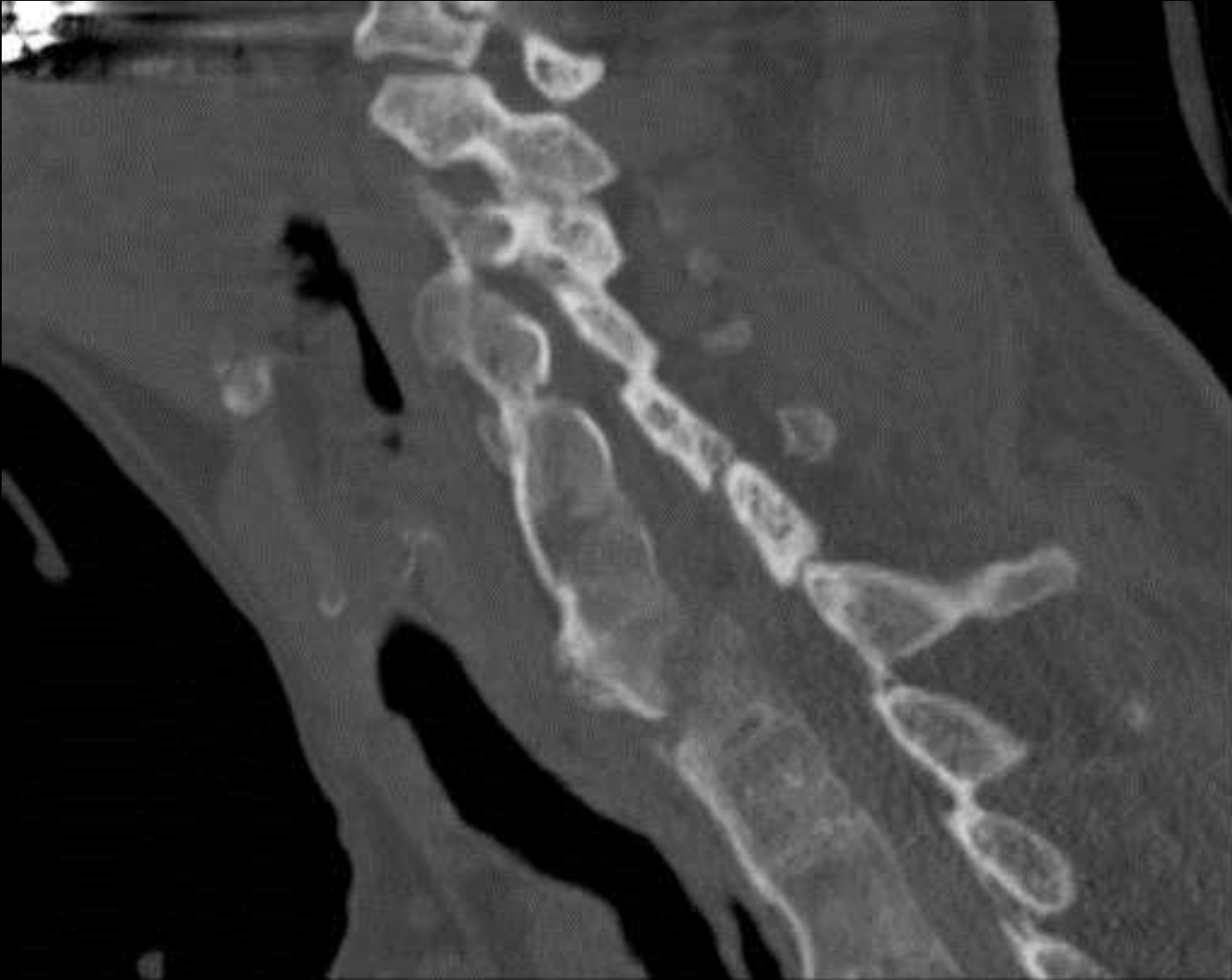Sag T2



Sag T2FS

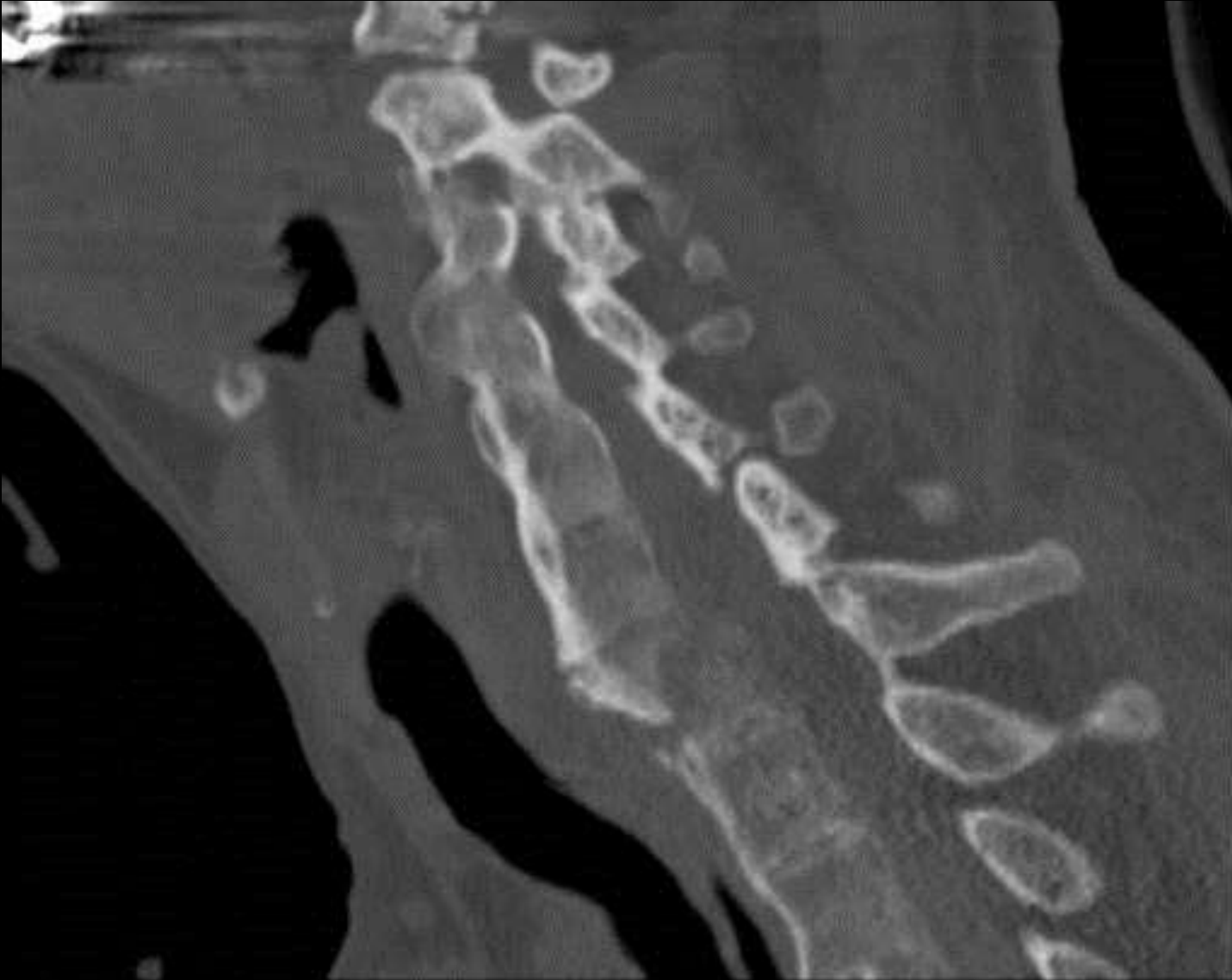Predisposing Factors

Ankylosing Spondylitis



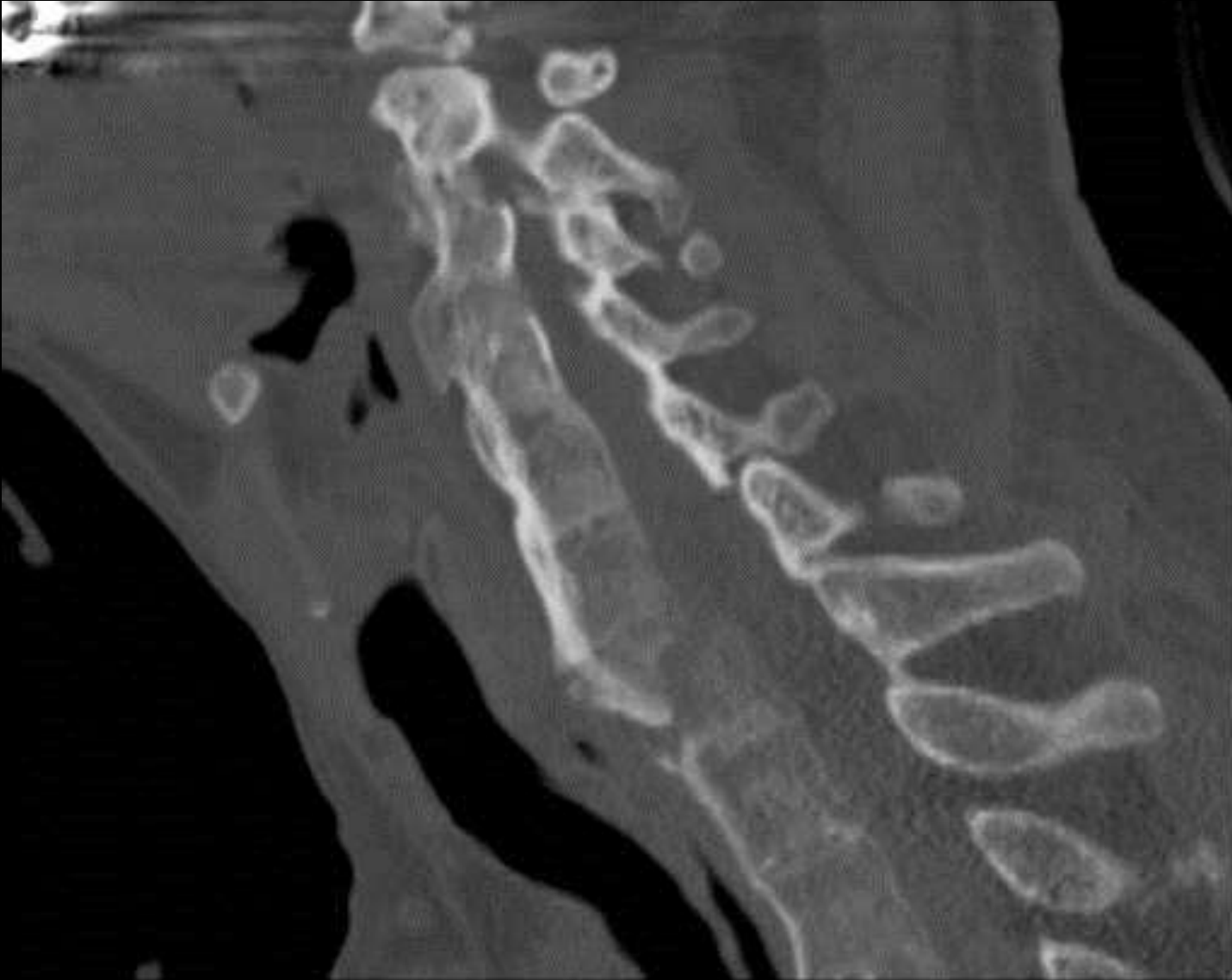Predisposing Factors

Ankylosing Spondylitis



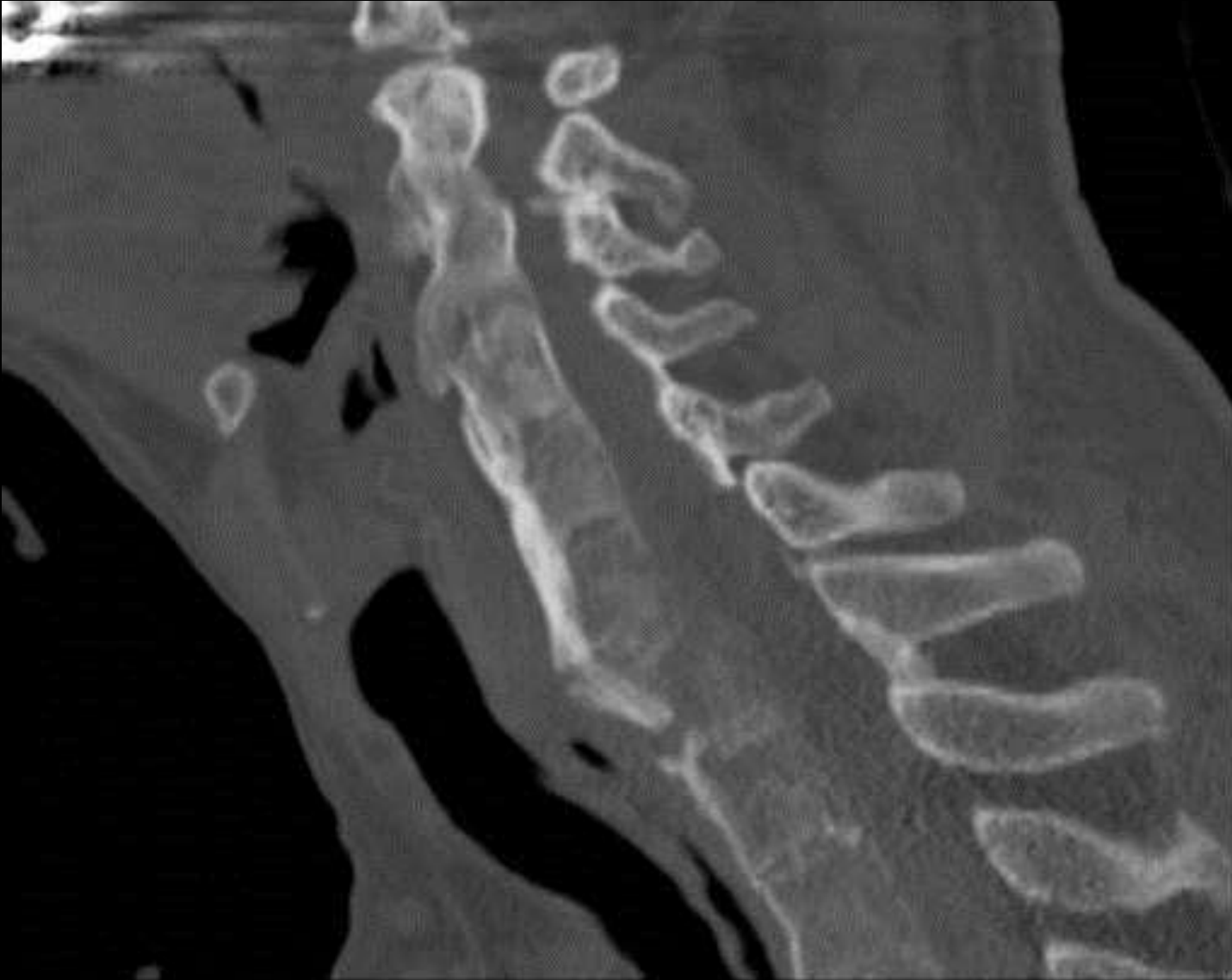Predisposing Factors

Ankylosing Spondylitis



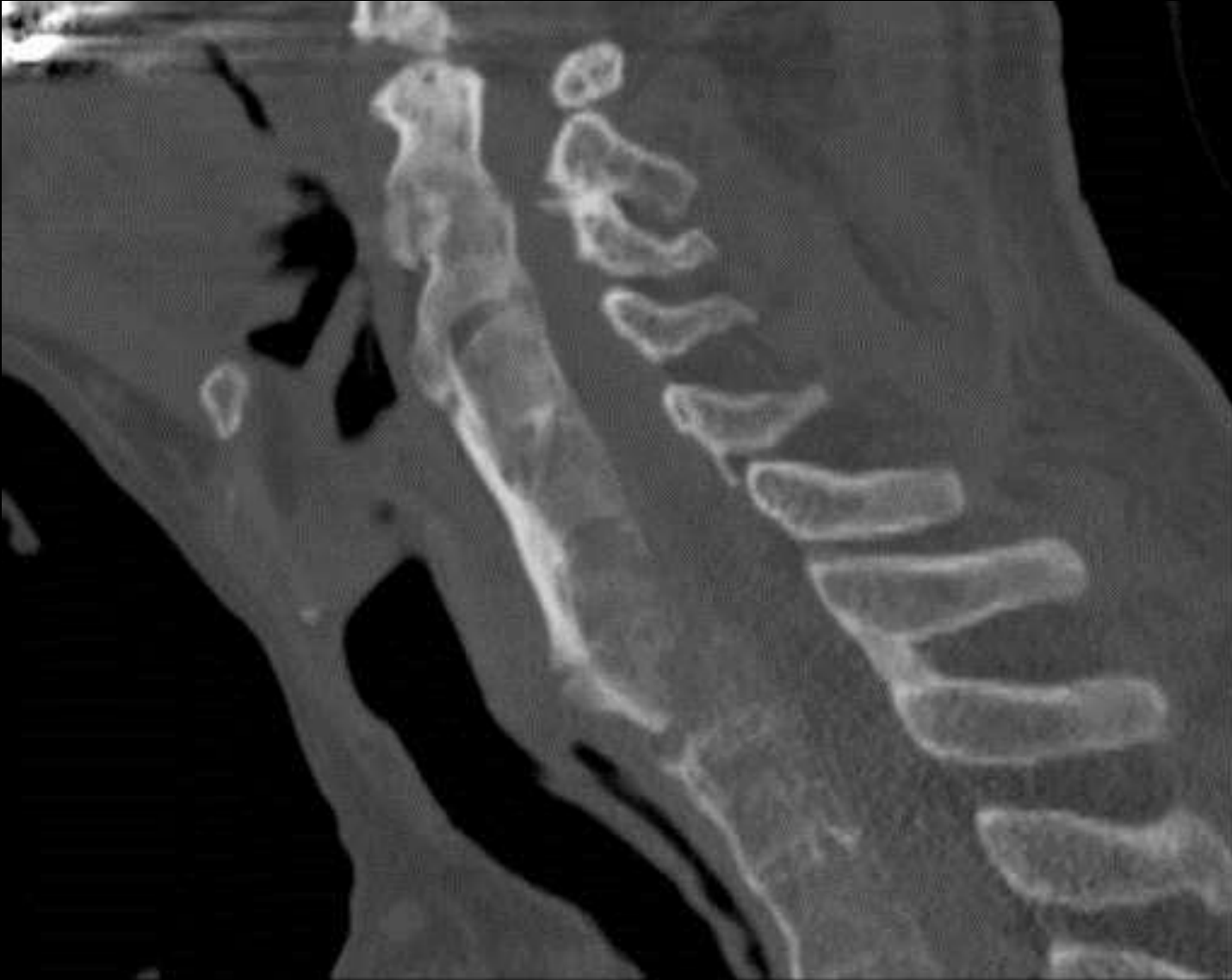Predisposing Factors

Ankylosing Spondylitis



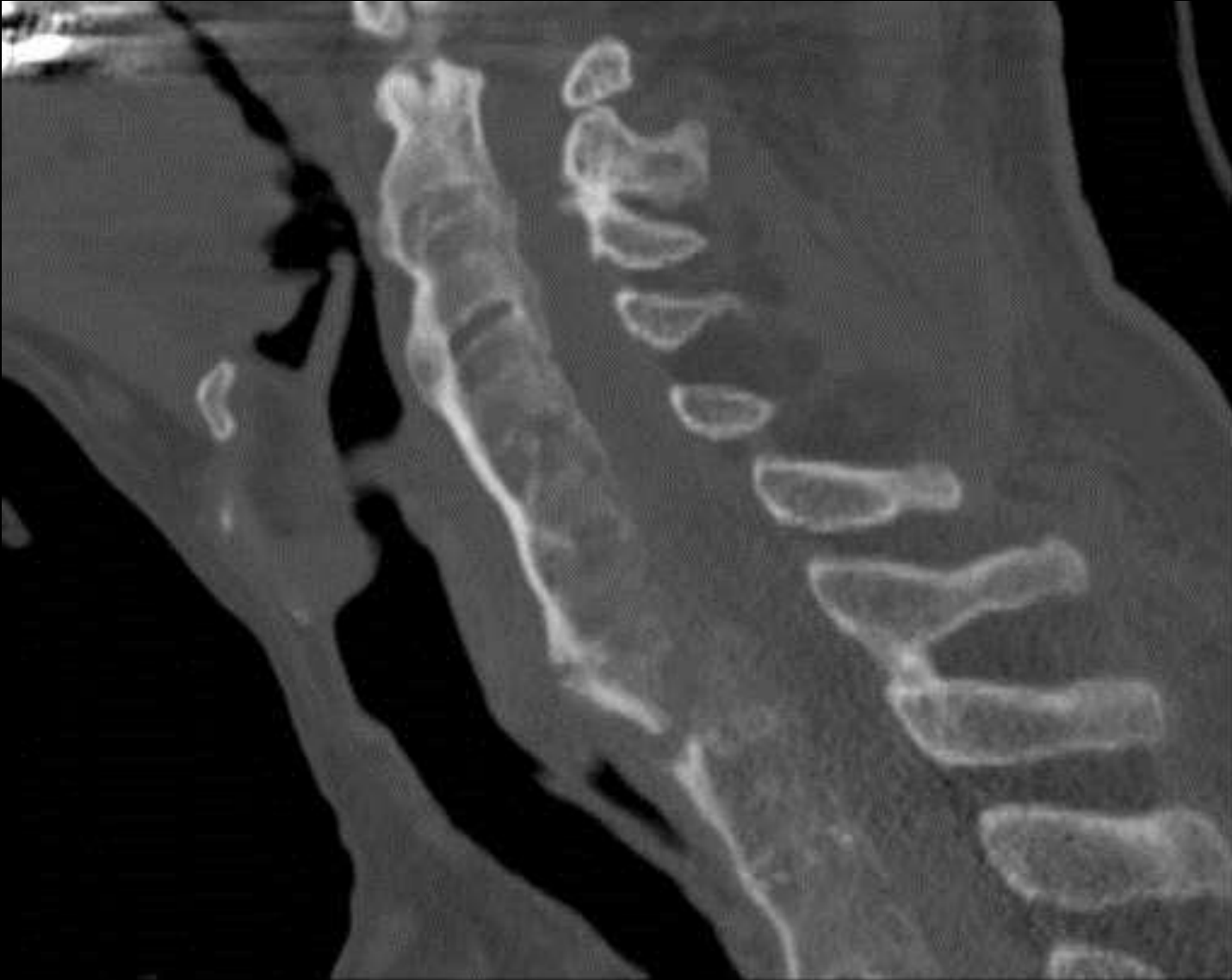Predisposing Factors

Ankylosing Spondylitis



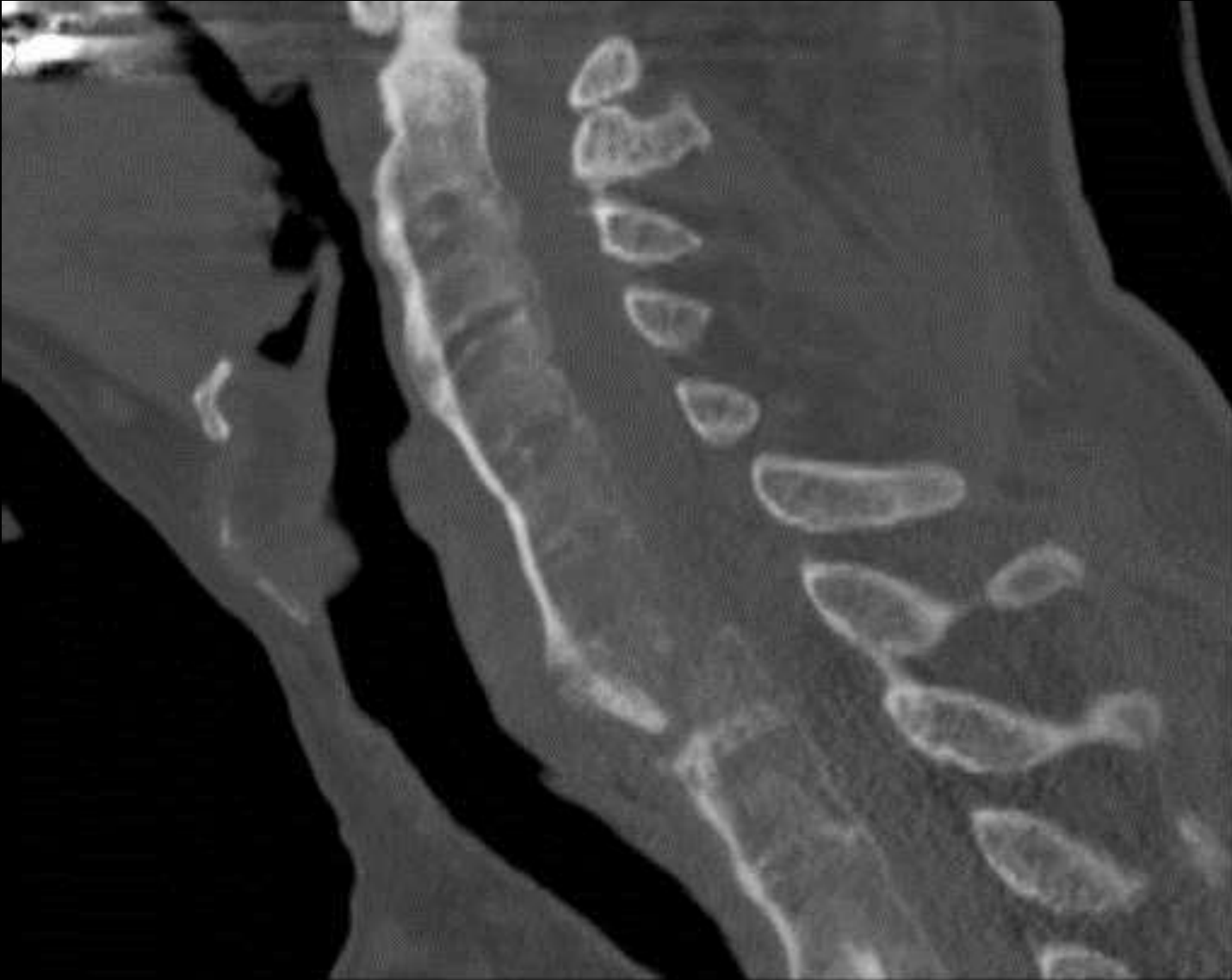
Predisposing Factors

Ankylosing Spondylitis



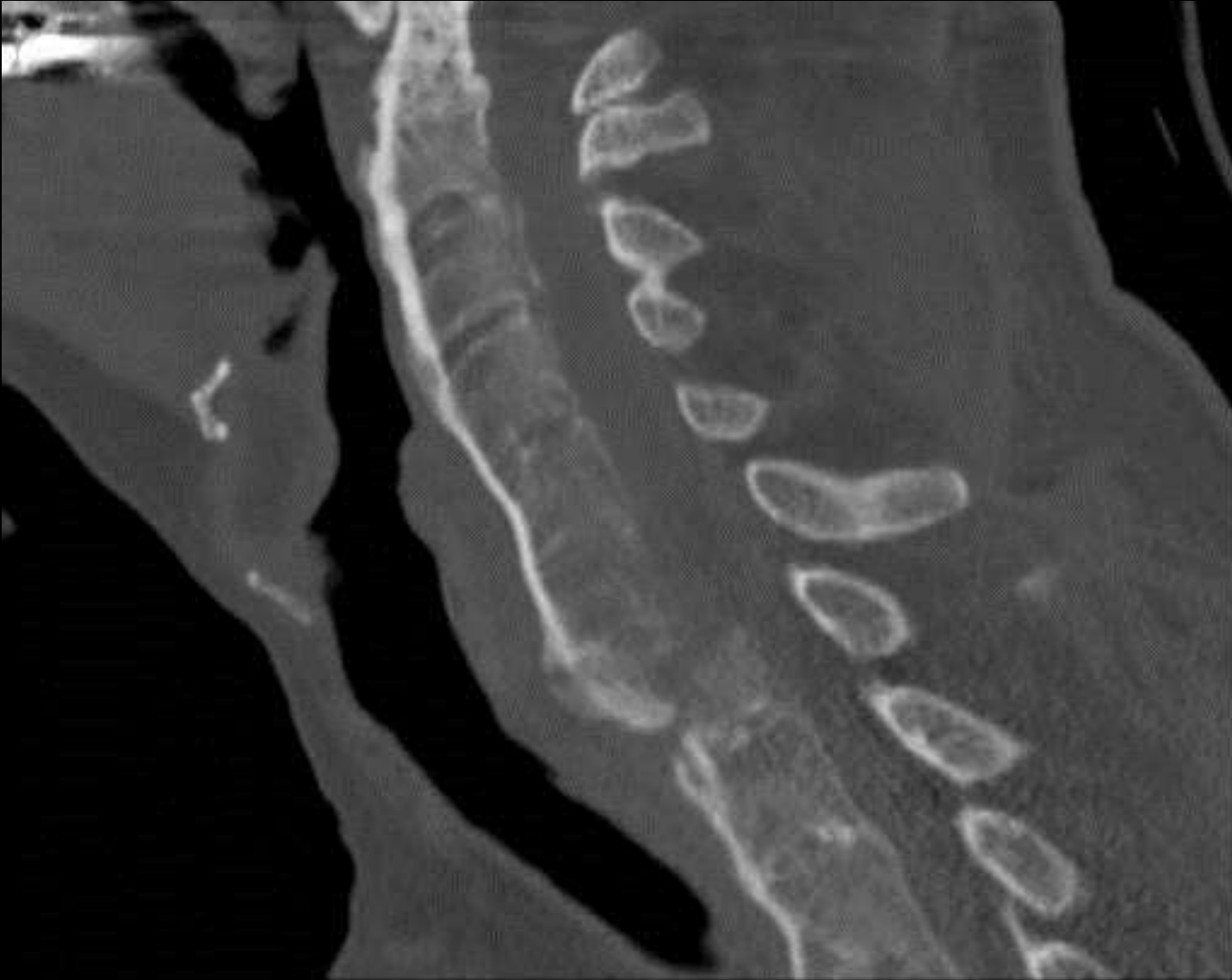
Predisposing Factors

Ankylosing Spondylitis



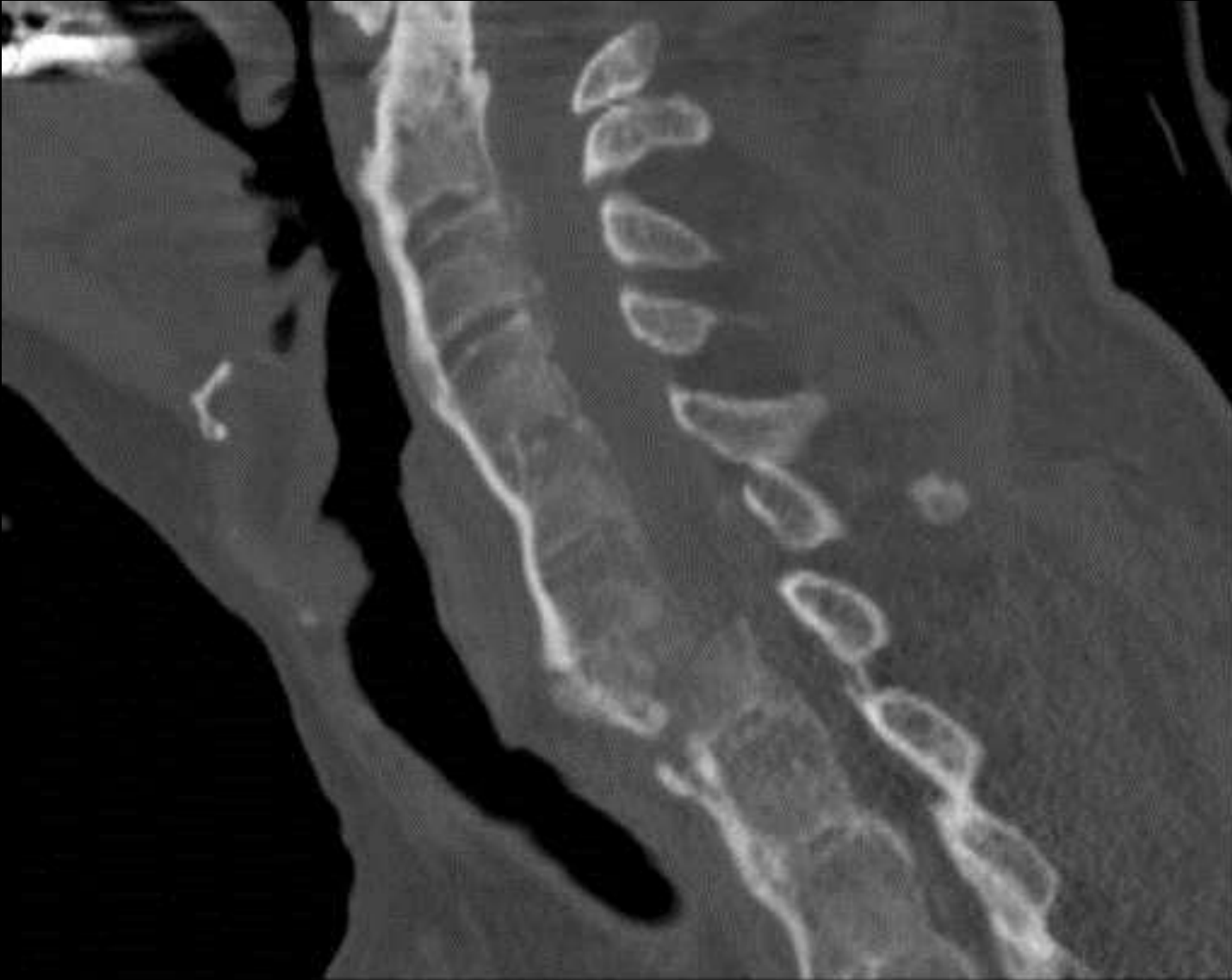Predisposing Factors

Ankylosing Spondylitis



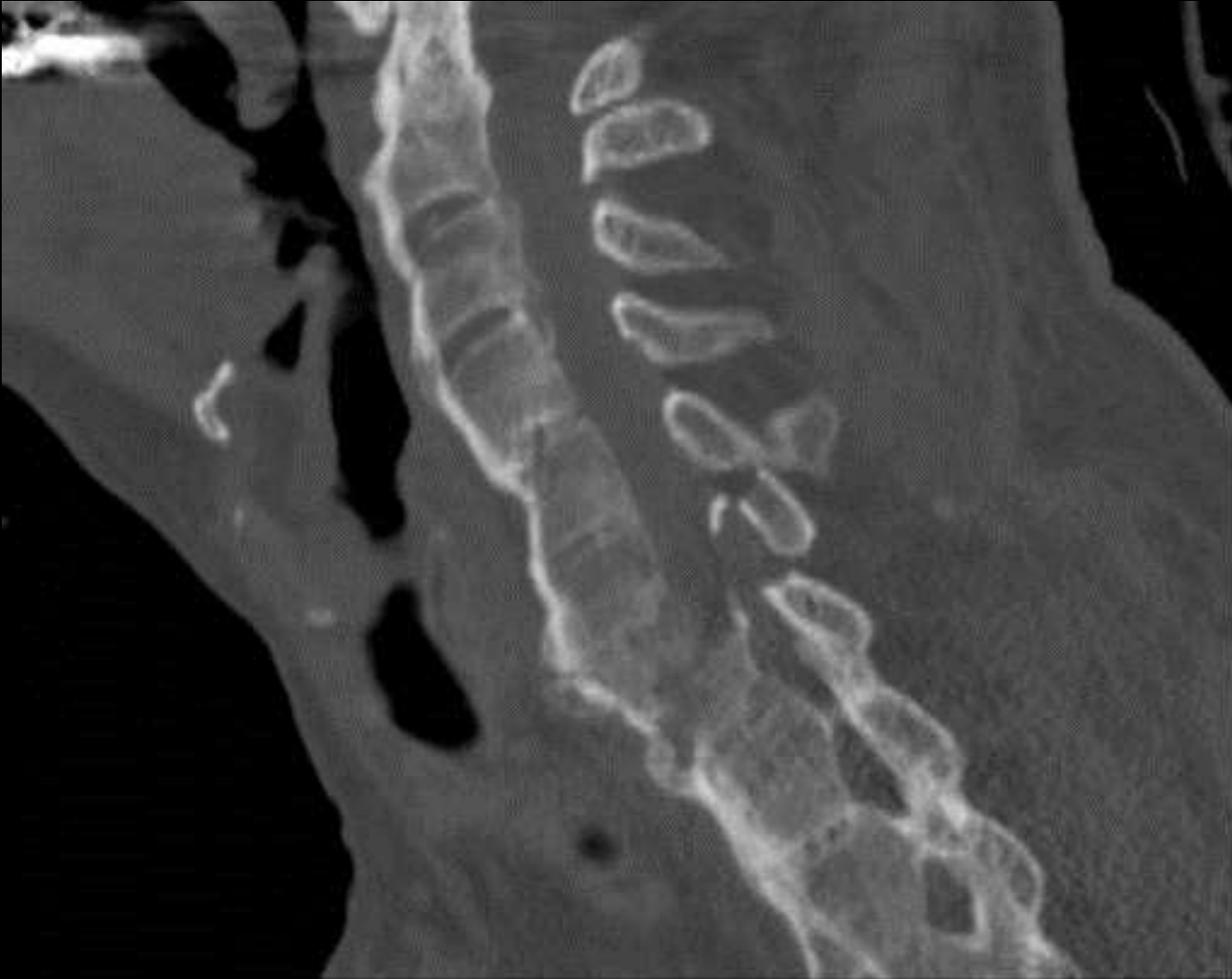
Predisposing Factors

Ankylosing Spondylitis



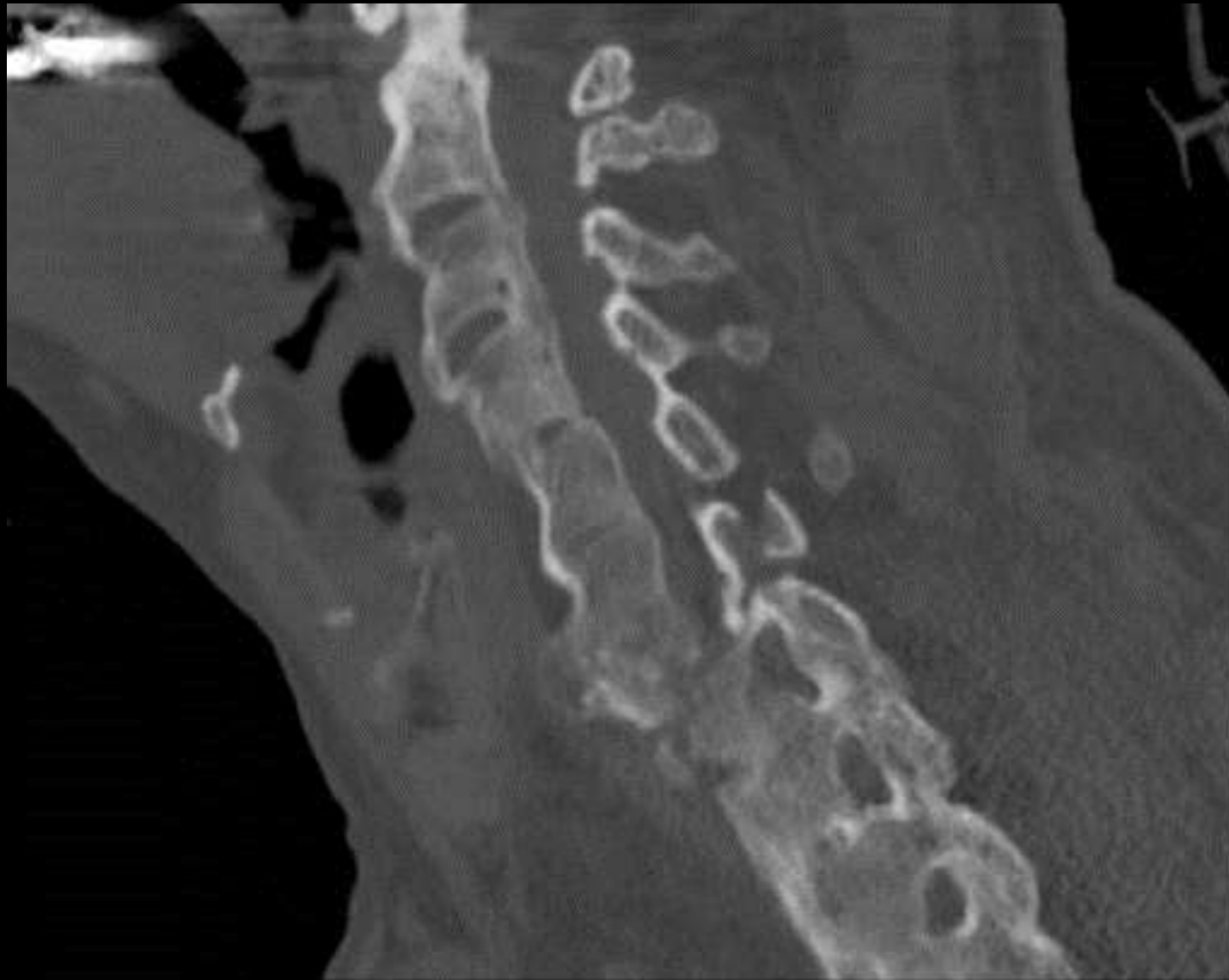
Predisposing Factors

Ankylosing Spondylitis



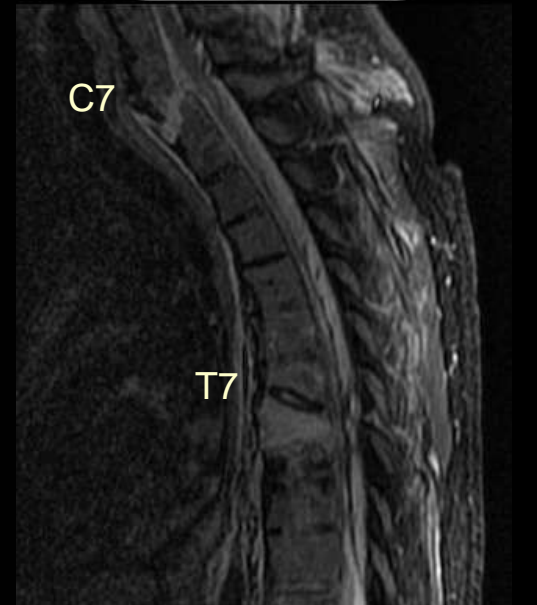
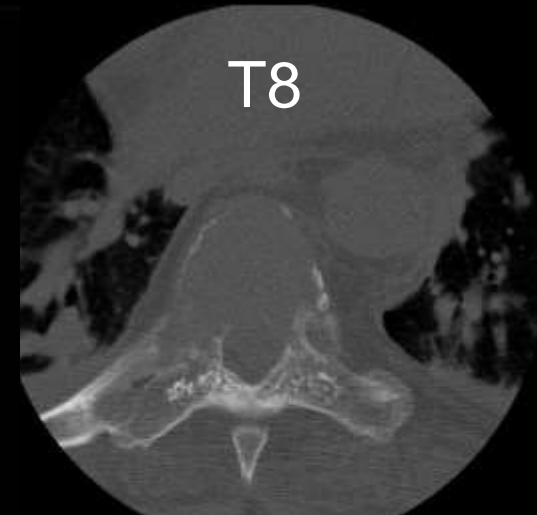
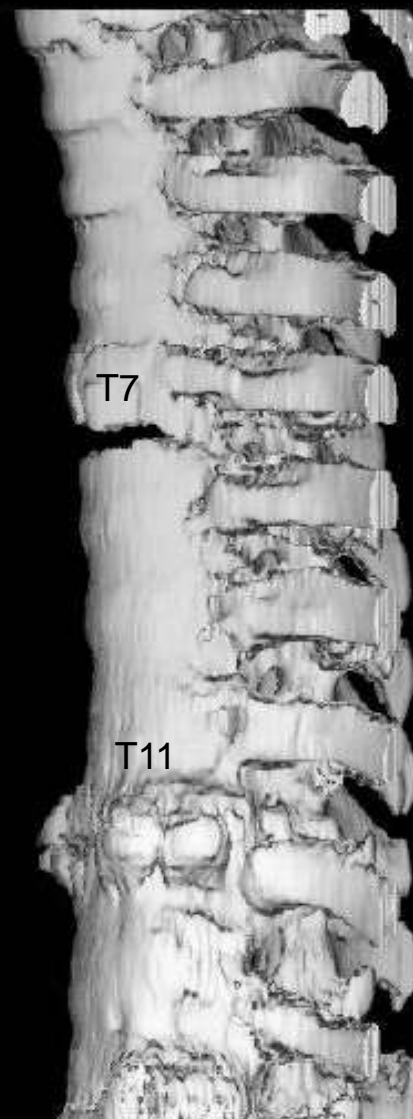
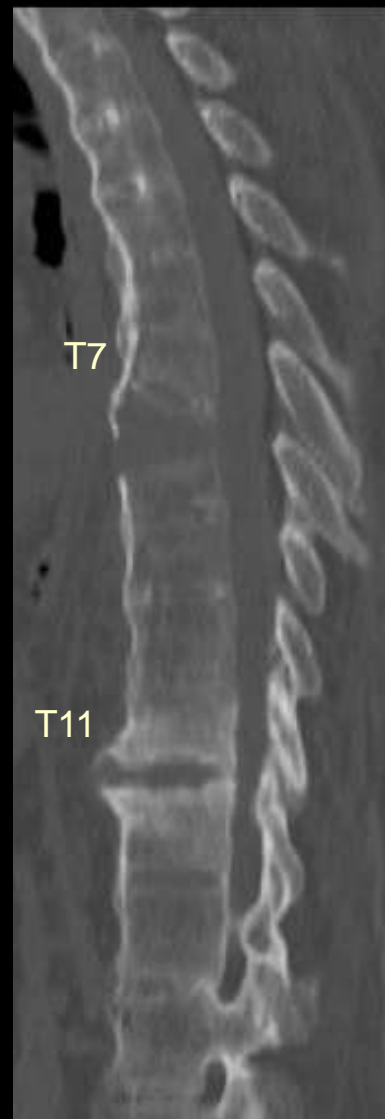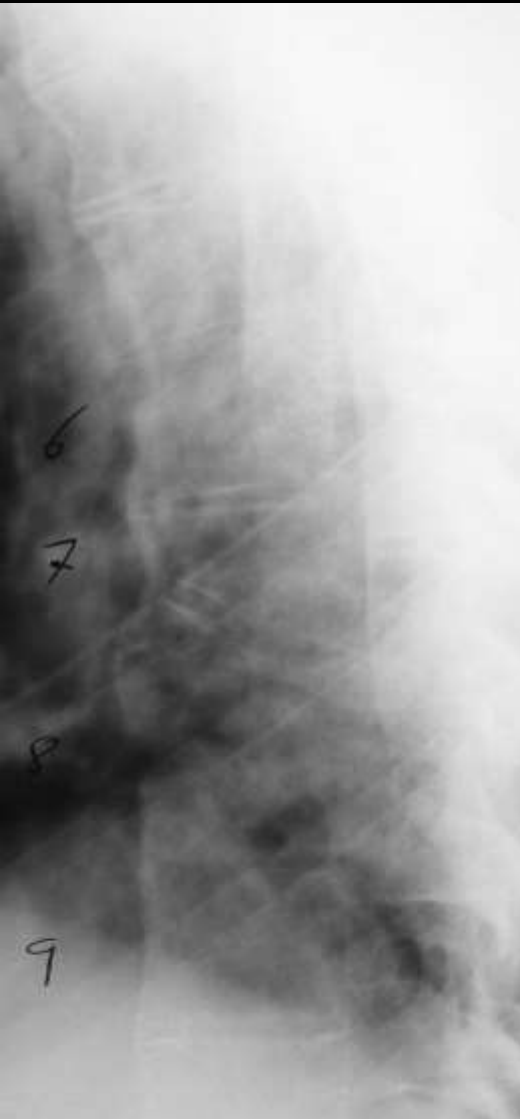Predisposing Factors

Ankylosing Spondylitis



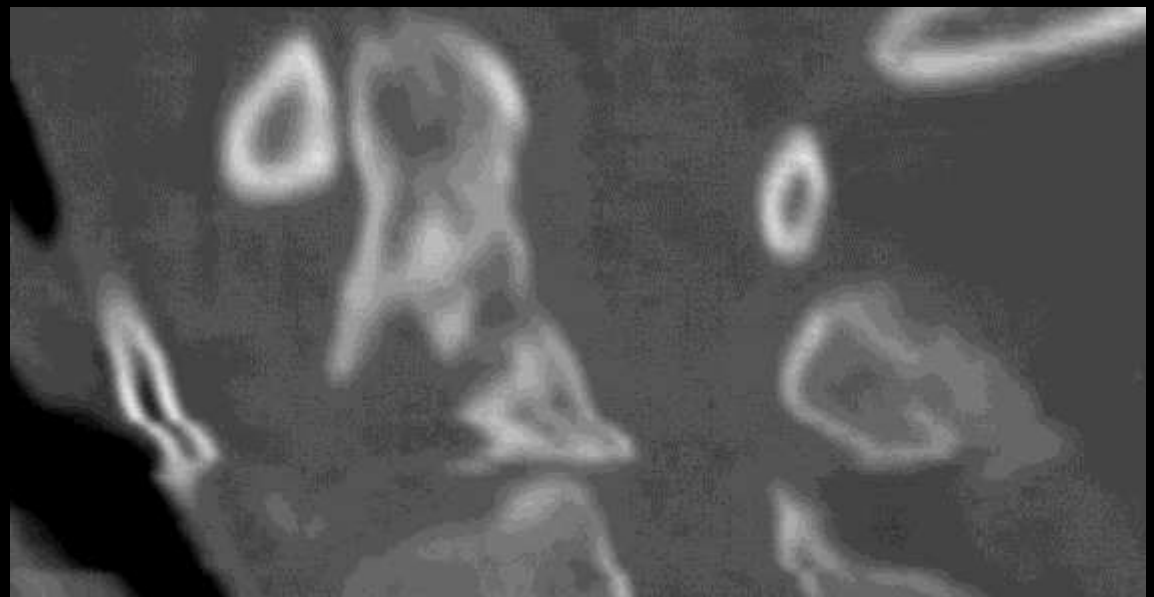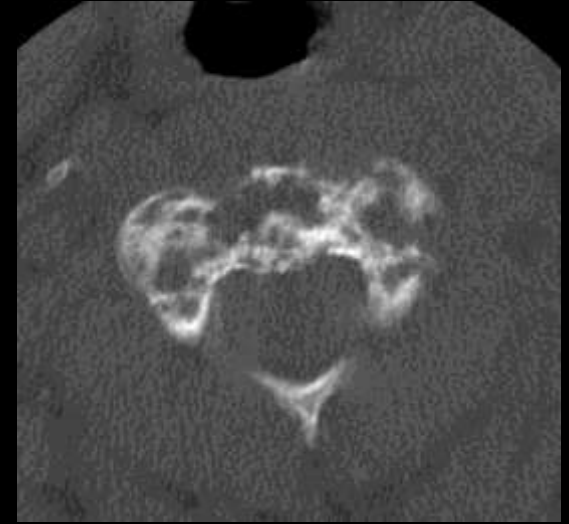
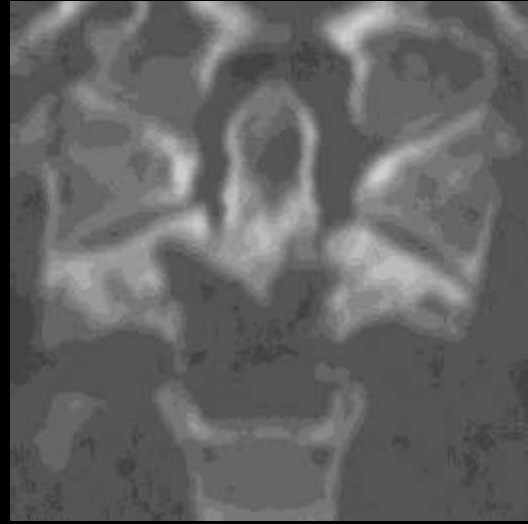
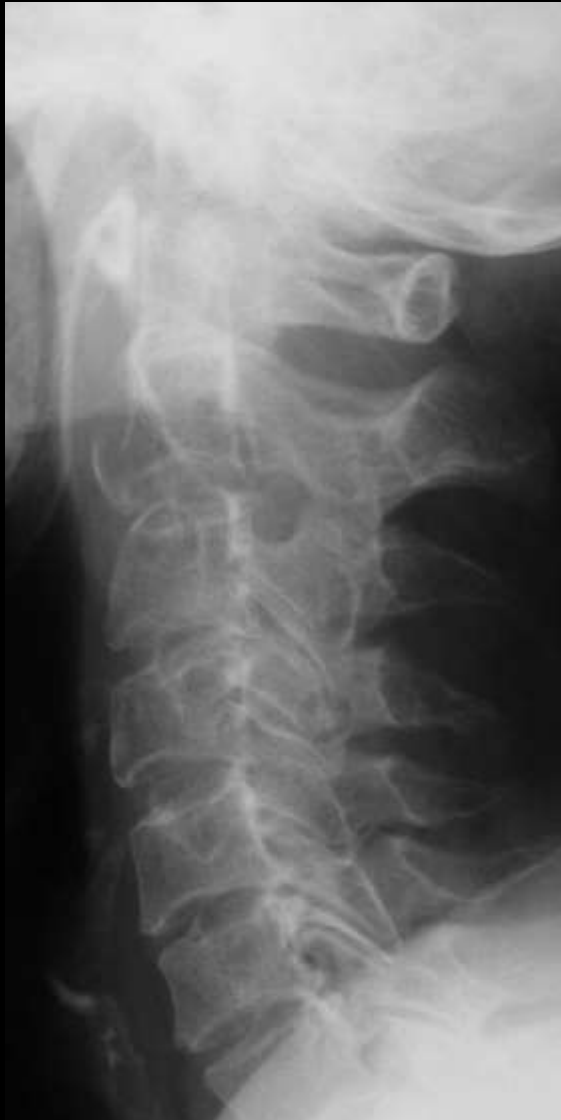Predisposing Factors

Ankylosing Spondylitis



Predisposing Factors

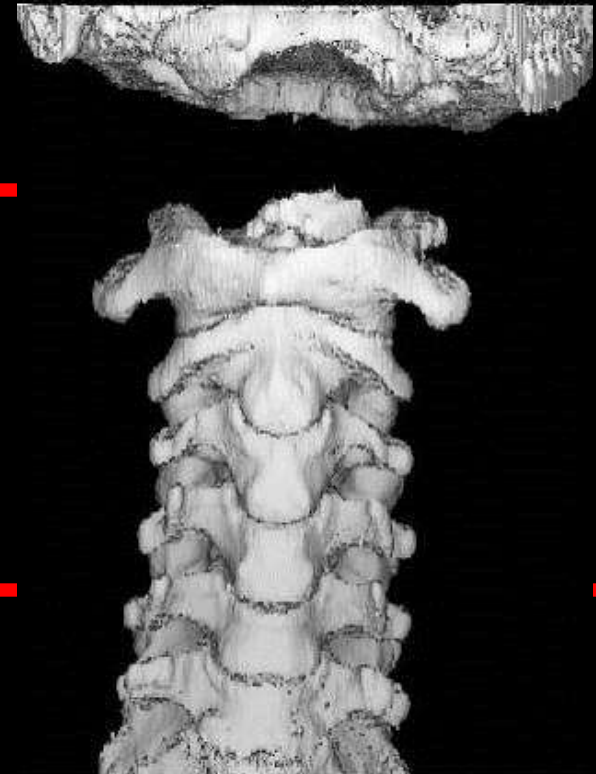
C2 Pathologic Fracture





Cervical Spine Trauma

Dr. Tudor H. Hughes M.D., FRCR
Department of Radiology
University of California School of Medicine
San Diego, California



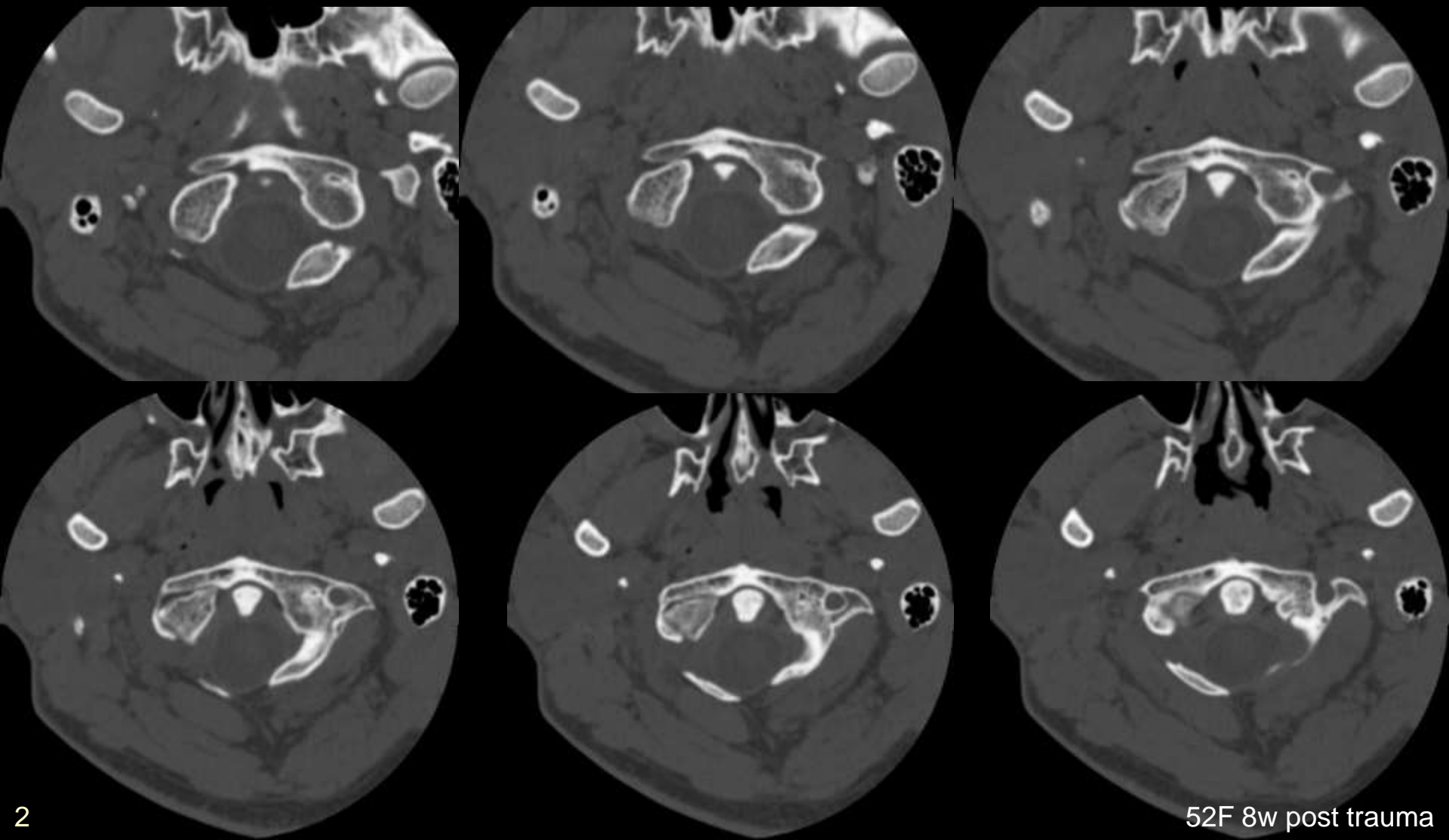
Occipitoatlas

- Fusion
- Fractures
 - Occipital condyles
- Subluxation / Dislocation
- ST injuries

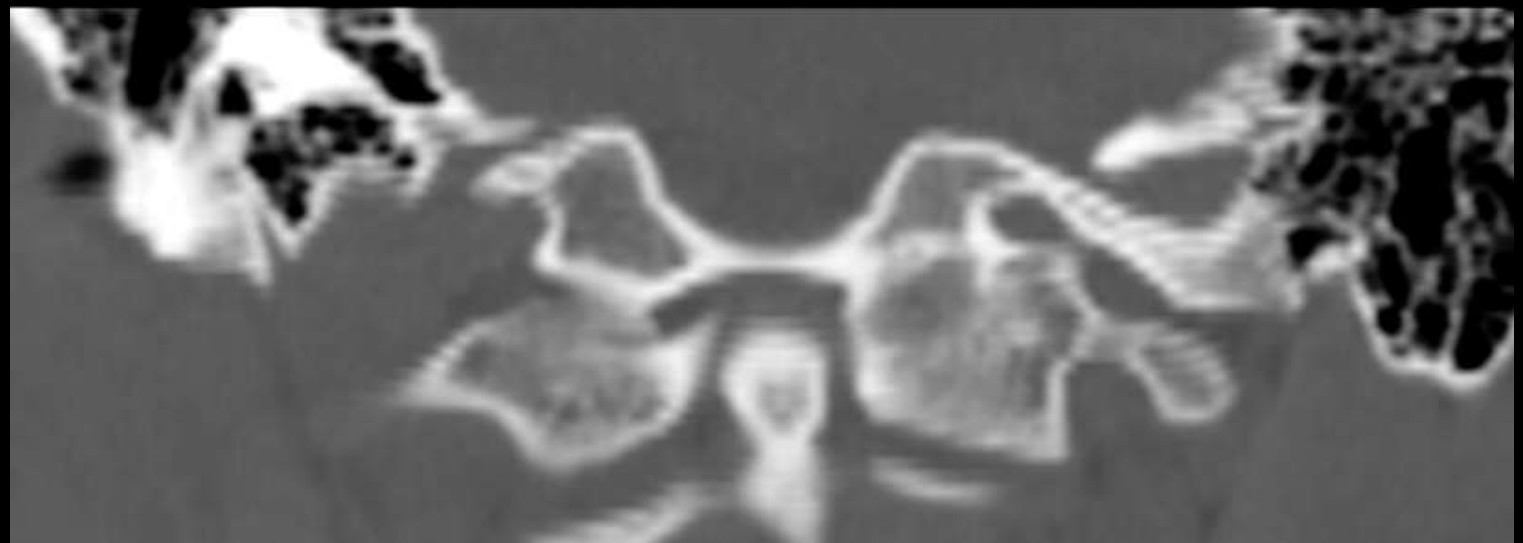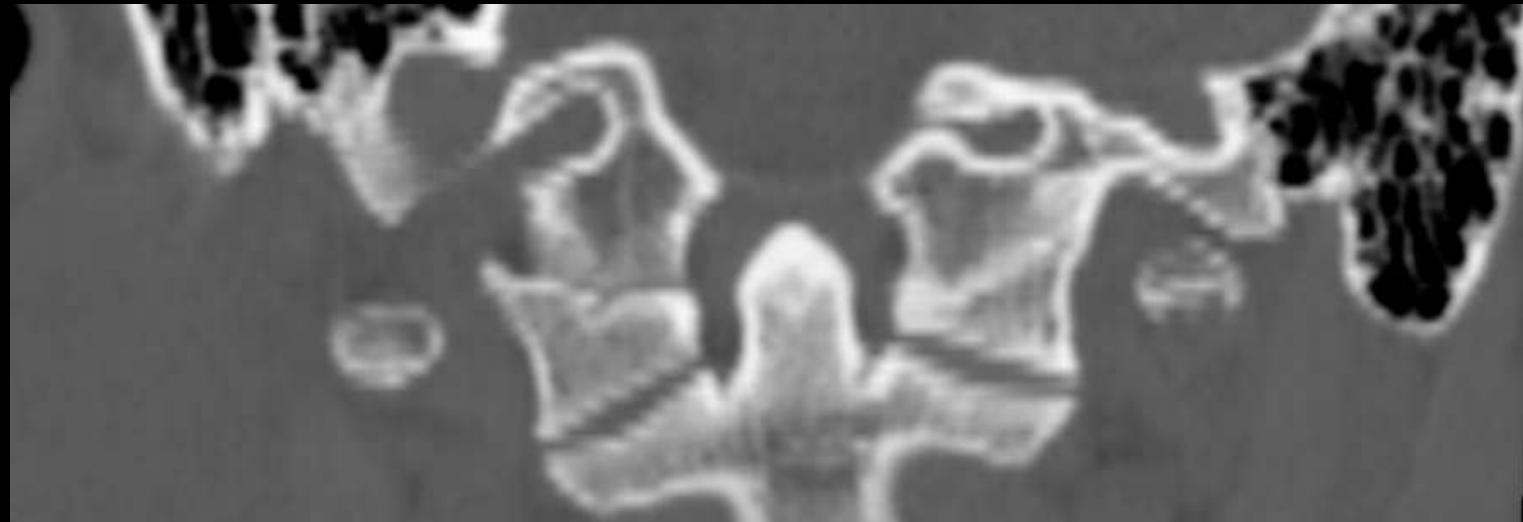CranioAtlas Assimilation

- Occipitalization of the atlas
- 0.75% of population
- Usually asymptomatic
- Usually anterior arch fusion
- 50% have C2-3 fusion
- Associated anterior atlantoaxial subluxation
- Associated middle ear anomalies
- Associated Chiari 1

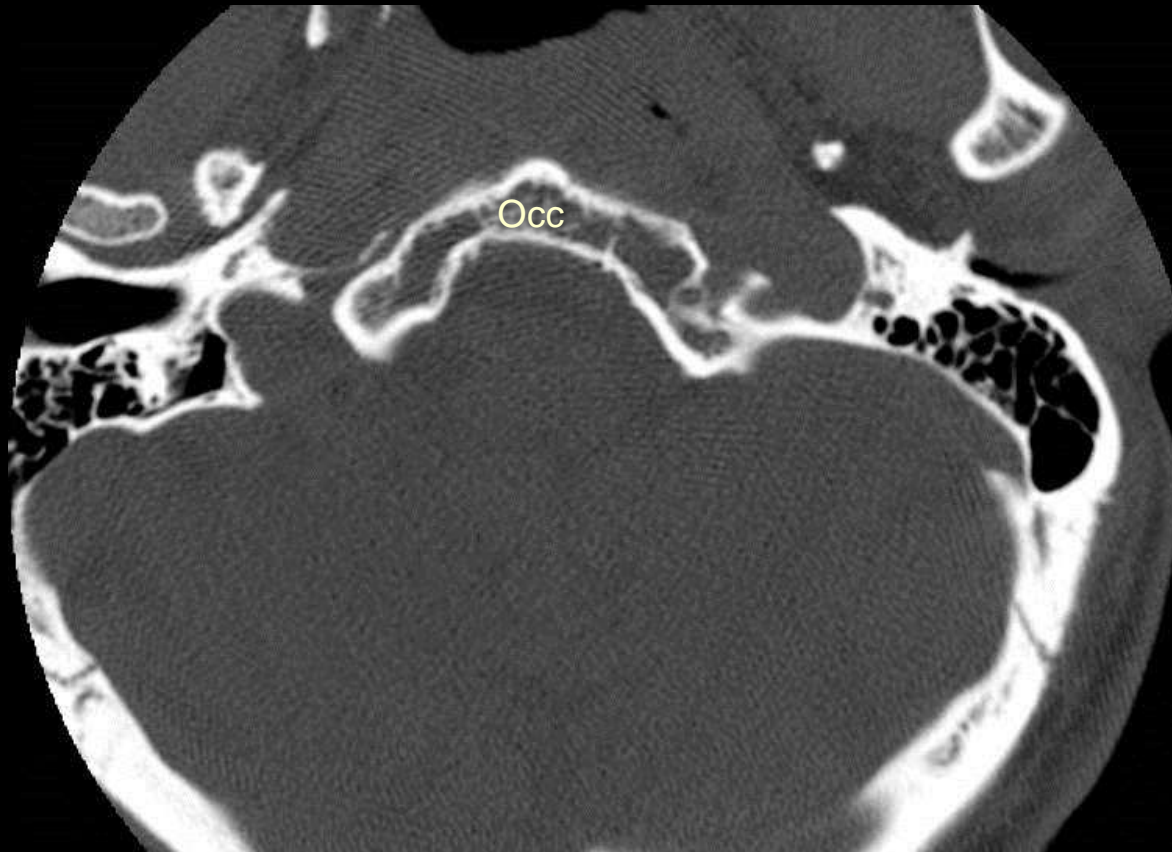
CranioAtlas Assimilation



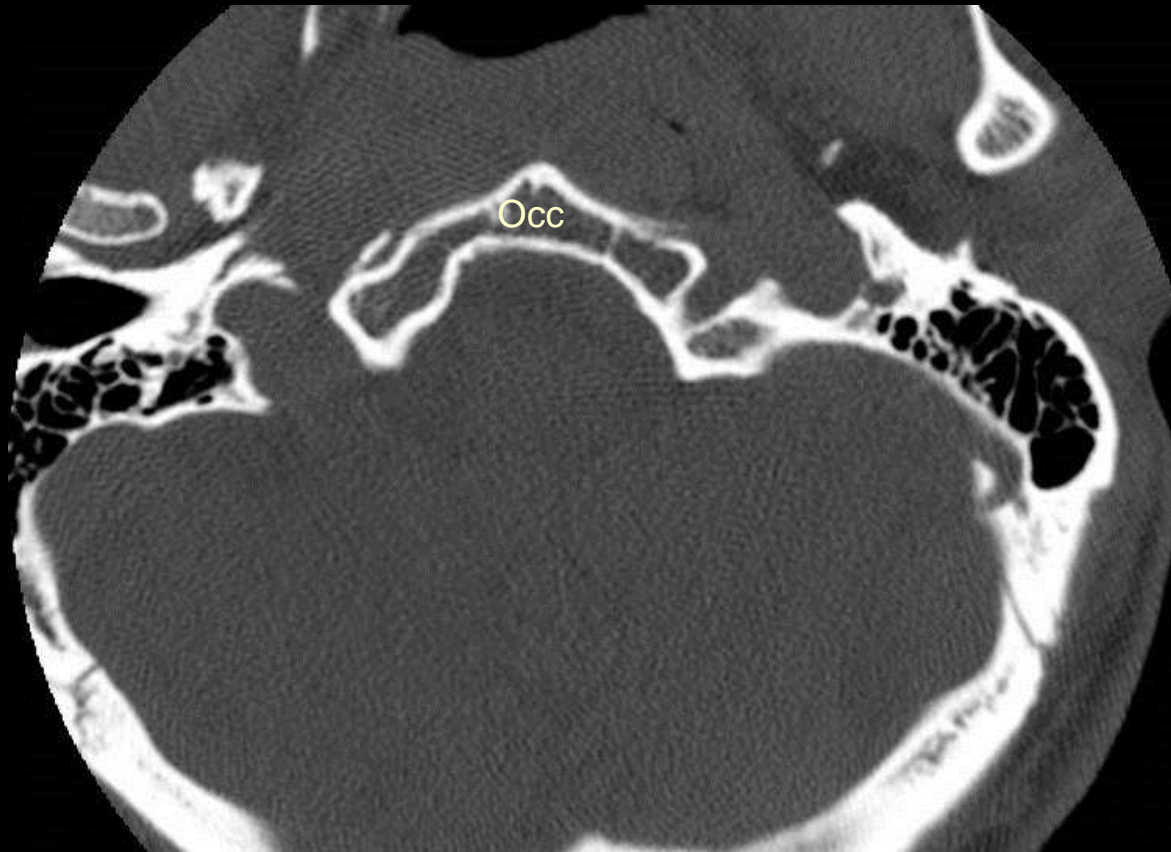
CranioAtlas Assimilation



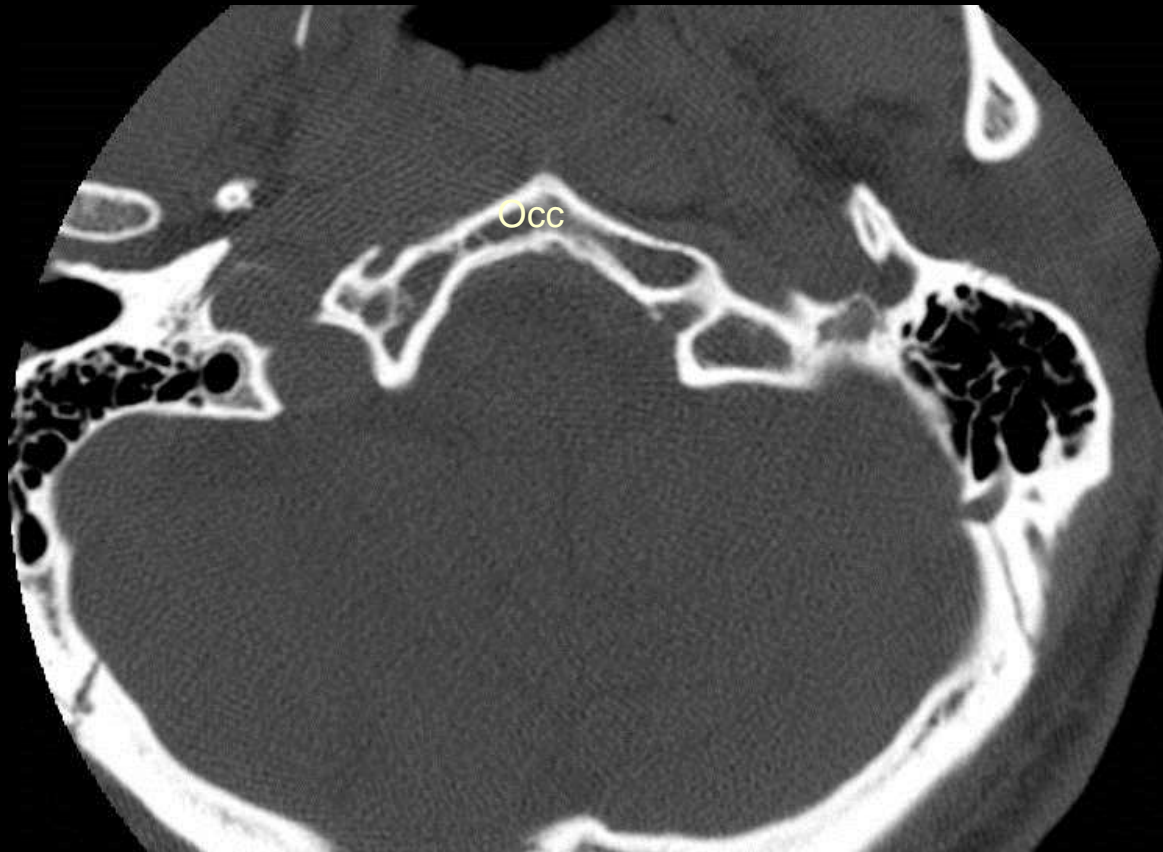
Occiptito-axial and C2-3 Fusions



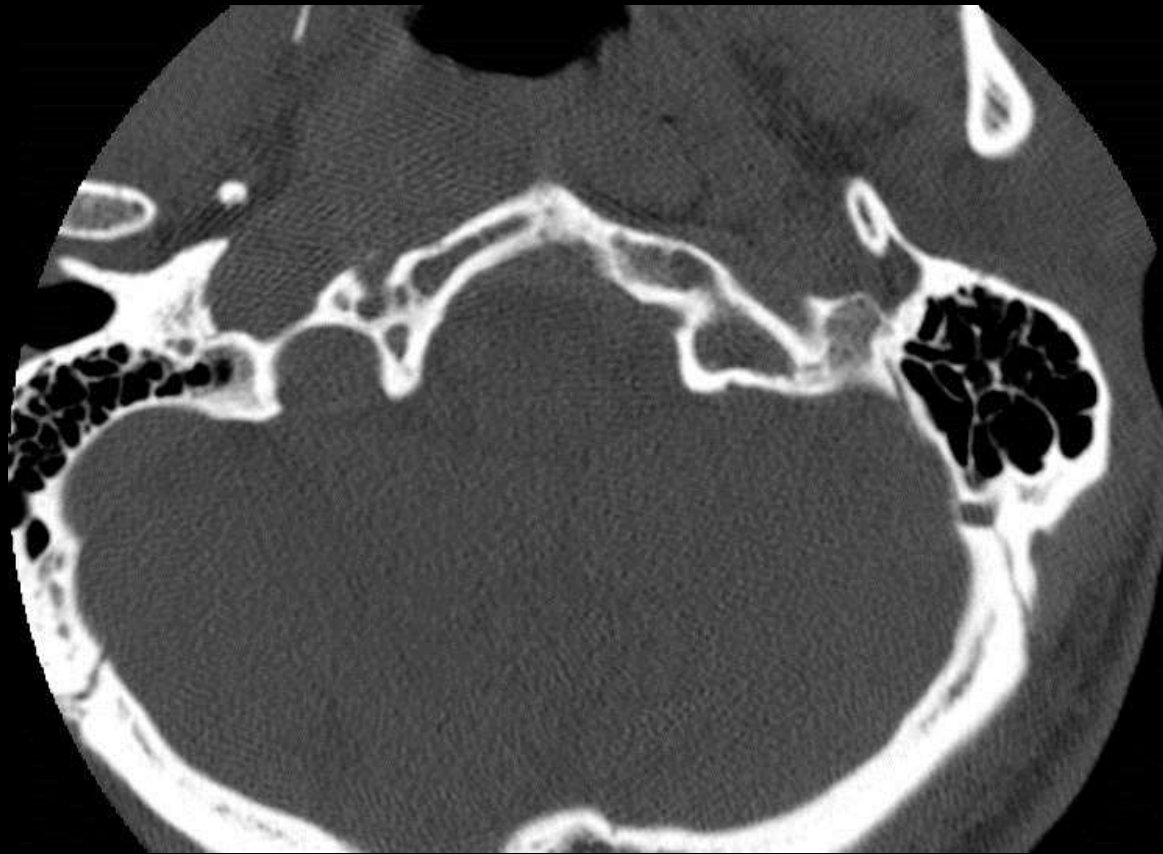
Occiptito-axial and C2-3 Fusions



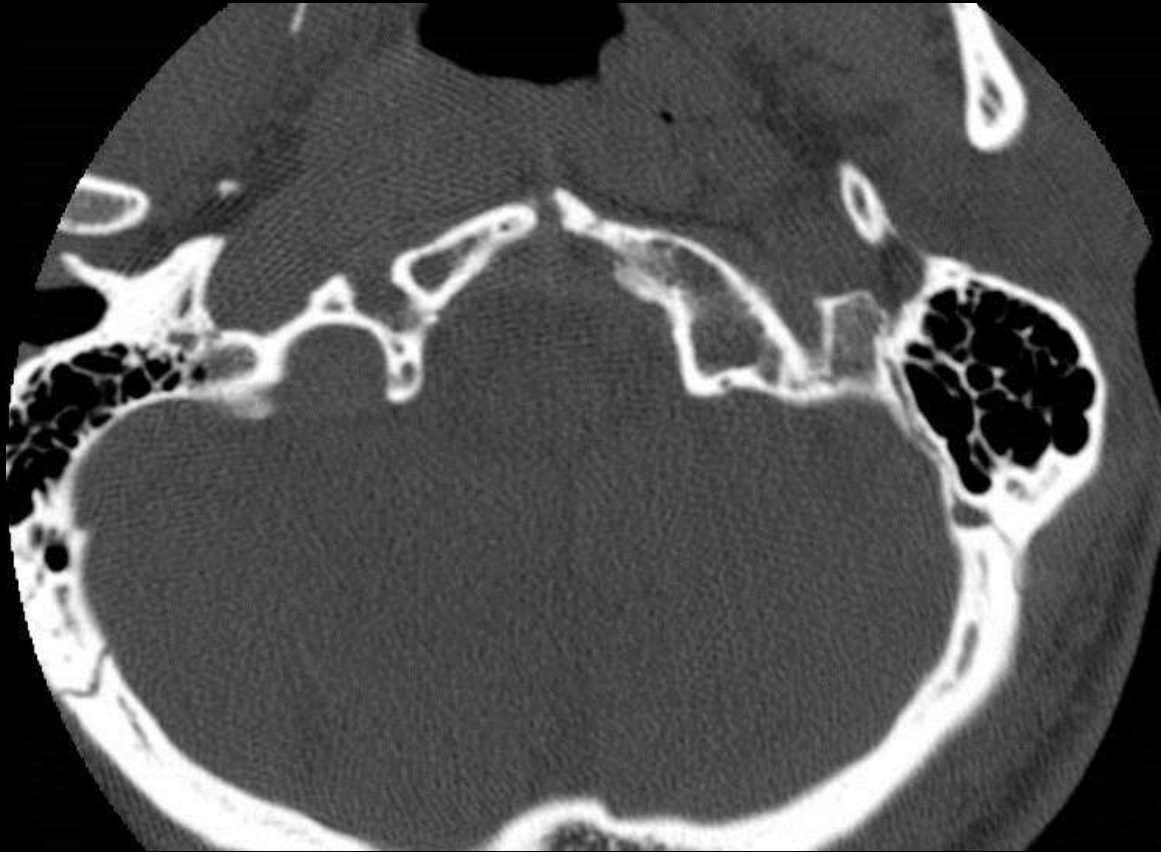
Occiptito-axial and C2-3 Fusions



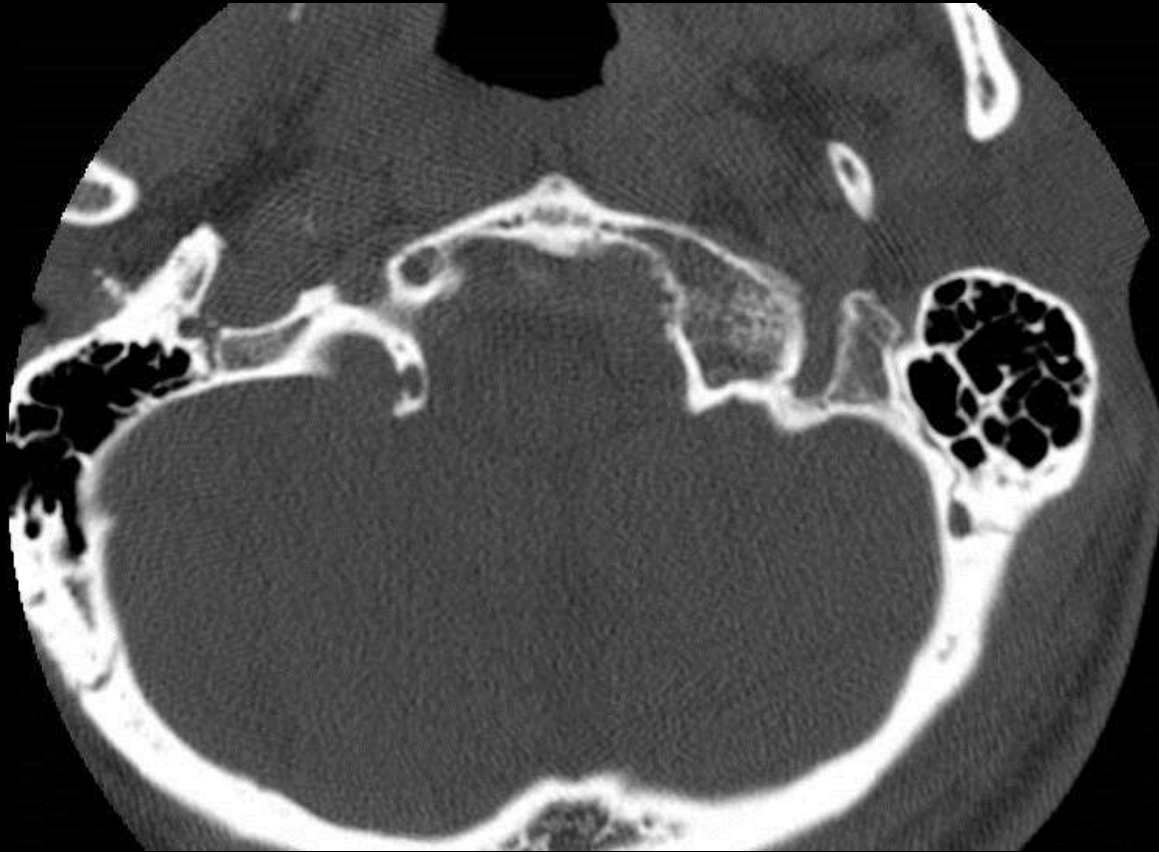Occiptito-axial and C2-3 Fusions



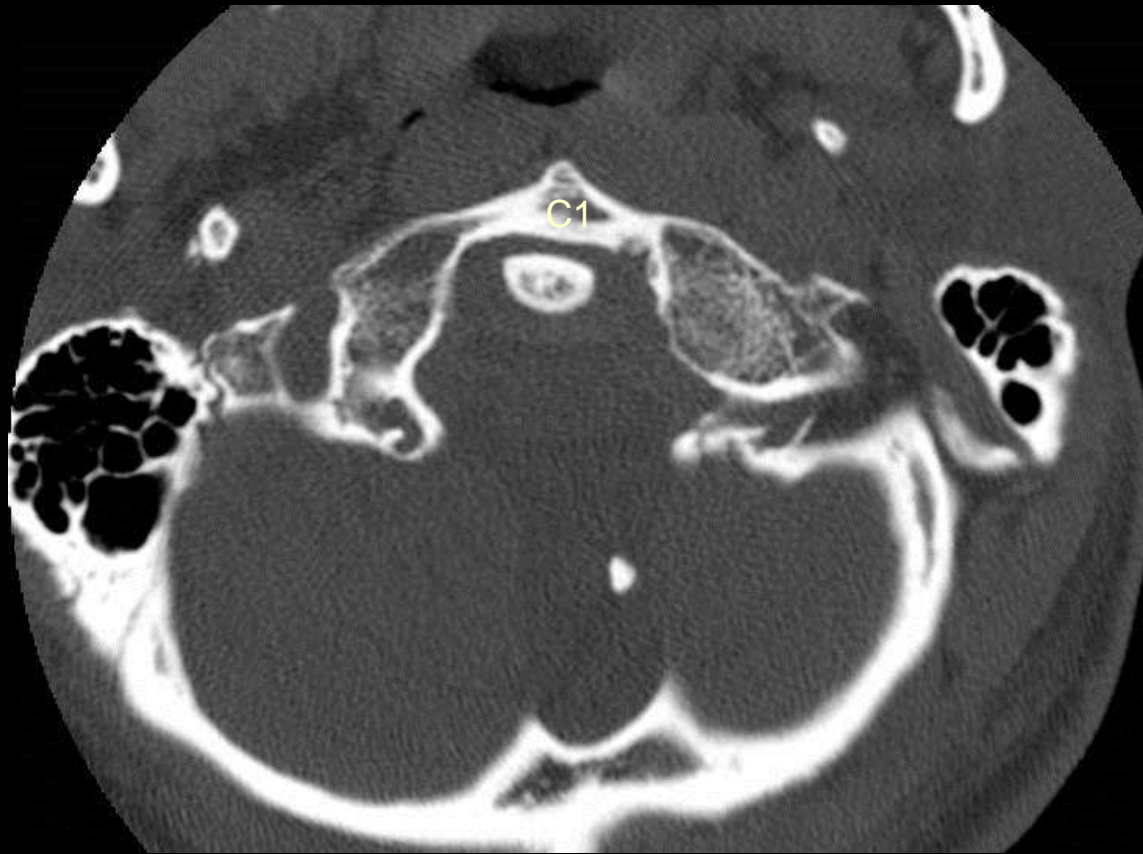
Occiptito-axial and C2-3 Fusions



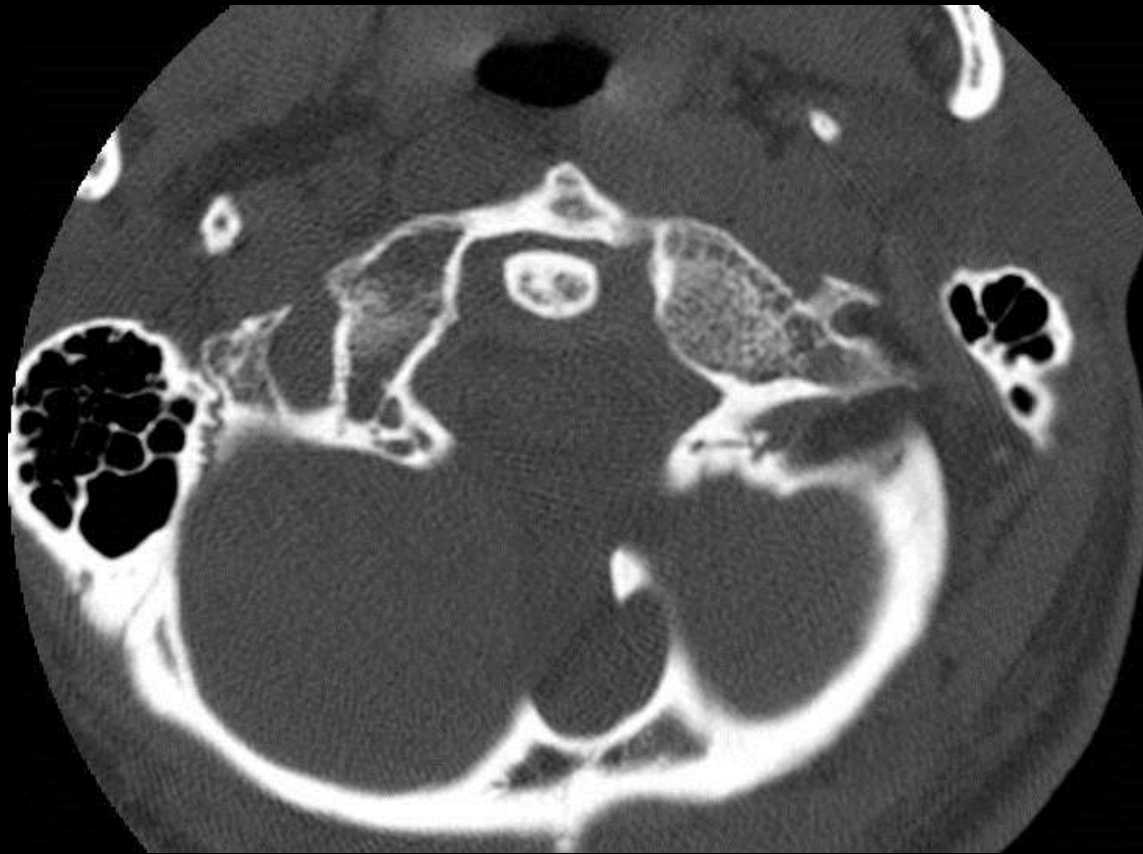
Occiptito-axial and C2-3 Fusions



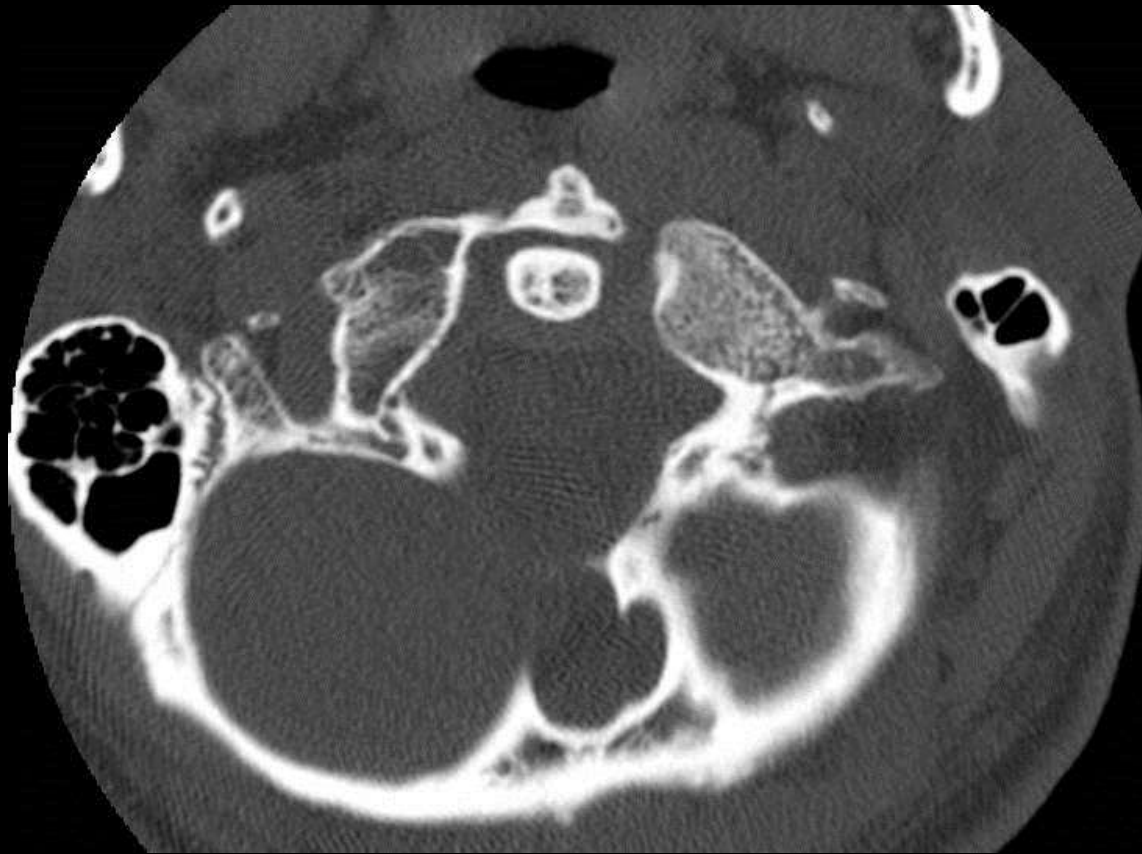
Occipitocranial and C2-3 Fusions



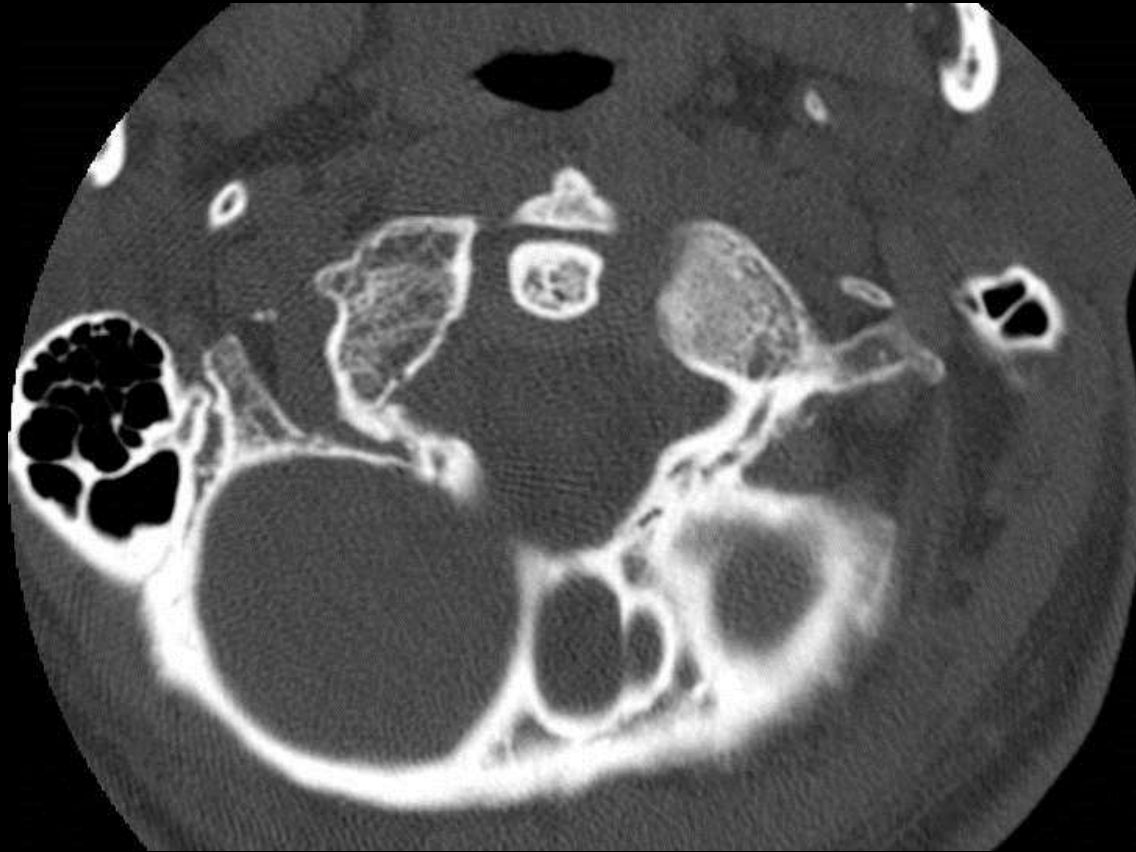Occipitocranial and C2-3 Fusions



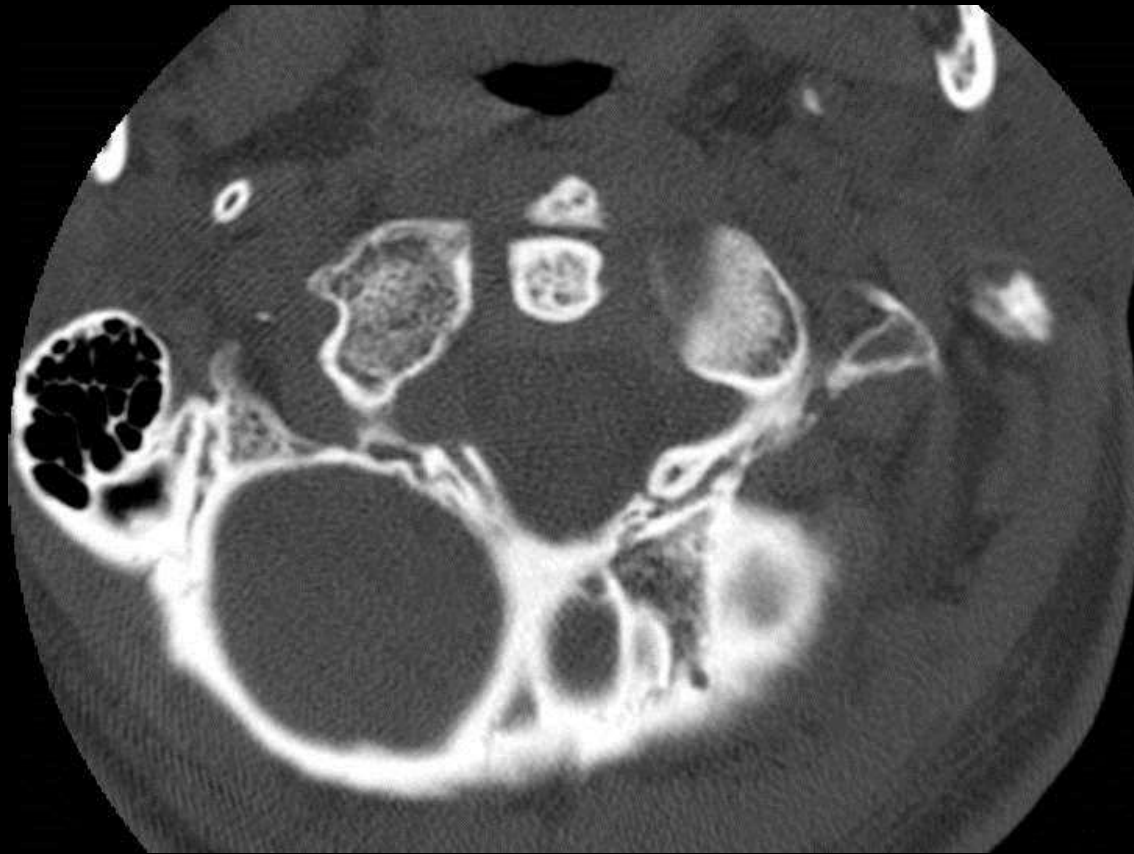
Occipitito-axial and C2-3 Fusions



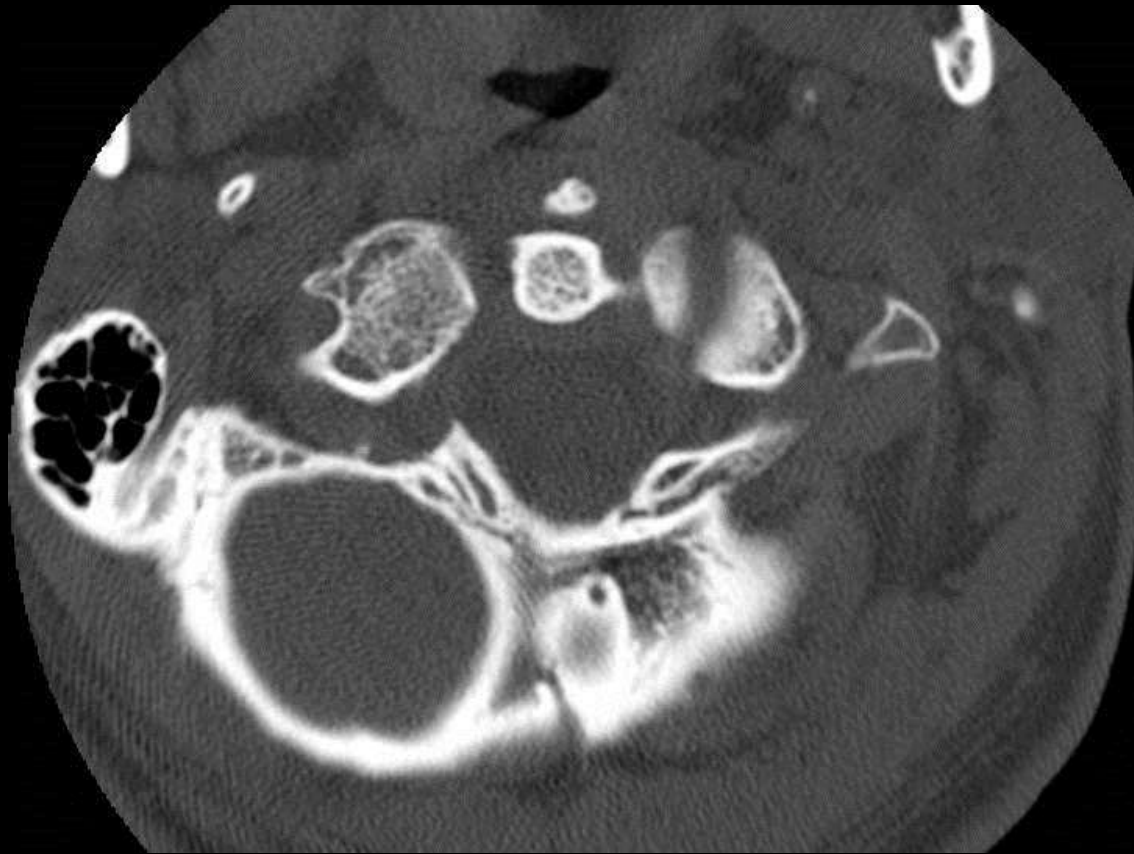
Occipitito-axial and C2-3 Fusions



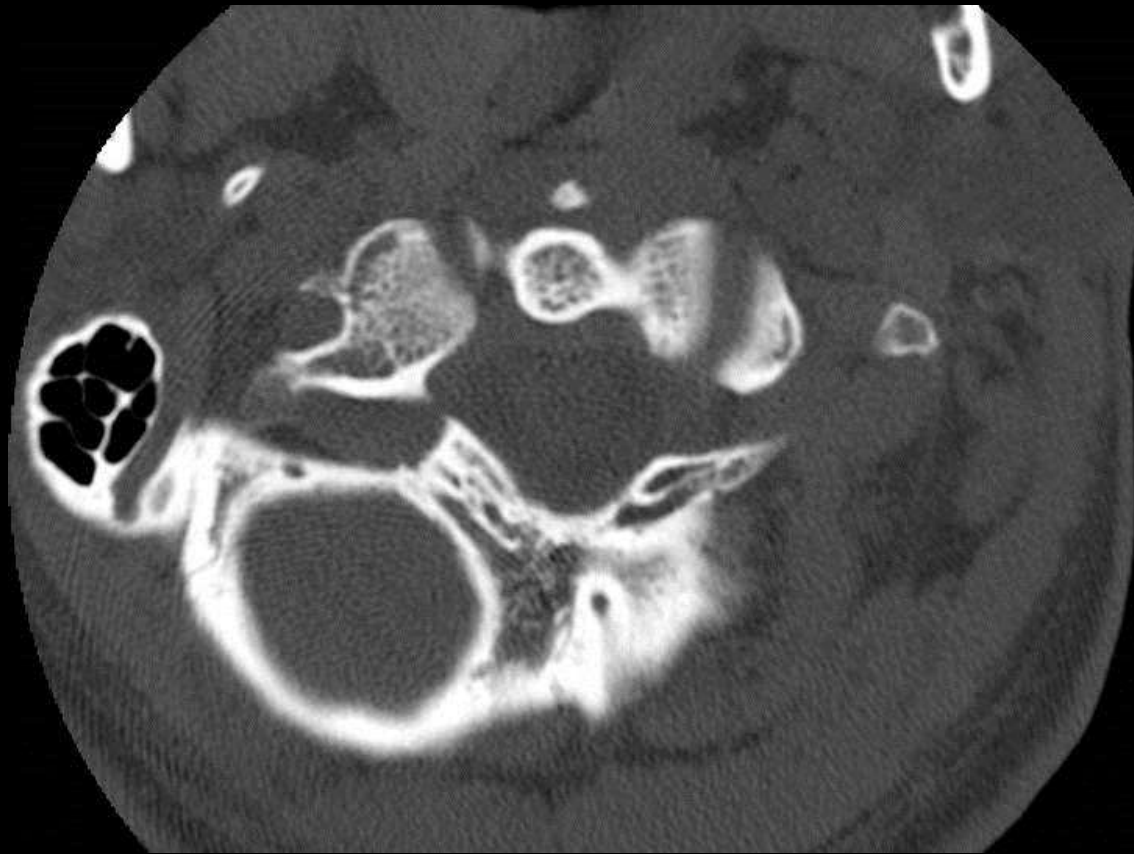
Occipitocranial and C2-3 Fusions



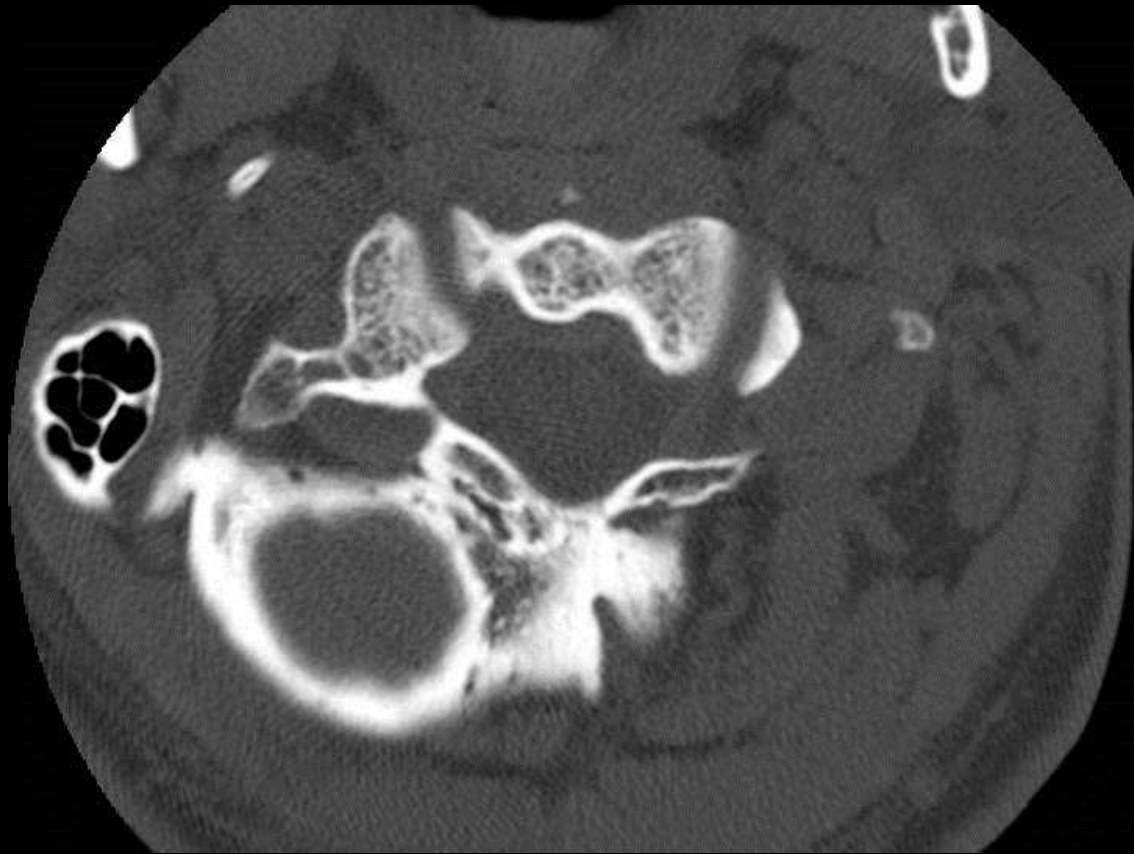Occipitito-axial and C2-3 Fusions



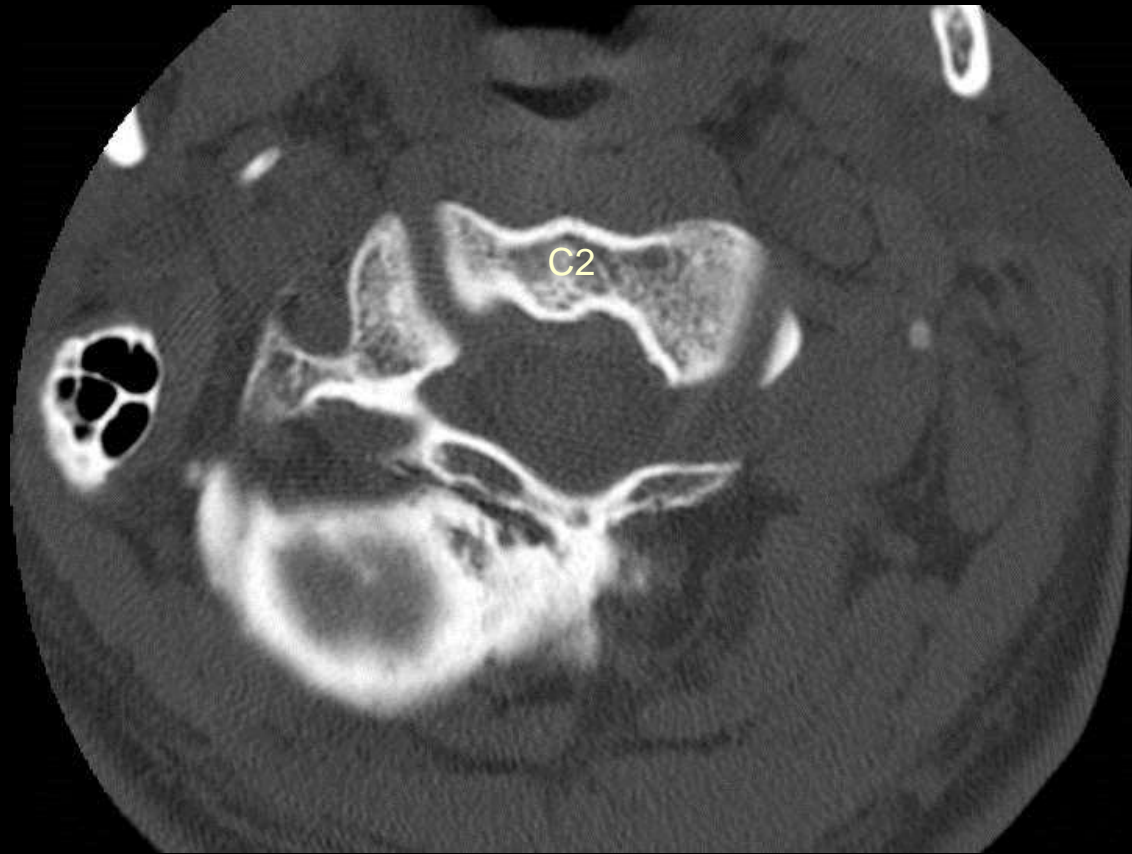
Occipitito-axial and C2-3 Fusions



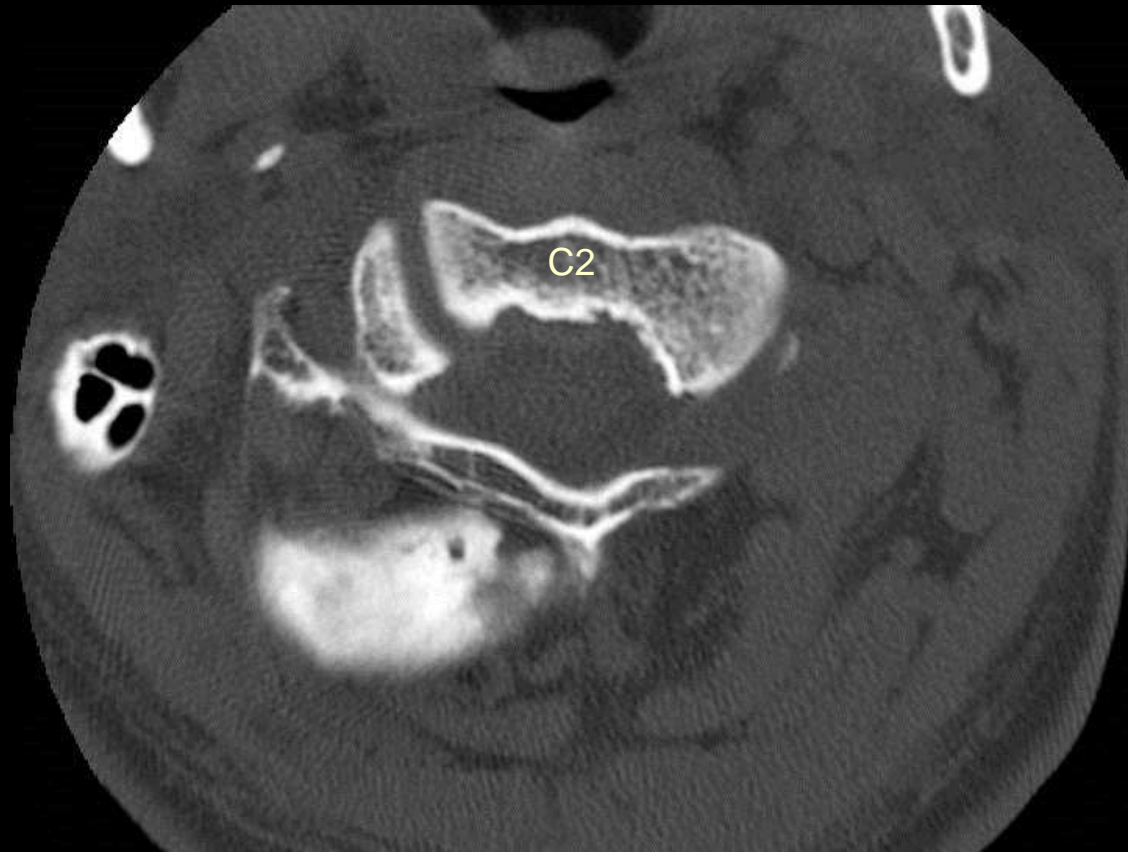Occipitito-axial and C2-3 Fusions



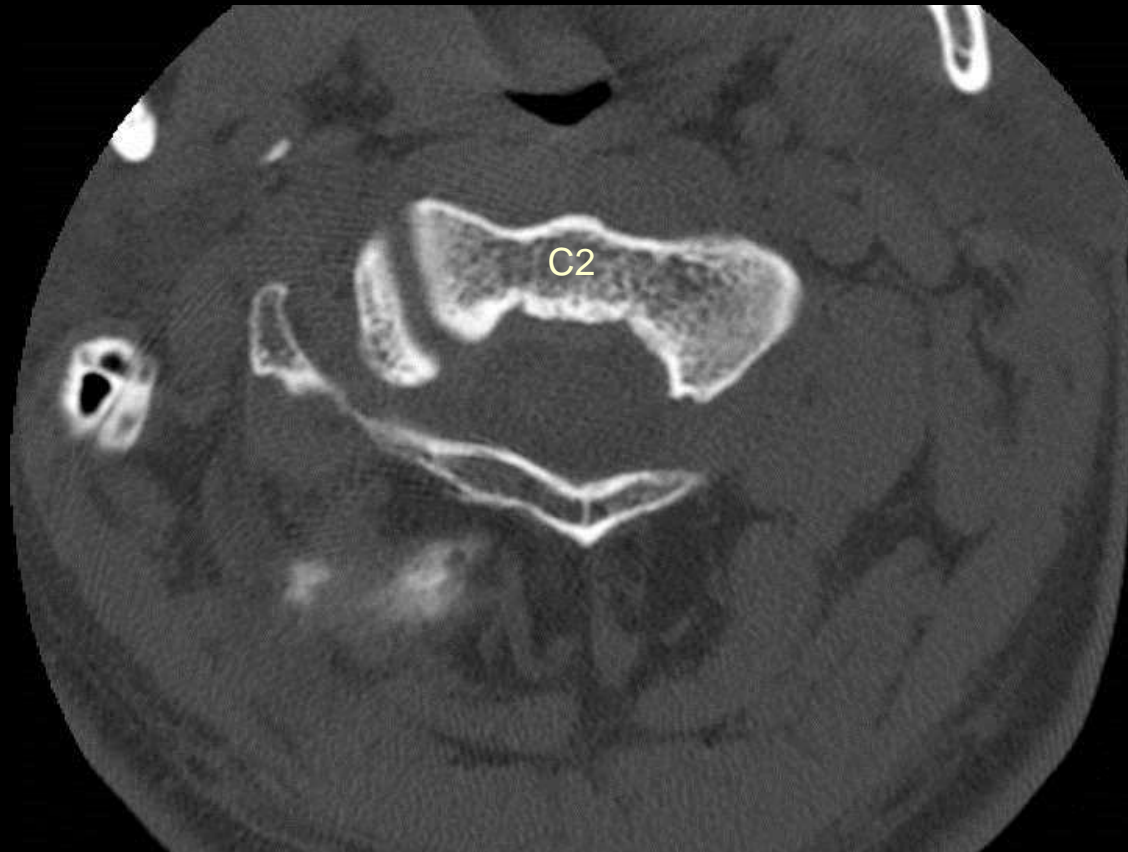
Occiptito-axial and C2-3 Fusions



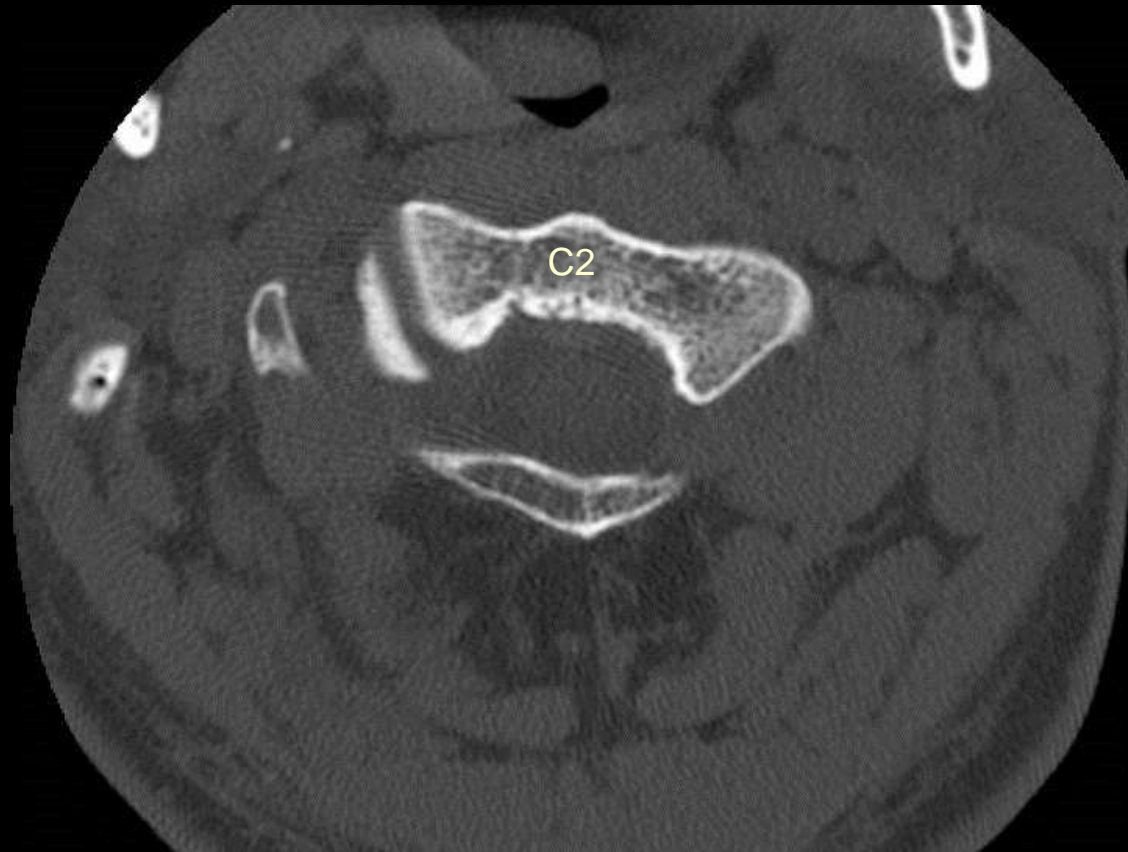
Occiptito-axial and C2-3 Fusions



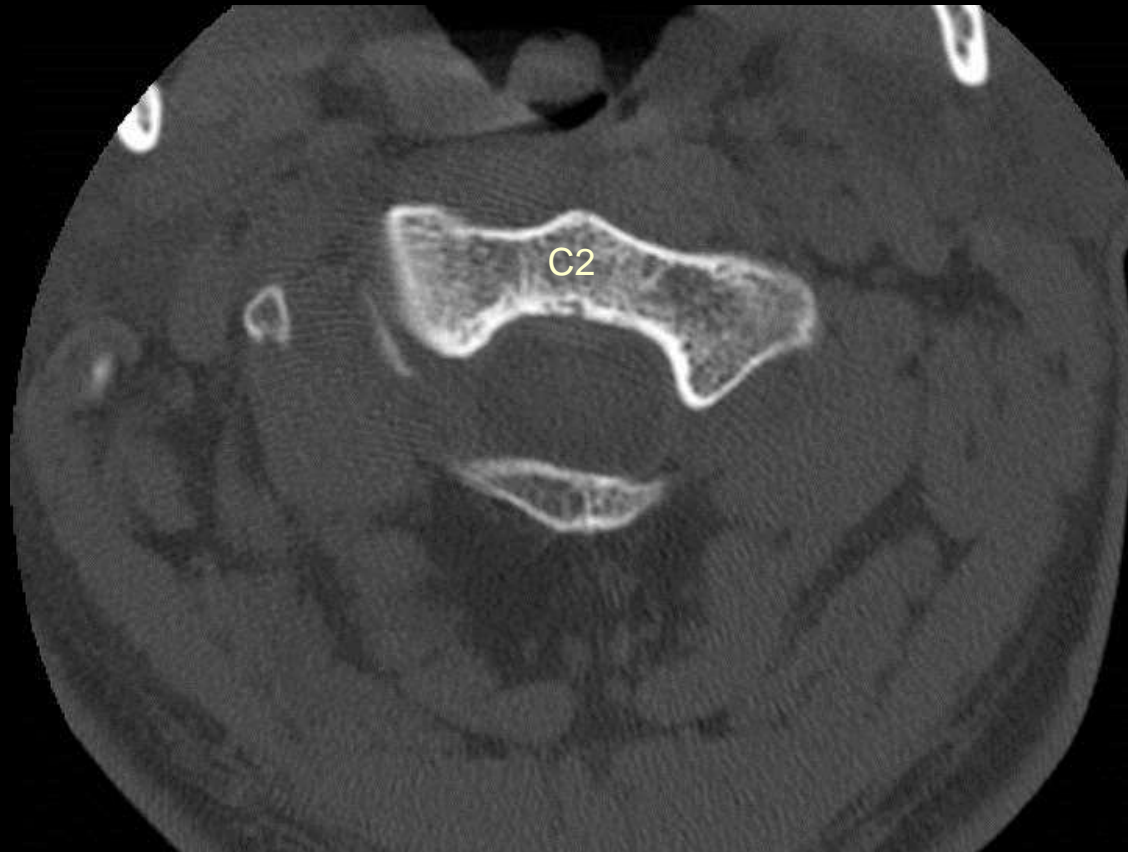Occiptito-axial and C2-3 Fusions



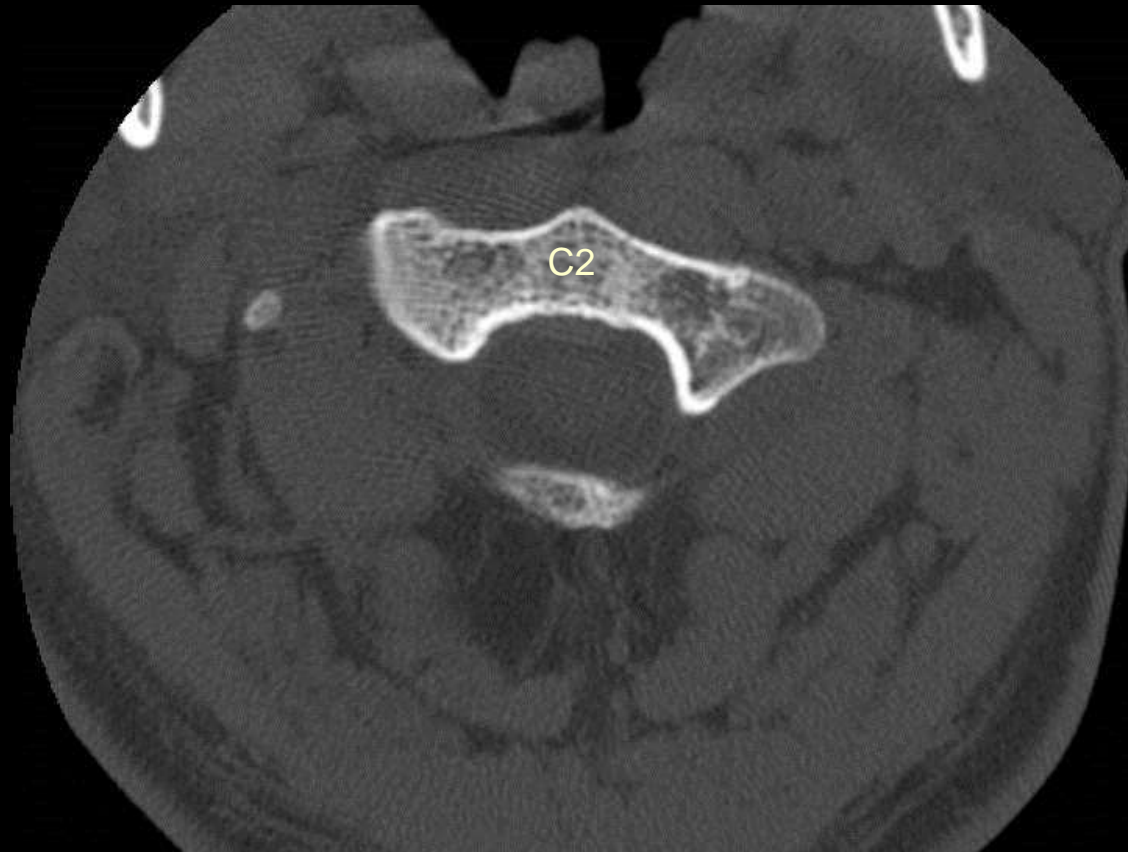
Occiptito-axial and C2-3 Fusions



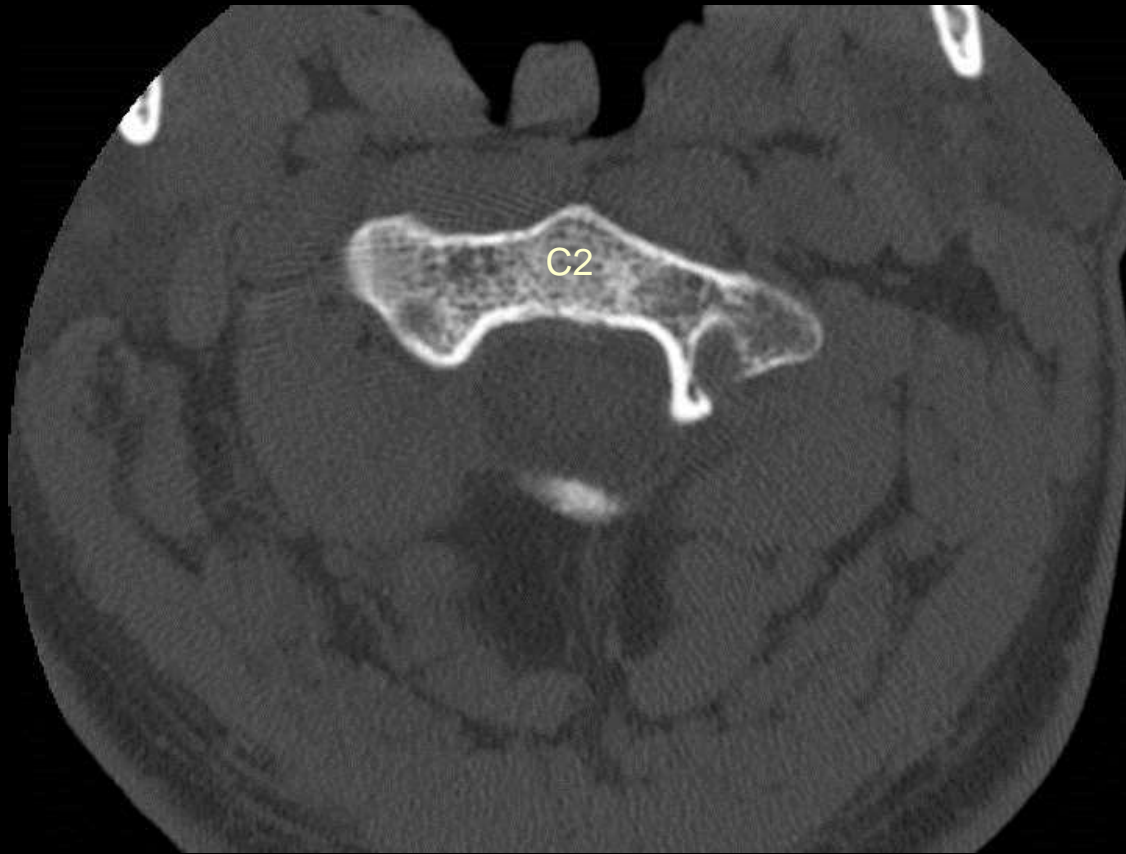
Occiptito-axial and C2-3 Fusions



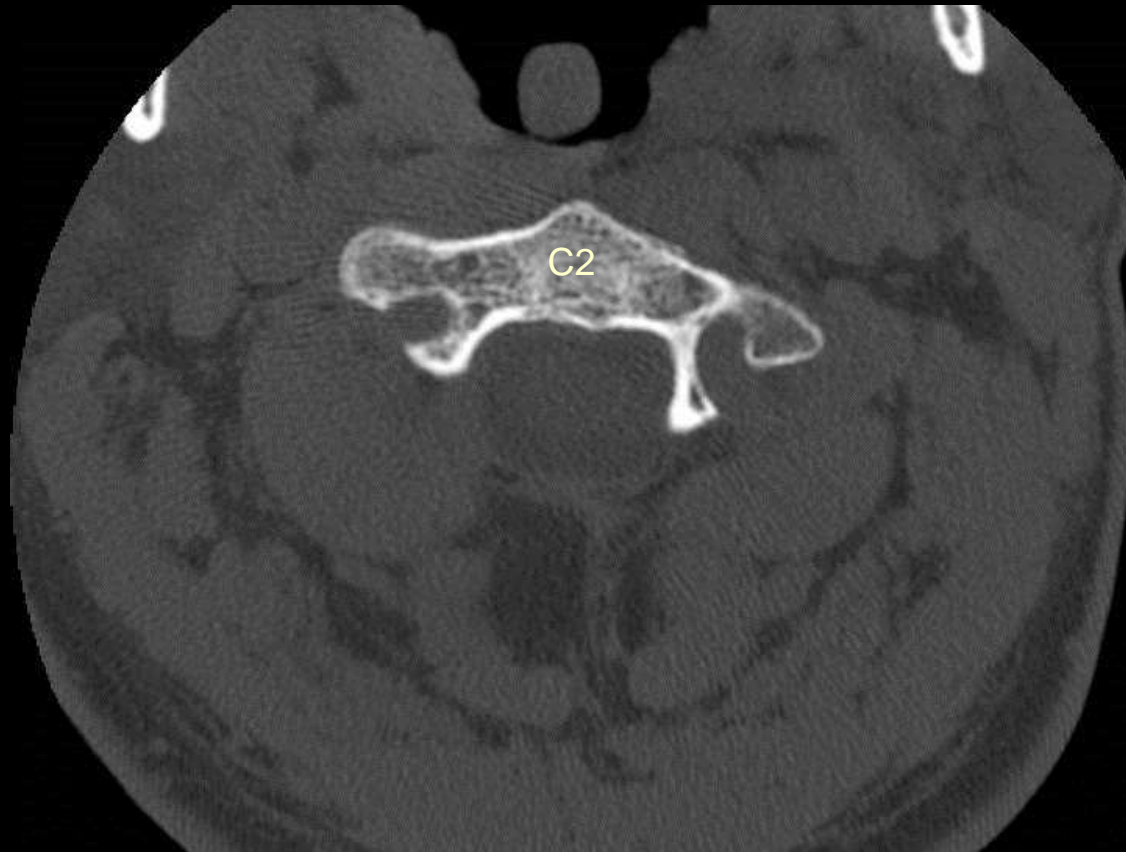
Occiptito-axial and C2-3 Fusions



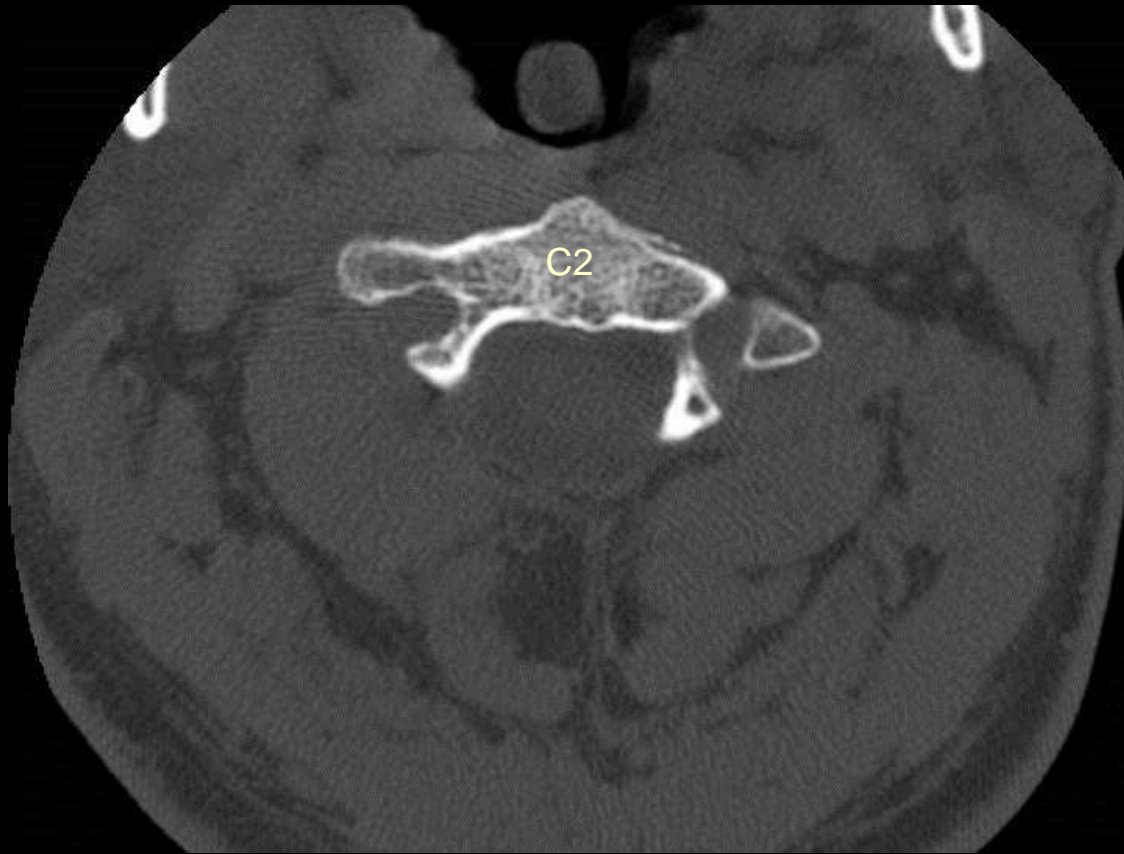
Occiptito-axial and C2-3 Fusions



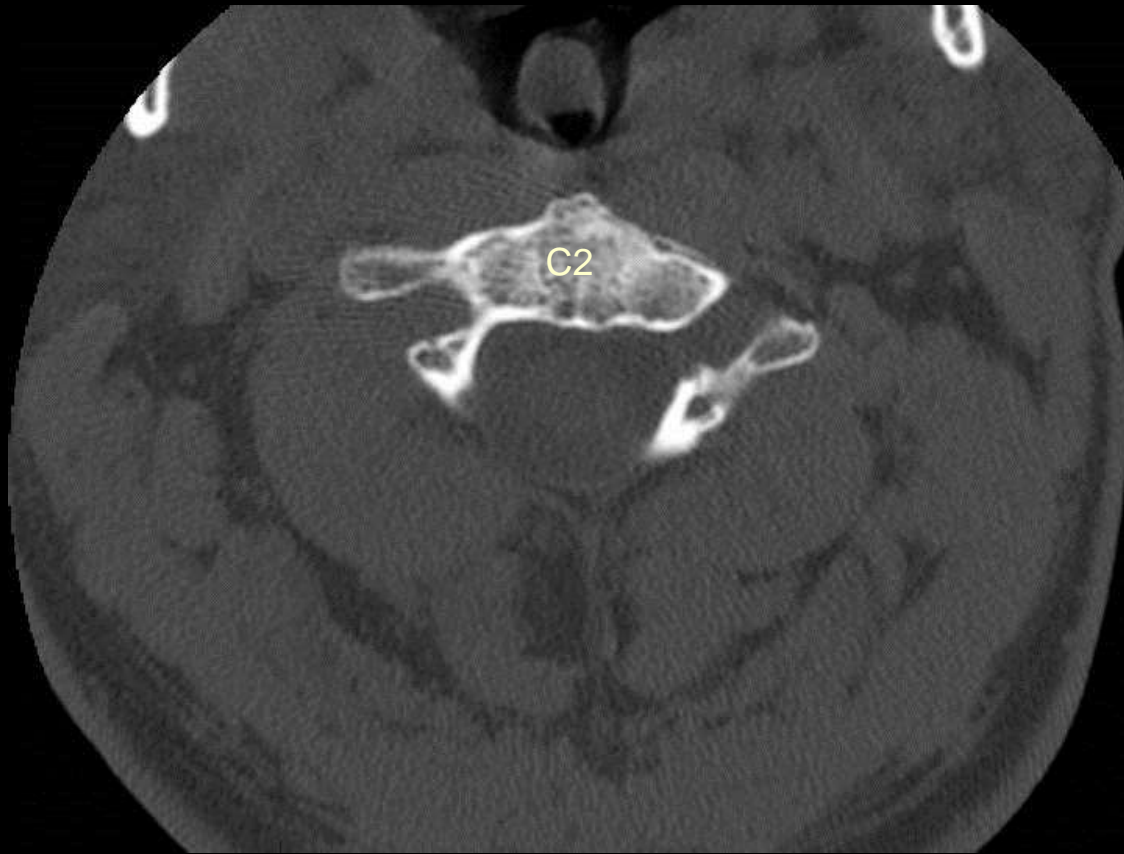Occiptito-axial and C2-3 Fusions



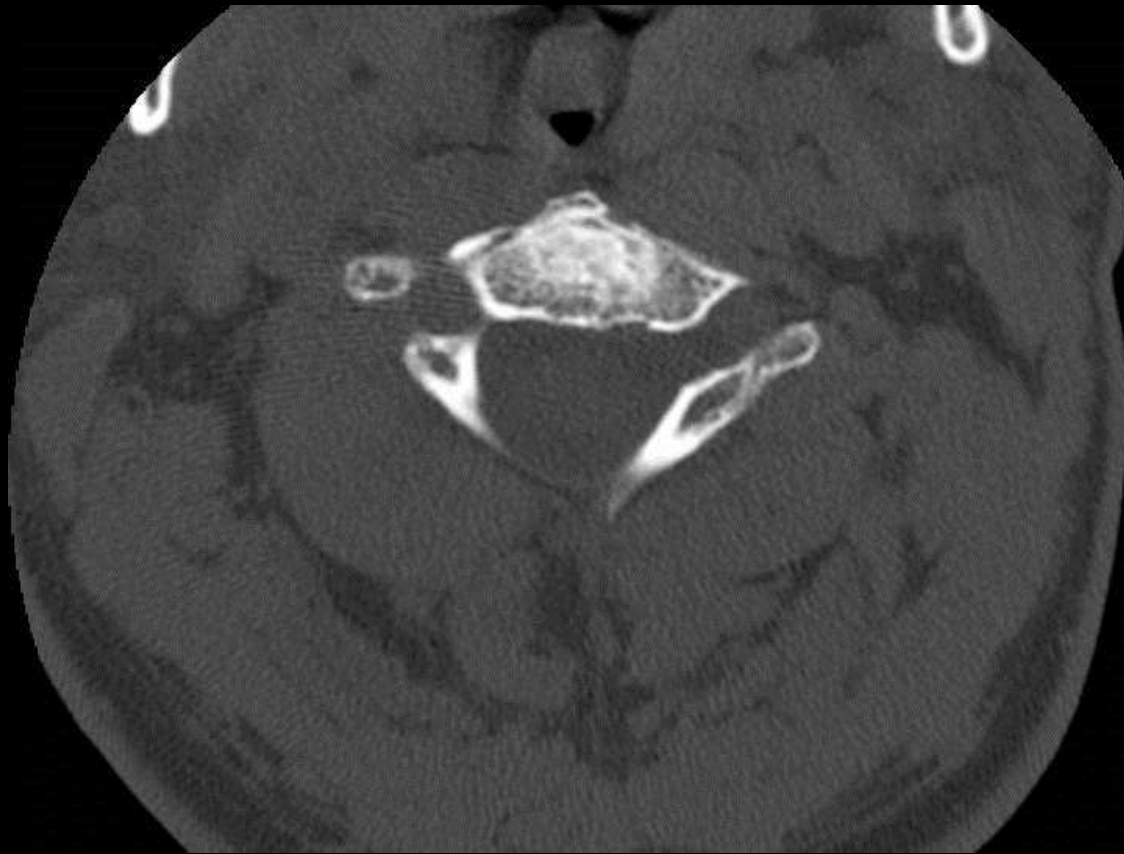Occiptito-axial and C2-3 Fusions



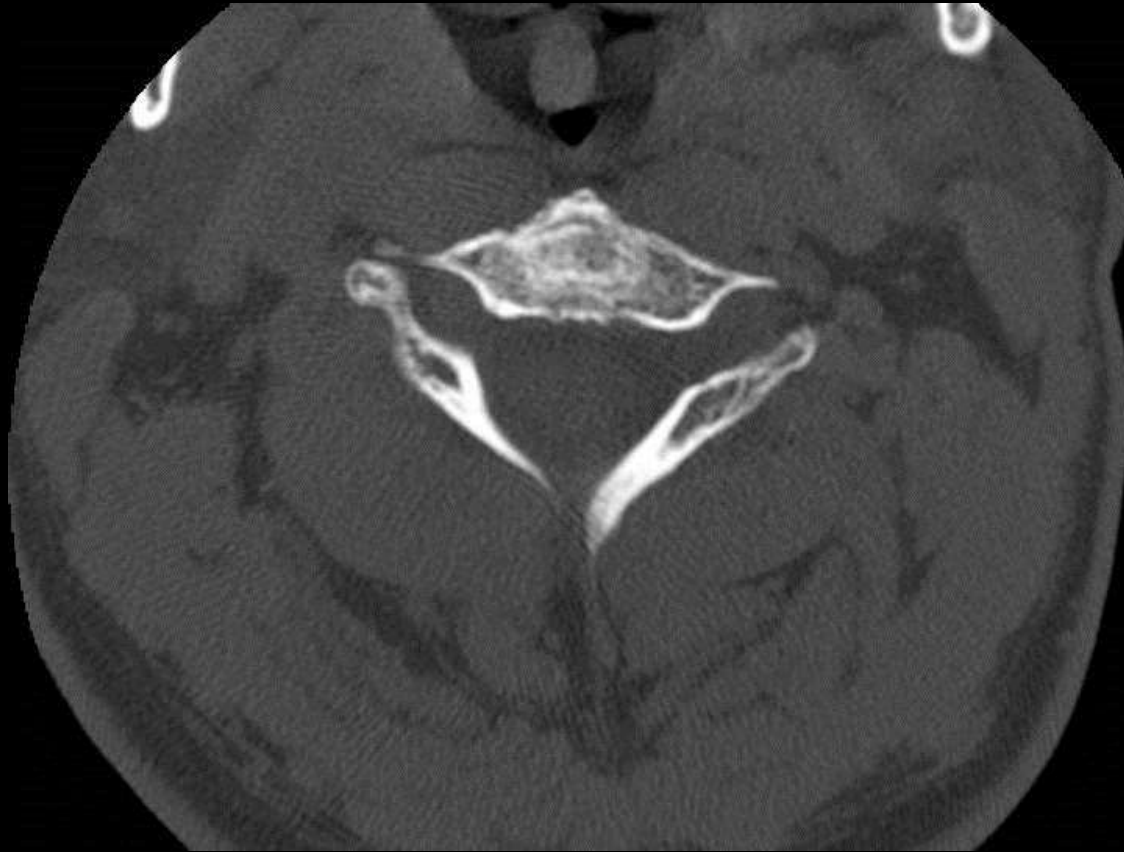Occiptito-axial and C2-3 Fusions



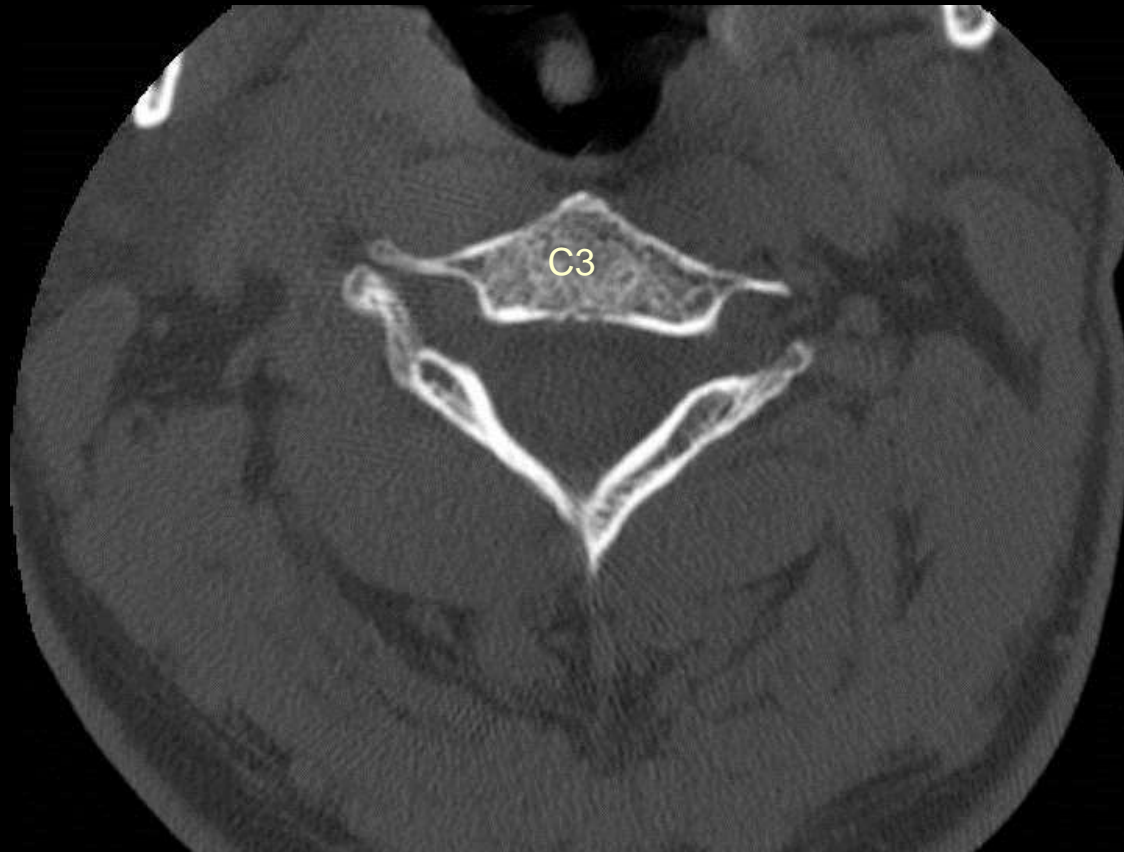Occiptito-axial and C2-3 Fusions



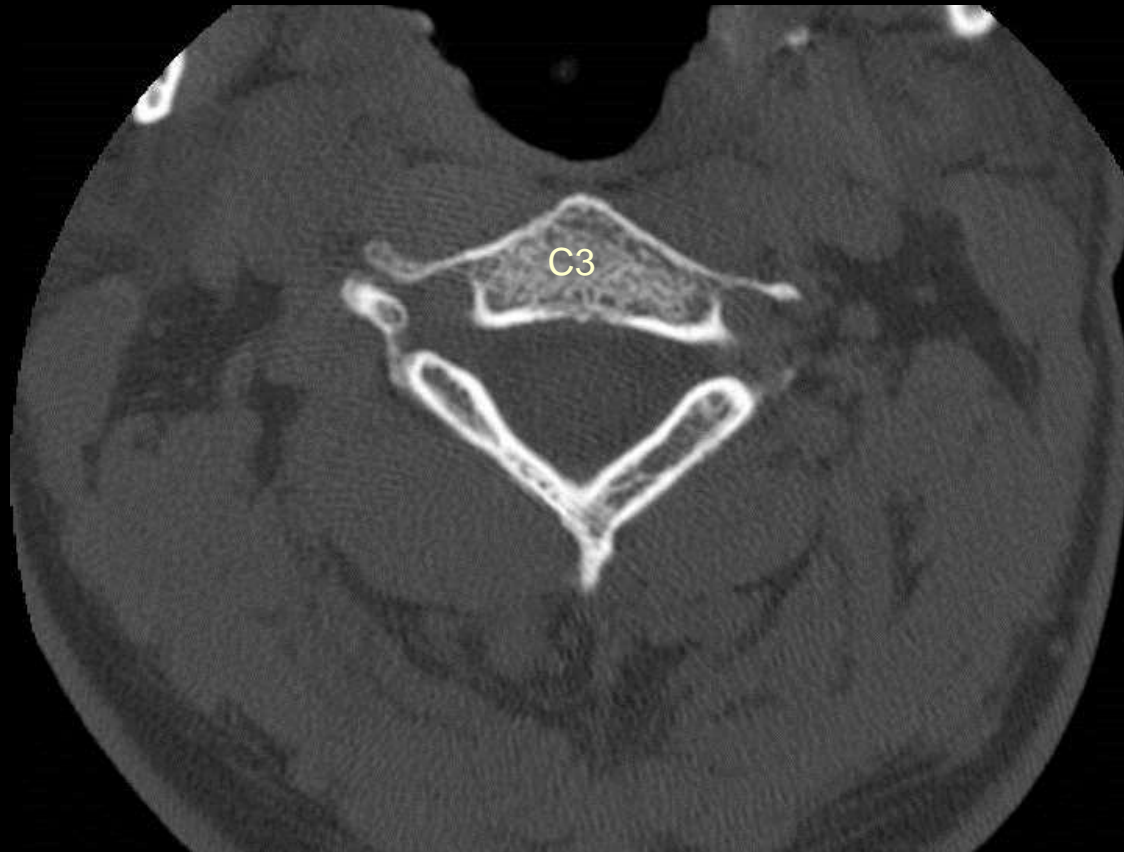
Occiptito-axial and C2-3 Fusions



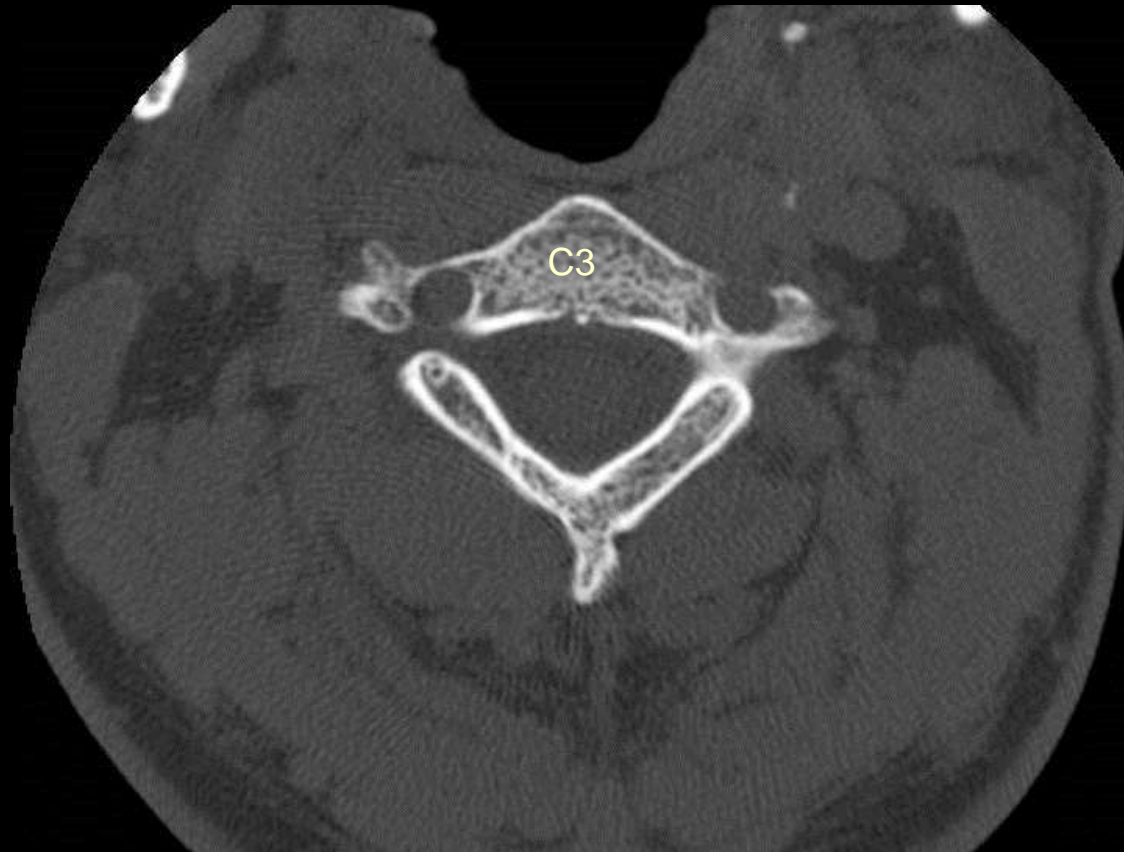
Occiptito-axial and C2-3 Fusions



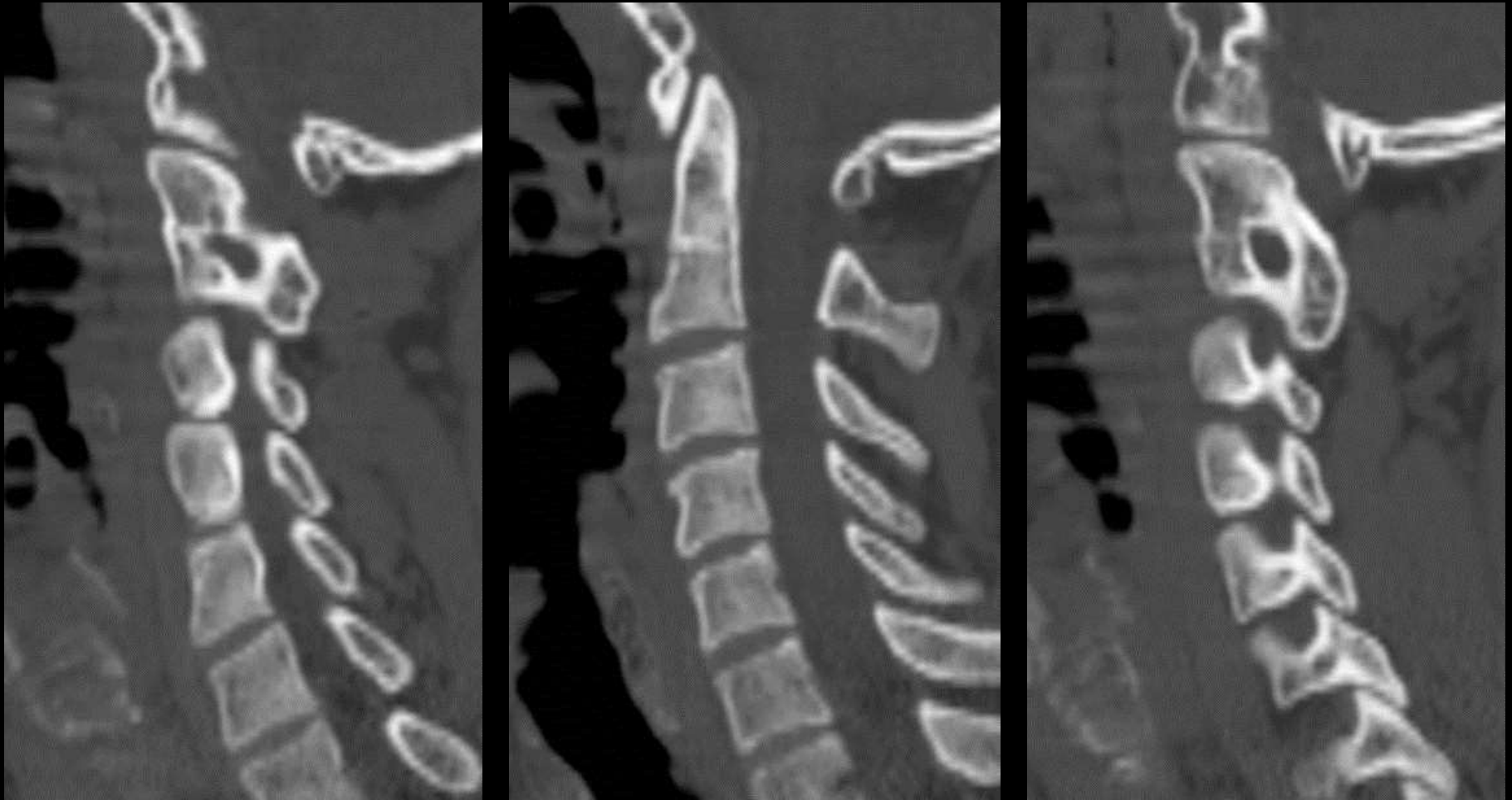Occiptito-axial and C2-3 Fusions



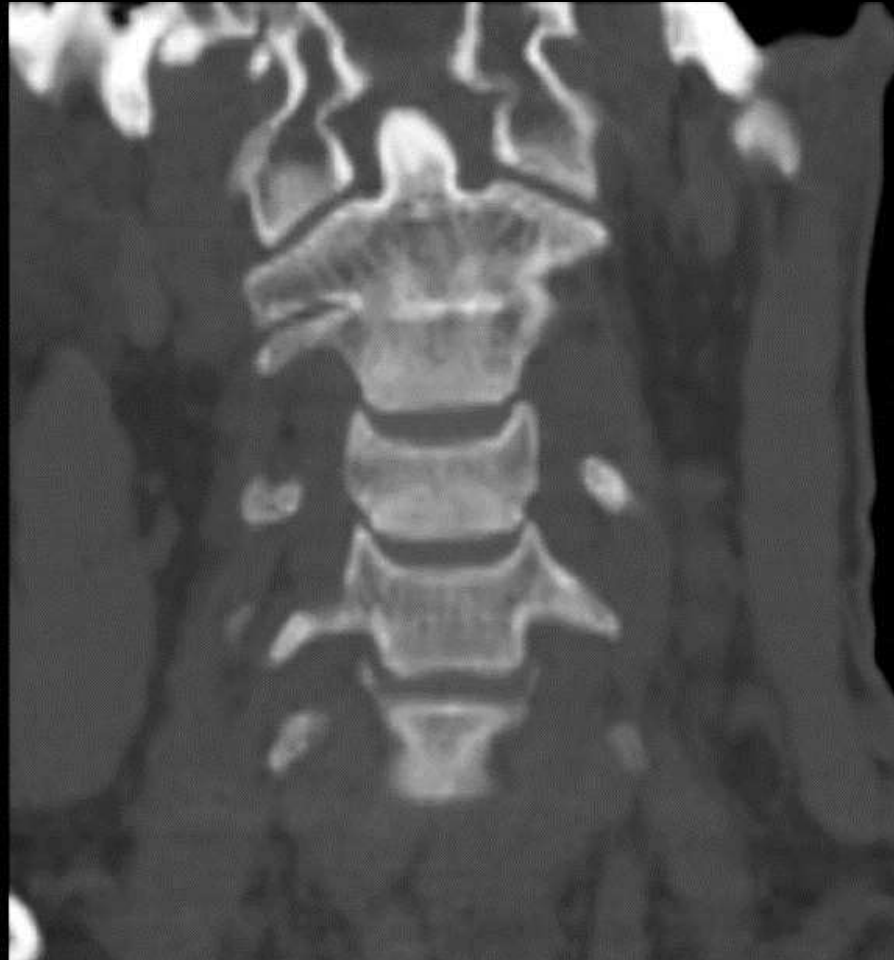Occipitito-axial and C2-3 Fusions



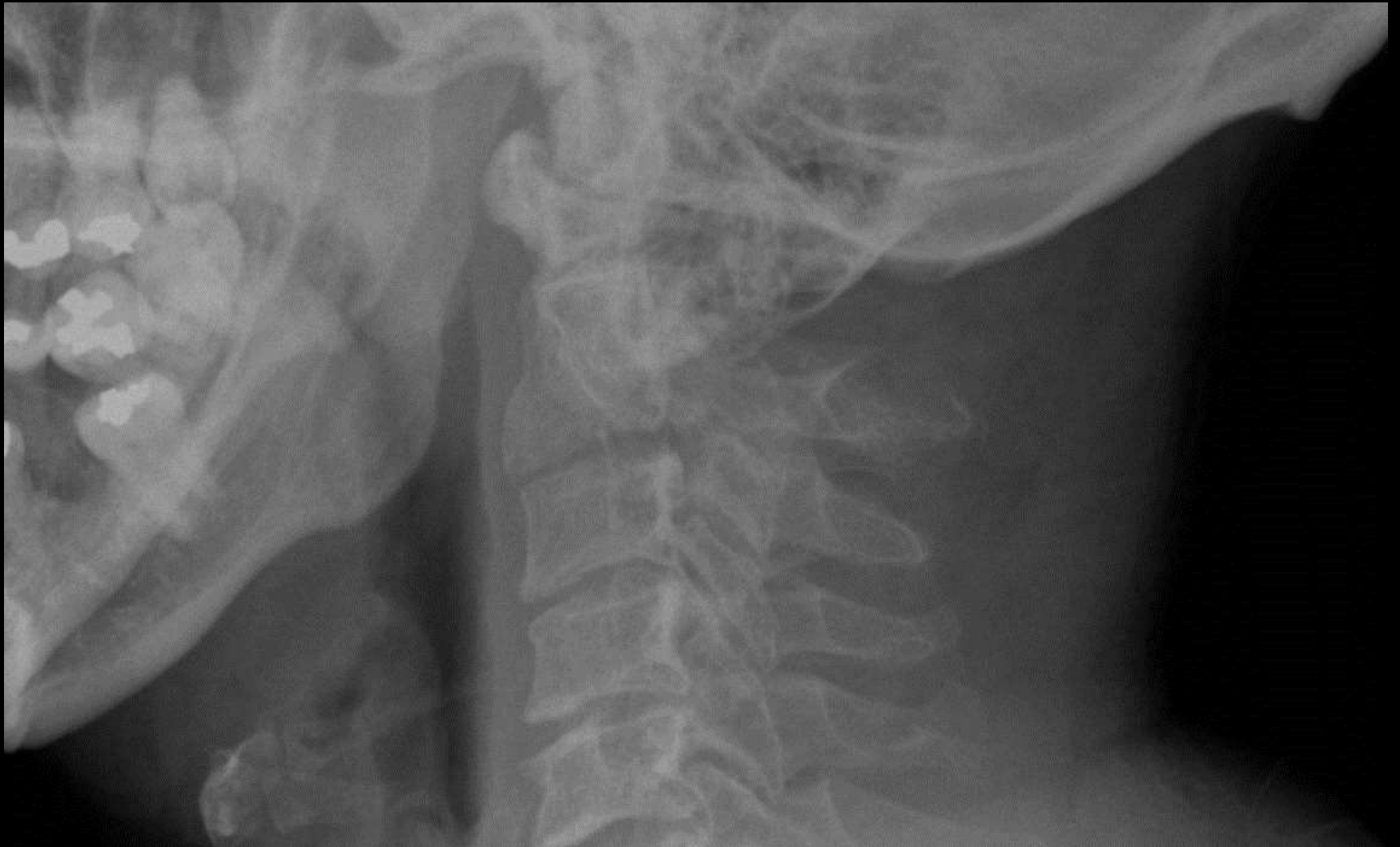Occipitocranial and C2-3 Fusions



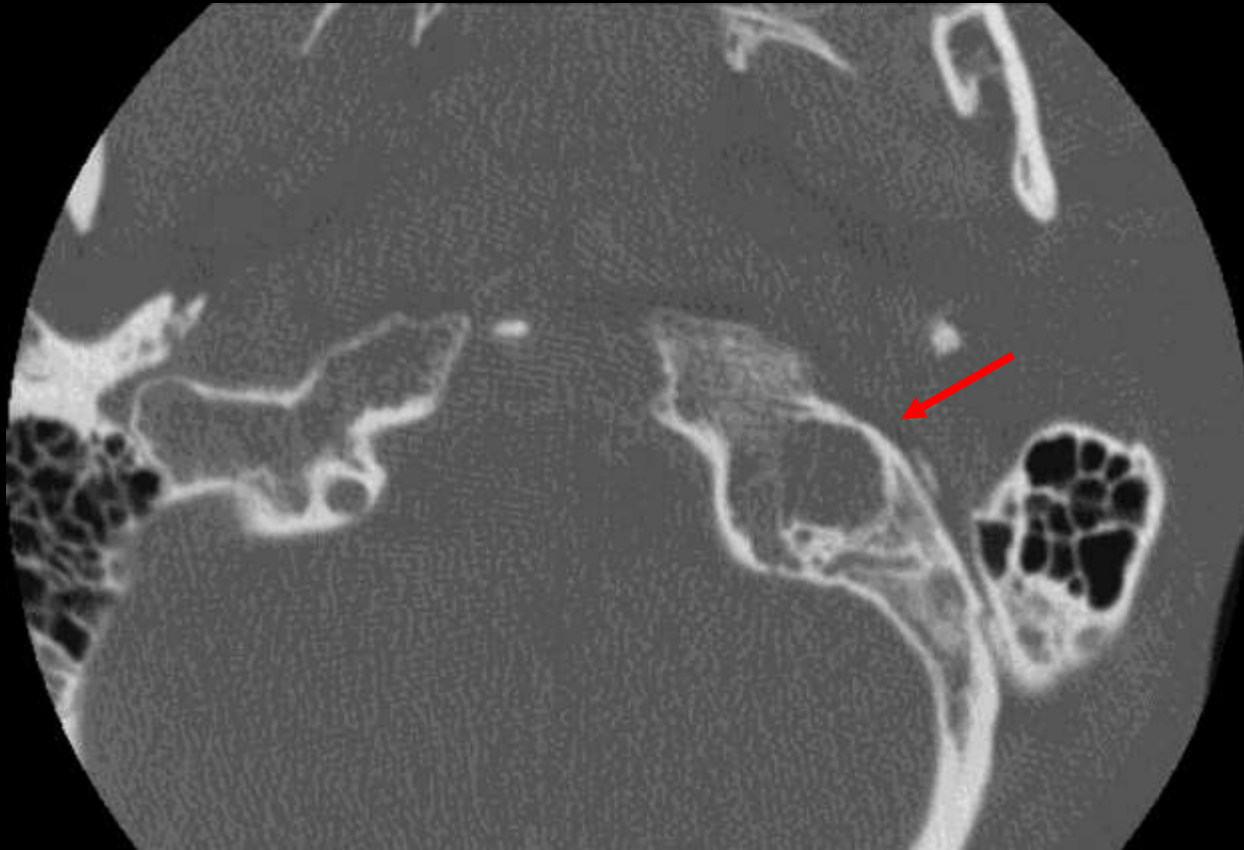Occiptito-axial and C2-3 Fusions



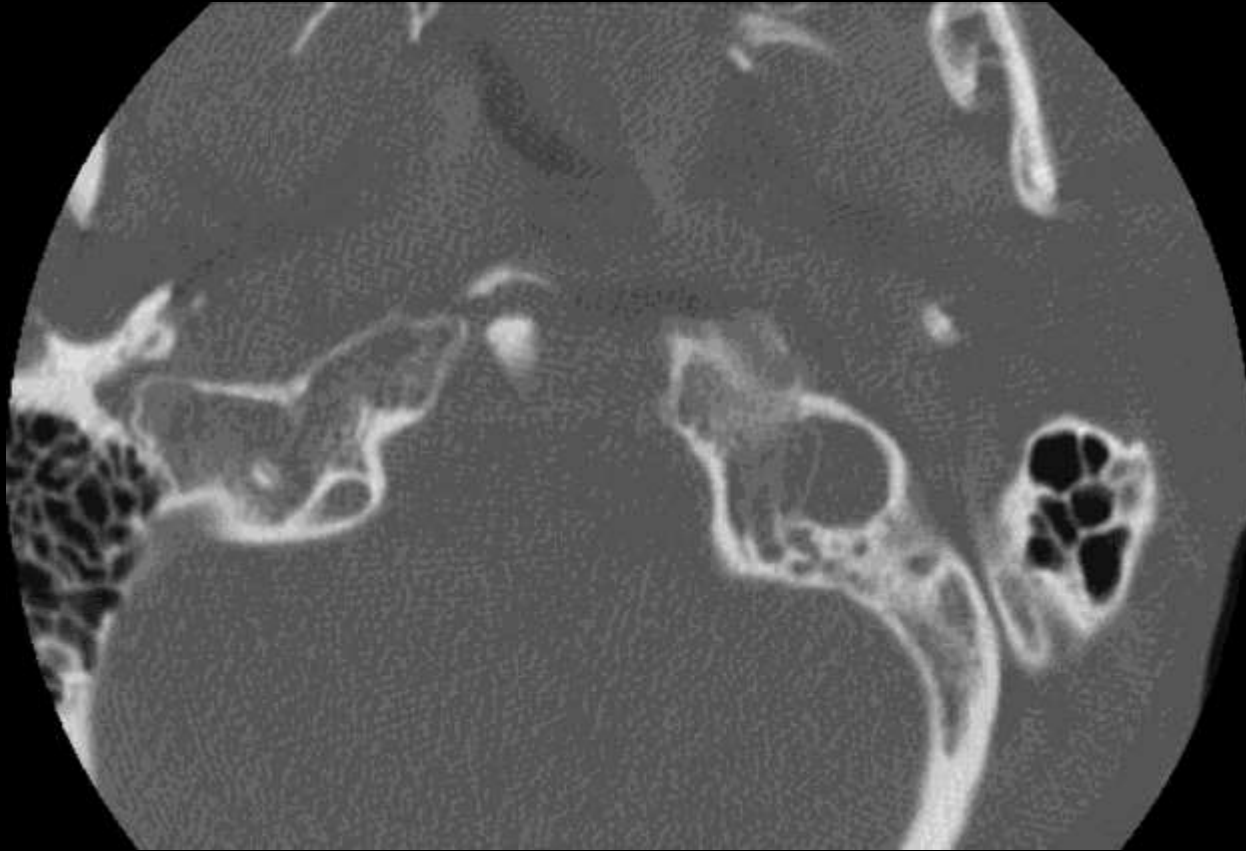
Occipital Vertebrae



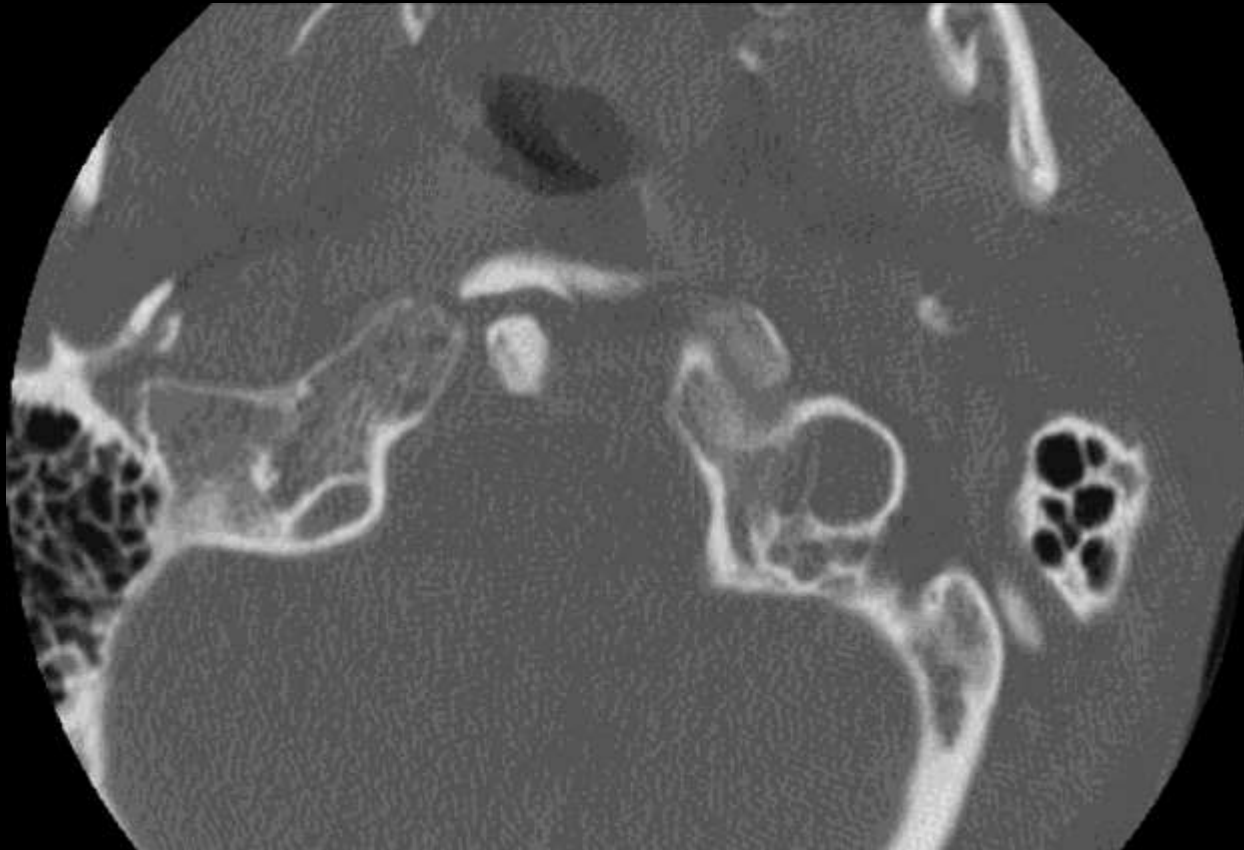
Occipital Vertebrae



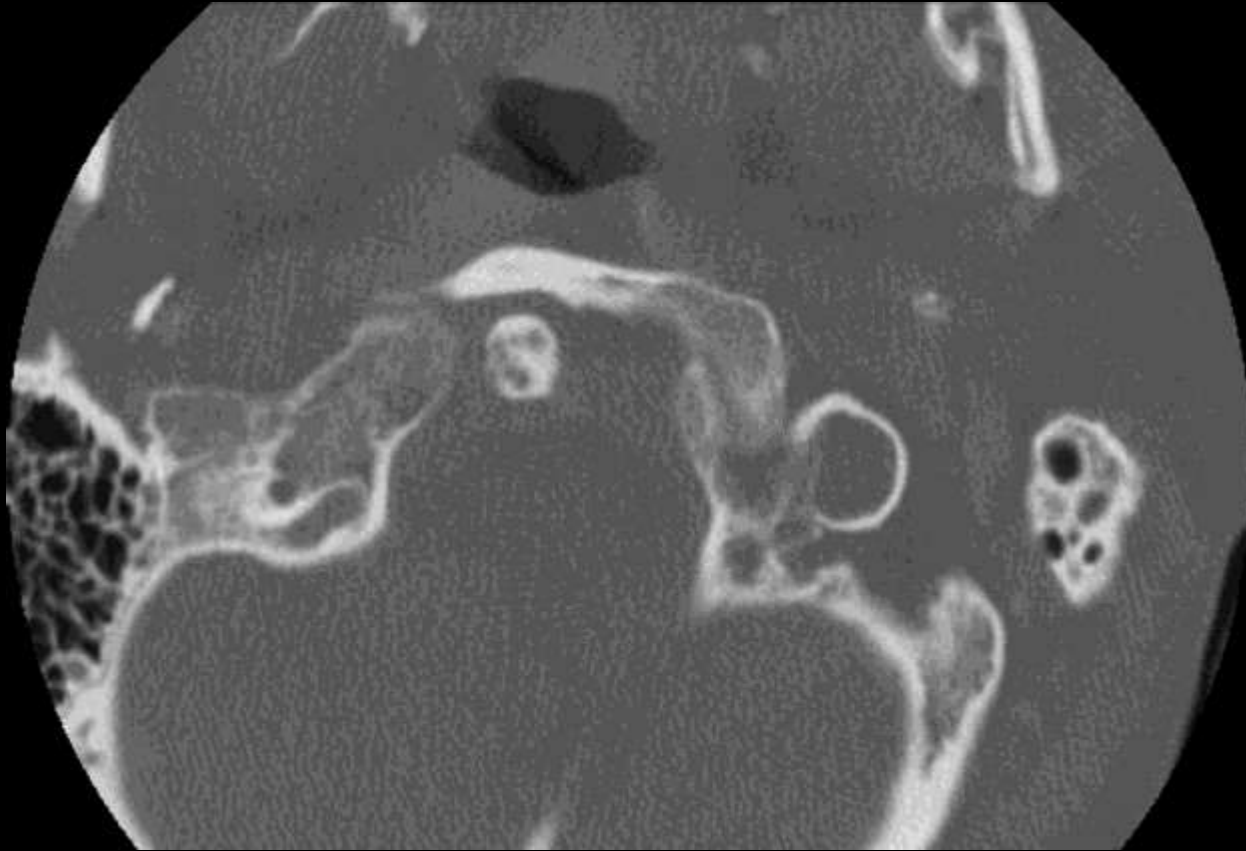
Occipital Vertebrae



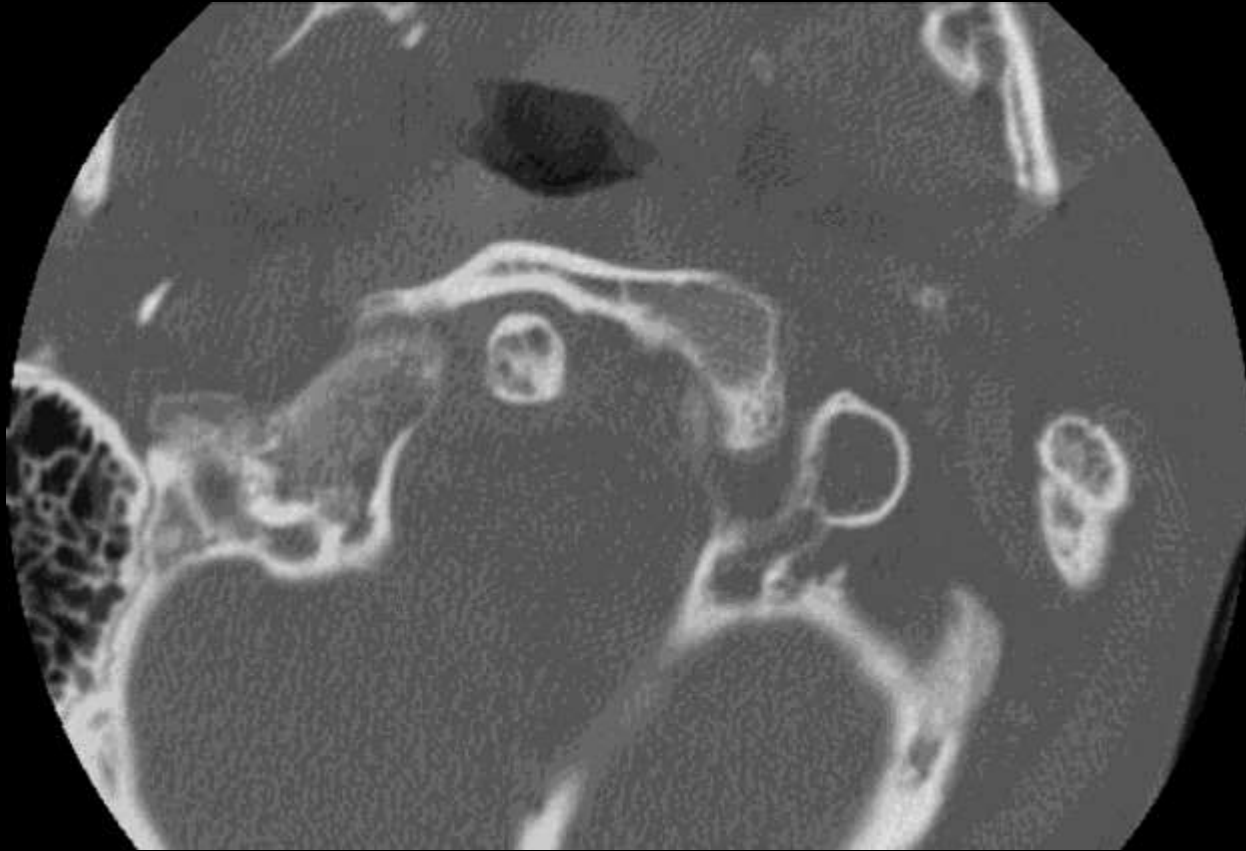Occipital Vertebrae



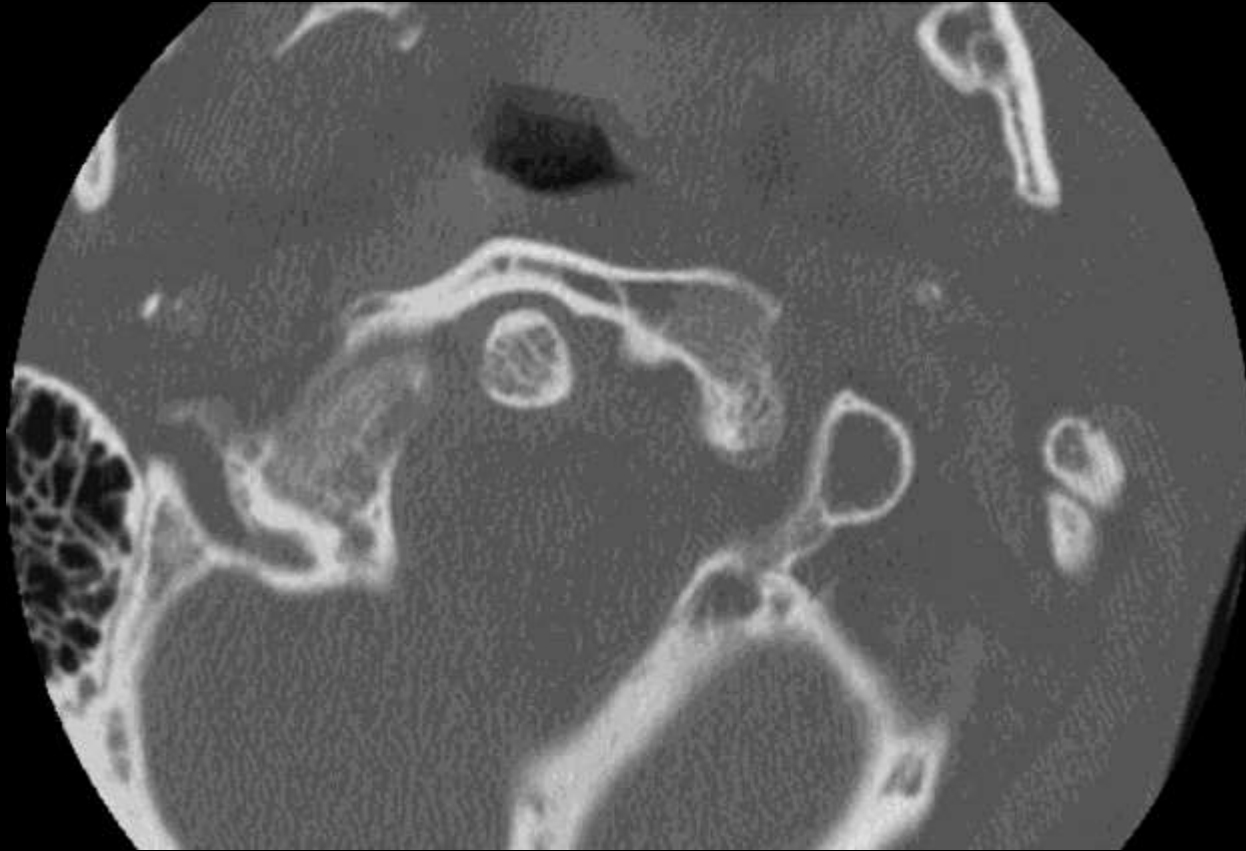Occipital Vertebrae



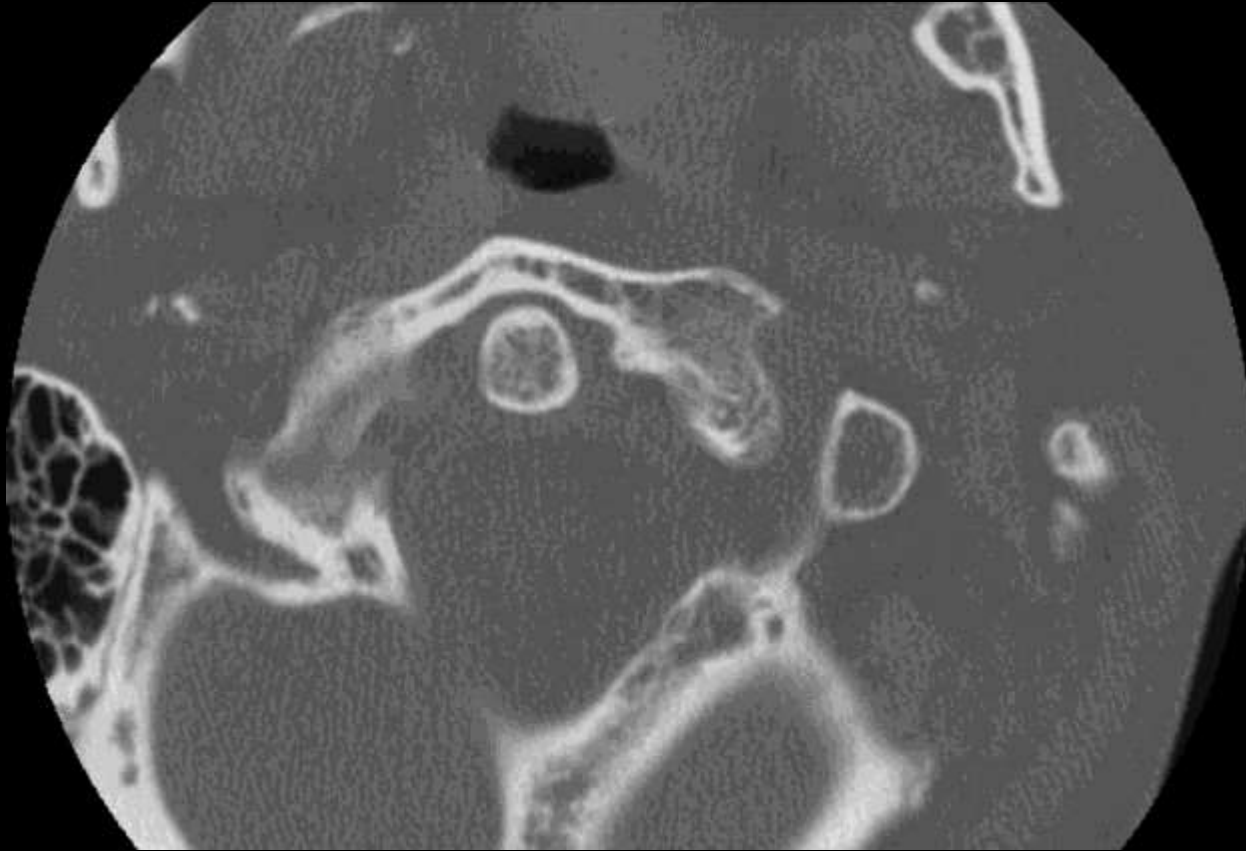Occipital Vertebrae



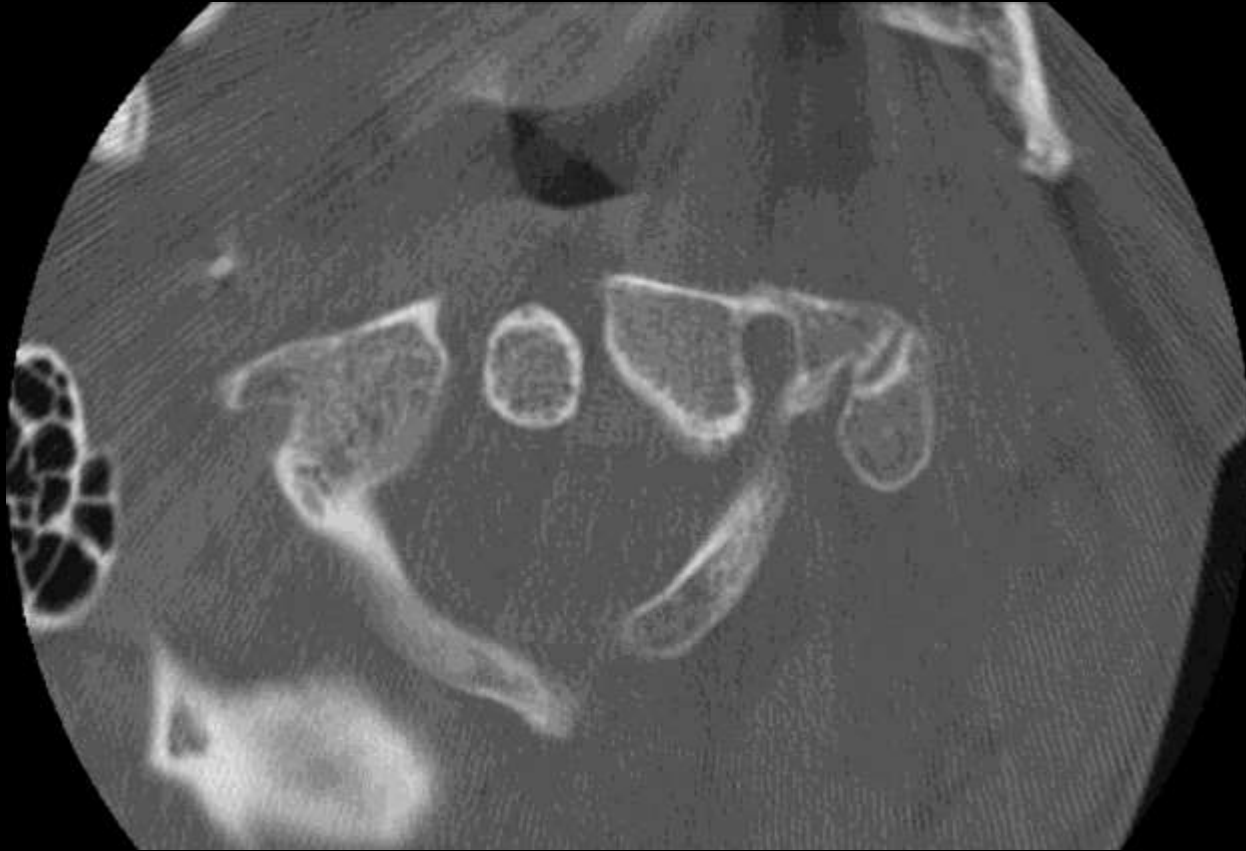Occipital Vertebrae



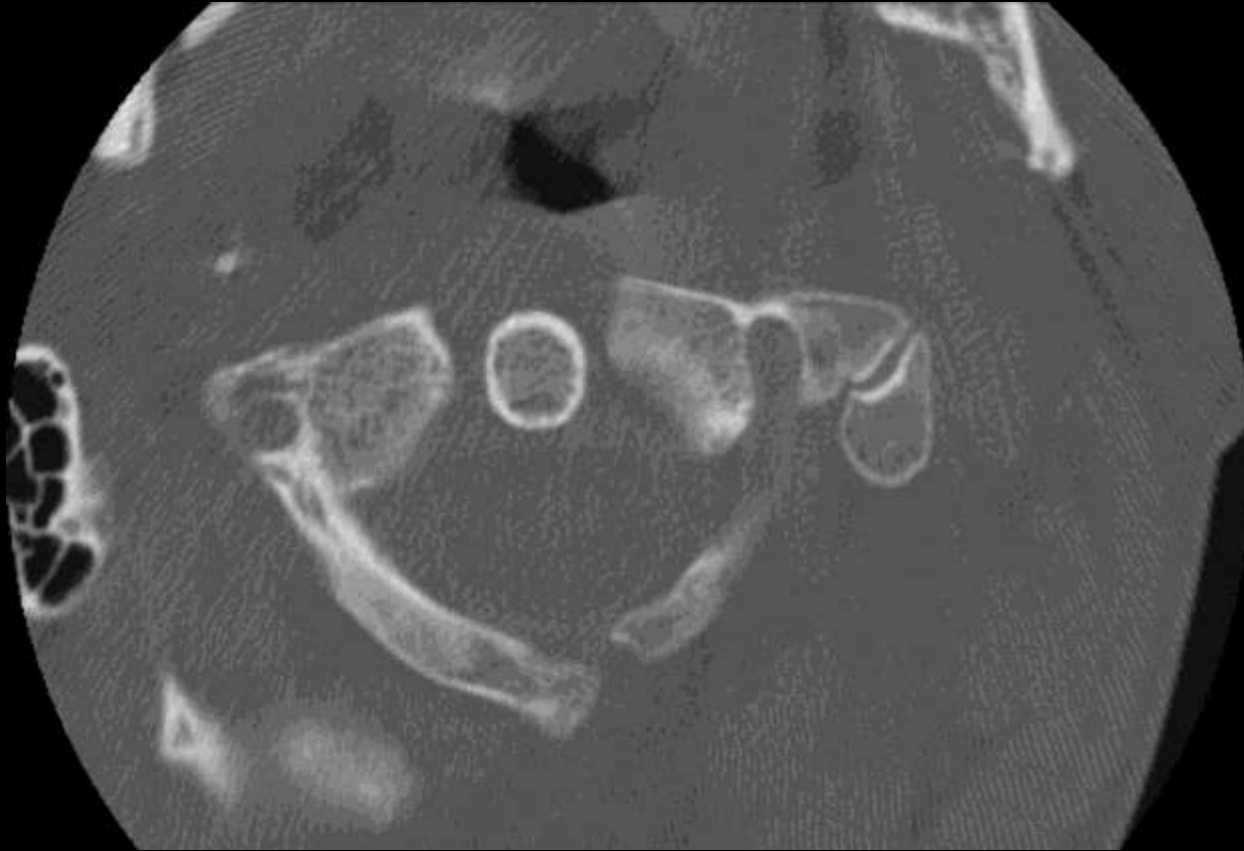Occipital Vertebrae



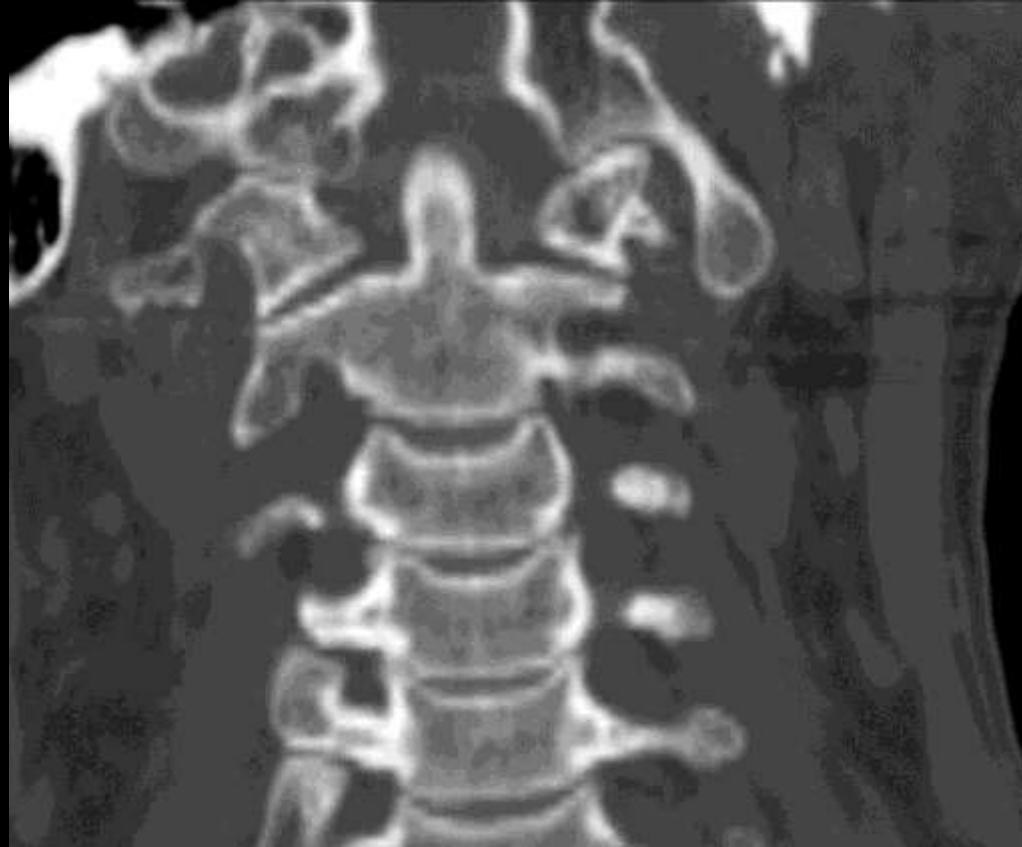Occipital Vertebrae



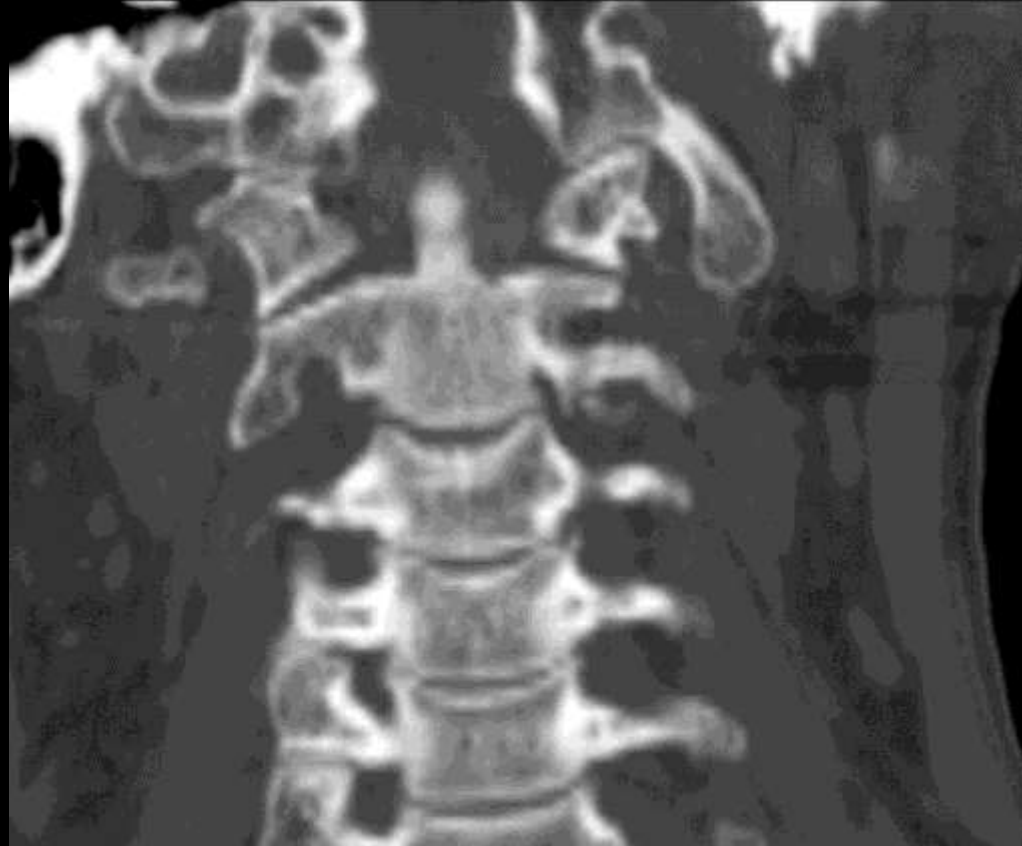Occipital Vertebrae



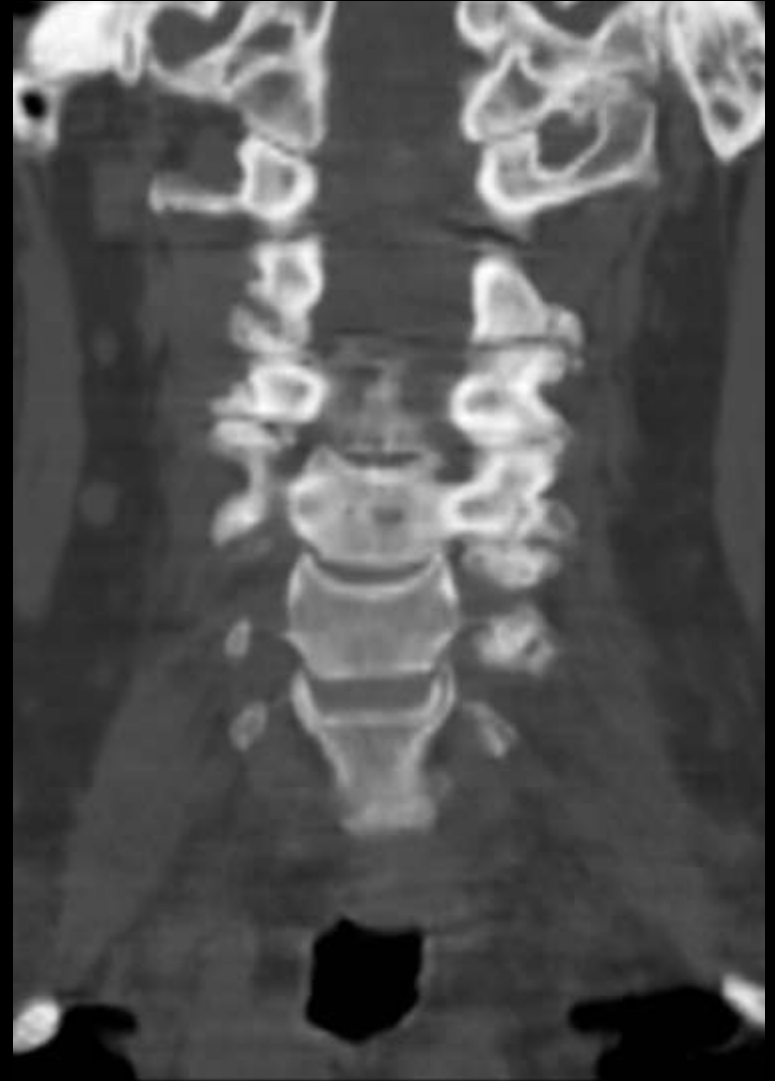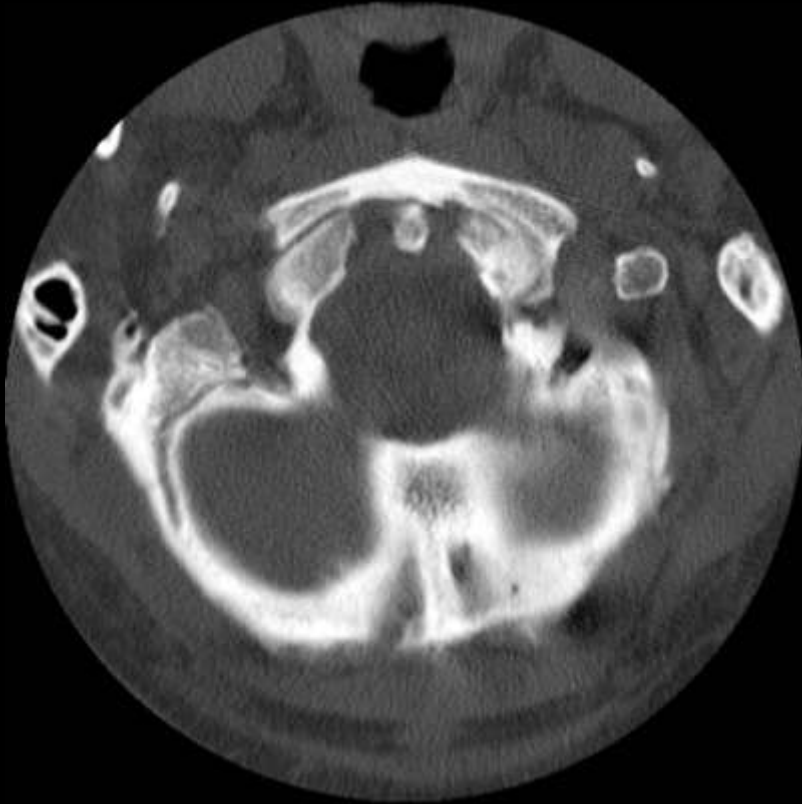Occipital Vertebrae



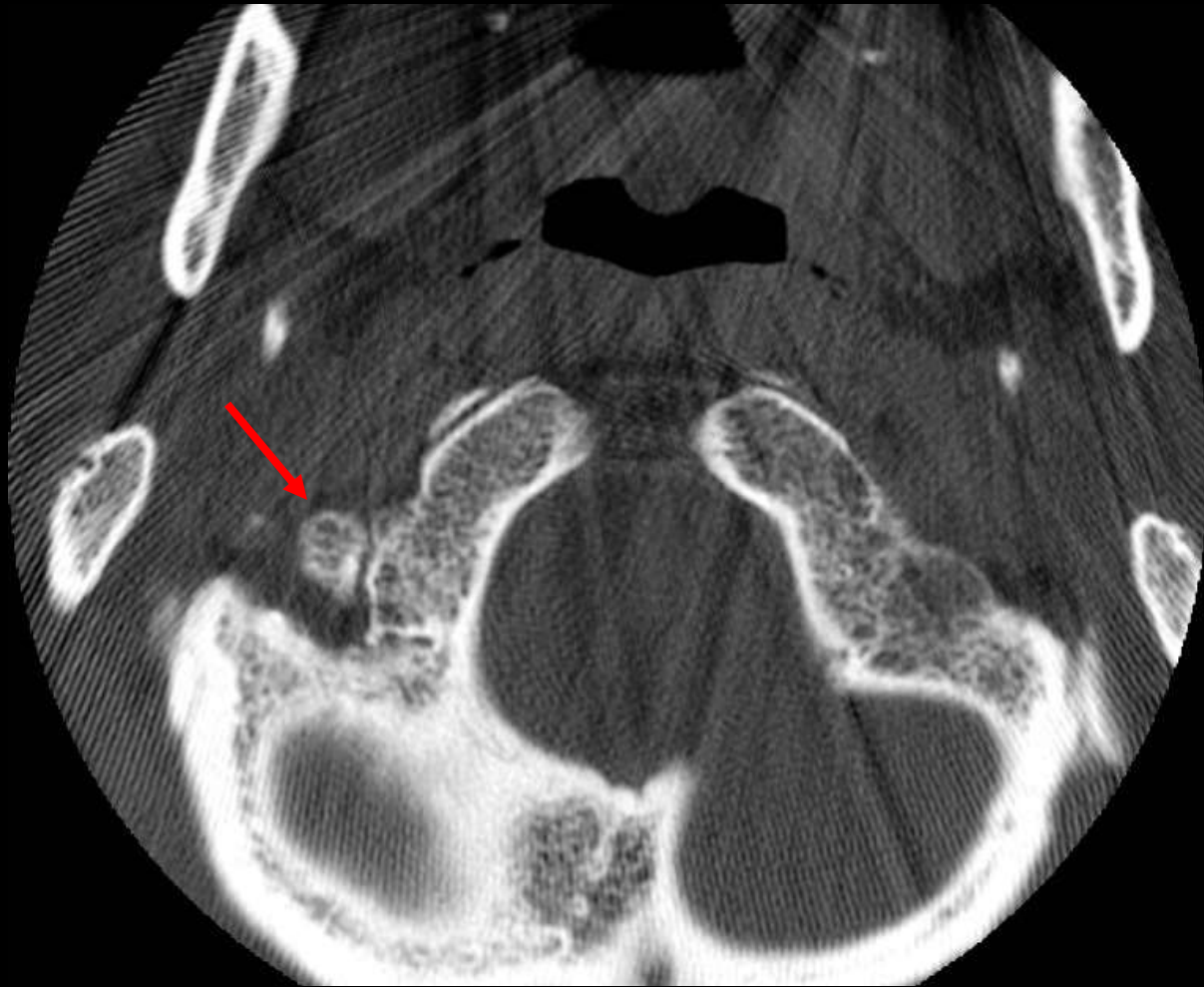Occipital Vertebrae



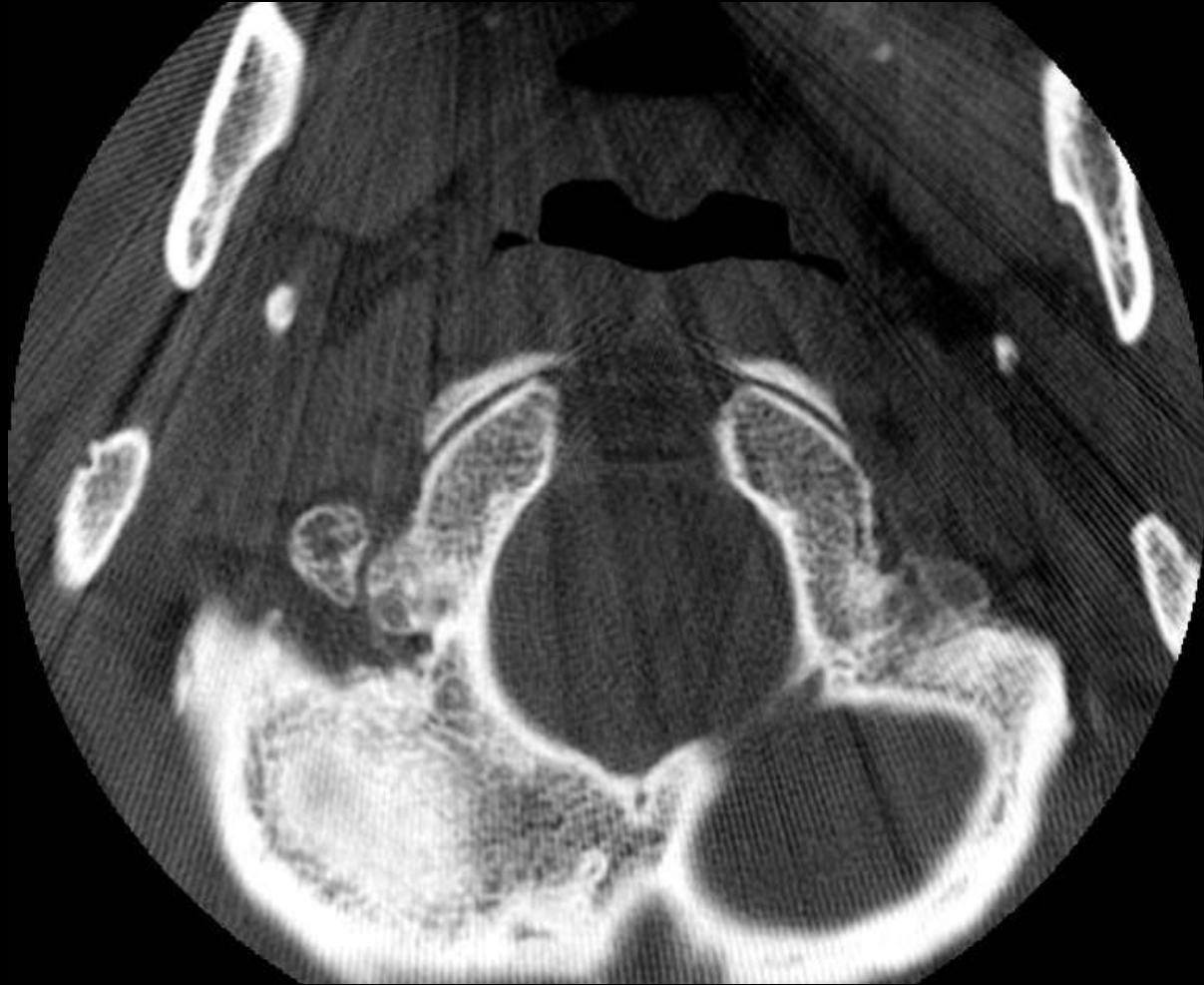Occipitoatlas transitional vertebrae



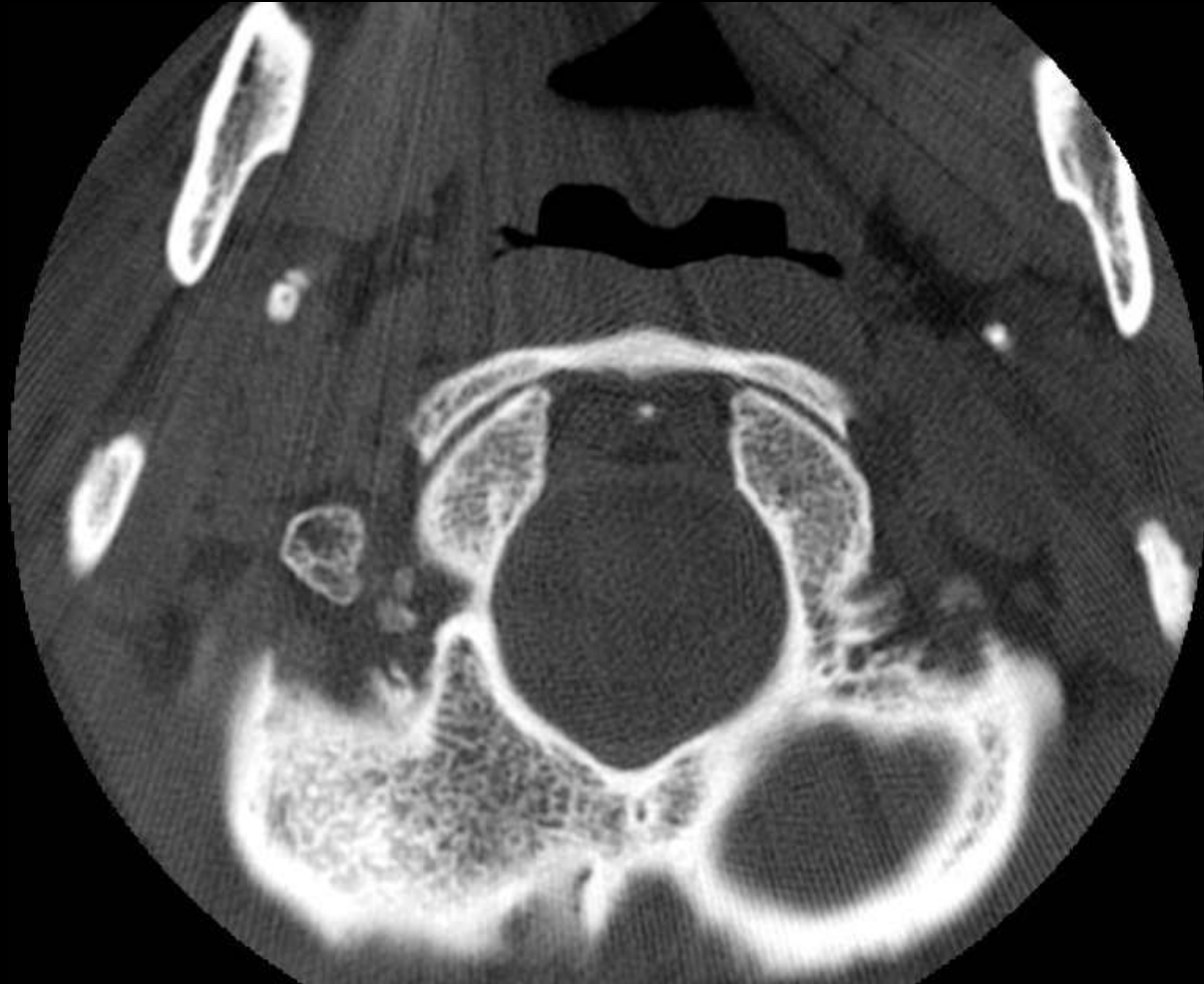
Occipital Vertebrae



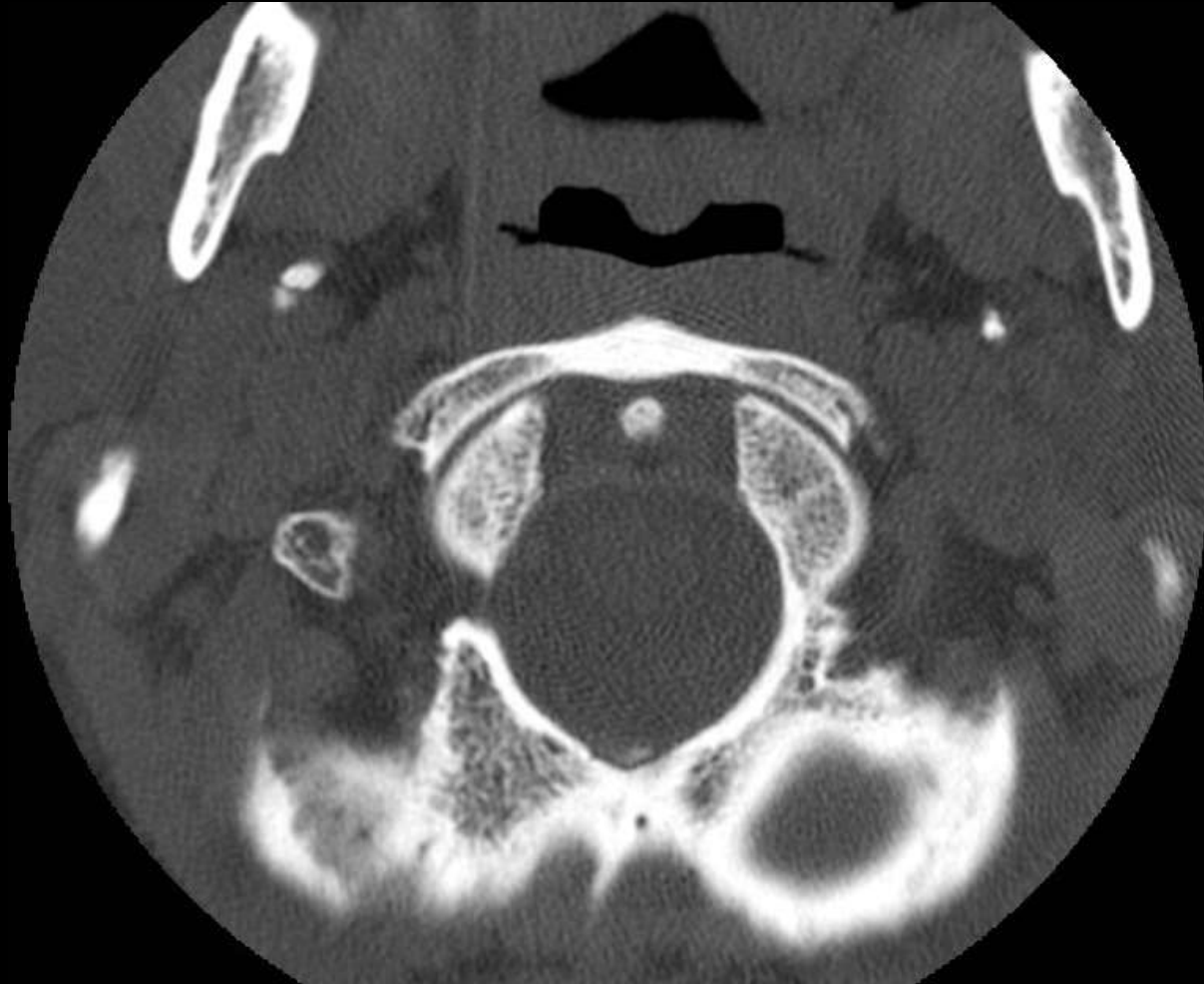Occipital Vertebrae



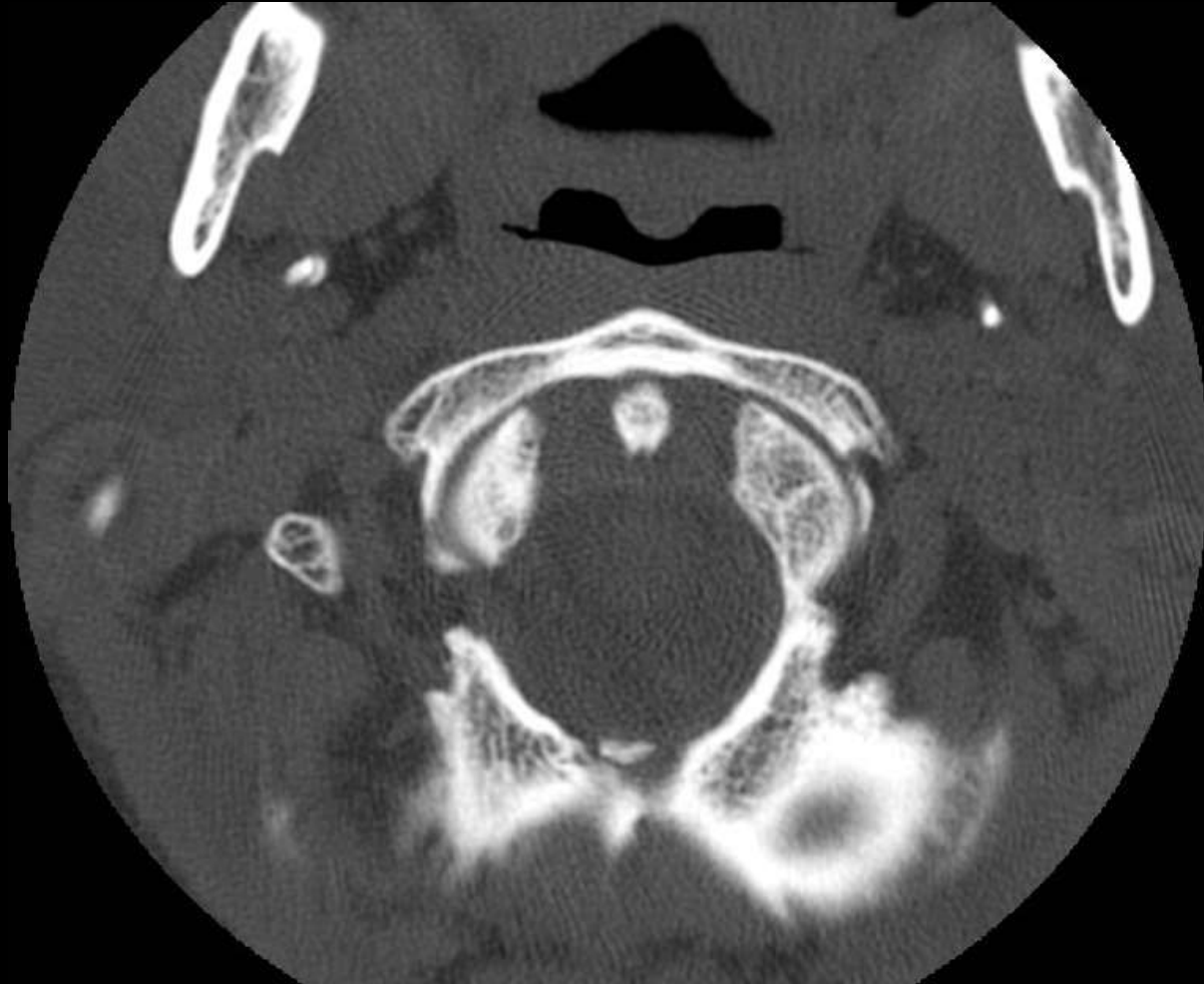
Occipital Vertebrae



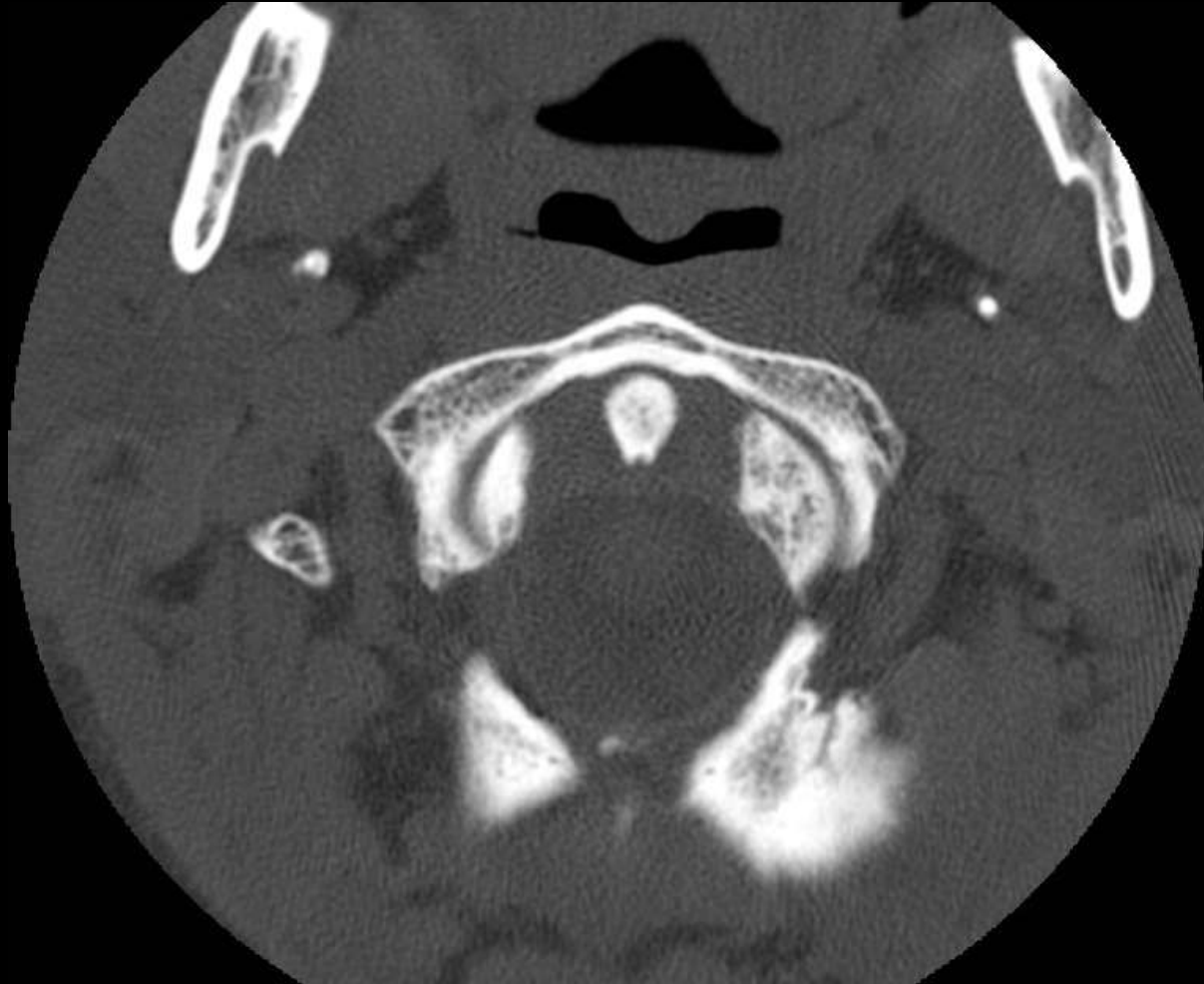
Occipital Vertebrae



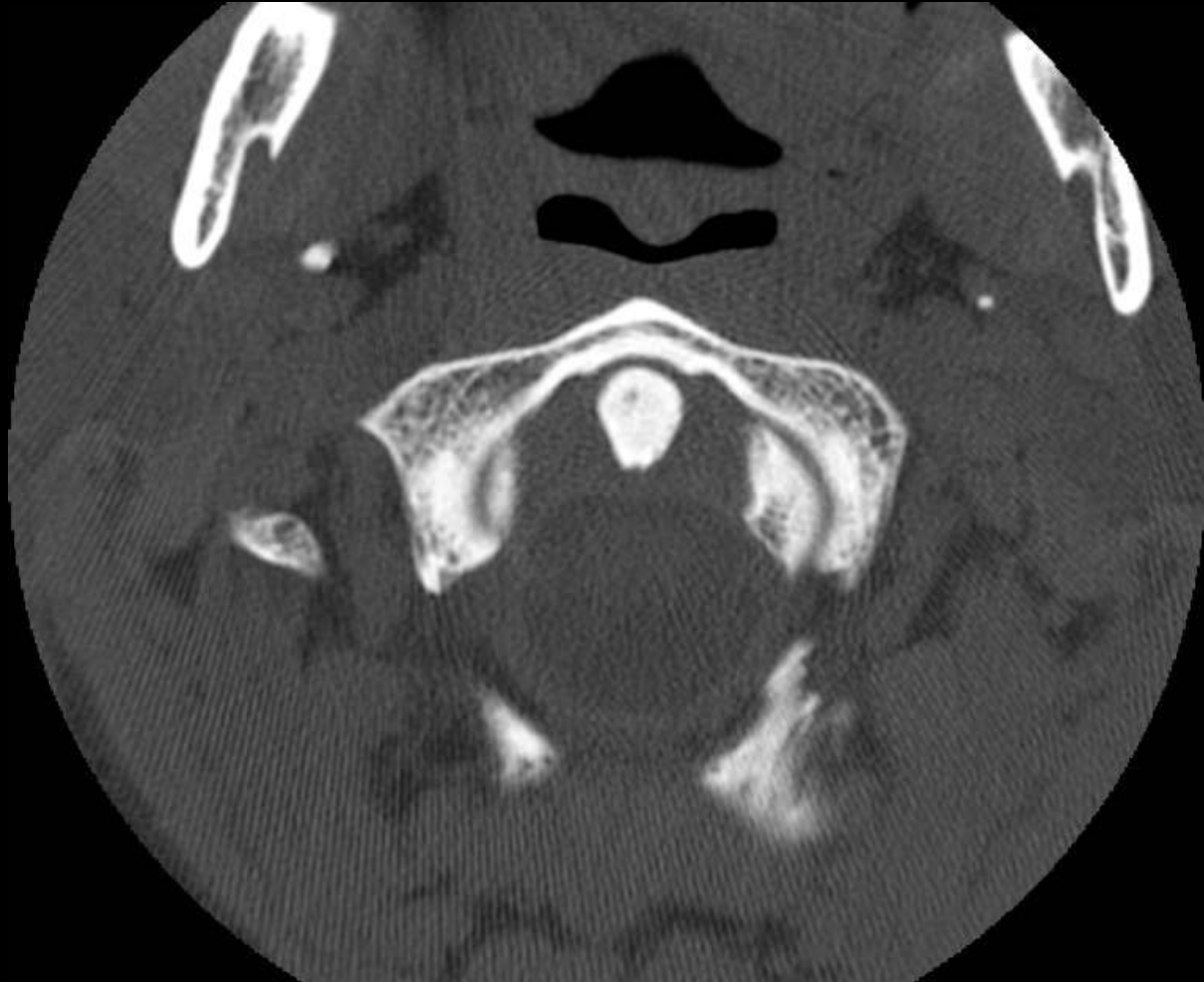
Occipital Vertebrae



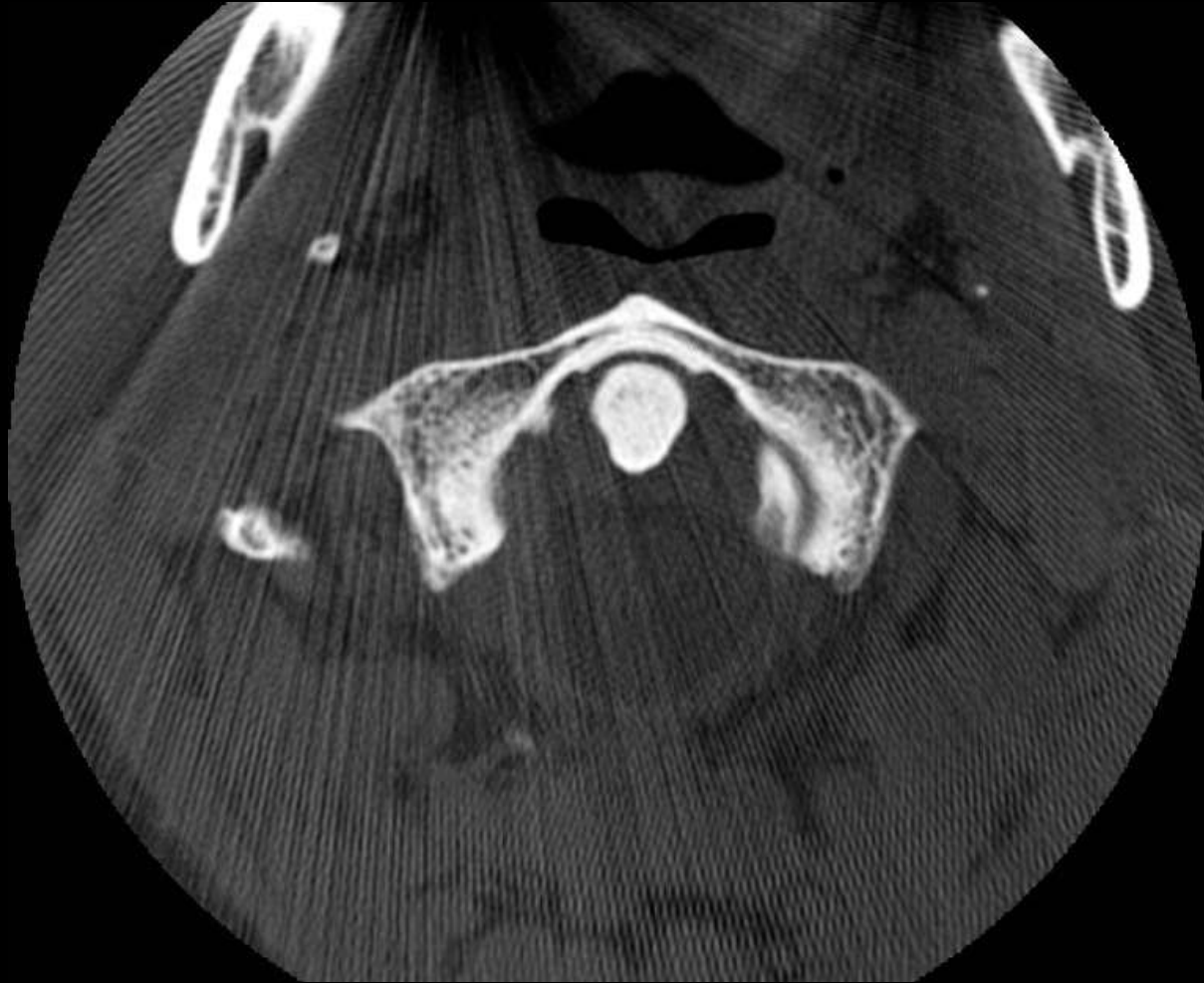Occipital Vertebrae



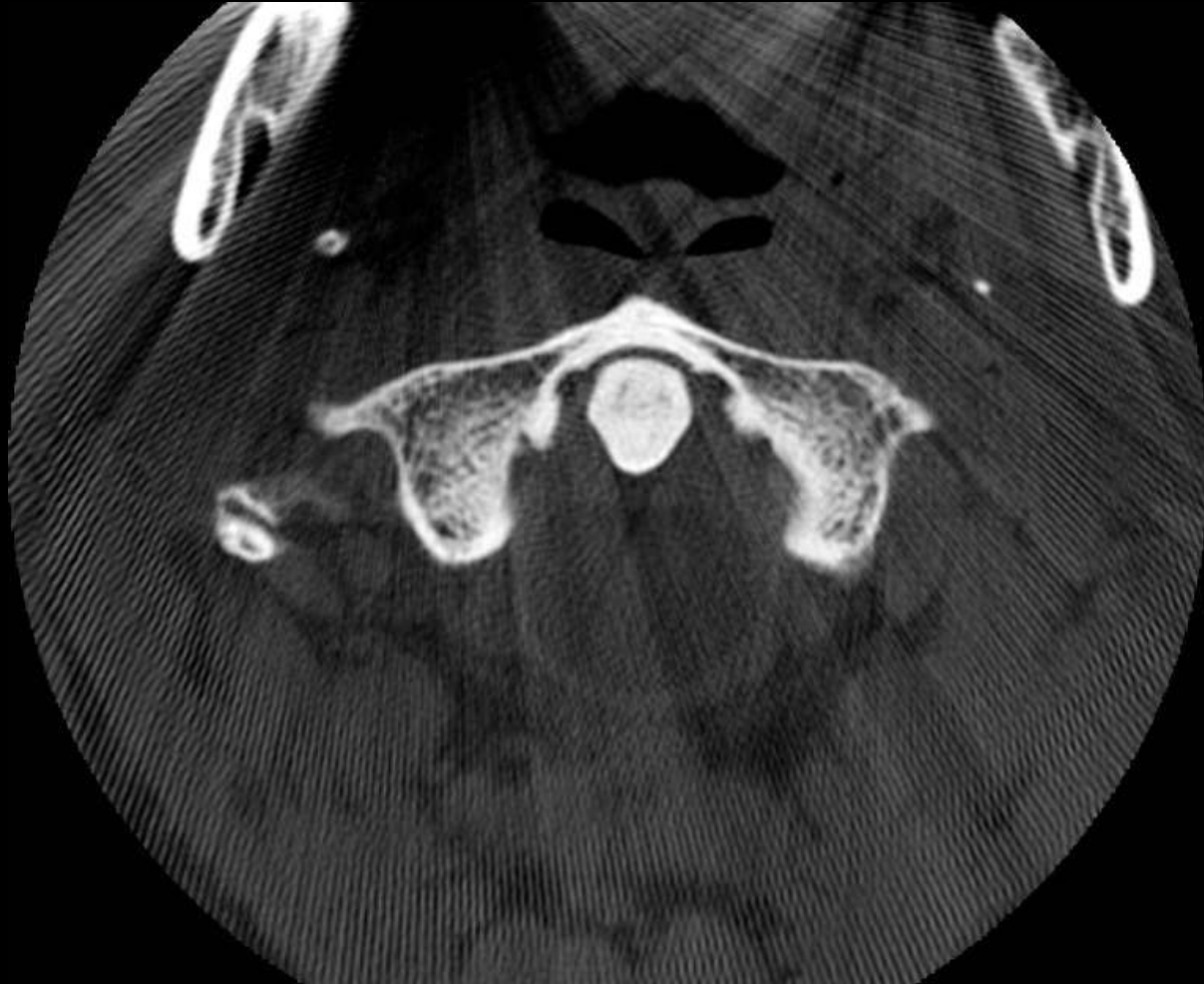Occipital Vertebrae



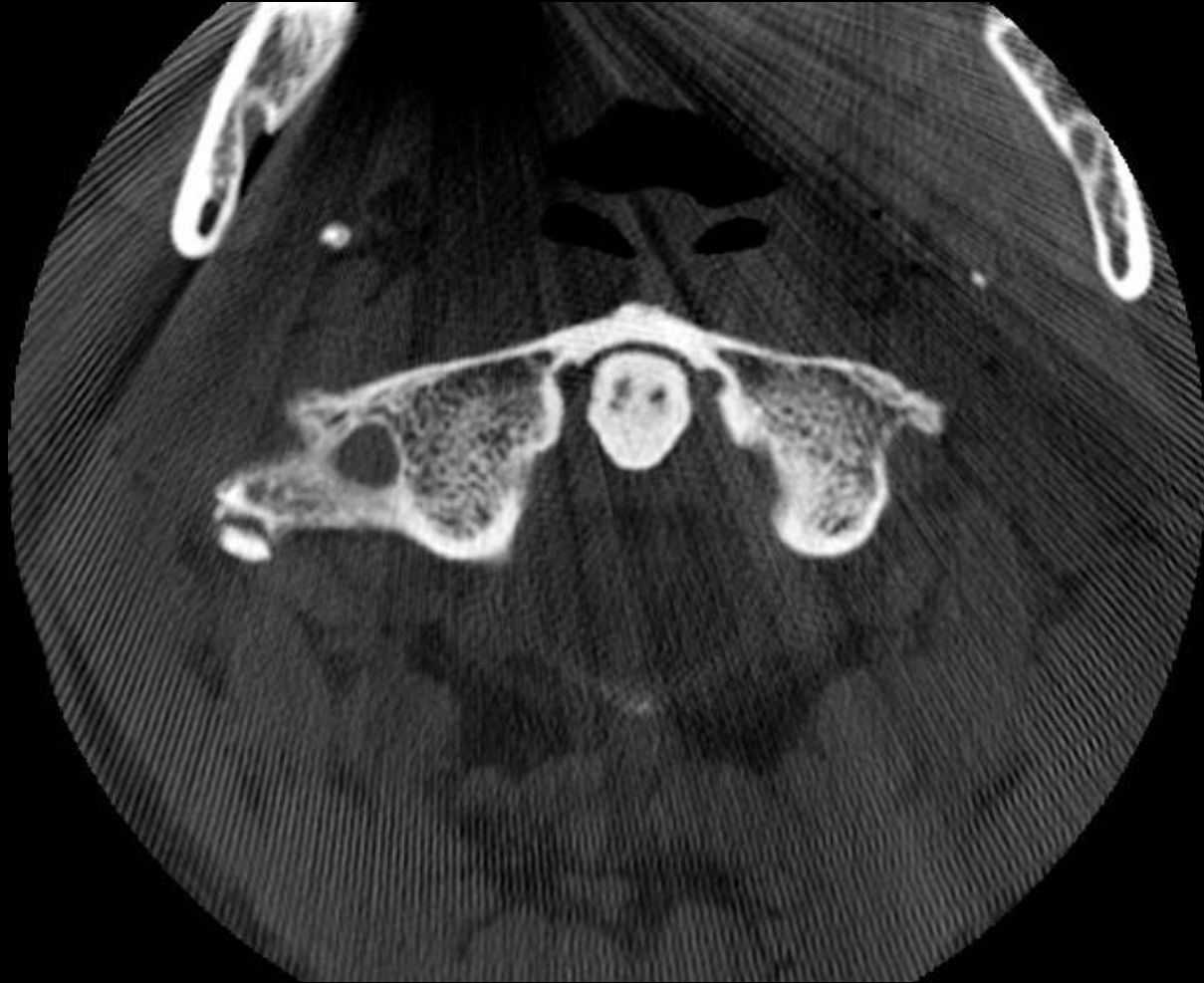Occipital Vertebrae



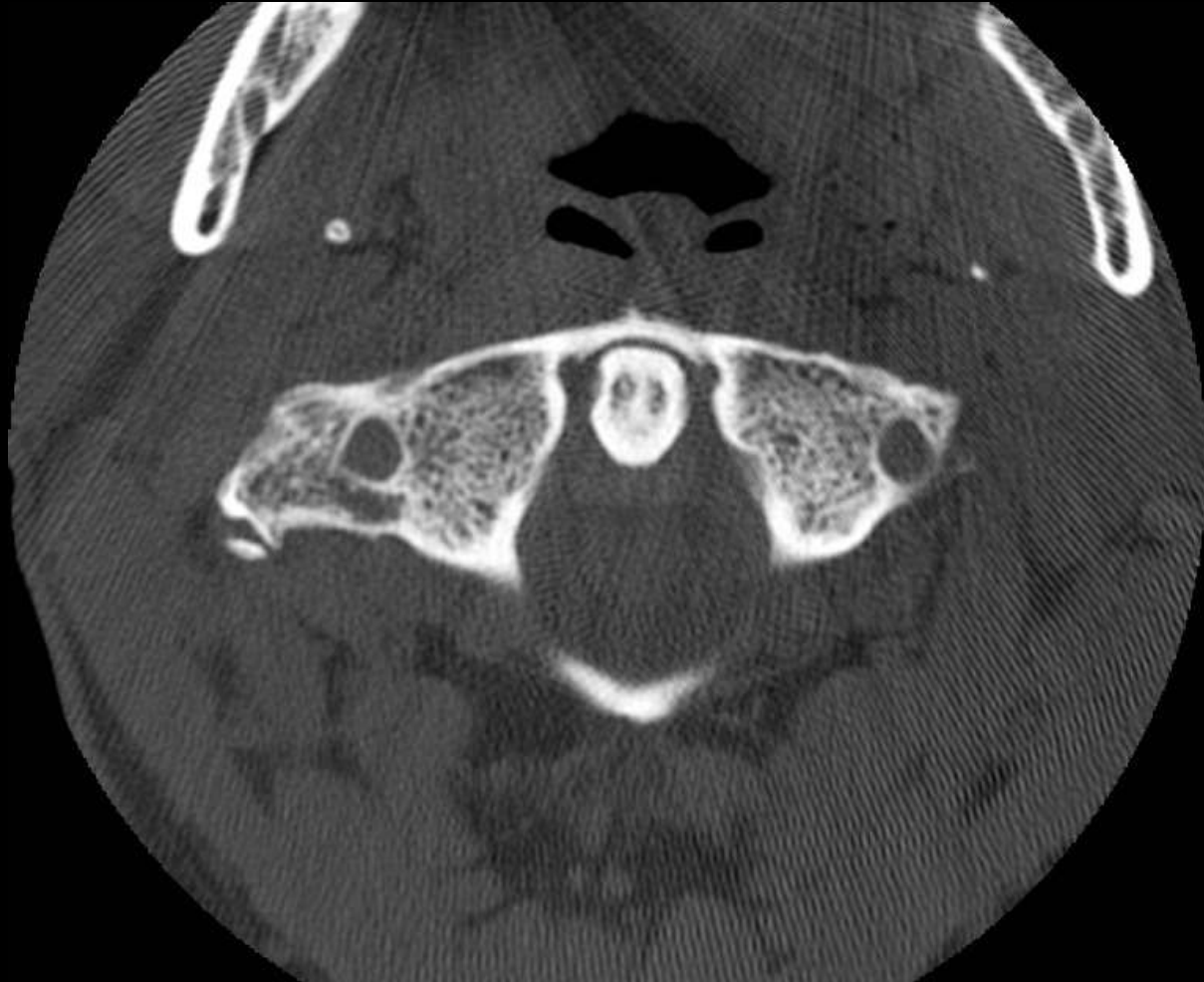Occipital Vertebrae



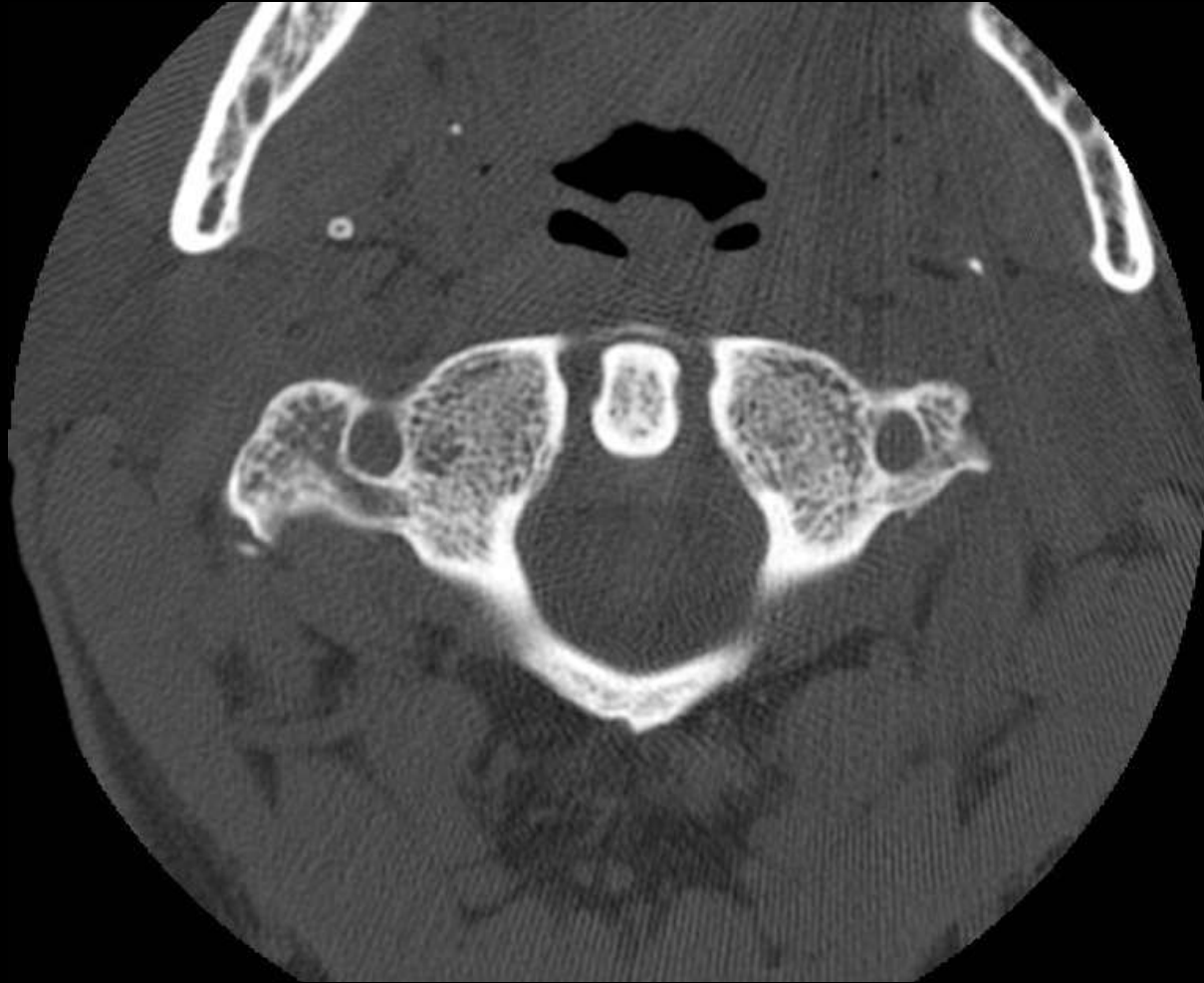Occipital Vertebrae



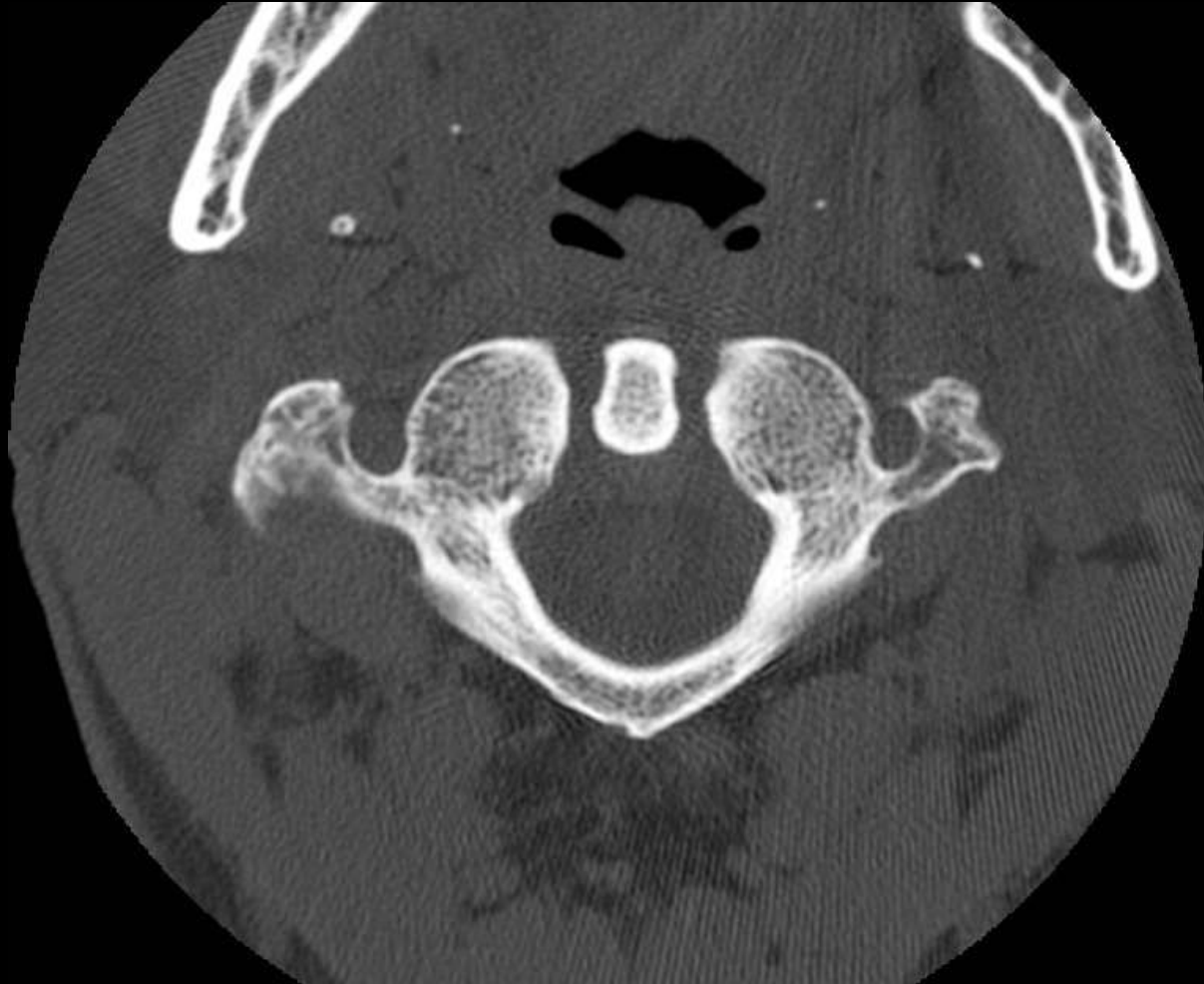Occipital Vertebrae



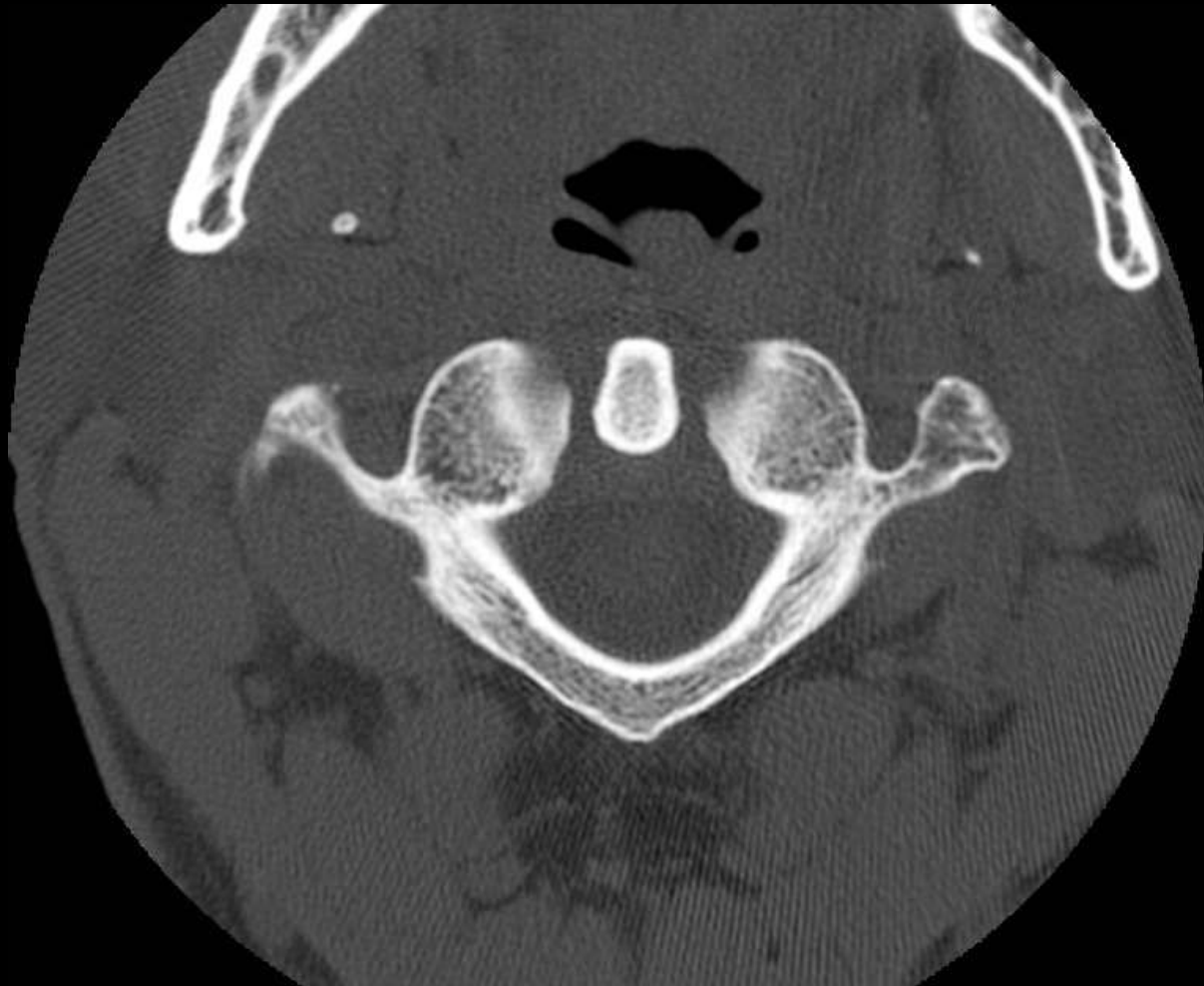
Occipital Vertebrae



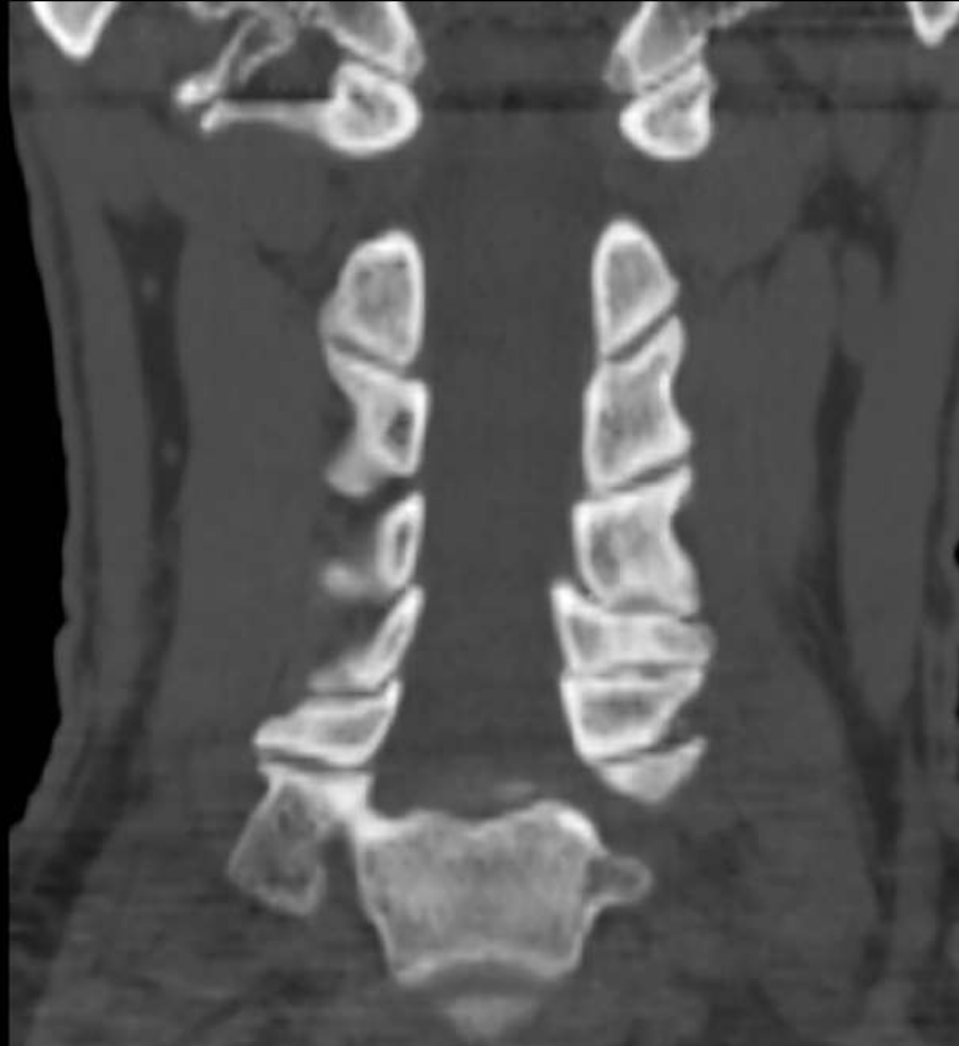Occipital Vertebrae



Occipital Vertebrae

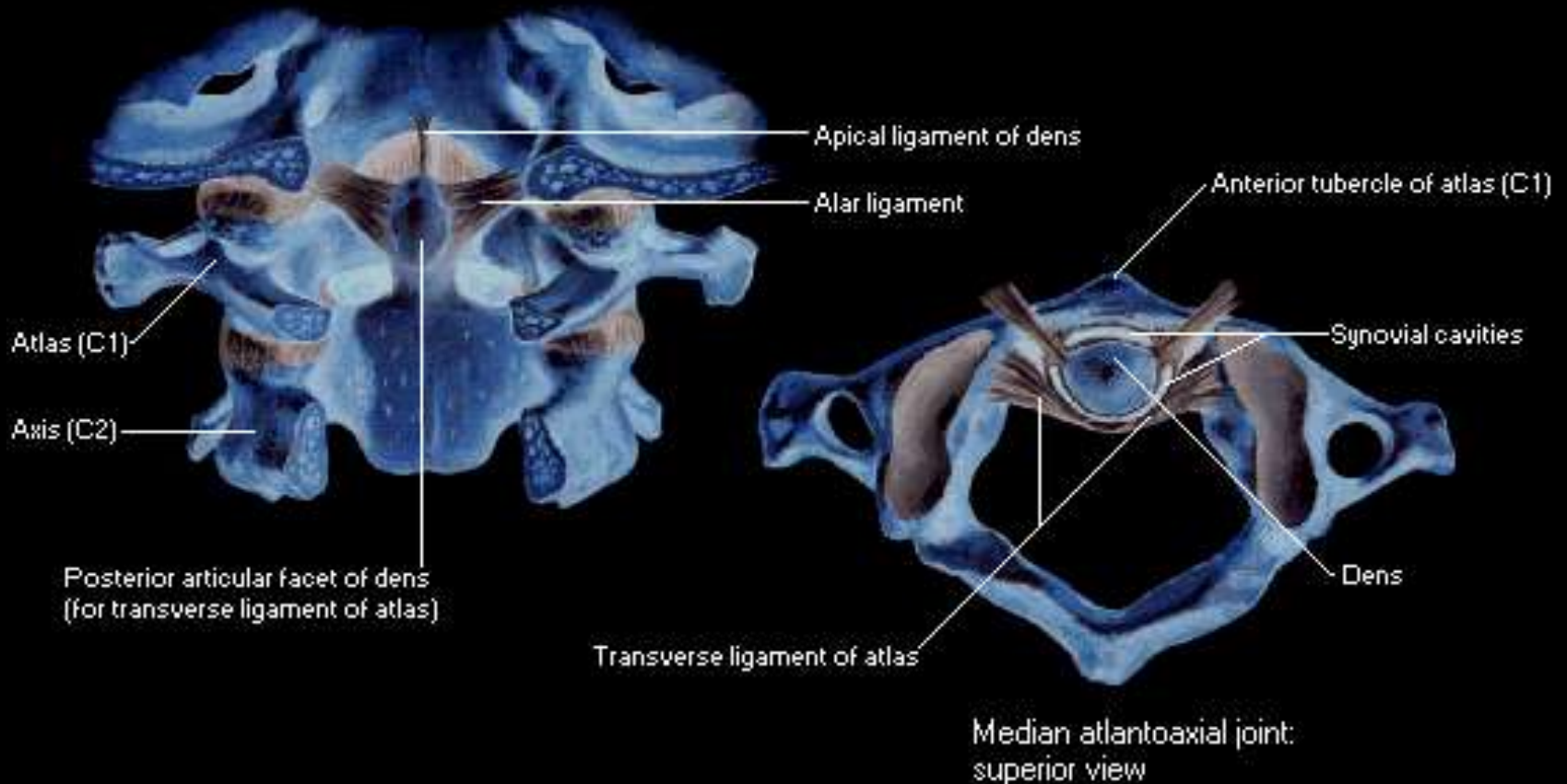


Occipital Vertebrae

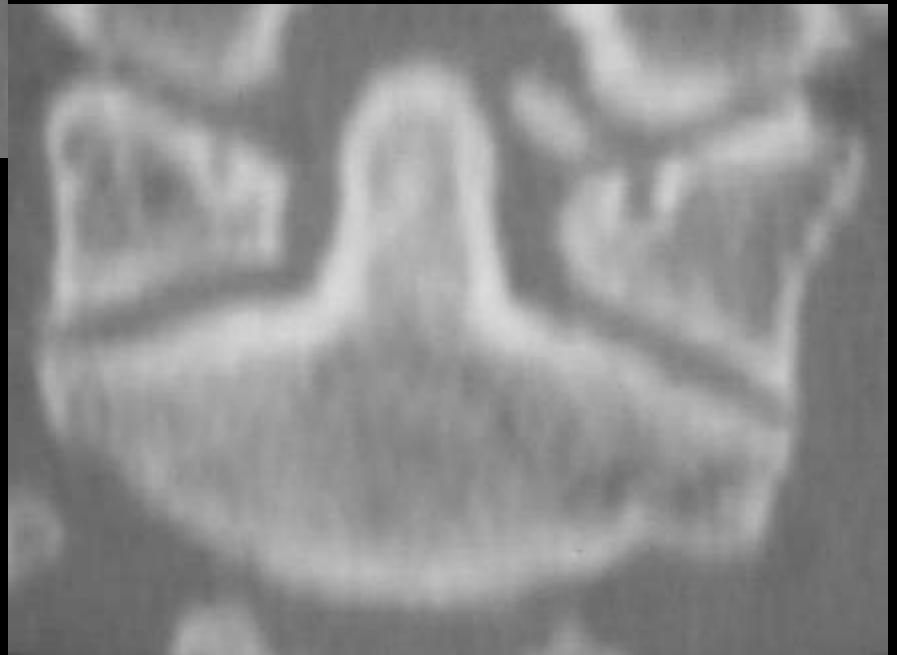
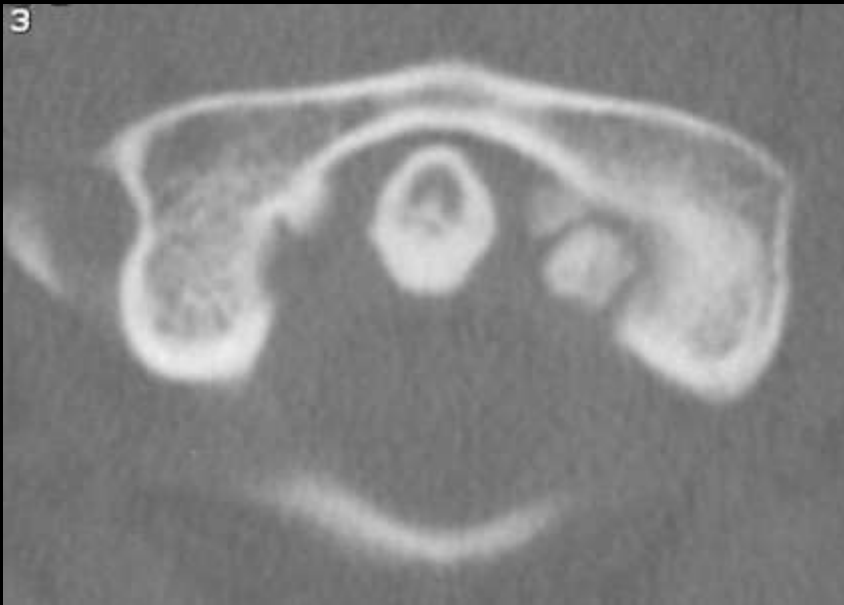

Craniocervical Ligaments

Cruciate ligament removed to show deepest ligaments: posterior view

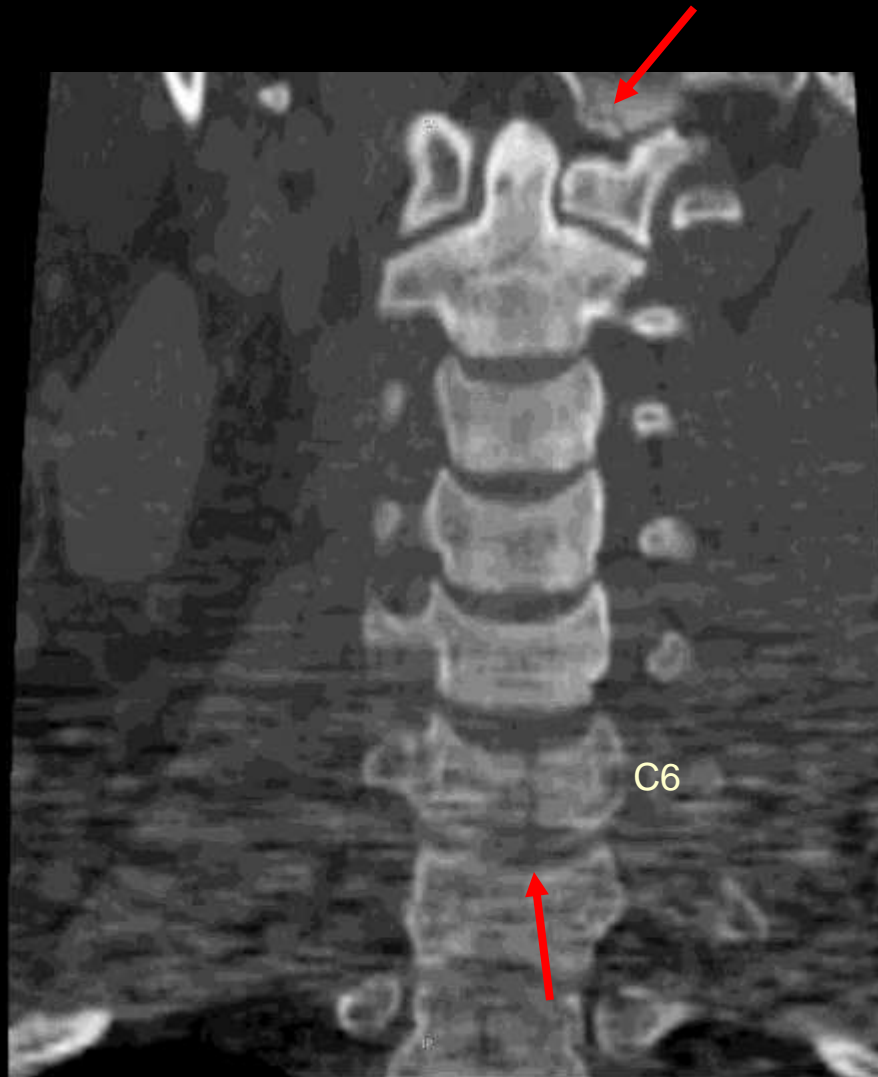


Alar avulsion occipital condyle



Forced lateral flexion
Hematoma
Look for second fracture

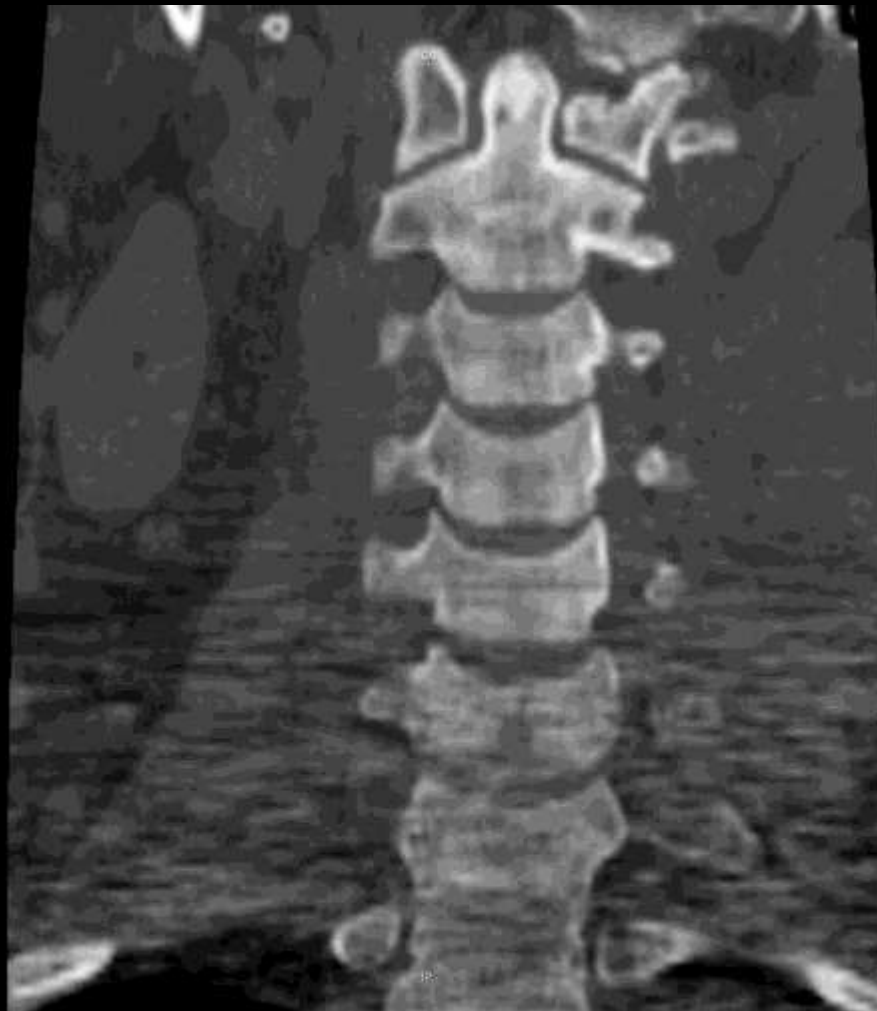Occipital and C6 Fxs



KV:128
mA:200
1782mmsec
D:370mm
T:41.0
DFOV:161.2
ALUS-STANDARD
Ver 2000 1 500

down

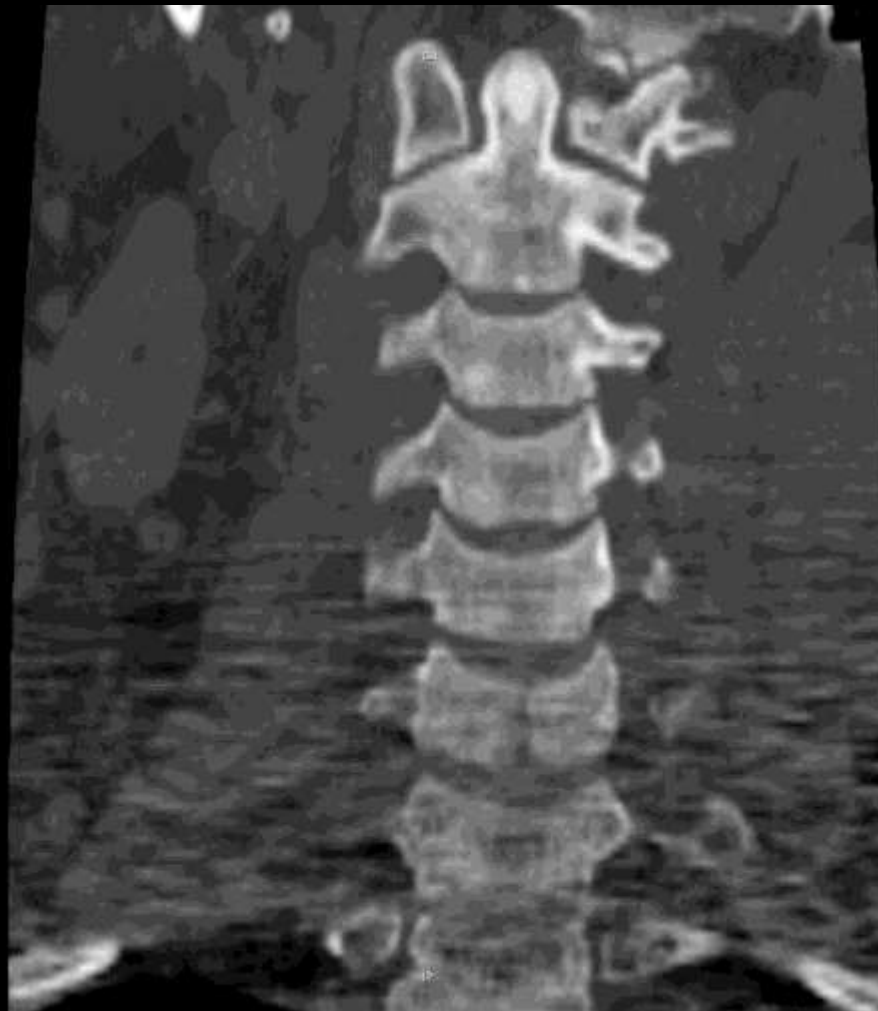Occipital and C6 Fxs



KV 128
HA200
1782mm
0.270mm
141.6
DFOV161.2
ALU-STANDARD
Nr 2000 1:500

CONT

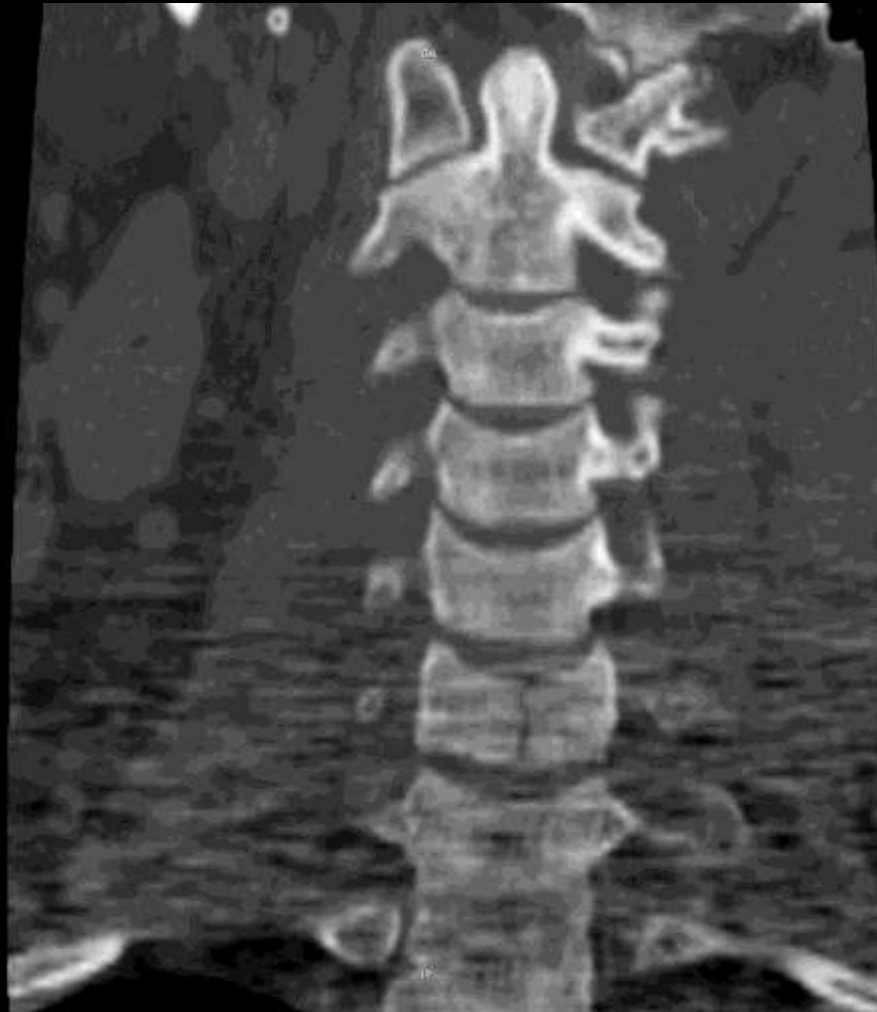Occipital and C6 Fxs



KV:128
mA:200
1782mmsec
0.270mm
14.1.0
EPOV101.2
ALU-STANDARD
Ver 2000 1.500

CONT

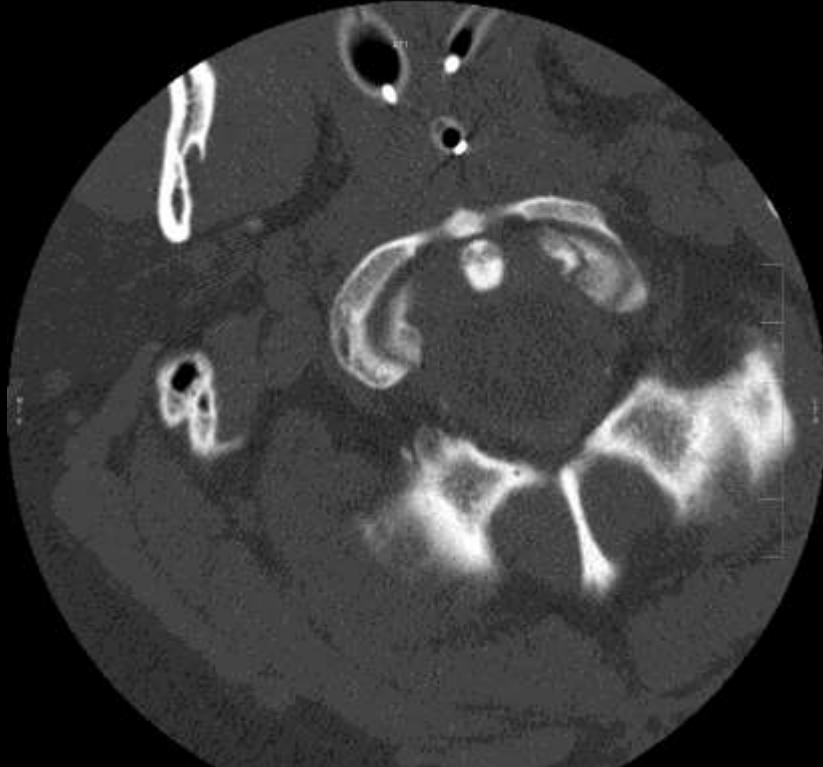
Occipital and C6 Fxs



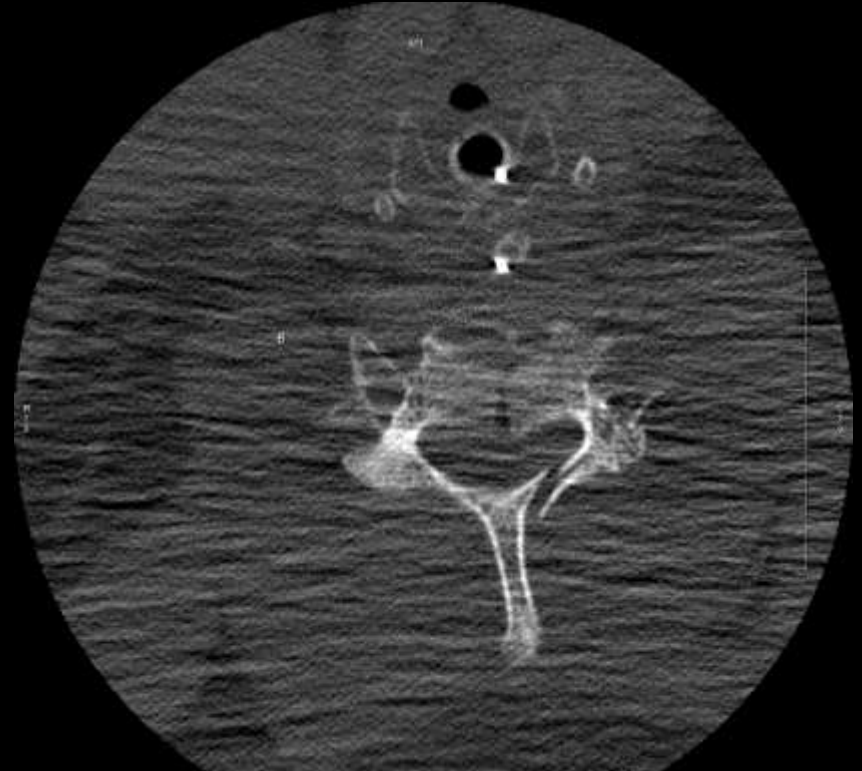KV:128
HA200
1782mm
0.270mm
141.0
EFOV161.2
ALU-STANDARD
Vr 2000 1 500

CONT

Occipital and C6 Fxs



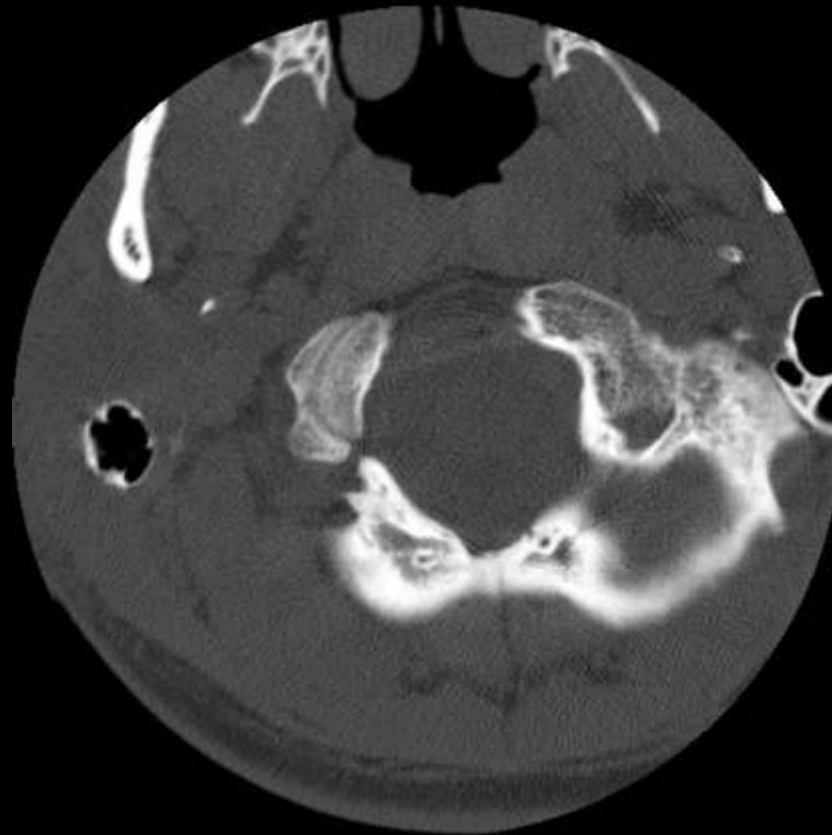
Left Occipital condyle Fx



C6 burst Fx

Chronic alar lig avulsion

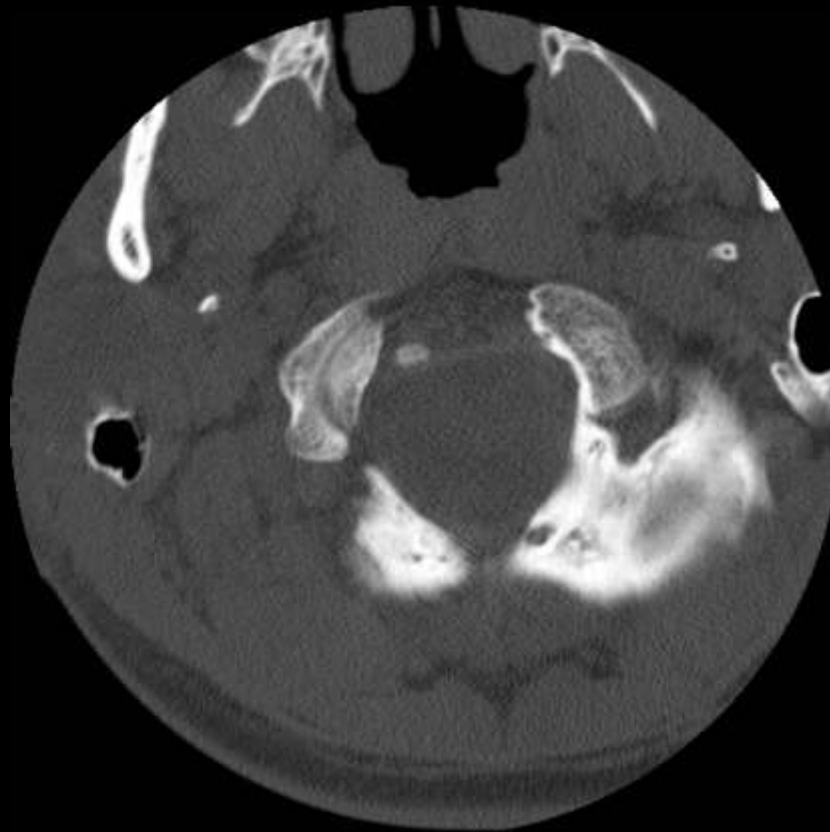
14



W 2000 : L 500

Chronic alar lig avulsion

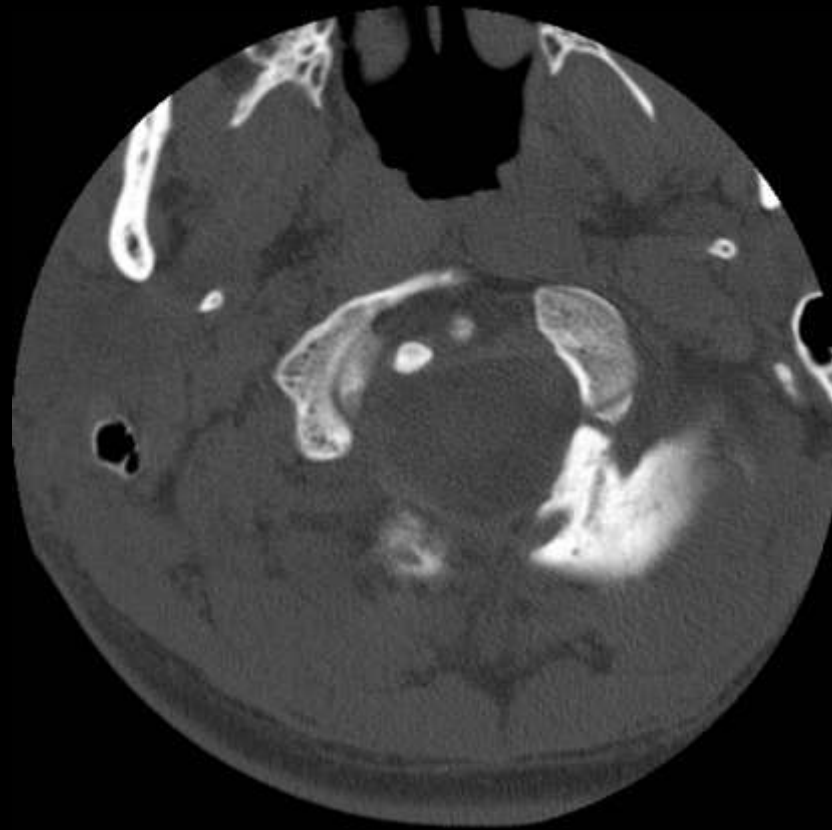
15



W 2000 : L 500

Chronic alar lig avulsion

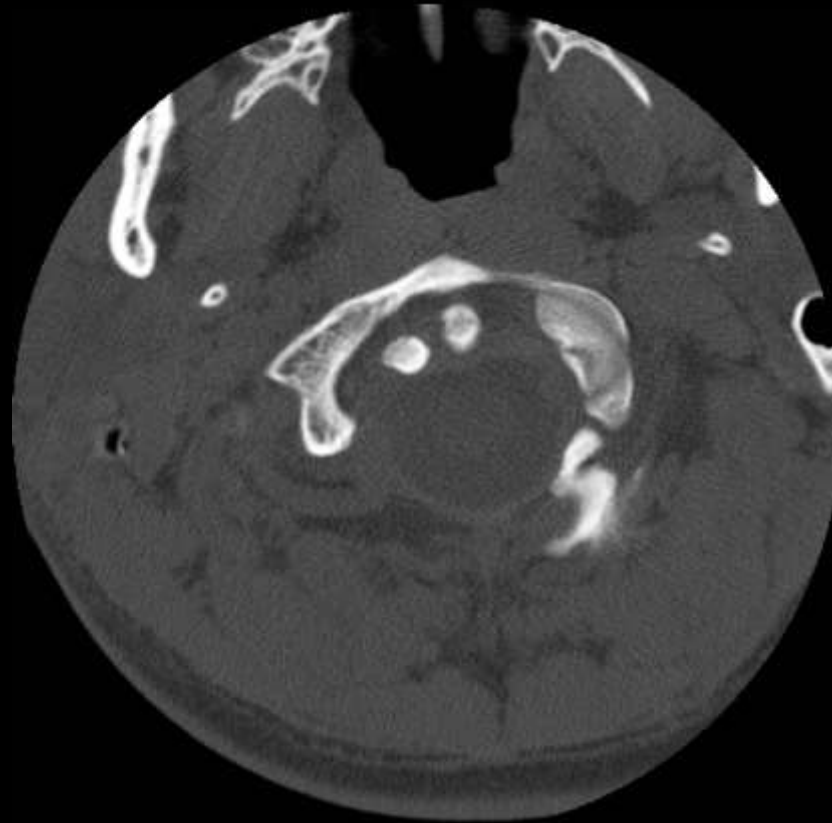
16



W 2000 : L 500

Chronic alar lig avulsion

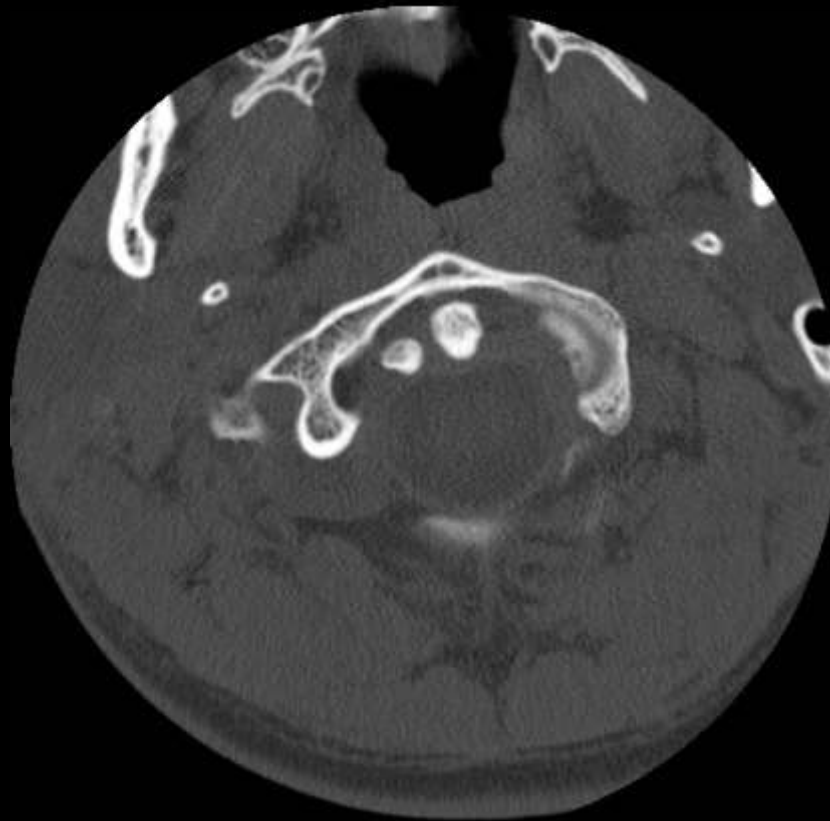
17



W 2000 : L 500

Chronic alar lig avulsion

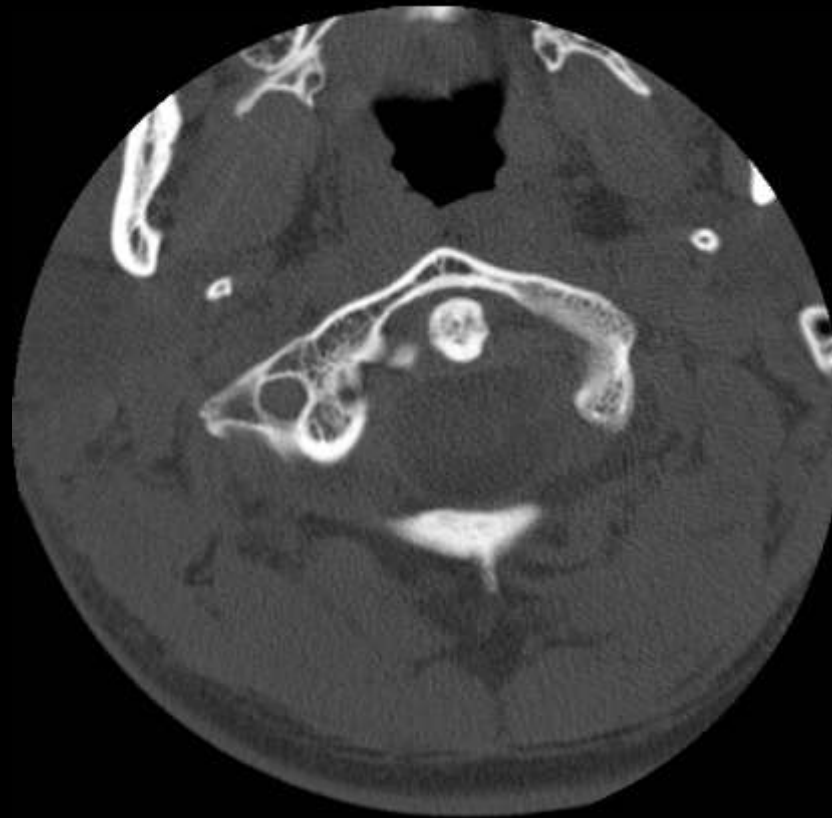18



W 2000 : L 500

Chronic alar lig avulsion

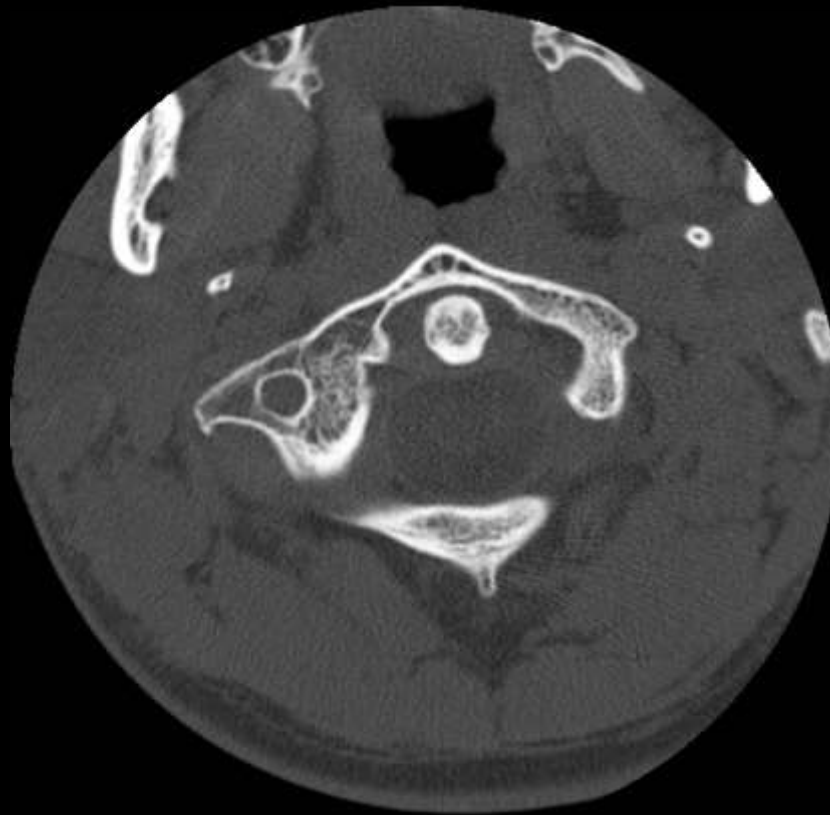19



W 2000 ; L 500

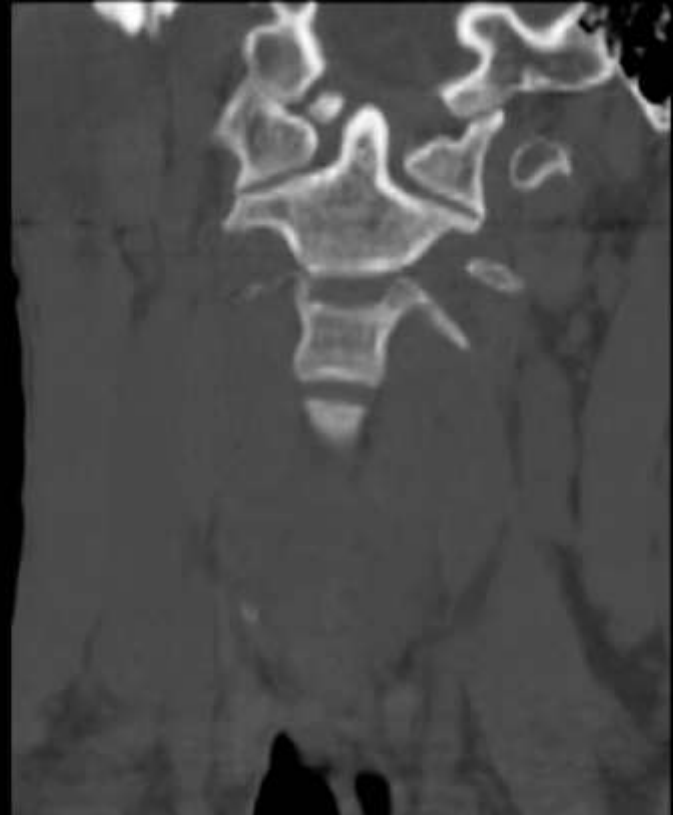
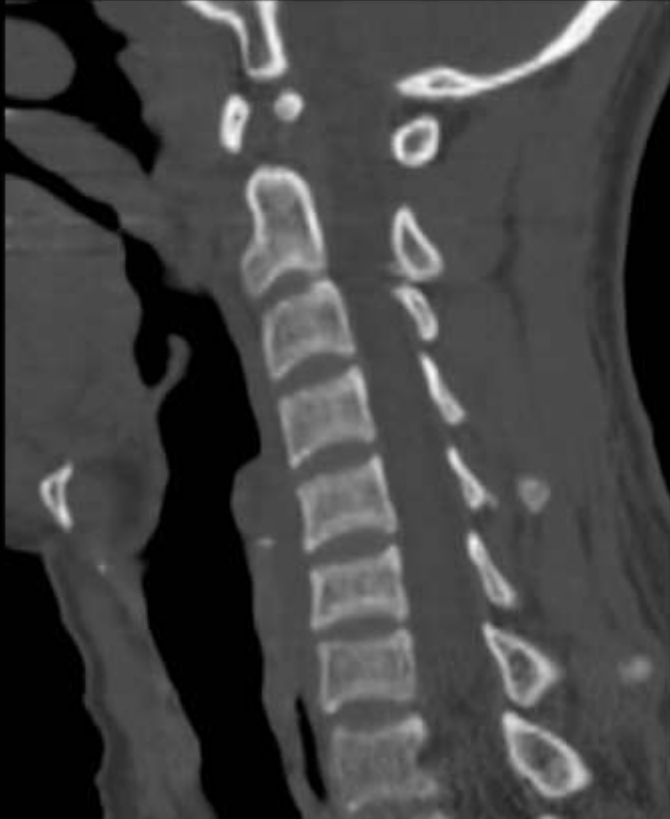Chronic alar lig avulsion

20

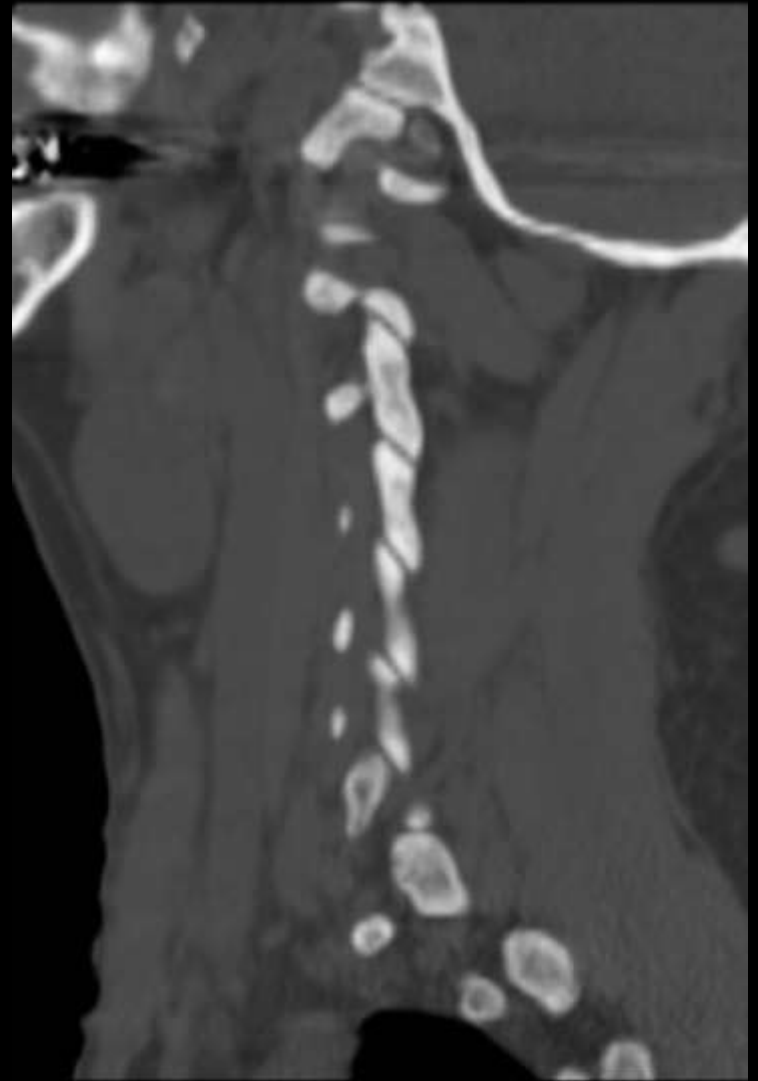
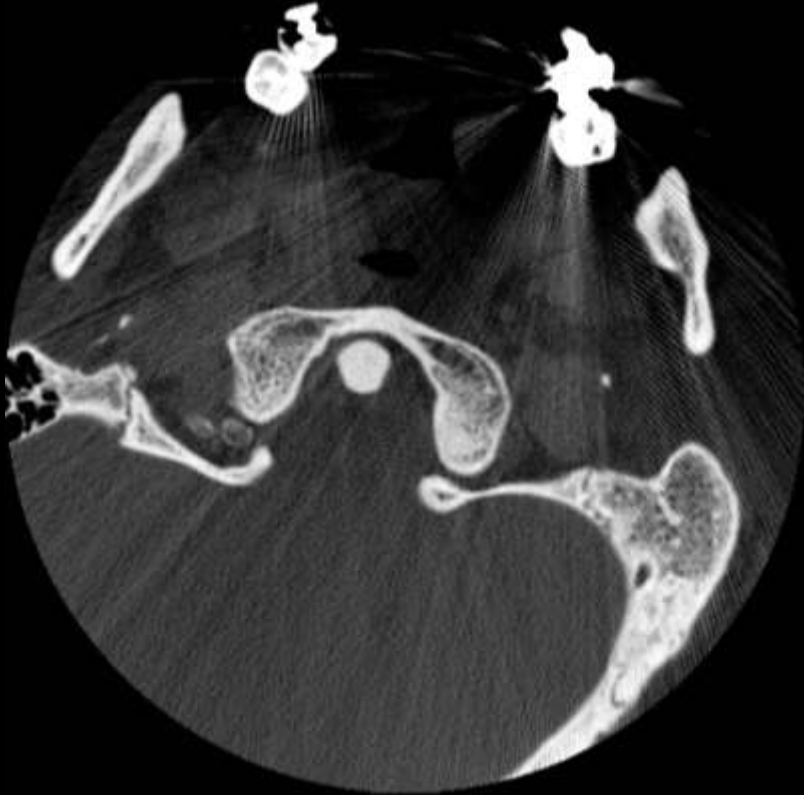
W 2000 ; L 500

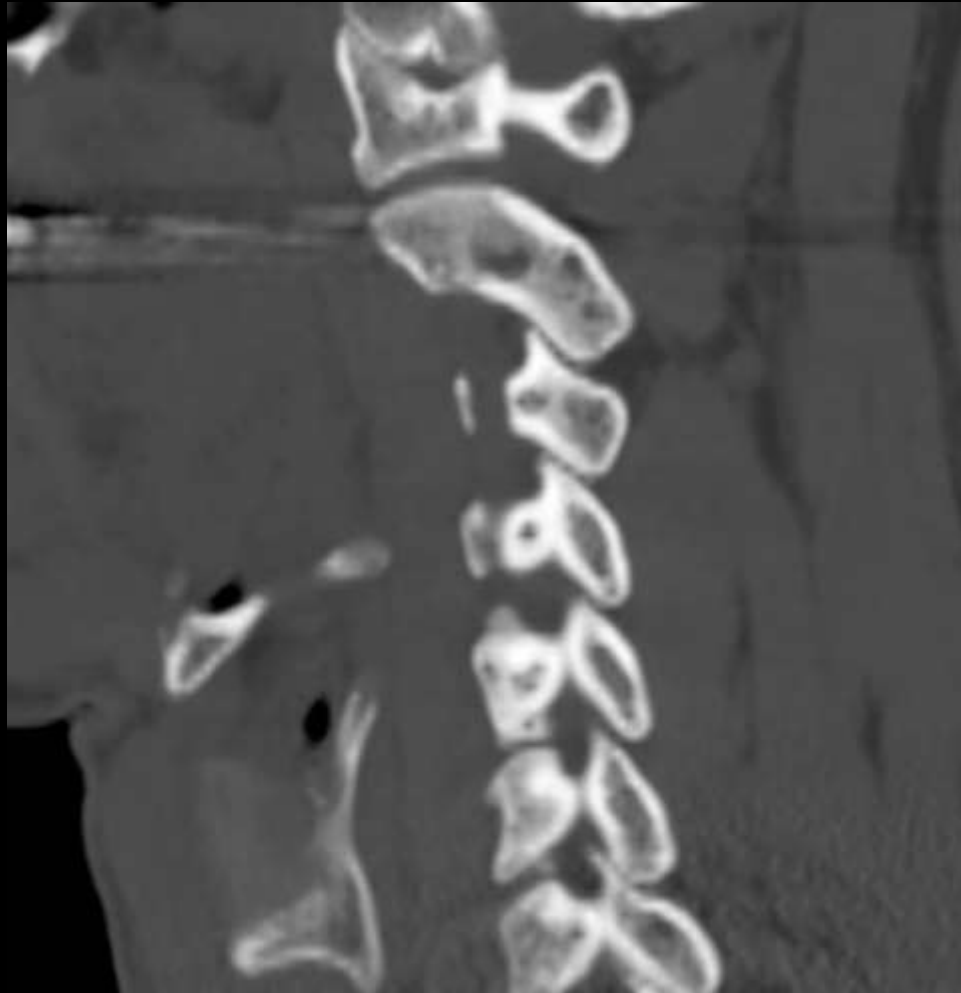Chronic alar lig avulsion



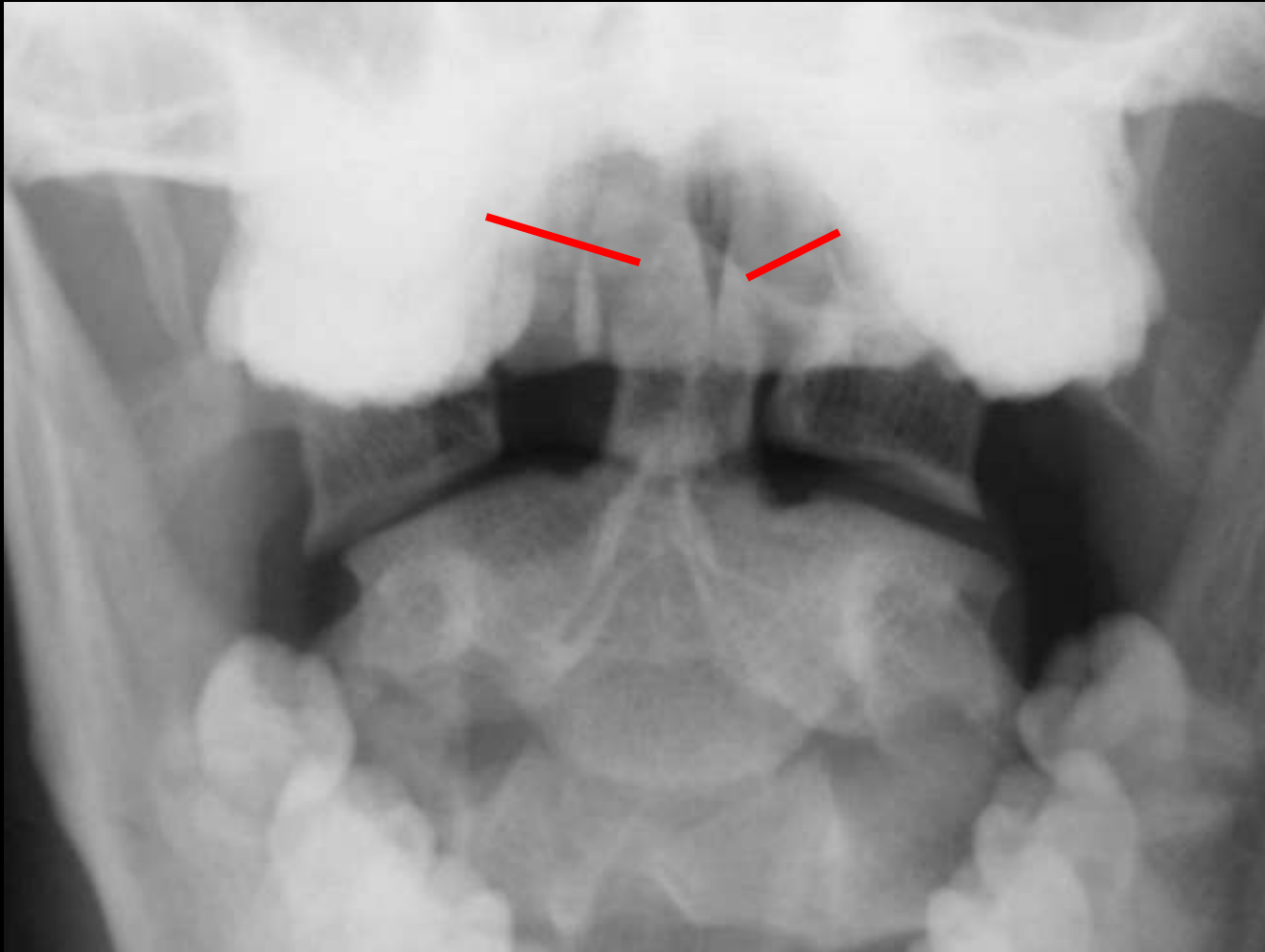
Posticus Ponticus remnants



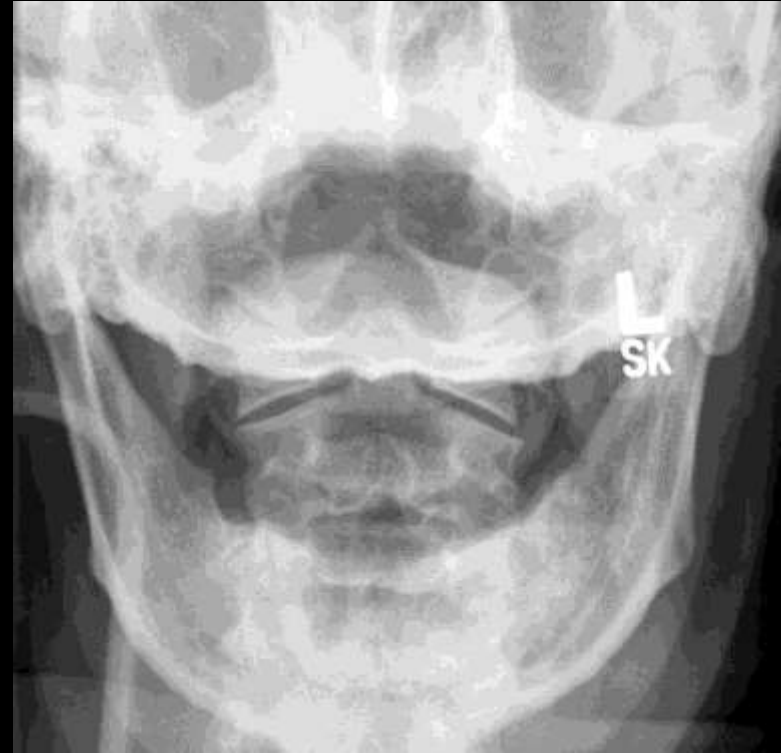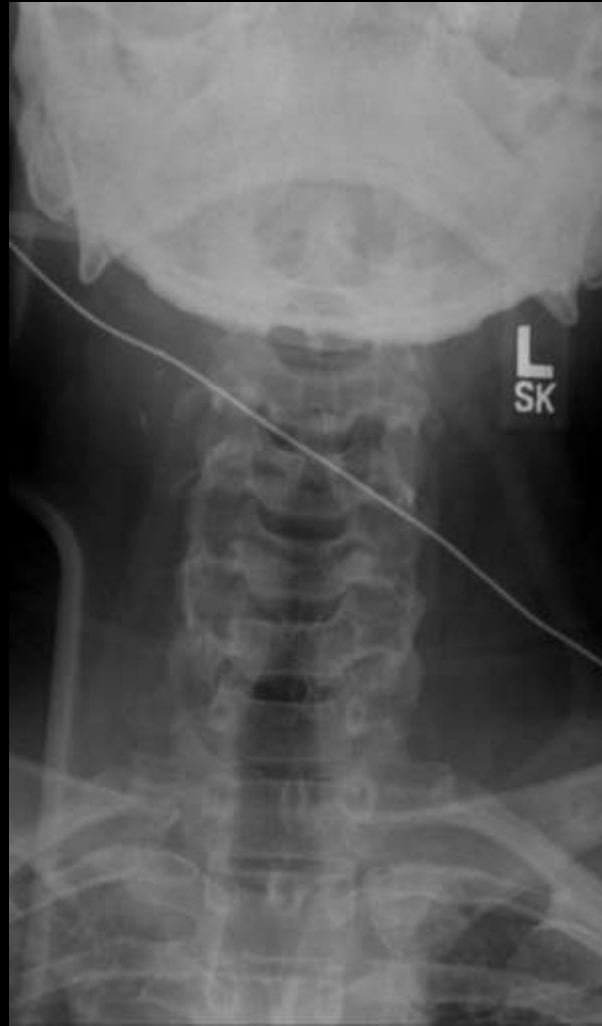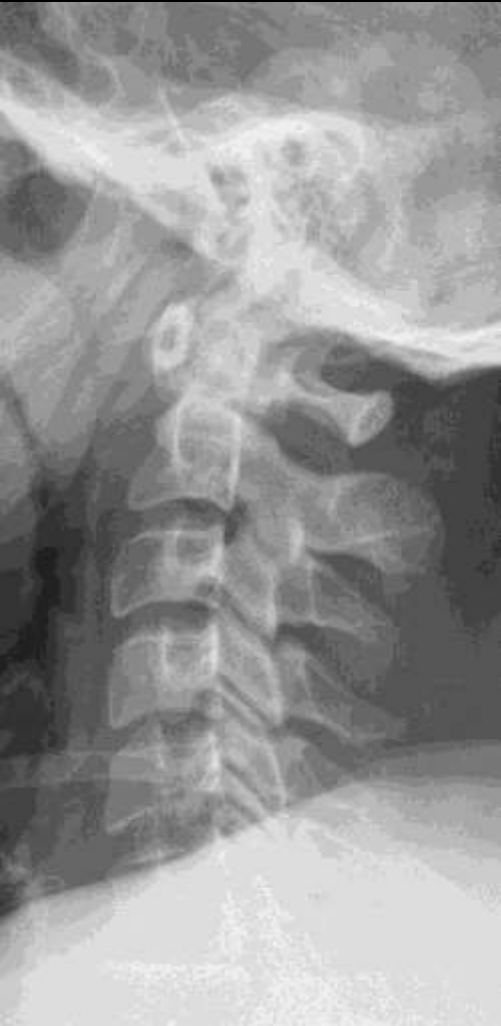Occipital condyle cleft



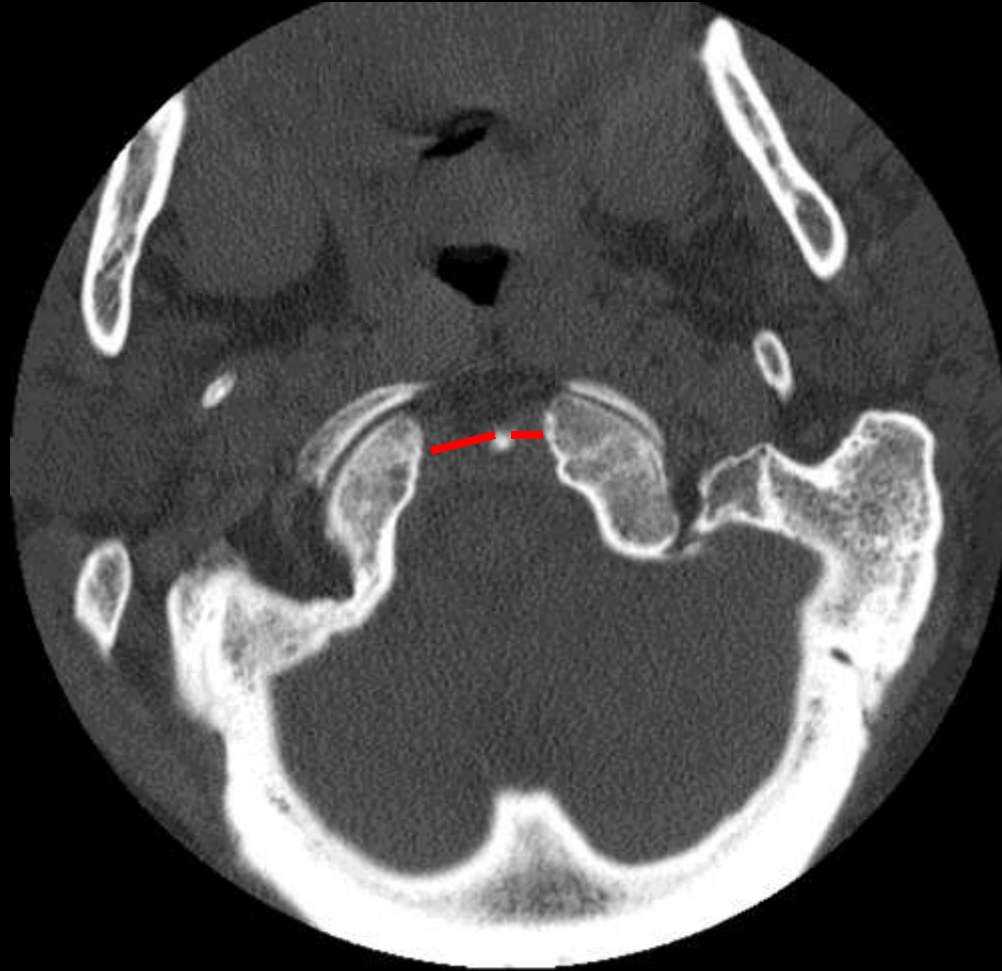
Right Alar ligament rupture



Right Alar ligament tear

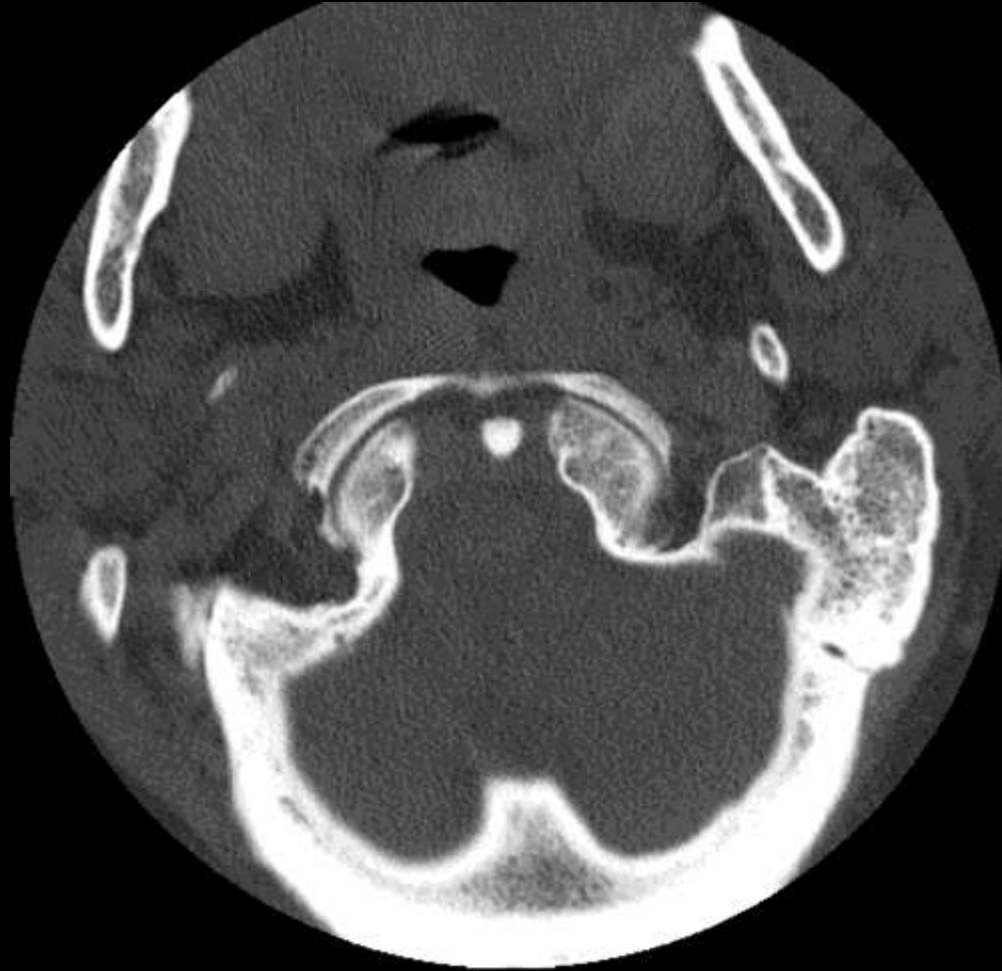


Right Alar ligament tear



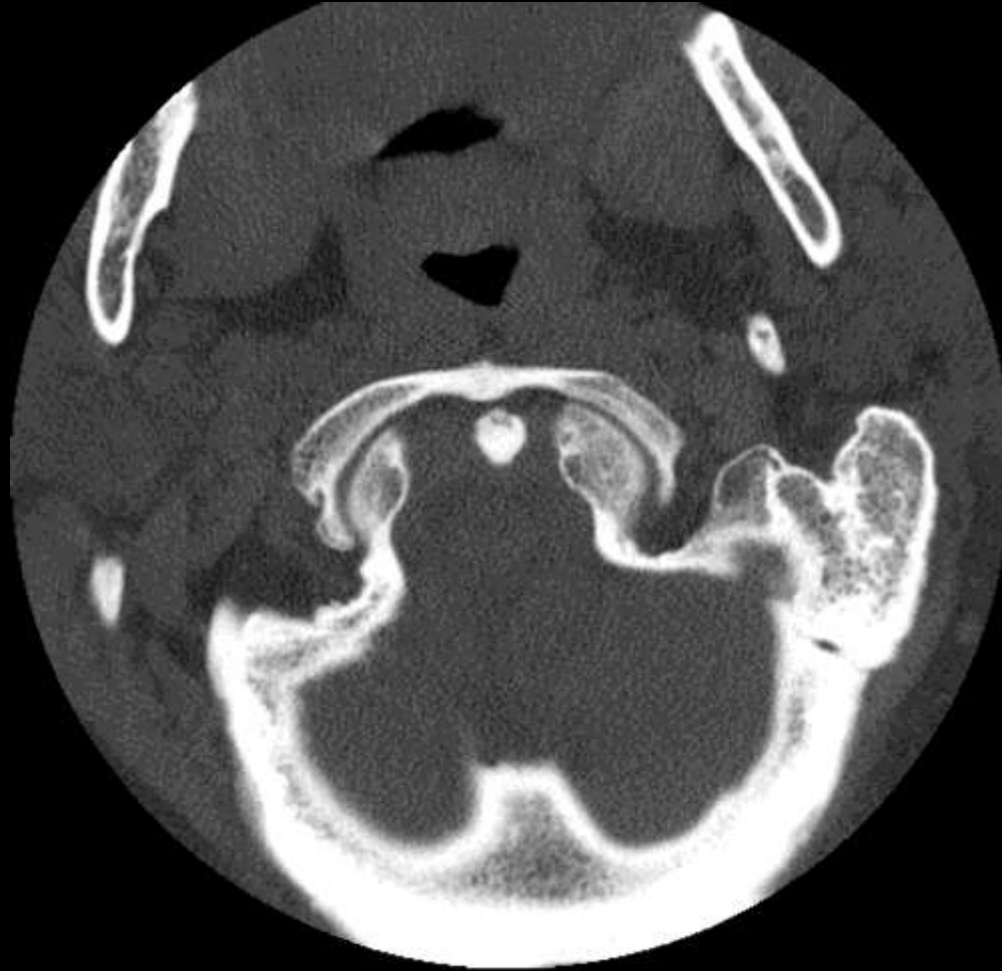W 2000 : L 500

Right Alar ligament tear



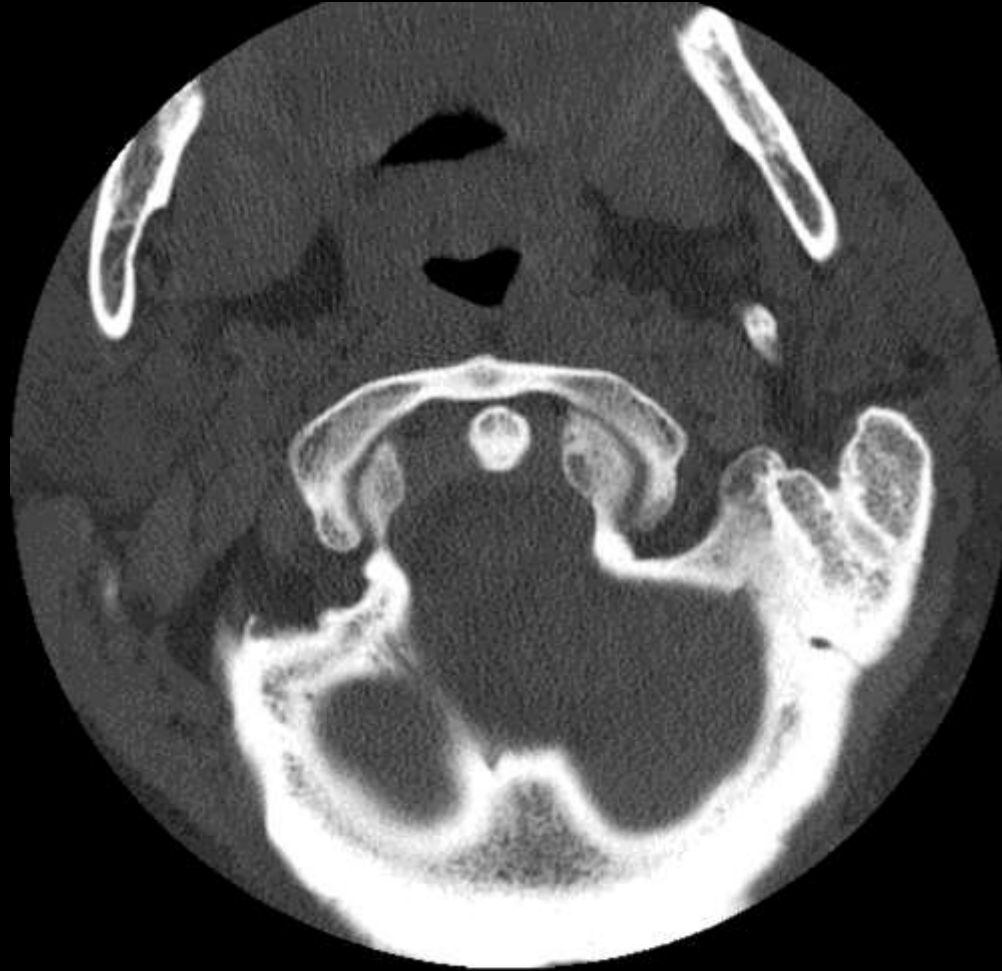
W 2000 : L 500

Right Alar ligament tear



W 2000 : L 500

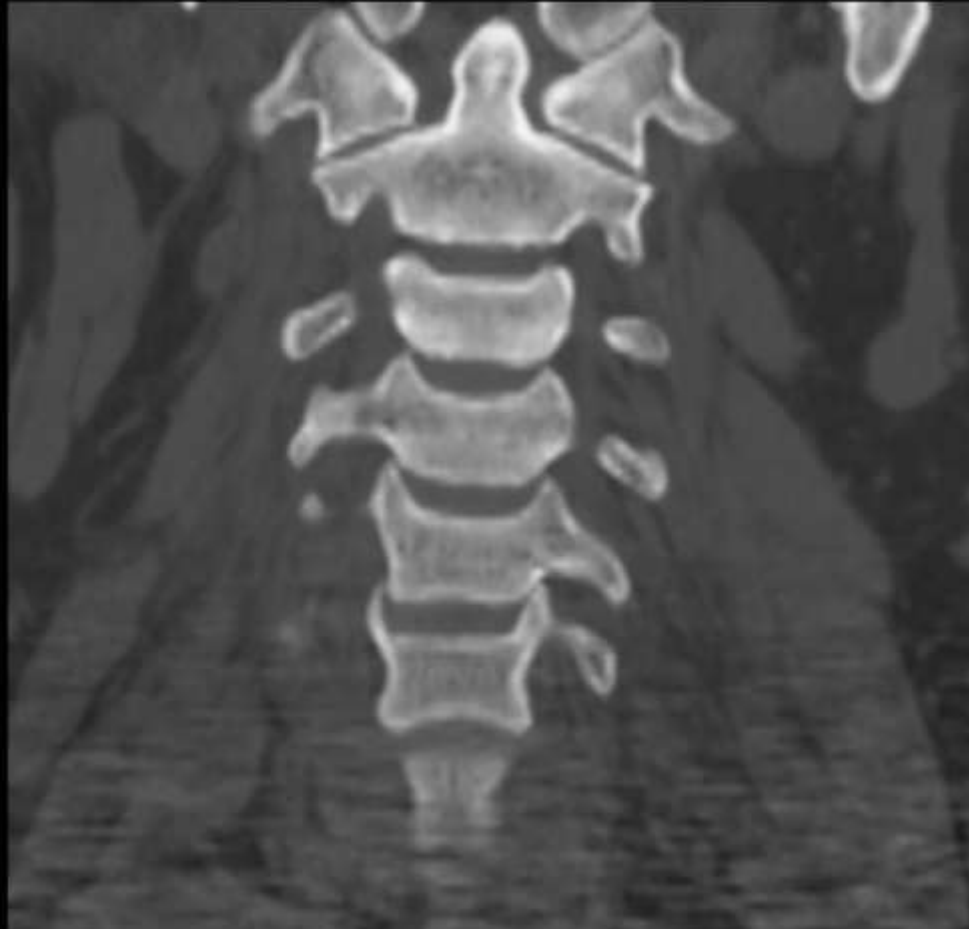Right Alar ligament tear



W 2000 : L 500

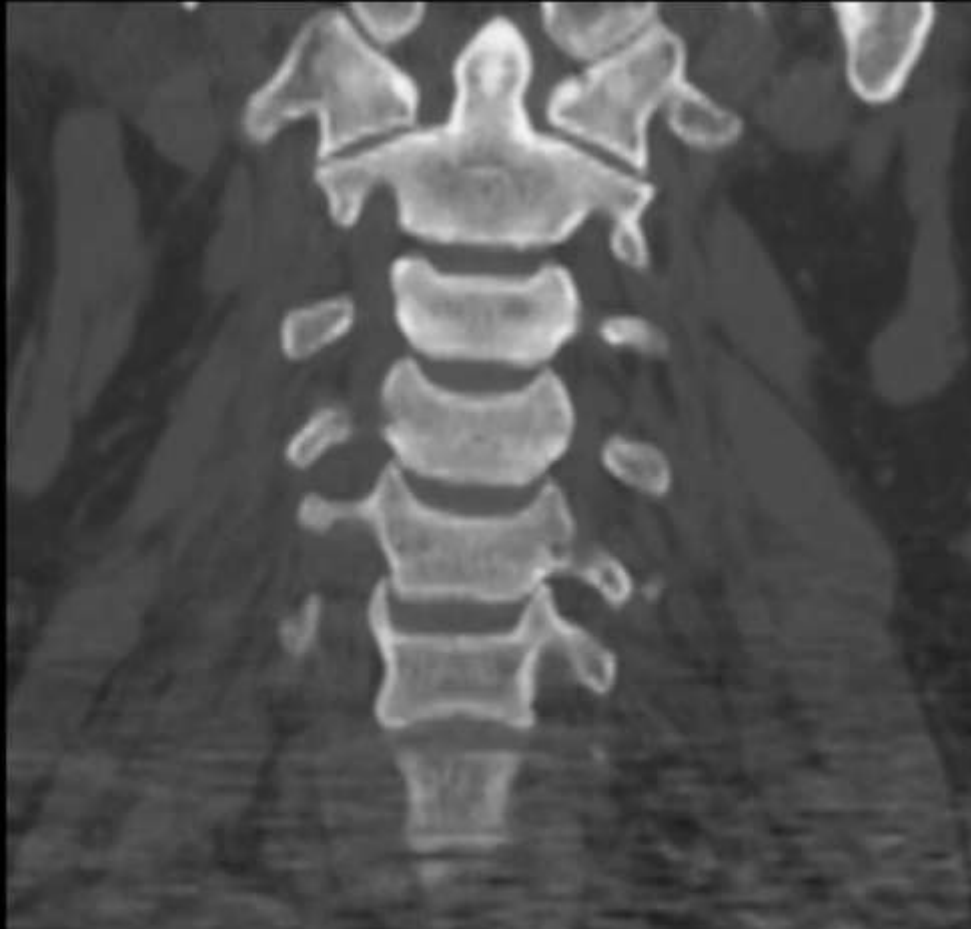
Right Alar ligament tear

19



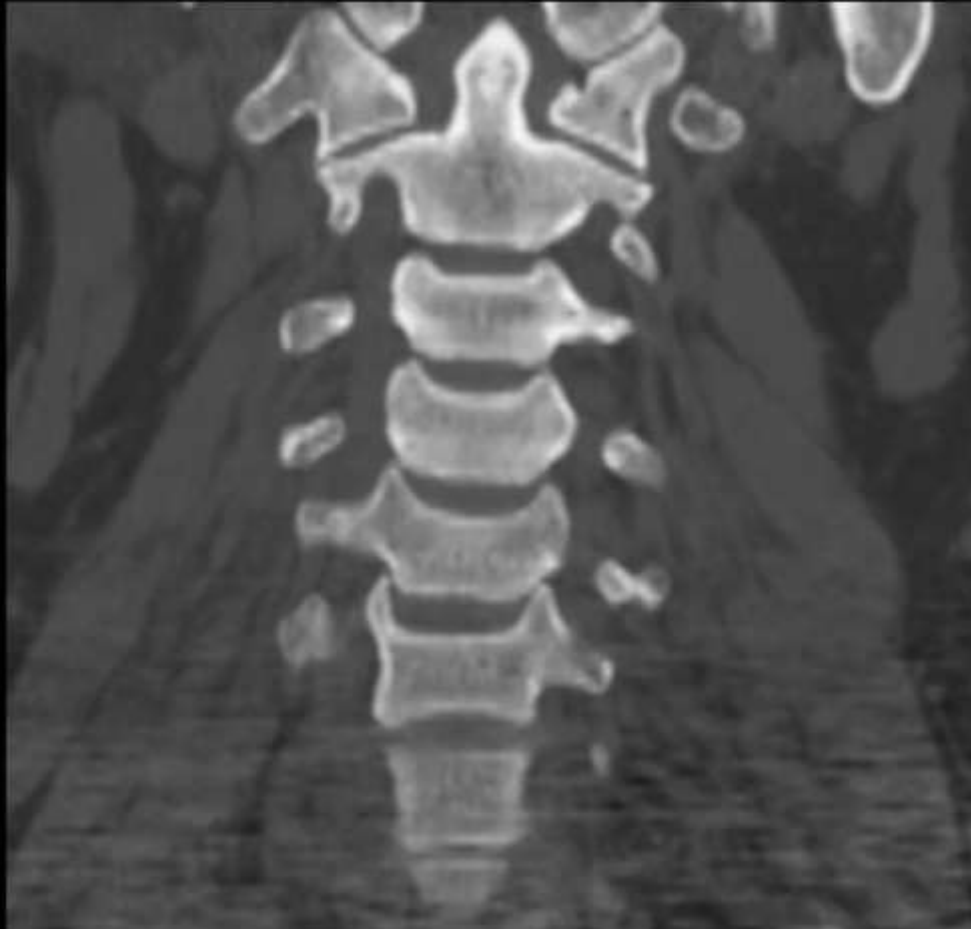
Right Alar ligament tear

20



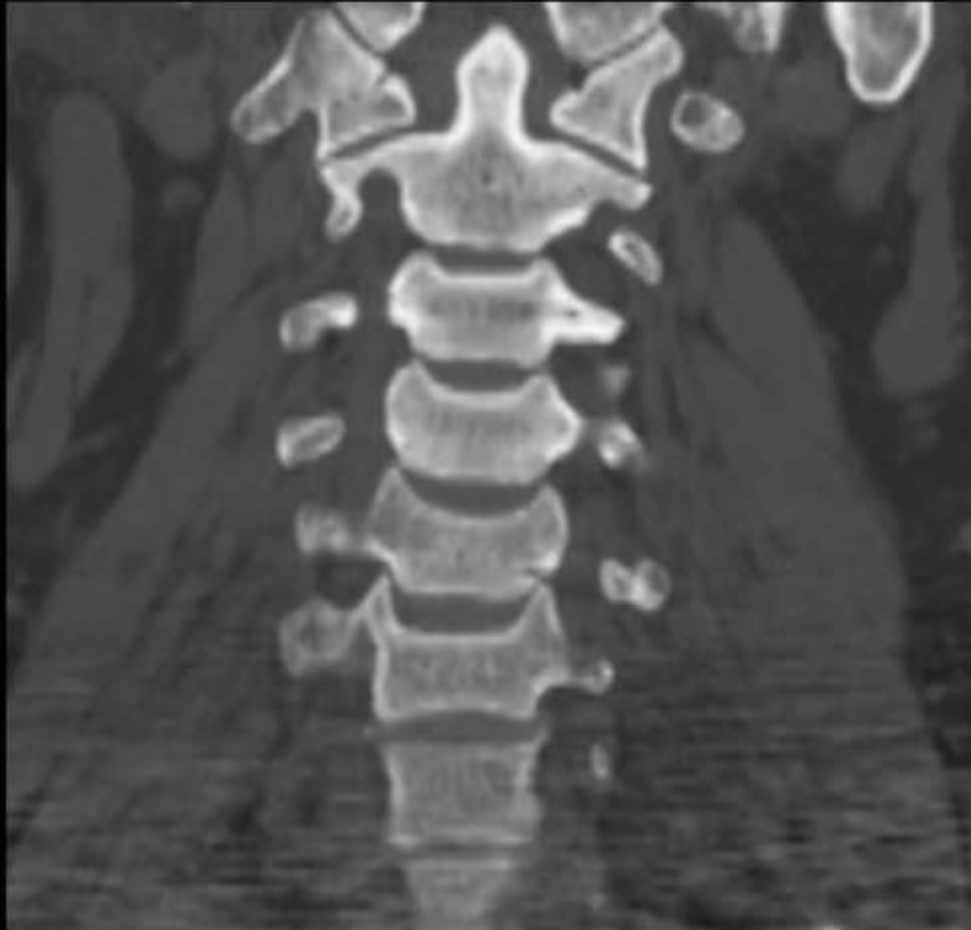Right Alar ligament tear

21



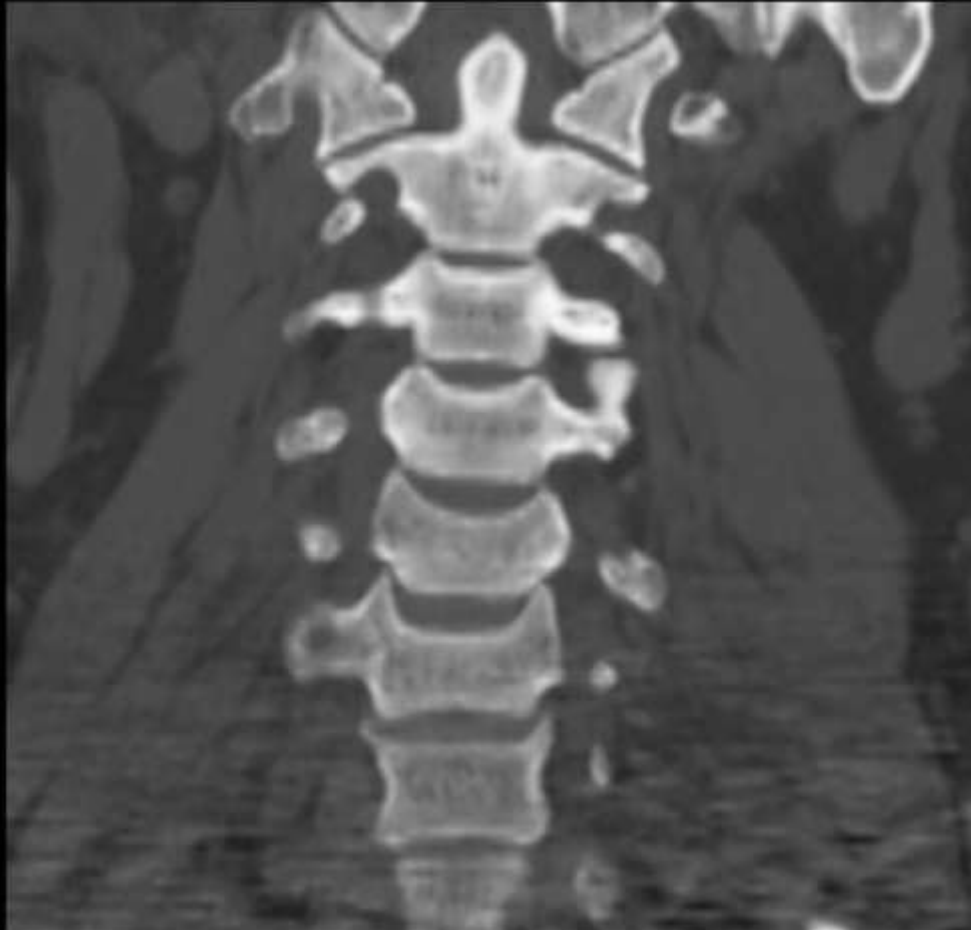Right Alar ligament tear

22



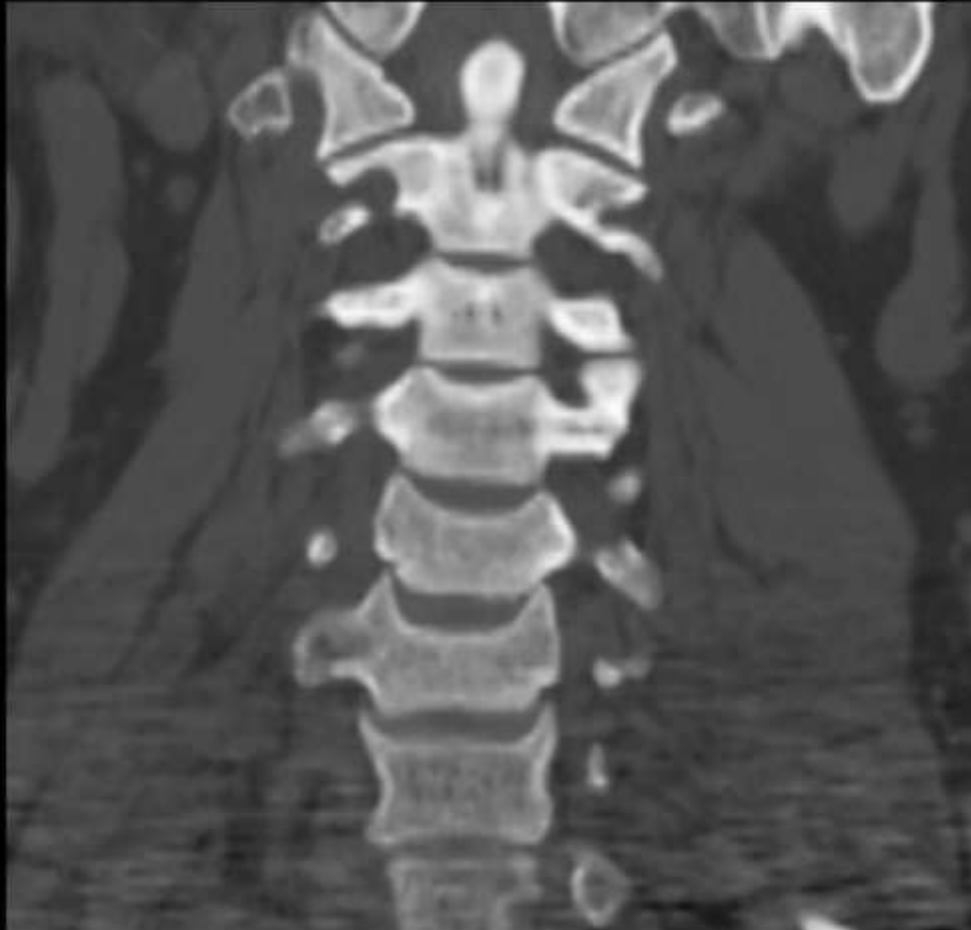Right Alar ligament tear

23

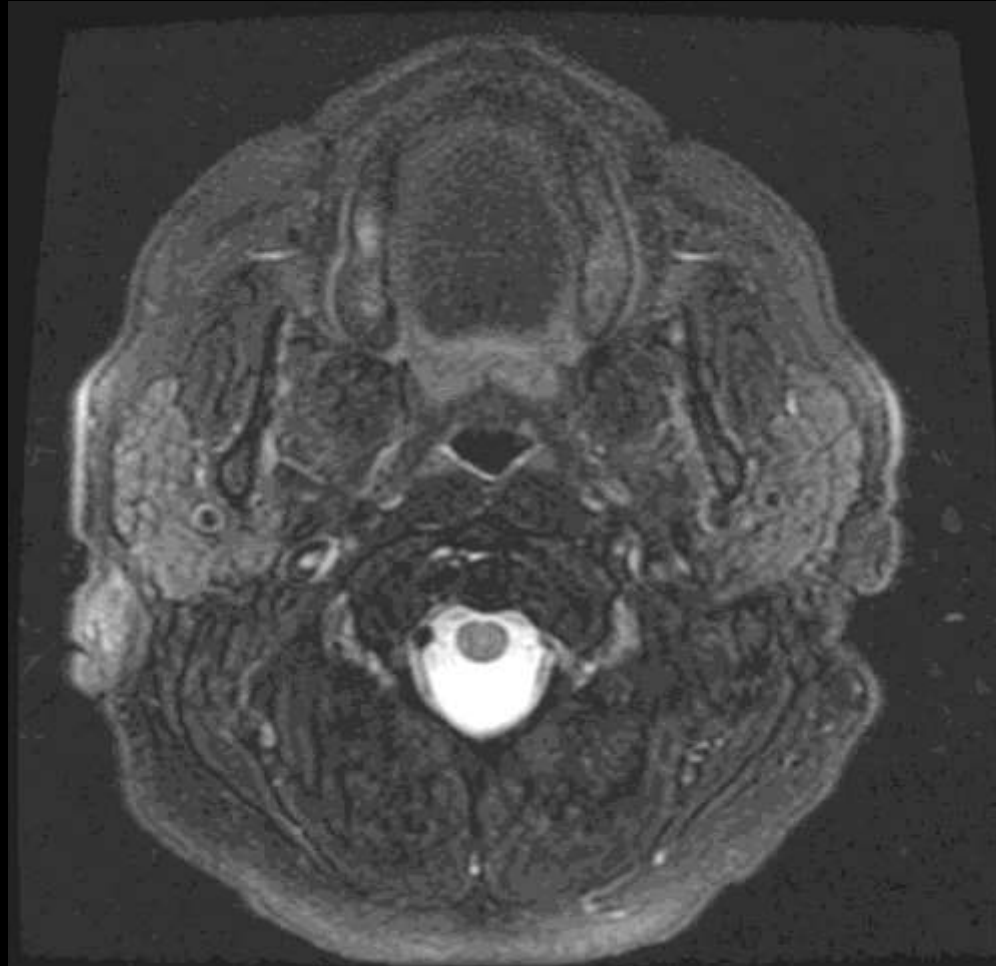


Right Alar ligament tear

24

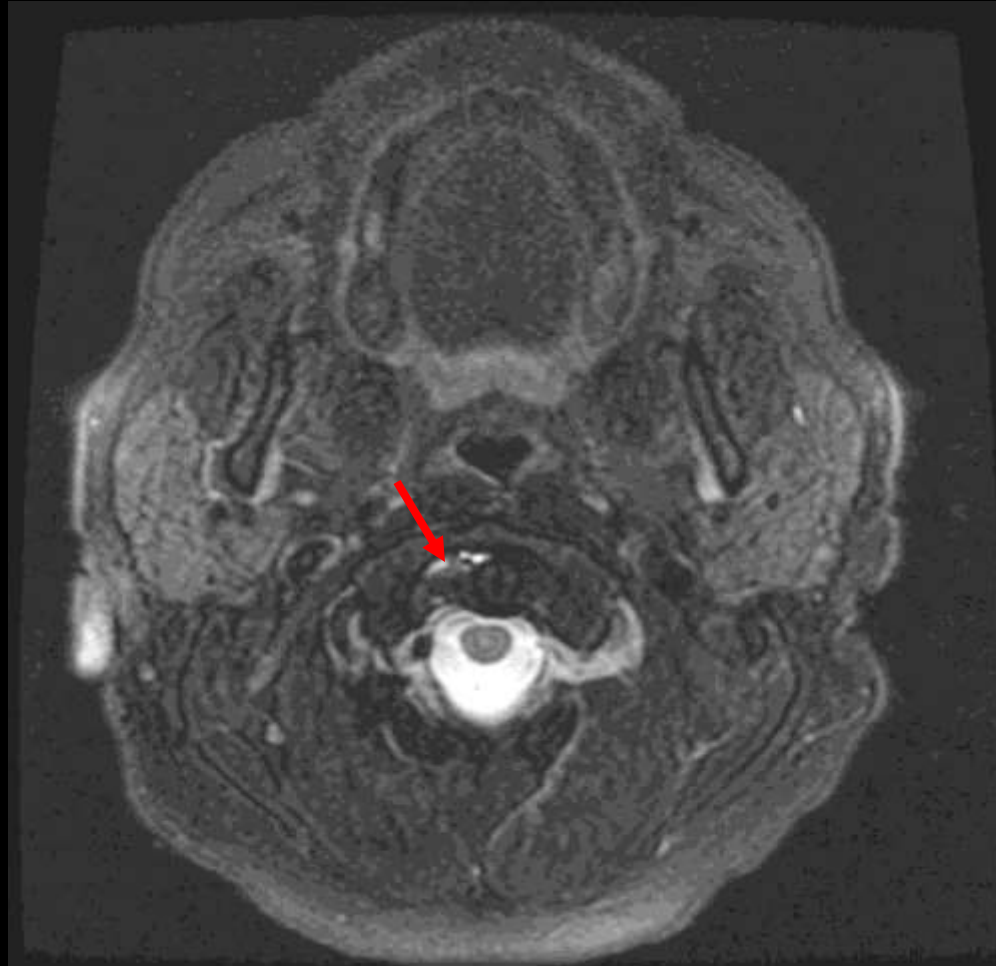


Right Alar ligament tear



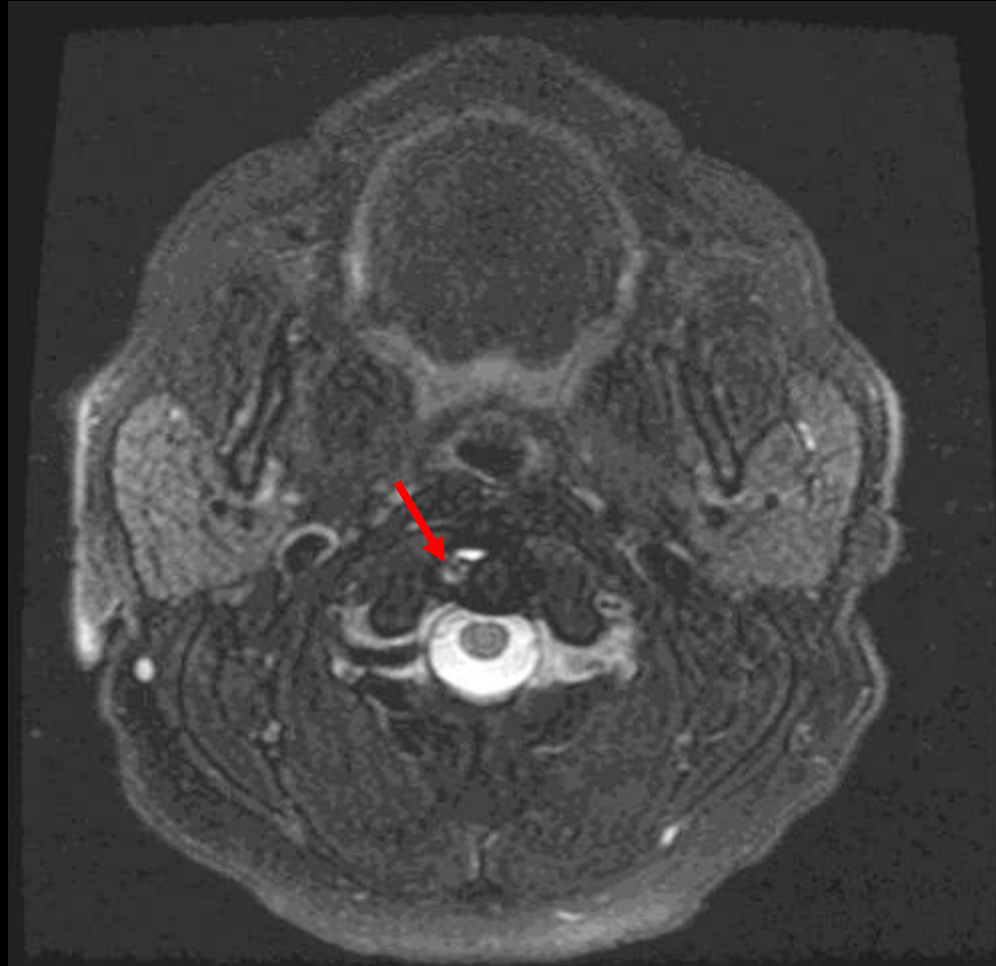
W 654 : L 204

Right Alar ligament tear



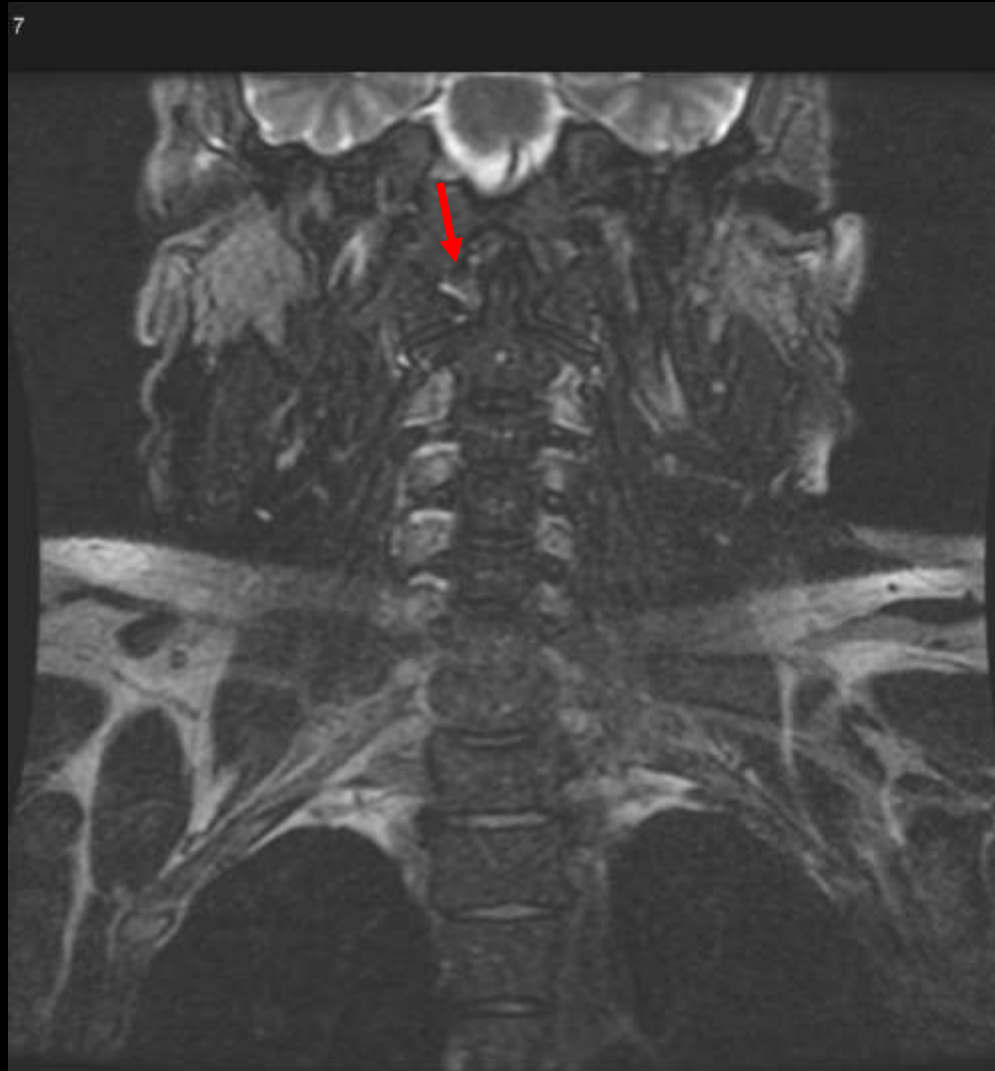
W 654 : L 204

Right Alar ligament tear

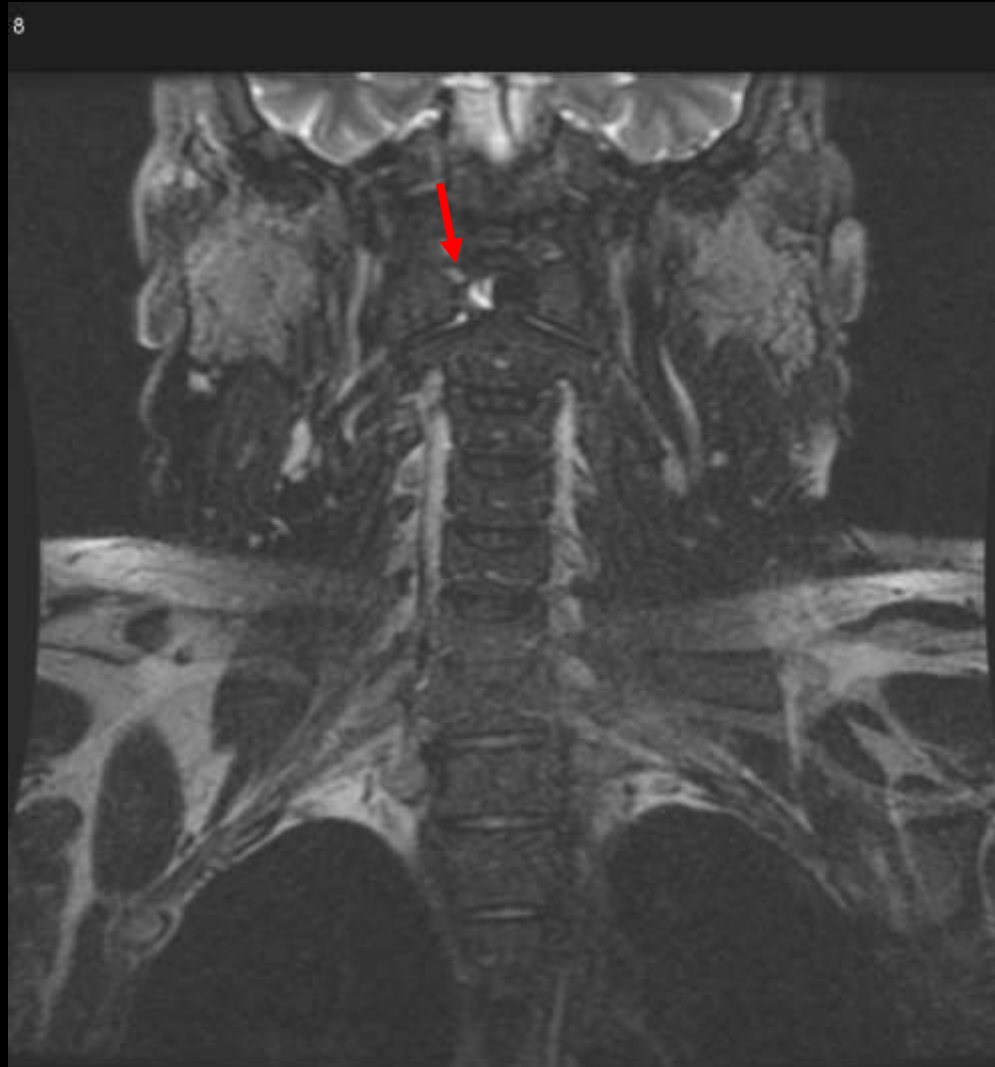


W 654 : L 204

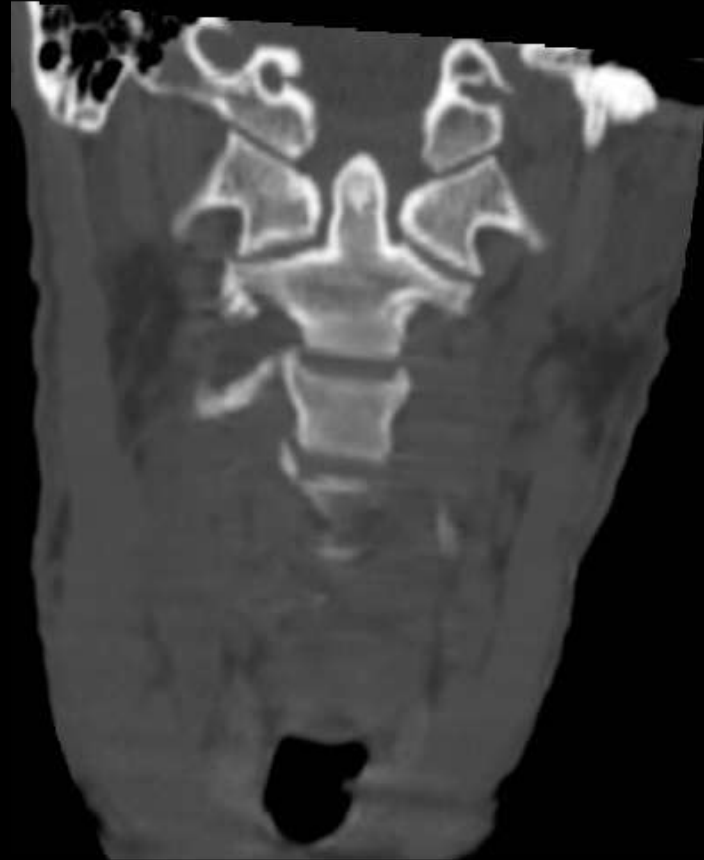
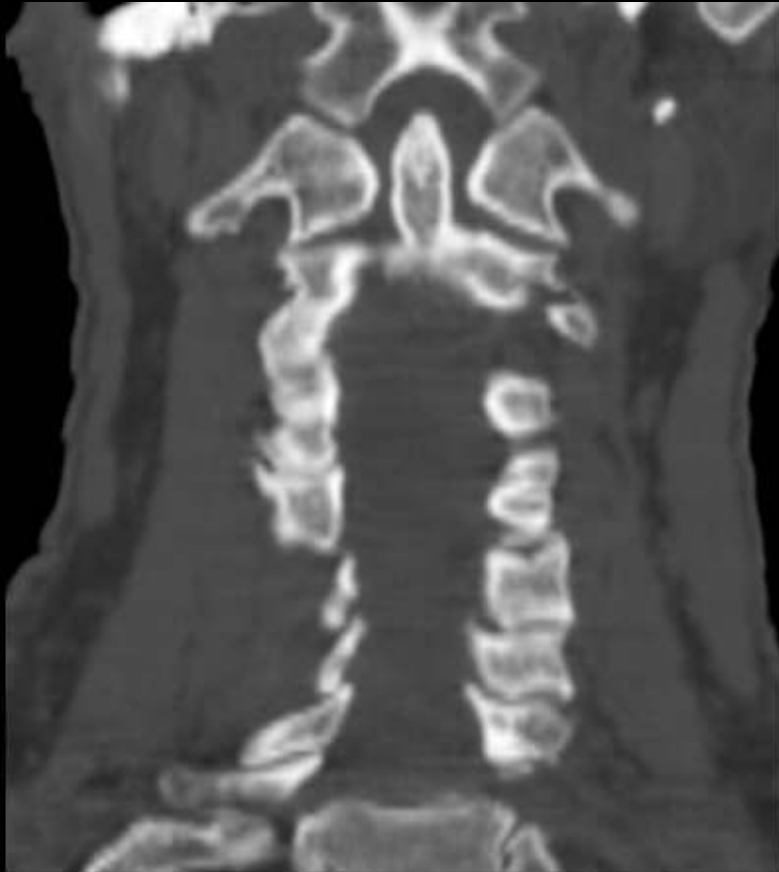Right Alar ligament tear



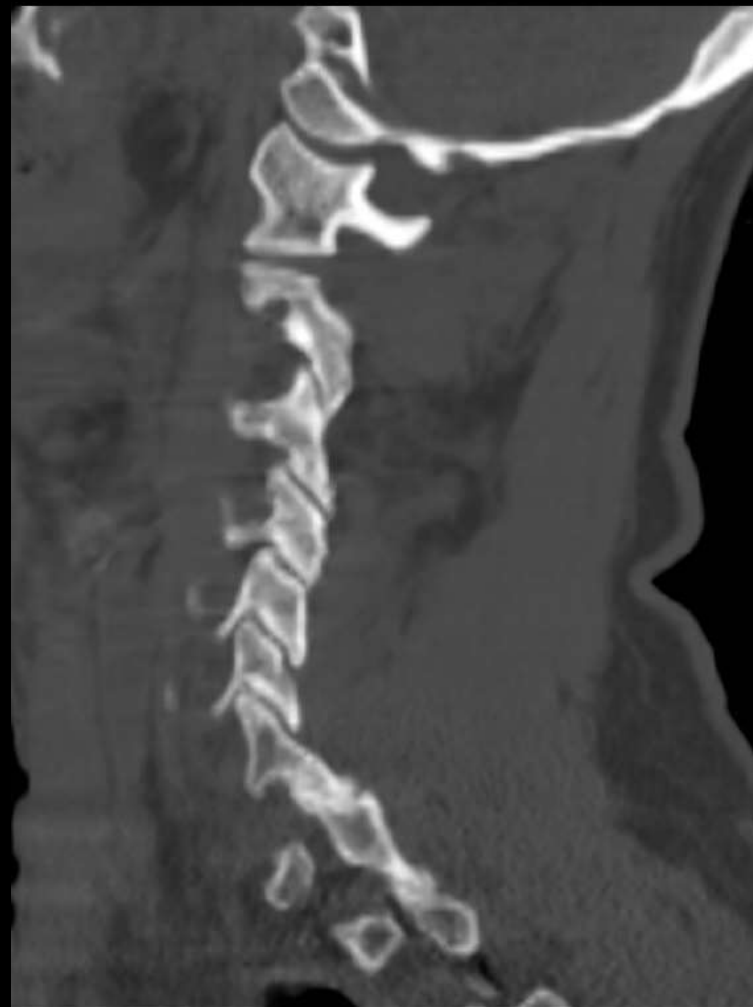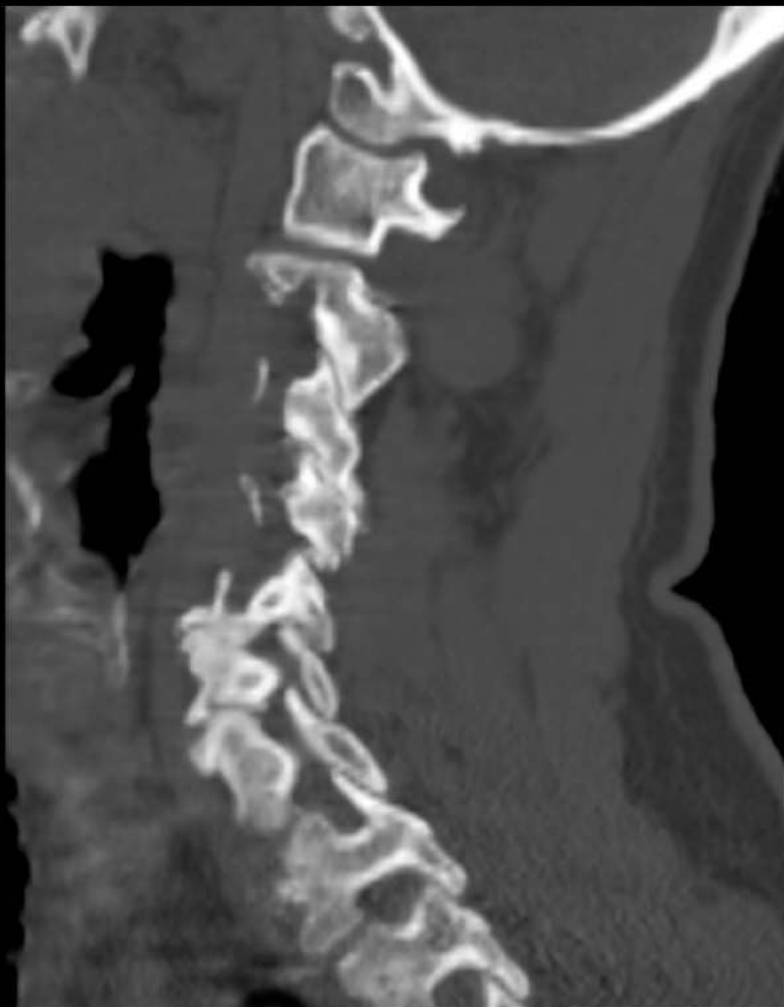Right Alar ligament tear



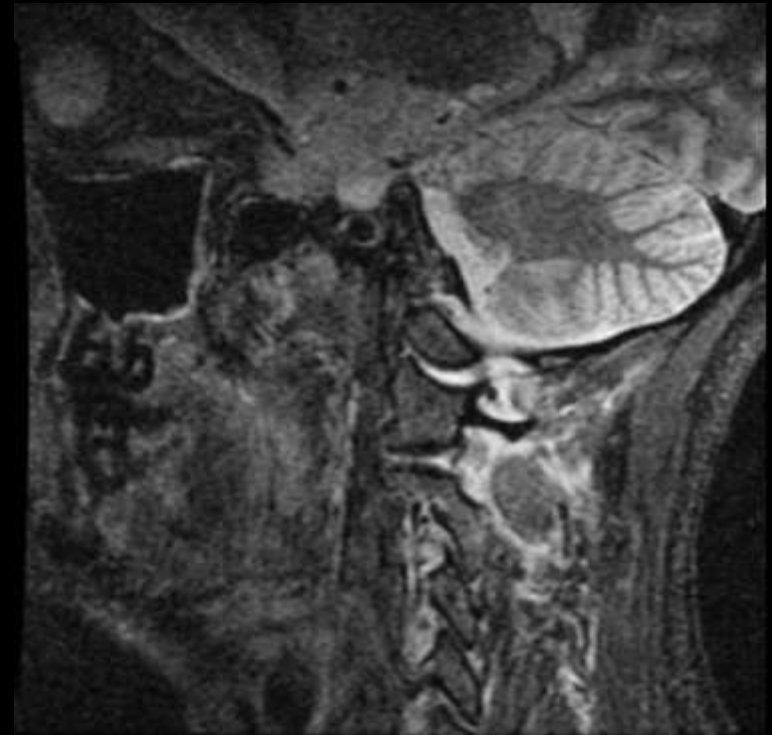
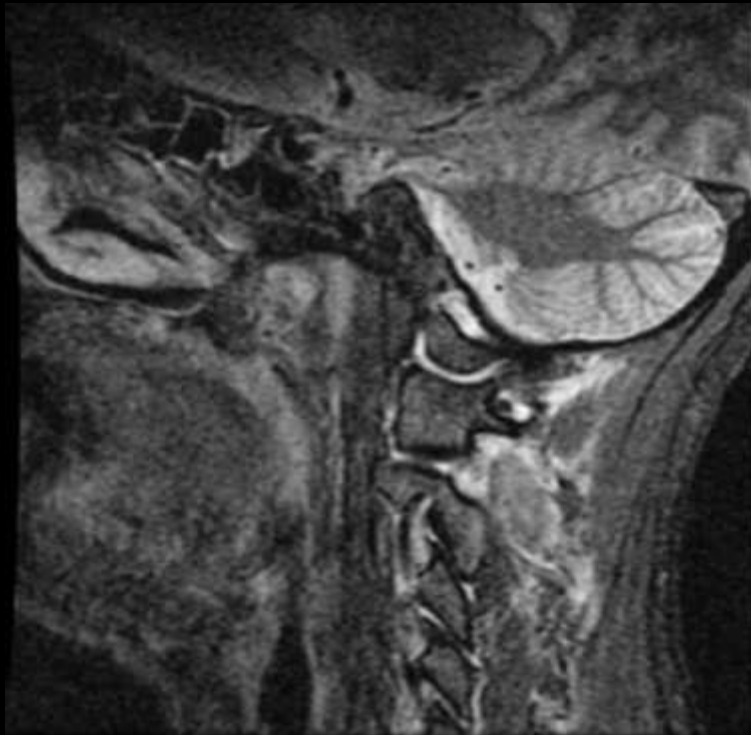
Left Alar ligament tear



Left Alar ligament tear

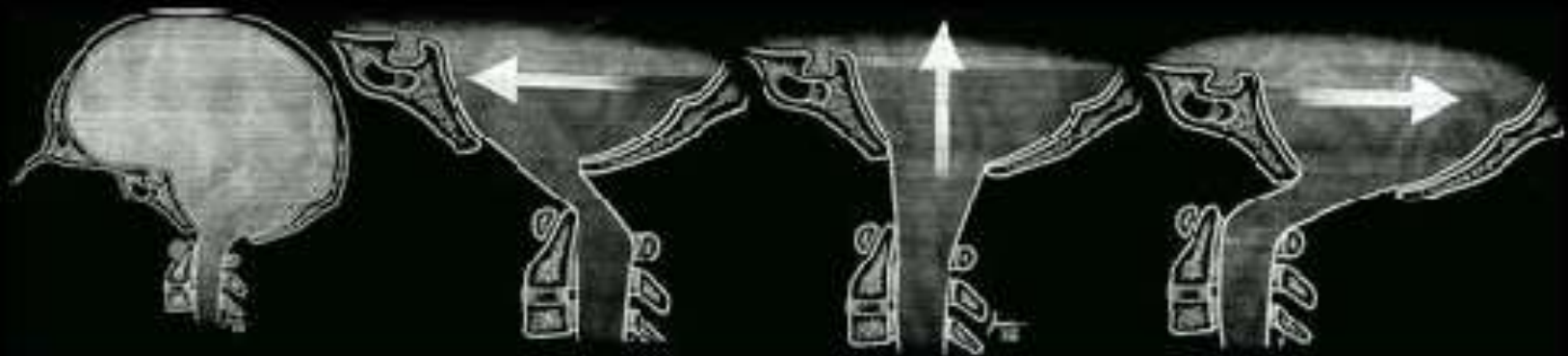

Left Alar ligament tear



Atlanto Occipital Dislocation

- 40% missed dx at presentation
- STS +/- Retropharyngeal air
- Avulsion fractures occipital condyle or lower tip of clivus
- Classification:



Normal

I

II

III

Atlanto Occipital Dislocation

Causes:

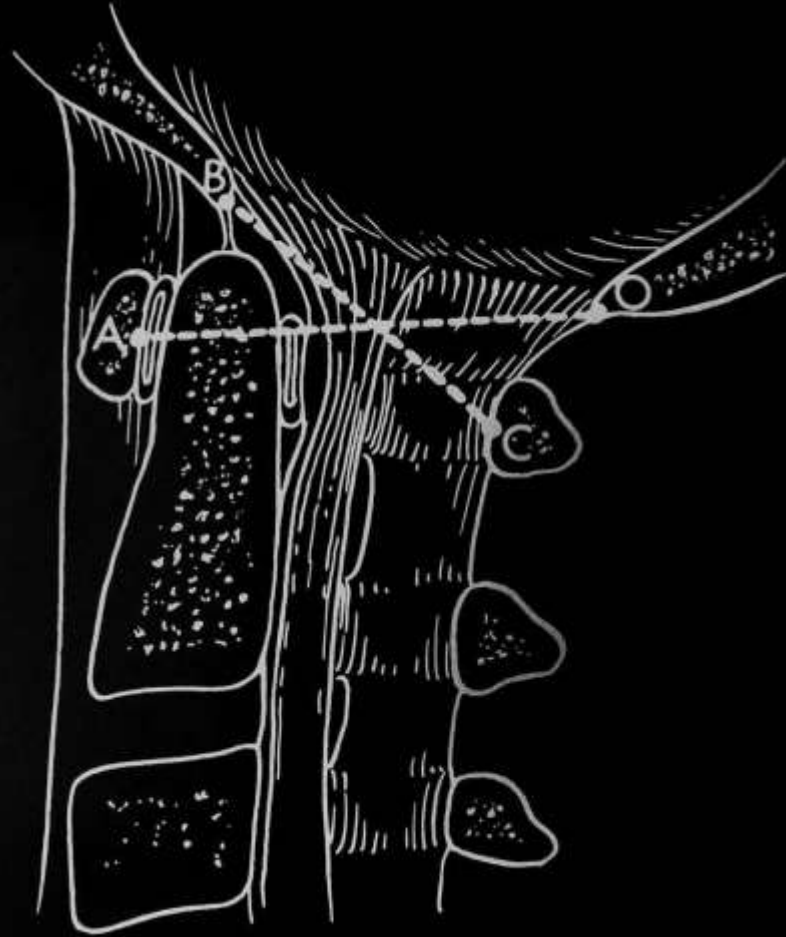- Traumatic
- Nontraumatic
 - RA
 - Congenital Skeletal Abnormalities
 - Down's
 - Infection
 - CPPD
- Prognosis not good
 - (but 20% may have no deficit!)

Atlantooccipital subluxation

- Powers ratio:
 - Basion to C1 Posterior lamina line / Opisthion to posterior cortex of the anterior C1 tubercle <1
- X method of Lee
- Clival line
- BAI (Basion Axial Interval)
 - Anterior distance of basion from PSL $-4 - +12$ mm
- BDI (Basion Dental Interval)
 - Vertical distance of basion above dens <12 mm

Occipito atlas separation

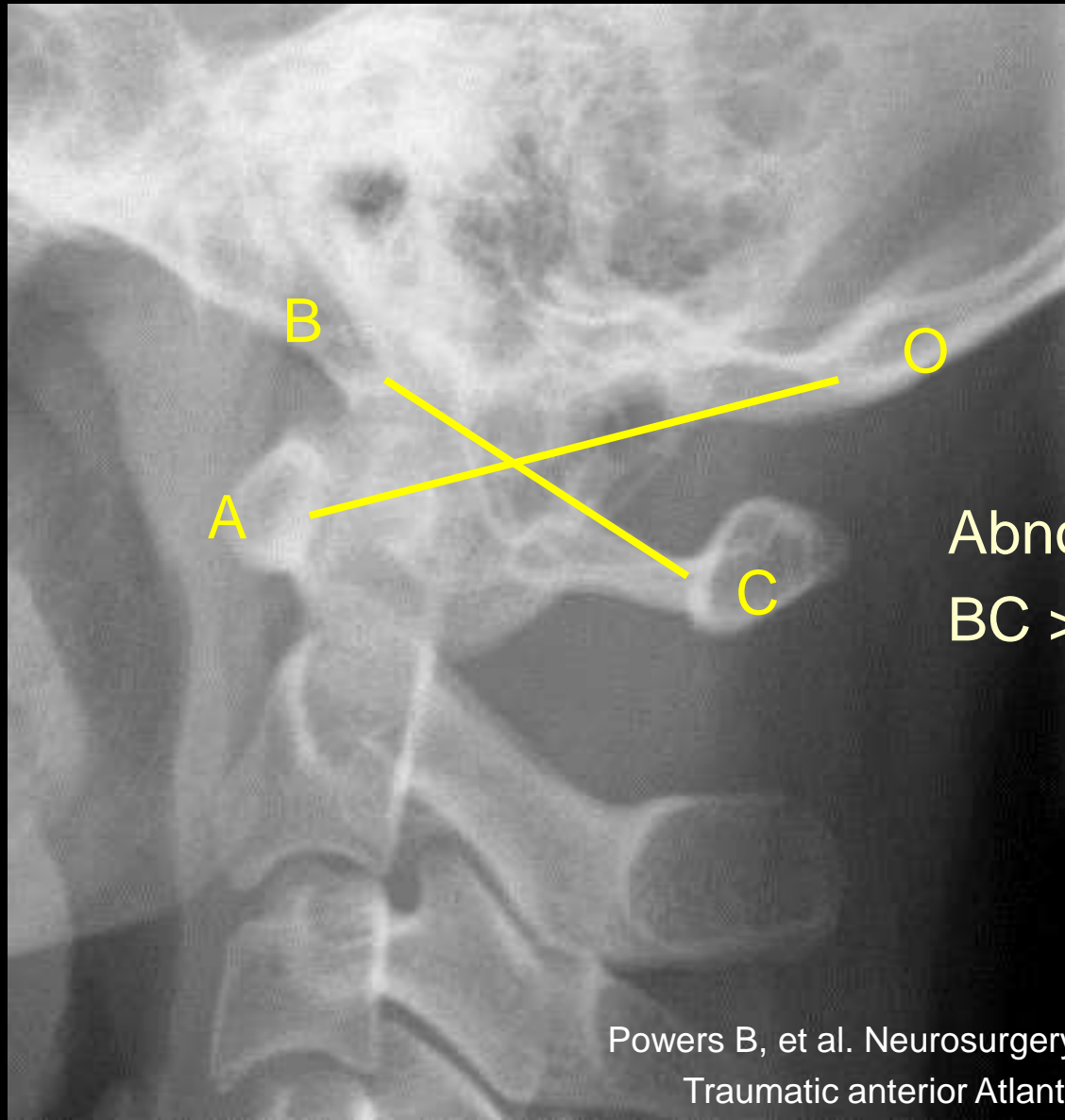
Power's ratio



Powers B, et al. Neurosurgery. 1979 Jan;4(1):12-7.
Traumatic anterior Atlanto-occipital dislocation.

Occipito atlas separation

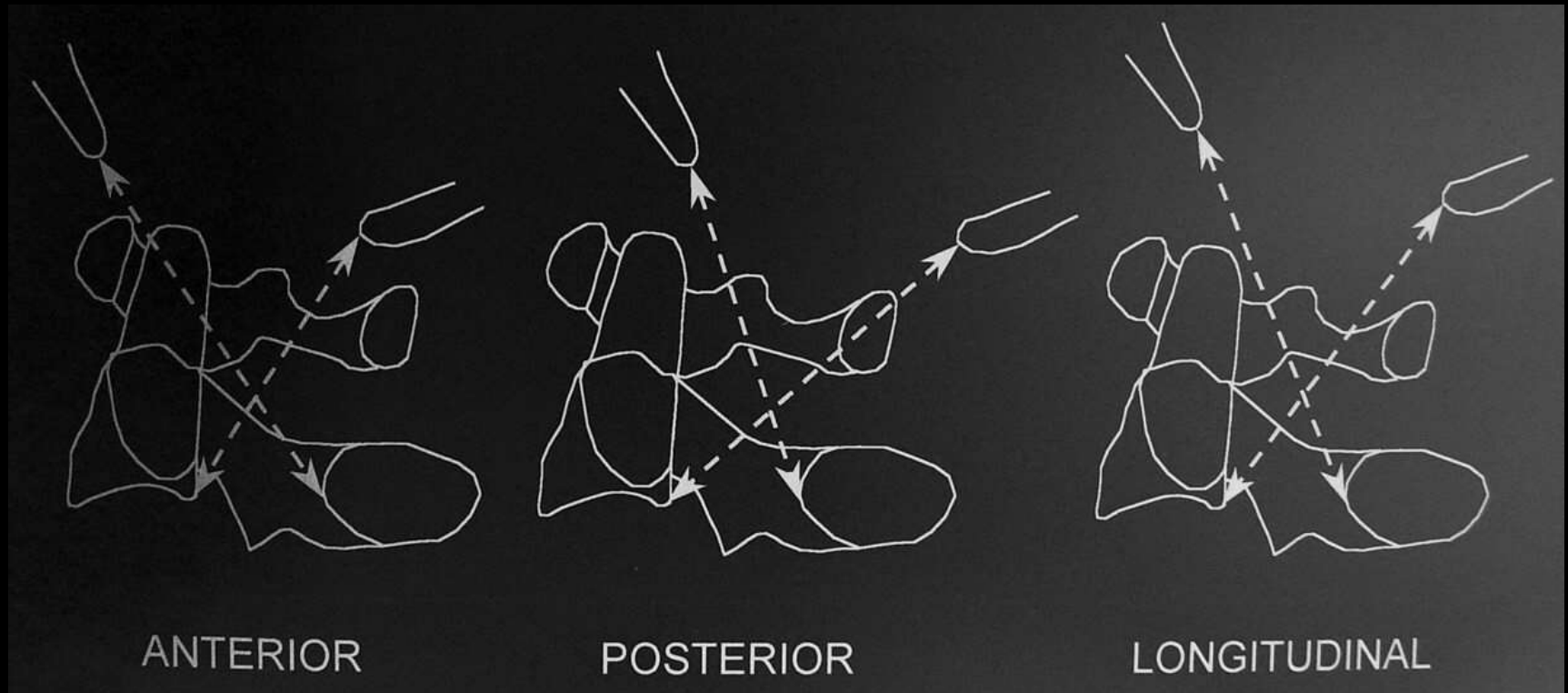
Power's ratio - Normal



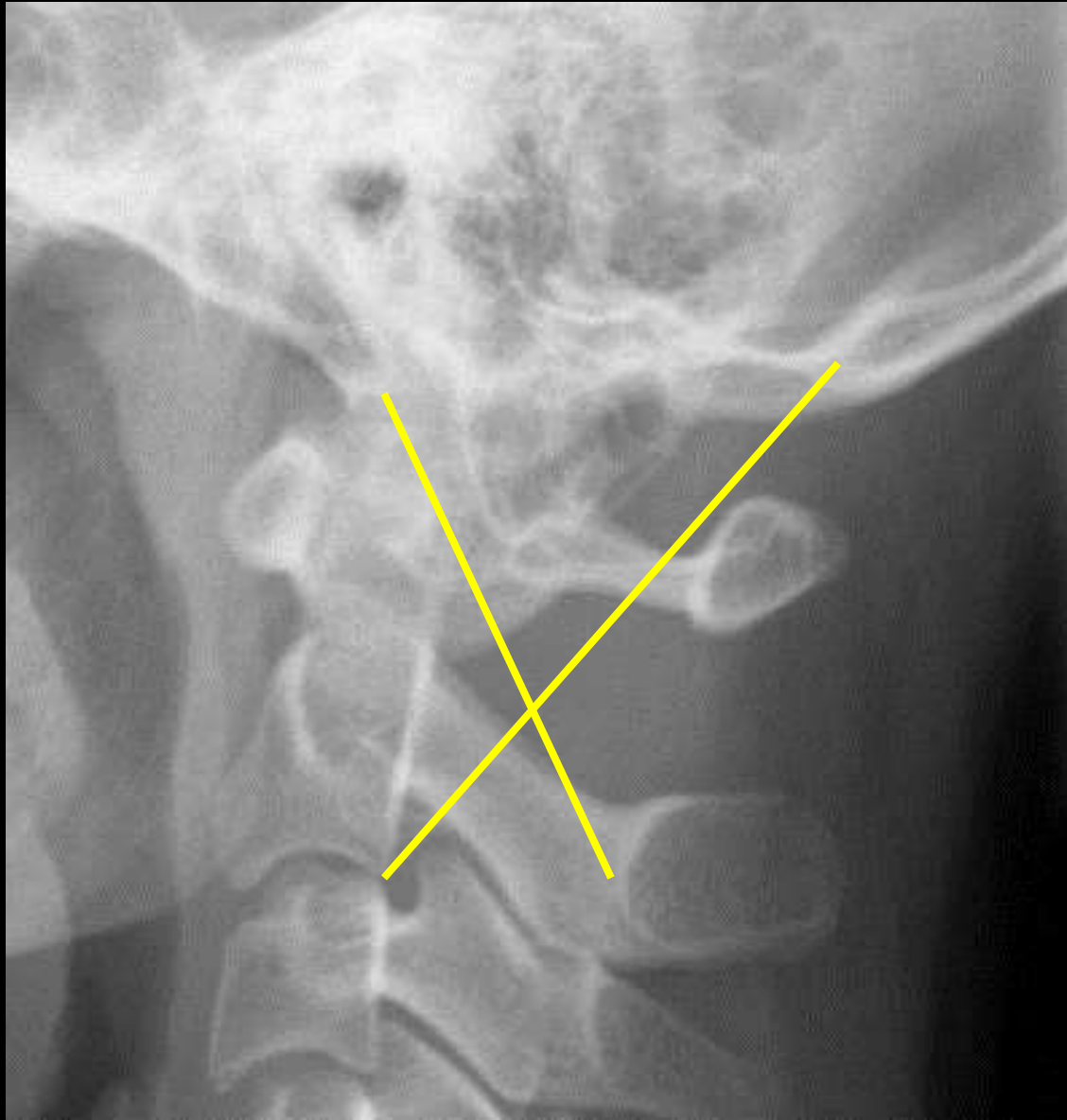
Abnormal
 $BC > AO$

Powers B, et al. Neurosurgery. 1979 Jan;4(1):12-7.
Traumatic anterior Atlanto-occipital dislocation.

Occipito atlas separation X Line

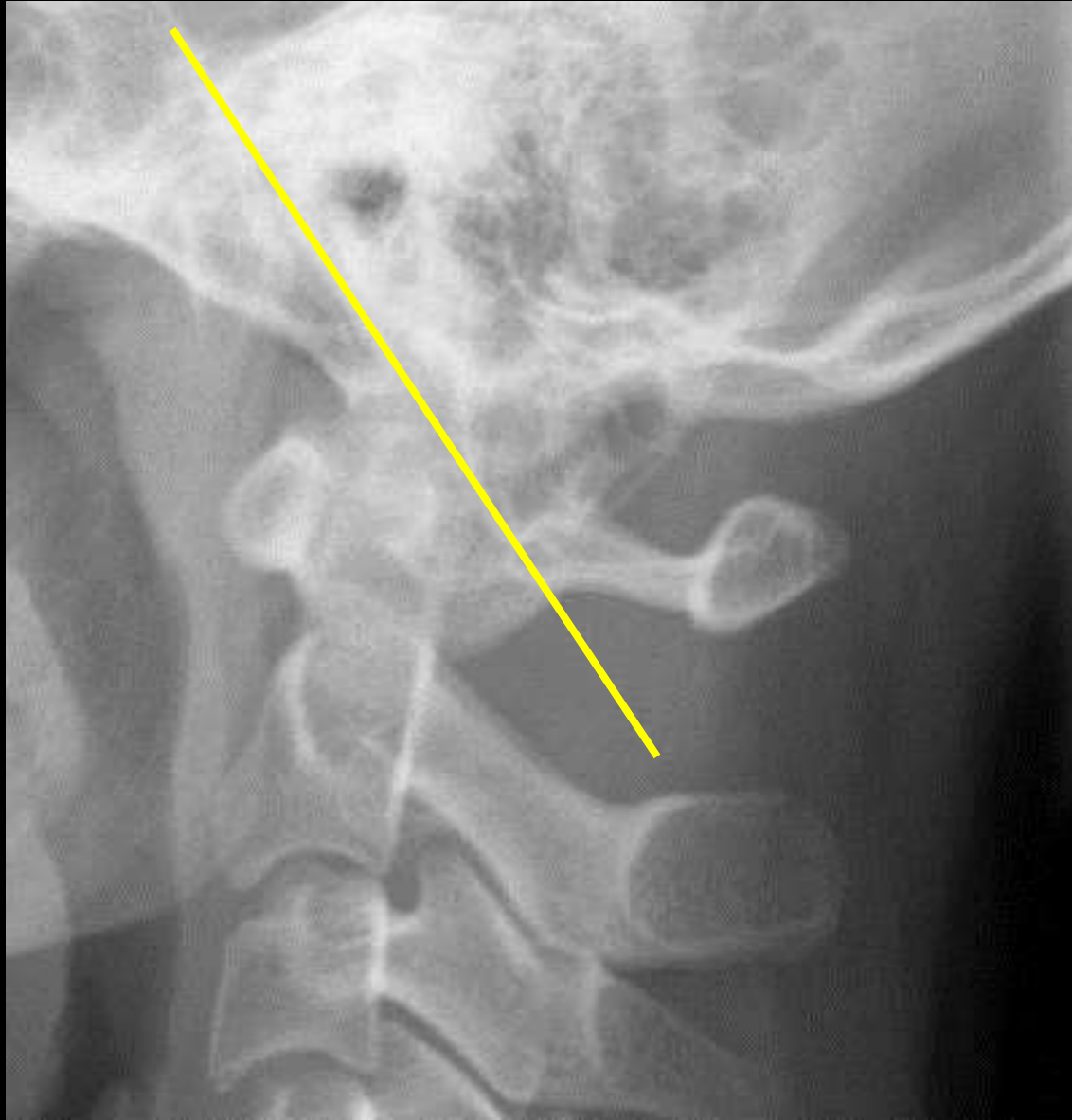

Occipito atlas separation
X Line - Normal



Occipito atlas separation

Clival Line - Normal

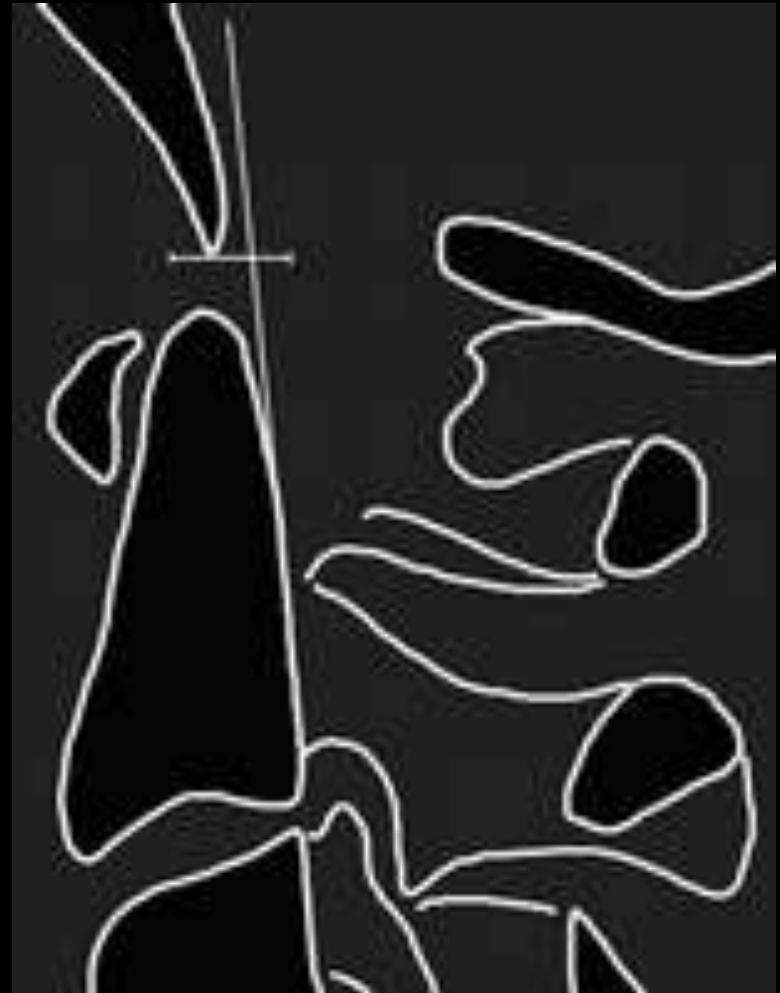

Occipito atlas separation

Basion Axial Interval

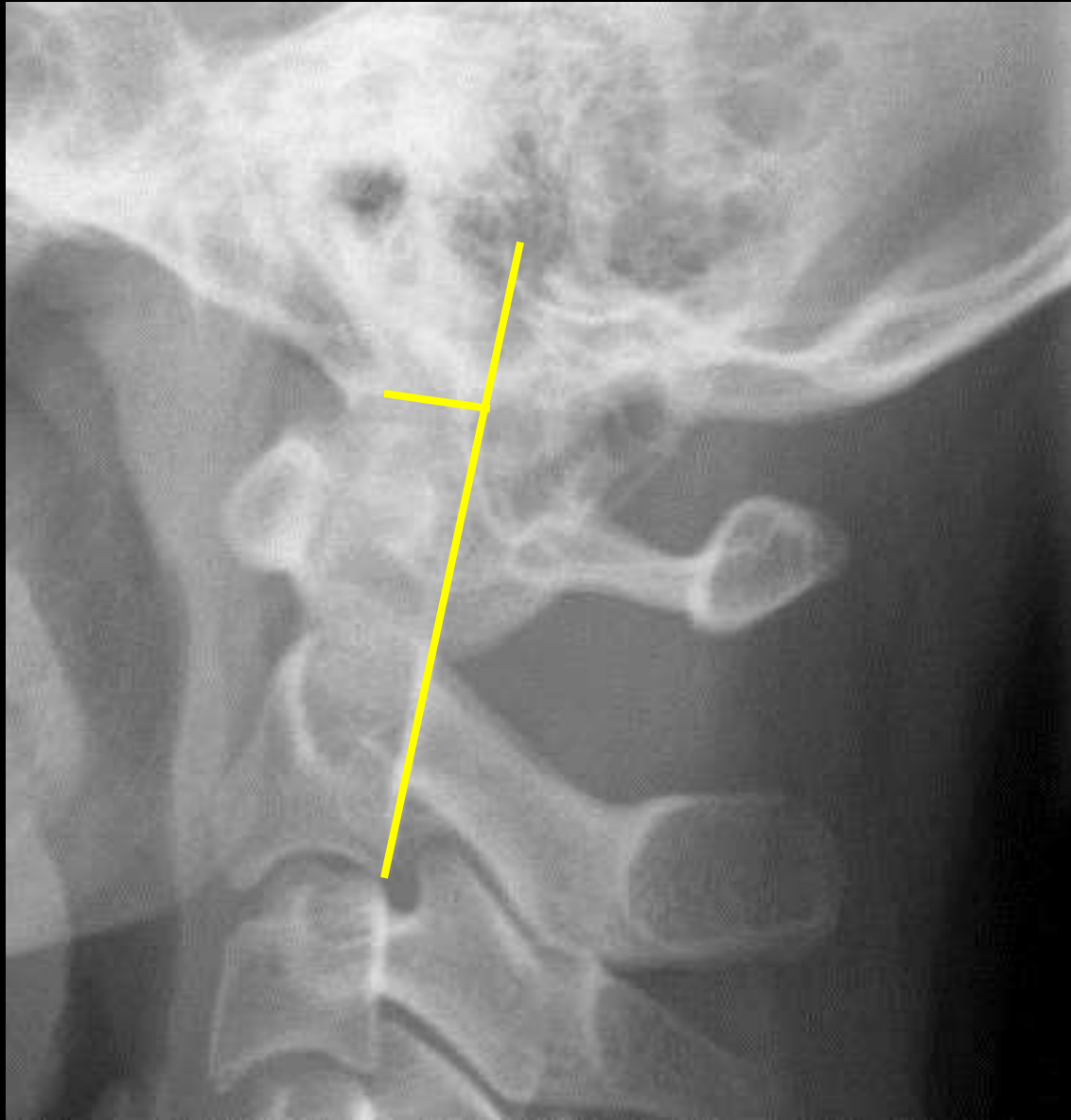Basion / Posterior axial line interval

- Vertical line along posterior aspect of C2
- Basion should <12mm anterior or <4mm posterior to this line



Occipito atlas separation

Basion Axial Interval - Normal

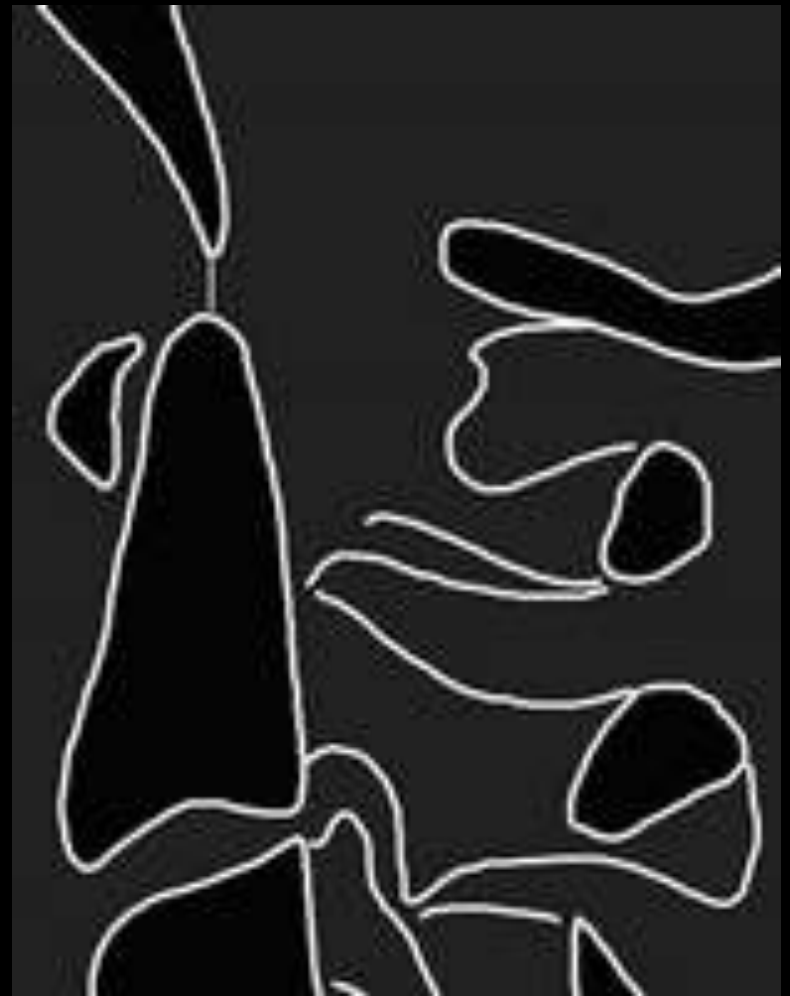

Occipito atlas separation

Basion Dental Interval

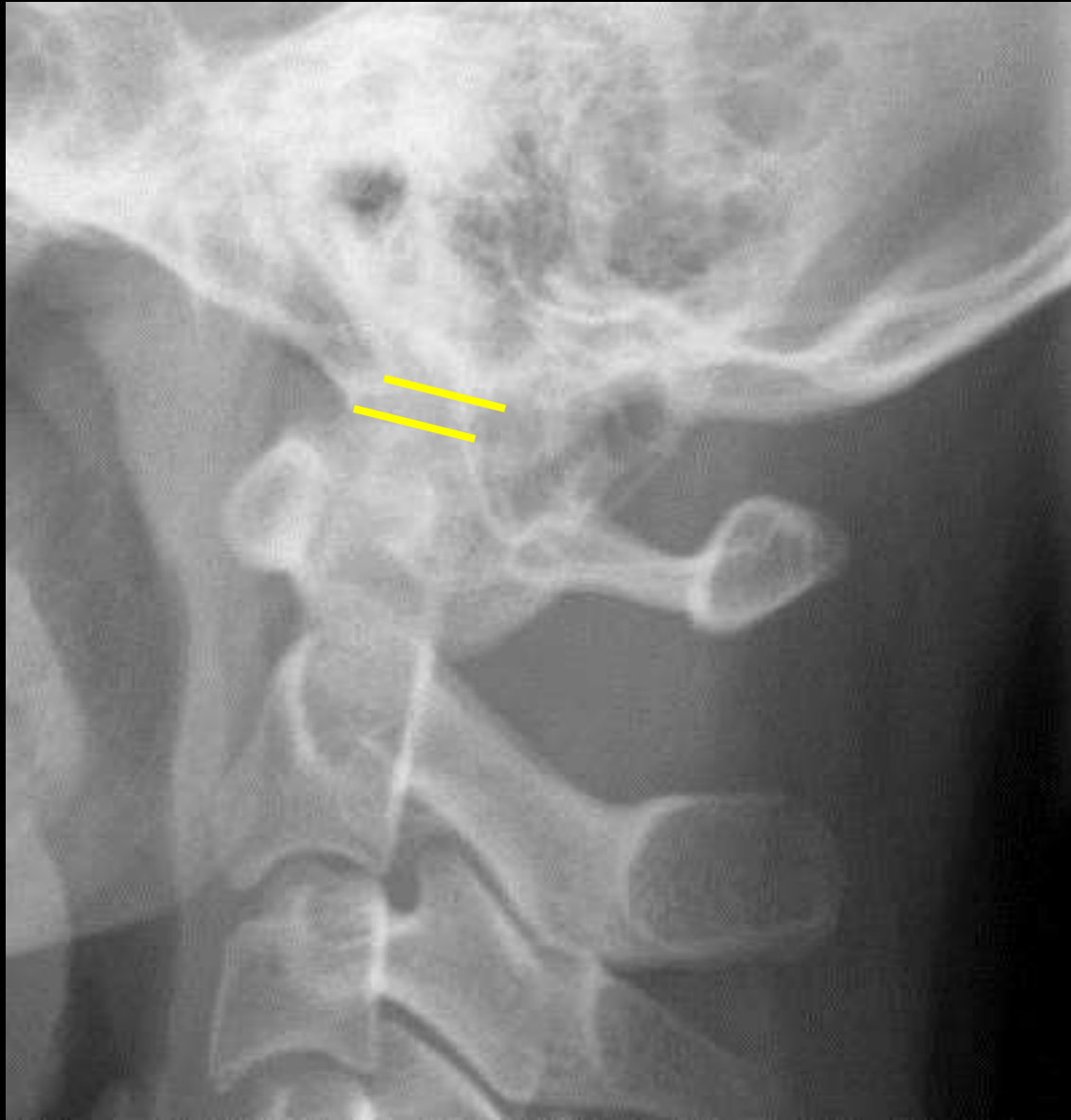Basion dens interval

- Tip of basion to dens
- <12mm

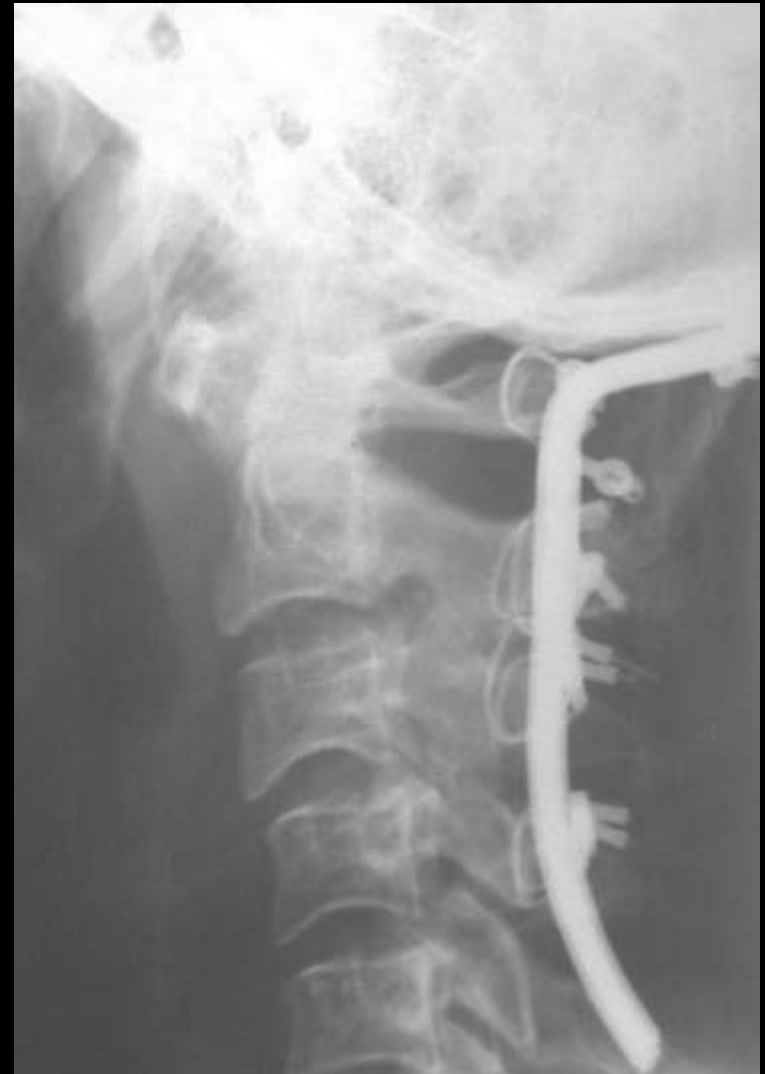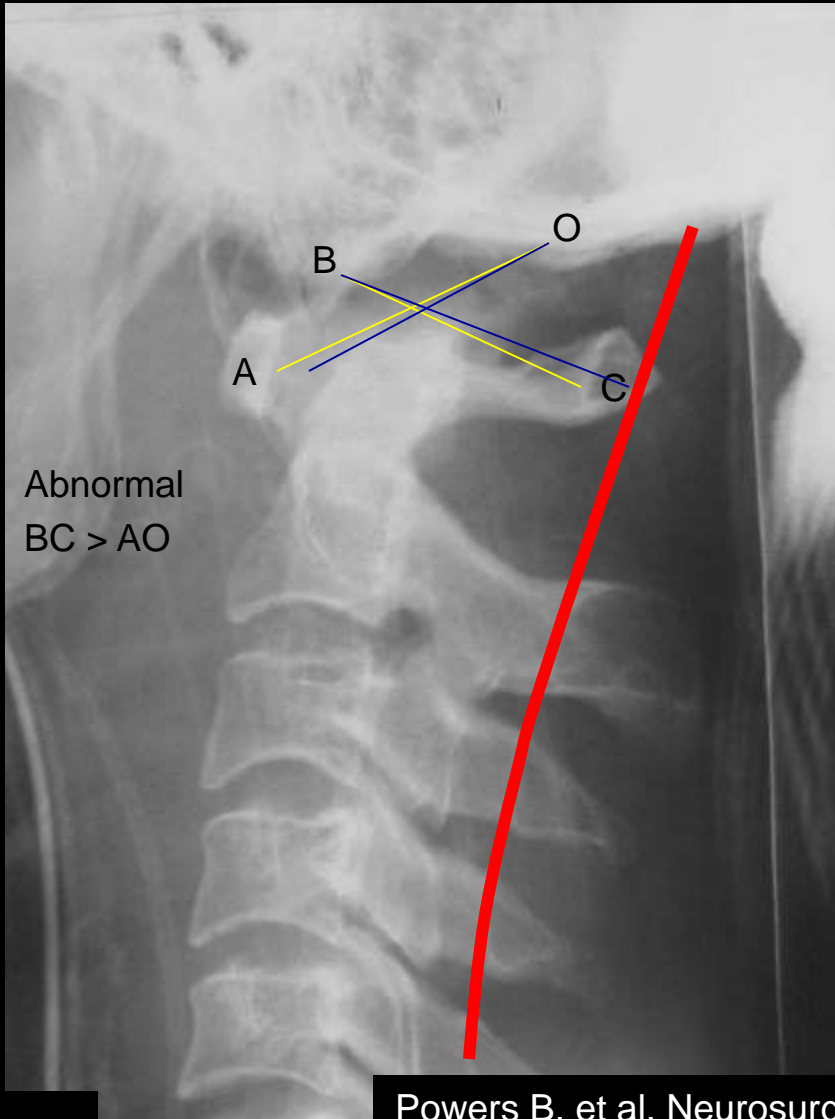


Occipito atlas separation

Basion Dental Interval



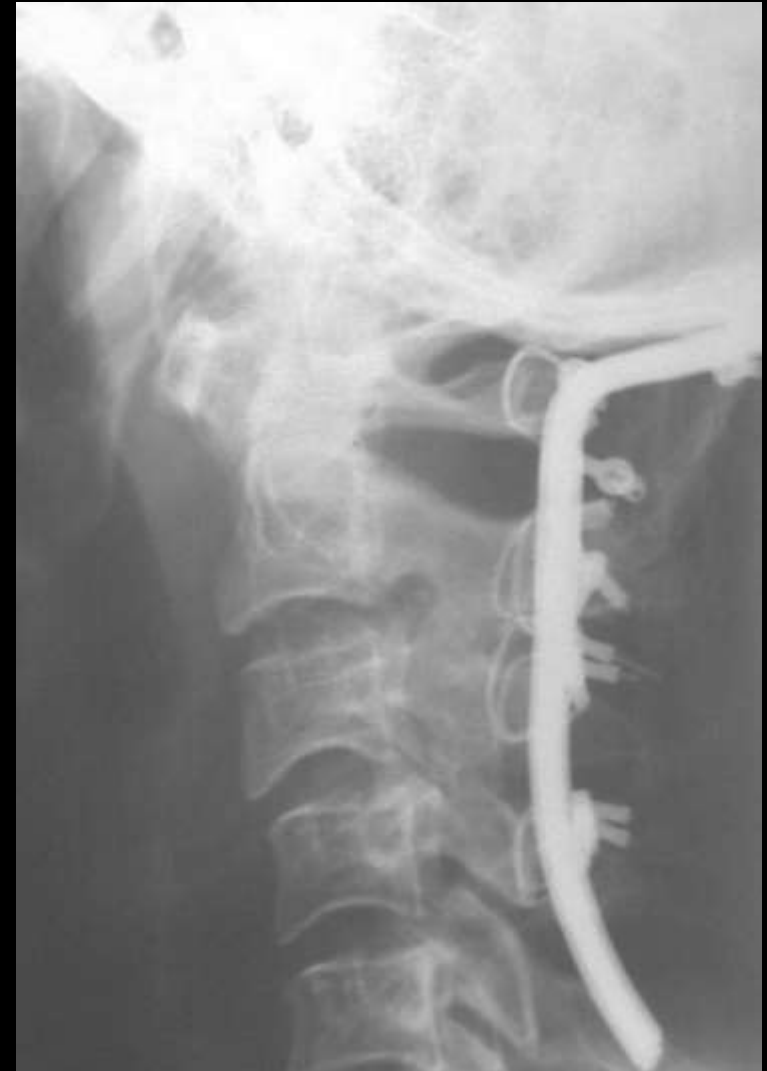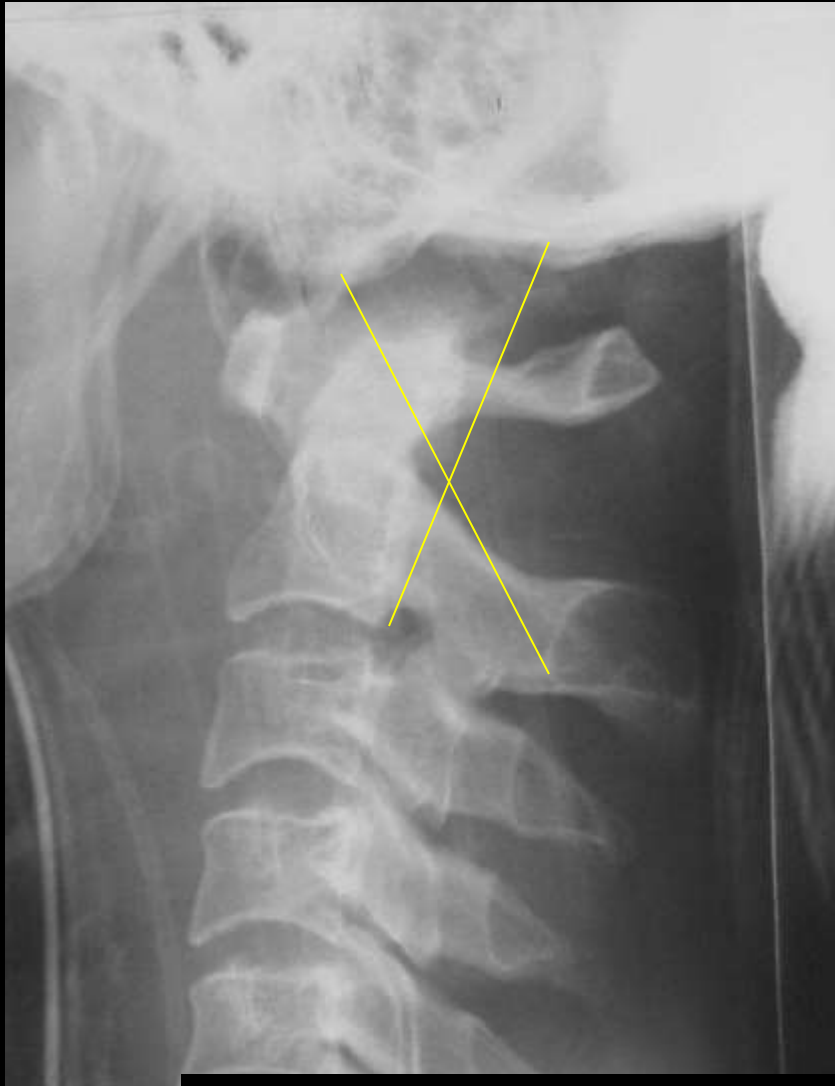
Anterior Atlanto-occipital Dislocation.



Powers B, et al. Neurosurgery. 1979 Jan;4(1):12-7.
Traumatic anterior Atlanto-occipital dislocation.

Atlanto axial and cranial
atlas separation 32M

Anterior Atlanto-occipital Dislocation.

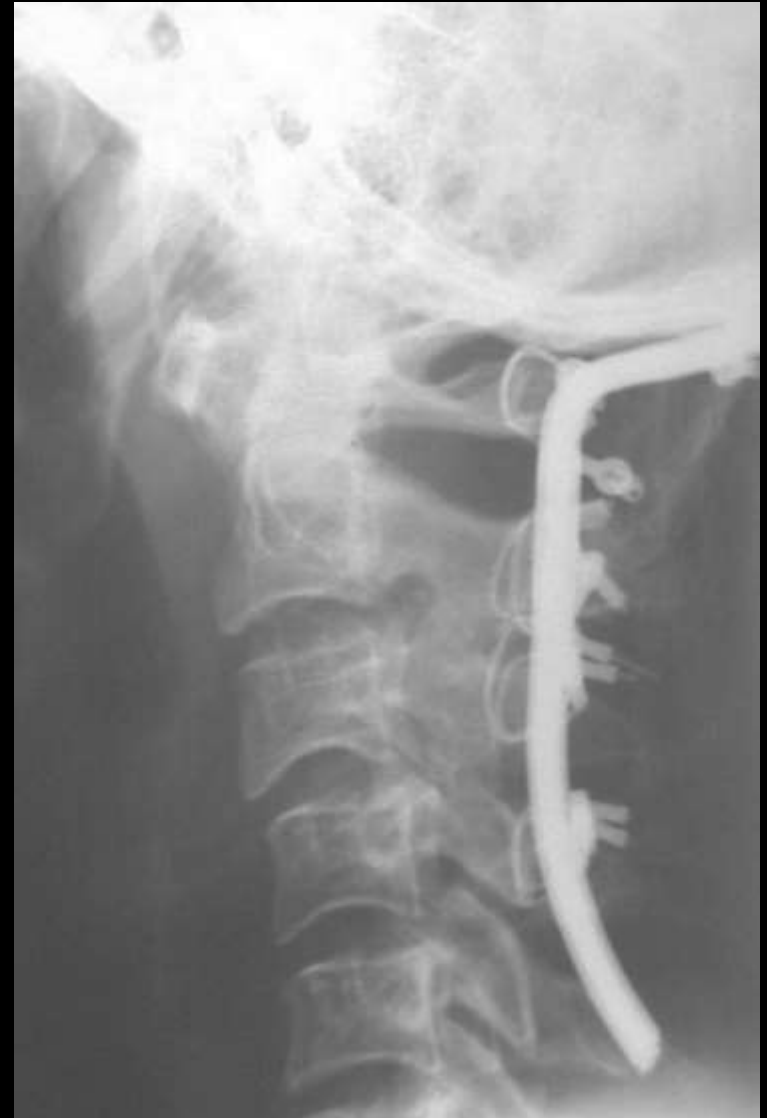
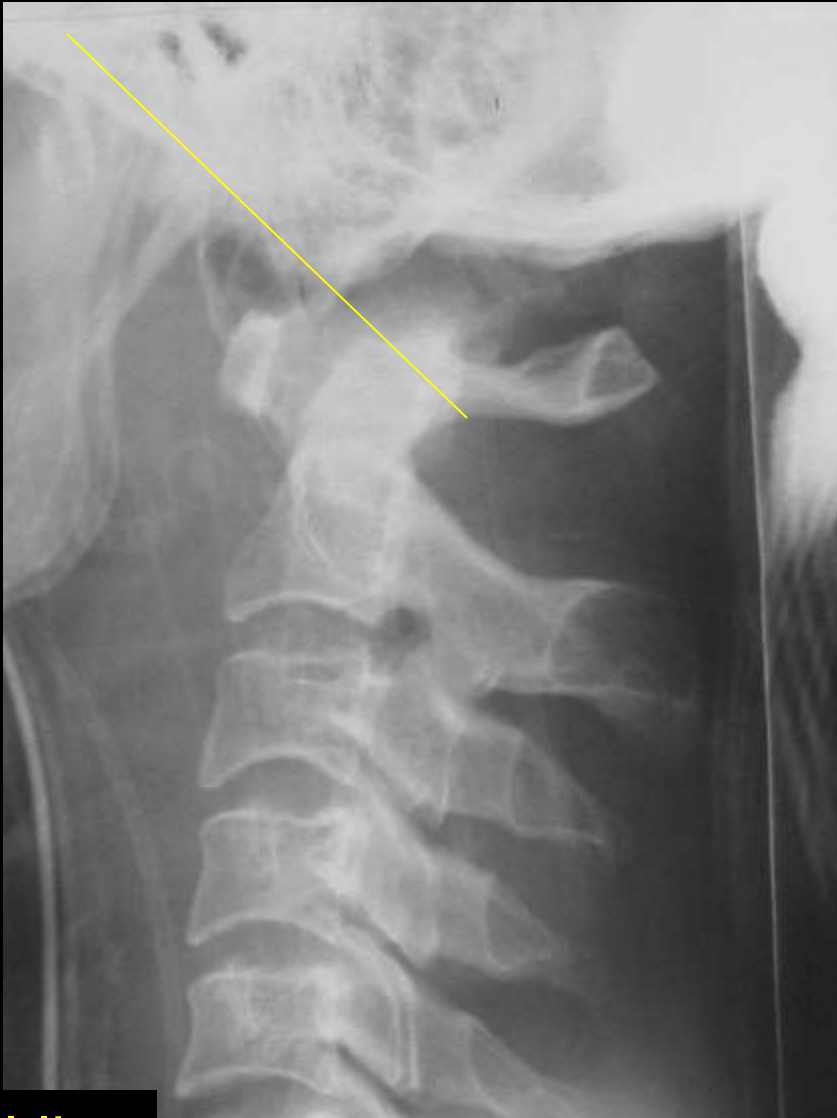
X method

Lee C, et al AJNR Am J Neuroradiol. 1994 May;15(5):990.
Evaluation of traumatic atlantooccipital dislocations.

Atlanto axial and cranial
atlas separation 32M

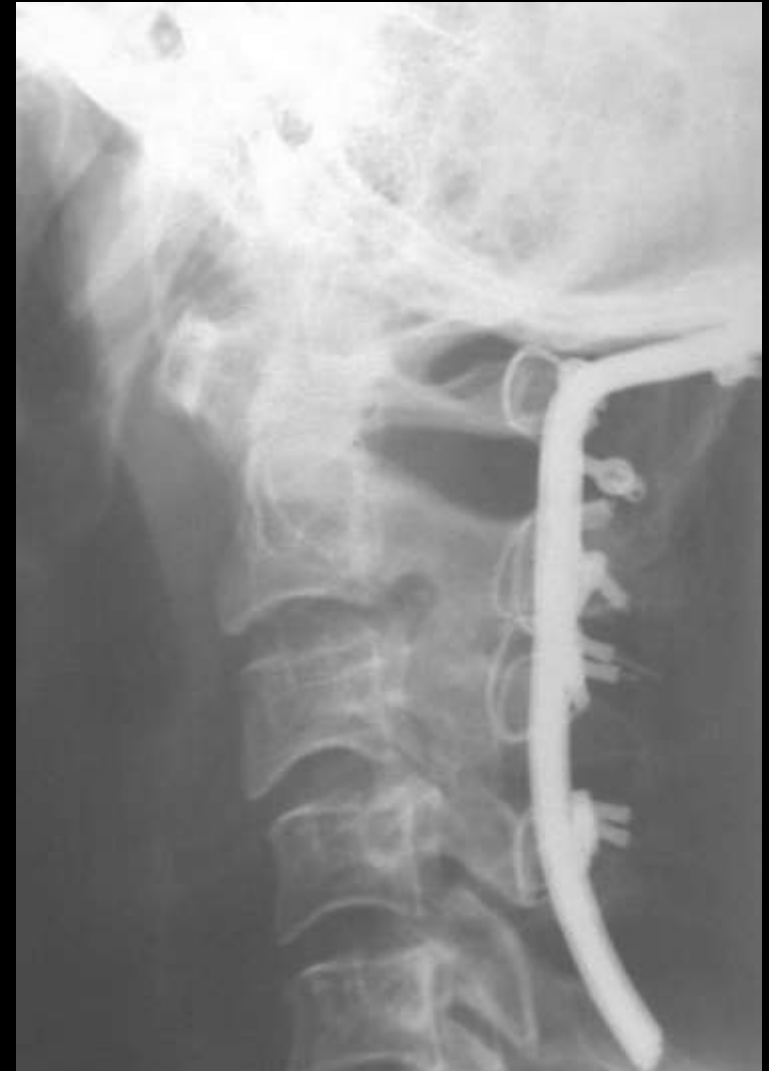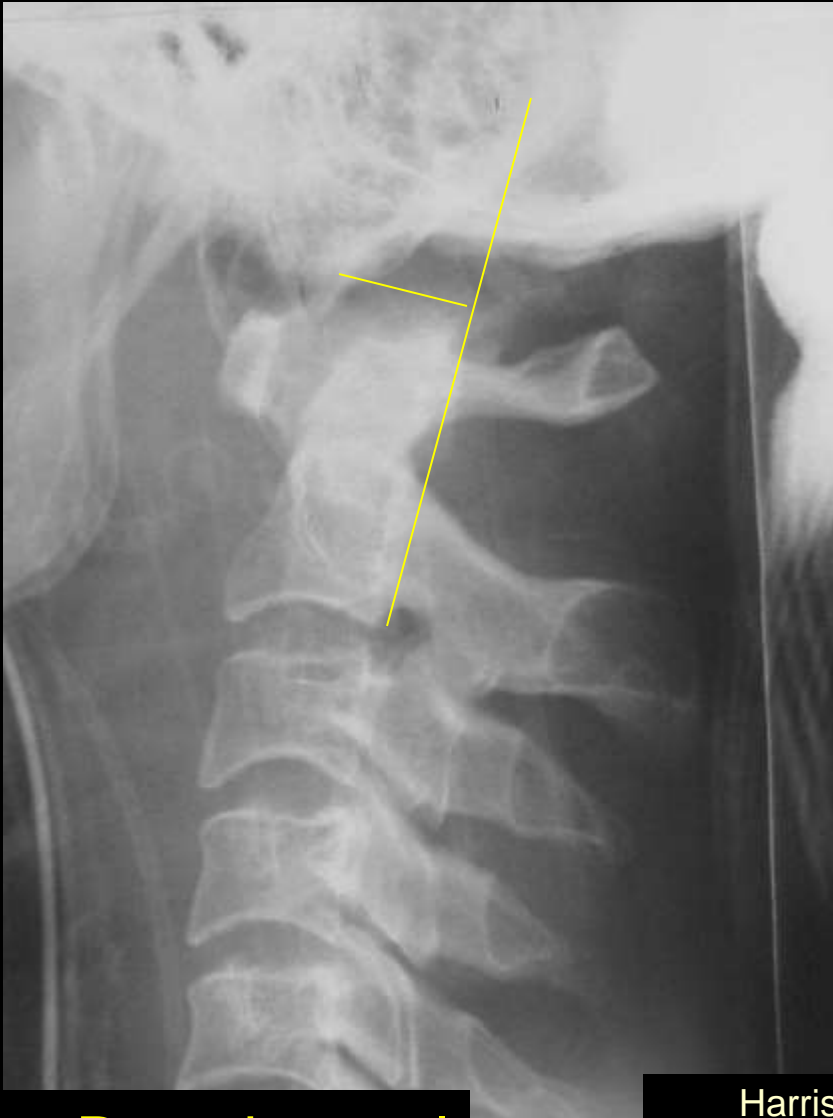Anterior Atlanto-occipital Dislocation.



Clival line

Atlanto axial and cranial atlas separation 32M

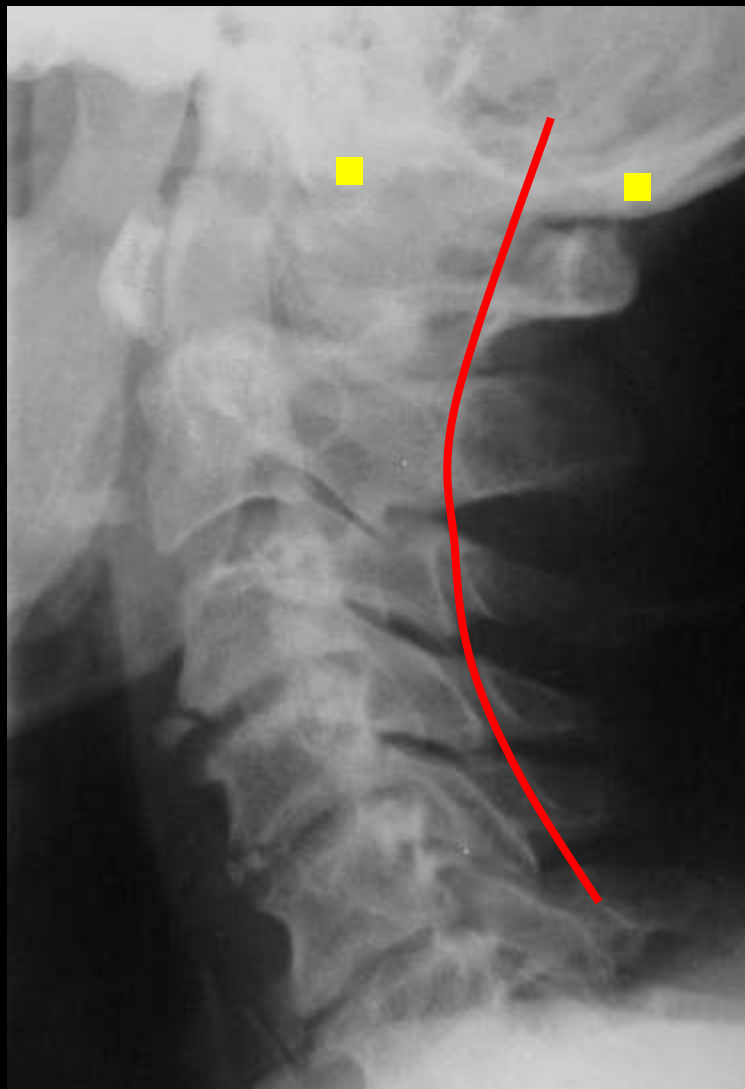Anterior Atlanto-occipital Dislocation.



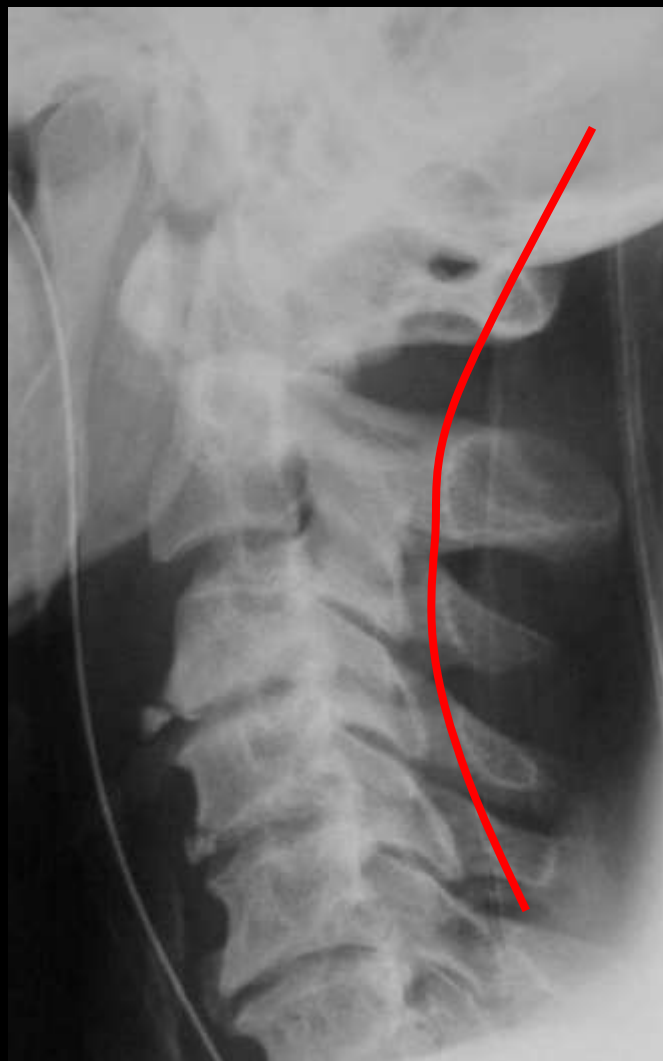Basion Dens interval

Harris JH Jr AJR Am J Roentgenol. 1994 Apr;162(4):887-92.
Radiologic diagnosis of traumatic occipitovertebral dissociation:

Posterior Occipito atlas separation and Fx atlas

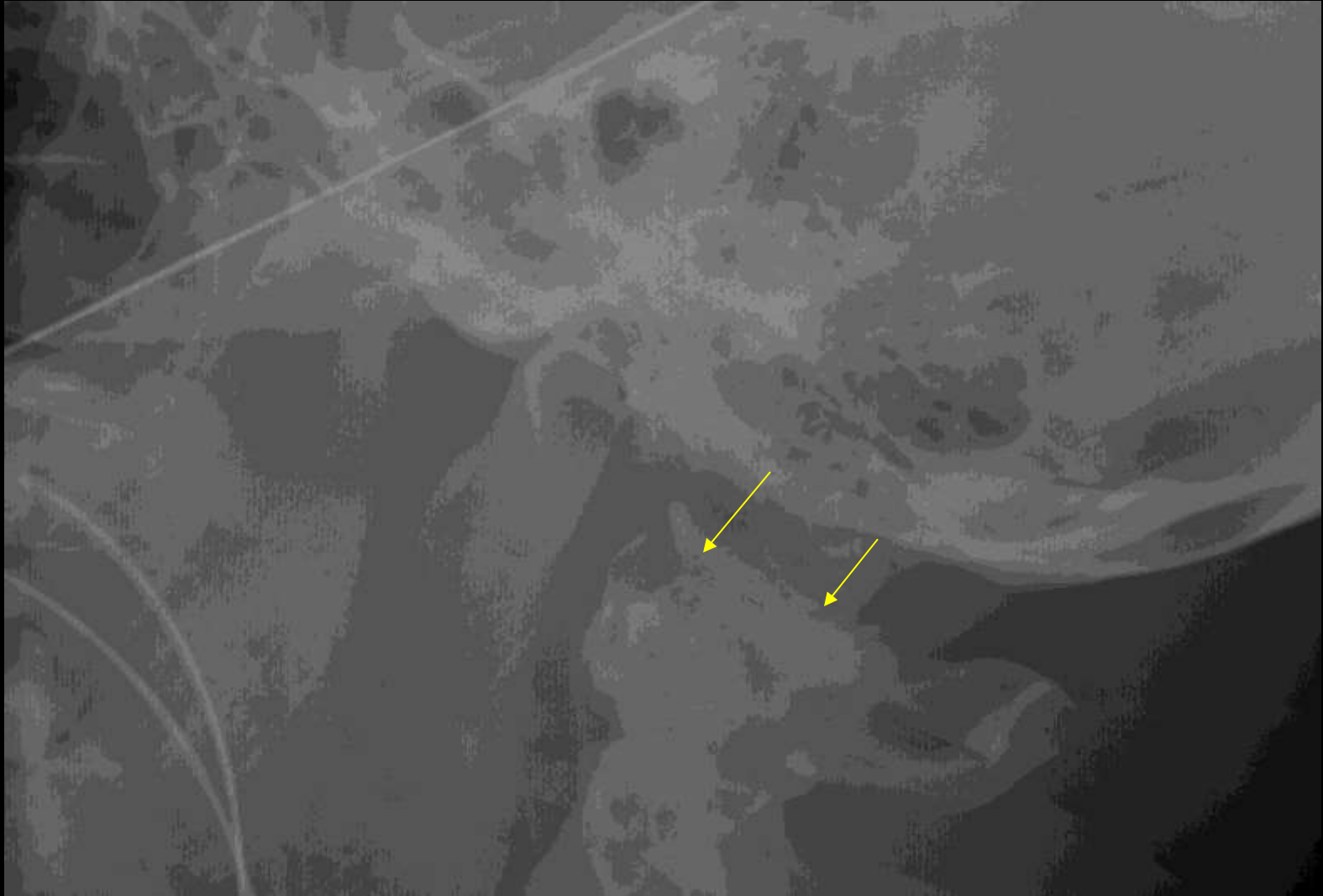


Posterior Occipito atlas separation and Fx atlas

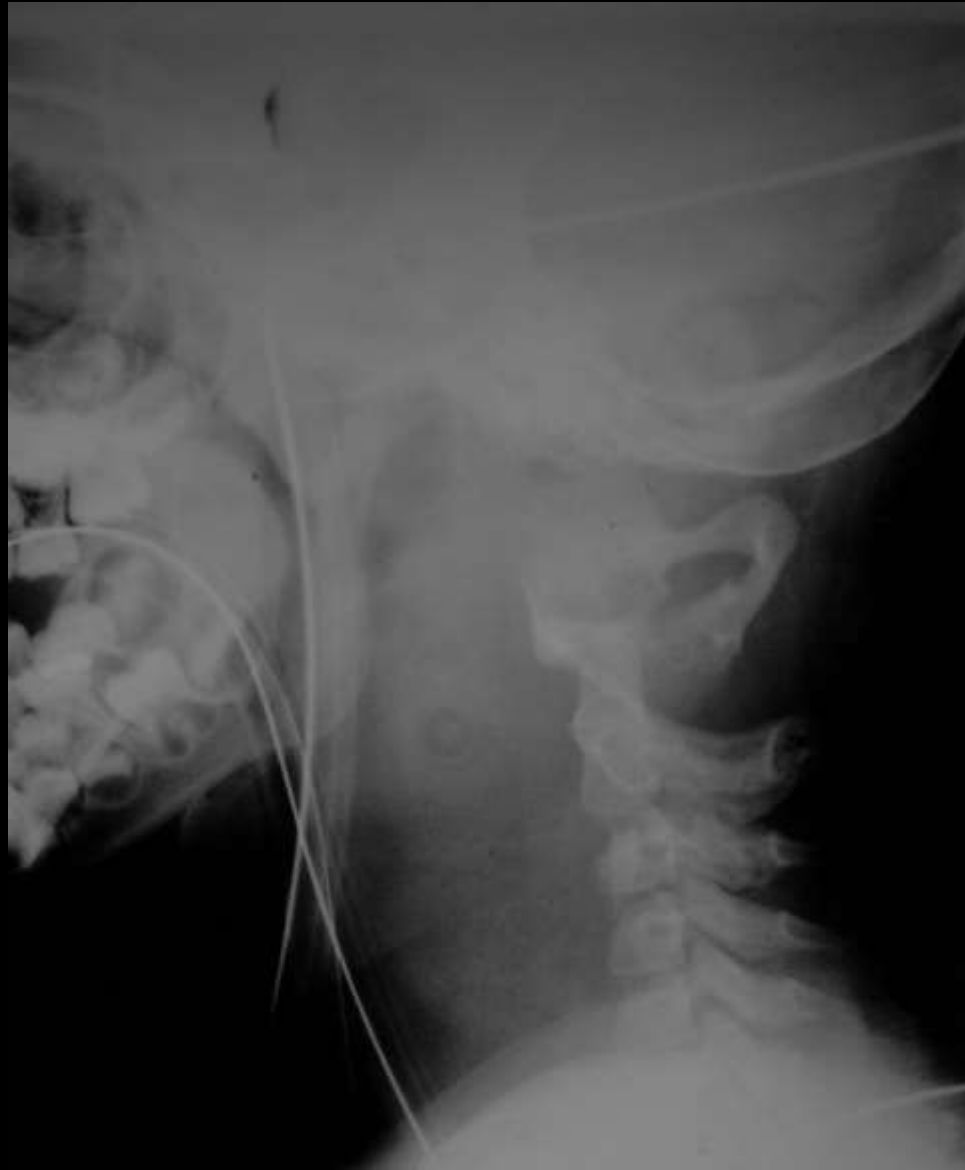

Post reduction

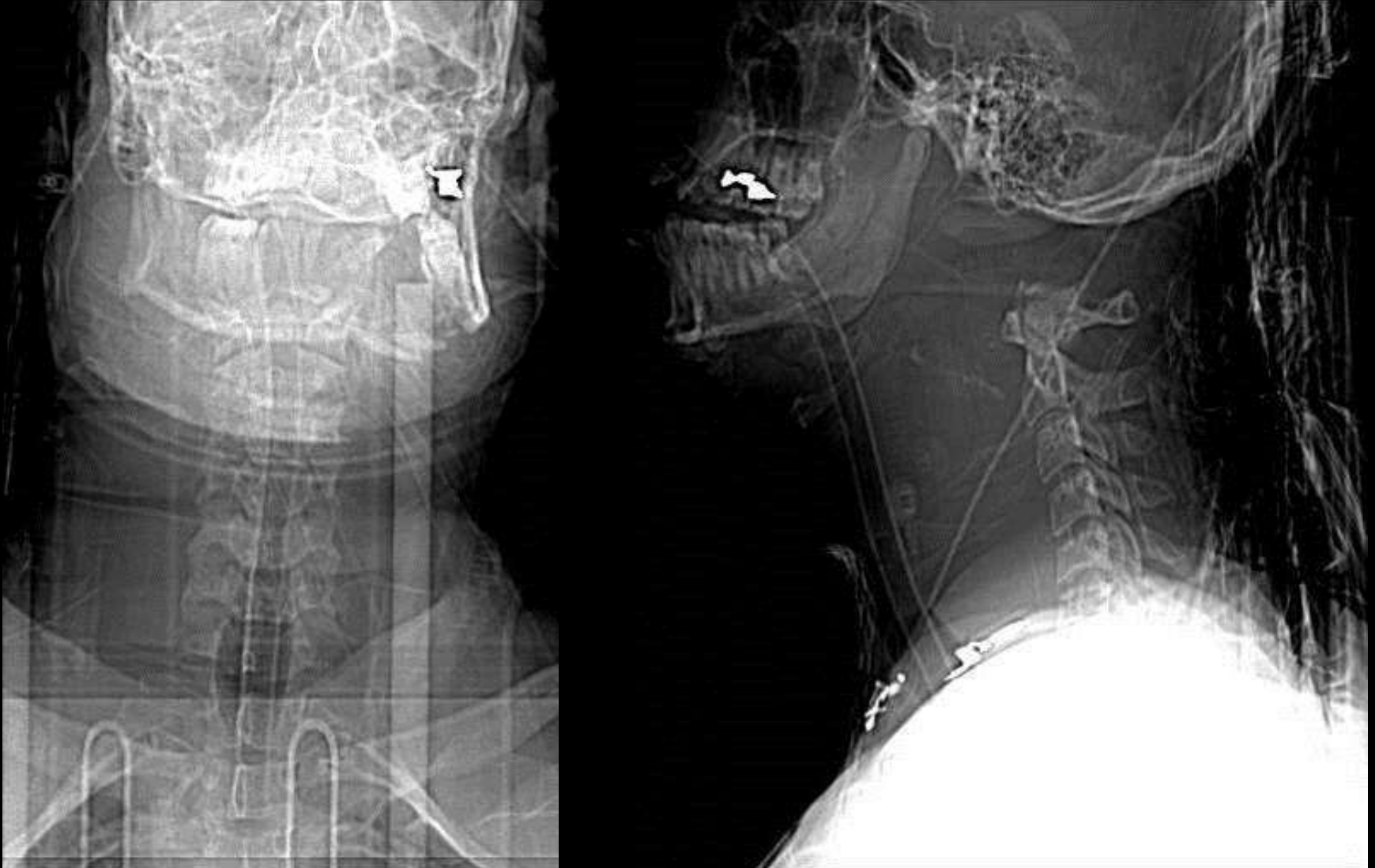
Superior Atlanto-Occipital Dislocation



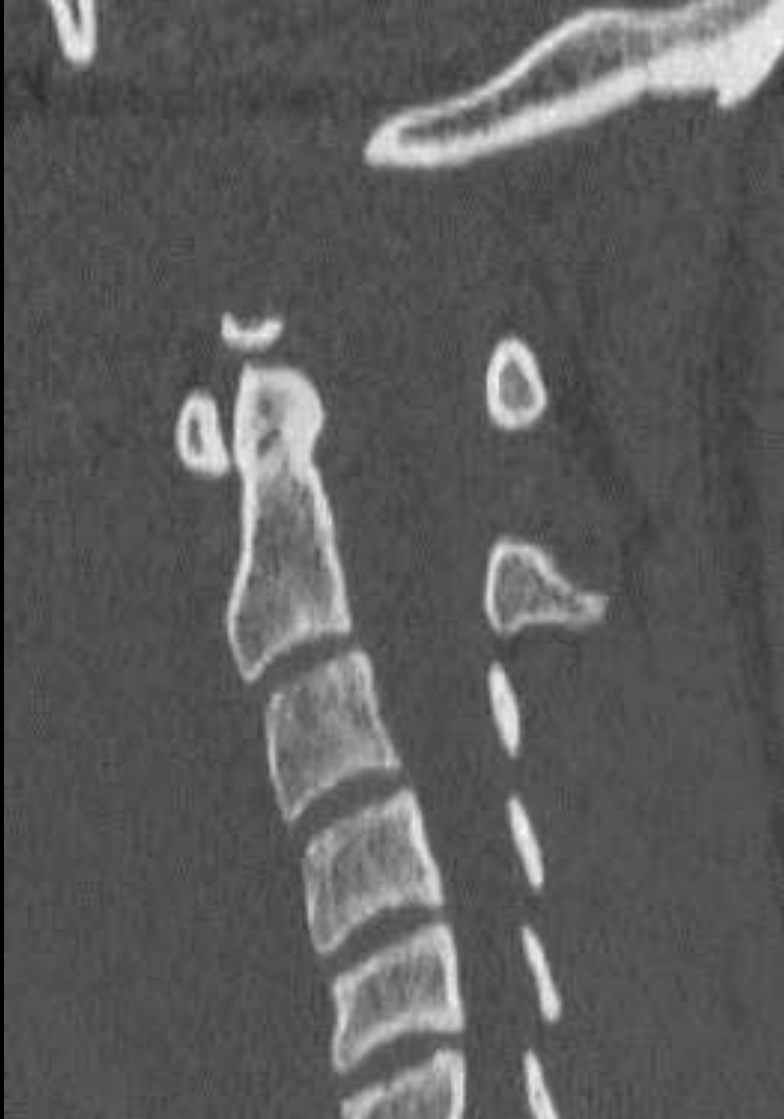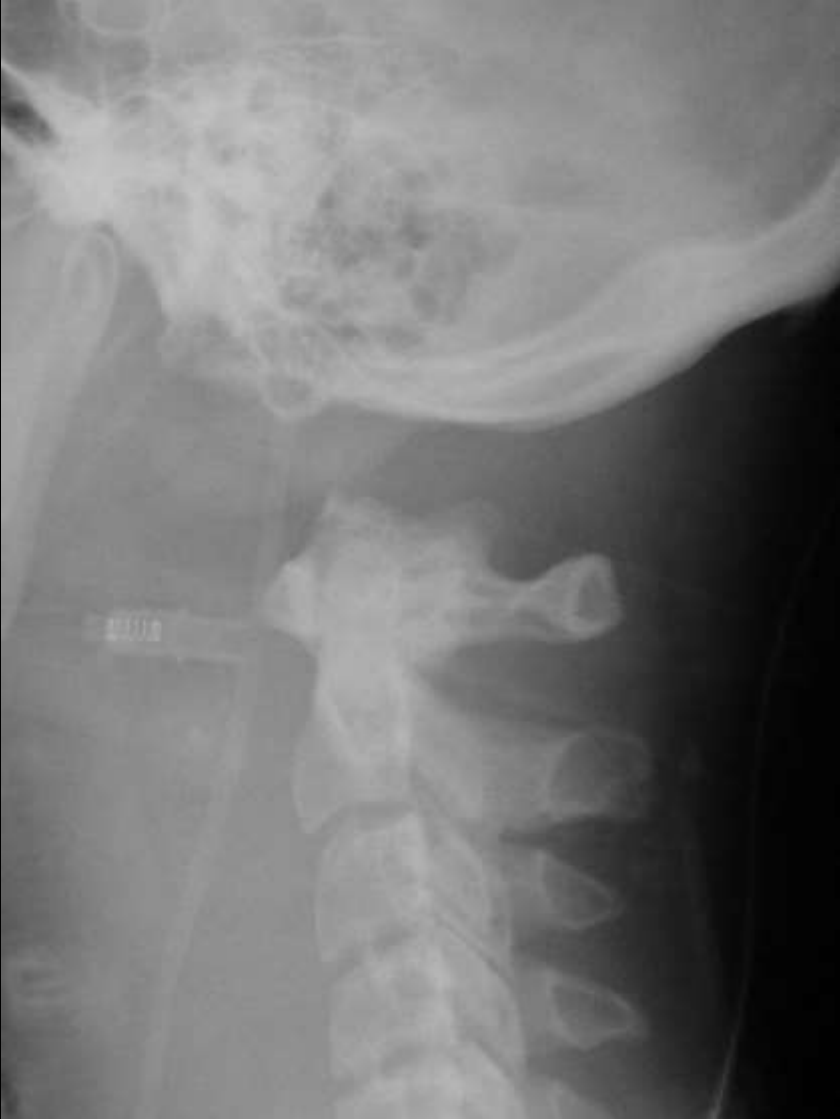Superior Atlanto-Occipital Dislocation



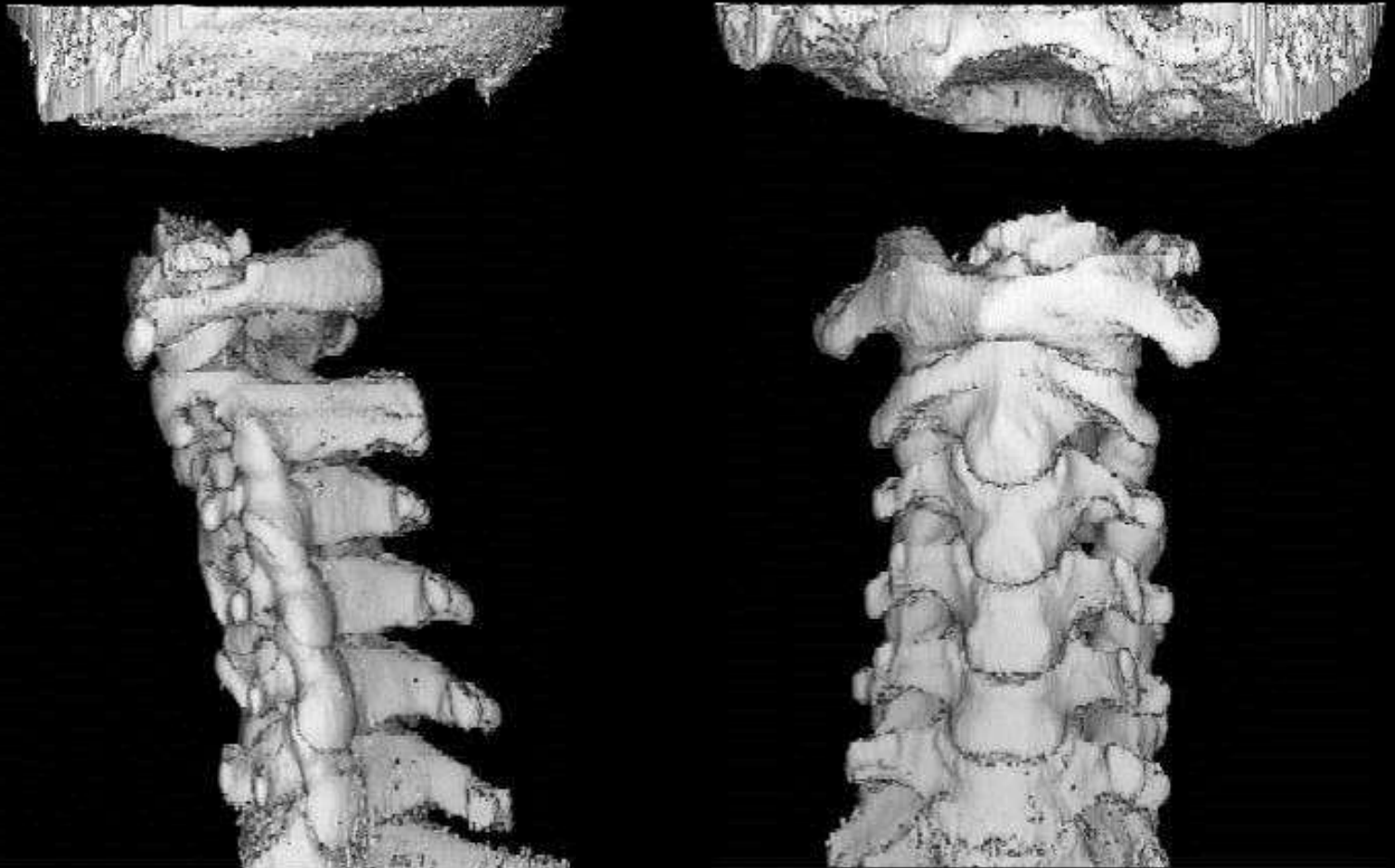
Superior Atlanto-Occipital Fracture Dislocation



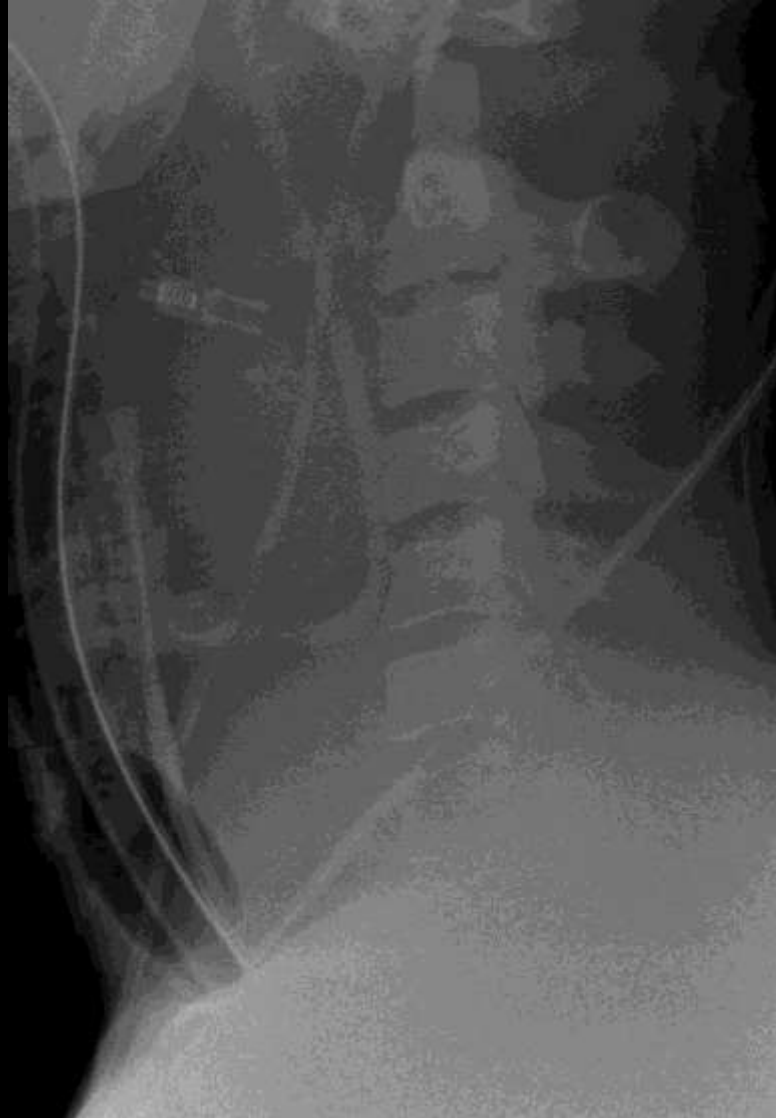Superior Atlanto-Occipital Fracture Dislocation



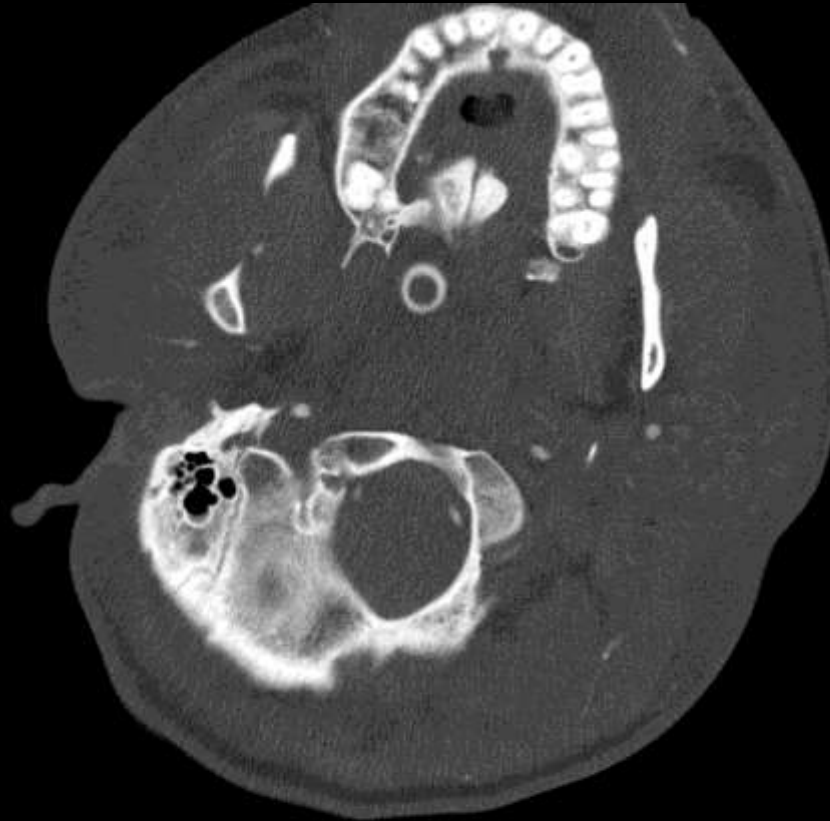Superior Atlanto-Occipital Fracture Dislocation



Atlantoaxial Dislocation

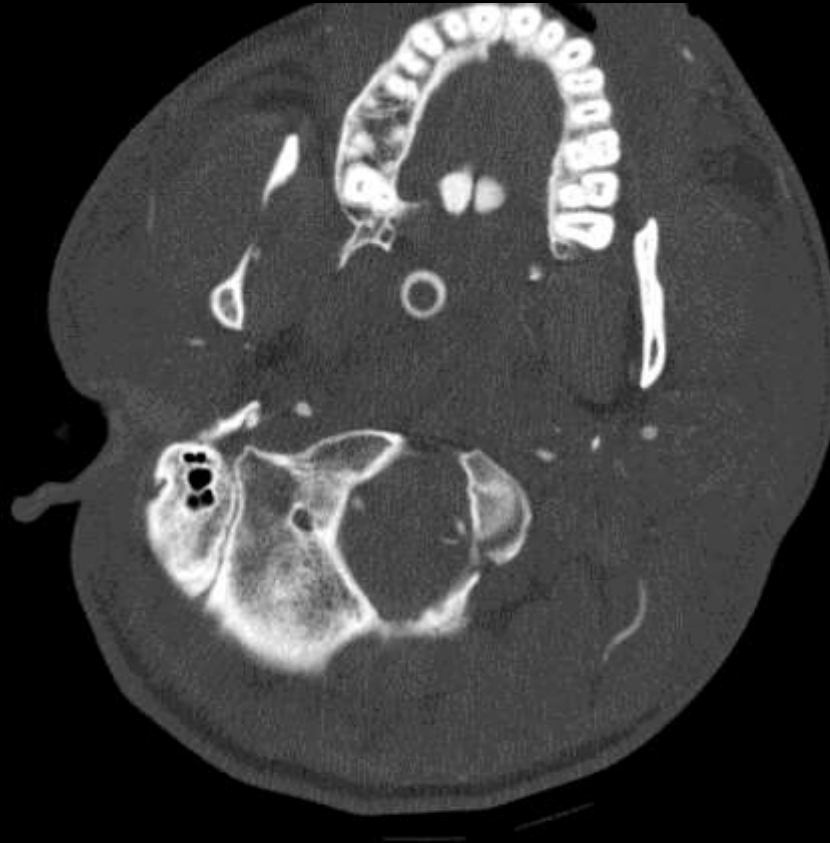

Atlantoaxial Dislocation



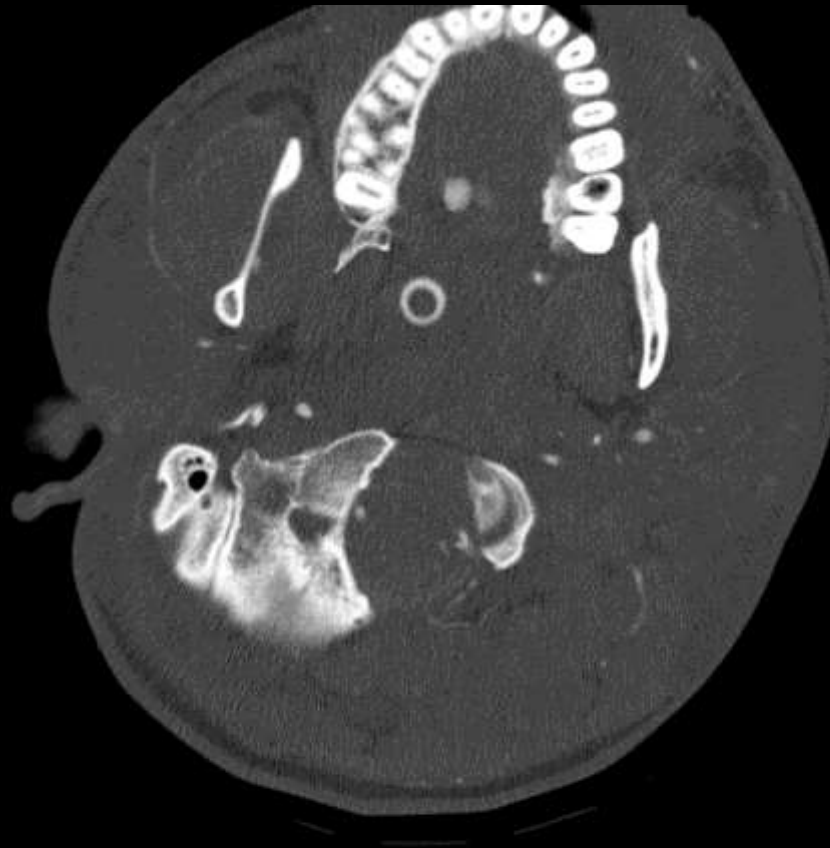W 2000 : L 500

Atlantoaxial Dislocation



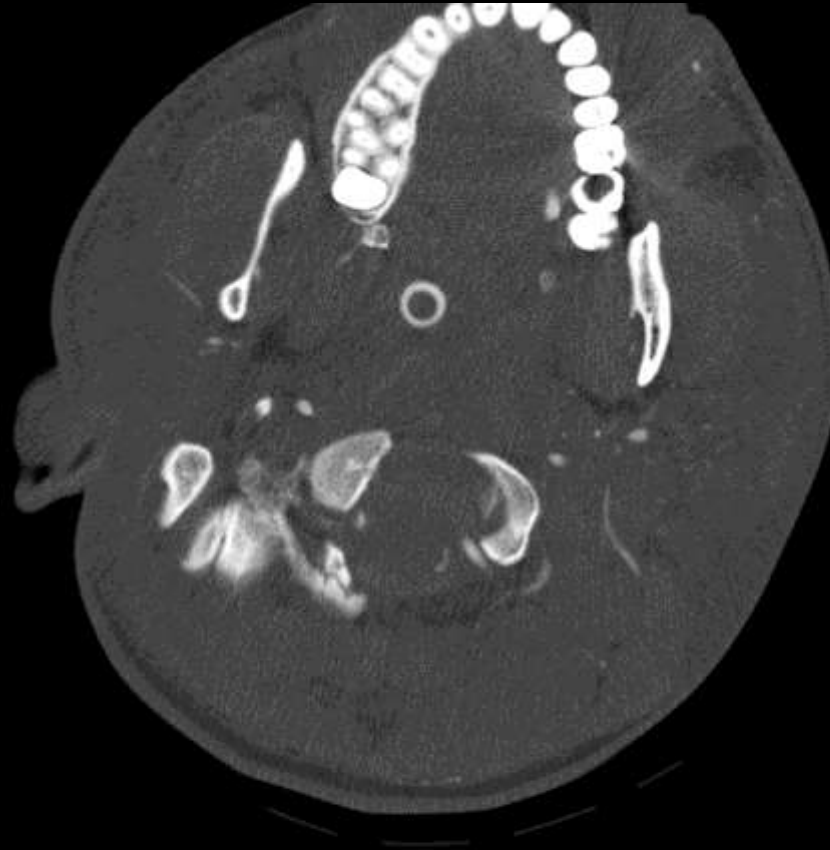W 2000 : L 500

Atlantoaxial Dislocation



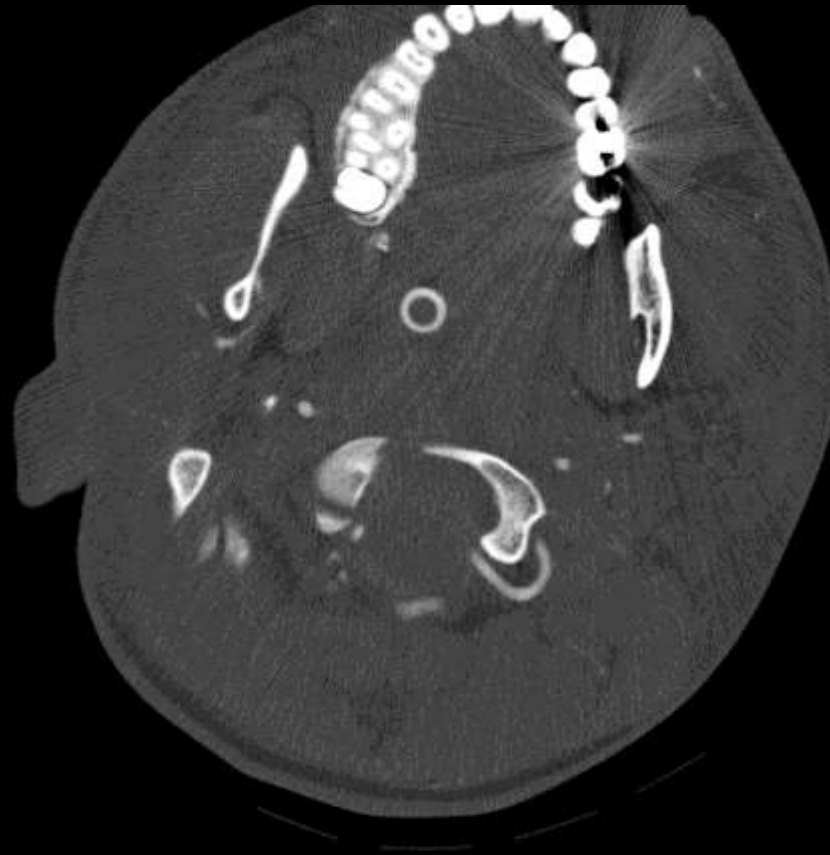
W 2000 : L 500

Atlantoaxial Dislocation



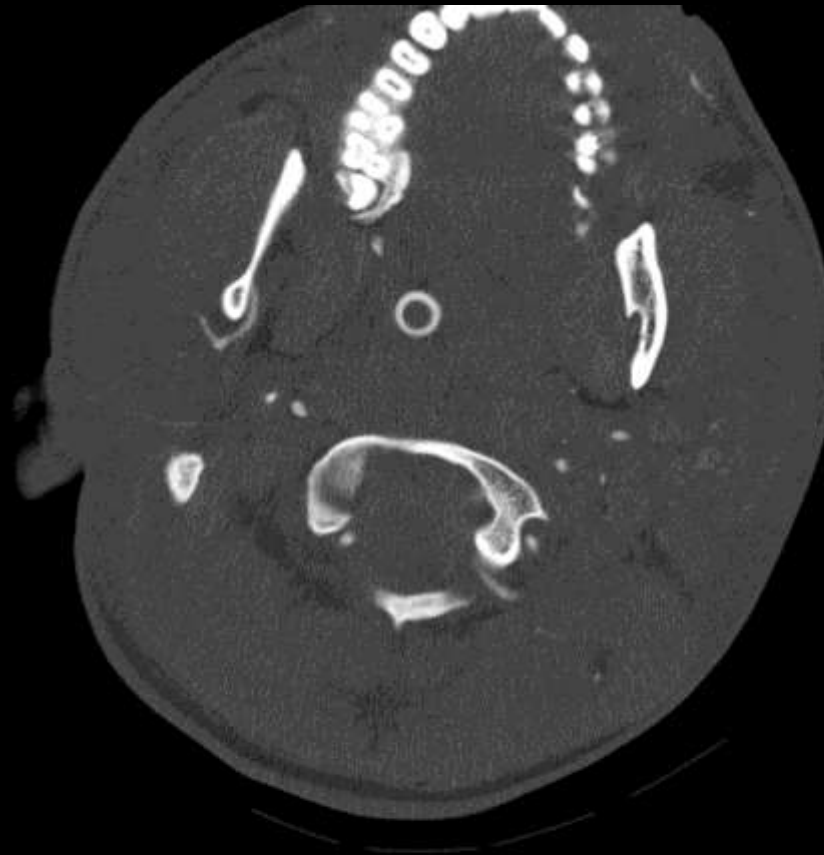
W 2000 : L 500

Atlantoaxial Dislocation



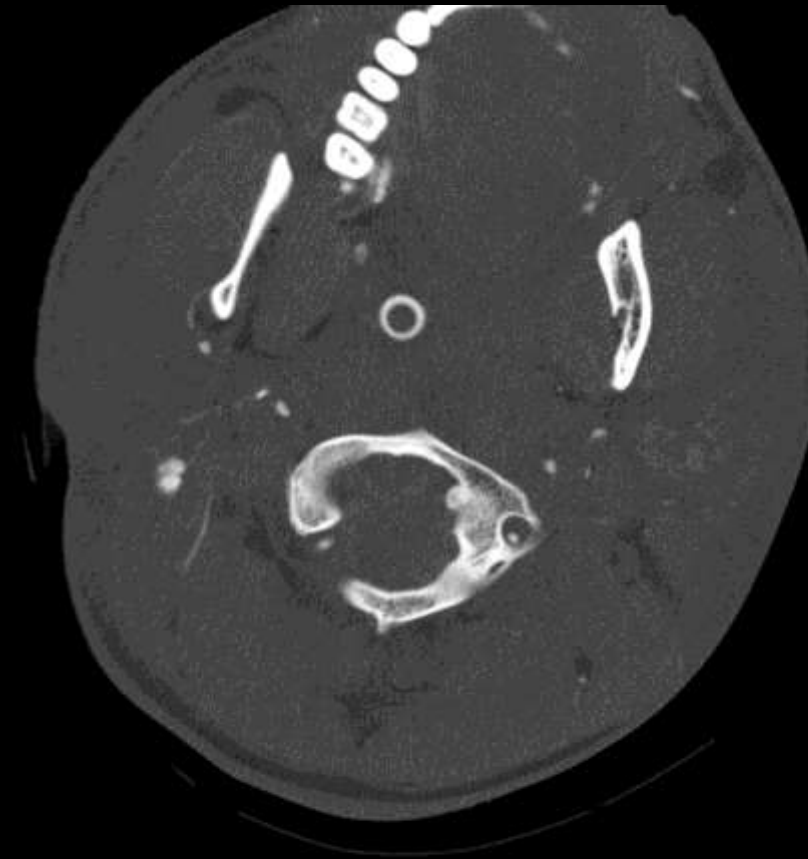
W 2000 : L 500

Atlantoaxial Dislocation



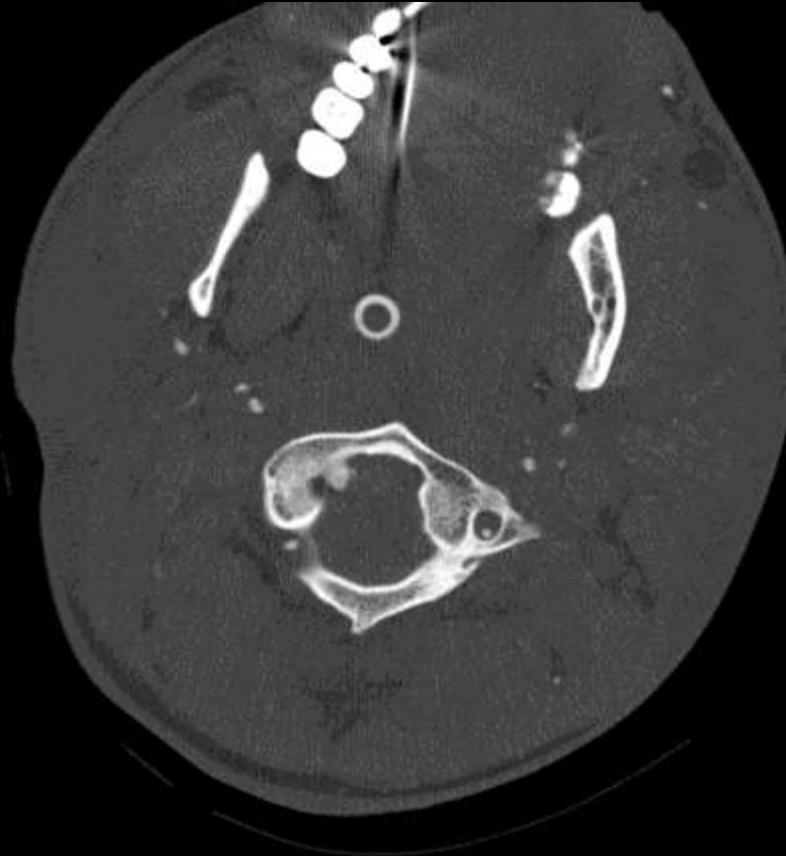W 2000 : L 500

Atlantoaxial Dislocation



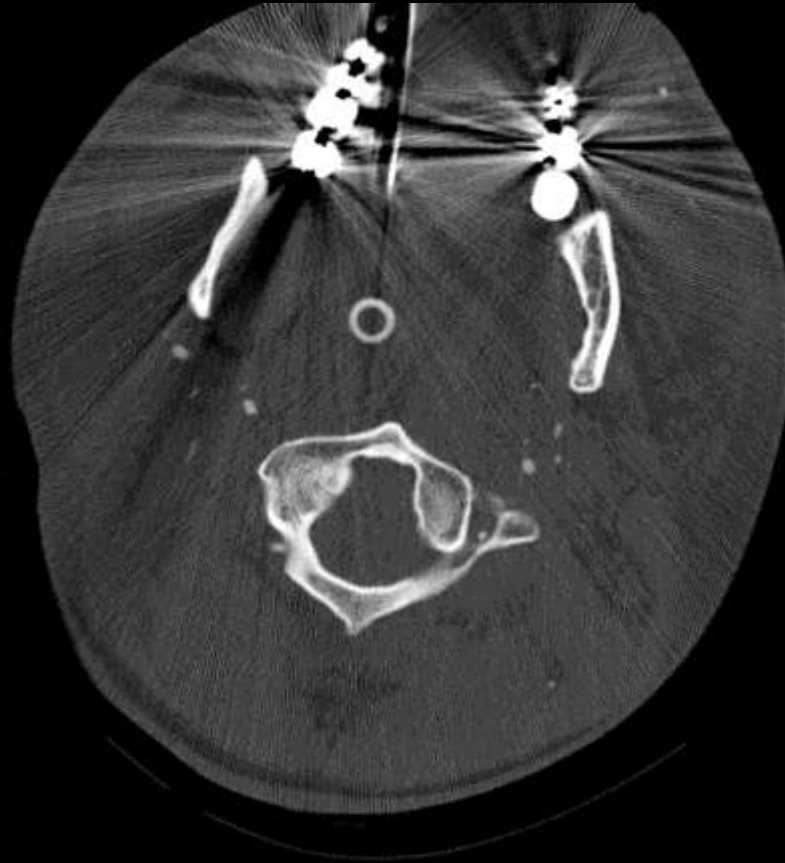W 2000 : L 500

Atlantoaxial Dislocation



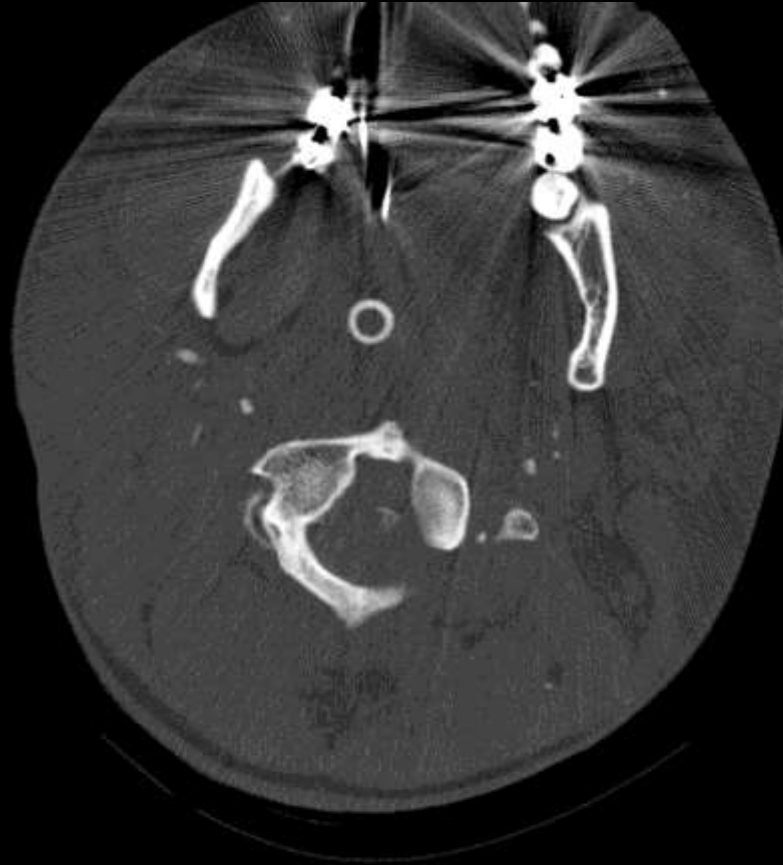
W 2000 : L 500

Atlantoaxial Dislocation



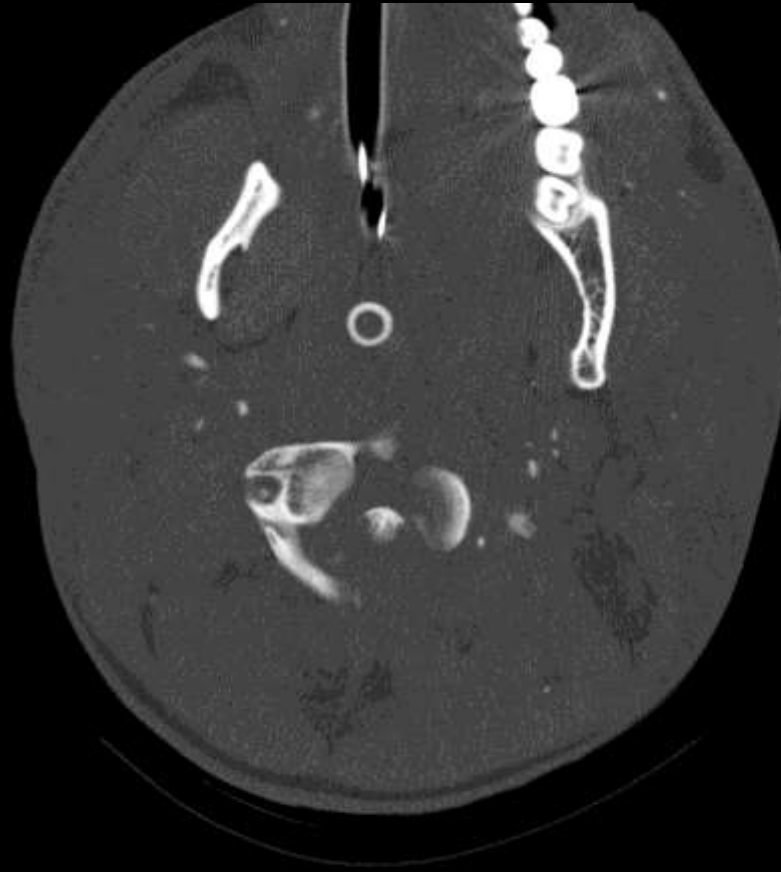
W 2000 : L 500

Atlantoaxial Dislocation



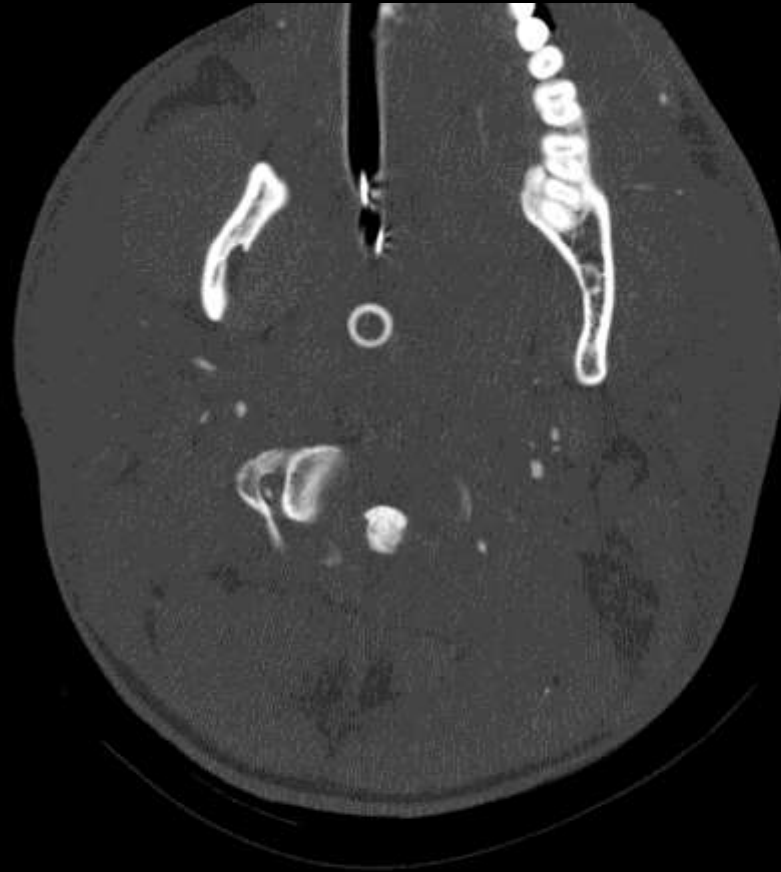W 2000 : L 500

Atlantoaxial Dislocation



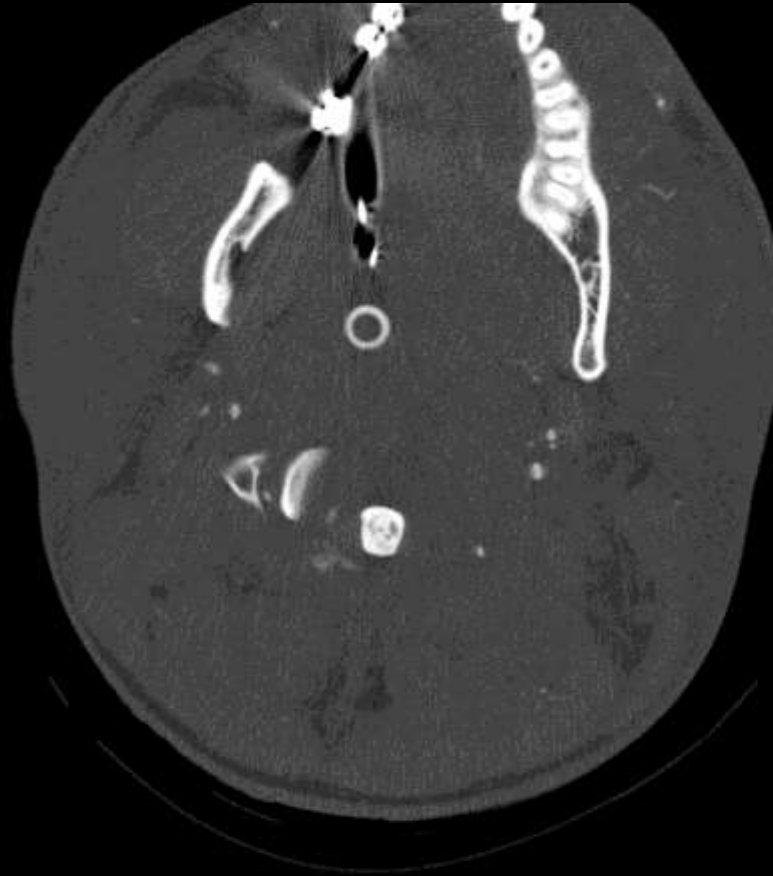W 2000 : L 500

Atlantoaxial Dislocation



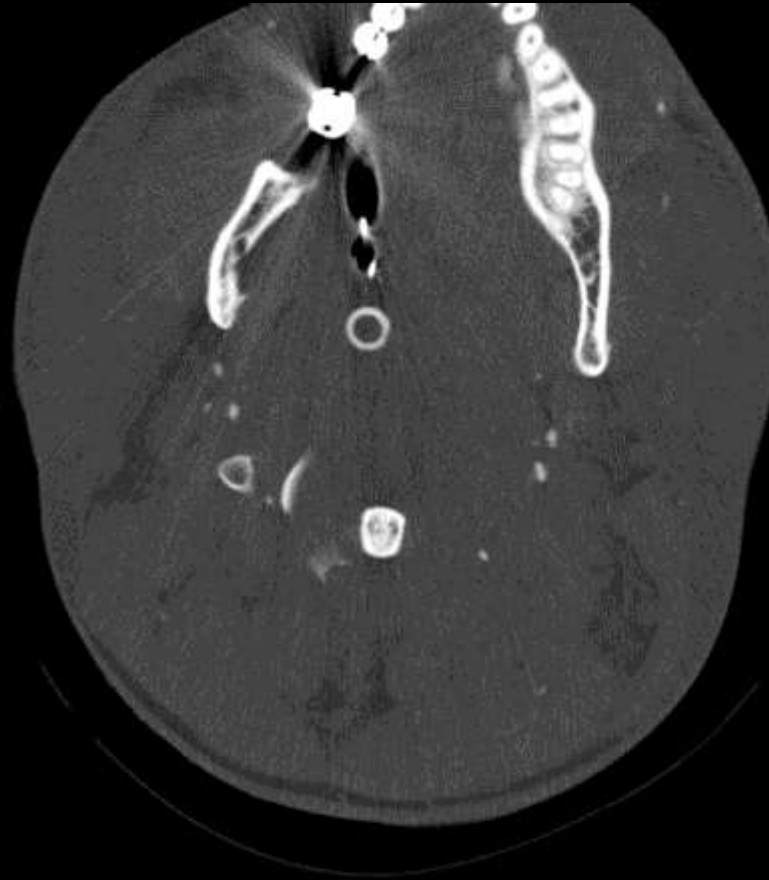W 2000 : L 500

Atlantoaxial Dislocation



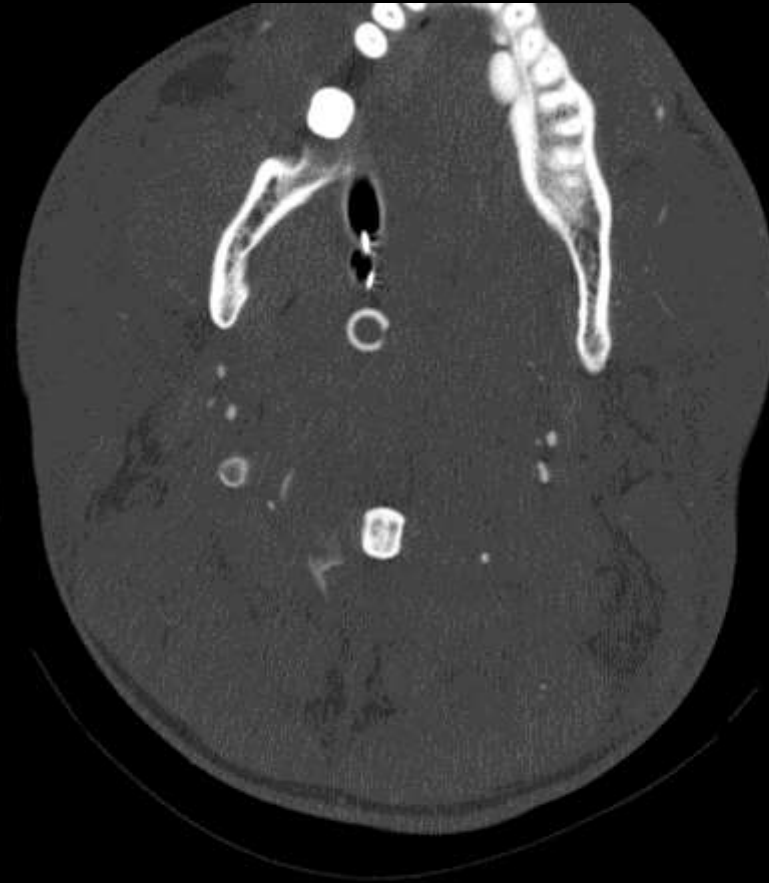W 2000 : L 500

Atlantoaxial Dislocation



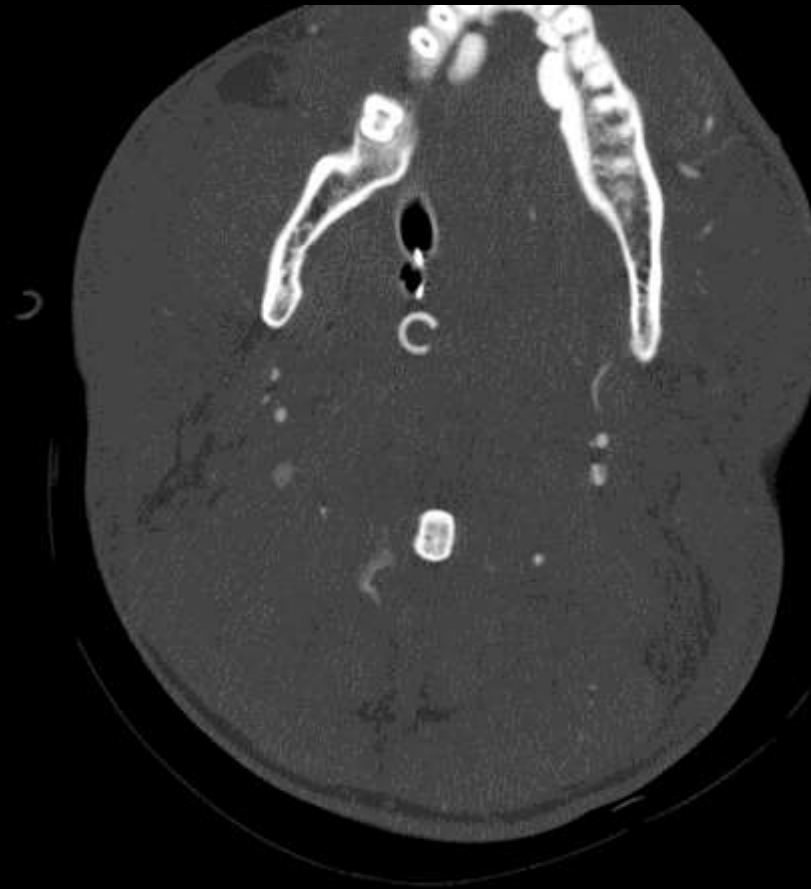
W 2000 : L 500

Atlantoaxial Dislocation



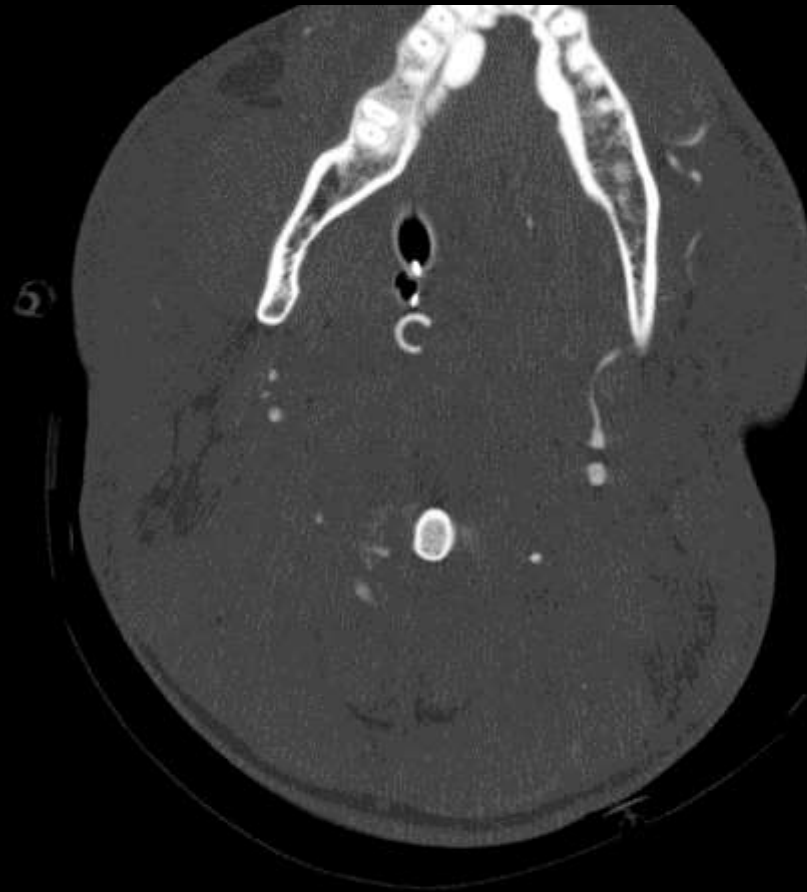W 2000 : L 500

Atlantoaxial Dislocation



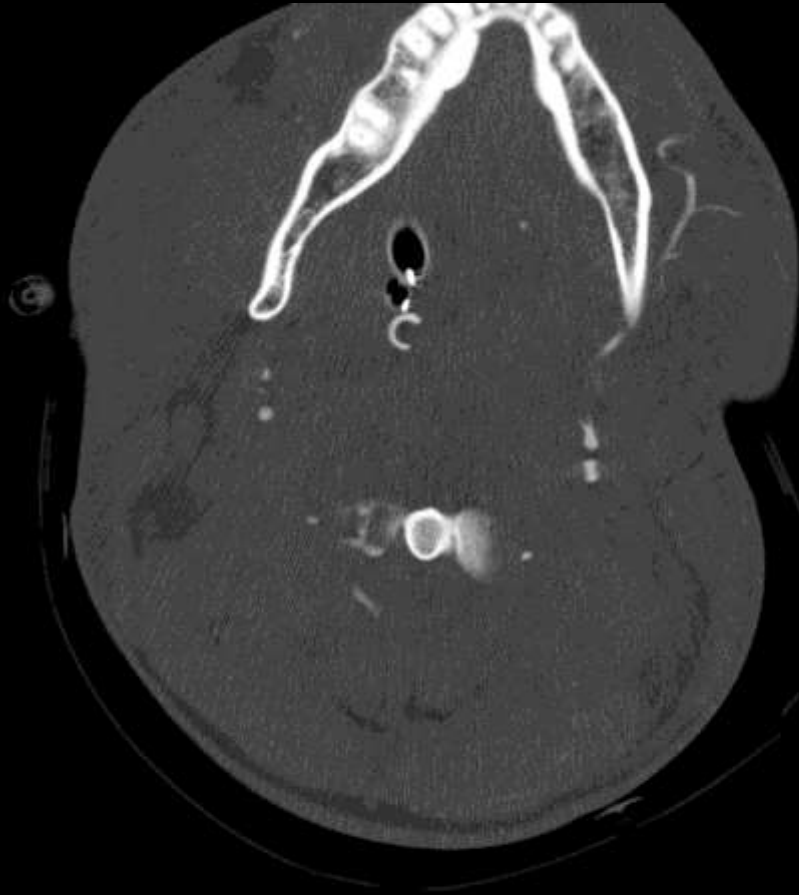W 2000 : L 500

Atlantoaxial Dislocation



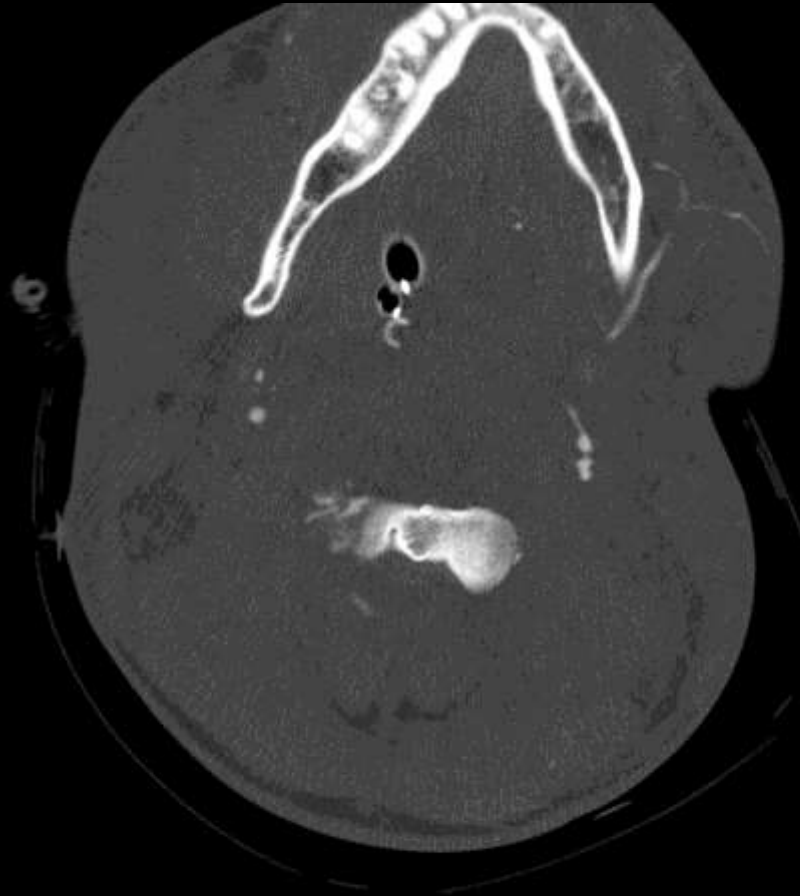W 2000 : L 500

Atlantoaxial Dislocation



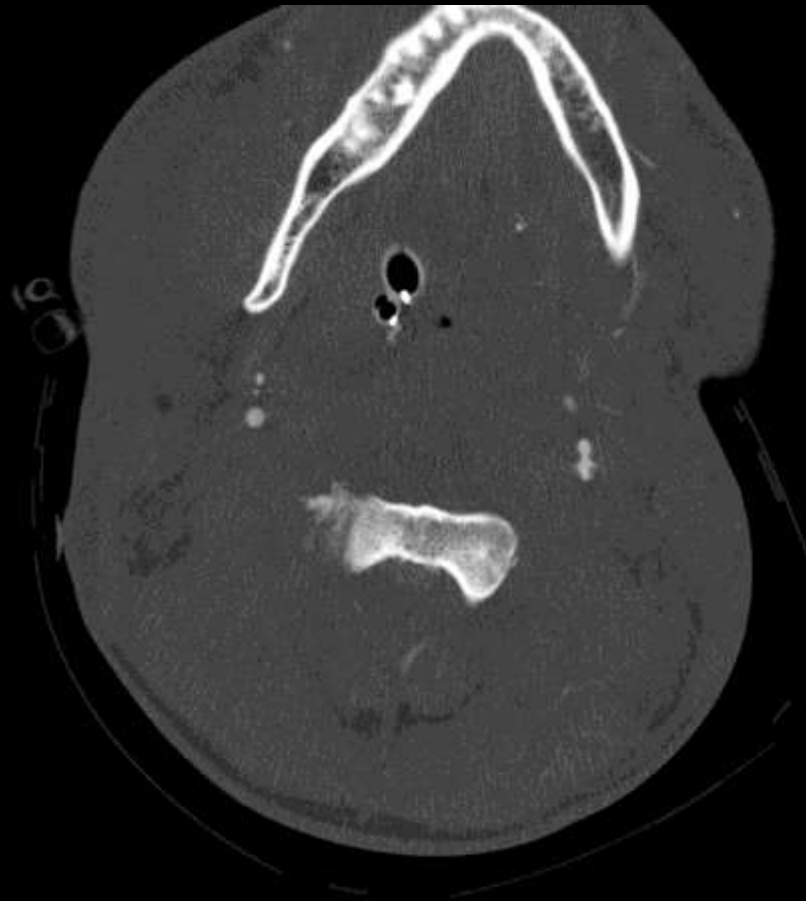W 2000 : L 500

Atlantoaxial Dislocation



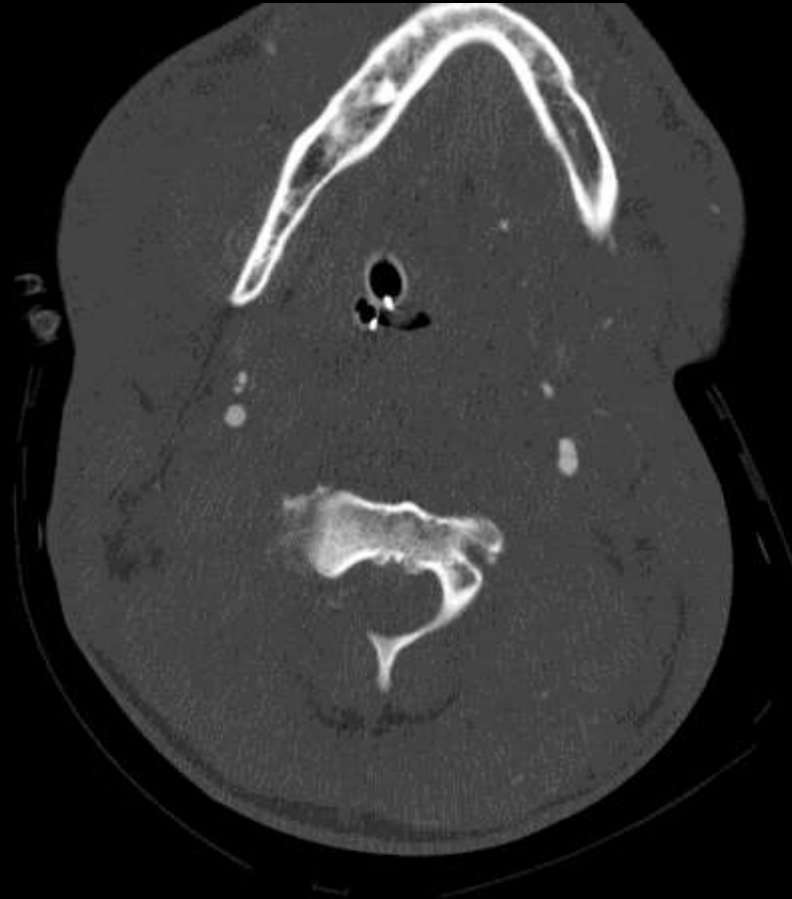W 2000 : L 500

Atlantoaxial Dislocation



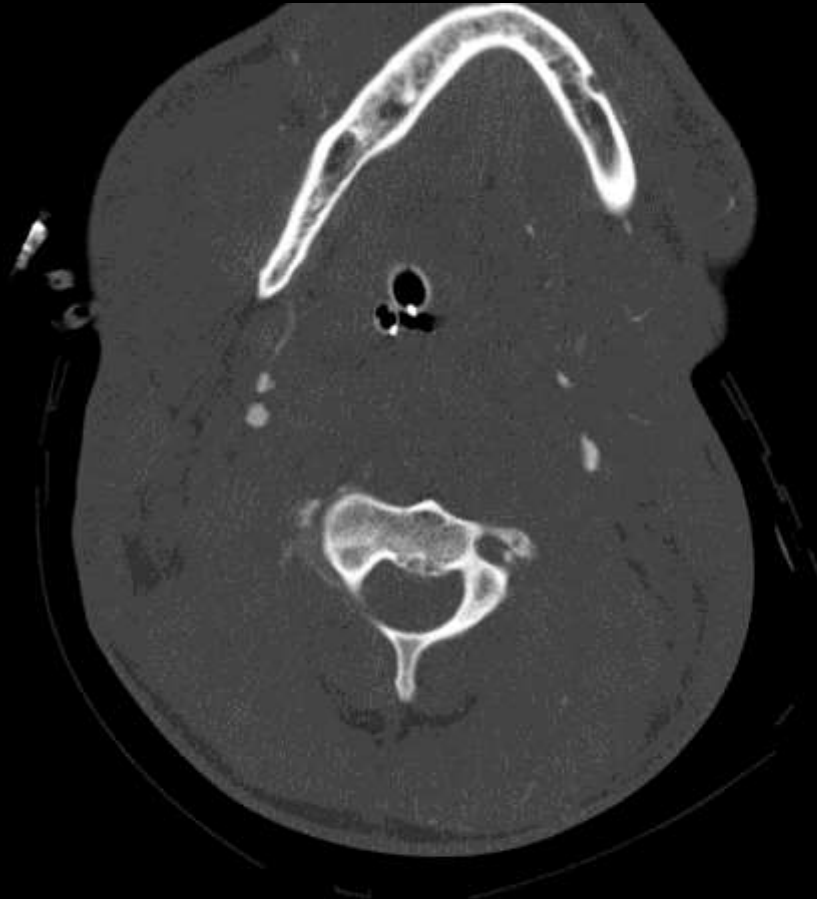W 2000 : L 500

Atlantoaxial Dislocation



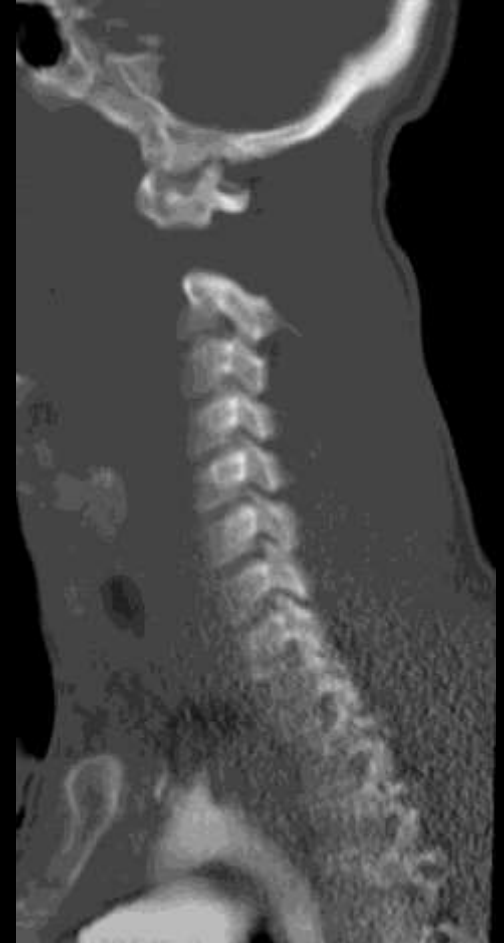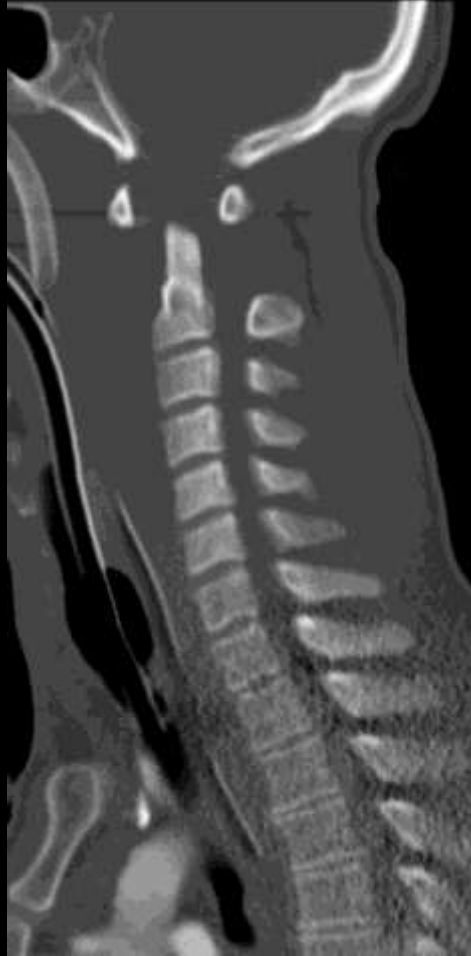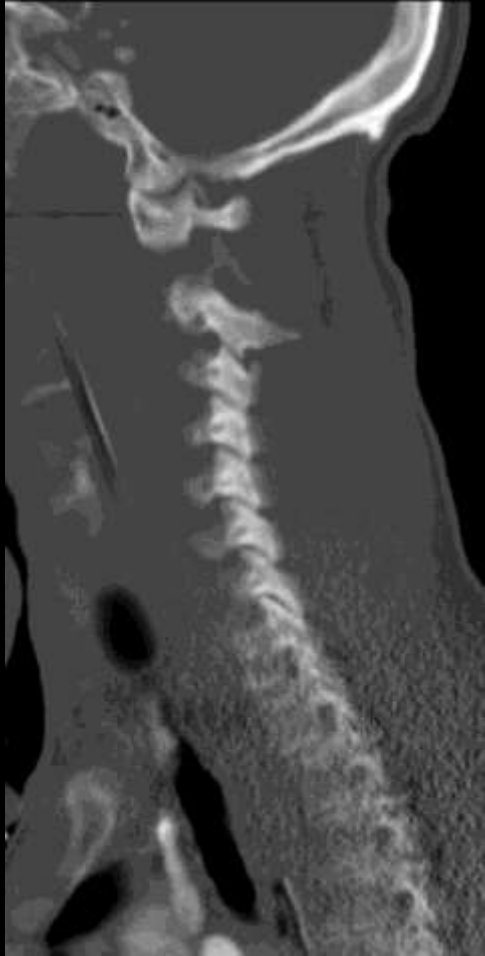W 2000 : L 500

Atlantoaxial Dislocation

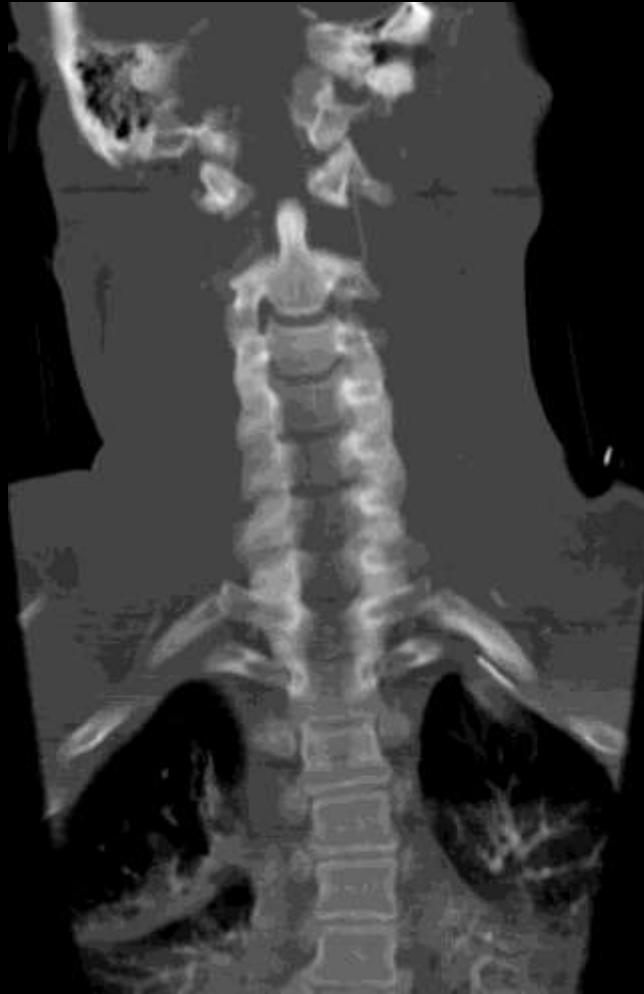

W 2000 : L 500

Atlantoaxial Dislocation

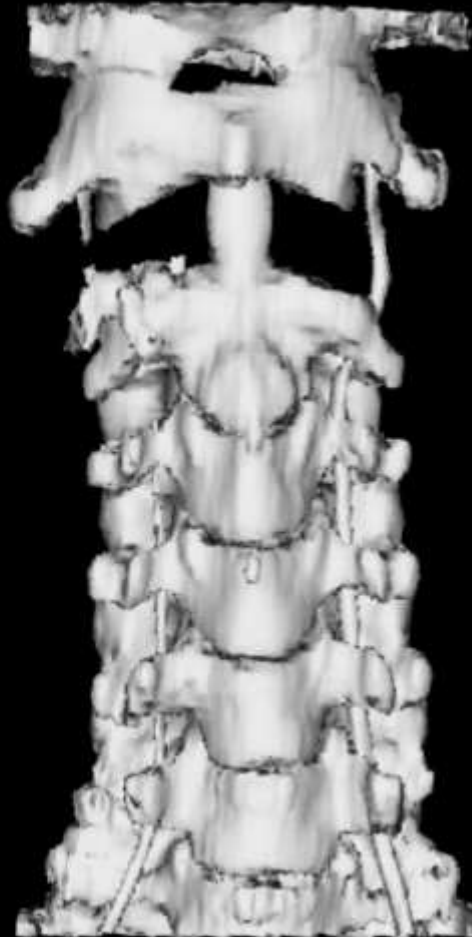

Atlantoaxial Dislocation



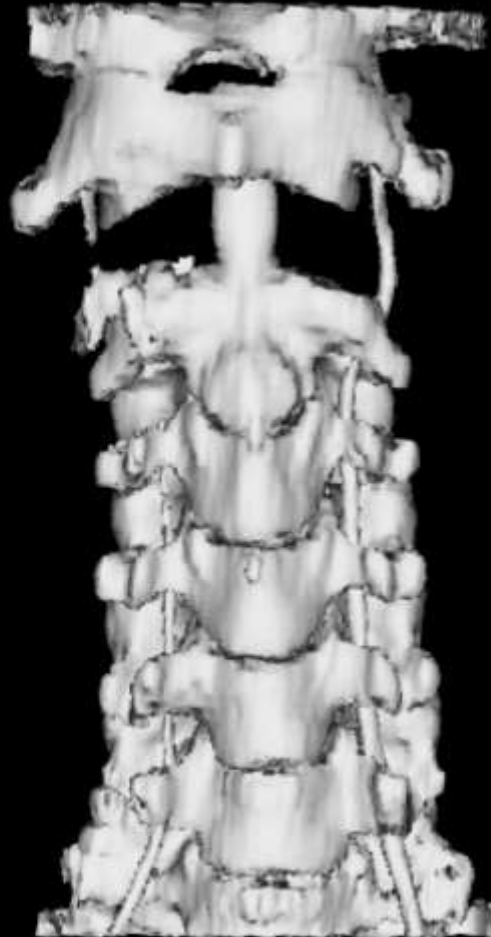Atlantoaxial Dislocation

2



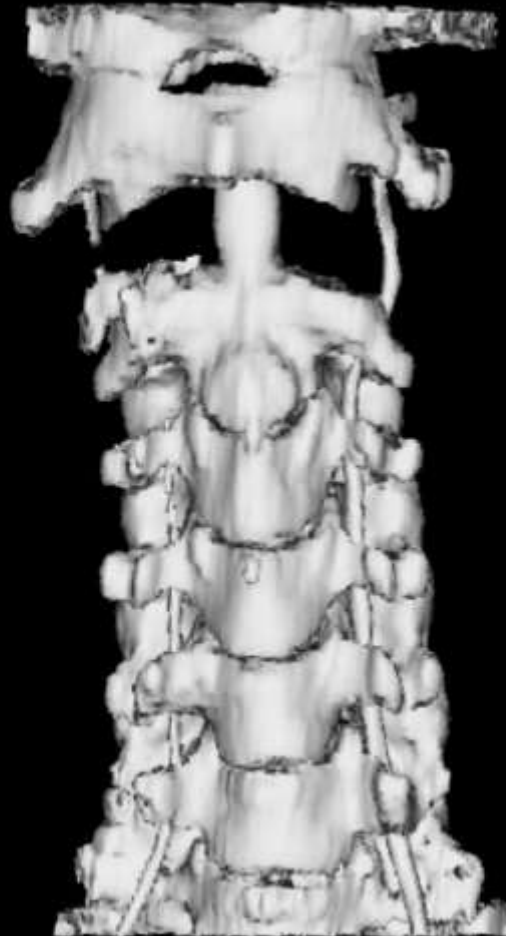
Atlantoaxial Dislocation

3



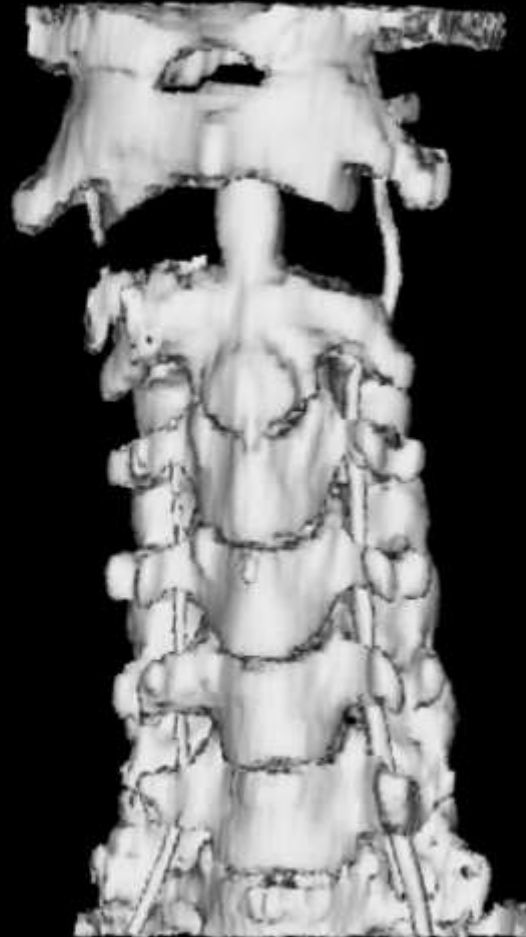Atlantoaxial Dislocation

4



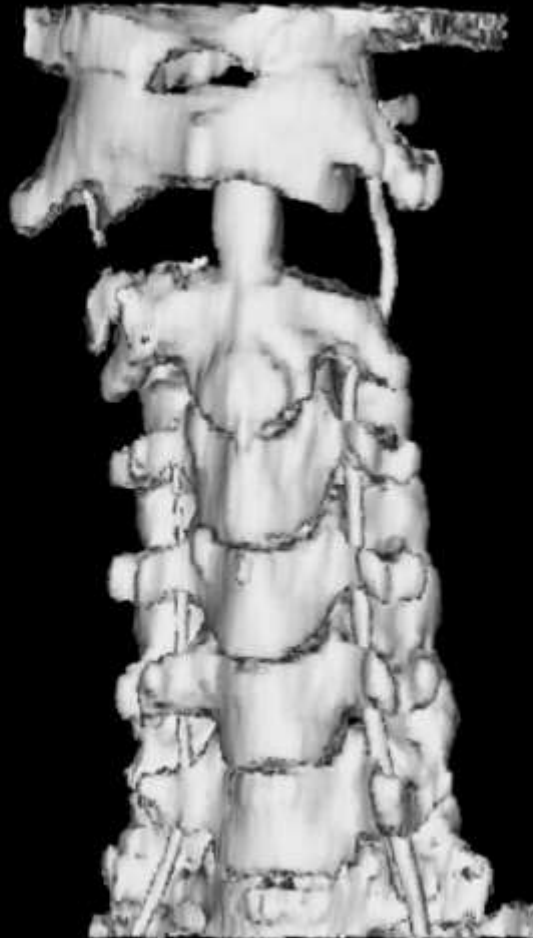
Atlantoaxial Dislocation

5



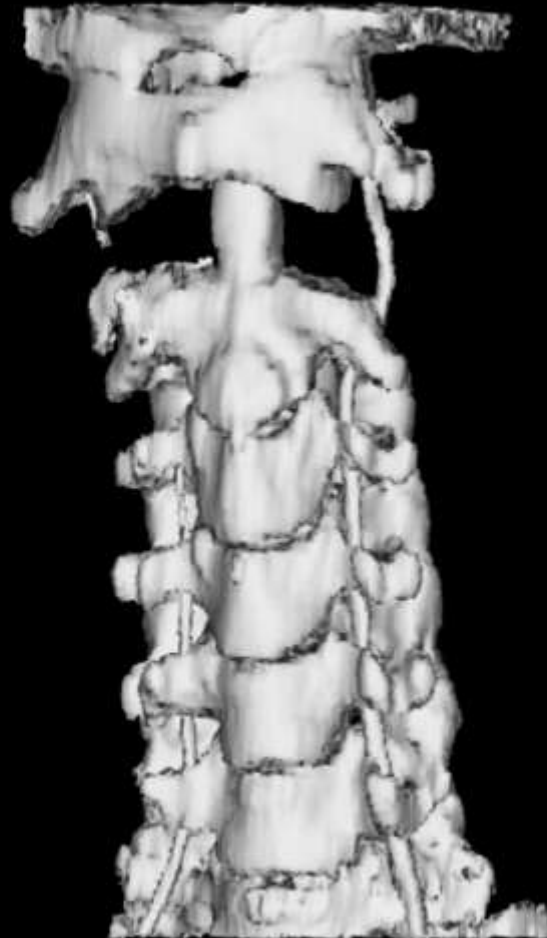
Atlantoaxial Dislocation

6



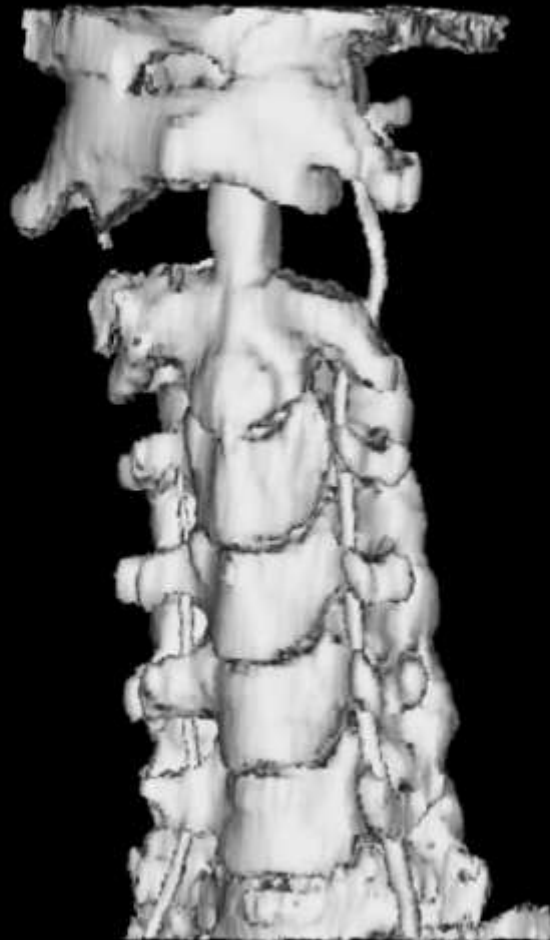
Atlantoaxial Dislocation

7



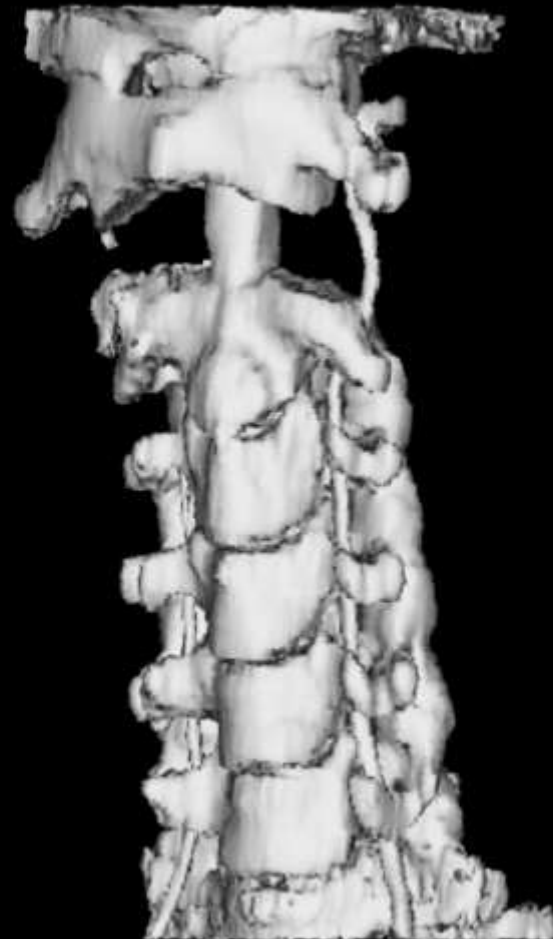
Atlantoaxial Dislocation

8



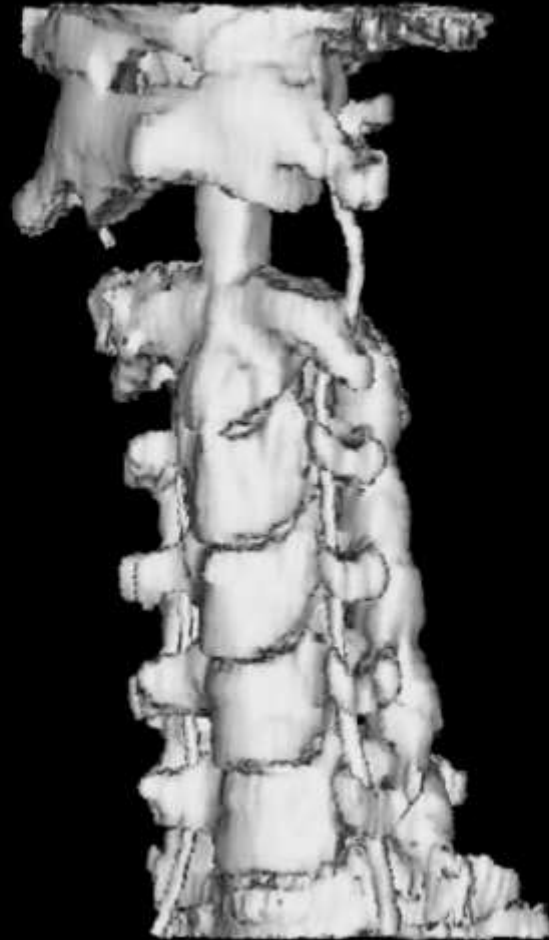
Atlantoaxial Dislocation

9



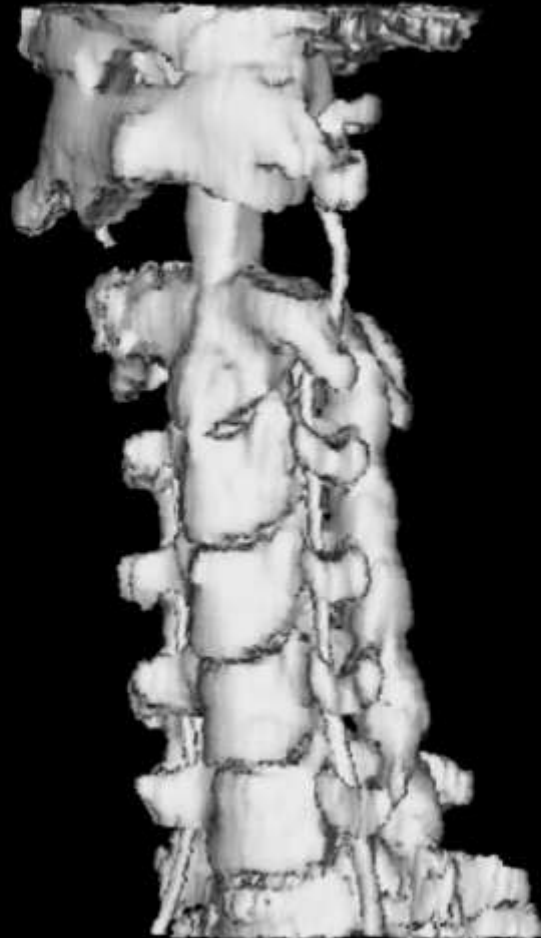
Atlantoaxial Dislocation

10



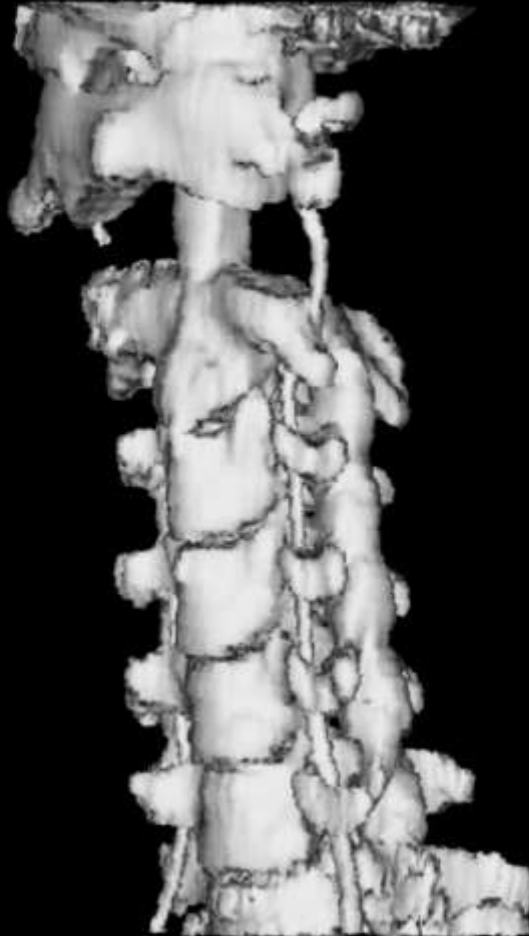
Atlantoaxial Dislocation

11



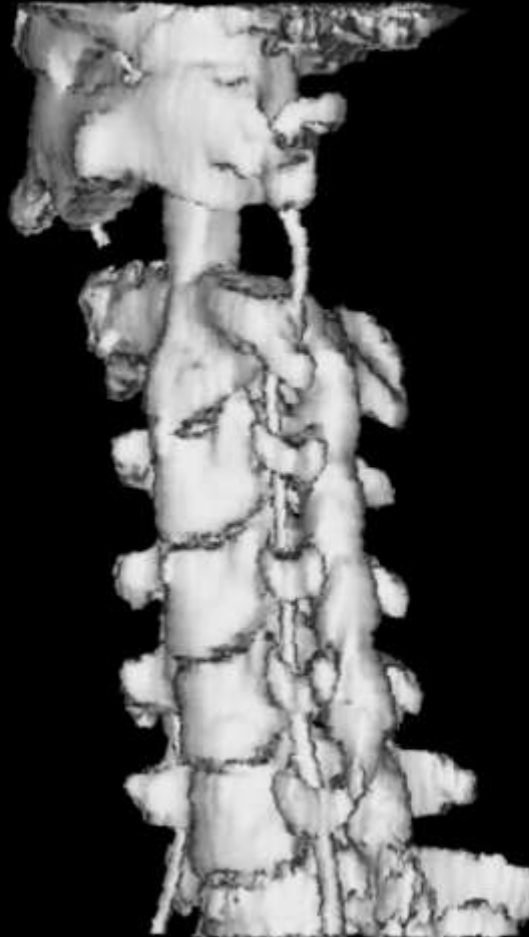
Atlantoaxial Dislocation

12



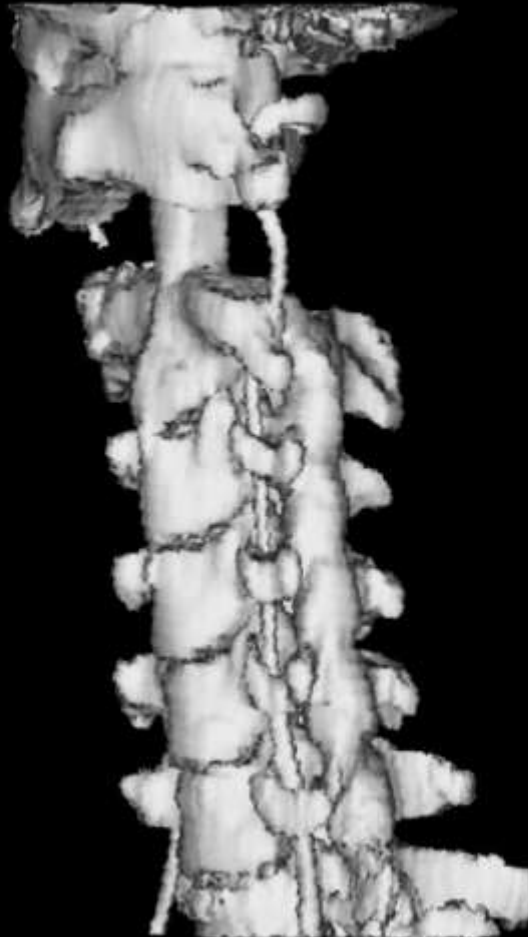
Atlantoaxial Dislocation

13



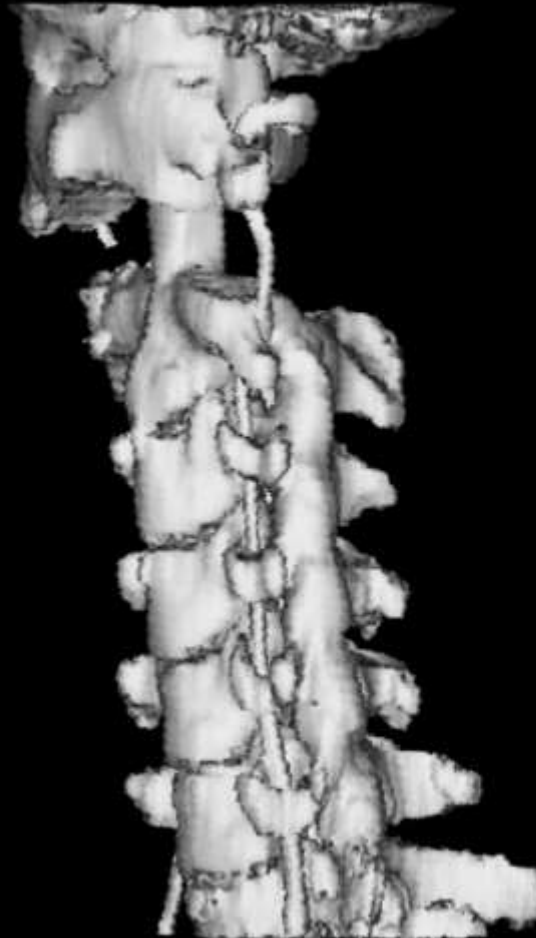
Atlantoaxial Dislocation

14



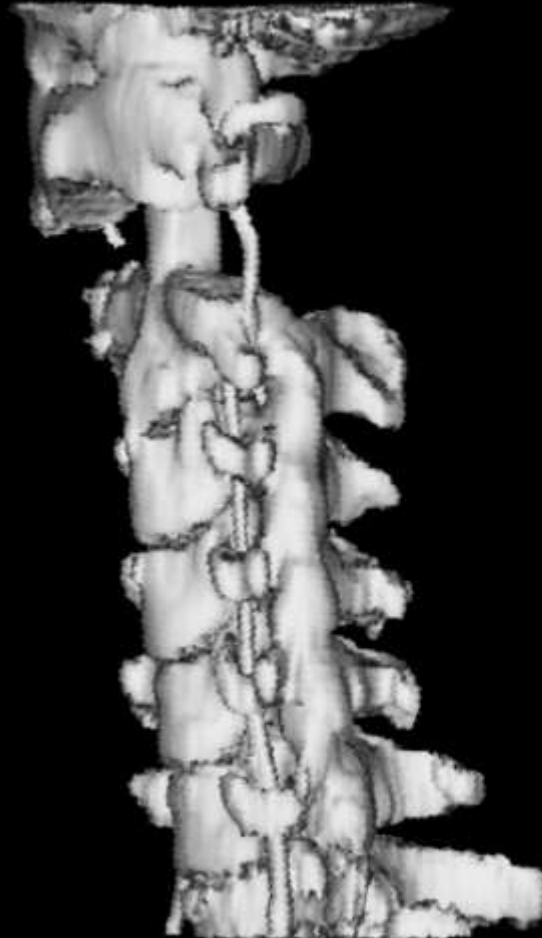
Atlantoaxial Dislocation

15



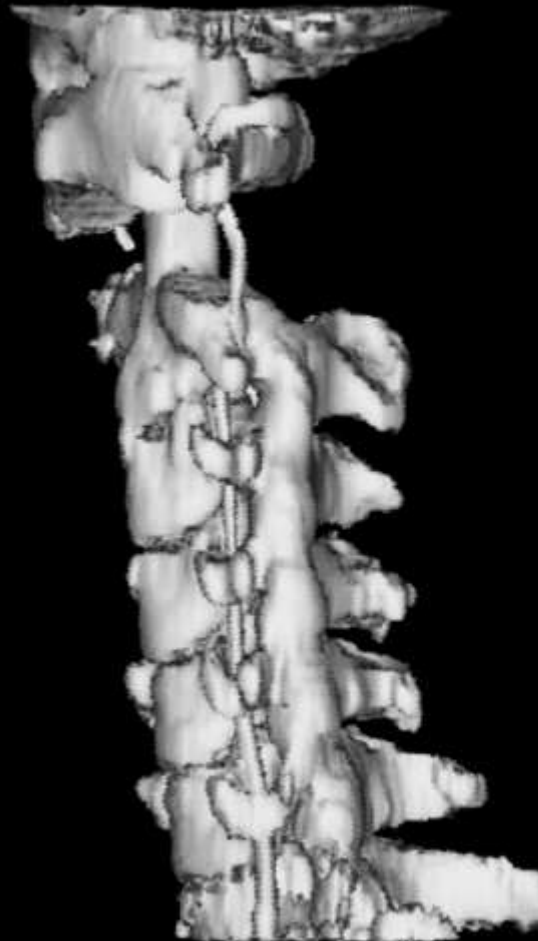Atlantoaxial Dislocation

16



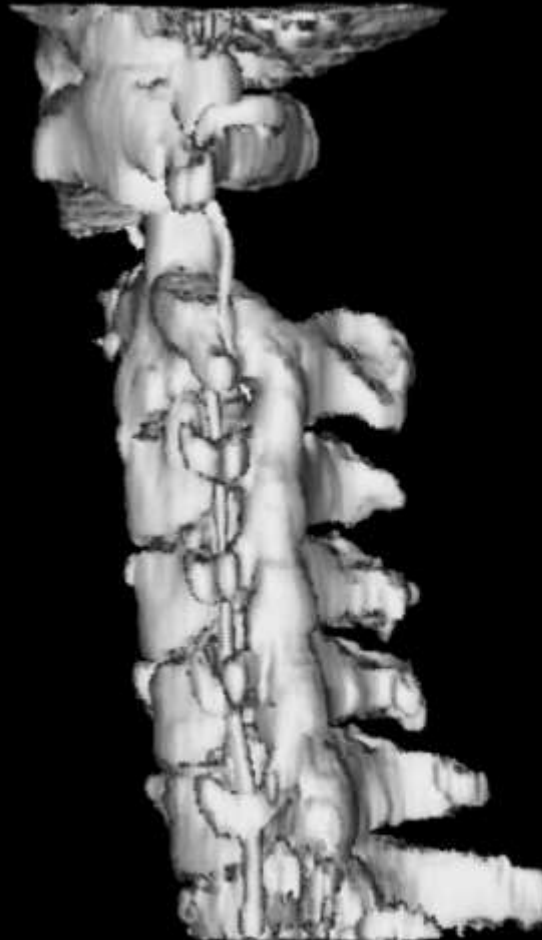Atlantoaxial Dislocation

17



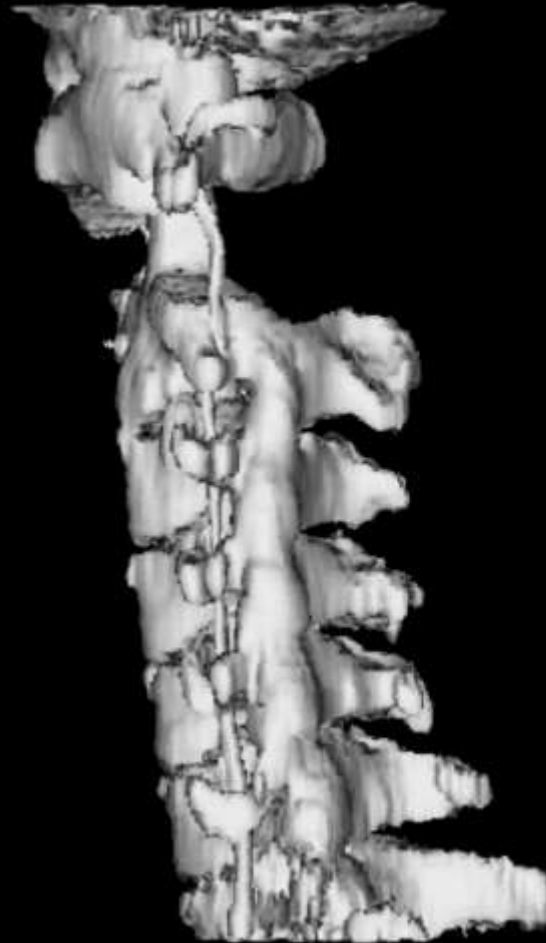Atlantoaxial Dislocation

18



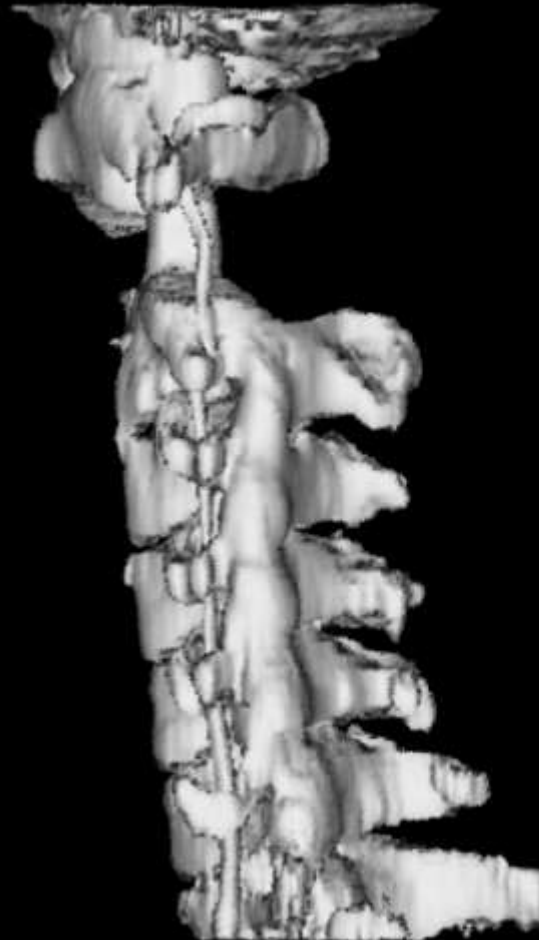
Atlantoaxial Dislocation

19



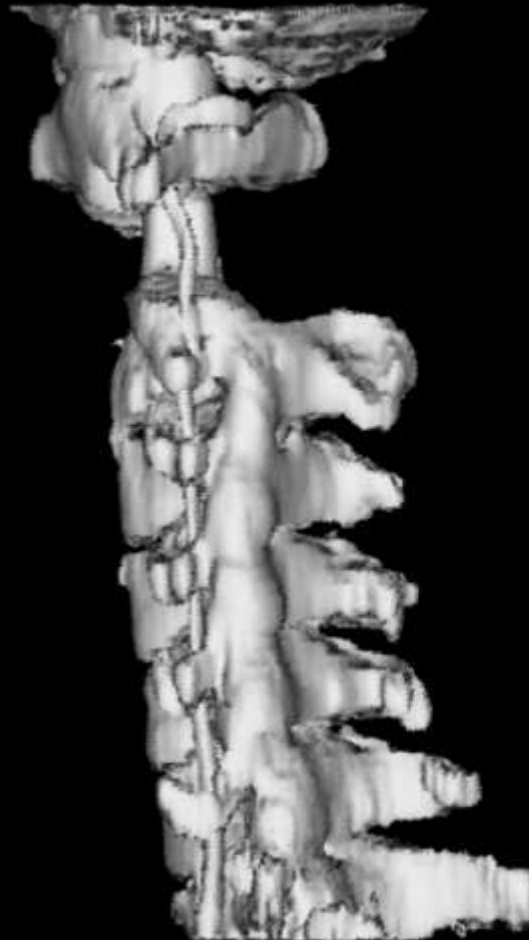Atlantoaxial Dislocation

20



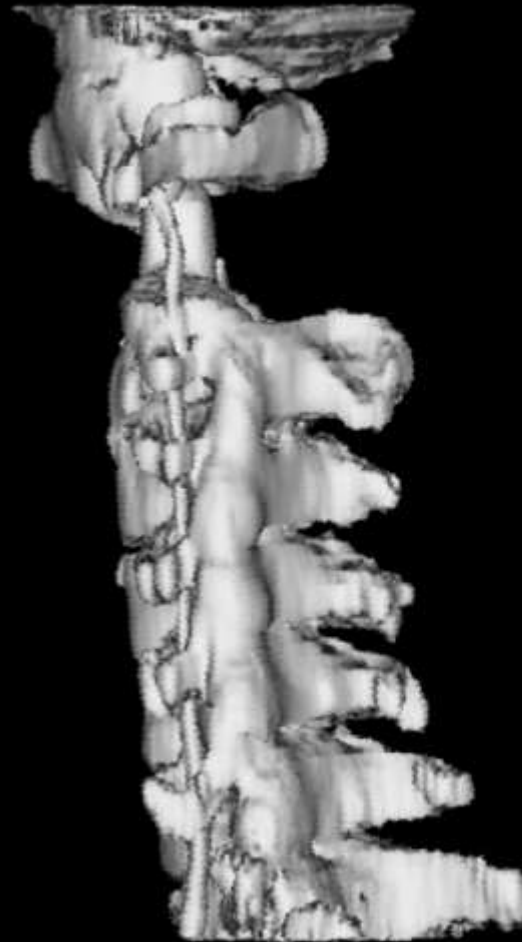
Atlantoaxial Dislocation

21



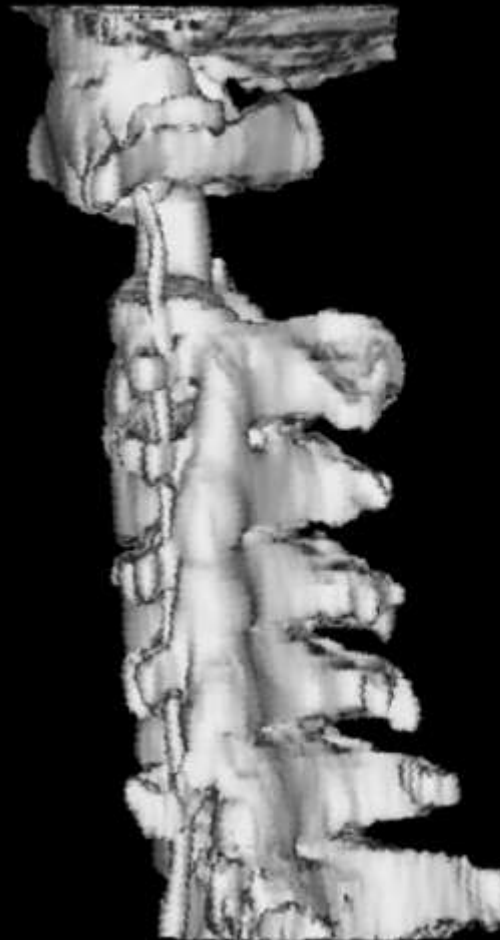
Atlantoaxial Dislocation

22



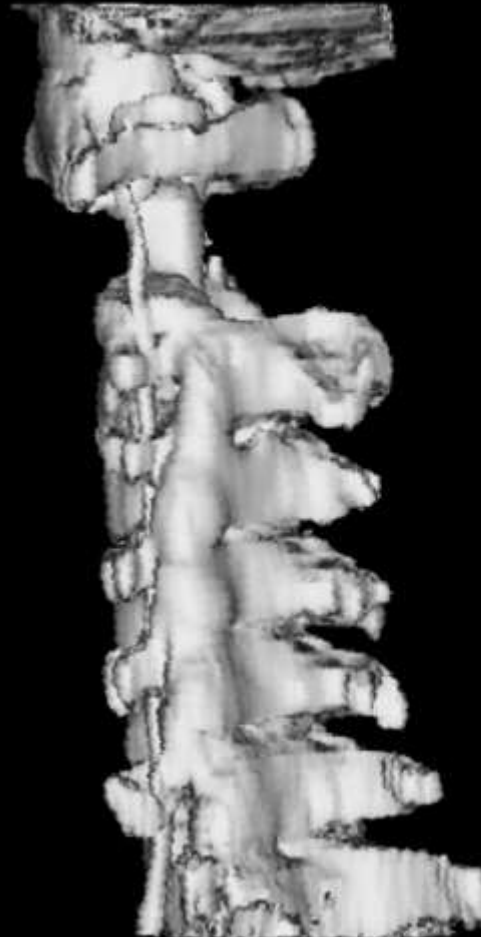Atlantoaxial Dislocation

23



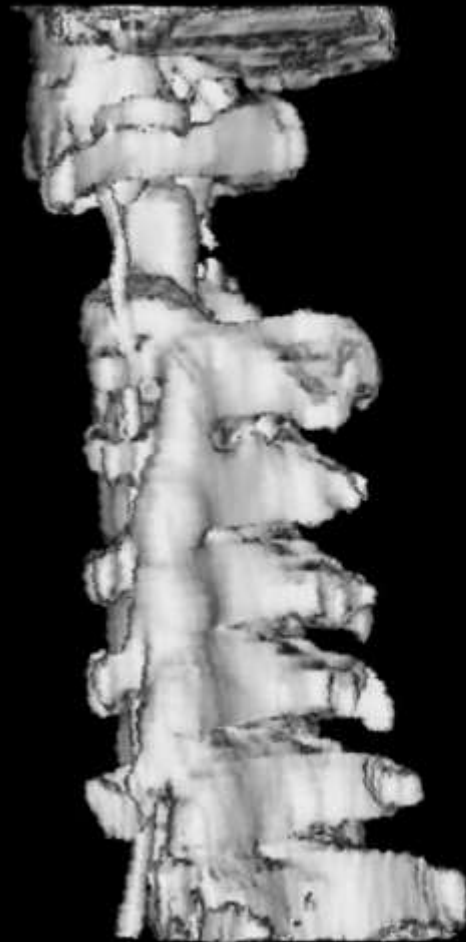Atlantoaxial Dislocation

24



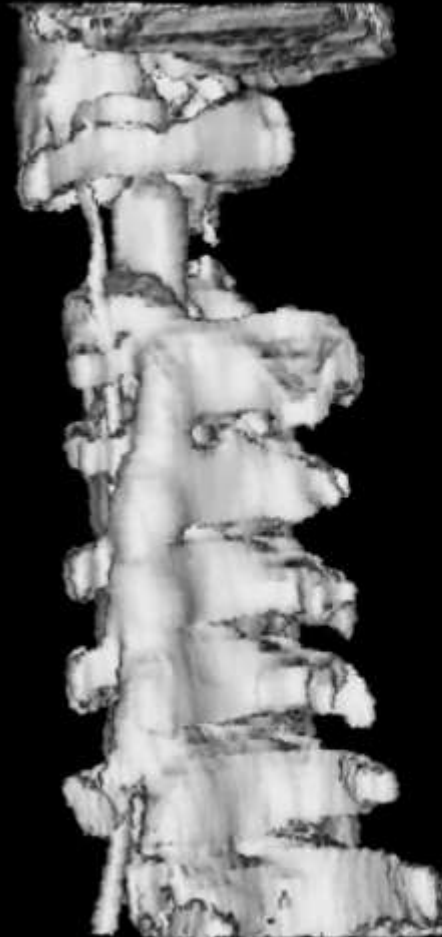Atlantoaxial Dislocation

25



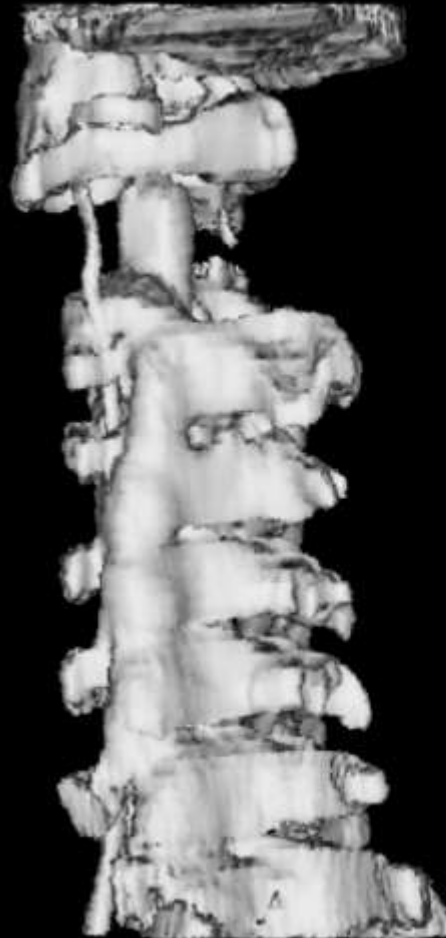Atlantoaxial Dislocation

26

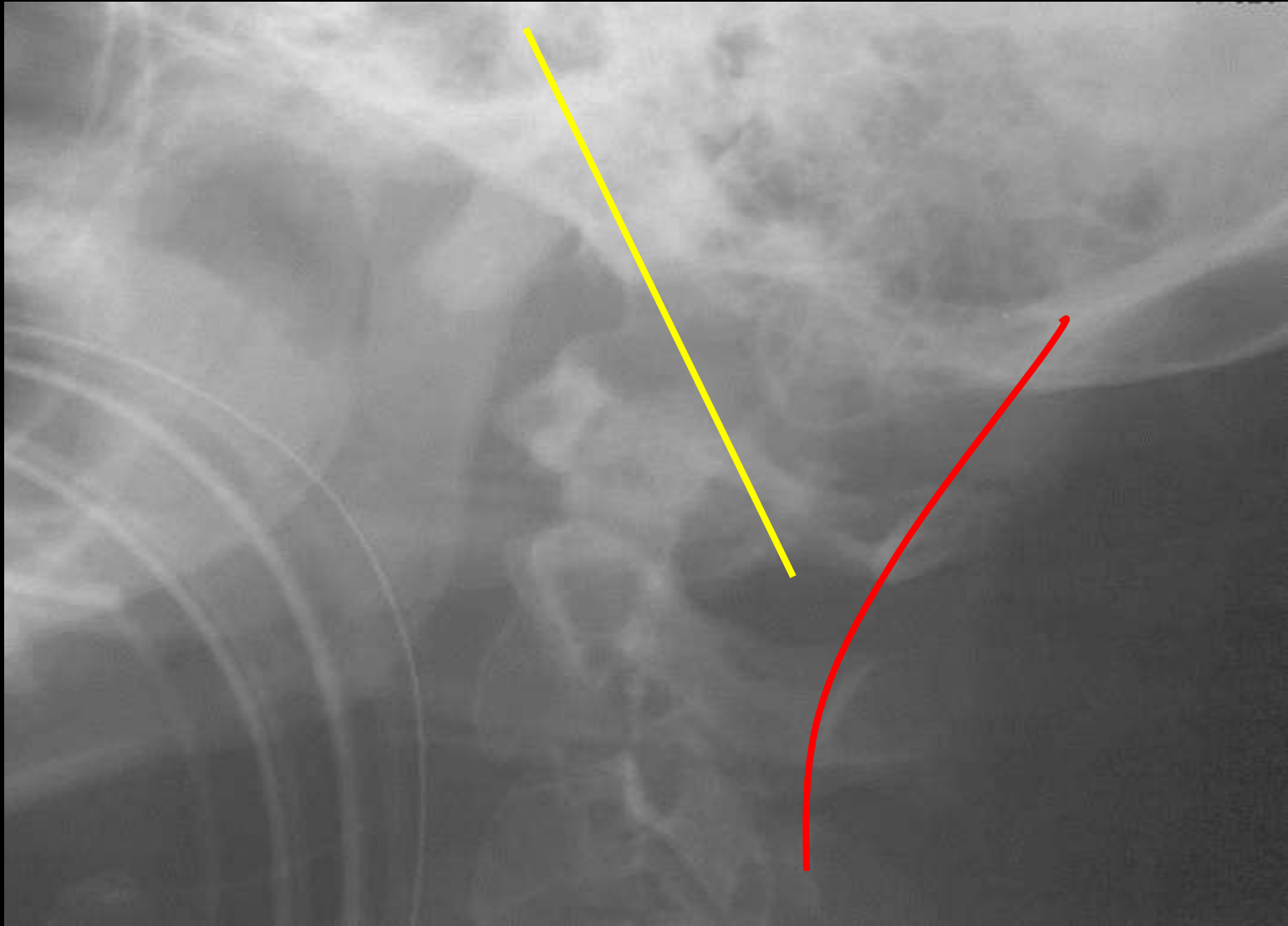


Atlantoaxial Dislocation

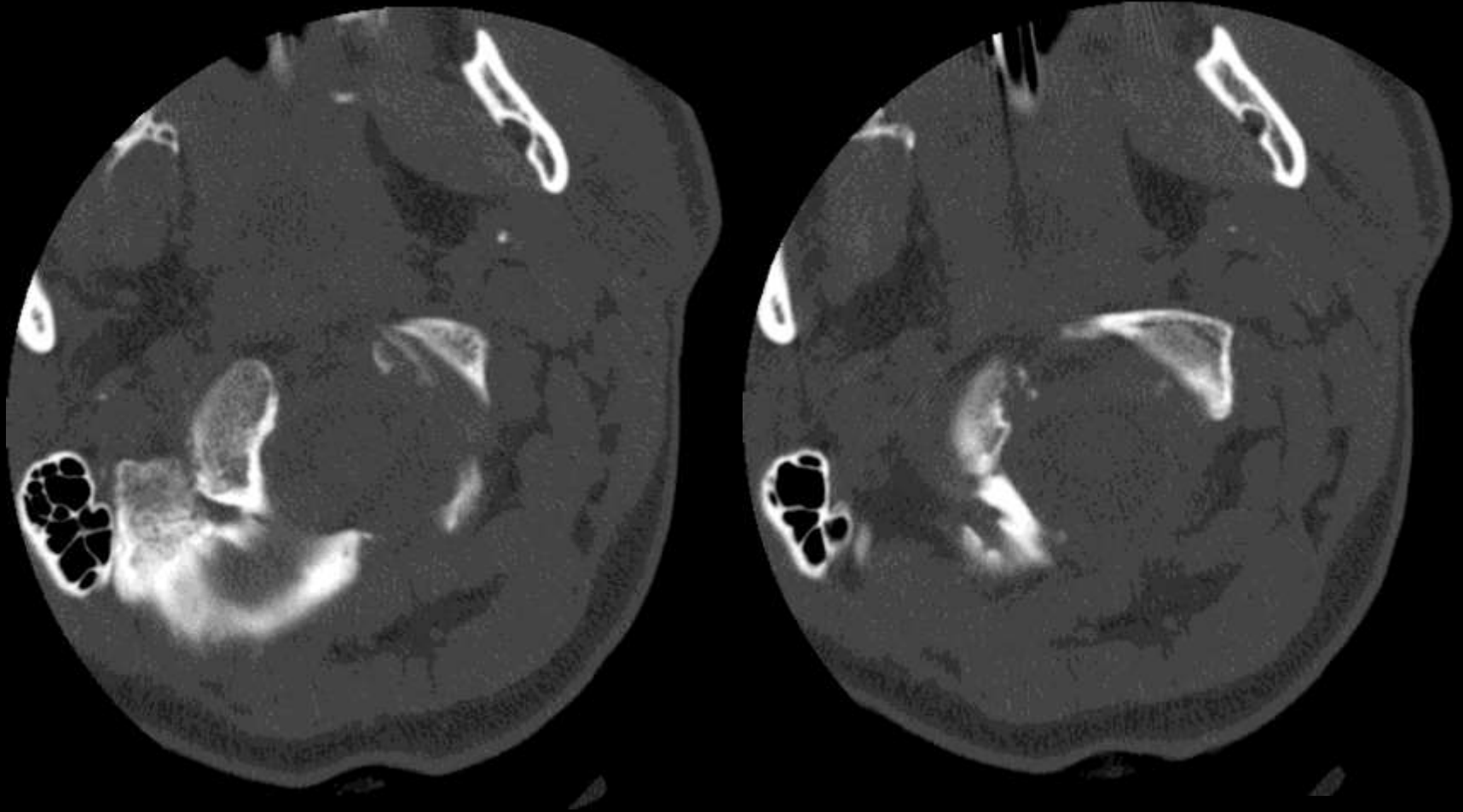
27



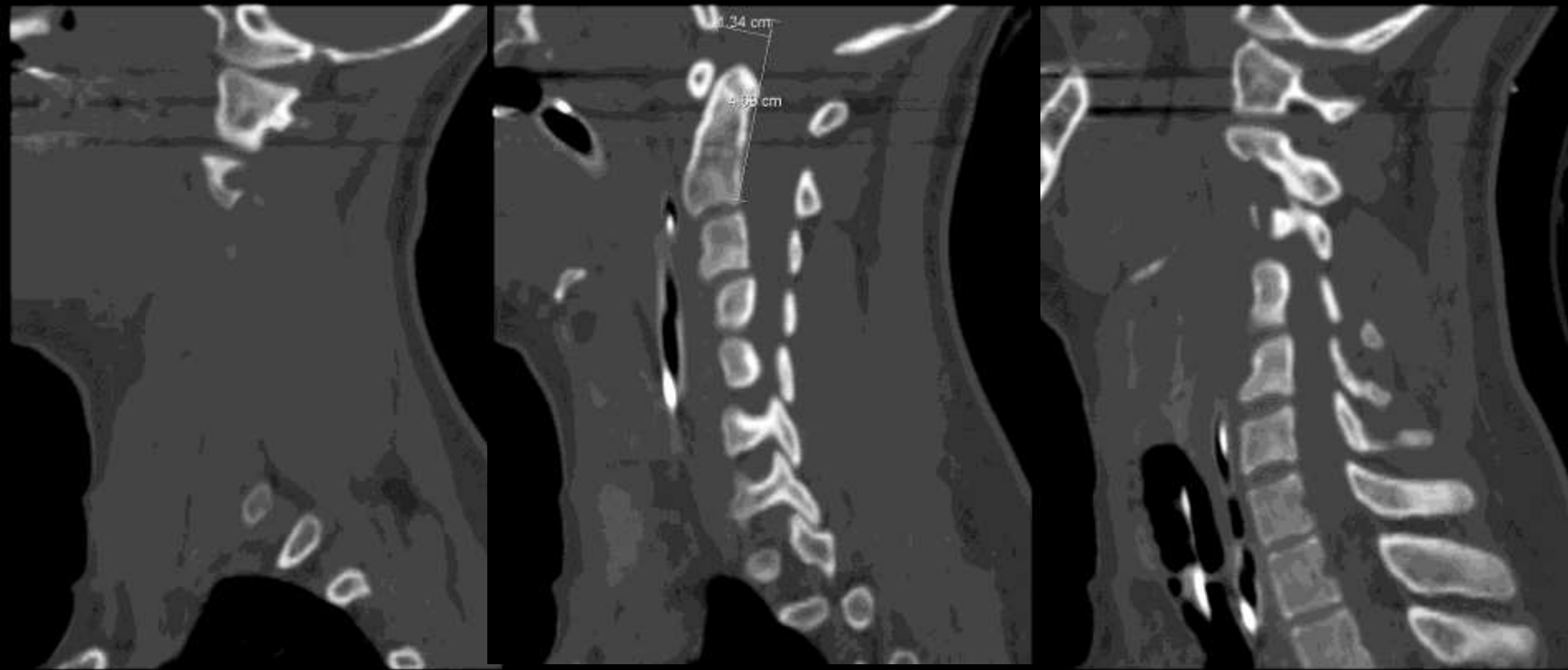
Atlantooccipital Subluxation



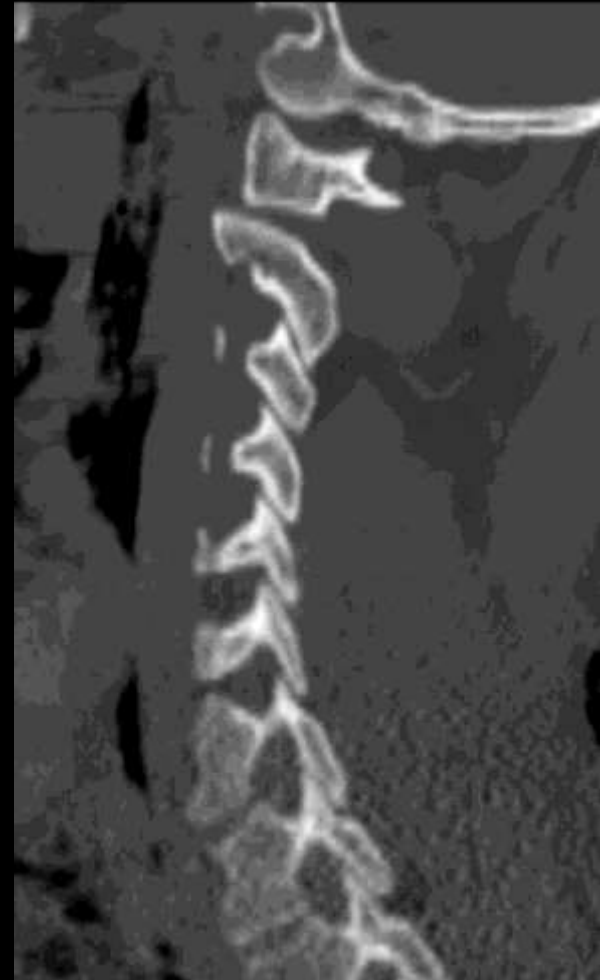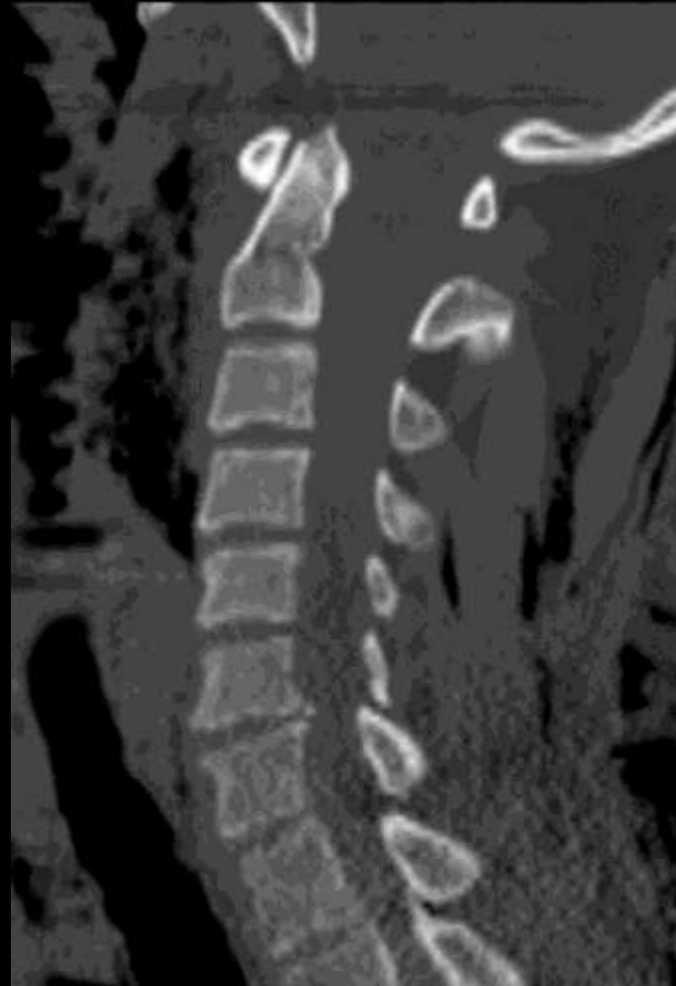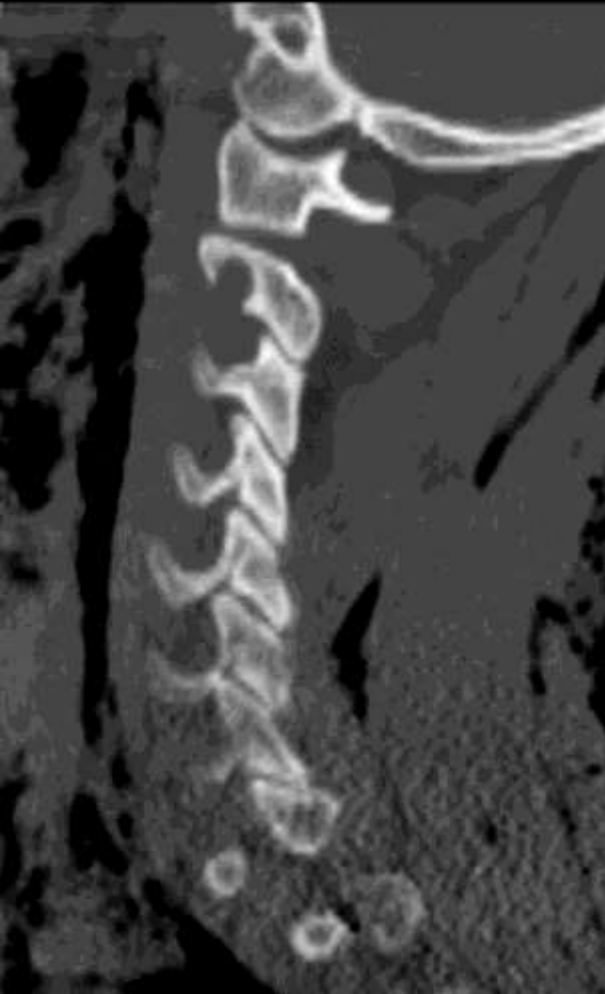Atlantooccipital subluxation



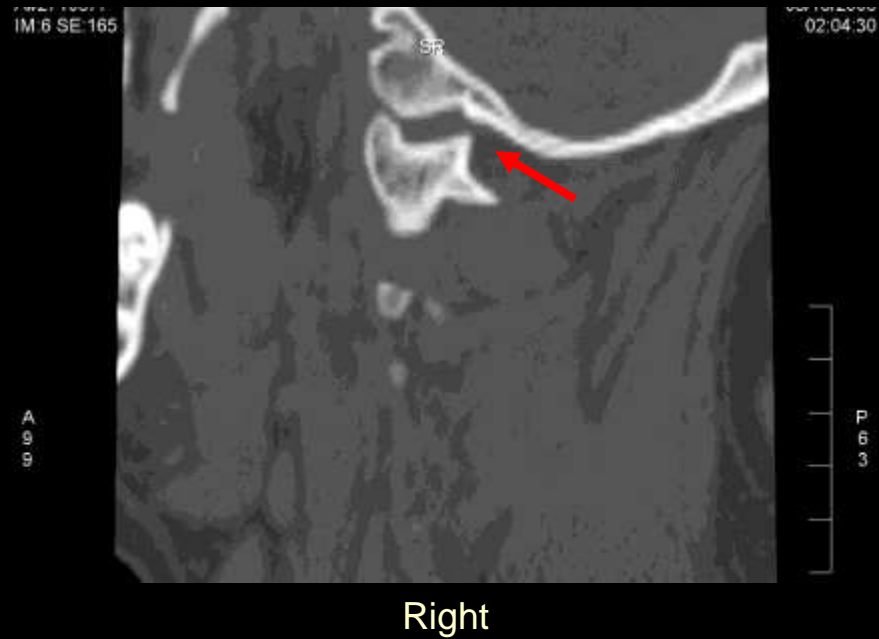Atlantooccipital subluxation



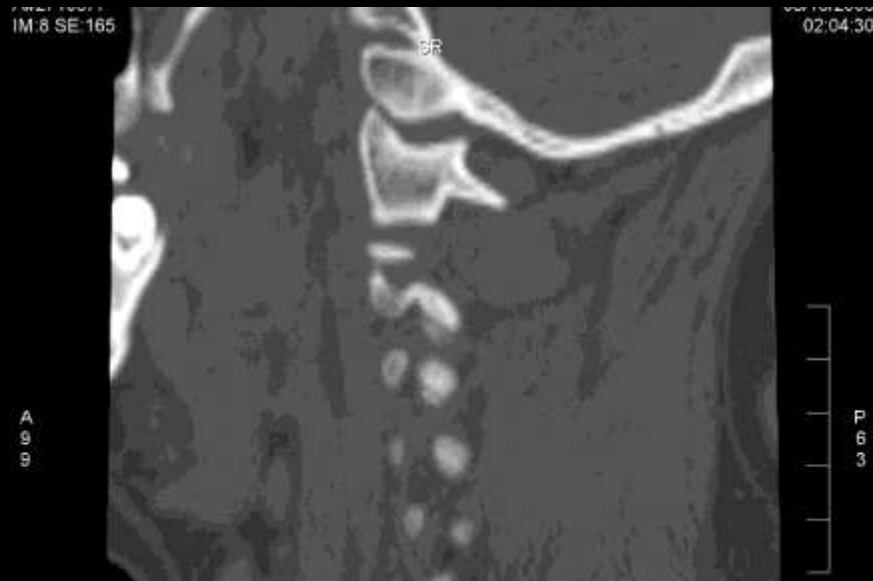Atlantooccipital subluxation



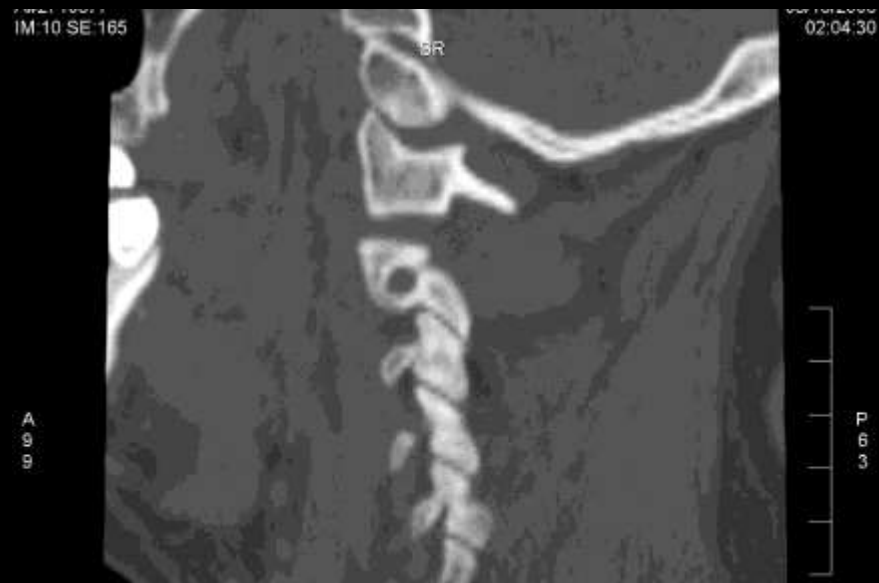Atlantooccipital subluxation



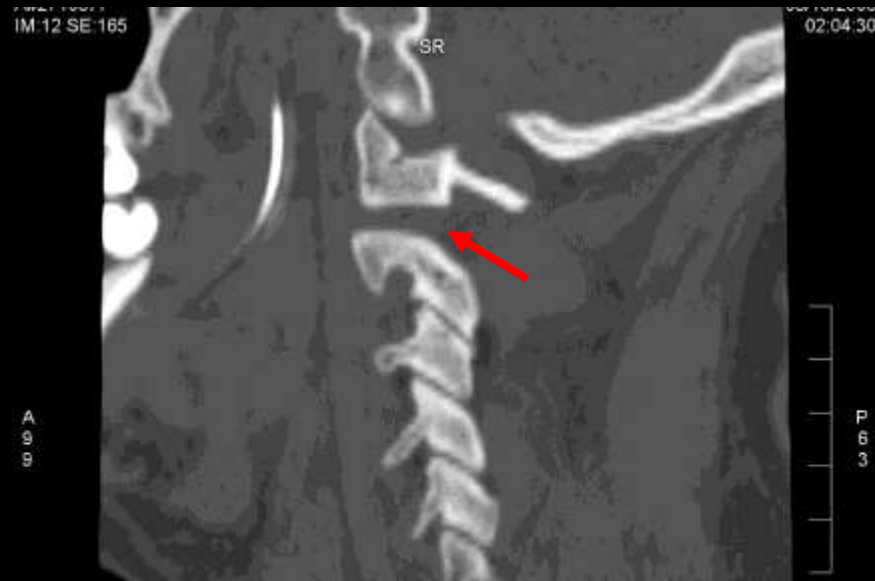Atlantooccipital subluxation



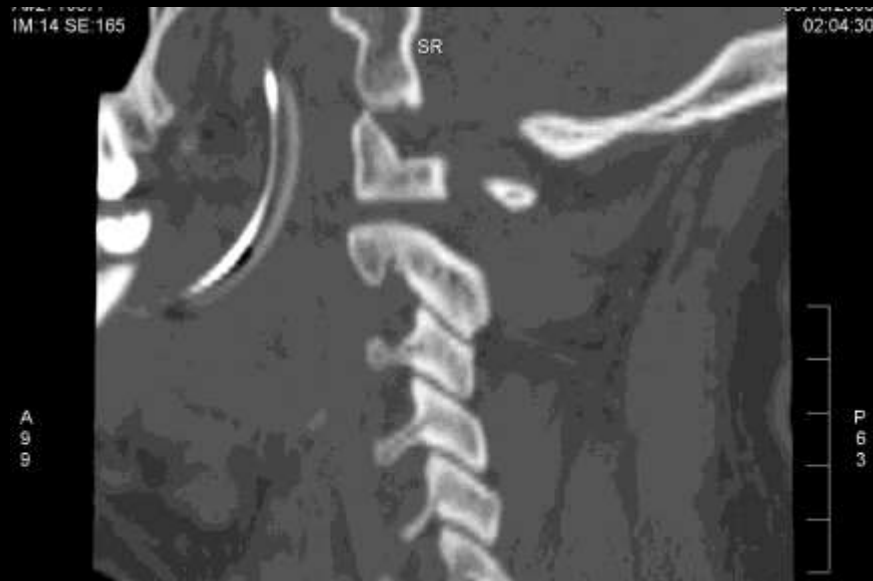Atlantooccipital subluxation



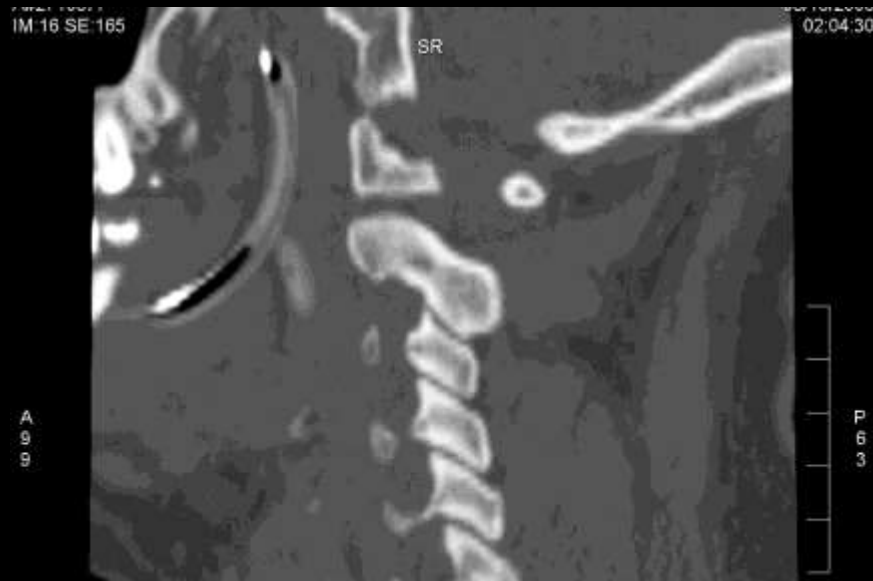Atlantooccipital subluxation



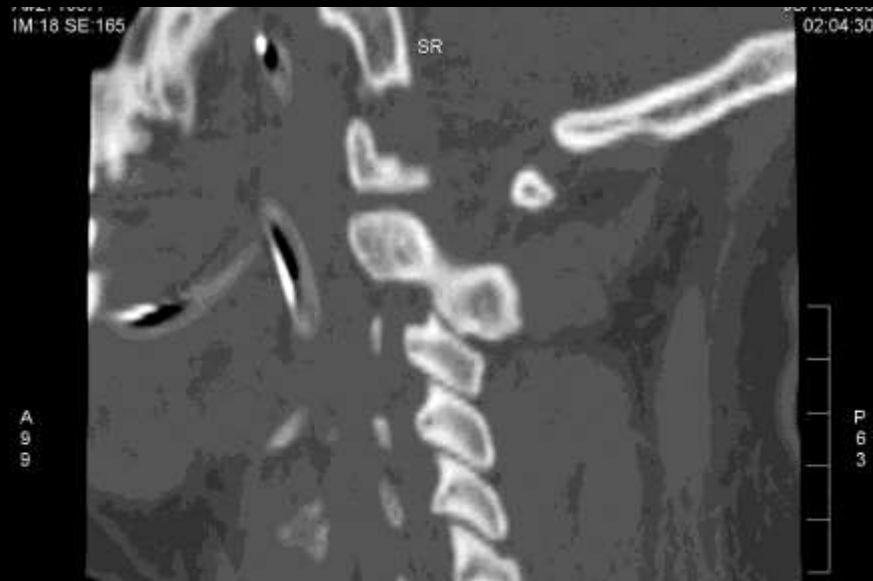Atlantooccipital subluxation



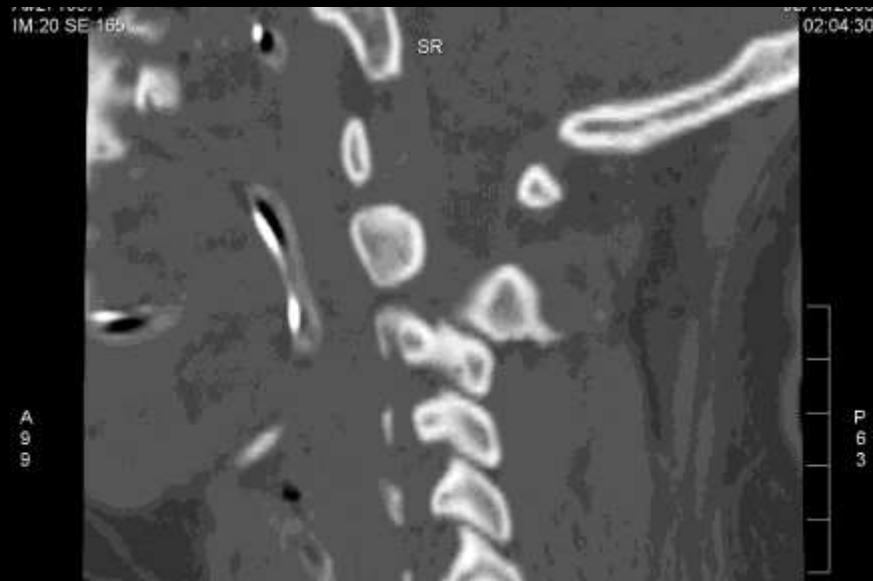
Atlantooccipital subluxation



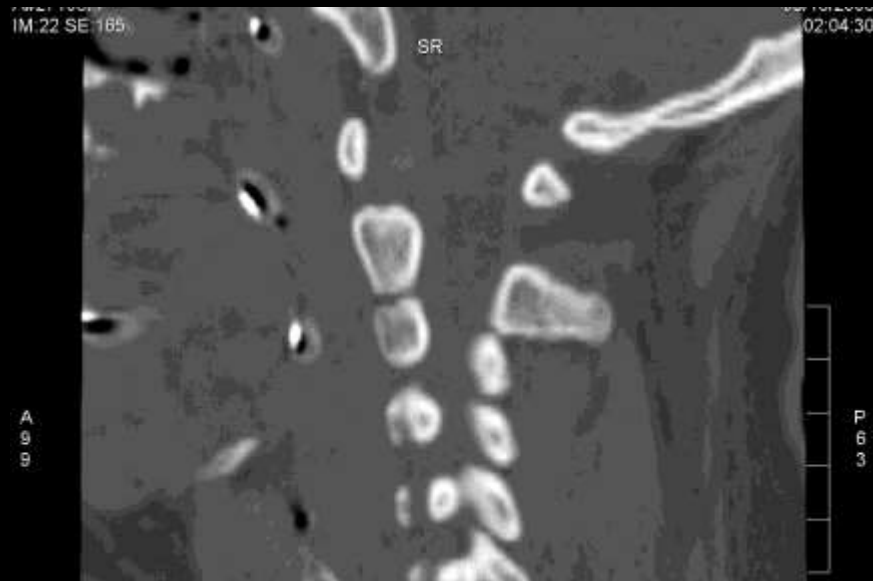Atlantooccipital subluxation



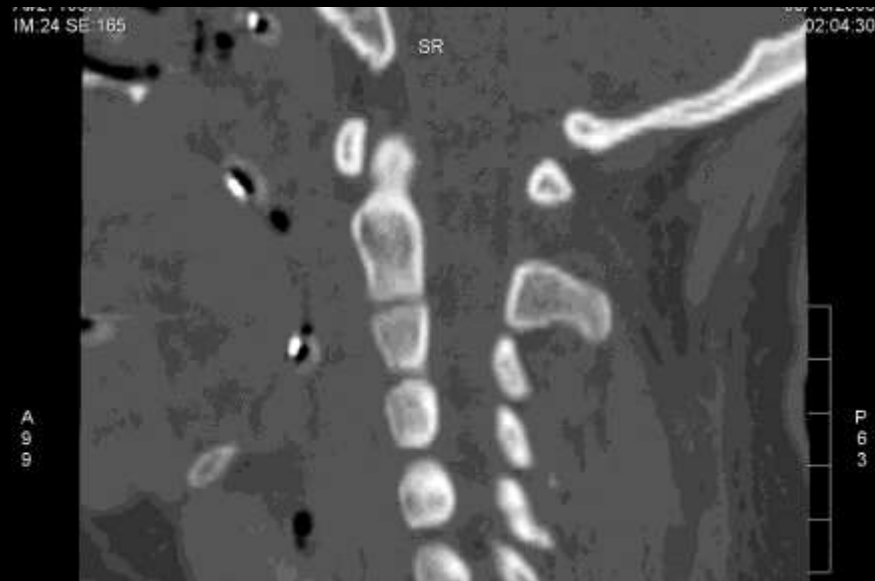
Atlantooccipital subluxation



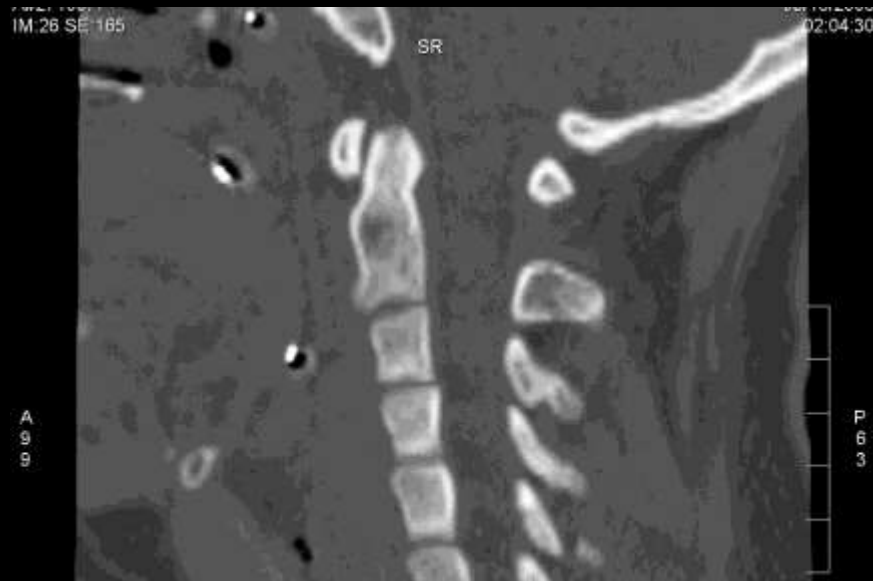Atlantooccipital subluxation



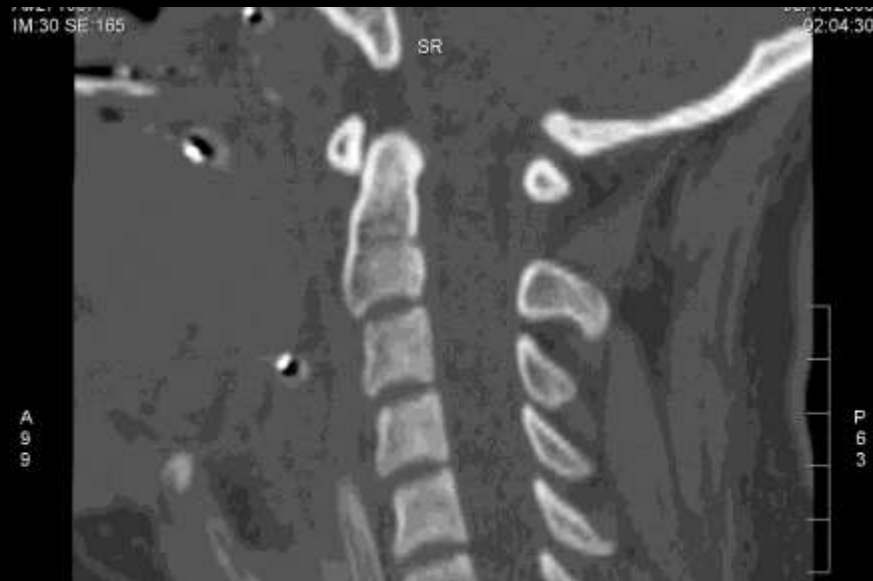Atlantooccipital subluxation



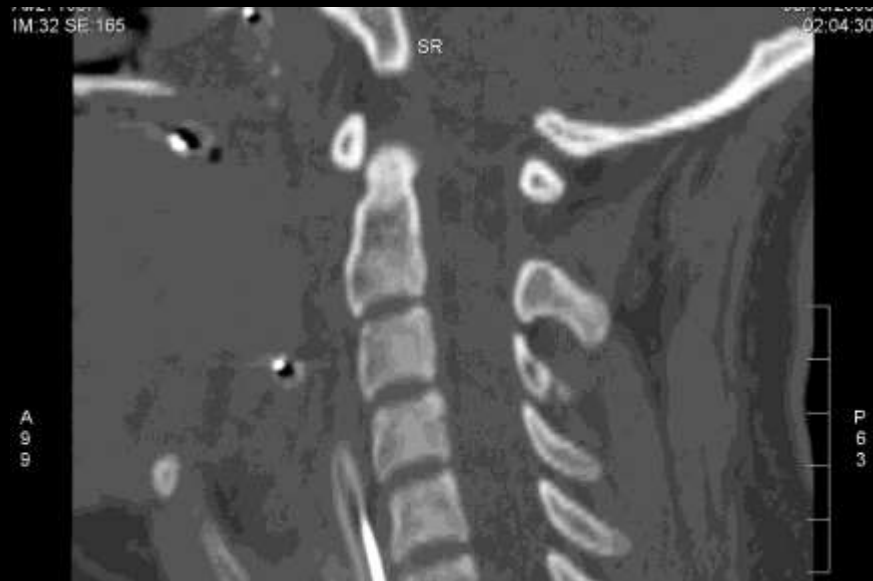Atlantooccipital subluxation



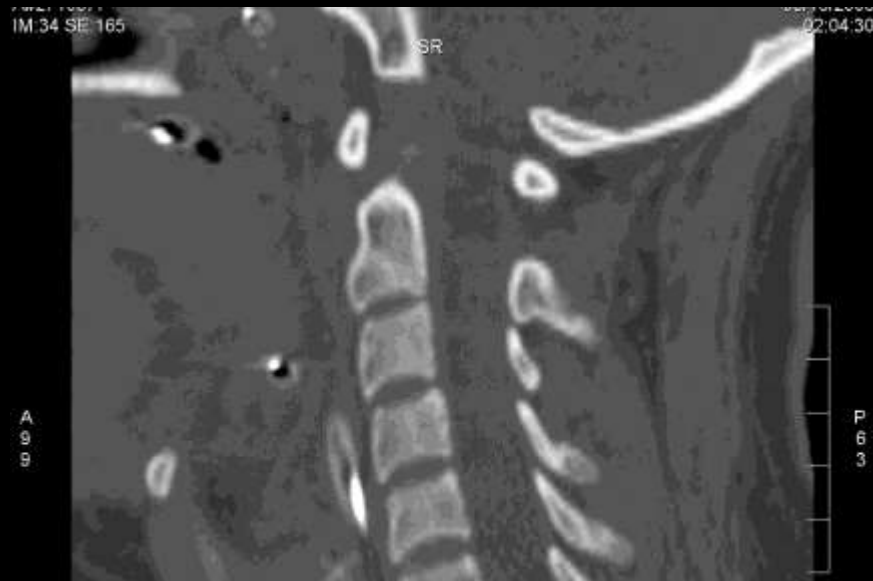Atlantooccipital subluxation



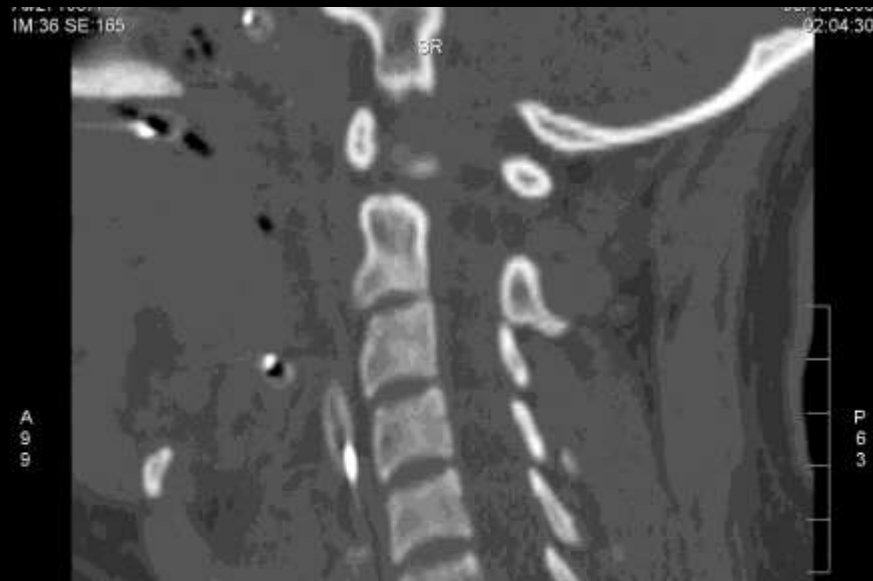Atlantooccipital subluxation



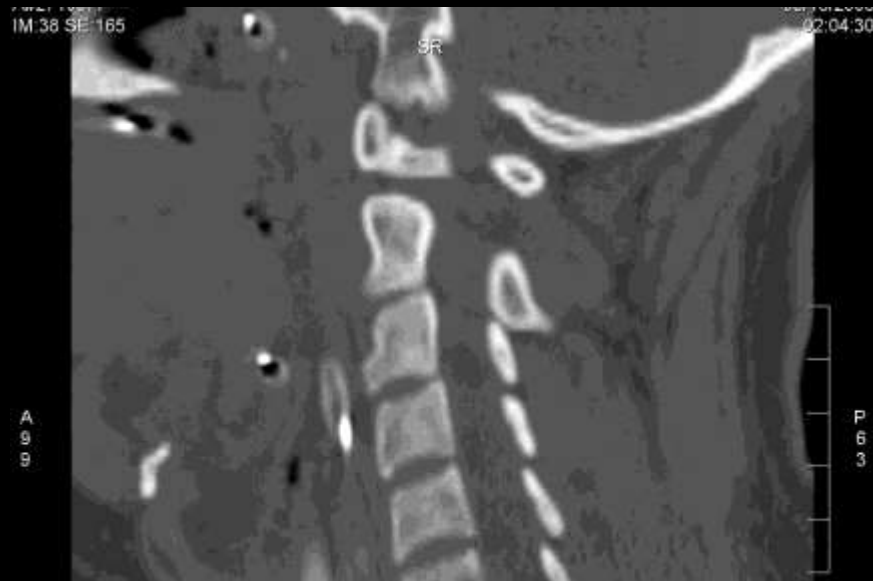Atlantooccipital subluxation



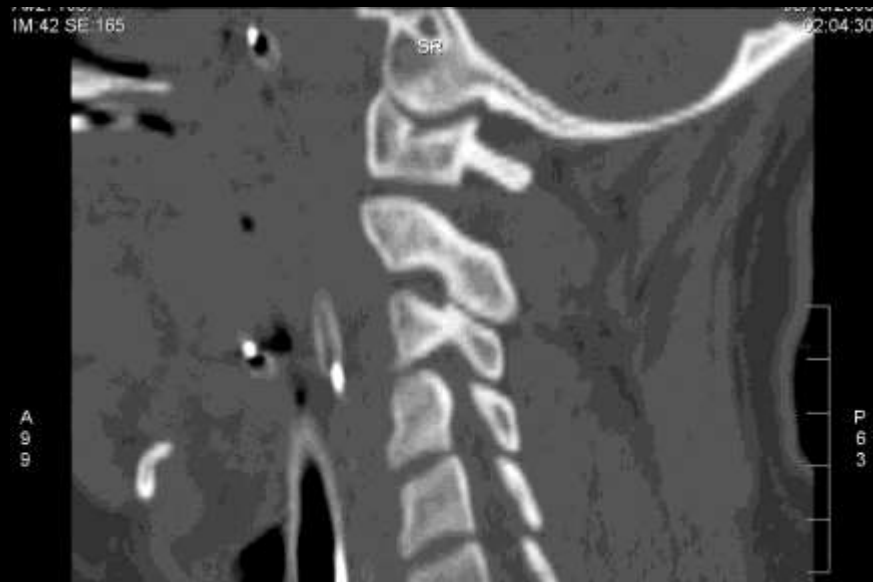Atlantooccipital subluxation



Atlantooccipital subluxation

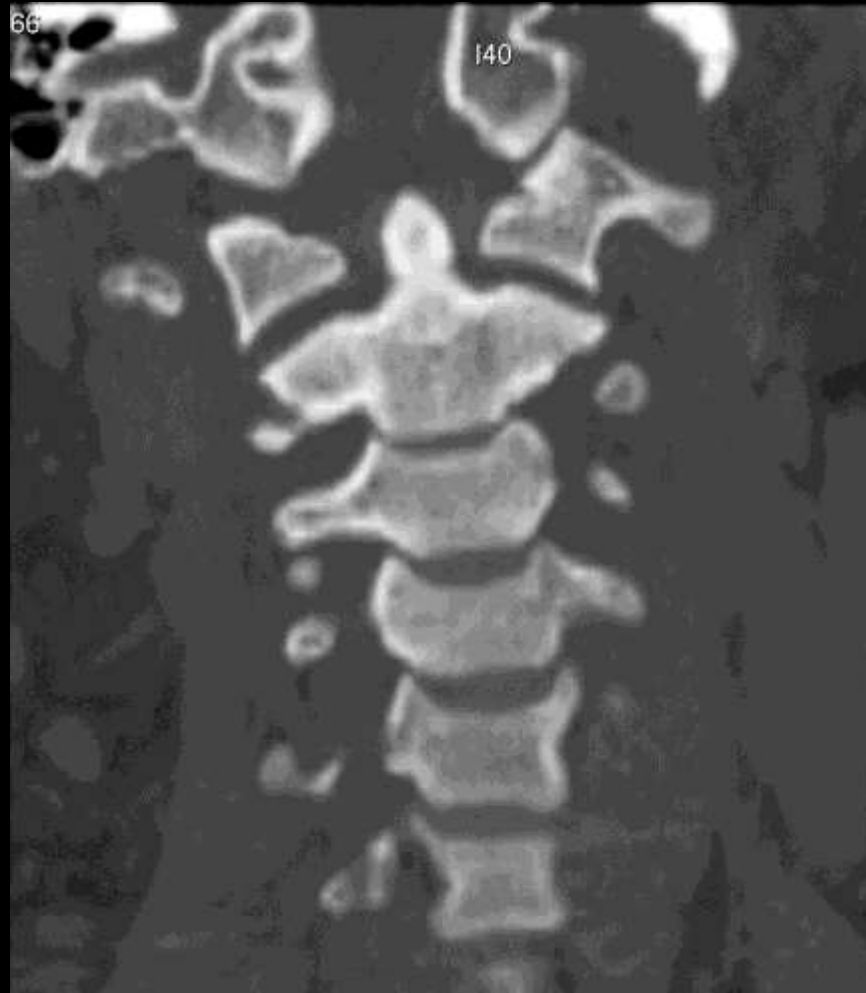

Atlantooccipital subluxation

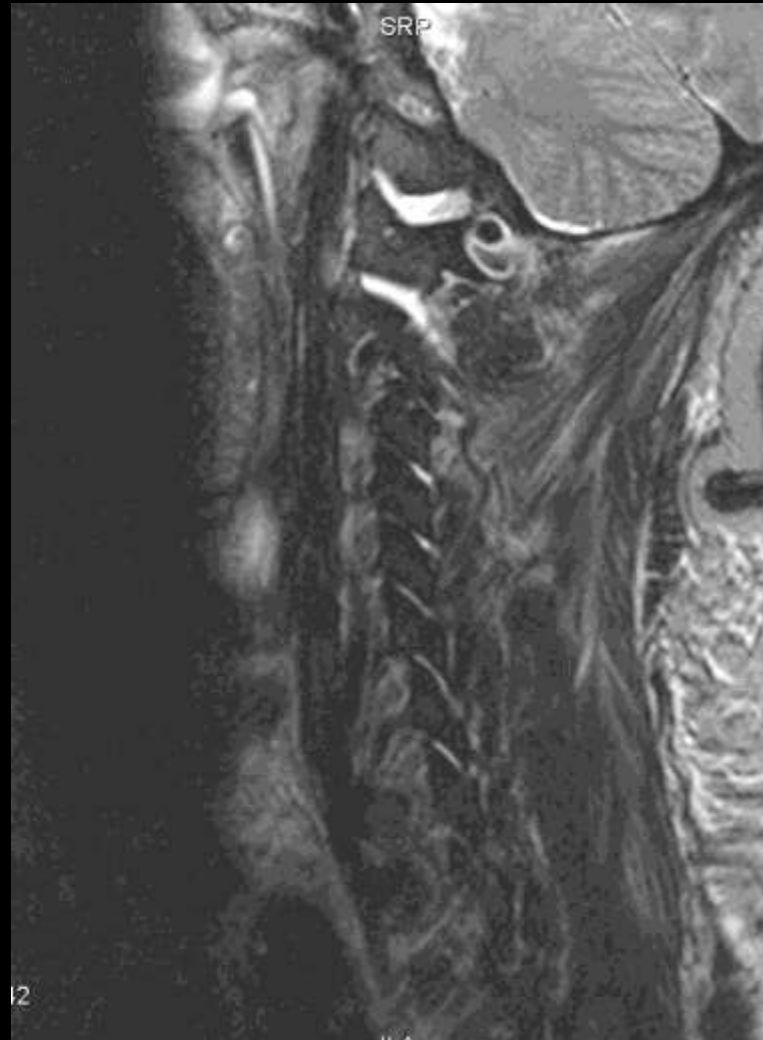

Left

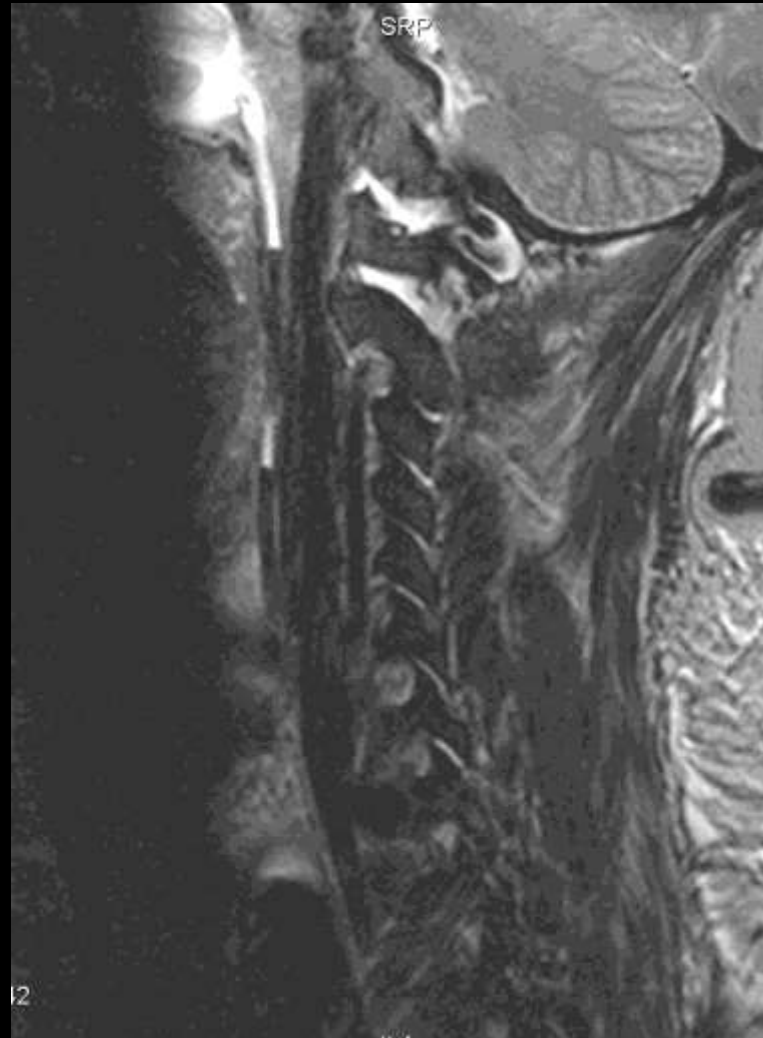Atlantooccipital subluxation



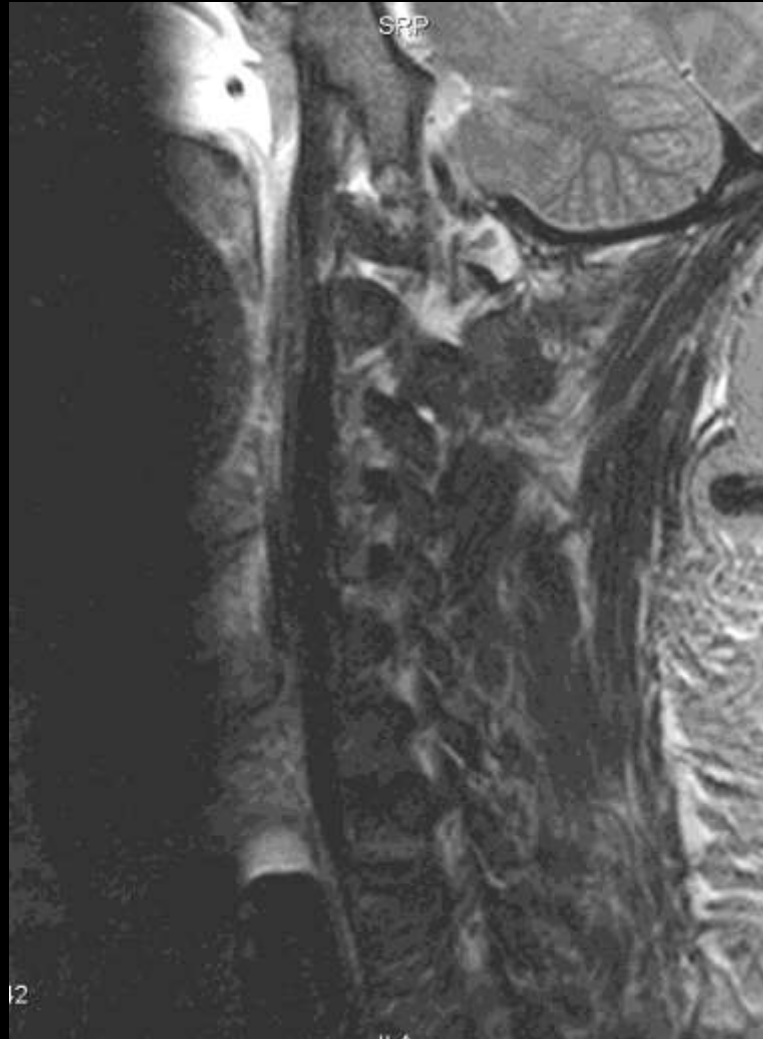Atlantooccipital subluxation



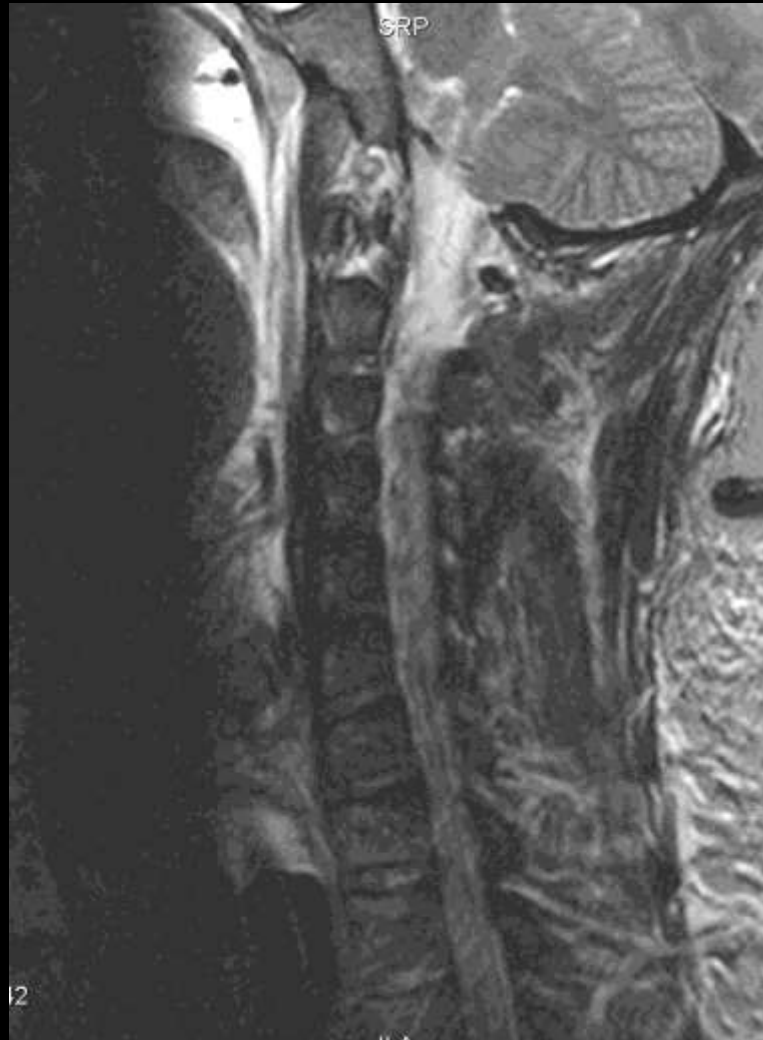Atlantooccipital subluxation



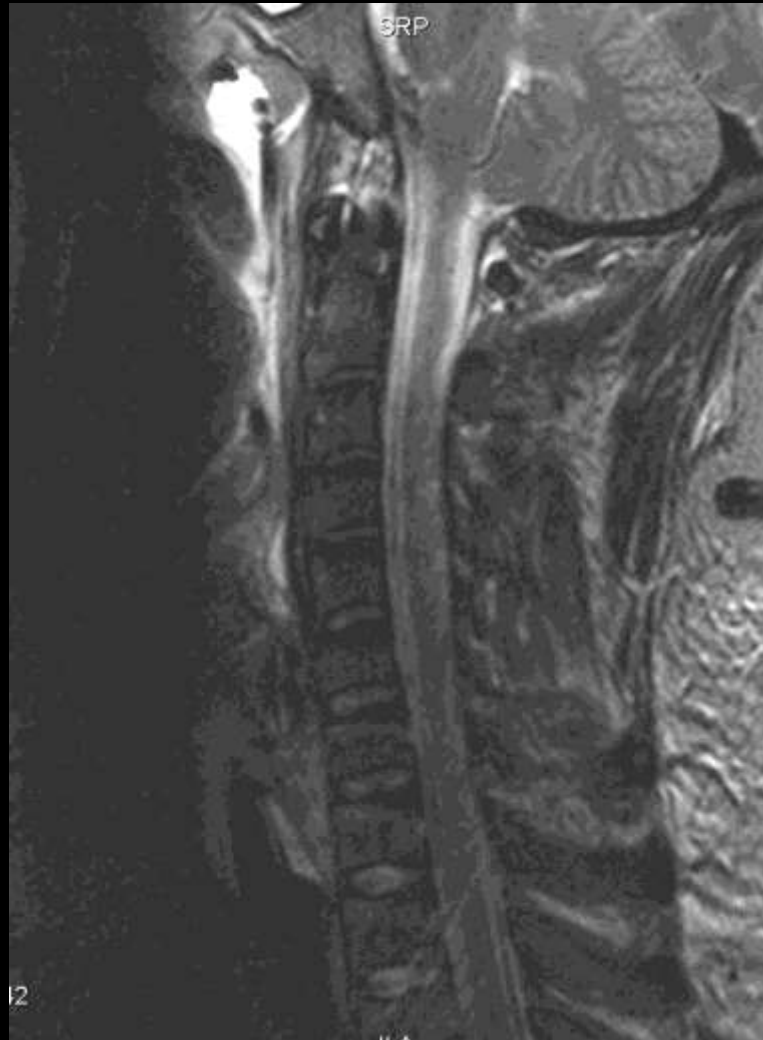Atlantooccipital subluxation



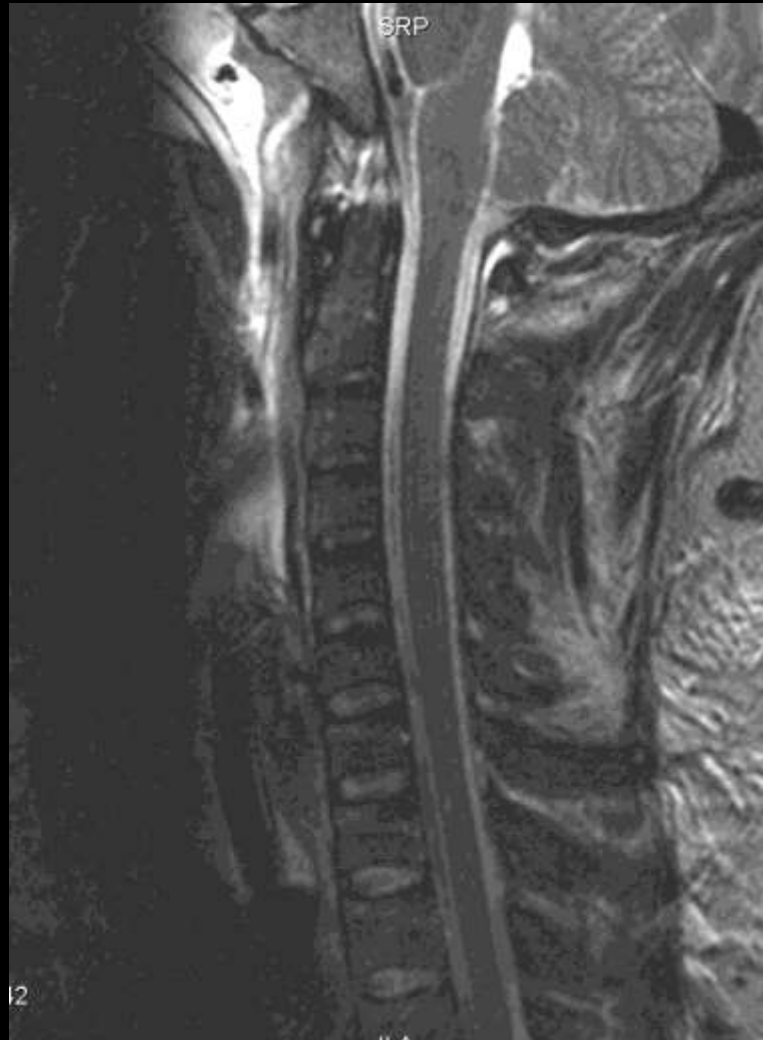Atlantooccipital subluxation



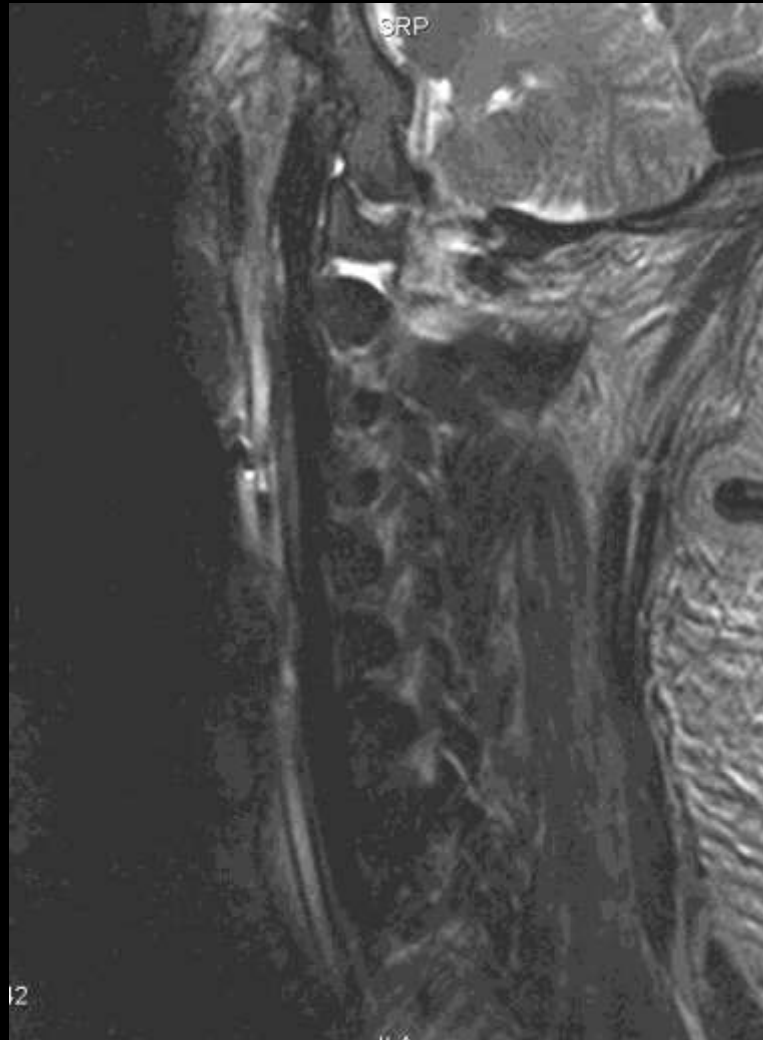Atlantooccipital subluxation



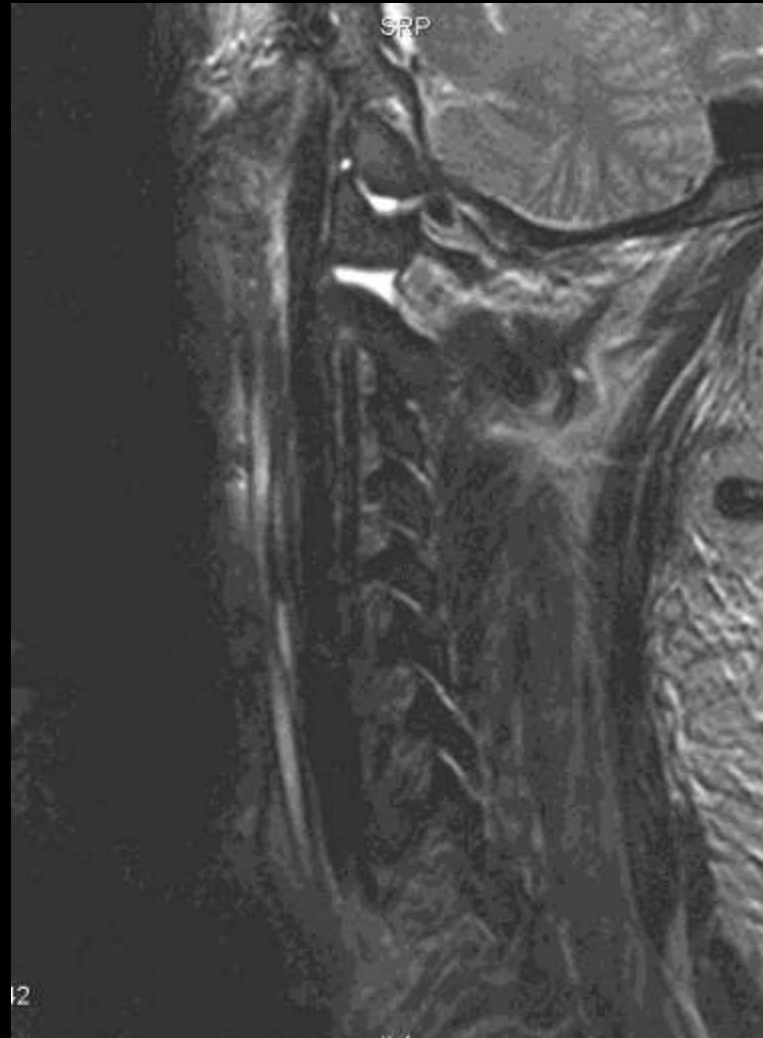
Atlantooccipital subluxation



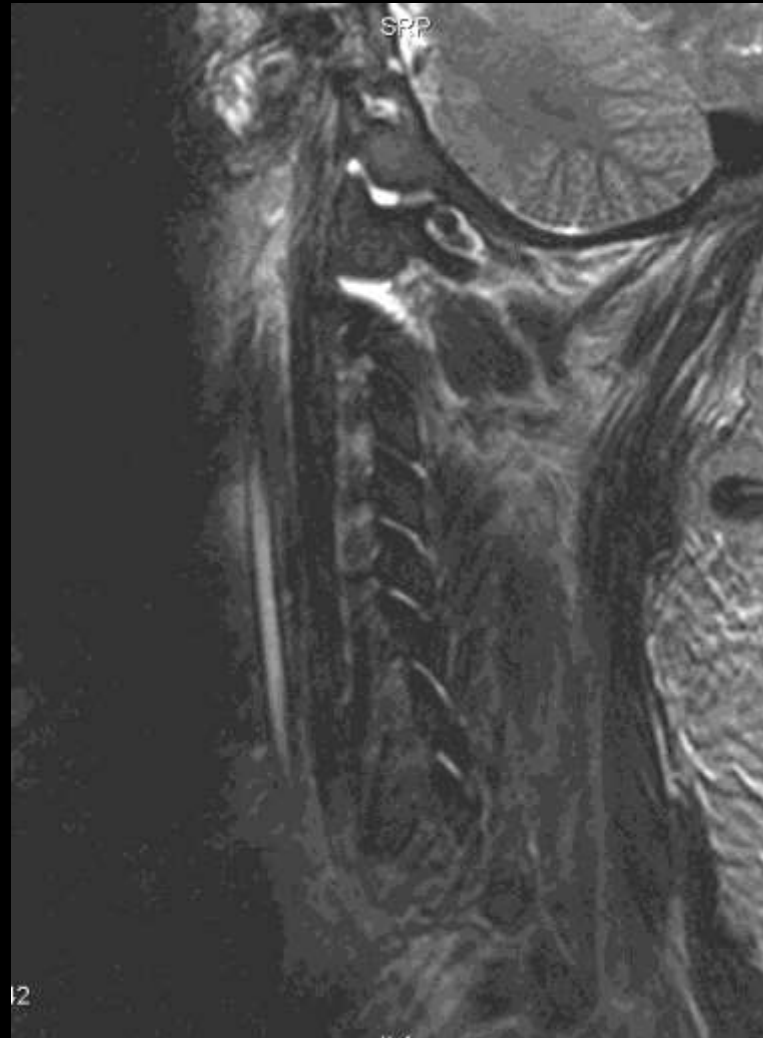
Atlantooccipital subluxation



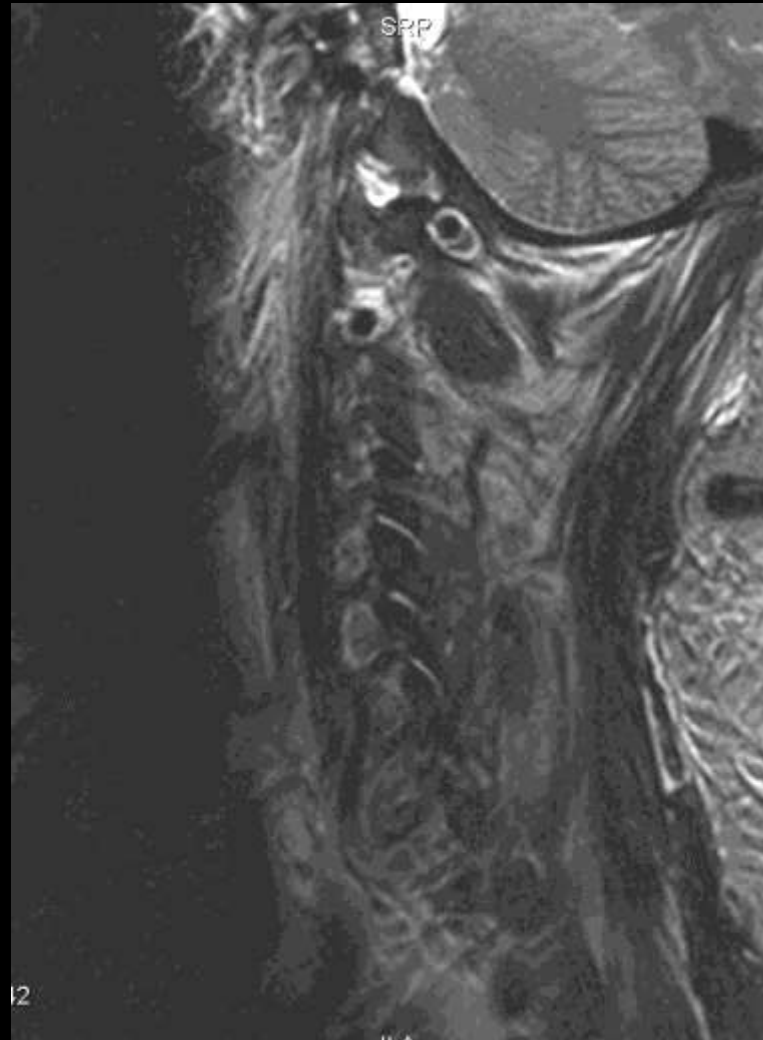Atlantooccipital subluxation



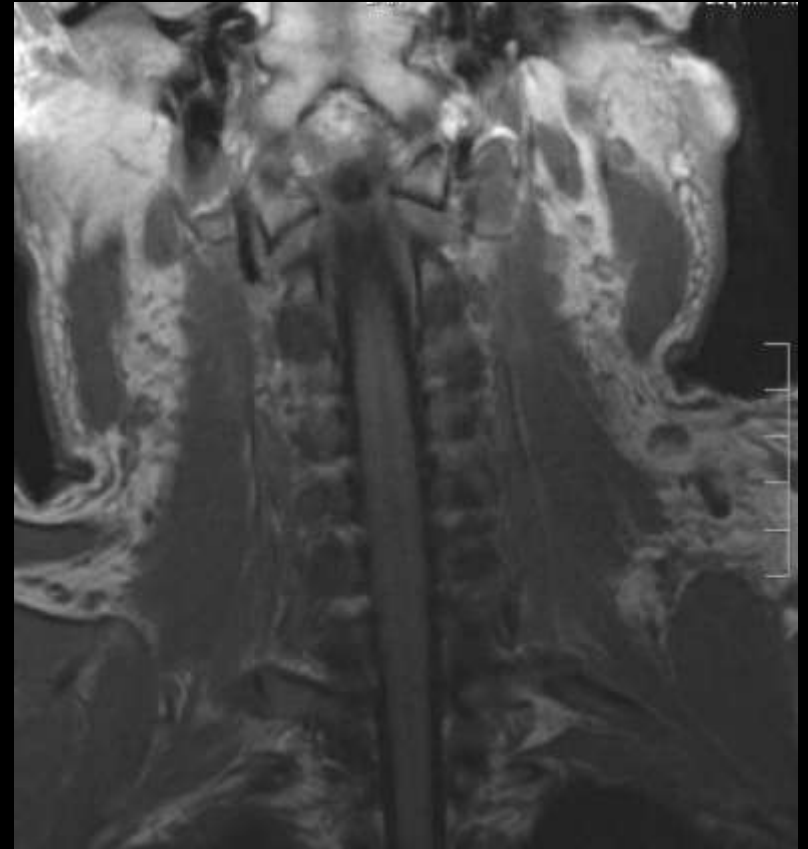
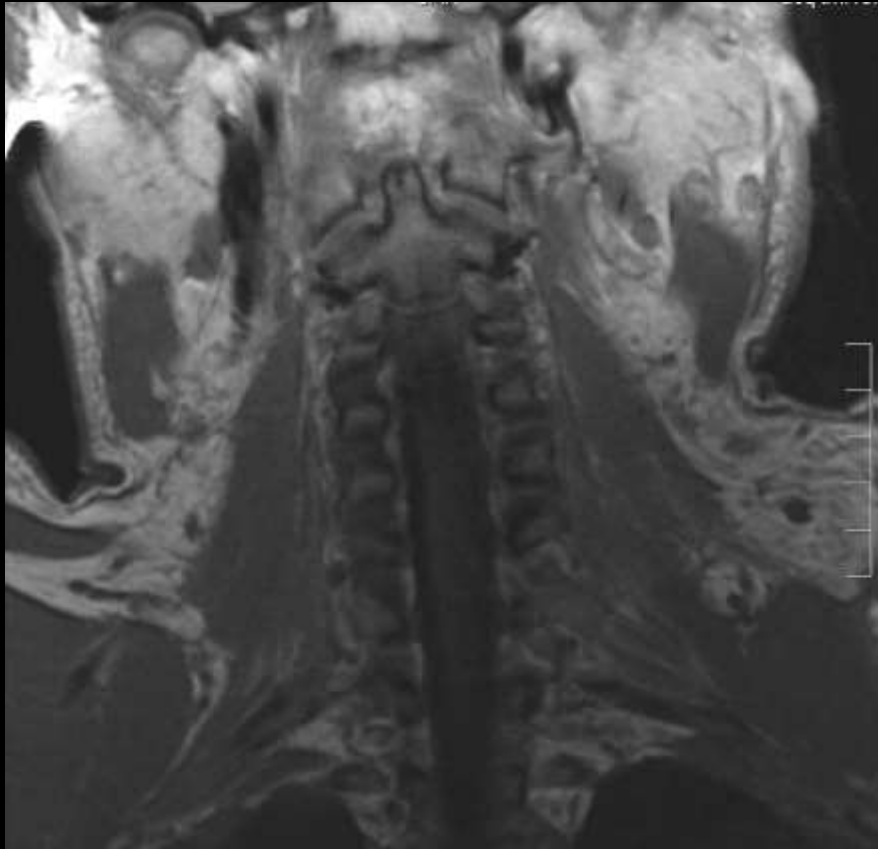
Atlantooccipital subluxation



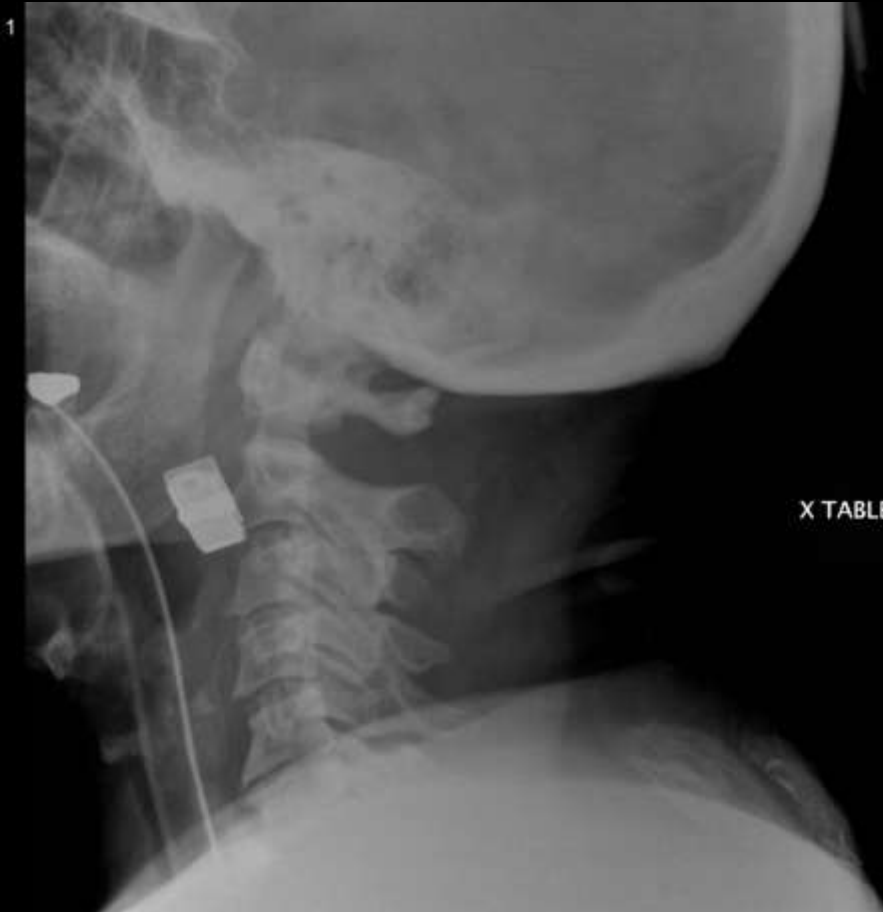Atlantooccipital subluxation



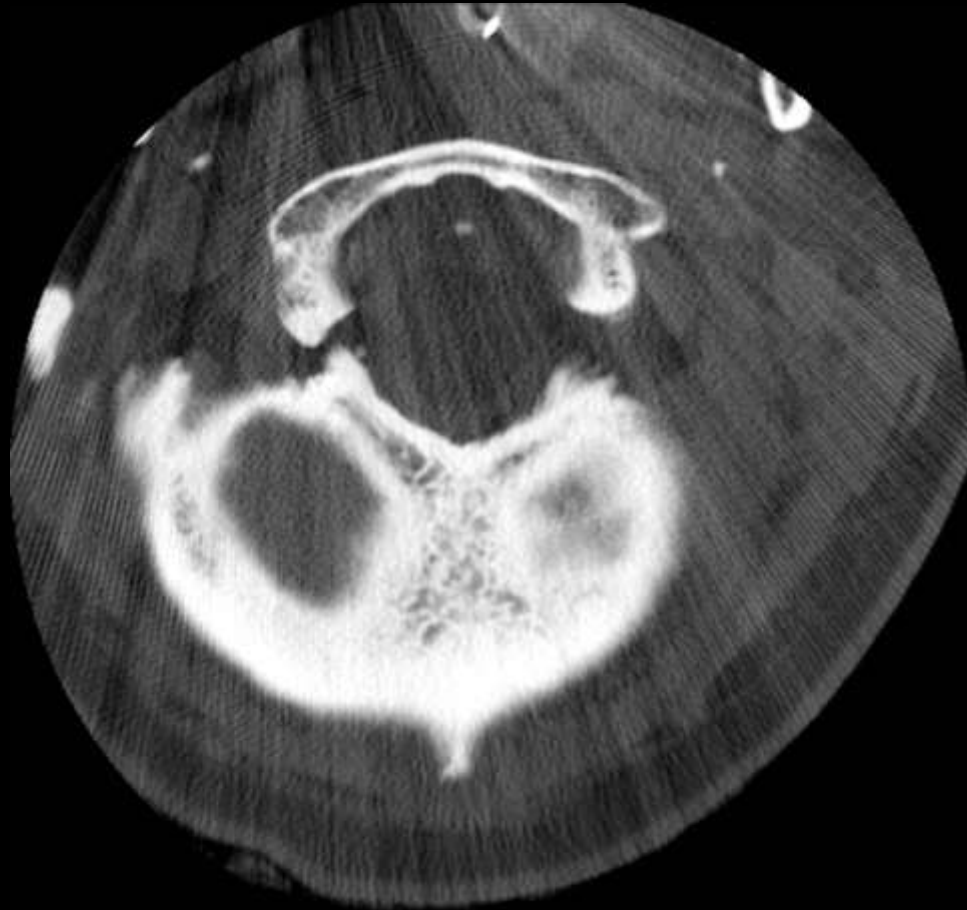Atlantooccipital subluxation



Occipito Axial Dislocation

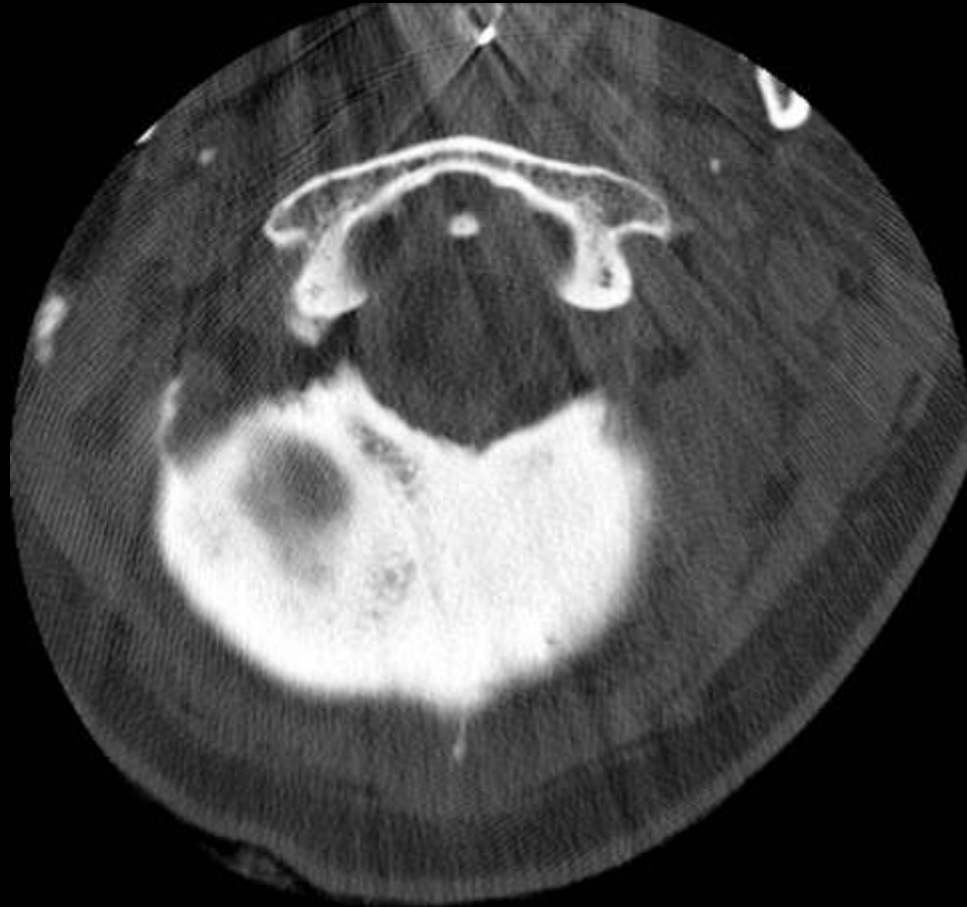

Occipito Axial Dislocation



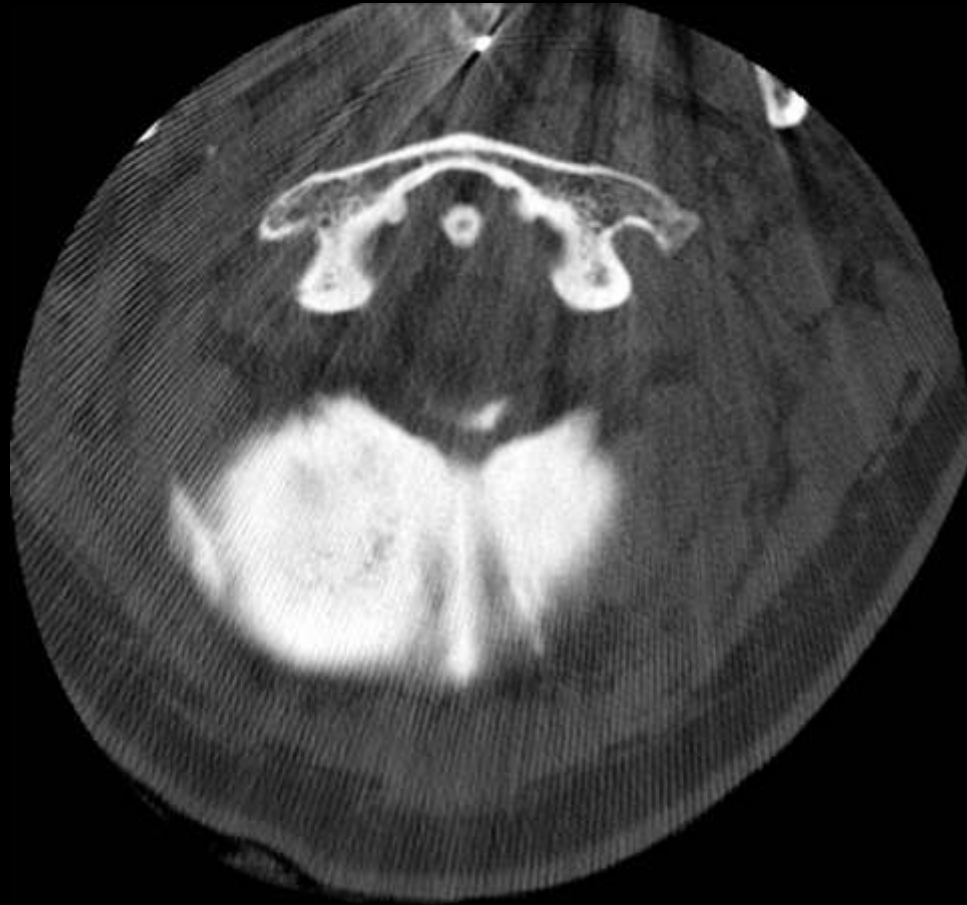W 2000 : L 500

Occipito Axial Dislocation



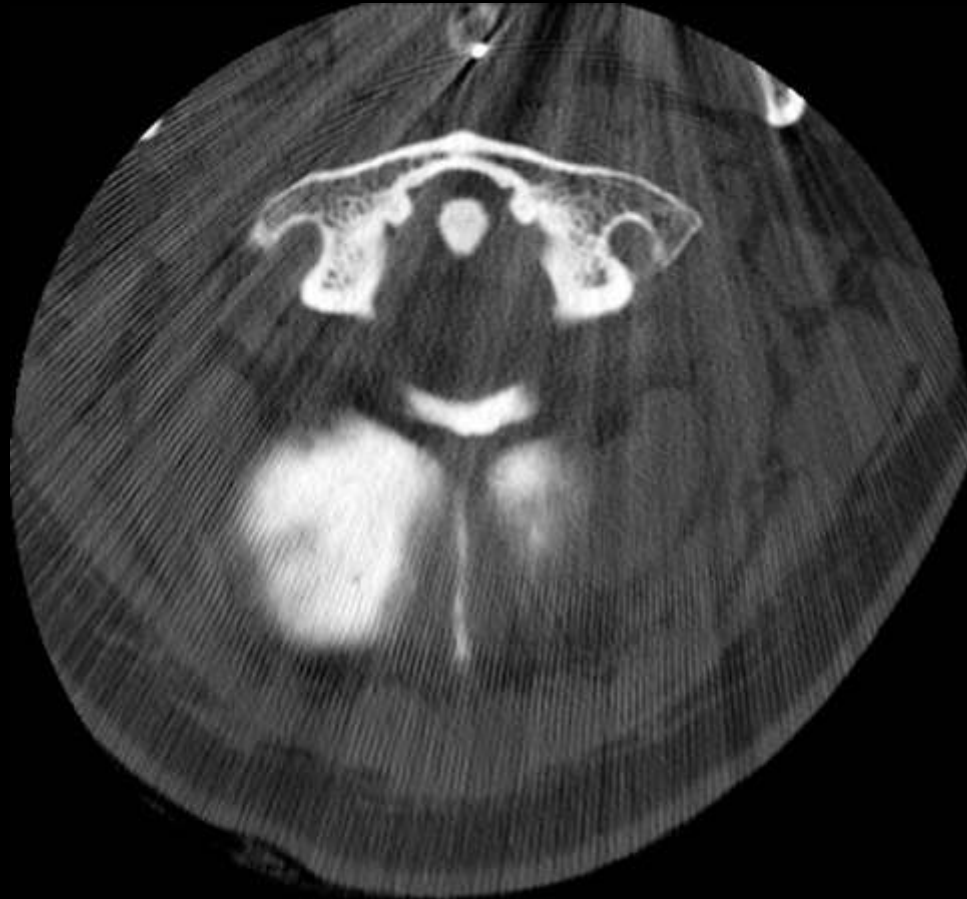W 2000 : L 500

Occipito Axial Dislocation



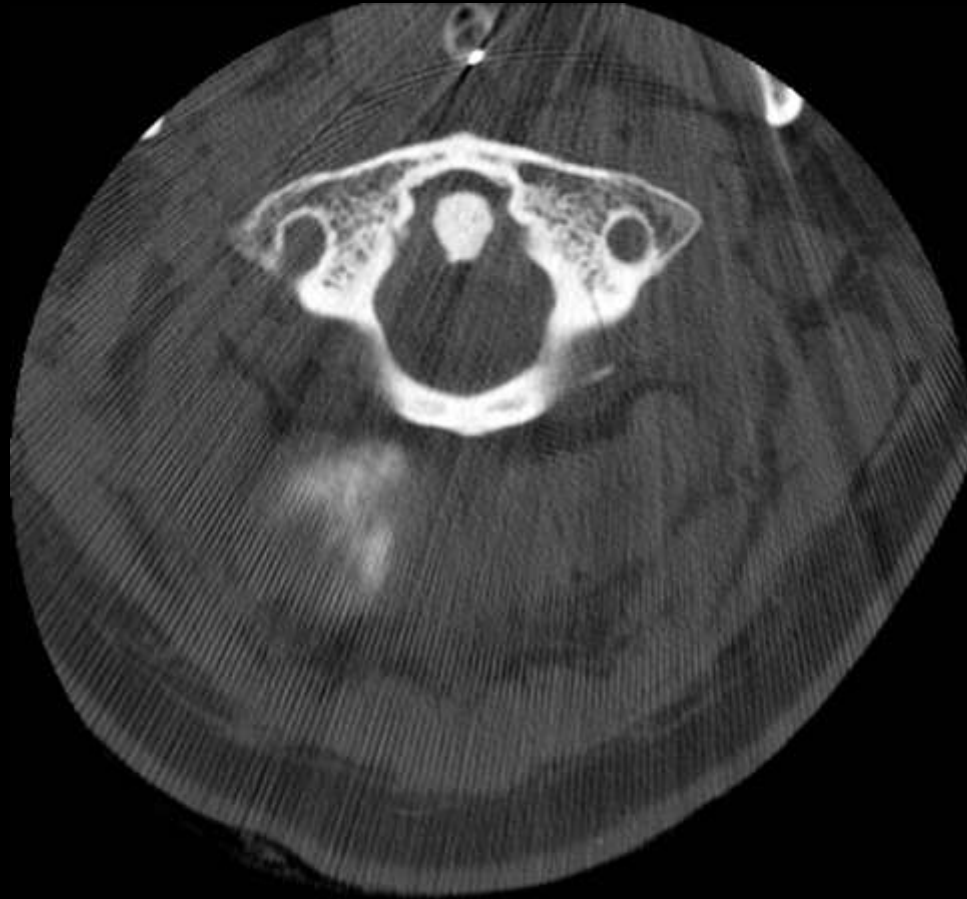W 2000 : L 500

Occipito Axial Dislocation



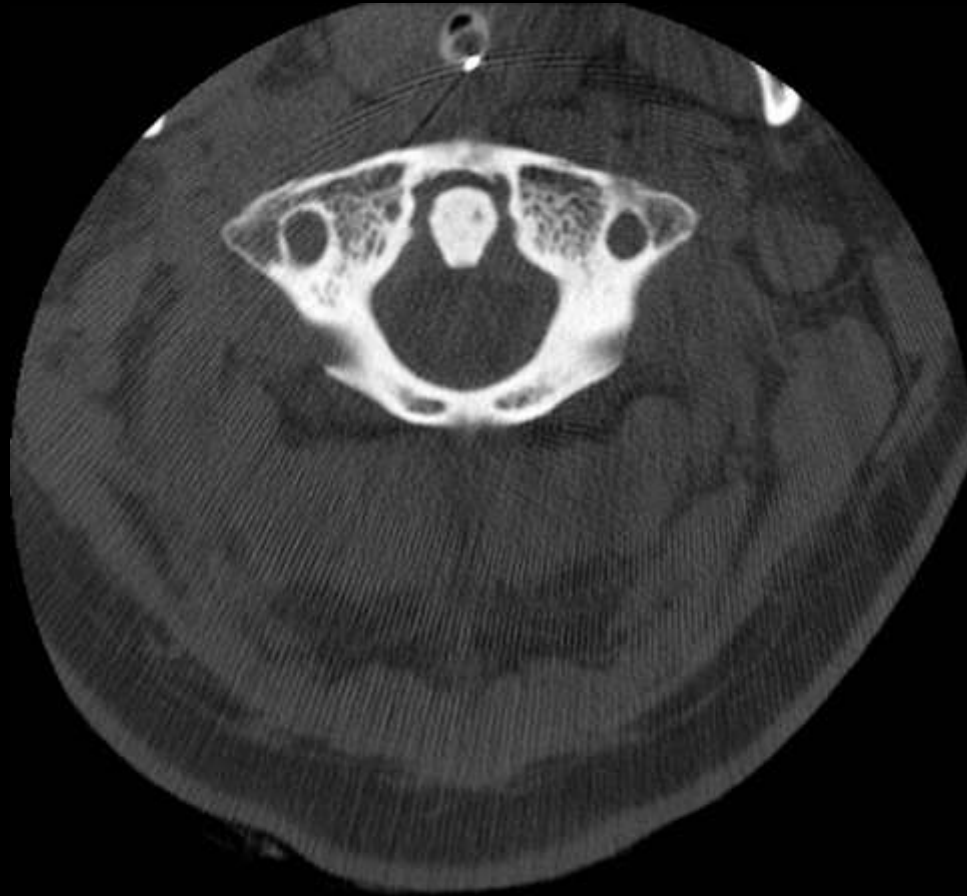
W 2000 : L 500

Occipito Axial Dislocation



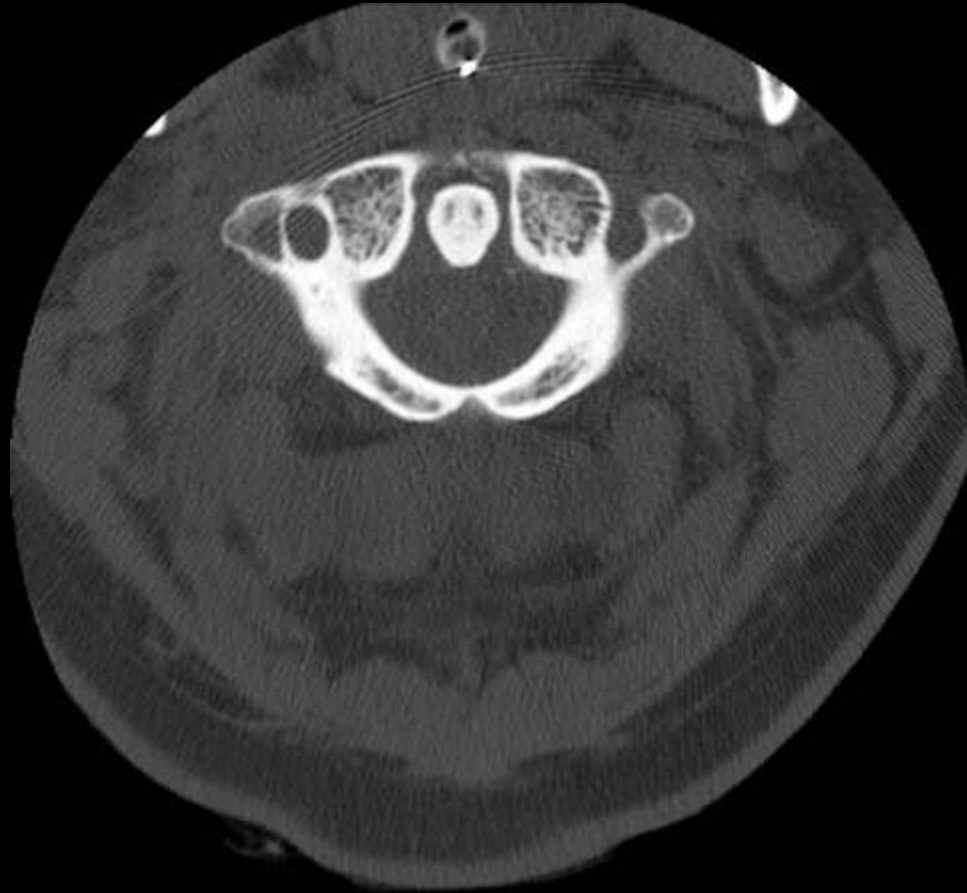W 2000 : L 500

Occipito Axial Dislocation



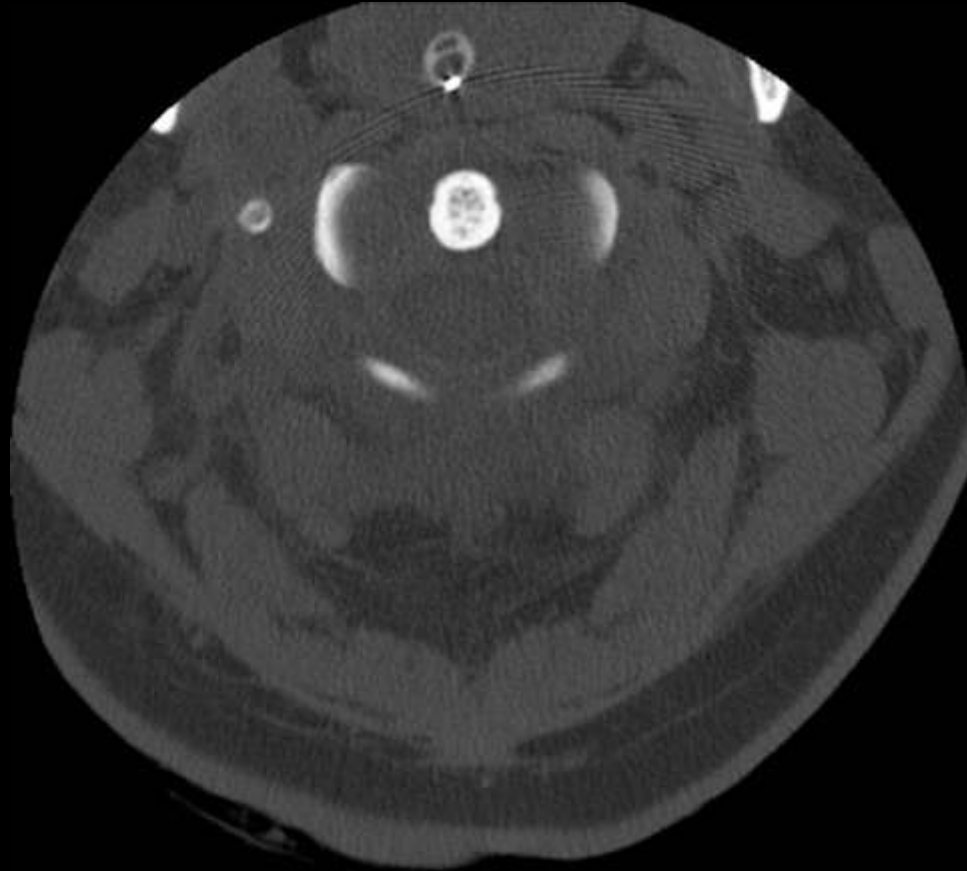
W 2000 : L 500

Occipito Axial Dislocation



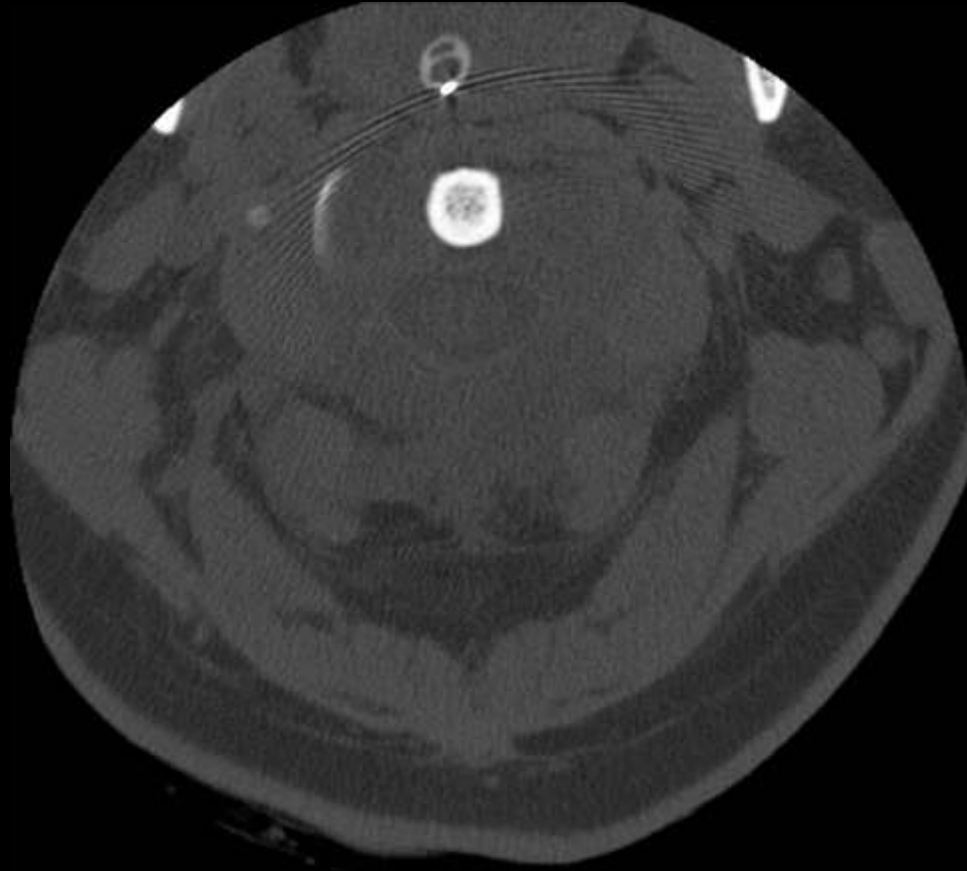
W 2000 : L 500

Occipito Axial Dislocation



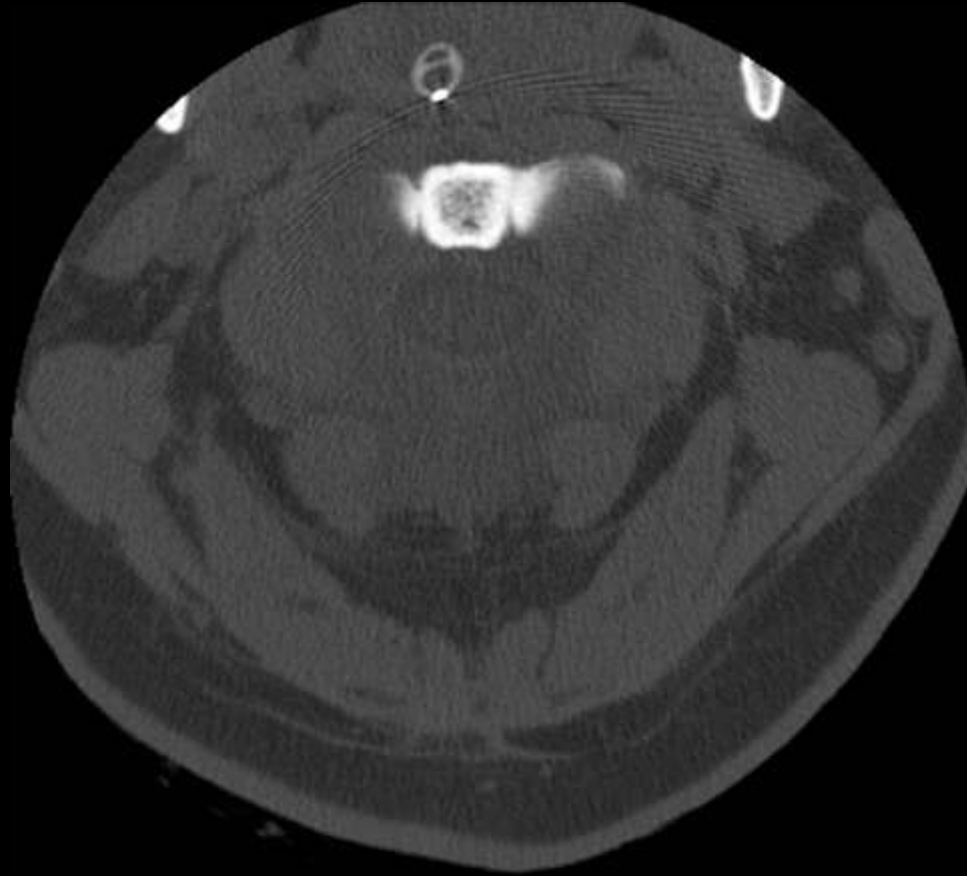
W 2000 : L 500

Occipito Axial Dislocation



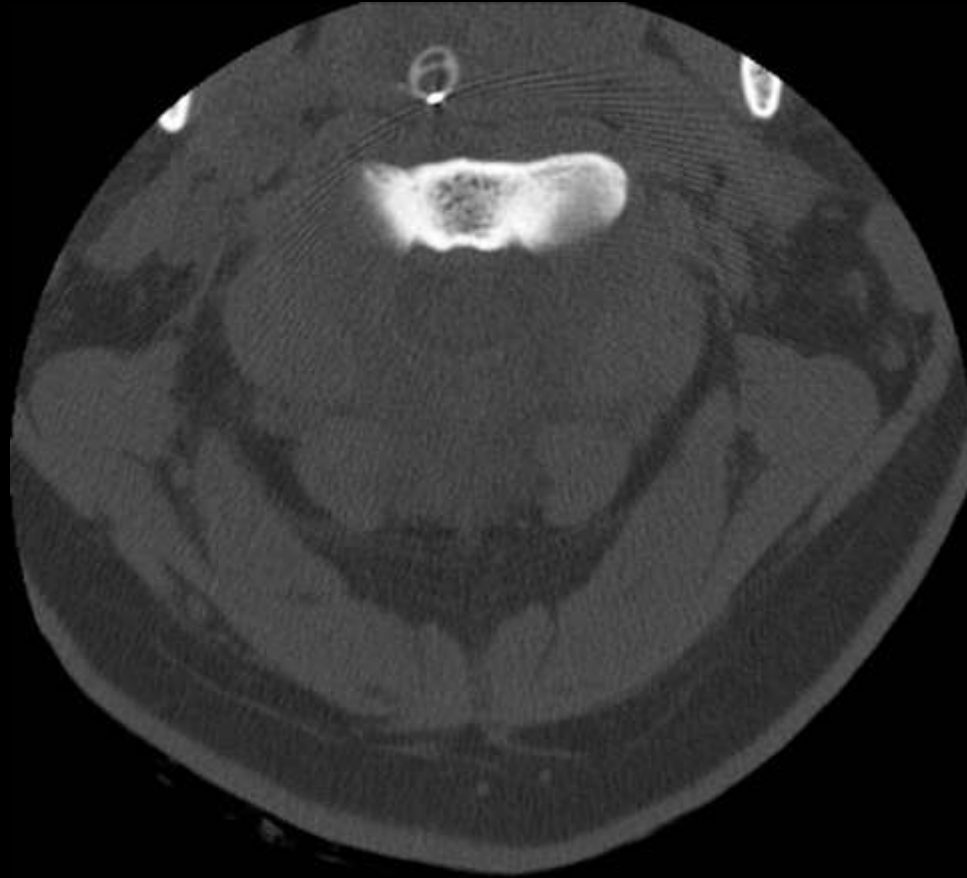
W 2000 : L 500

Occipito Axial Dislocation



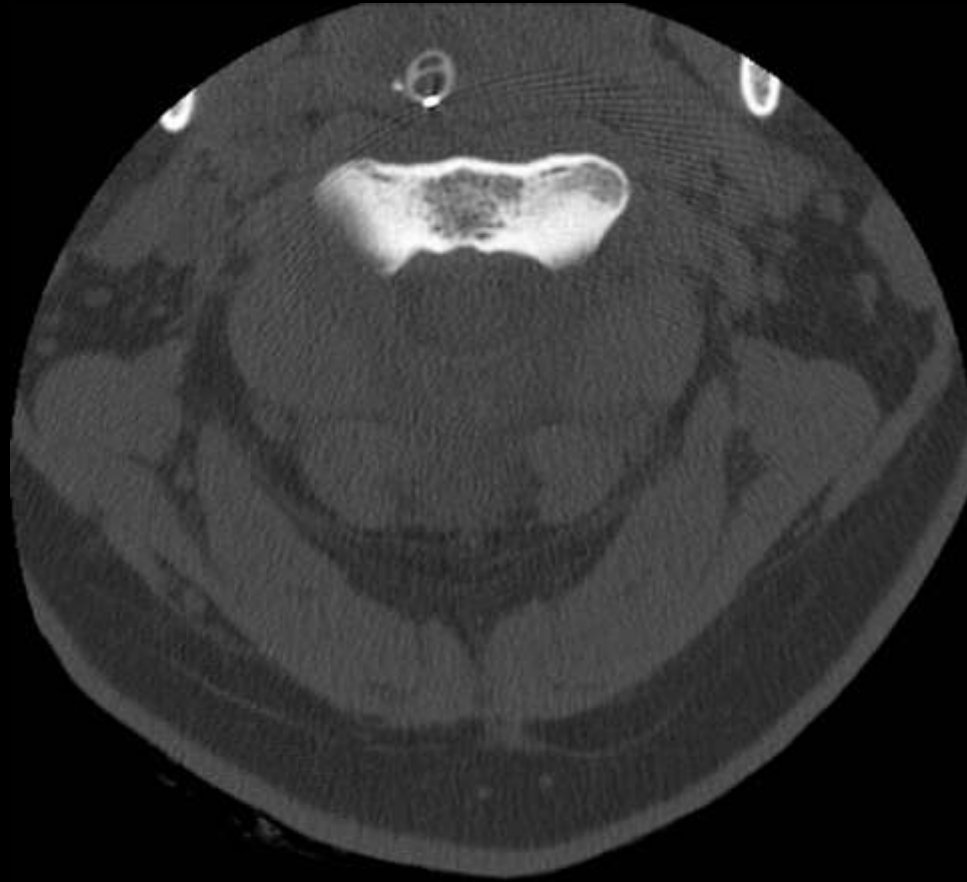
W 2000 : L 500

Occipito Axial Dislocation



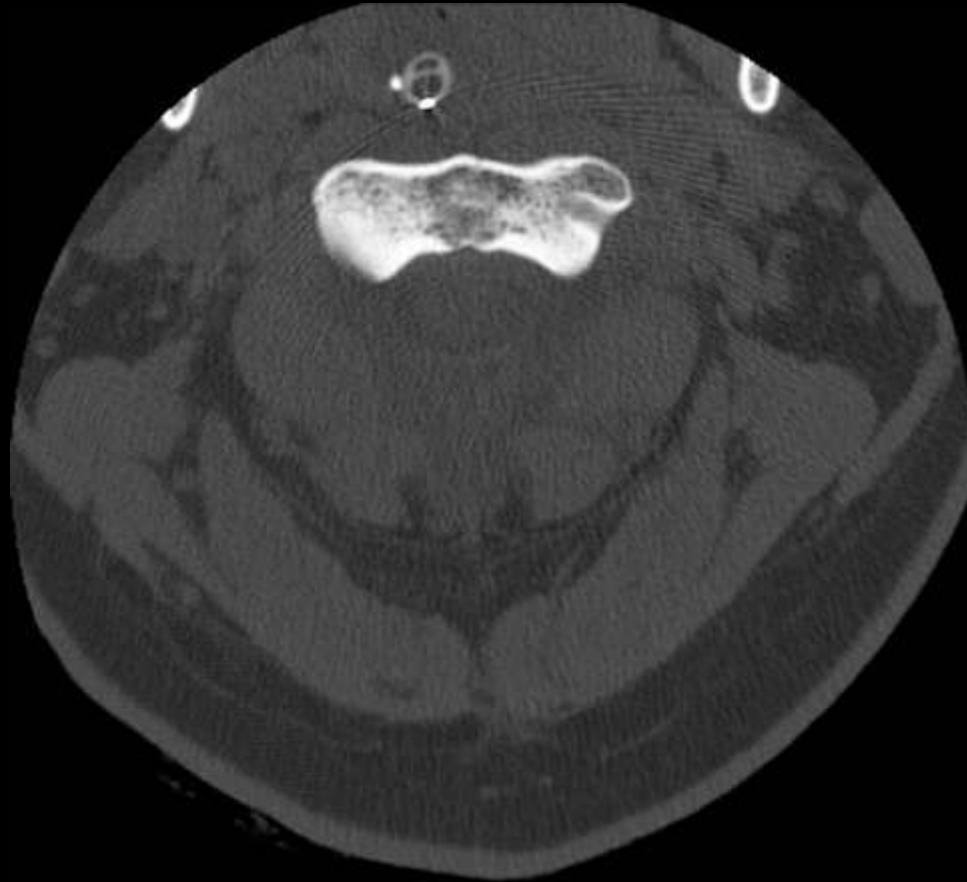W 2000 : L 500

Occipito Axial Dislocation



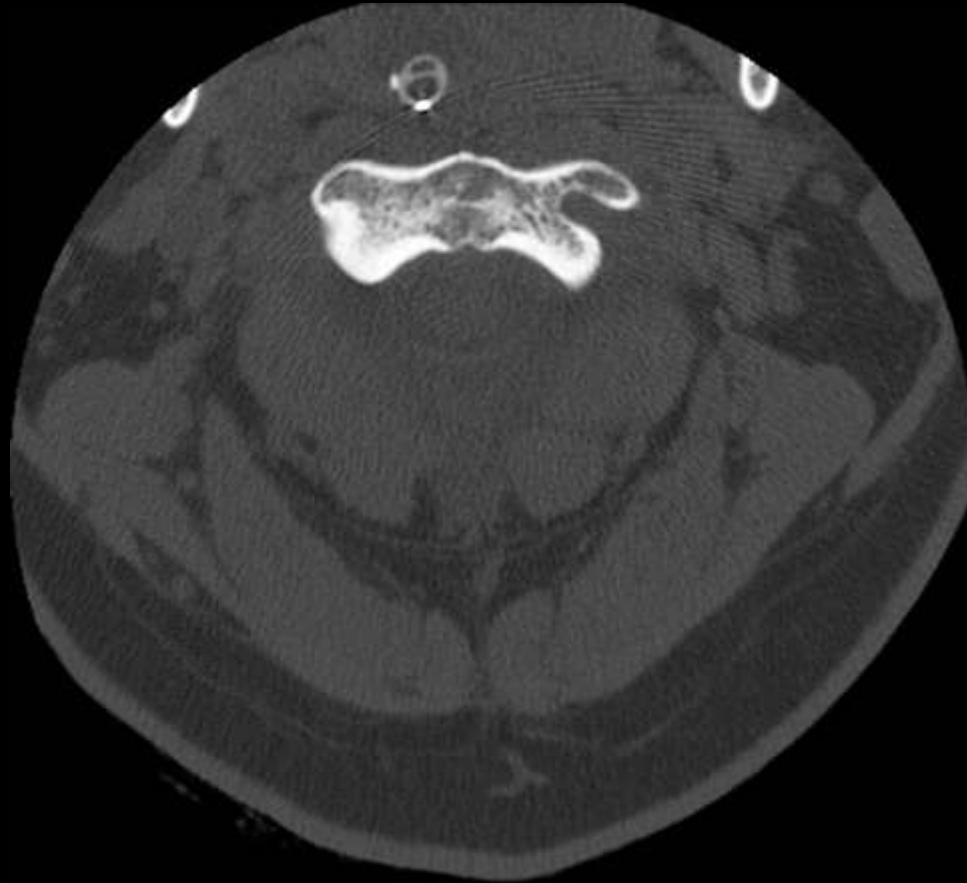W 2000 : L 500

Occipito Axial Dislocation



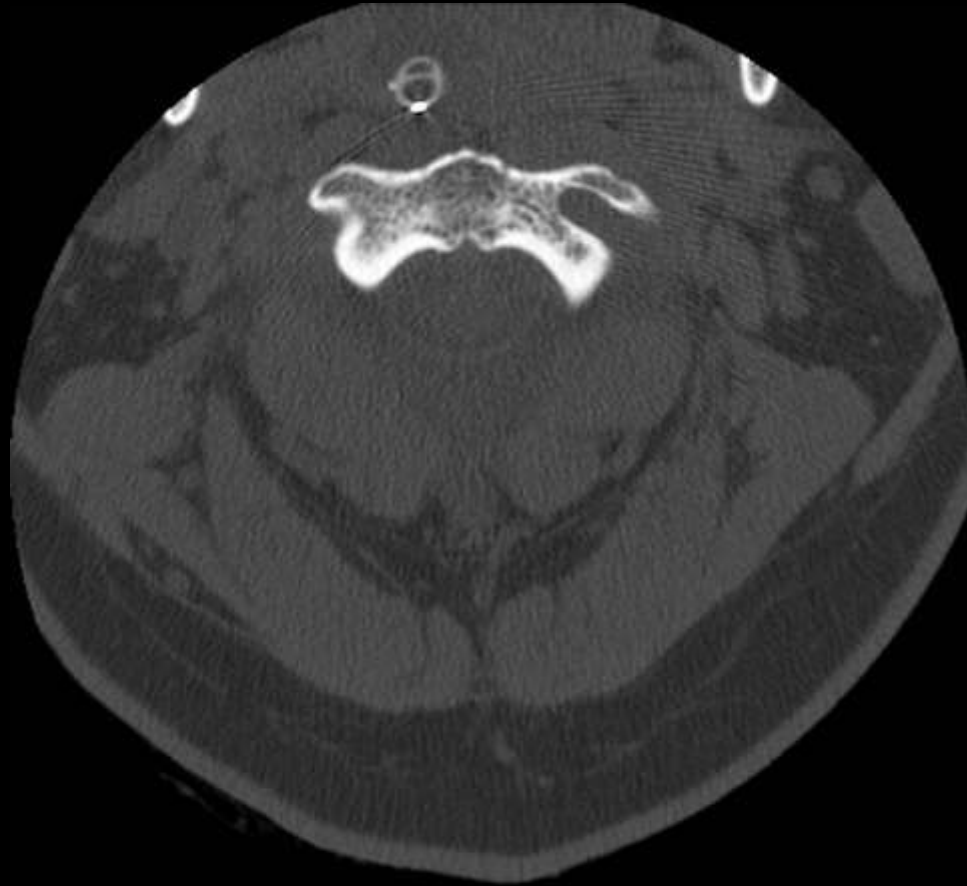
W 2000 : L 500

Occipito Axial Dislocation



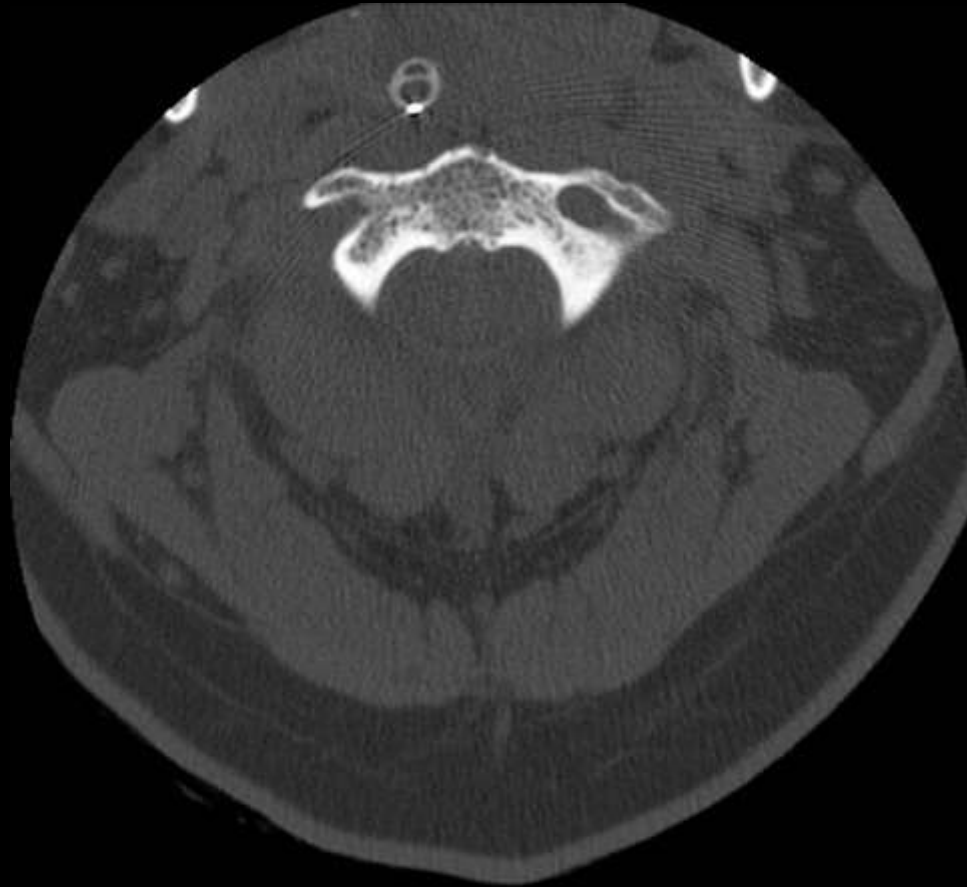W 2000 : L 500

Occipito Axial Dislocation



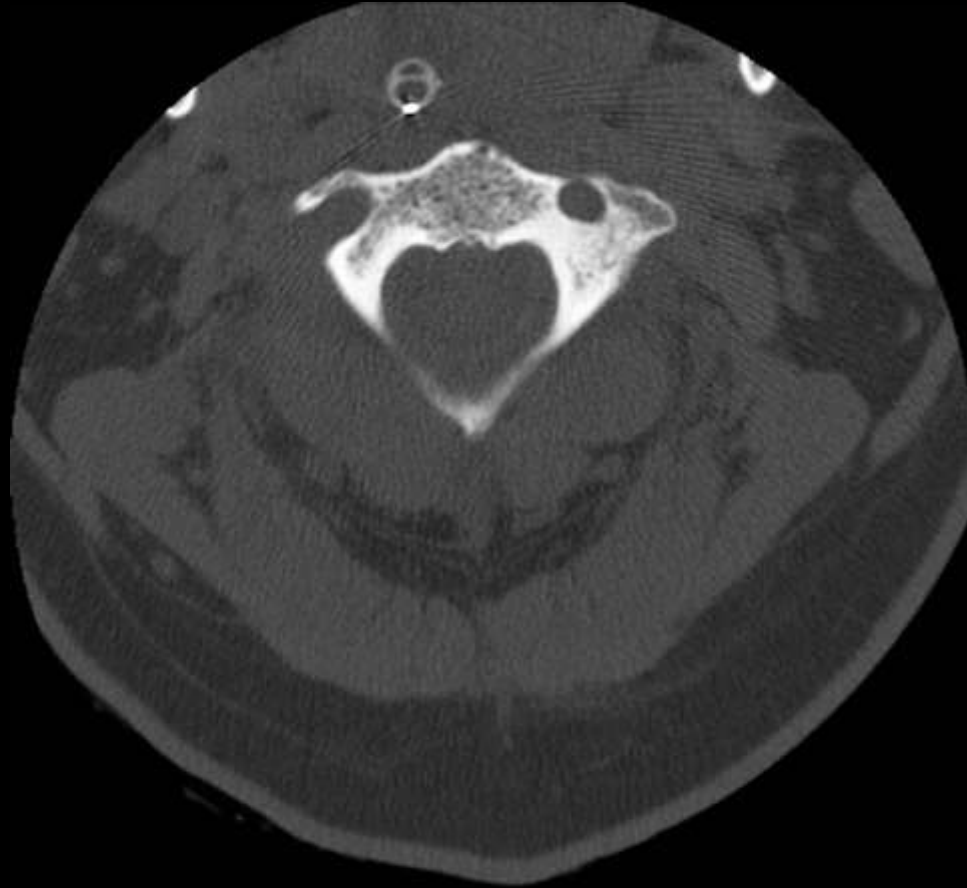
W 2000 : L 500

Occipito Axial Dislocation



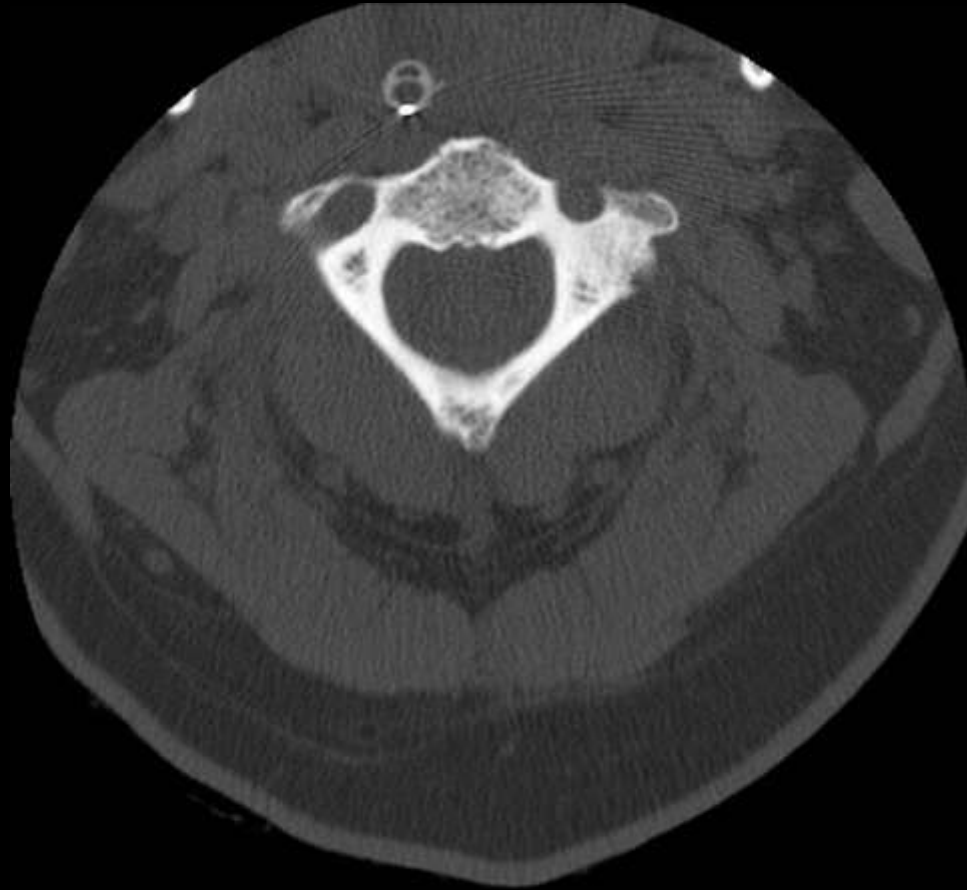
W 2000 : L 500

Occipito Axial Dislocation



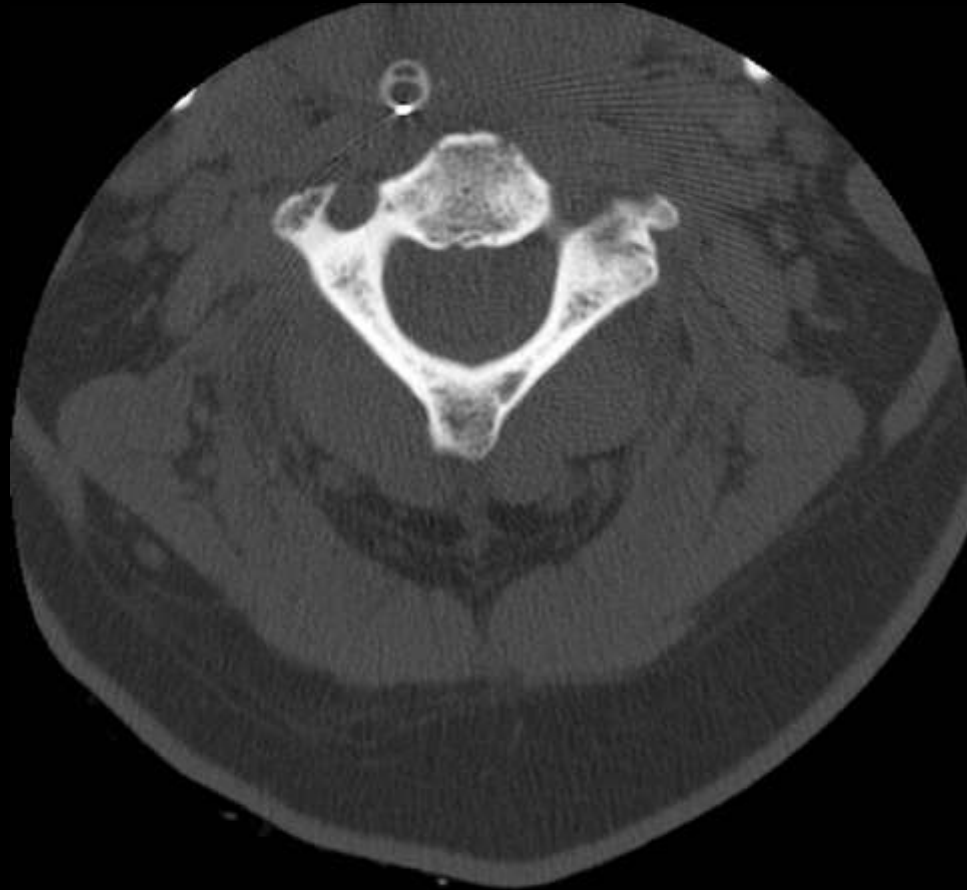
W 2000 : L 500

Occipito Axial Dislocation



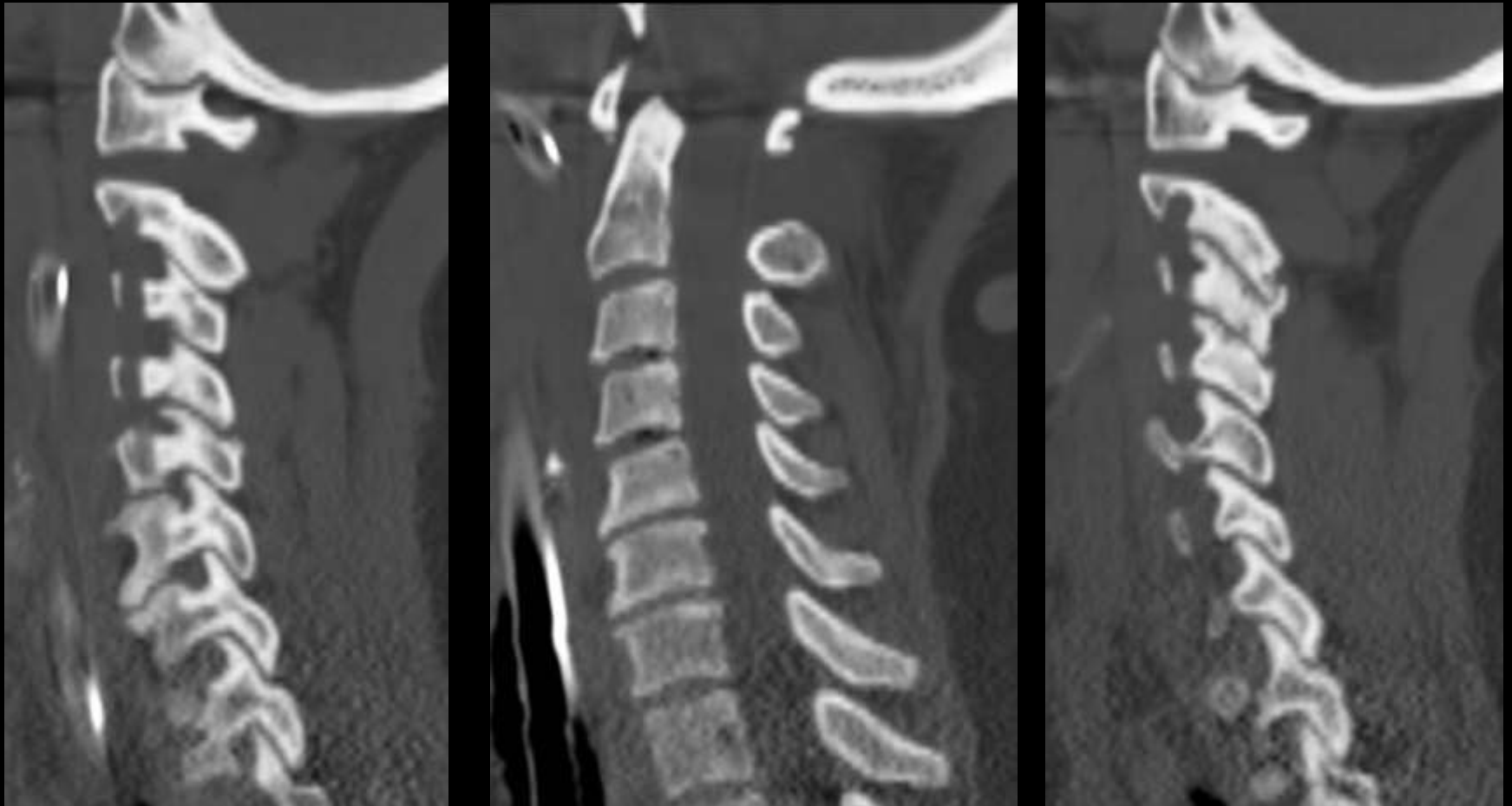W 2000 : L 500

Occipito Axial Dislocation

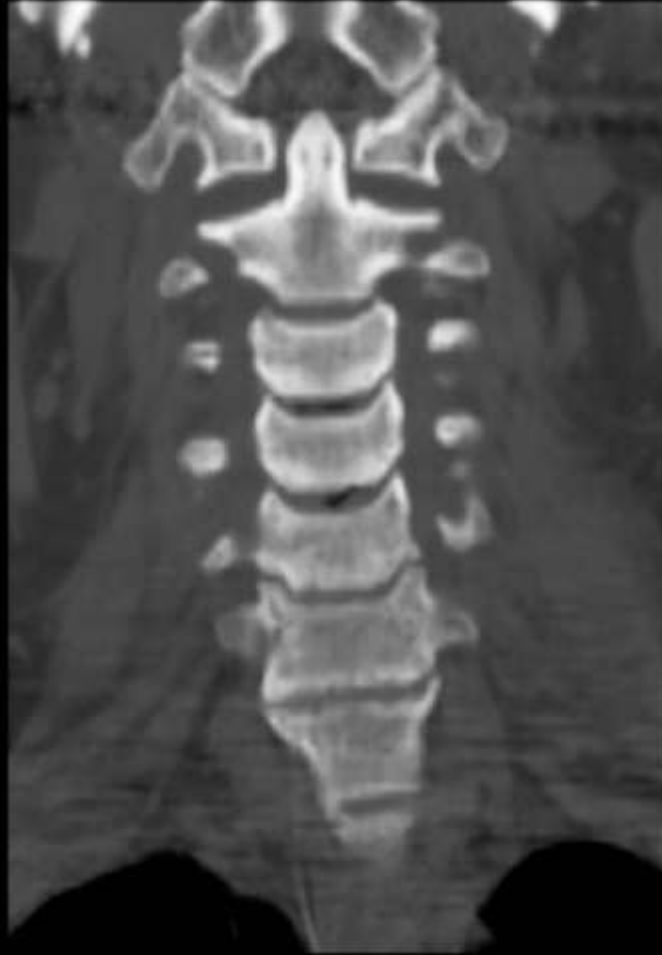

W 2000 : L 500

Occipito Axial Dislocation

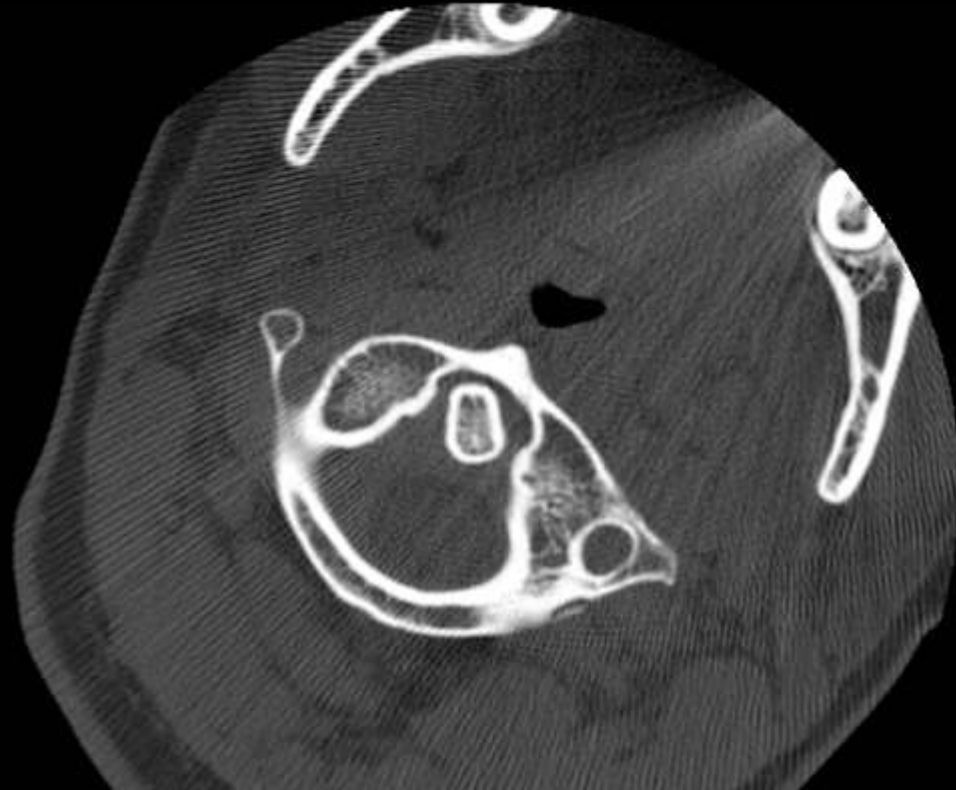


Occipito Axial Dislocation



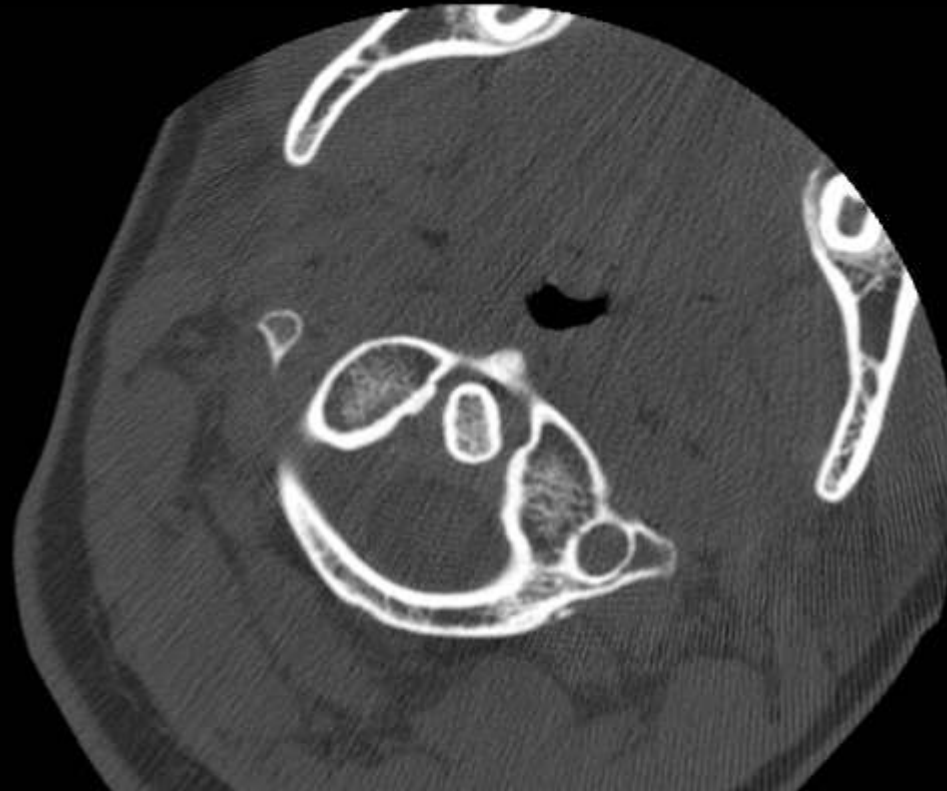
Rotary C1-2 Dislocation/Fixation

28



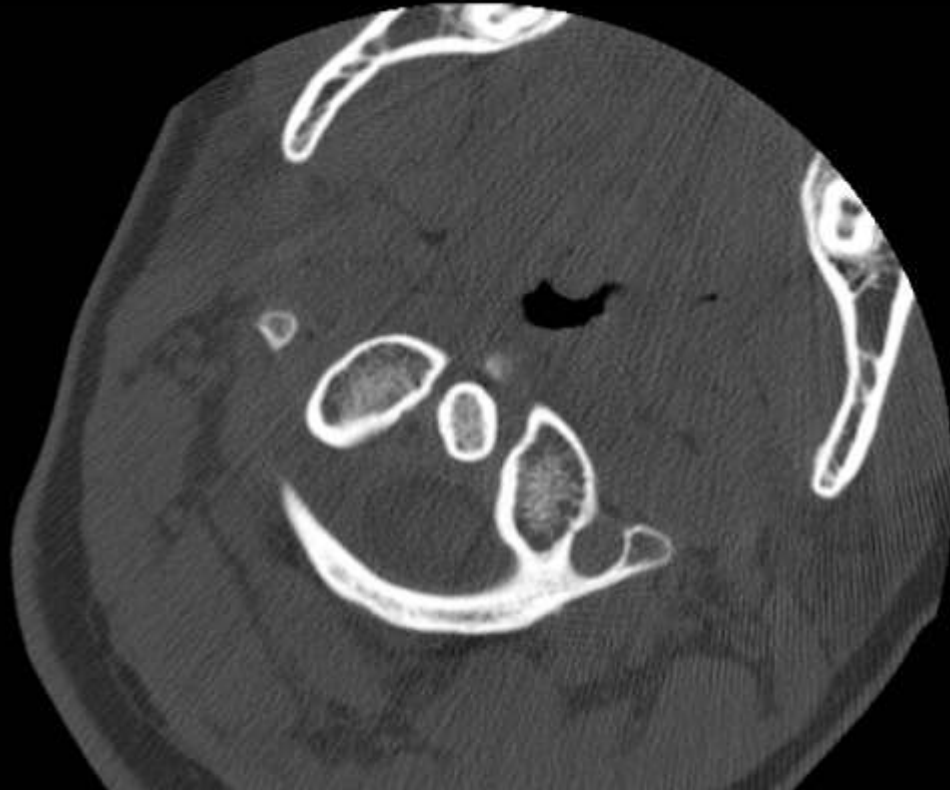
Rotary C1-2 Dislocation/Fixation

29



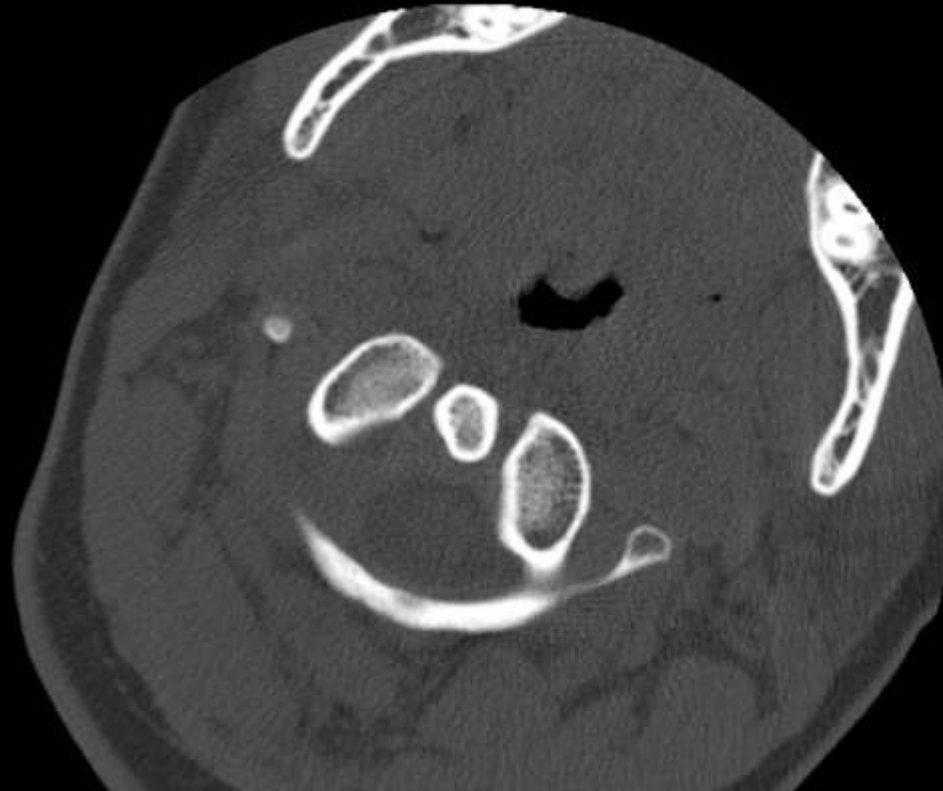Rotary C1-2 Dislocation/Fixation

30



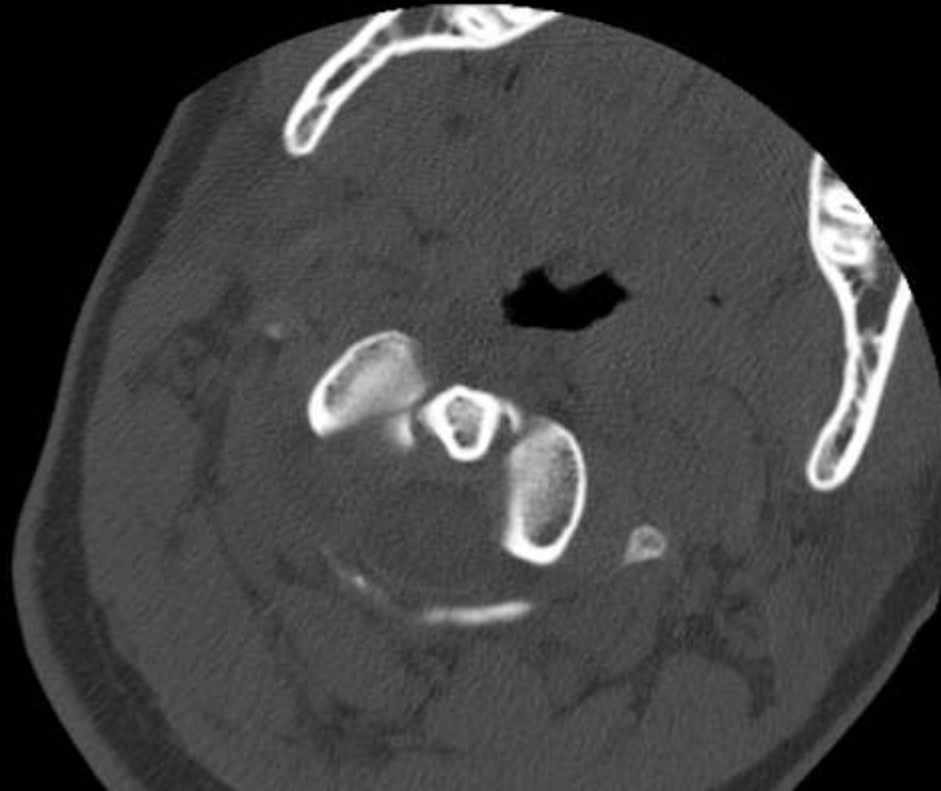
Rotary C1-2 Dislocation/Fixation

31



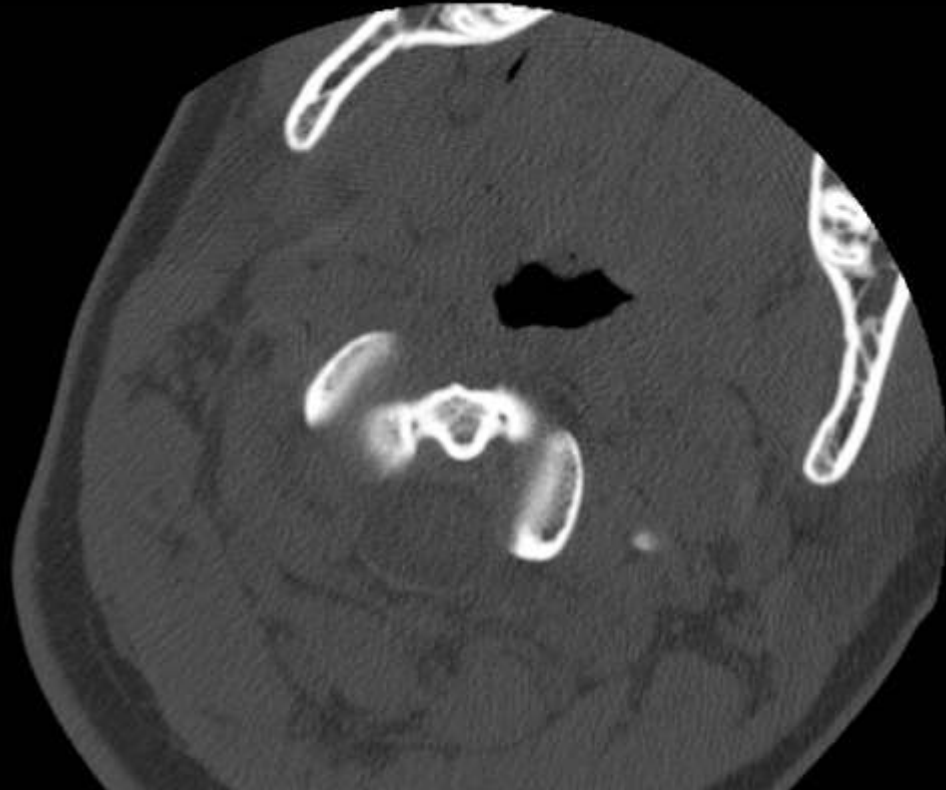
Rotary C1-2 Dislocation/Fixation

32



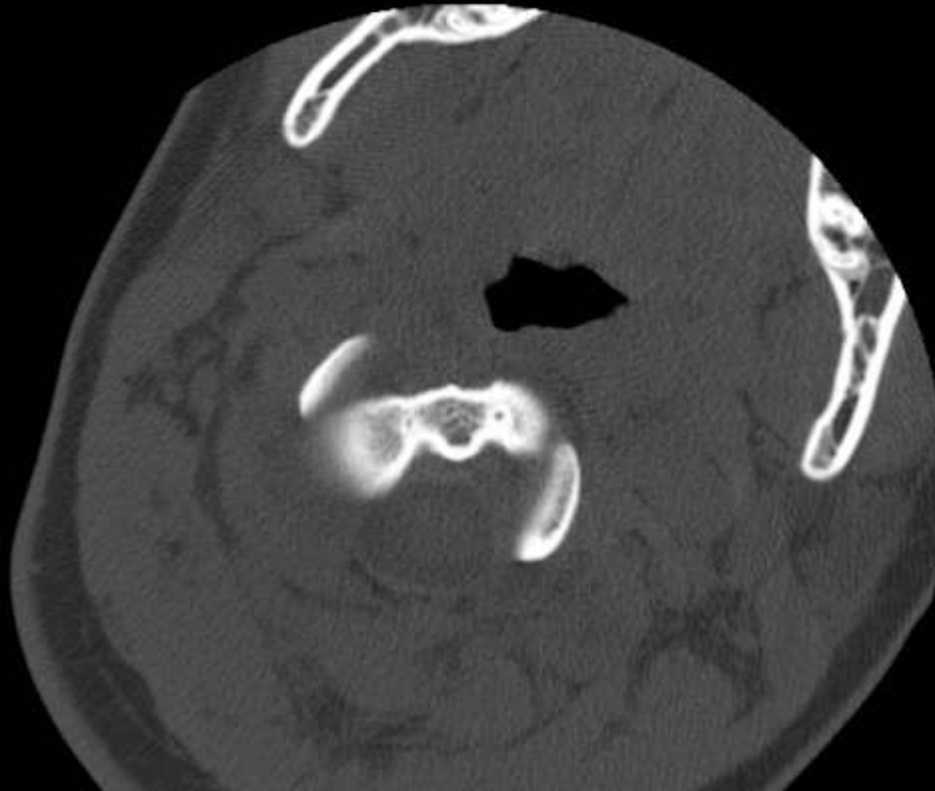
Rotary C1-2 Dislocation/Fixation

33



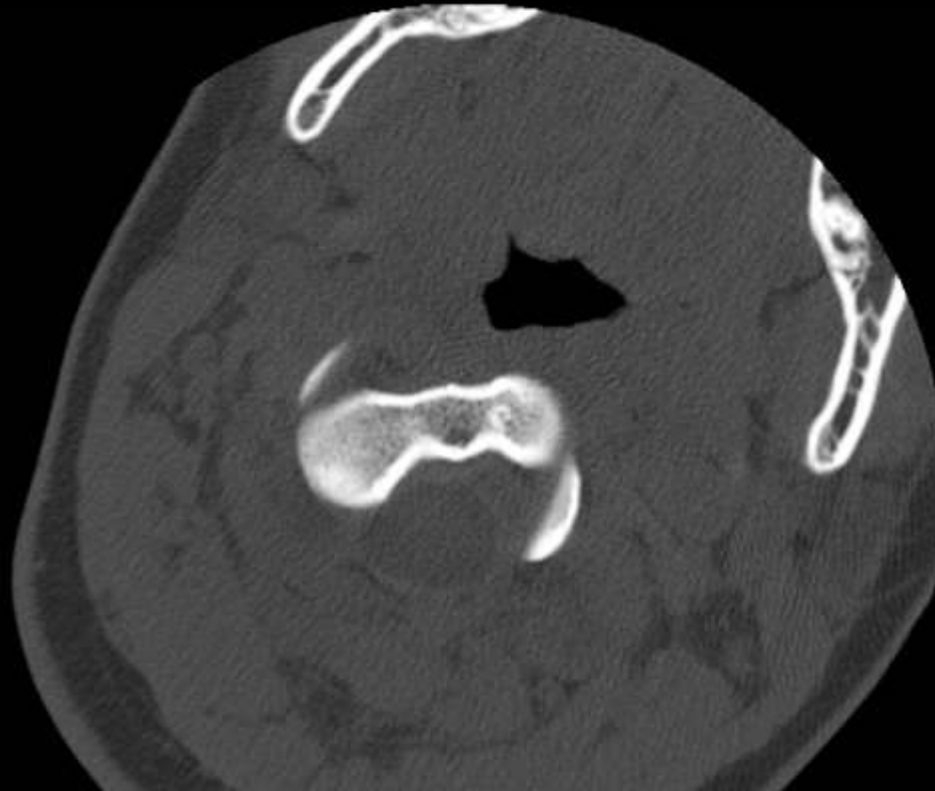
Rotary C1-2 Dislocation/Fixation

34



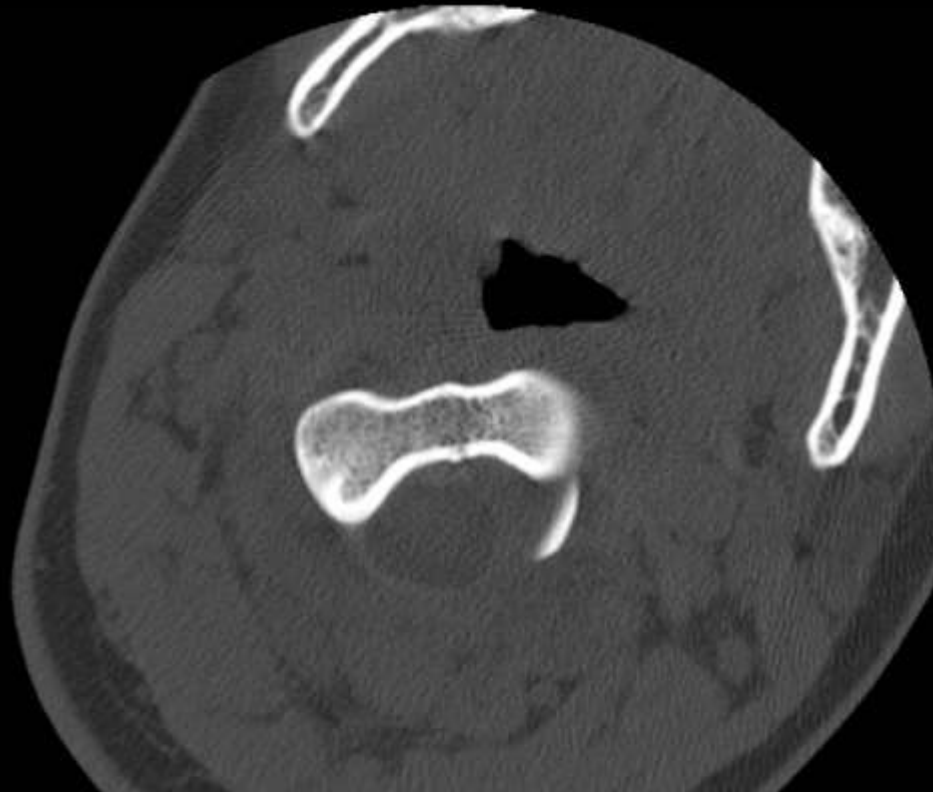Rotary C1-2 Dislocation/Fixation

35



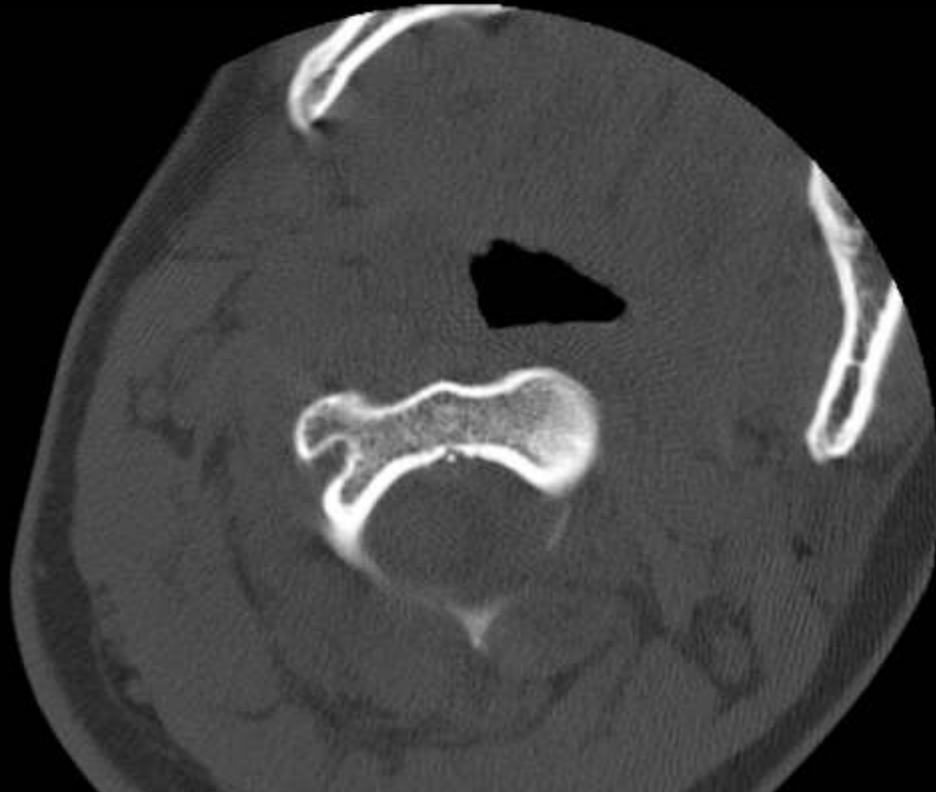
Rotary C1-2 Dislocation/Fixation

36



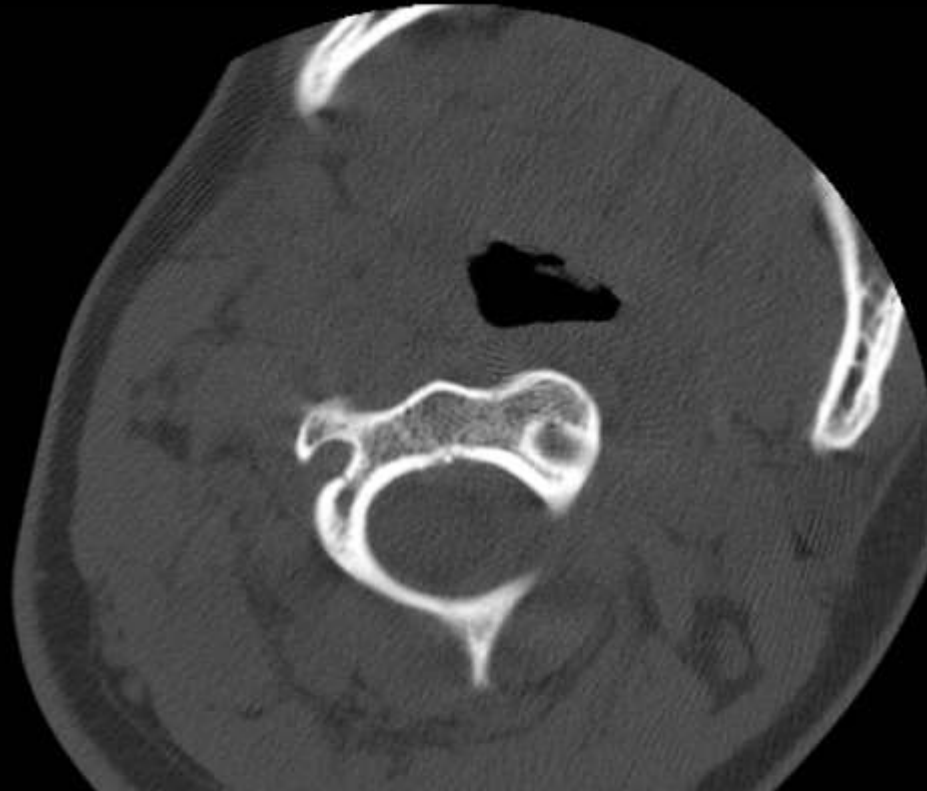
Rotary C1-2 Dislocation/Fixation

37



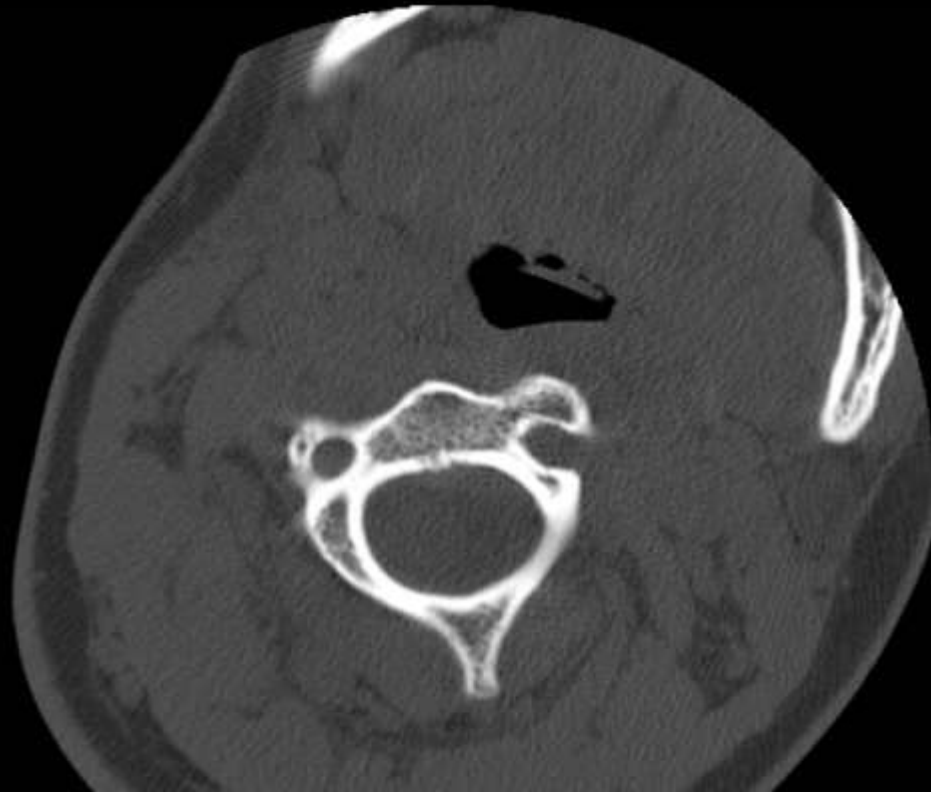Rotary C1-2 Dislocation/Fixation

38



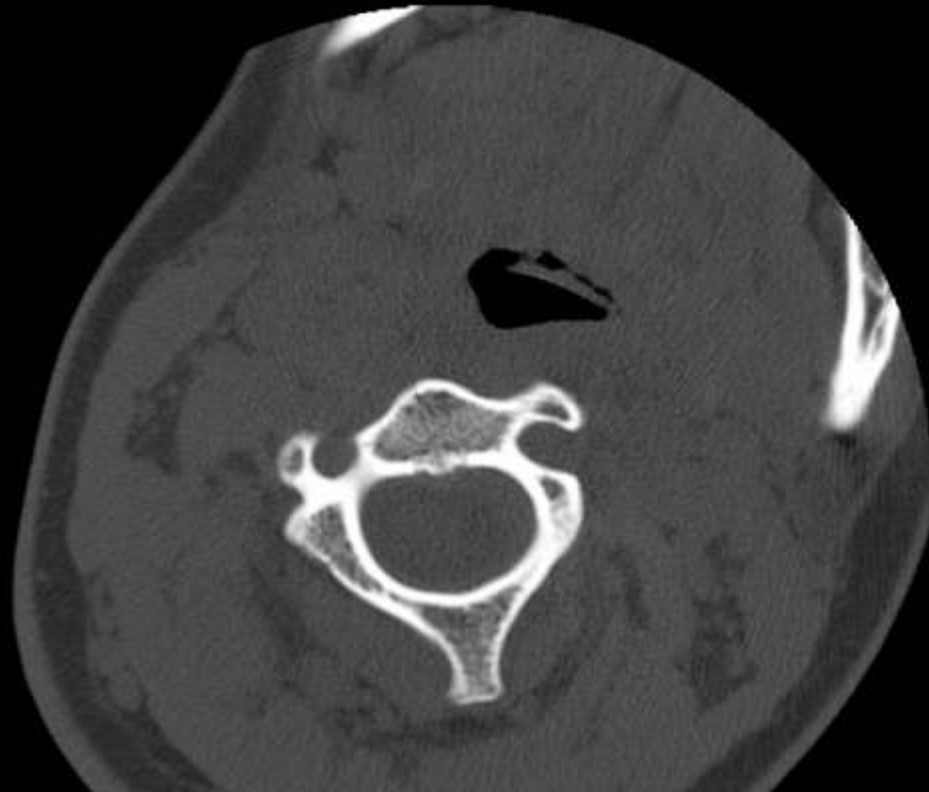
Rotary C1-2 Dislocation/Fixation

39

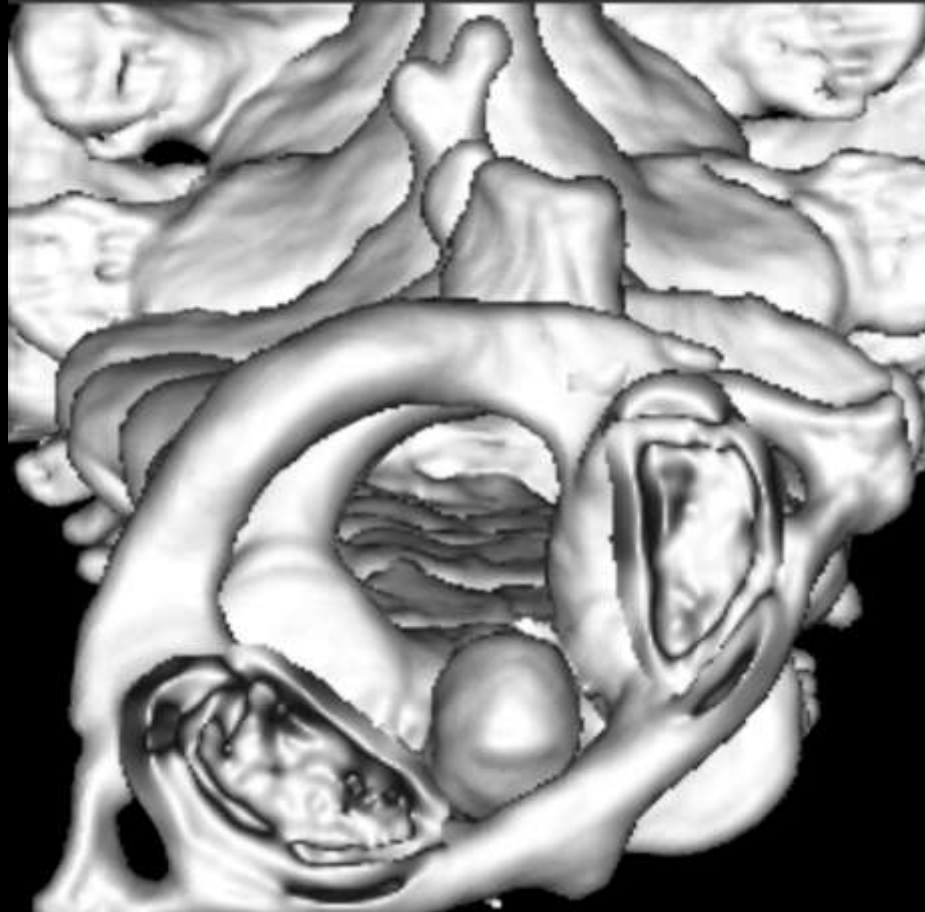


Rotary C1-2 Dislocation/Fixation

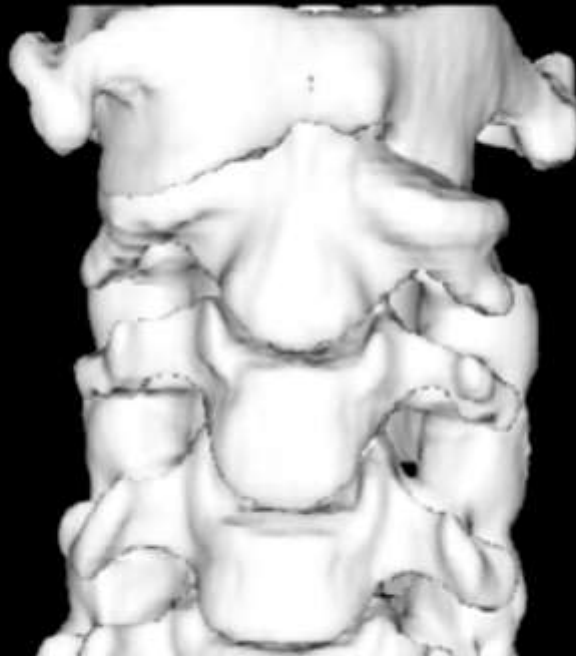40



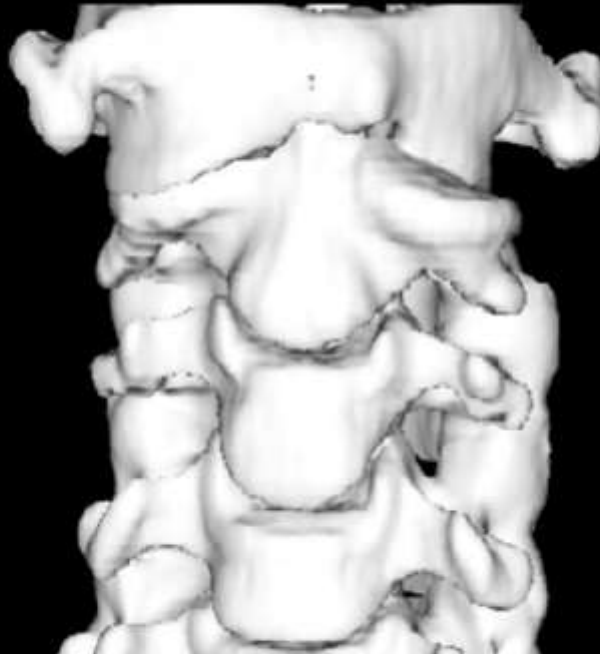Rotary C1-2 Dislocation/Fixation



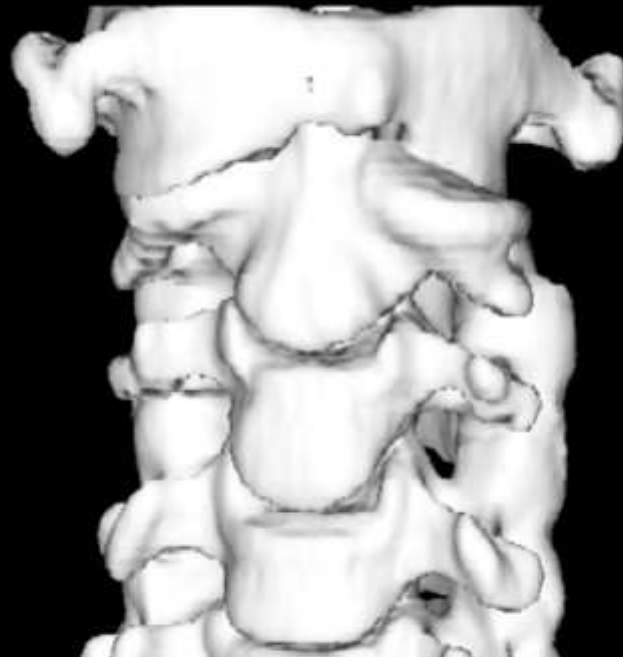Rotary C1-2 Dislocation/Fixation



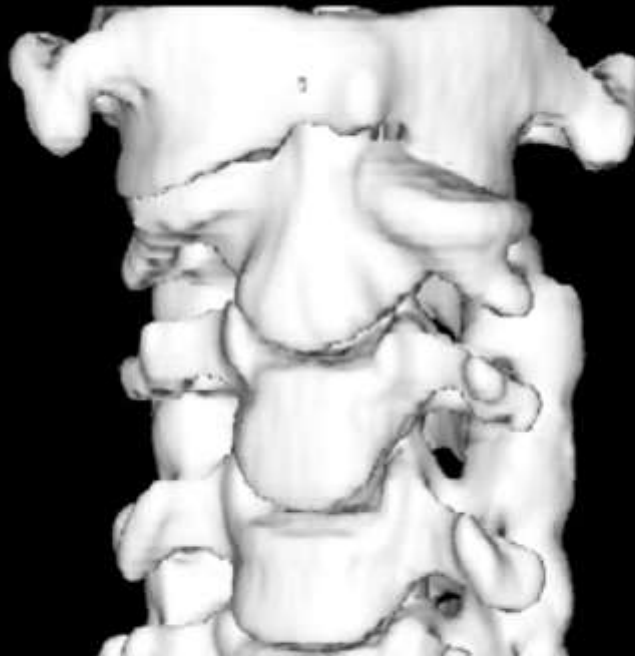Rotary C1-2 Dislocation/Fixation



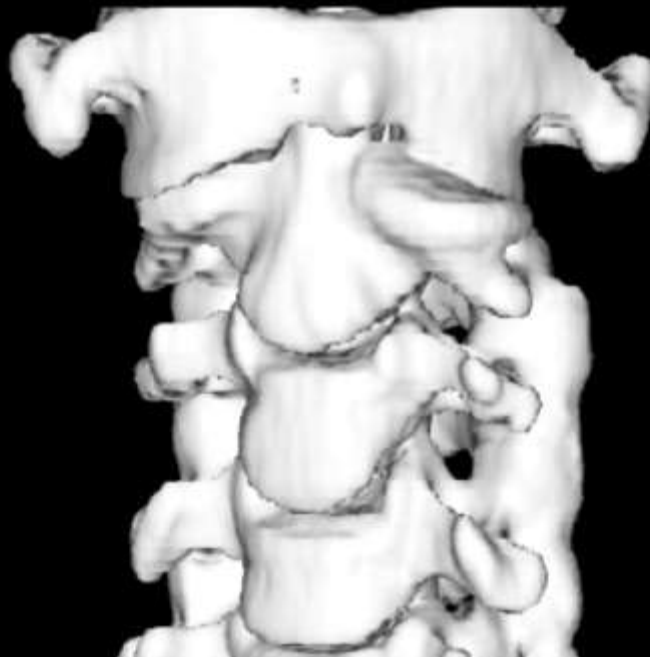
Rotary C1-2 Dislocation/Fixation



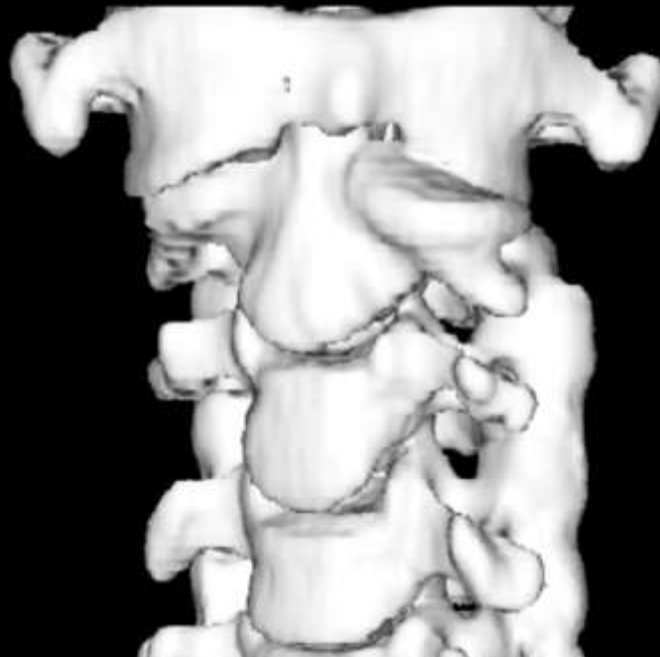
Rotary C1-2 Dislocation/Fixation



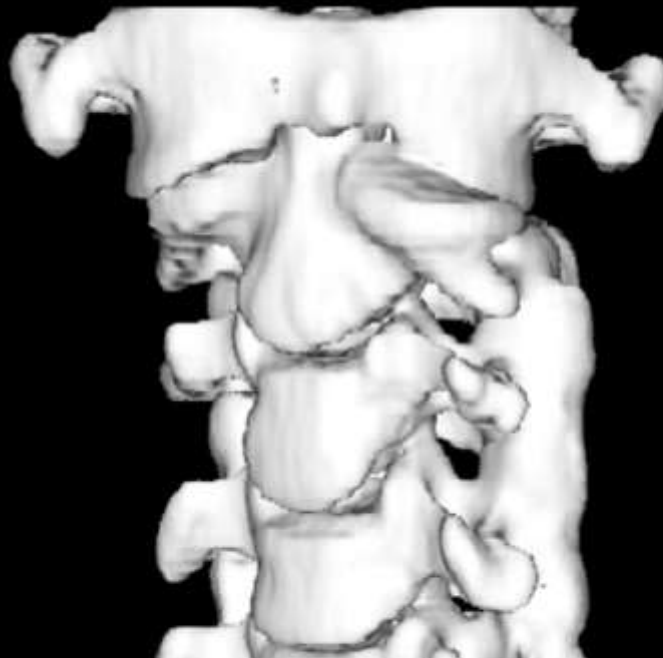
Rotary C1-2 Dislocation/Fixation



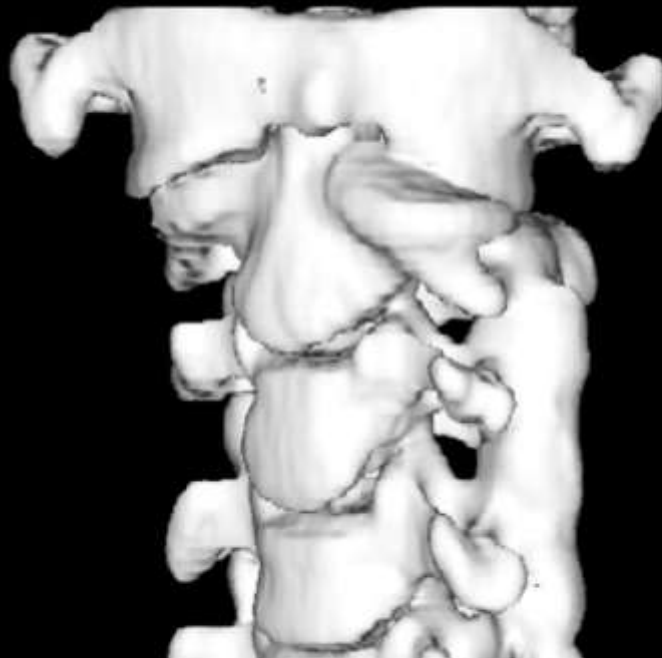
Rotary C1-2 Dislocation/Fixation



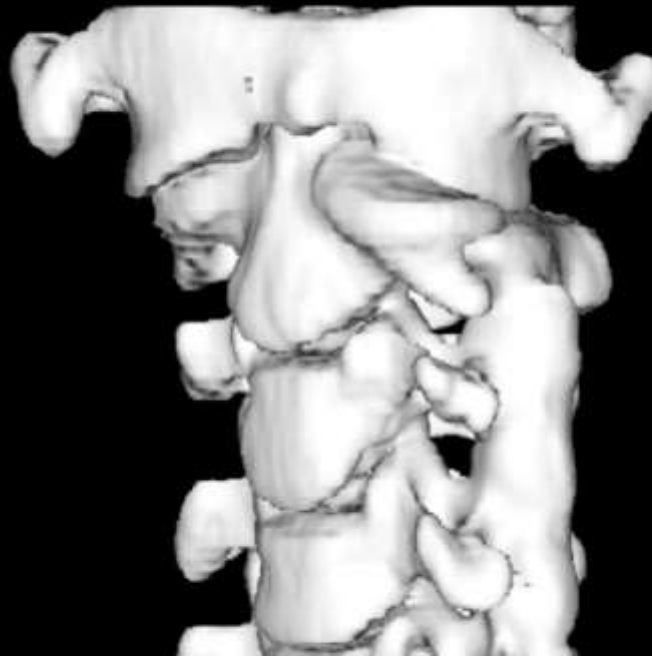Rotary C1-2 Dislocation/Fixation



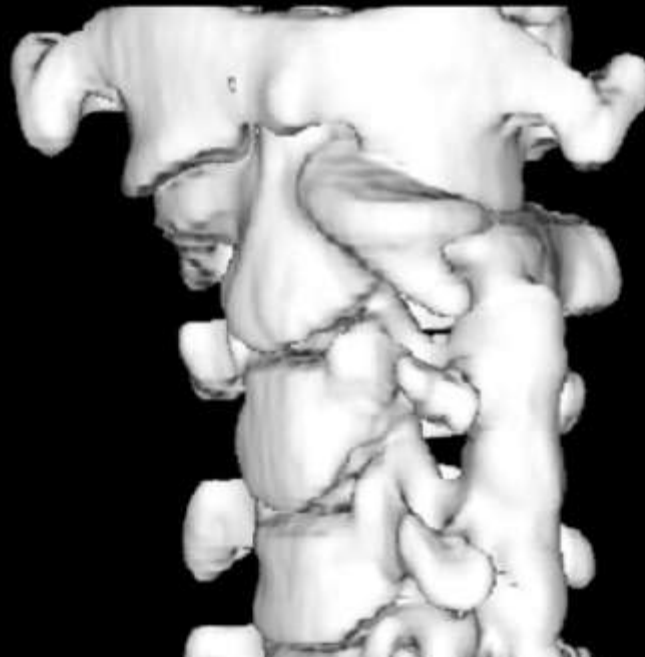
Rotary C1-2 Dislocation/Fixation



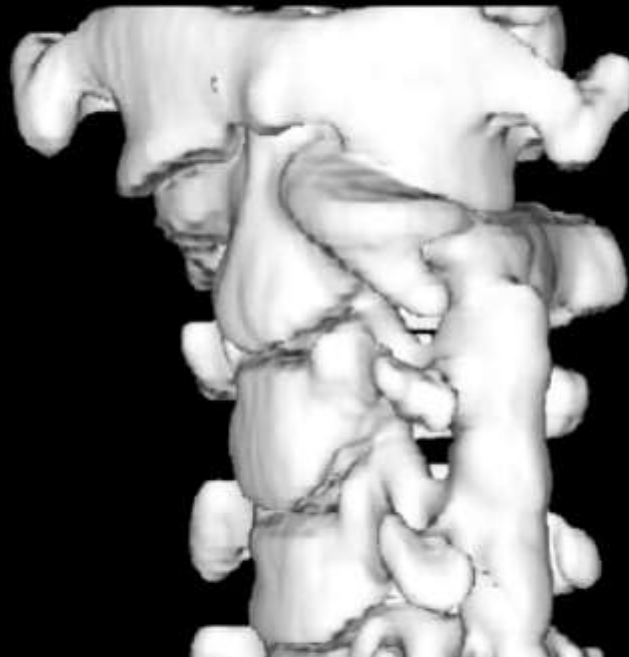
Rotary C1-2 Dislocation/Fixation



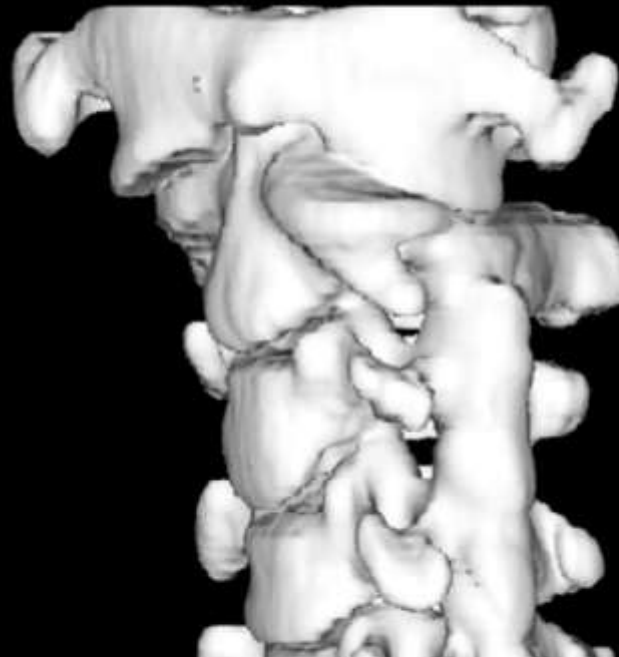
Rotary C1-2 Dislocation/Fixation



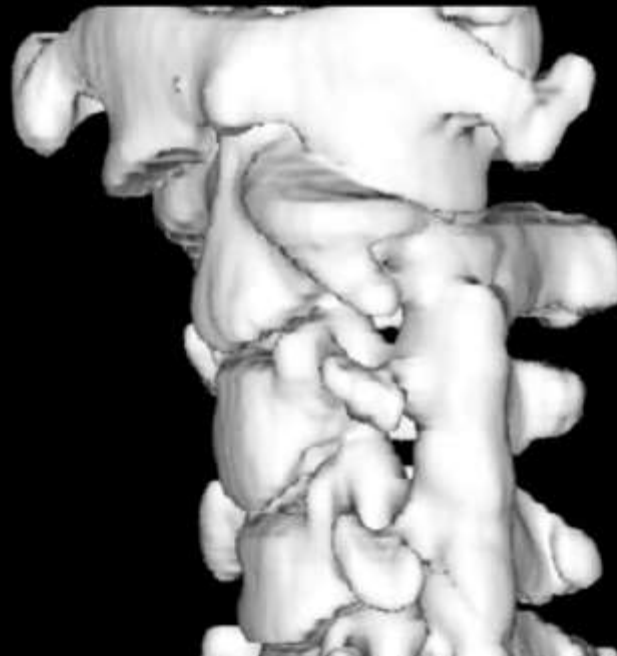Rotary C1-2 Dislocation/Fixation



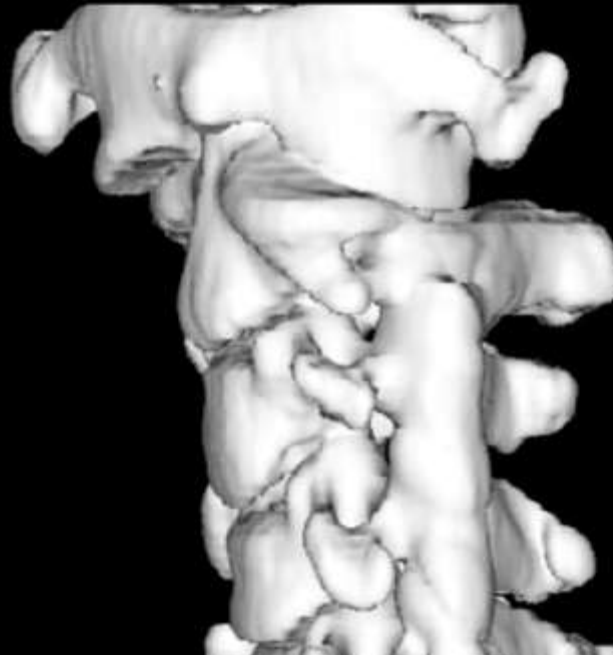
Rotary C1-2 Dislocation/Fixation



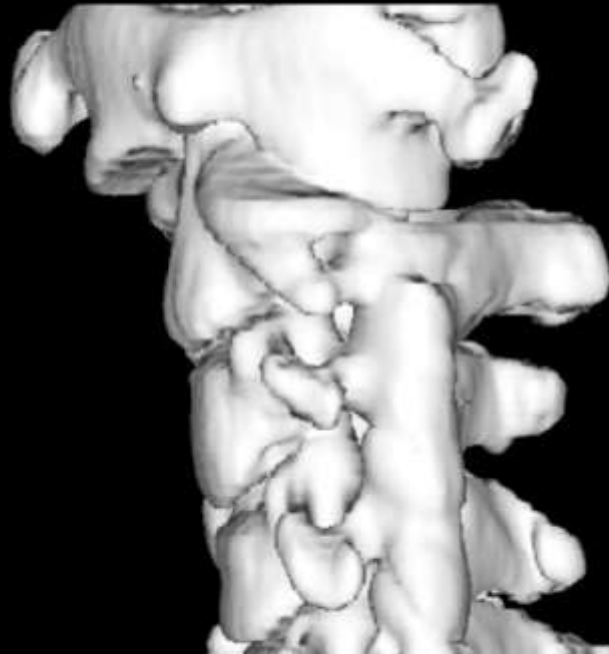
Rotary C1-2 Dislocation/Fixation



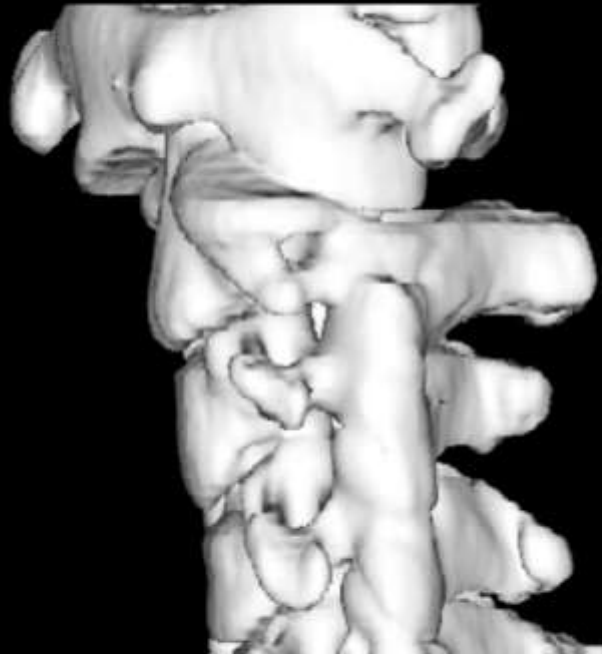Rotary C1-2 Dislocation/Fixation



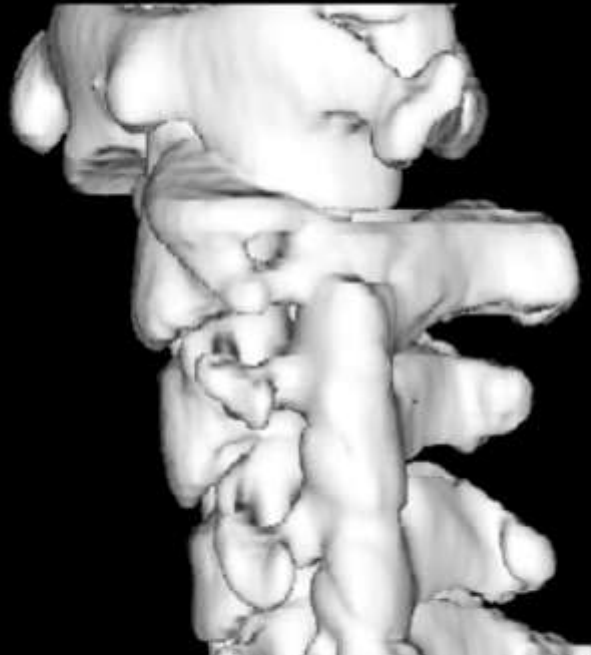Rotary C1-2 Dislocation/Fixation



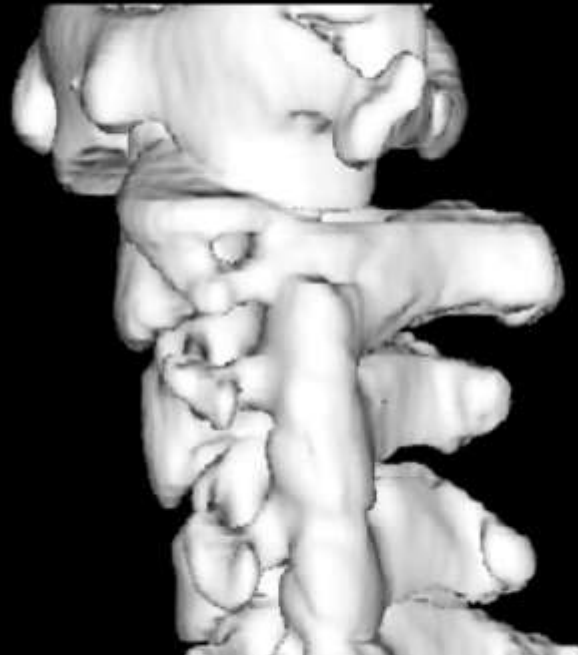Rotary C1-2 Dislocation/Fixation



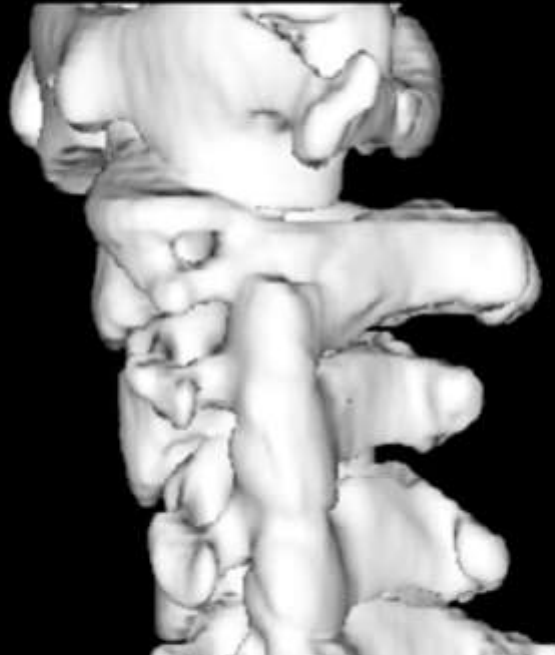Rotary C1-2 Dislocation/Fixation



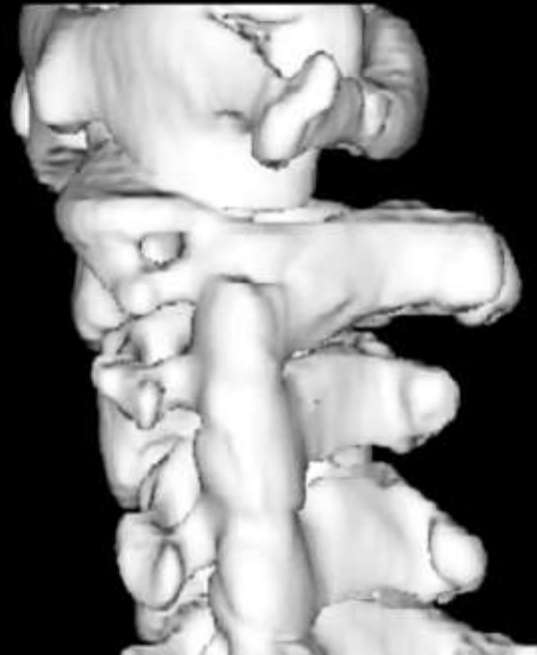Rotary C1-2 Dislocation/Fixation



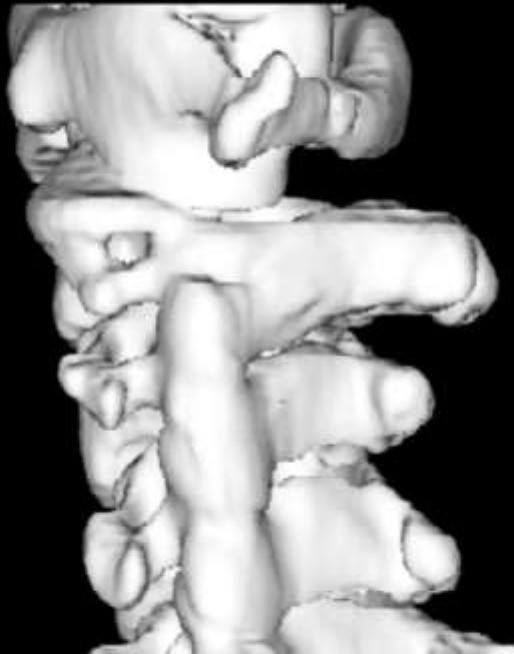Rotary C1-2 Dislocation/Fixation



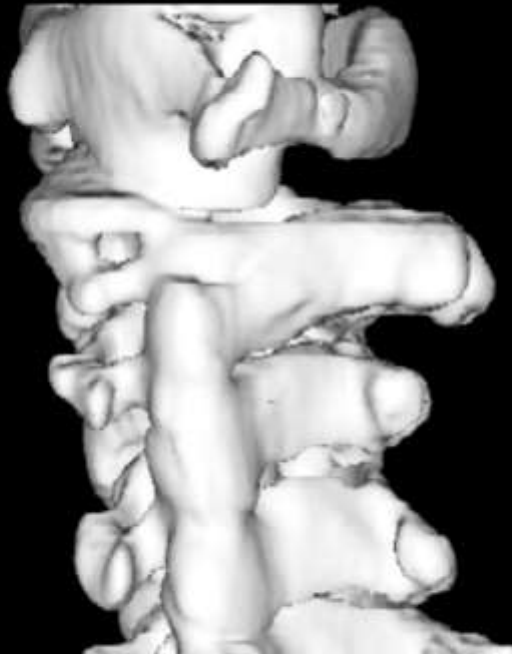Rotary C1-2 Dislocation/Fixation



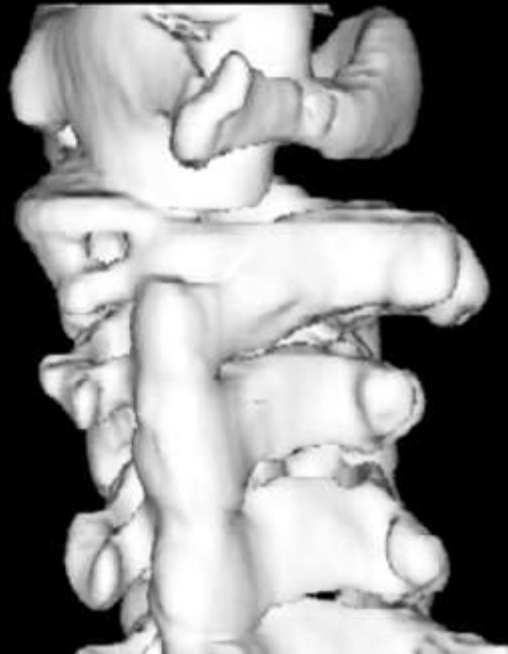Rotary C1-2 Dislocation/Fixation



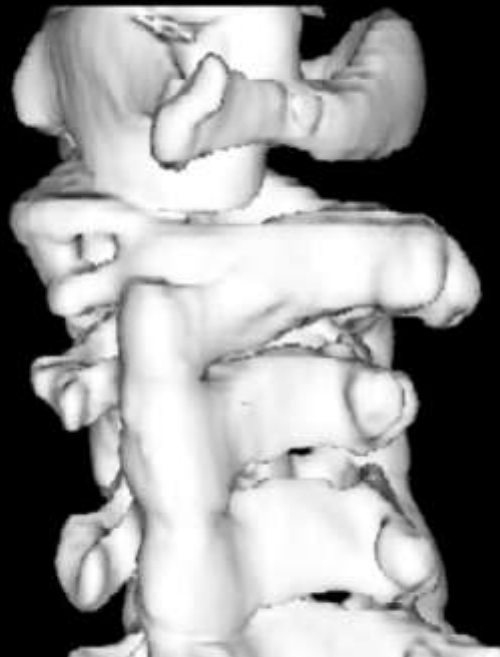Rotary C1-2 Dislocation/Fixation



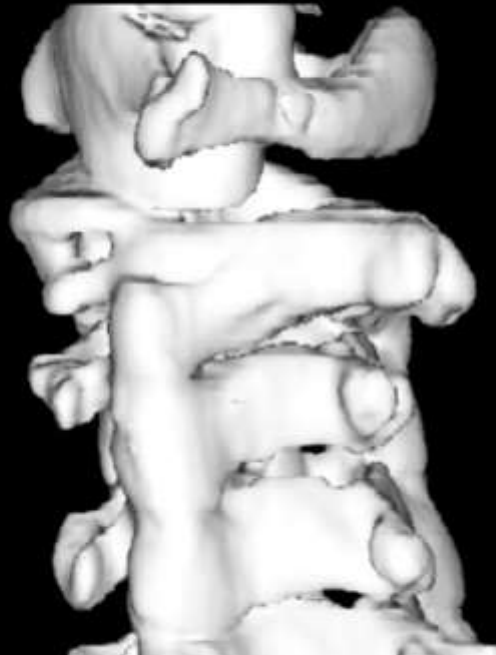Rotary C1-2 Dislocation/Fixation



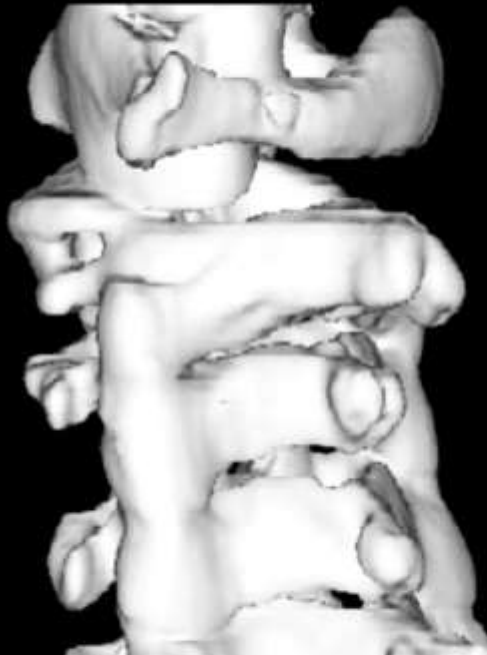Rotary C1-2 Dislocation/Fixation



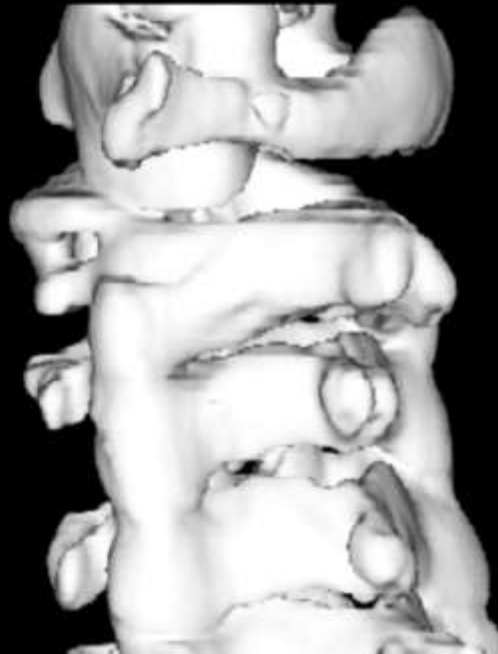Rotary C1-2 Dislocation/Fixation



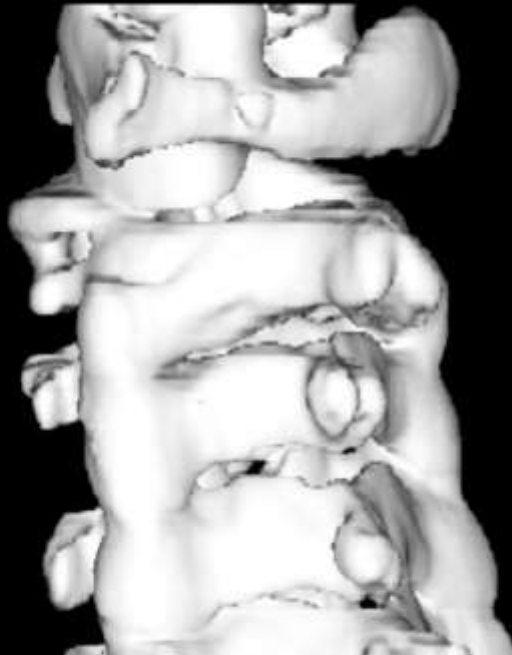
Rotary C1-2 Dislocation/Fixation



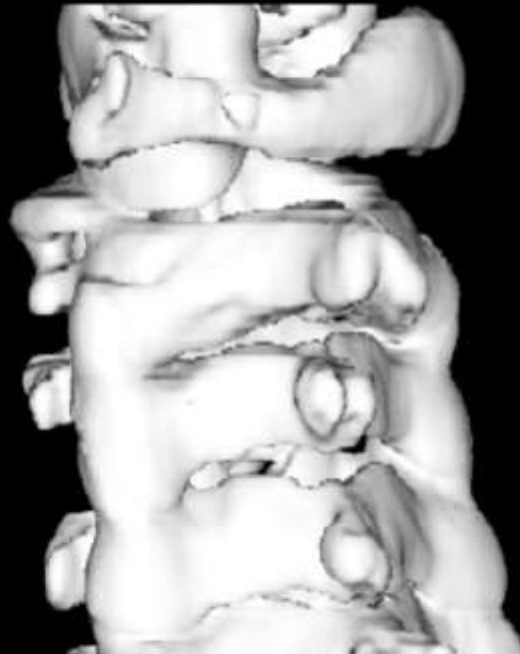
Rotary C1-2 Dislocation/Fixation



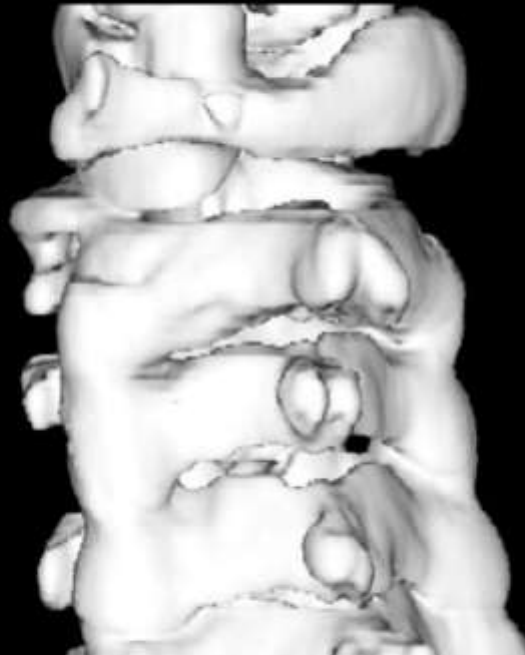
Rotary C1-2 Dislocation/Fixation



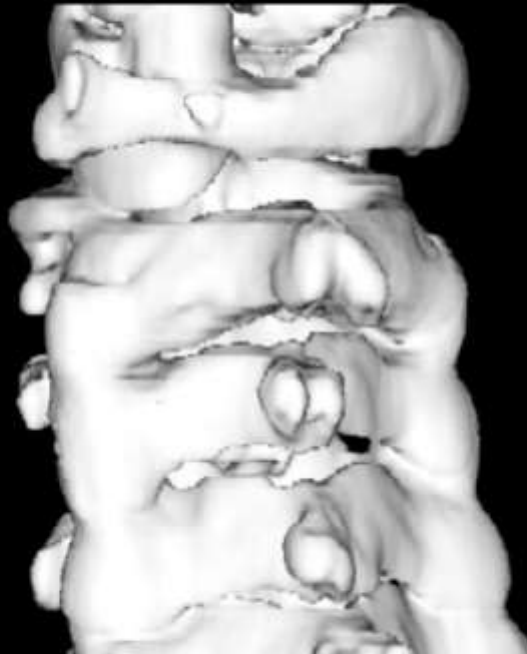
Rotary C1-2 Dislocation/Fixation



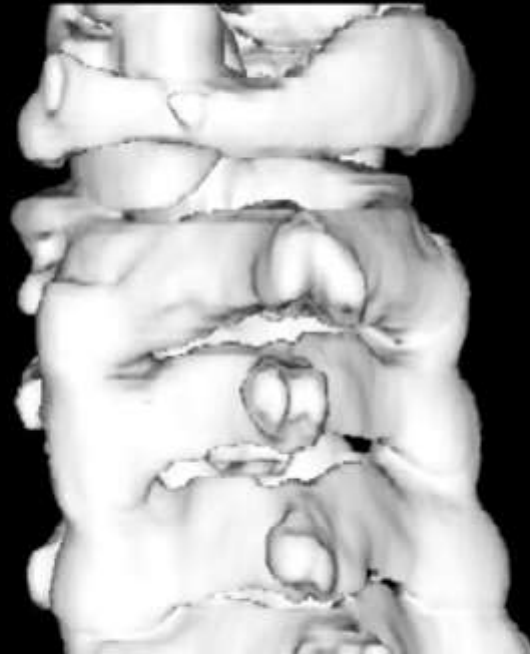
Rotary C1-2 Dislocation/Fixation



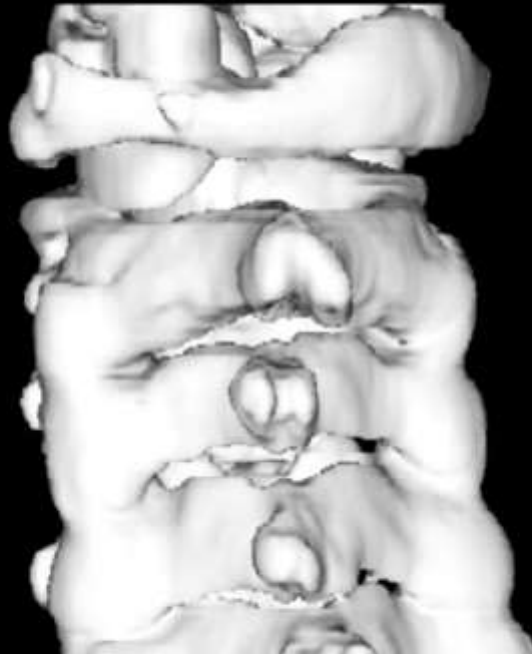
Rotary C1-2 Dislocation/Fixation



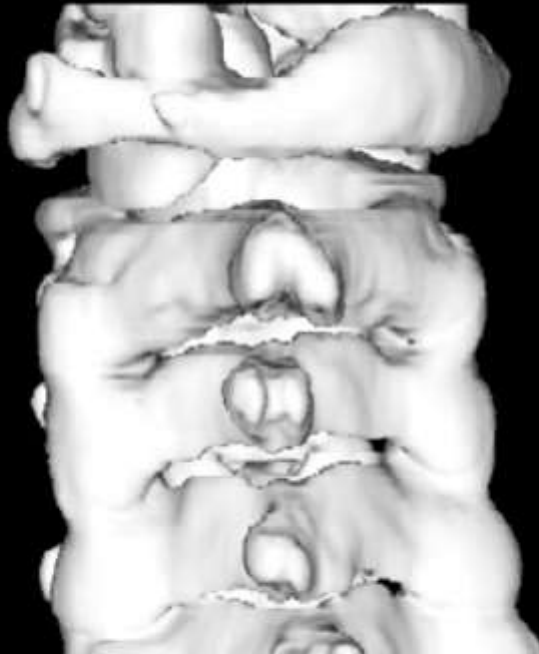Rotary C1-2 Dislocation/Fixation



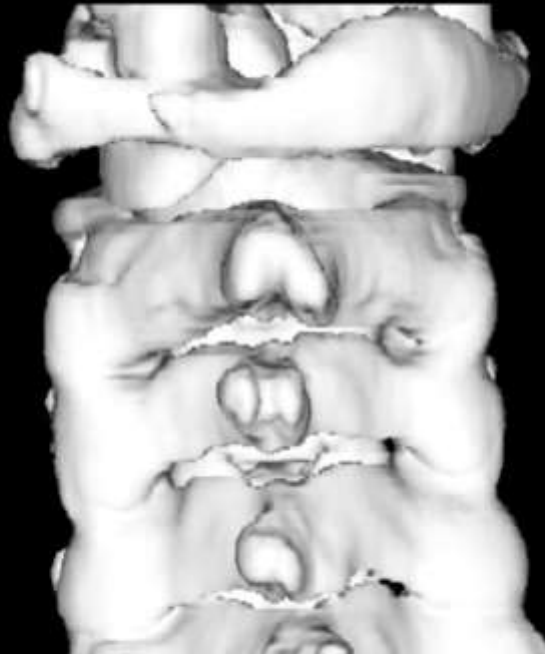Rotary C1-2 Dislocation/Fixation



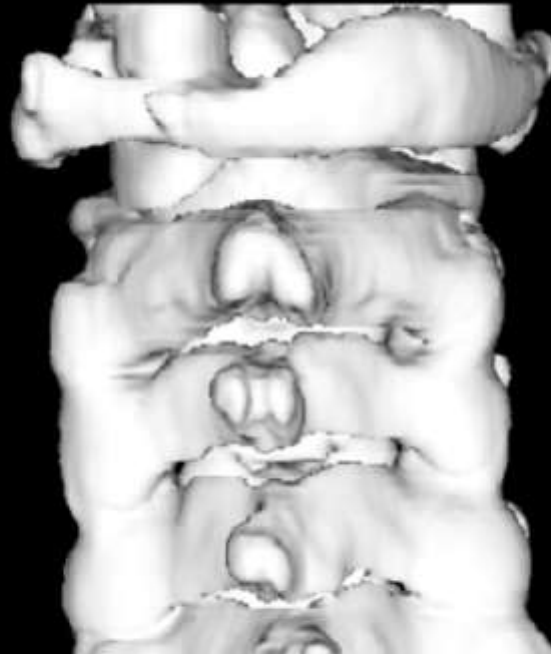Rotary C1-2 Dislocation/Fixation



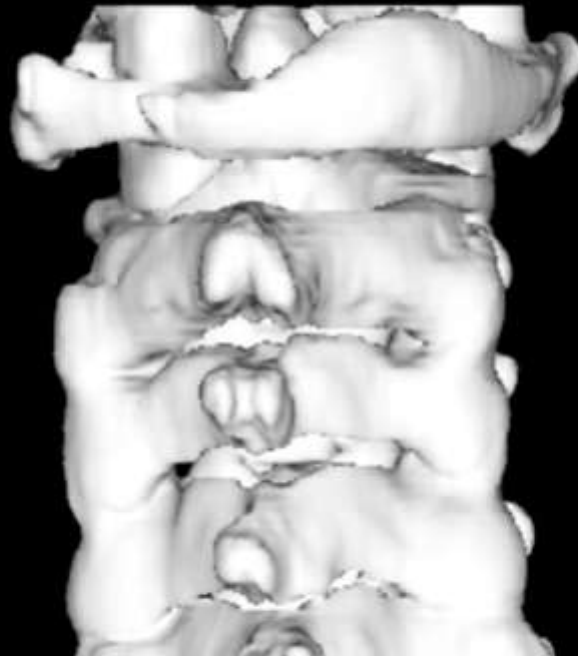
Rotary C1-2 Dislocation/Fixation



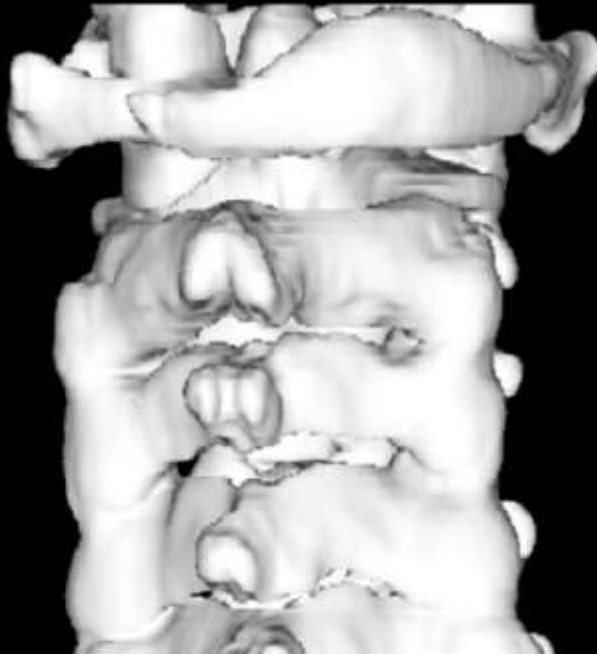Rotary C1-2 Dislocation/Fixation



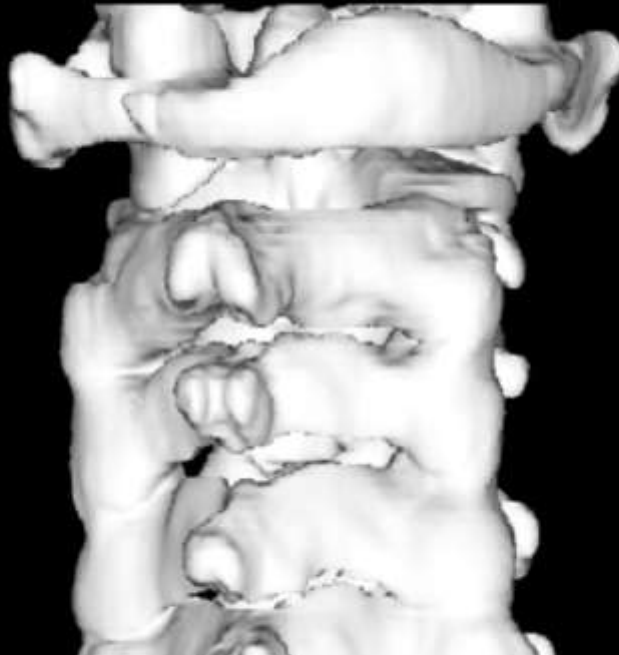Rotary C1-2 Dislocation/Fixation



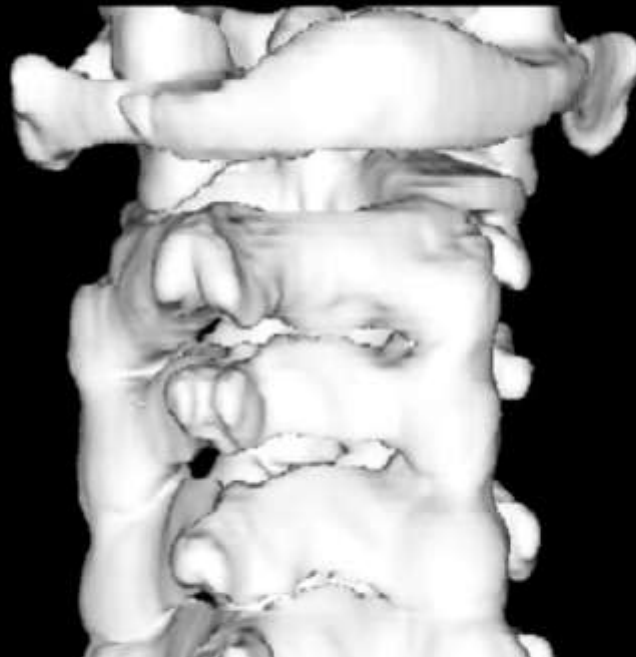Rotary C1-2 Dislocation/Fixation



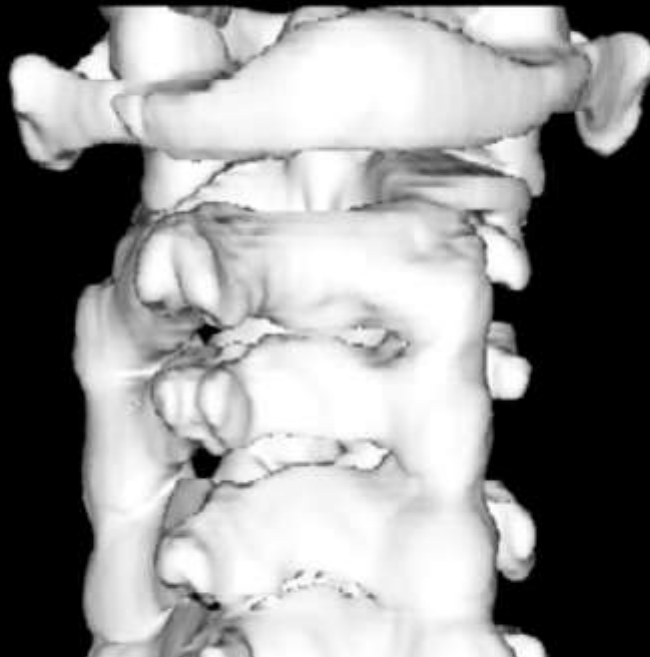
Rotary C1-2 Dislocation/Fixation



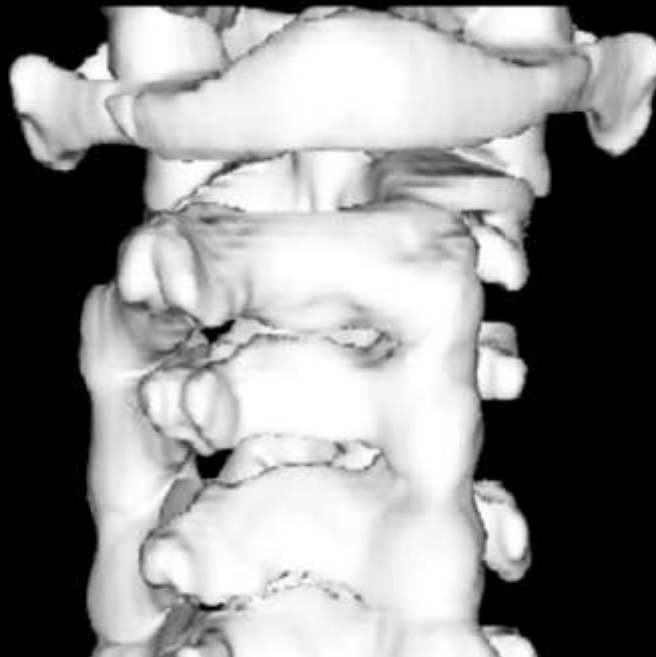Rotary C1-2 Dislocation/Fixation



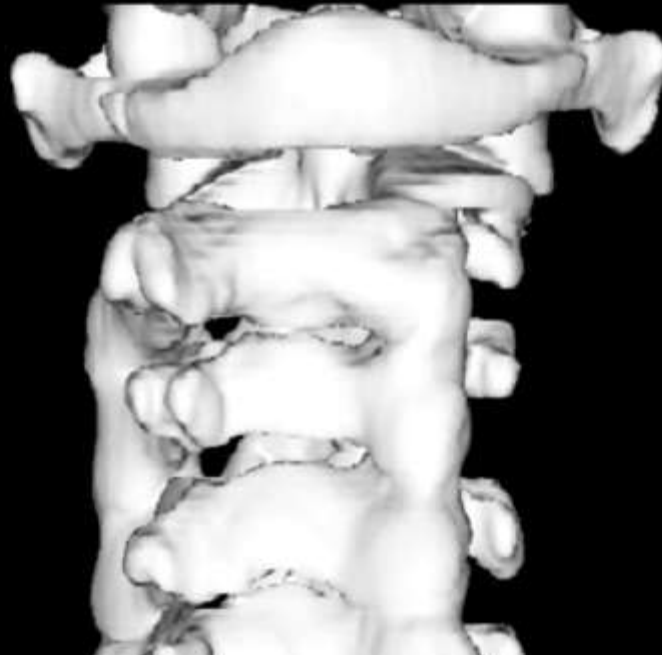Rotary C1-2 Dislocation/Fixation



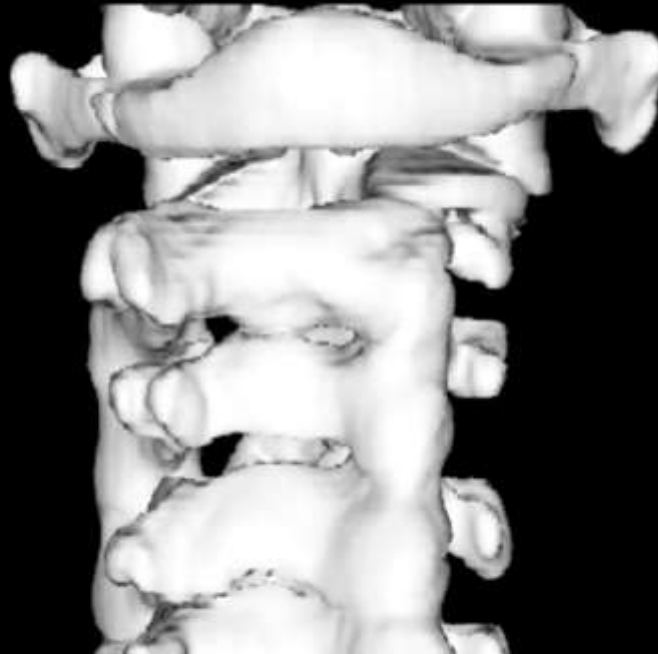Rotary C1-2 Dislocation/Fixation



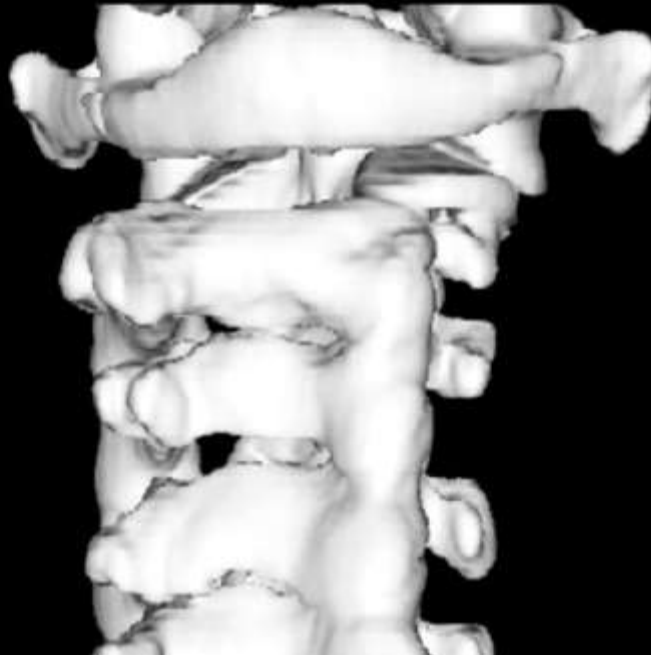Rotary C1-2 Dislocation/Fixation



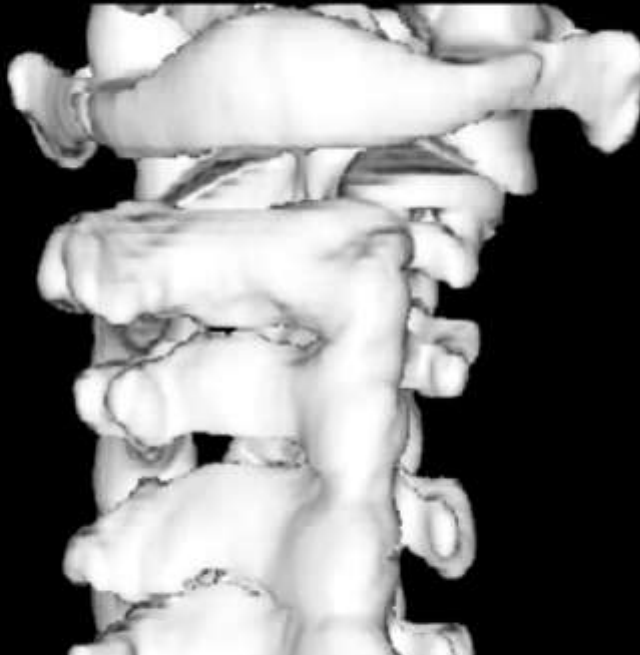
Rotary C1-2 Dislocation/Fixation



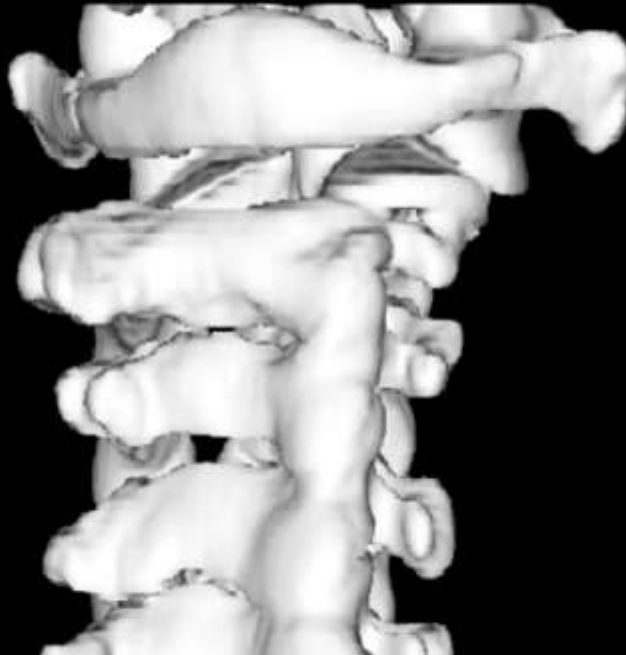Rotary C1-2 Dislocation/Fixation



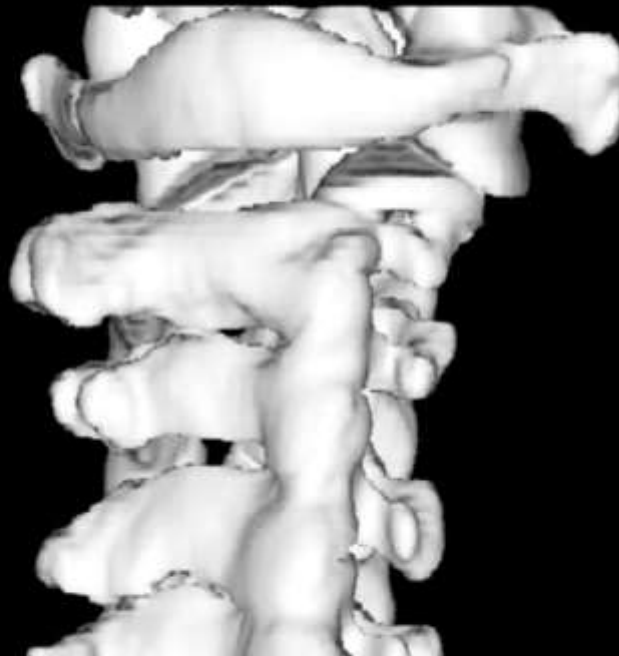Rotary C1-2 Dislocation/Fixation



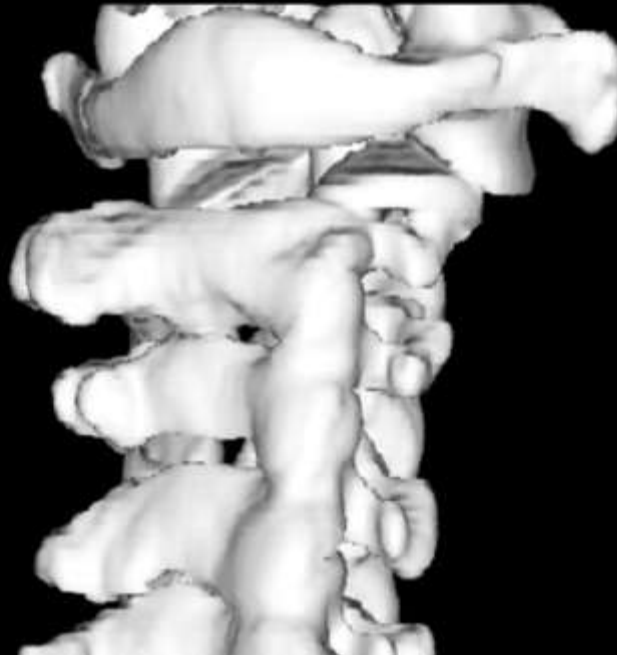
Rotary C1-2 Dislocation/Fixation



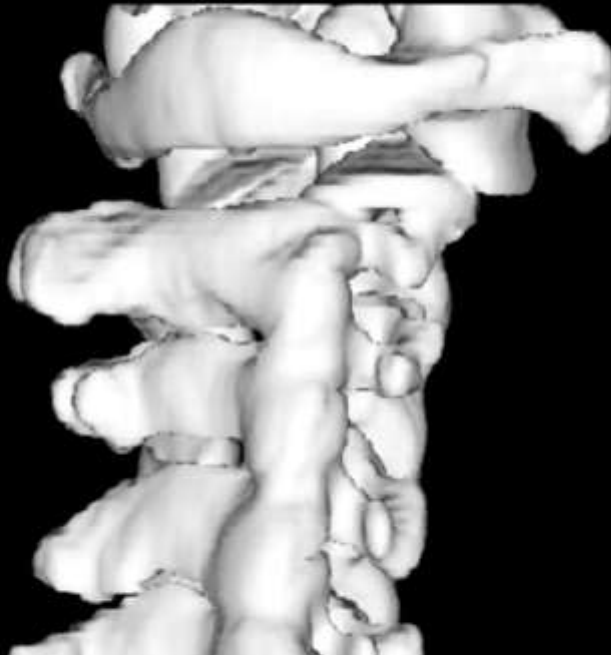Rotary C1-2 Dislocation/Fixation



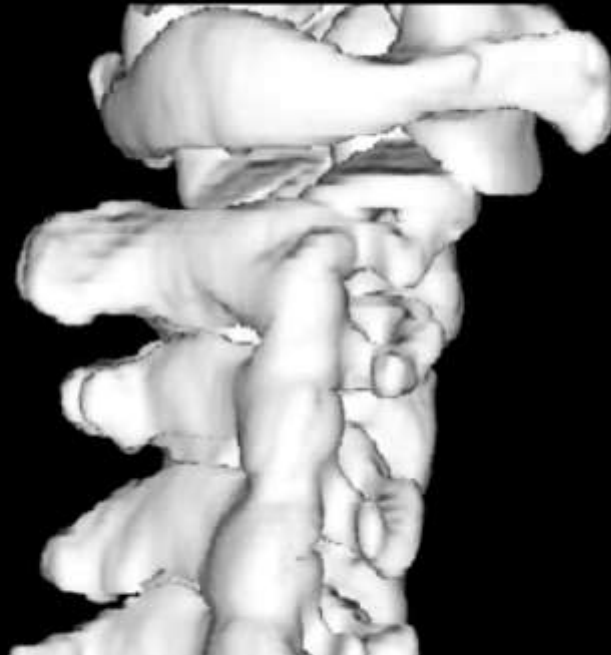
Rotary C1-2 Dislocation/Fixation



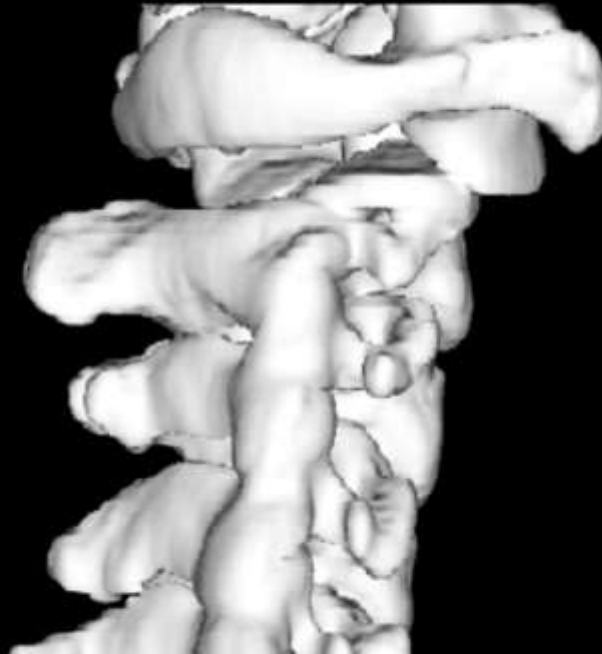
Rotary C1-2 Dislocation/Fixation



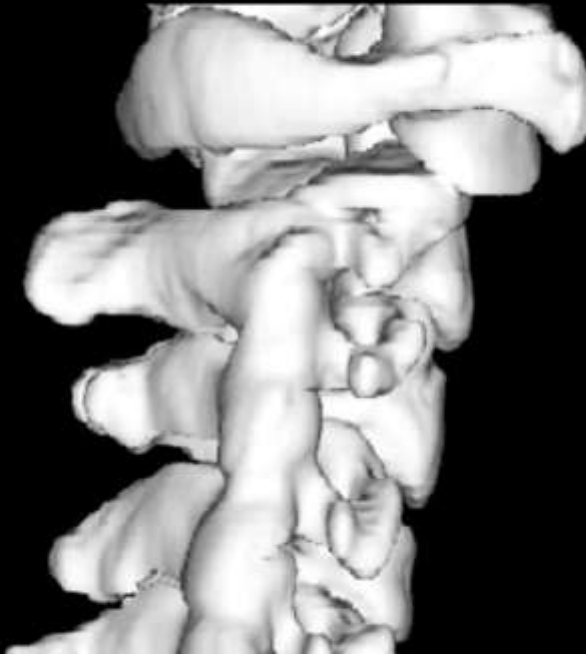
Rotary C1-2 Dislocation/Fixation



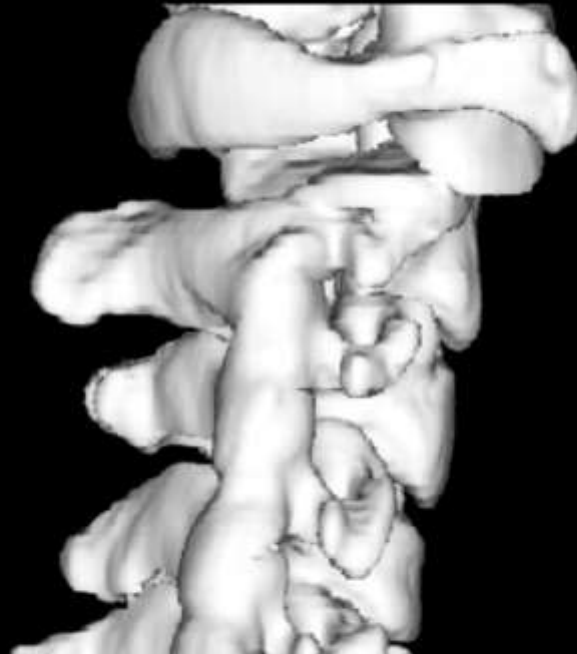Rotary C1-2 Dislocation/Fixation



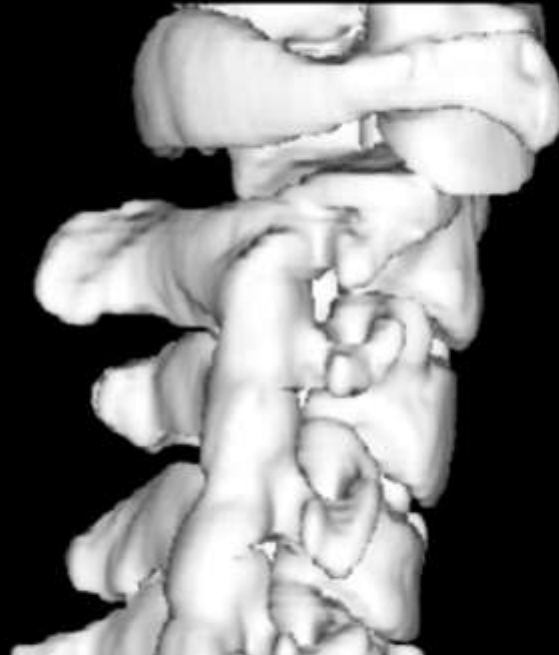Rotary C1-2 Dislocation/Fixation



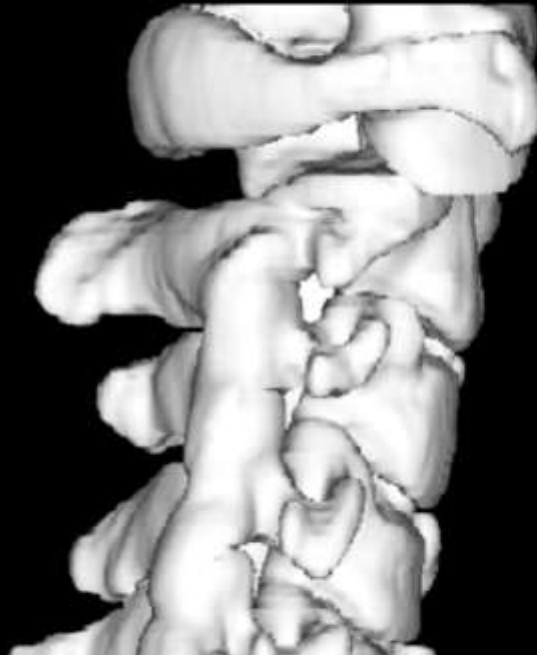Rotary C1-2 Dislocation/Fixation



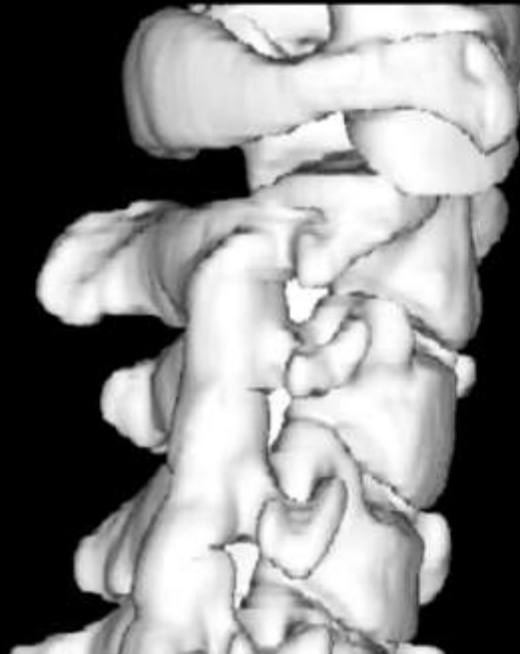Rotary C1-2 Dislocation/Fixation



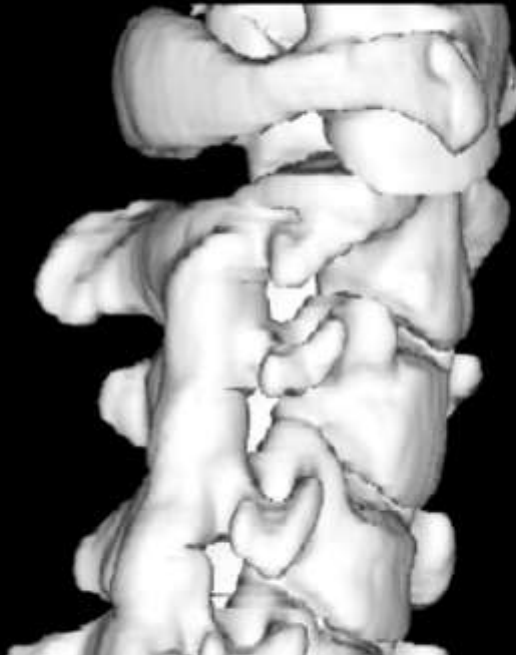Rotary C1-2 Dislocation/Fixation



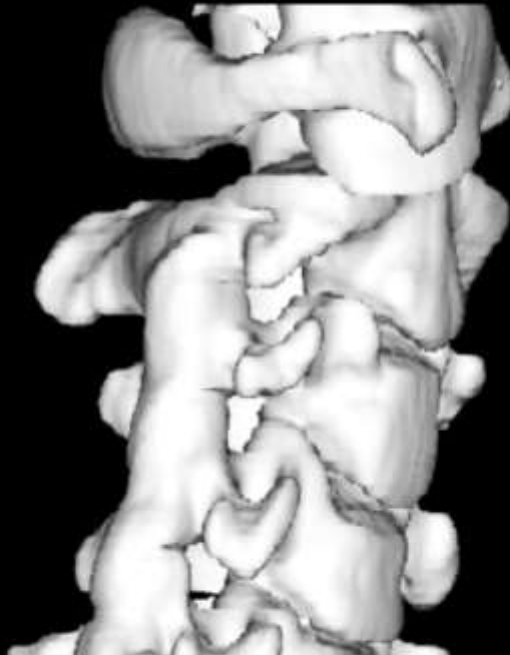Rotary C1-2 Dislocation/Fixation



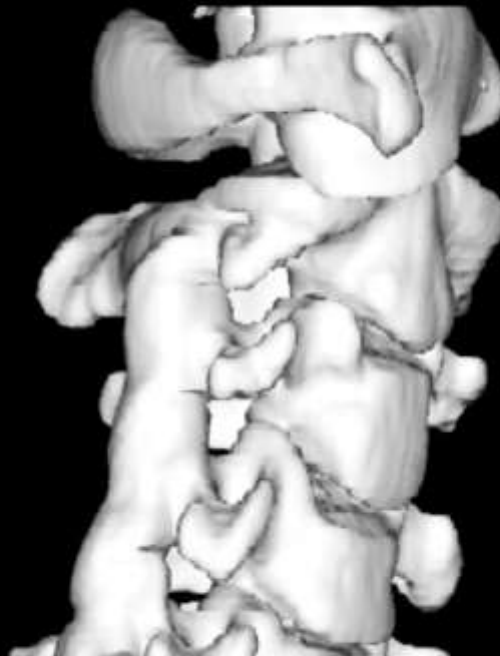Rotary C1-2 Dislocation/Fixation



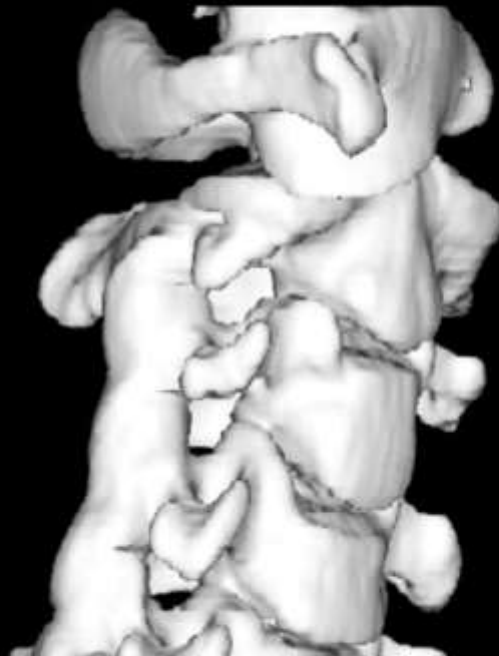Rotary C1-2 Dislocation/Fixation



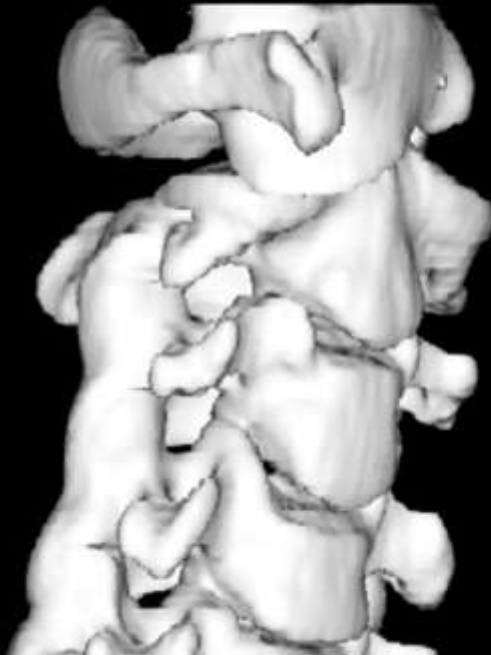Rotary C1-2 Dislocation/Fixation



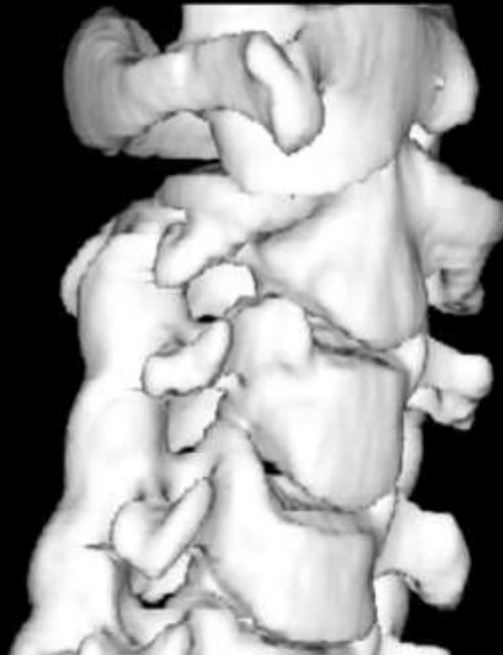Rotary C1-2 Dislocation/Fixation



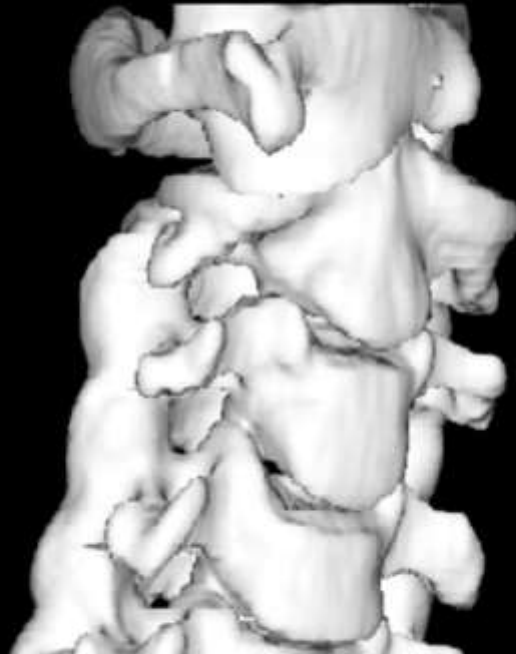Rotary C1-2 Dislocation/Fixation



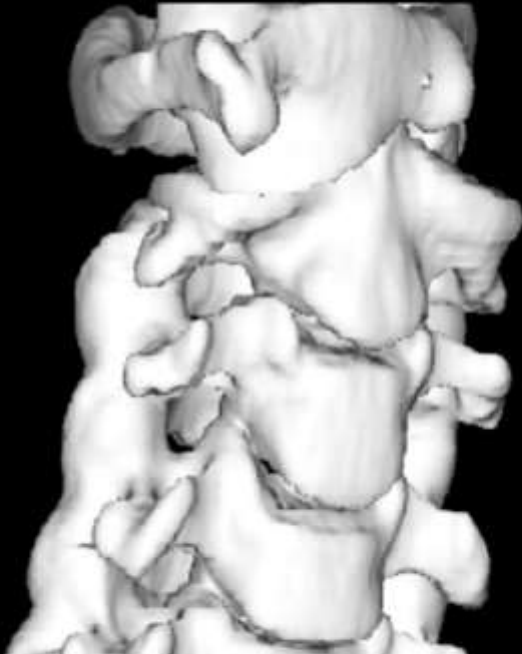Rotary C1-2 Dislocation/Fixation



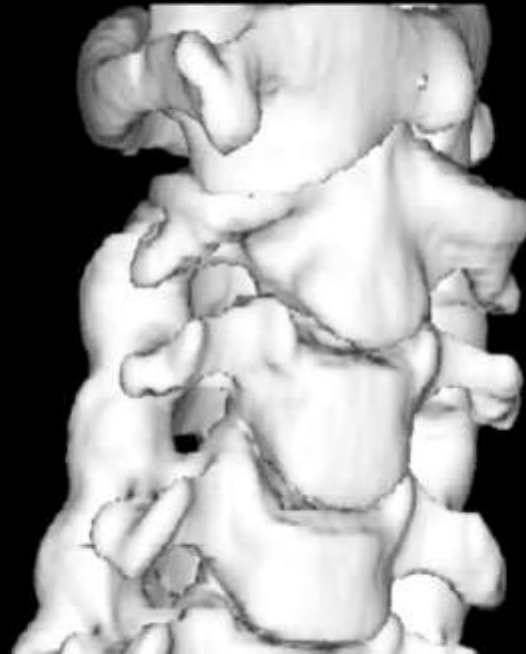Rotary C1-2 Dislocation/Fixation



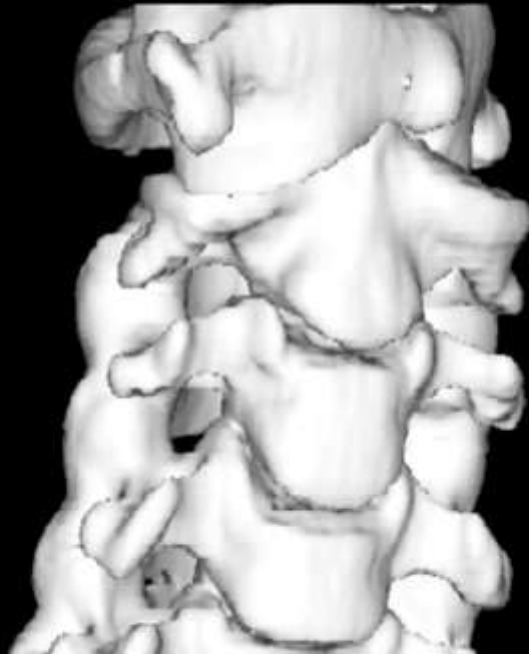Rotary C1-2 Dislocation/Fixation



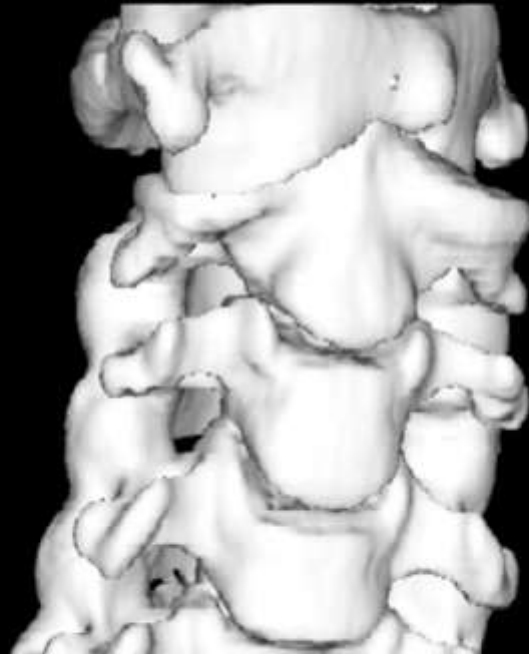Rotary C1-2 Dislocation/Fixation



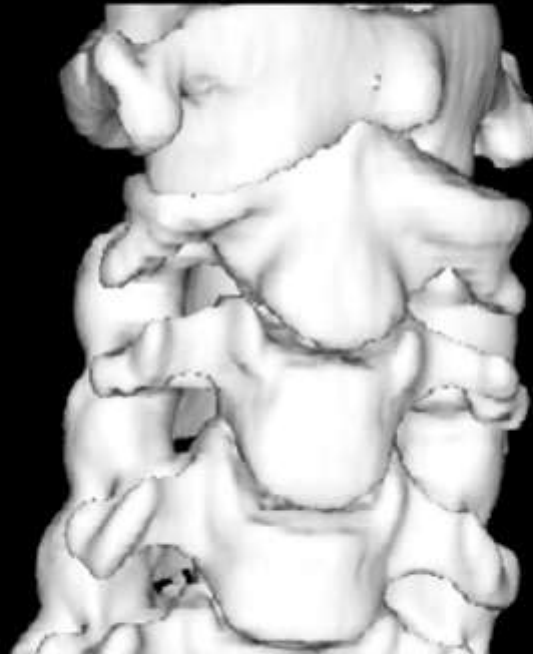Rotary C1-2 Dislocation/Fixation



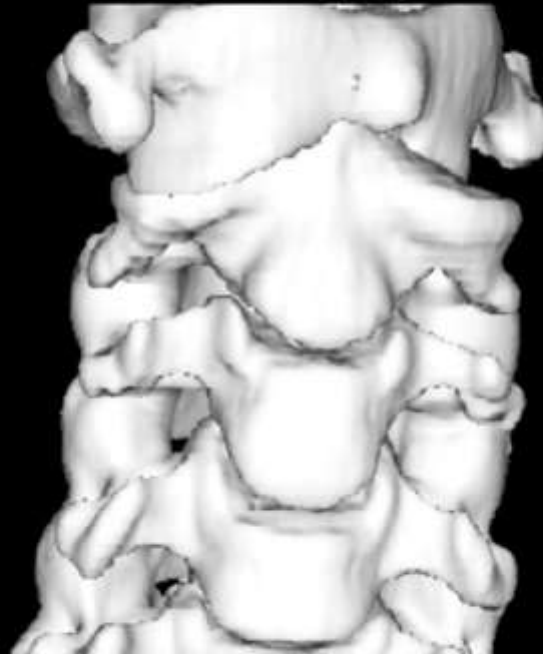Rotary C1-2 Dislocation/Fixation



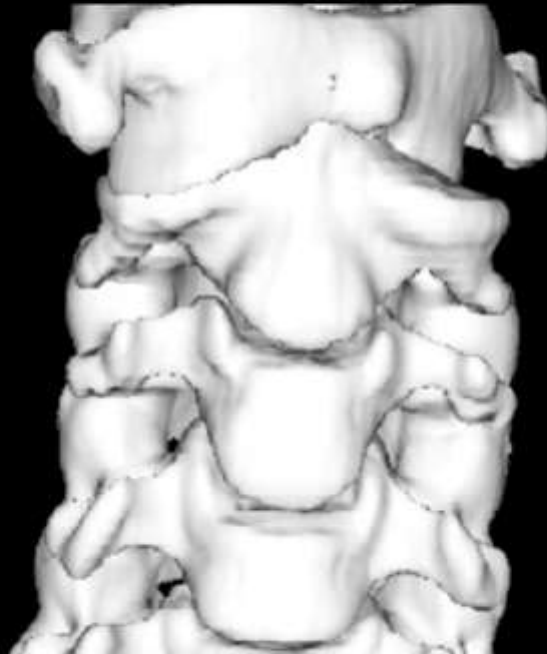Rotary C1-2 Dislocation/Fixation



Rotary C1-2 Dislocation/Fixation



Rotary C1-2 Dislocation/Fixation



Rotary C1-2 Dislocation/Fixation

