

# Carpal Instability

Caroline Yang



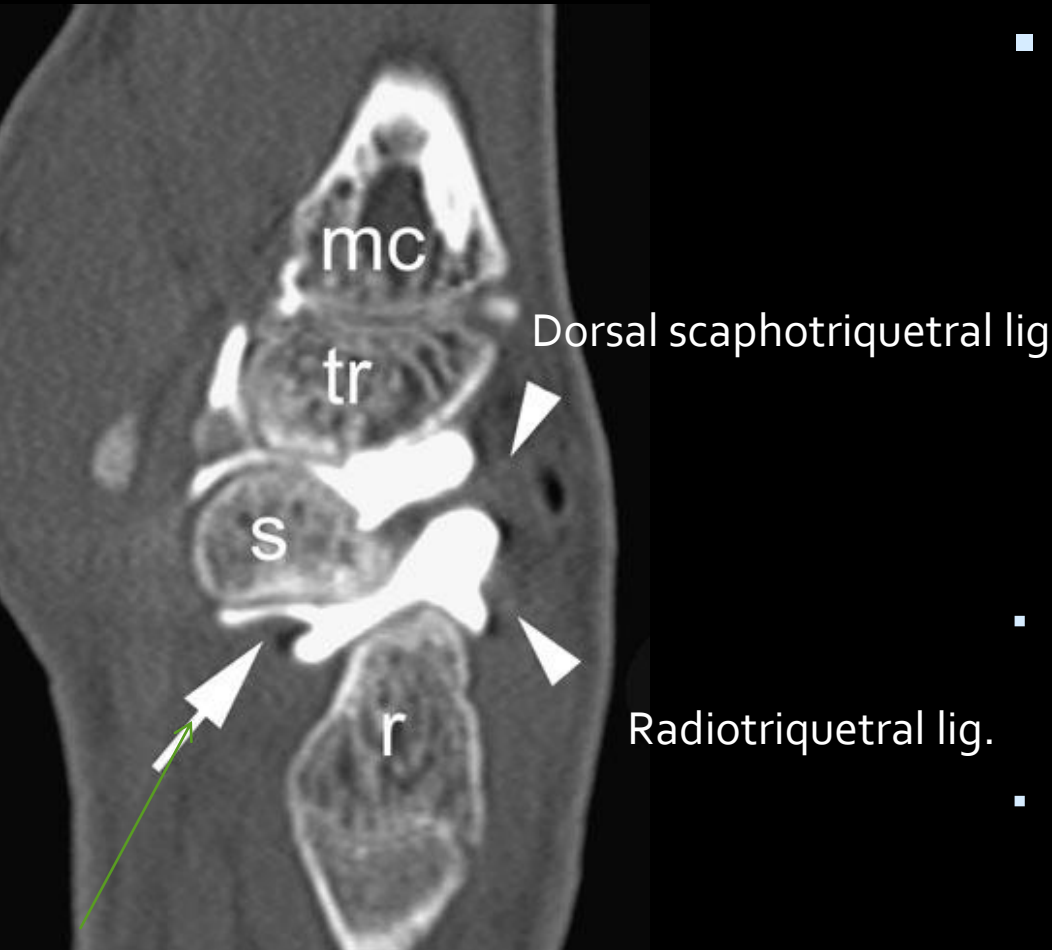
# Diagnosis of carpal instability

- Radiographs
  - PA (neutral, ulnar and radial deviation)
  - AP (tightly clenched fist)
  - Oblique
  - Lateral
- assess alignment on radiographs
  - Articular bones have opposing surfaces 2 mm or less apart.
  - Check Gilulas lines- 3 smooth arcs.
  - Disruption in the continuity suggests abnormality at site of broken arc.

# Diagnosis of carpal instability

- Fluoroscopy can be used in transient subluxations in the wrist, especially when combined with applied stress
- CT arthrography- increasing popularity for internal derangement evaluation.
  - Intrinsic ligaments (S/L and L/T)
  - Extrinsic ligament evaluation is difficult

# CT arthrography



- MDCT arthrography has been recently shown to be an excellent technique for the assessment of scapholunate and lunotriquetral interosseous ligament tears with superior accuracy when compared to MRI – according to Moser and Schmid
- Moser et al. Wrist ligament tears: evaluation of MRI and combined MDCT and MR arthrography. *Am J Roentgenol.* 2007;188(5):1278
- Schmid et al. Interosseous ligament tears of the wrist: comparison of multi-detector row CT arthrography and MR imaging.

Radioscaphocapitate (part of palmar arcuate ligament)

# MR and MRA

- MR and MRA – to evaluate intrinsic ligaments and TFCC.
  - MR arthrography is useful for extrinsic ligaments as well.
  - VISI and DISI are well seen on sagittal MR images with the wrist in neutral position.
  - Must be sure wrist is not in ulnar deviation when evaluating for DISI since this position can produce some dorsal tilt of the lunate.
  - Evaluate for sequelae of malalignment – degenerative arthritis, crowding of the carpal tunnel.

# Most important stabilizers of the wrist

Silly bands



# Most important stabilizers of the wrist

**Table 1** Synoptic anatomy of the most important ligaments of the wrist. The ligaments are listed with respect of their positions and courses within the wrist. Additionally, the main function is listed in the right column (*PCR* proximal carpal row)

Position	Ligament	Abbrev.	Function
Interosseous	Scapholunate ligament	SLL	PCR stabilizer
	Lunotriquetral ligament	LTL	PCR stabilizer
	Radioscaphoid ligament	RSL	Volar scaphoid stabilizer
	Radioscapholunate ligament (Testut)	RSLL	Neurovascular bundle
	Radiolunate ligament (short RL ligament)	RLL	Volar lunate stabilizer
Volar proximal V	Volar radiolunotriquetral ligament (long RL ligament)	vRLTL	Radiocarpal stabilizer (“slingshot”)
	Ulnotriquetral ligament	UTL	Ulnocarpal stabilizer
	Ulnolunate ligament	ULL	Ulnocarpal stabilizer
Volar distal V	Radioscaphocapitate ligament	RSCCL	Radiocarpal and scaphoid stabilizer (“slingshot”, “supporter”)
	Scaphocapitate ligament	SCL	Midcarpal stabilizer
	Triquetrocapitatoscapoid (arcuate) lig.	TCSL	Midcarpal stabilizer
	Scaphotrapeziotrapezoidal ligament	STTL	Scapholunate stabilizer
Dorsal V	Dorsal radiolunotriquetral ligament	dRLTL	Radiocarpal stabilizer (“slingshot”)
	Dorsal intercarpal ligament	dICL	Midcarpal stabilizer



# Many ways to describe instability

**Table I.** Analysis of carpal instability, modified from Larsen et al<sup>25</sup>

Chronicity	Constancy	Aetiology	Location	Direction	Pattern
Acute < 1 week (maximum primary healing potential)	Static irreducible	Congenital	Radiocarpal	VISI rotation	Dissociative carpal instability (CID)
Subacute 1 to 6 weeks (some healing potential)	Static reducible	Traumatic	Proximal intercarpal	DISI rotation	Non-dissociative carpal instability (CIND)
Chronic > 6 weeks (little primary healing potential)	Dynamic	Inflammatory	Midcarpal	Ulnar translation	Complex carpal instability (CIC)
		Arthritic		Radial translation	
	Predynamic	Neoplastic	Distal intercarpal	Palmar translation	Adaptive carpal instability (CIA)
		Iatrogenic		Carpometacarpal	
		Miscellaneous	Specific bones	Distal translation	

# Patterns of Carpal Instability

- Dissociative (CID)
    - Scapholunate dissociation
    - Lunotriquetral dissociation
    - Scaphoid fractures that are unstable, ununited, or malunited
    - Kienbock's disease
  - Non-dissociative (CIND)
    - Radiocarpal
    - Midcarpal
  - Complex carpal instability (CIC)
    - Perilunate dislocations
  - Adaptive carpal instability (CIA)
- Dissociative is more common than nondissociative

# CID - Scapholunate dissociation

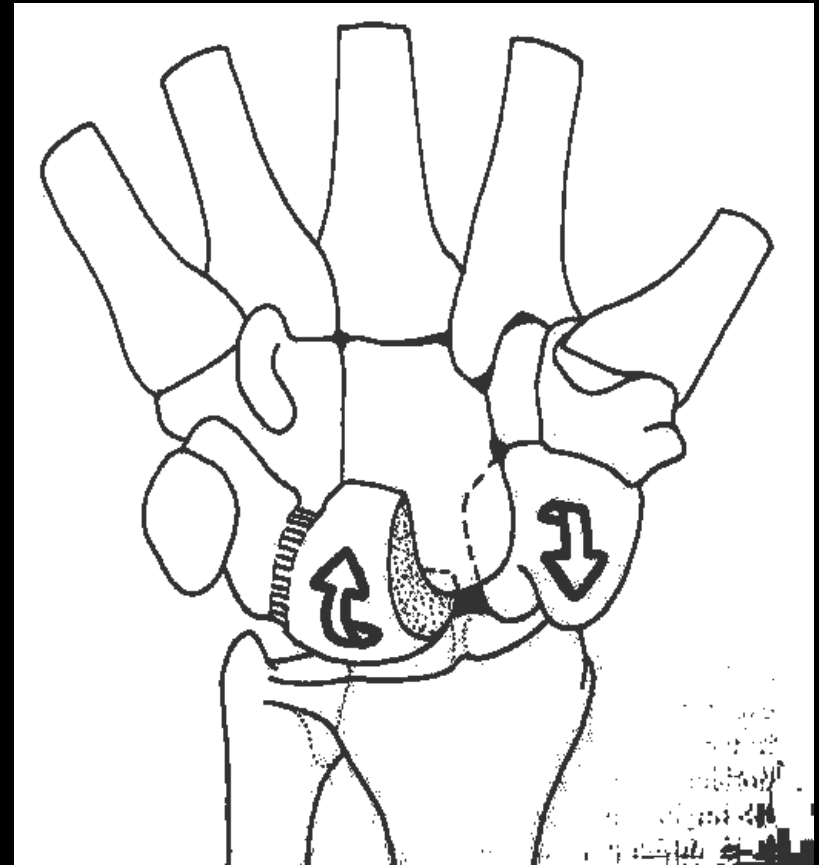
- A frequent cause of proximal CID.
  - Clinically: tenderness in the anatomic snuffbox.
- Scapholunate interosseous ligament is the strongest and stiffest of the interosseous ligaments
- Rupture site most often at scaphoid attachment sites because fibers less dense.
- Occurs as an isolated injury or with distal radius or scaphoid fractures.
- Tears are traumatic or degenerative.

# CID-Scapholunate dissociation (SLD)

- \*\*A spectrum of rotational abnormalities that is dependent on the severity of the injury and the nature and location of the resulting ligamentous abnormalities.
  - dynamic instability (requiring stress) → fixed or static instability patterns readily evident on radiography.
- Extreme example:
  - Rotatory subluxation of the scaphoid.

# Normal Carpal Kinematics

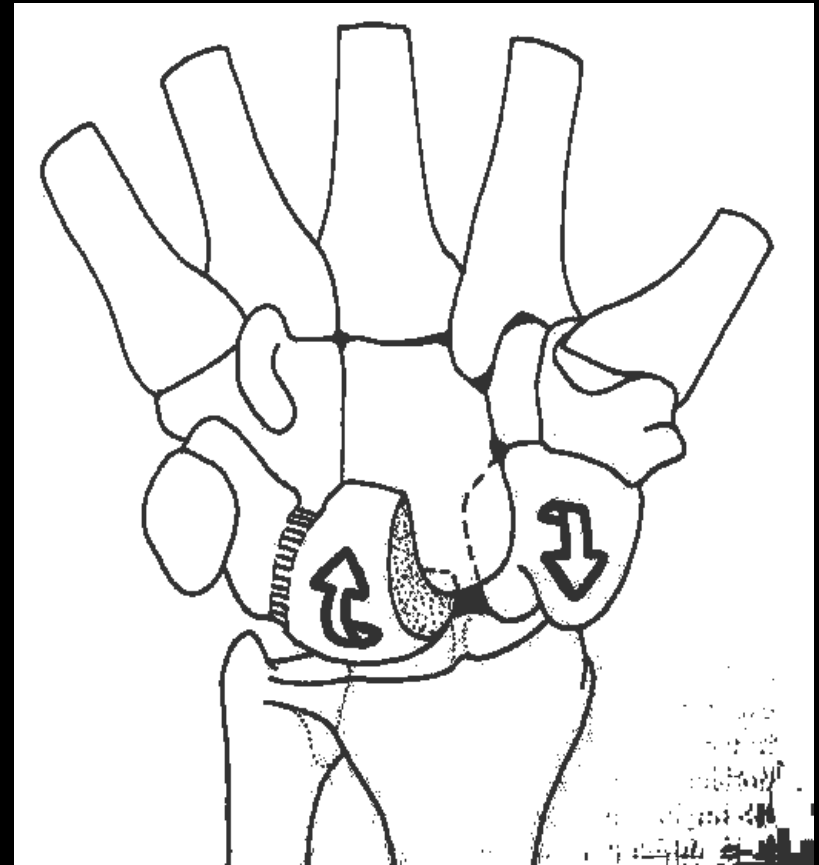
- At the carpus, OPPOSING dynamic torques are always acting:
  - Under axial load or radial deviation:
    - scaphoid → flexes
    - triquetrum → extends
  - With ulnar deviation:
    - scaphoid → extends
    - triquetrum → flexes
- Lunate is the intercalated segment between these opposing forces of the scaphoid and triquetrum
- It is highly unstable due to minor ligamentous insertions only



Dorsal intercalated segmental instability

# Normal Carpal Kinematics

- When the dynamic balance is interrupted, the lunate will tend to:
  - flex with the loss of ulnar support from the triquetrum via the LTL (VISI)
  - extend if there is loss of radial stability via the SLL (DISI)
- Forces are balanced by a ligamentous ring.

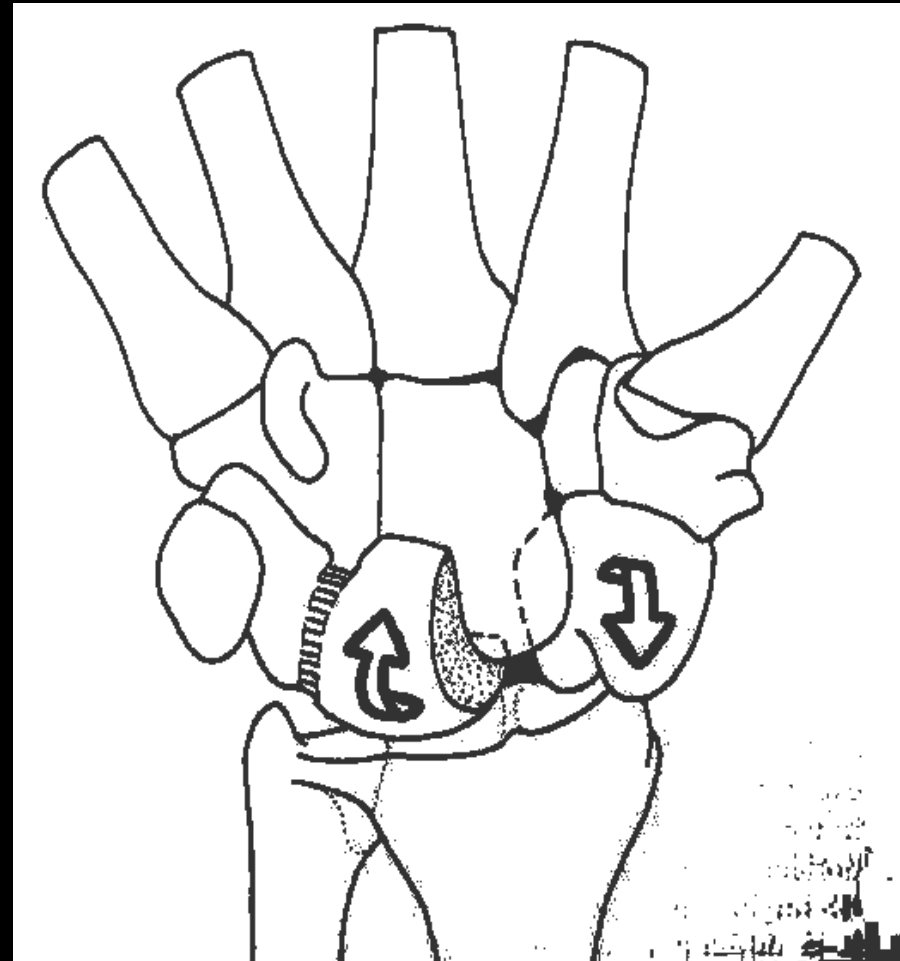


Dorsal intercalated segmental instability

# DISI Pattern

With complete disruption of the SL, a **static** carpal collapse may develop.

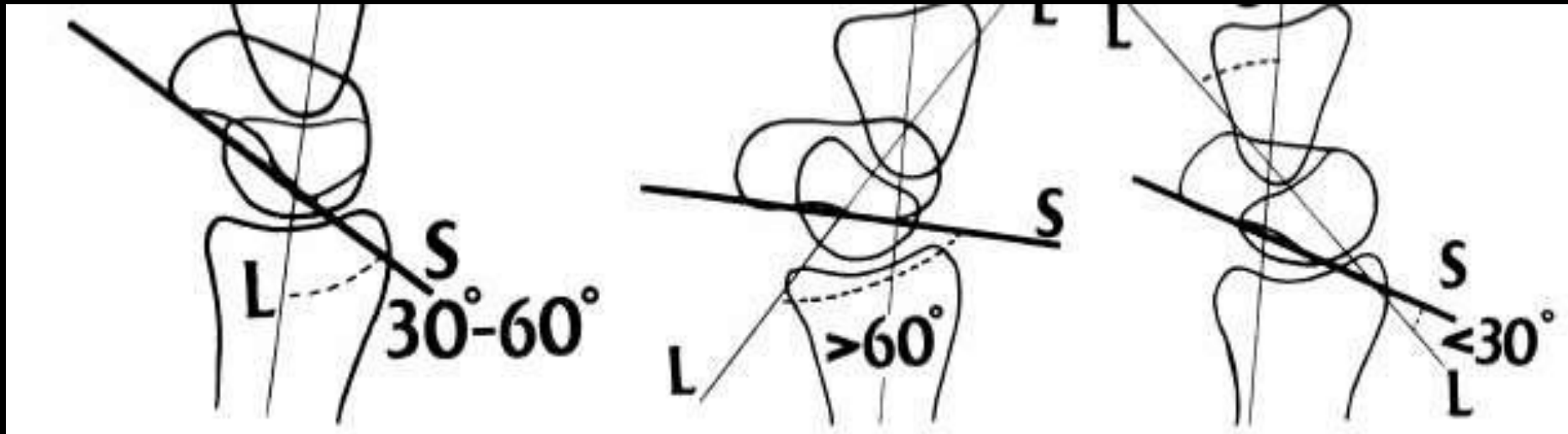
- Scaphoid: Volar flexion, ulnar deviation, and pronation
- Lunate and triquetrum: Extension, supination, and radial deviation



# Normal

# DISI

# VISI



MR imaging of the major carpal stabilizing ligaments: normal anatomy and clinical examples..Radiographics. 1995 May;15(3):575-87



# Things to remember:

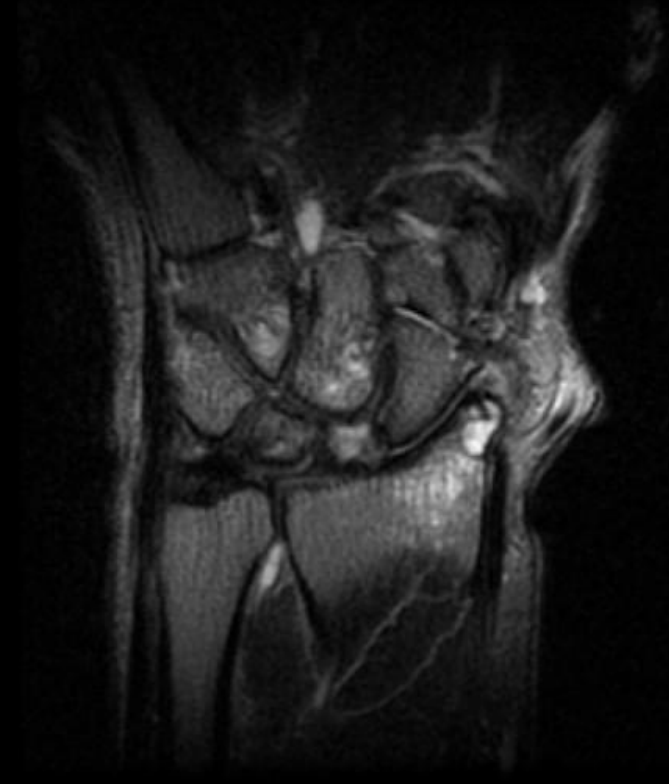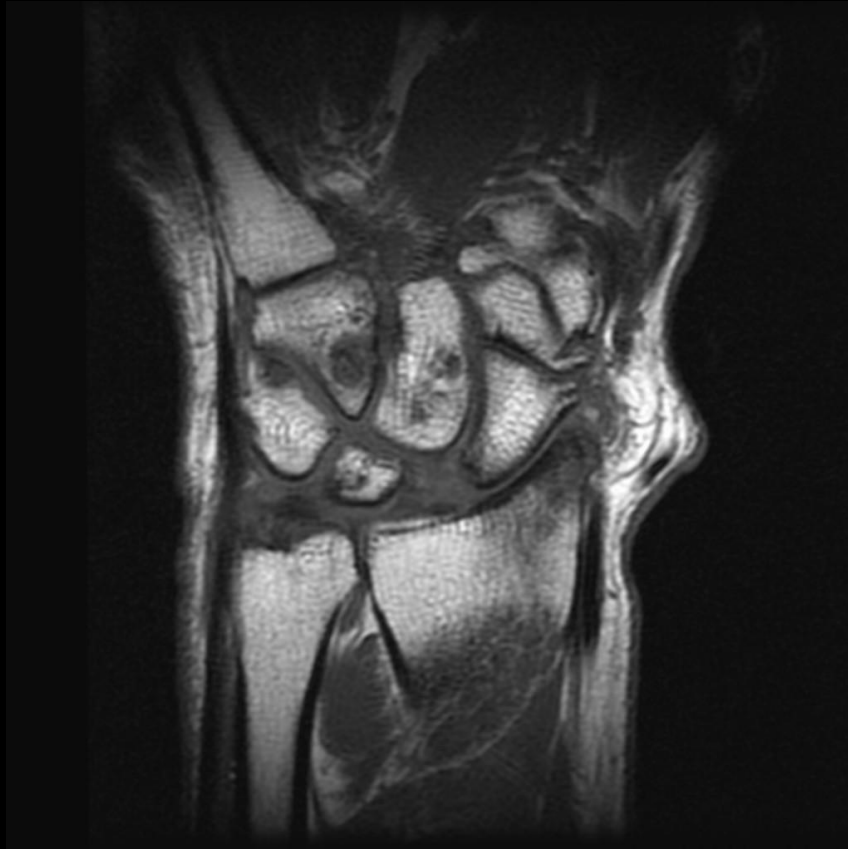- Dorsal tilting of the lunate → round distal contour of the lunate
- Volar tilting → angular distal margin
- Palmar tilting of the scaphoid on the PA view
  - a ring produced by the cortex of the distal pole of the scaphoid
  - Note: false + ring sign may be seen with wrist deviation in the coronal plane.



# EXAMPLES



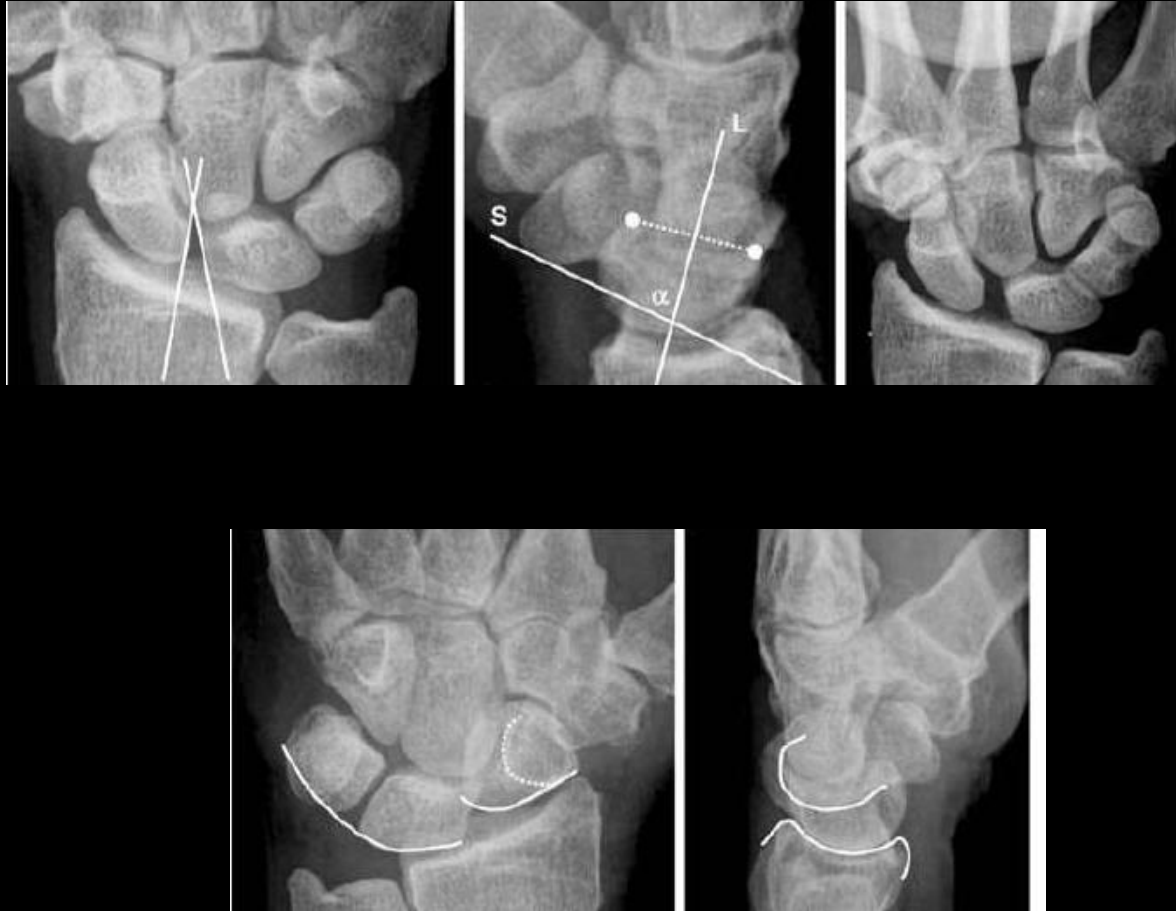
# Degenerative Scapholunate Tear with OA



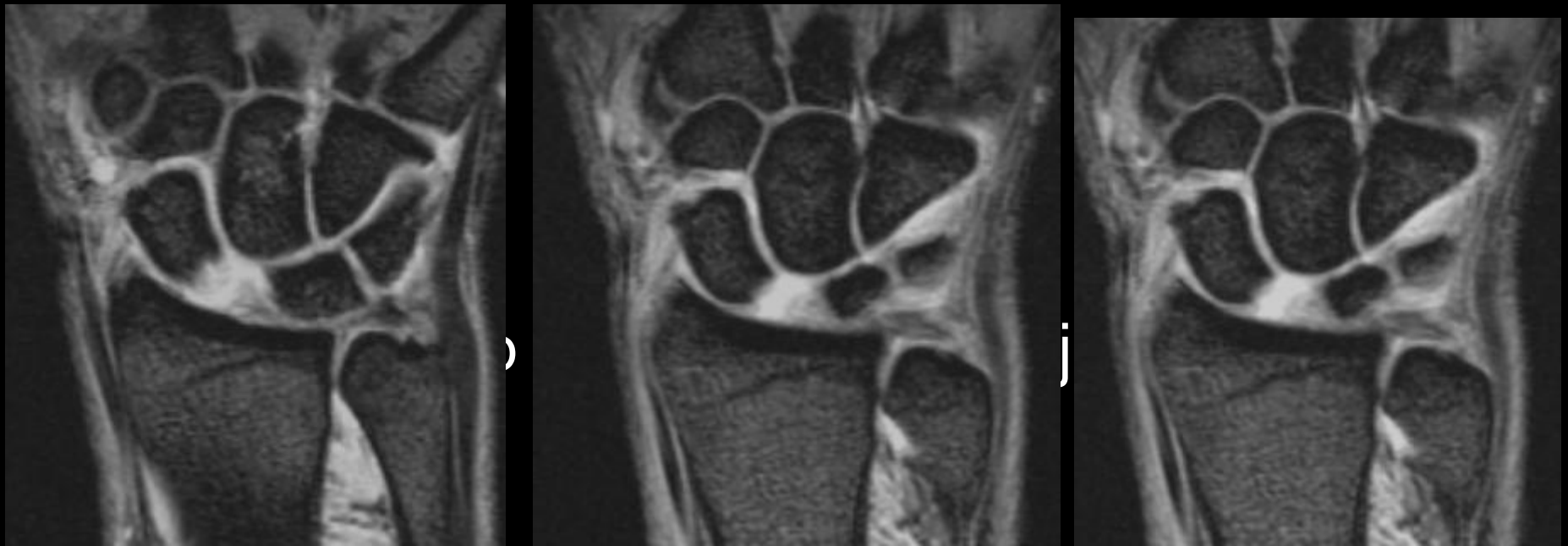# Degenerative Scapholunate Tear with OA

- Arthrosis at the lunate – capitate space occurs in combination with scapholunate separation and narrowing of the radioscaphoid space.
- Disruption of the scapholunate ligament by trauma or crystal deposition

# SLD



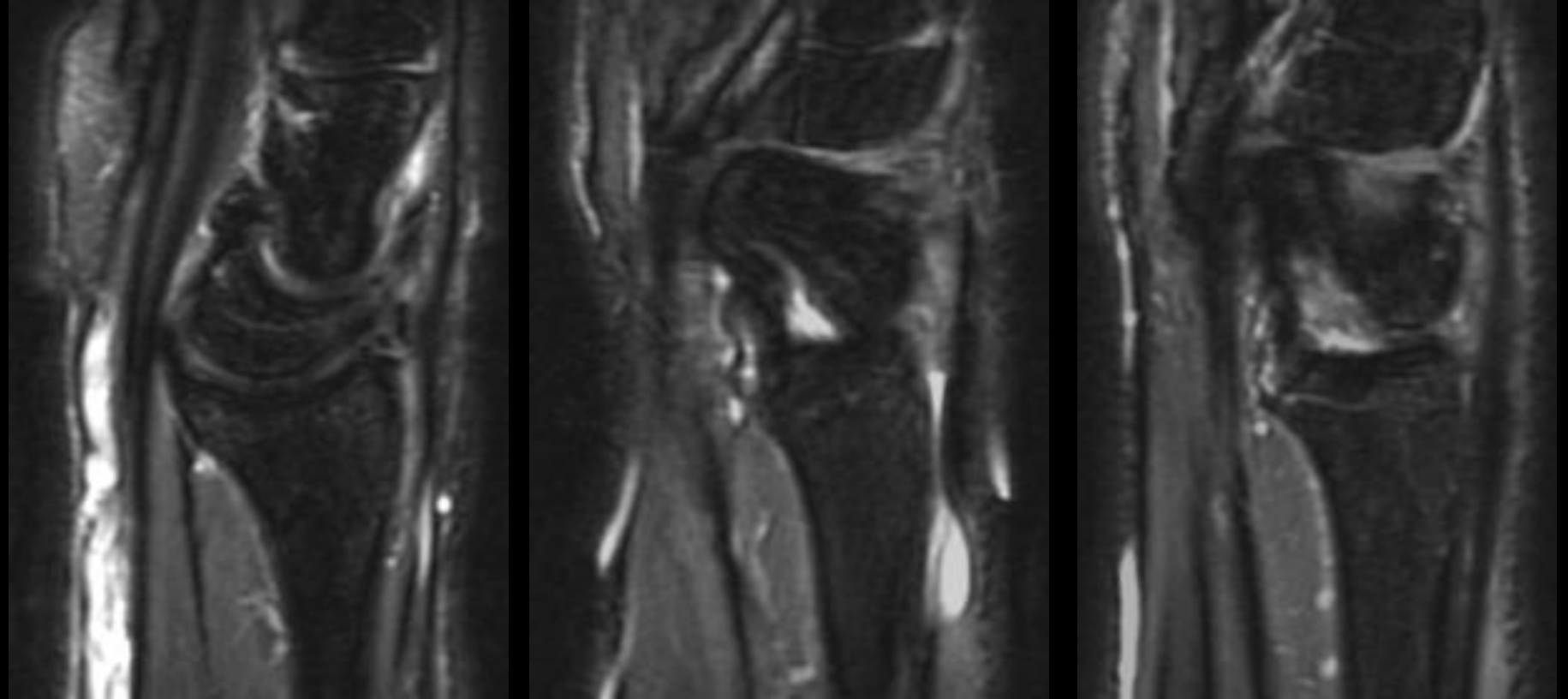
Schmitt et al. Eur Radiol. (2006 ) 16: 2161-2178.



## SLD

Hx: 35 y/o male with wrist injury 1 week ago.

- Widening of the Scapholunate distance
- Disruption of the SL ligament at scaphoid attachment
- Foreshortened appearance of the scaphoid



- Partial disruption of radioscaphoid portion of RCL at scaphoid attachment site
- Flexion of distal pole of the scaphoid
- Dorsal subluxation of the proximal pole with respect to radius

# Rotary Subluxation of the Scaphoid

- **Mechanism:** stress loading of extended carpus, usually in ulnar deviation
- **Associated injuries:** radiocarpitate ligaments, radiotriquetral ligaments, dorsal radiocarpal ligaments, DISI deformity, radial styloid fx and non-displaced scaphoid fx.
- **Why does it rotate?**
  - Scaphoid inherently tends to palmar flex because of its oblique position and the loading applied thru scaphotrapezium joint.
  - Lack of ligament restraint (primary by SL, secondary by RSCL and the FCR tendon) **will allow it to rotate around radioscapocaptitate** ligament leading to **dorsal** rotary subluxation of the proximal pole .

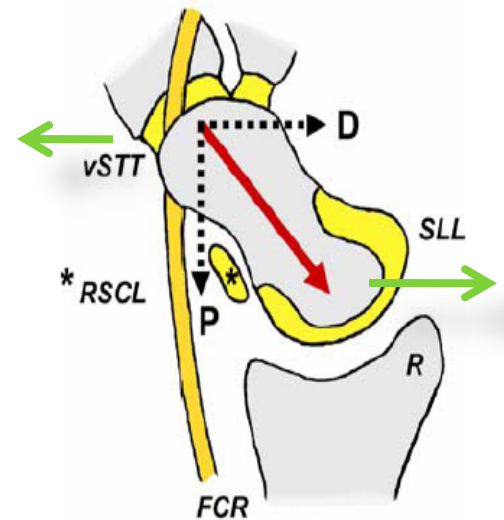
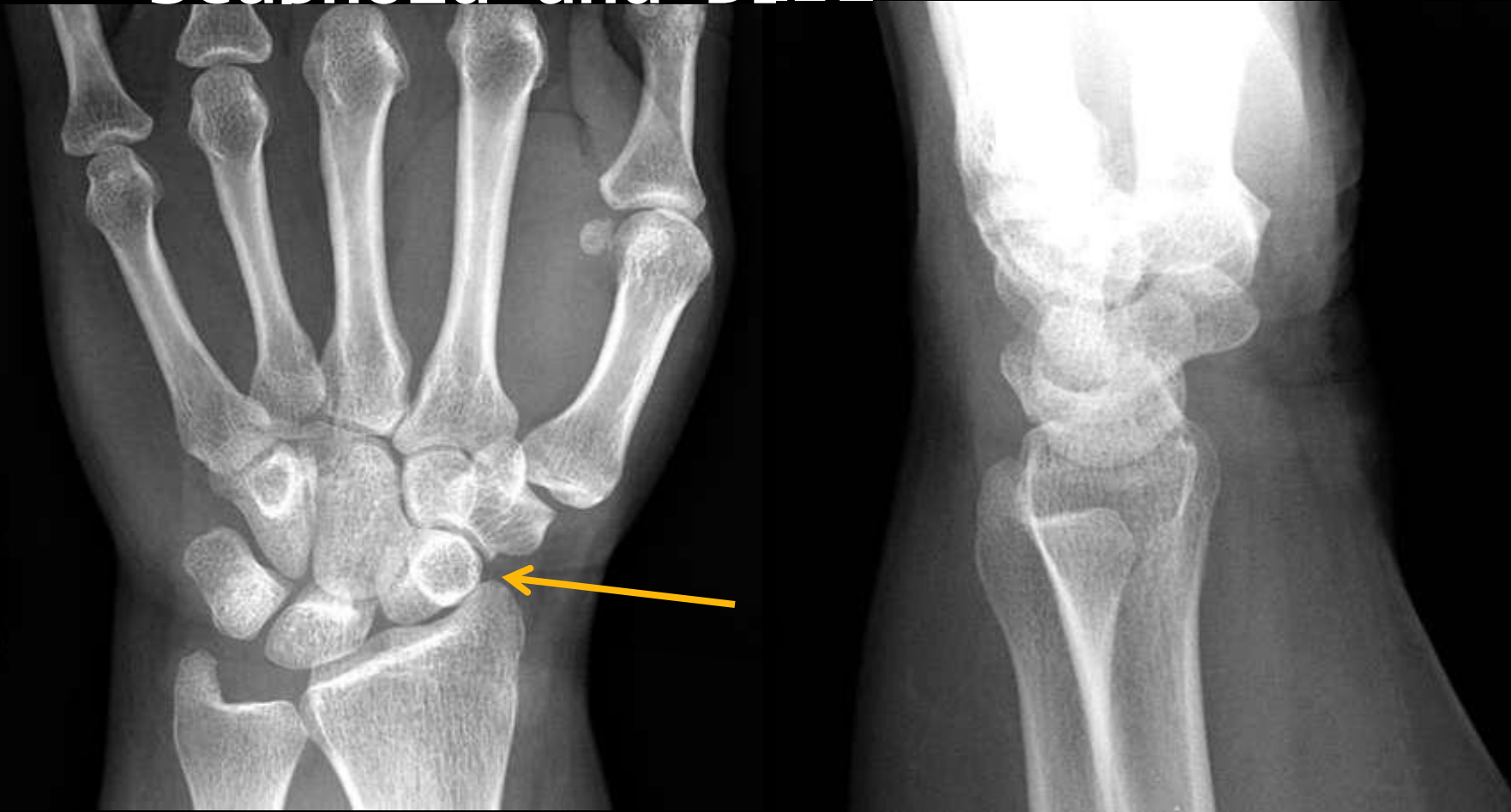

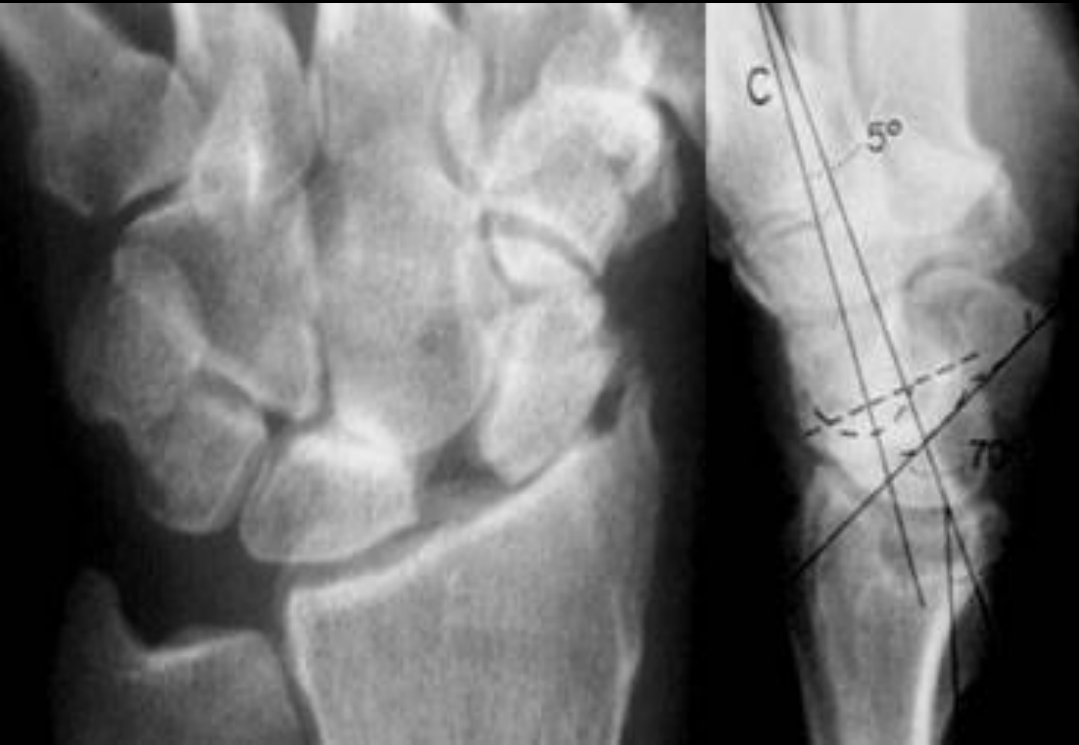Fig. 2 Schematic diagram of the forces transmitted across the scaphoid. Under axial load a longitudinal force vector (in red) is initiated within the scaphoid. This obliquely orientated vector is built of two fractions, a dorsal (*D*) and a proximal (*P*) vector, respectively. The dorsal vector (*D*) is mainly counteracted by the geometry of the volarly tilted scaphoid fossa of the radius (*R*). The proximal force vector (*P*) would induce the scaphoid to flex, if not resisted by the primary (*SLL*) and secondary stabilizers (*vSTTL*, *RSCL*) of the scaphoid as well as the bowstringing of the FCR tendon. The *RSCL* is acting as the “volar support band” of the scaphoid



# Rotary Subluxation of the Scaphoid and DISI



# SLAC wrist

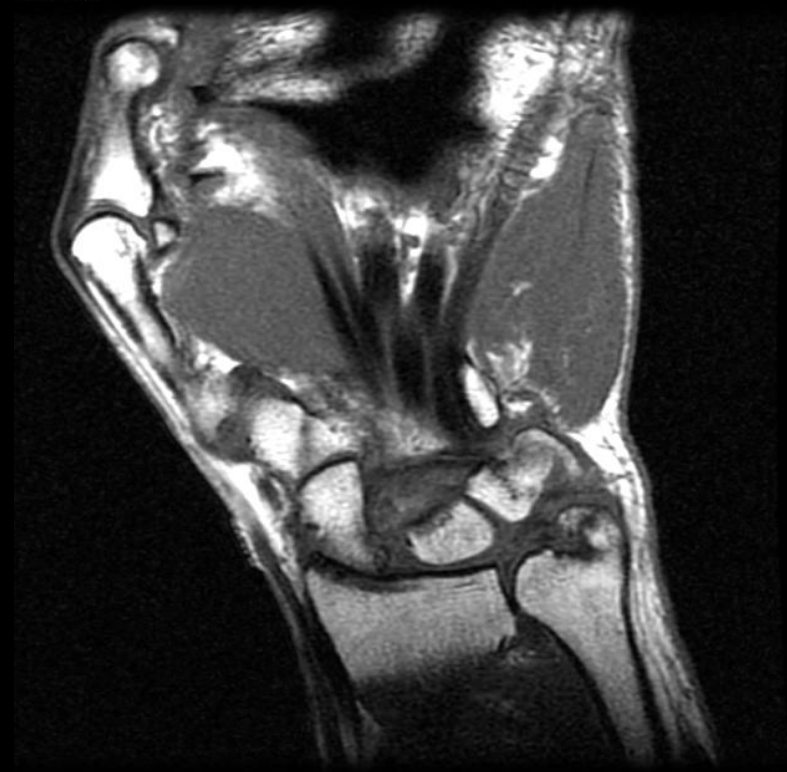


- **SLAC** (scapholunate advanced collapse) - a specific pattern of osteoarthritis and subluxation
- results from untreated chronic scapholunate dissociation or from chronic scaphoid non-union (SNAC).
- The degenerative changes occur in areas of abnormal loading:
  - radial-scaphoid joint,
  - lunatocapitate joint (as capitate subluxes dorsally on lunate.)

# SLAC WRIST

- Characterized by  
Narrowing of both the  
radioscaphoid and  
capitolunate spaces
- Common pattern of  
degenerative joint  
disease of the wrist
- Seen with CPPD
- Post Traumatic

5. Ratio: 8.0



# SLAC causes

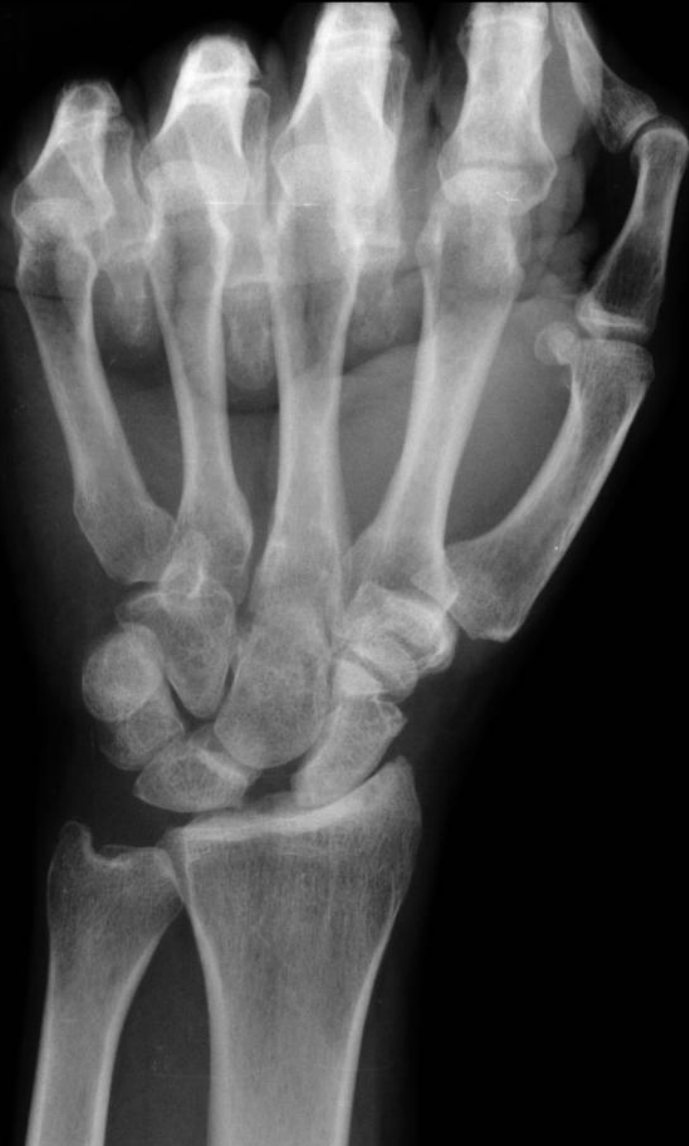- Traumatic
  - Rotatory subluxation of scaphoid
  - Scaphoid fx w/ delayed/non-union
  - IA fx's violating the radioscaphoid or lunoatocapitate joint
  - Kienbock's disease
  - Midcarpal instability
- Non traumatic.
  - CPPD: compromises intrinsic/extrinsic lig.



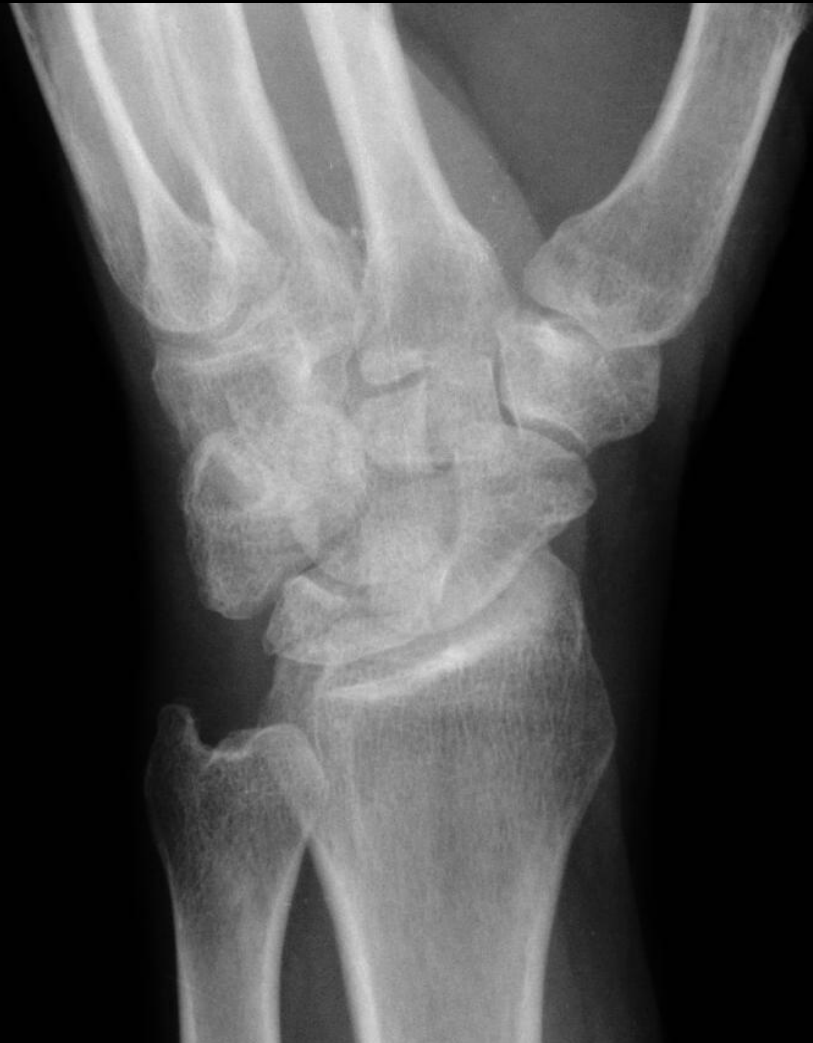examples



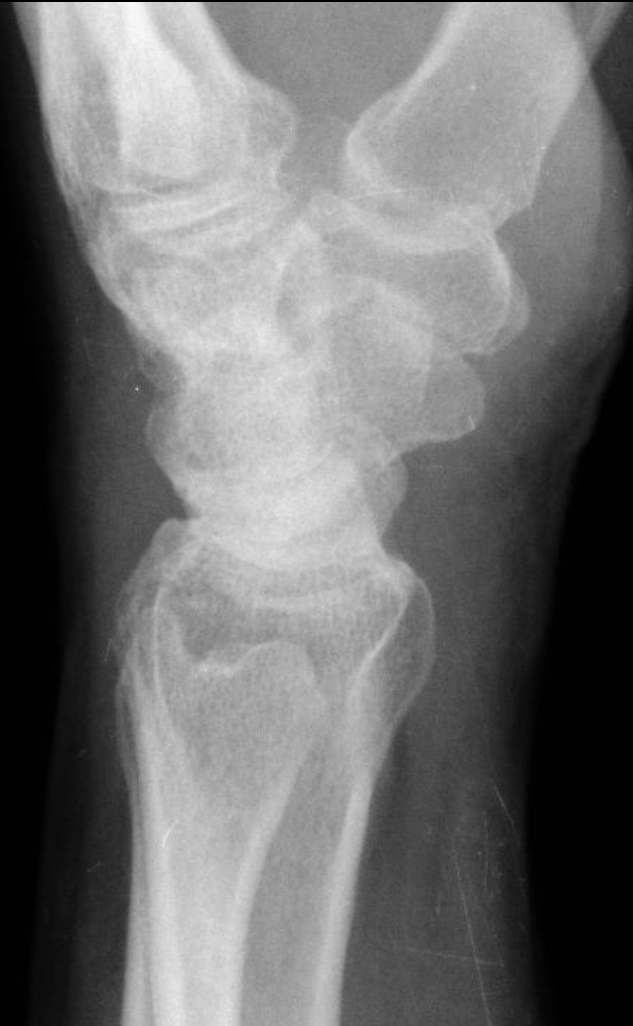# Scapholunate dissociation with SLAC wrist



# Scapholunate dissociation with SLAC wrist

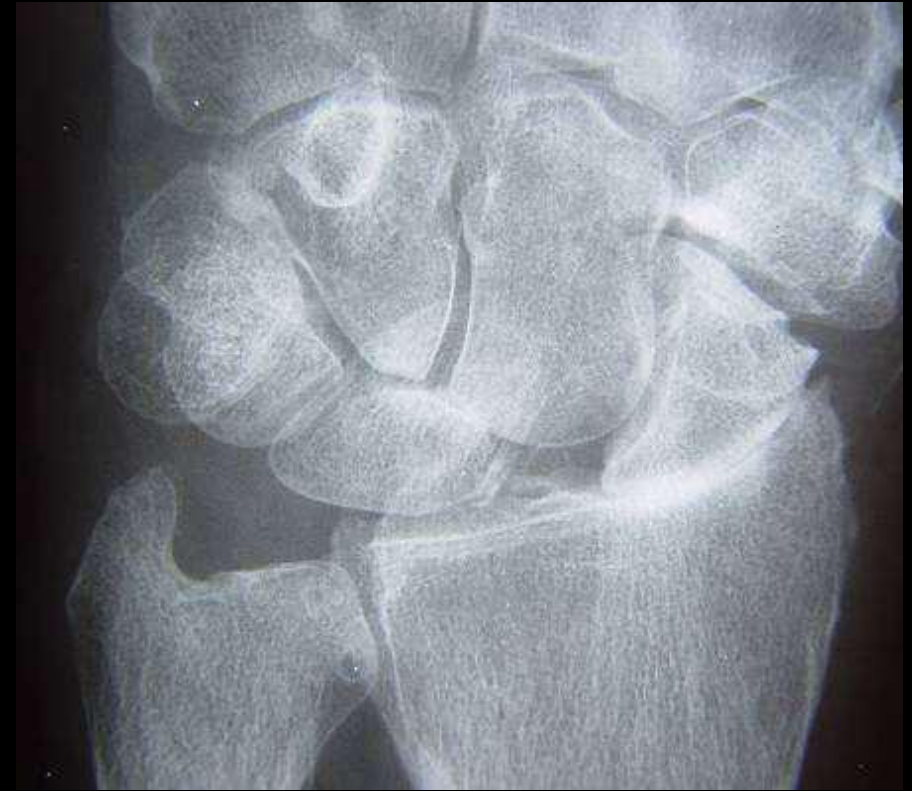
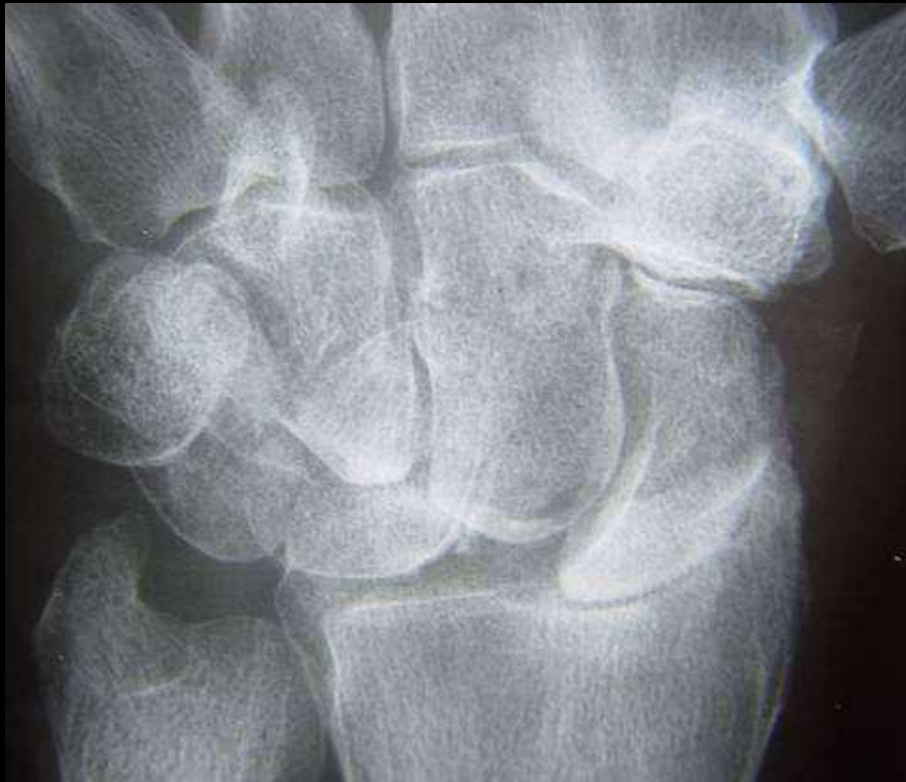
# Scapholunate dissociation with SLAC wrist

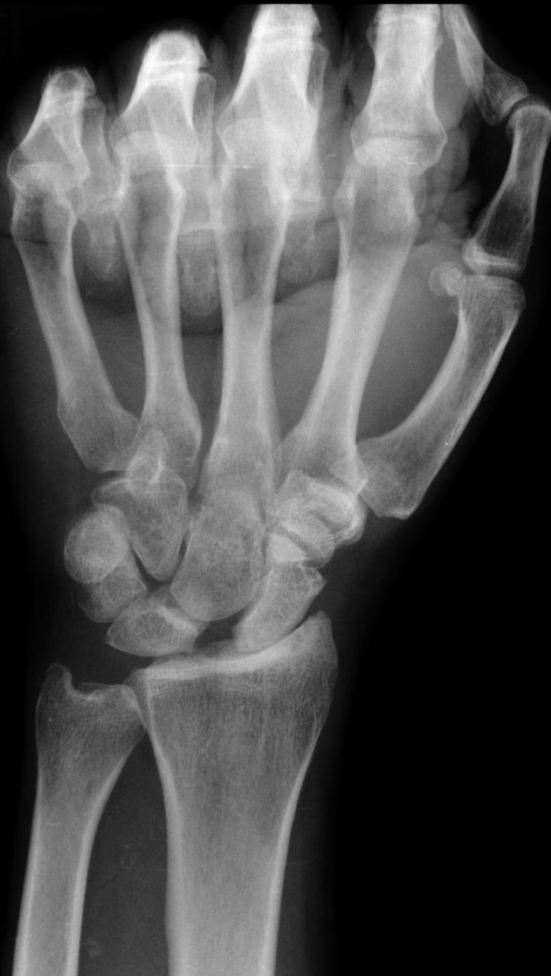



# SLAC wrist – another example



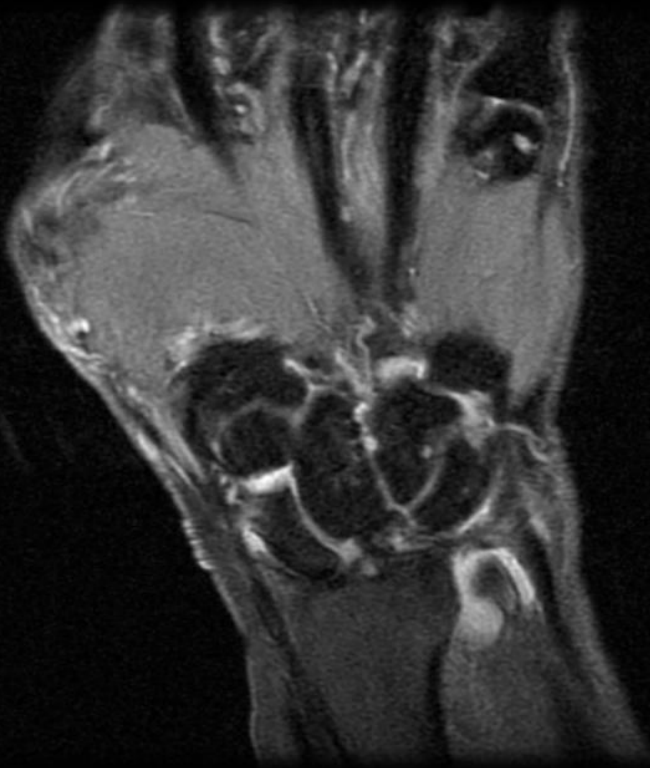
# SLAC stages



- Stage 1: Arthrosis limited to radial **styloid-scaphoid** articulation
- Stage 2 : Arthrosis of **entire radioscaphoid articulation**
- Stage 3 : **Capitolunate** arthroposis
- Additionally: destruction of scaphocapitate articulation with proximal migration of capitate on radius

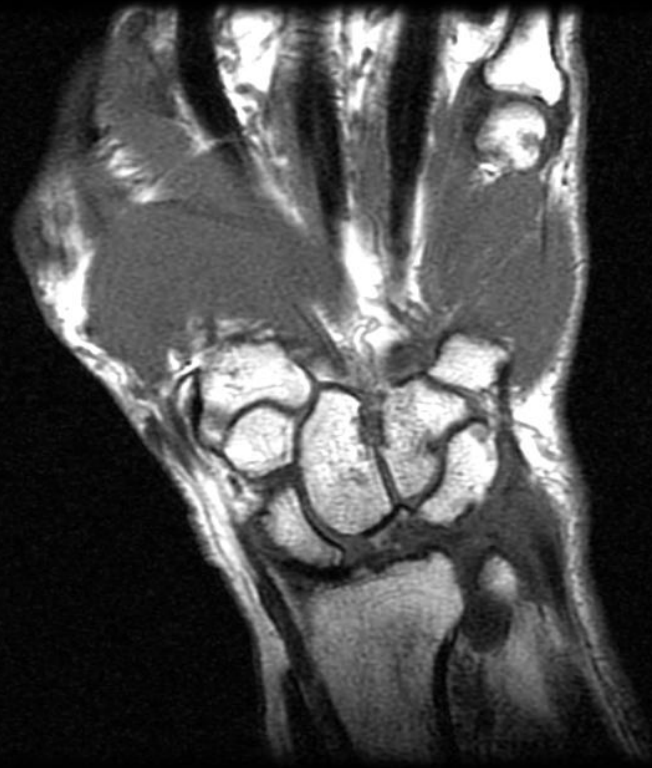
# SLAC wrist in 78 y.o with 3 months dorsal wrist pain r/o mass

7. Ratio: 8.0

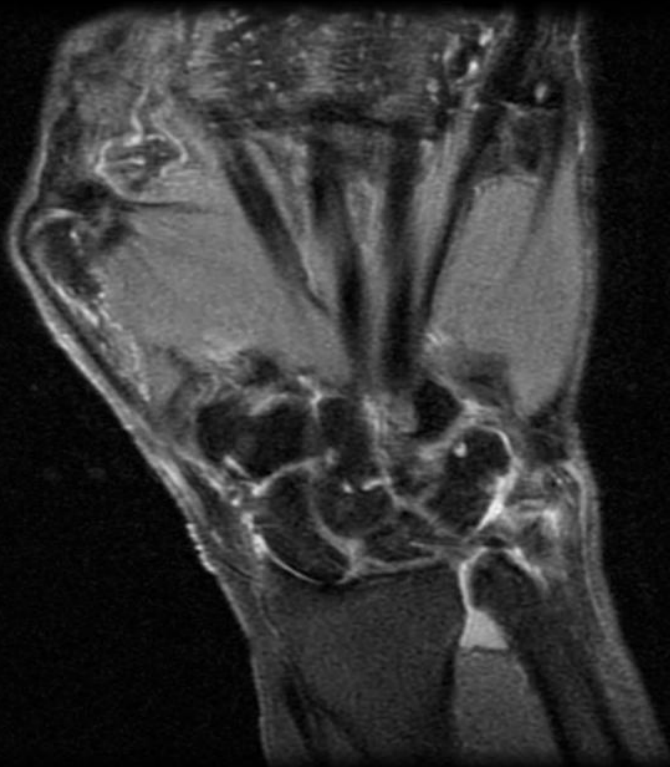


mass

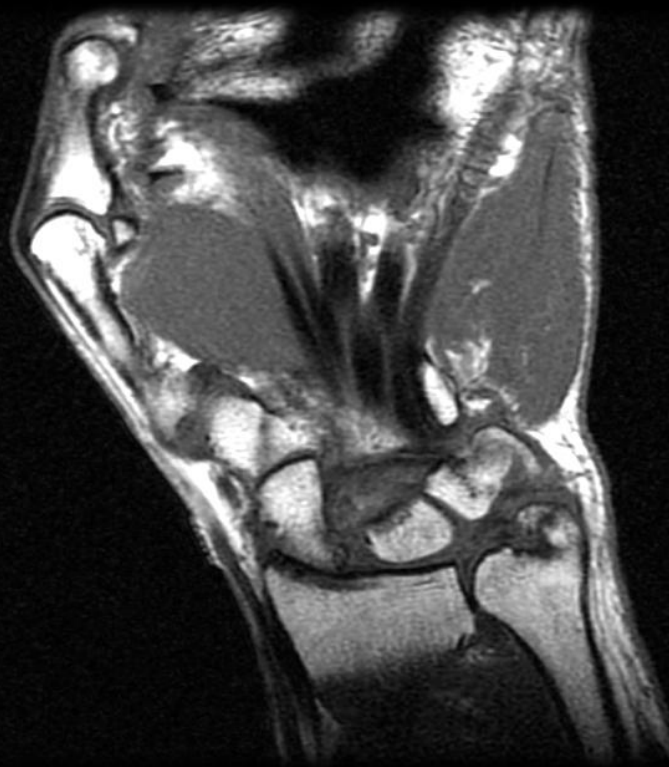
7. Ratio: 8.0



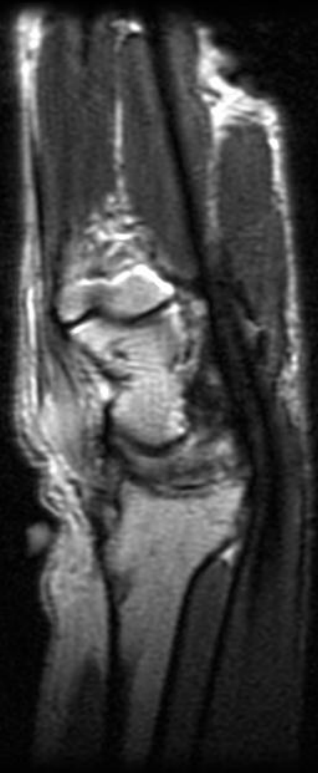6. Ratio: 8.0



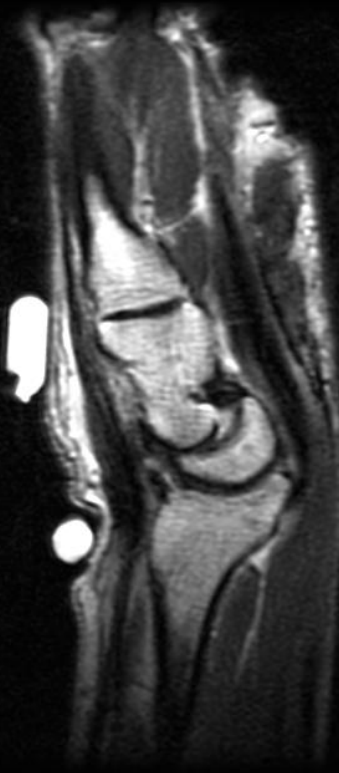5. Ratio: 8.0



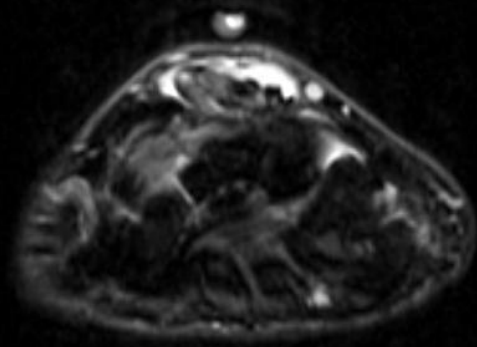
7. Ratio: 8.0



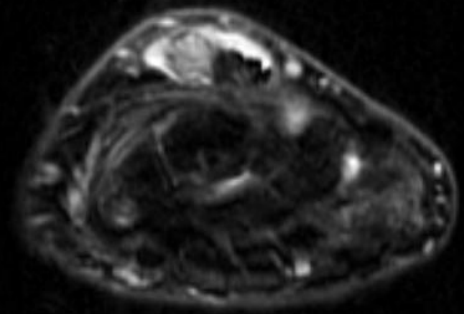
9. Ratio: 8.0



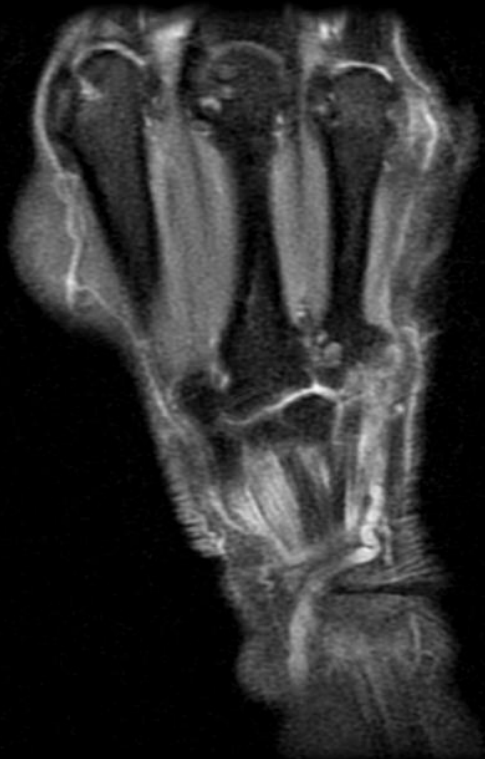12. Ratio: 8.0



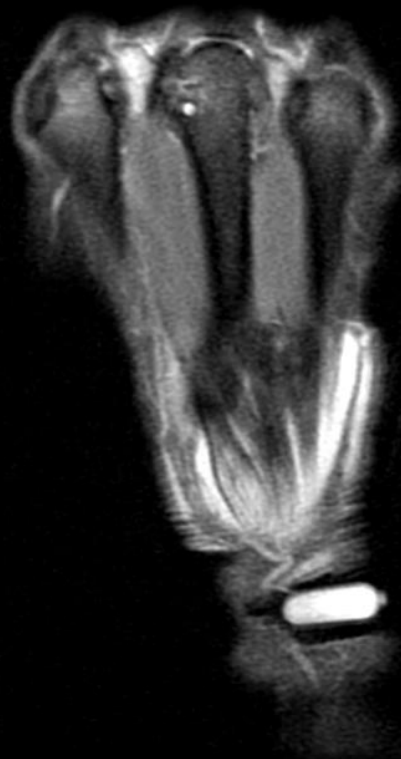
11. Ratio: 8.0



11. Ratio: 8.0



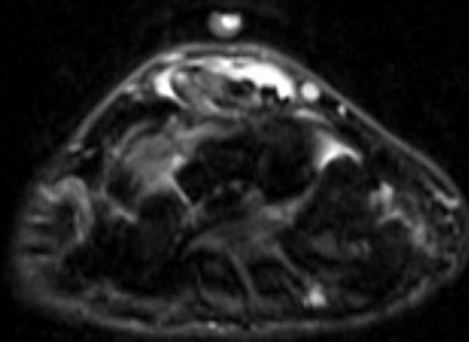
12. Ratio: 8.0



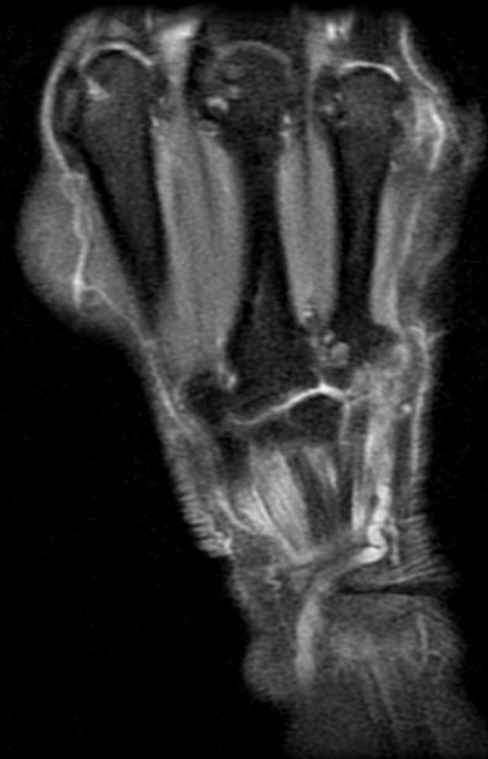

# High Grade PT of 2<sup>nd</sup> digit extensor Tendon

12. Ratio: 8.0



11. Ratio: 8.0





# Treatment

- SLAC 1: Radiostyloidectomy.
  - (may impair RC and part of RL lig- can re-attach to radius w/ anchor).
- SLAC 2: Proximal row carpectomy if cartilage of head of capitate preserved.
- SLAC 3: Scaphoidectomy + reconstruction around normal RL jnt + stabilisation w/ ltd arthrodesis ( CL arthrodesis or 4 corner).

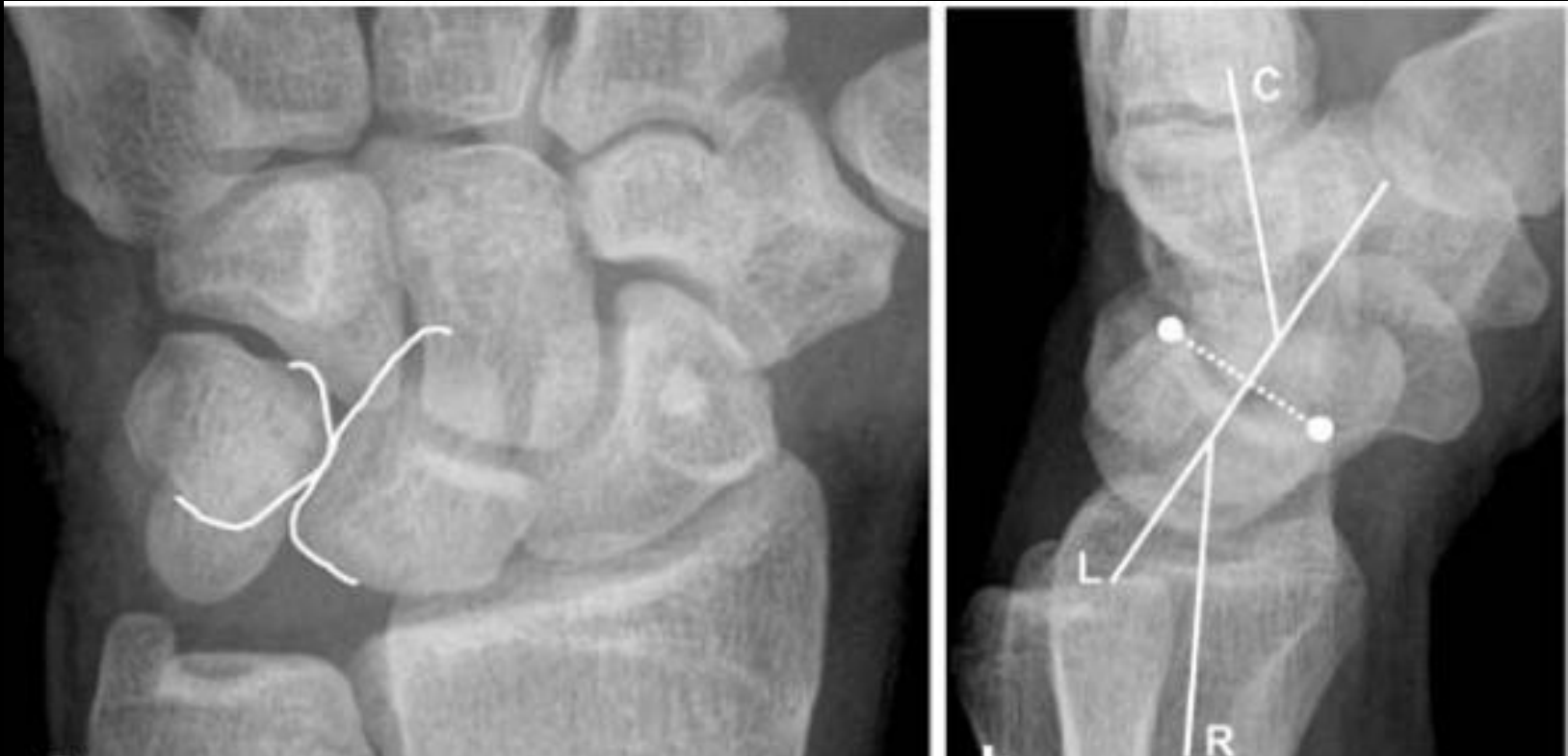# Patterns of Carpal Instability

- Dissociative (CID)
  - Scapholunate dissociation (SLD)
  - Lunotriquetral dissociation (LTD)
  - Scaphoid fractures that are unstable, ununited, or malunited
  - Kienbock's disease
- Non-dissociative (CIND)
  - Radiocarpal
  - Midcarpal
- Complex carpal instability (CIC)
  - Perilunate dislocations
- Adaptive carpal instability (CIA)

# CID: Lunotriquetral Dissociation (LTD)

- Progressive destruction of the LTL
- Mostly described in the context as a later stage of perilunate instability
  - In this progression of instability, the disruption progresses from scapholunate → lunocapitate → lunotriquetral.
- Alternatively, isolated lunotriquetral abnormalities may relate to reverse perilunate injury that begins on the triquetral side of the lunate and proceeds in the radial direction.
- Ulnocarpal impaction is another cause
- a fixed VISI (volar intercalated segmental instability) deformity may occur (but may require failure of other ligaments (ex. Dorsal radiolunotriquetral ligament as well))

# CID-LT dissociation



Lunate is not trapezoid, but moon shaped- VISI.

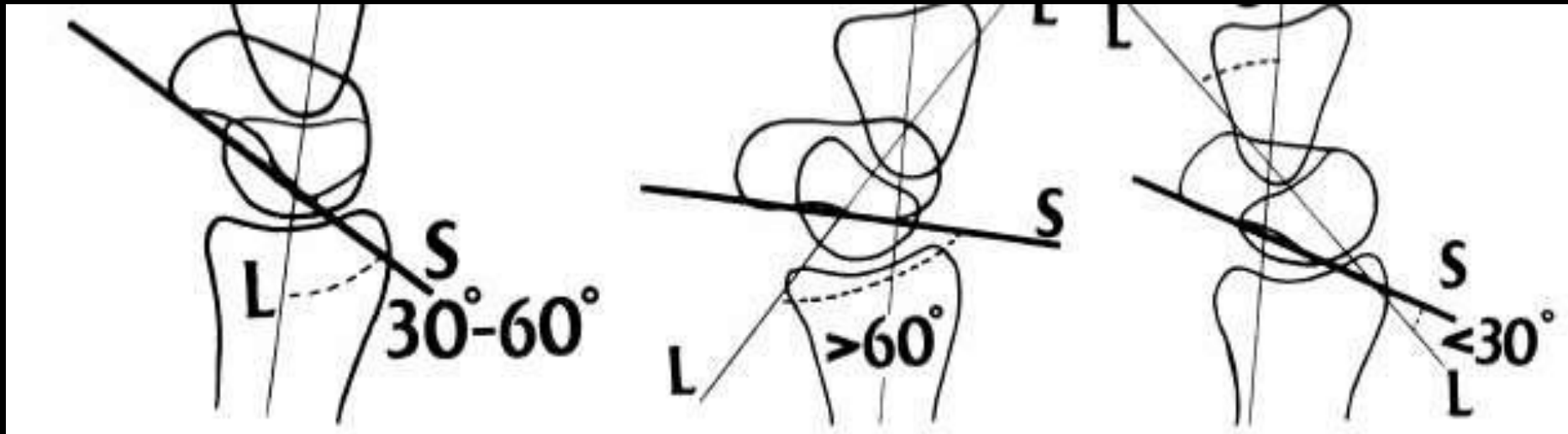
The lunotriquetral joint has nonparallel articulating surfaces

The capitulolunate angle is over 30 degrees.

# Normal

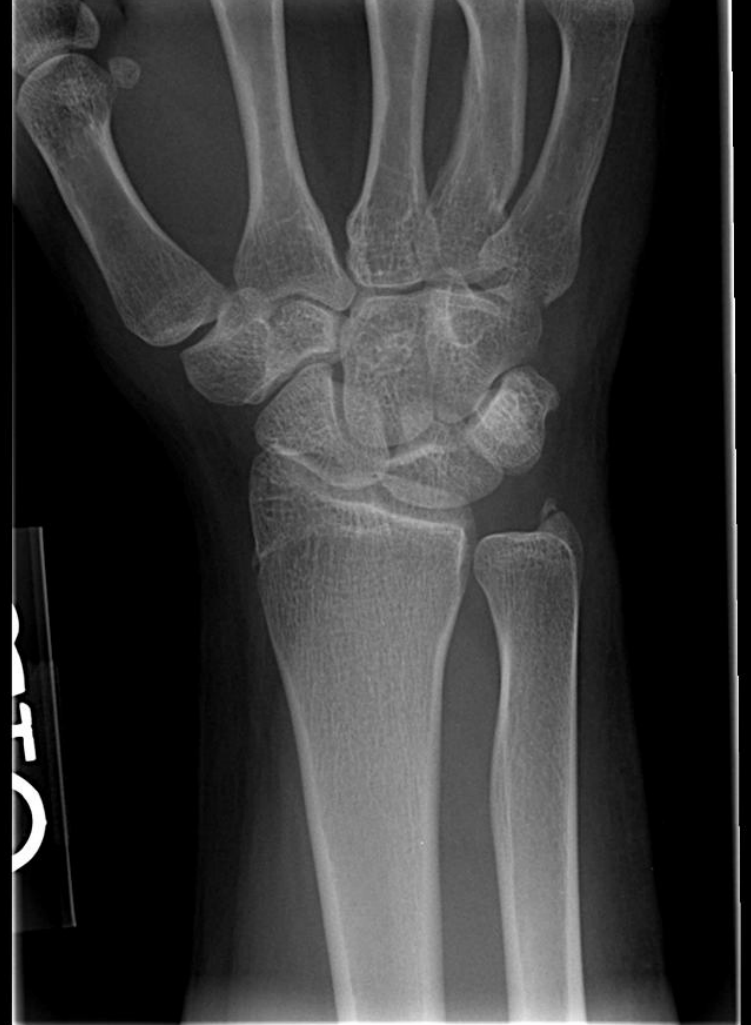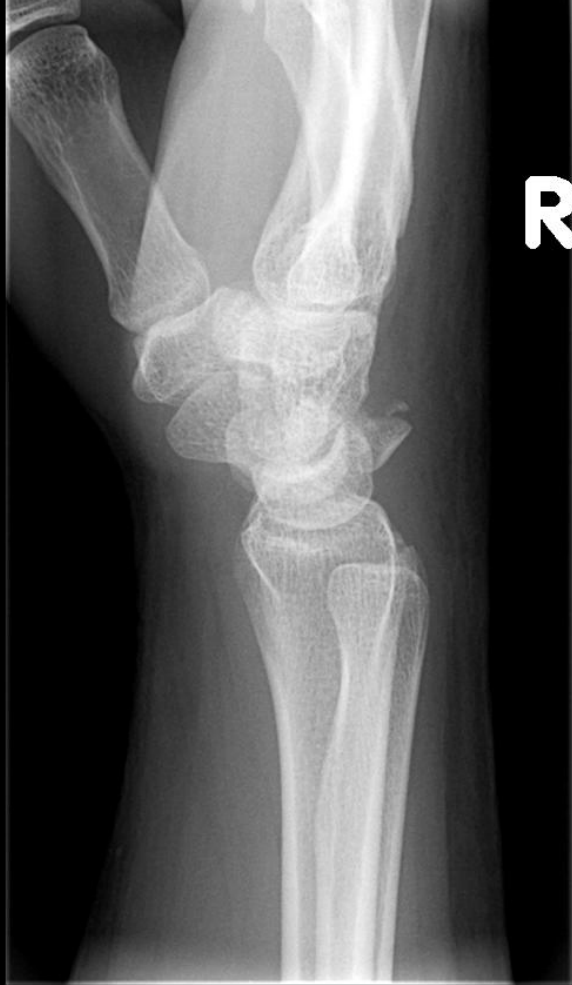# DISI

# VISI

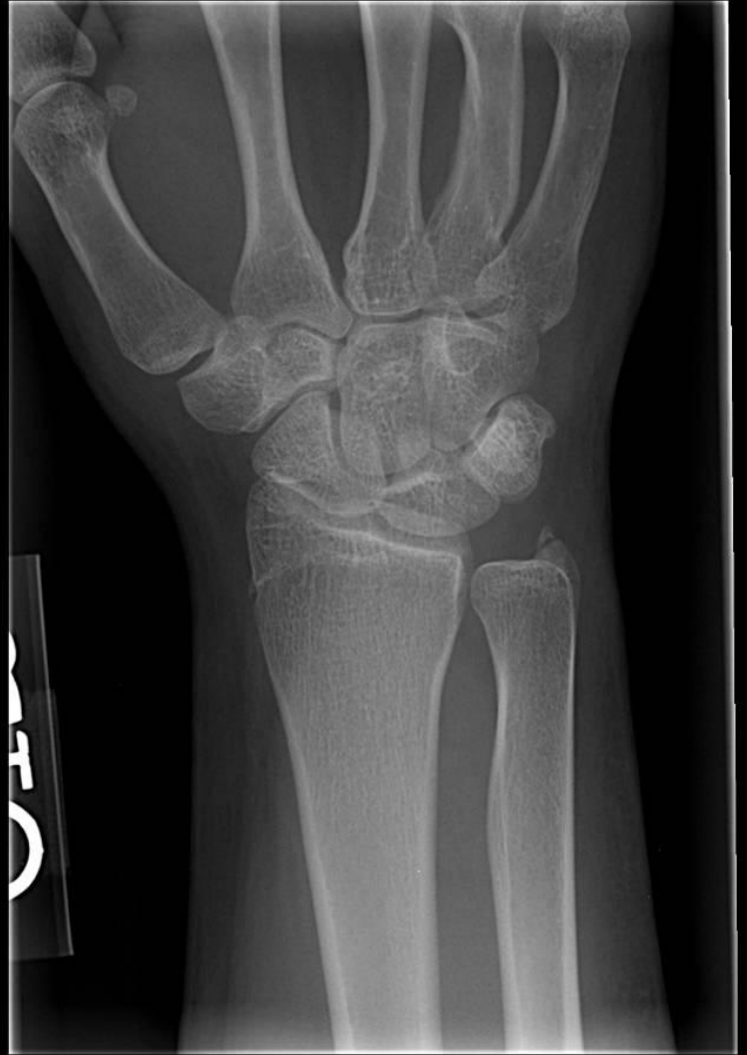
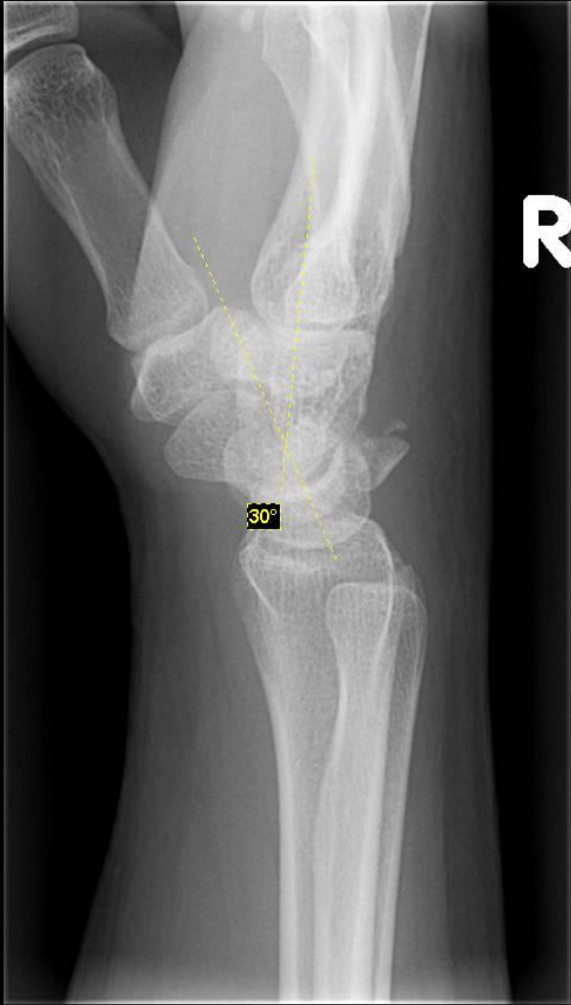
MR imaging of the major carpal stabilizing ligaments: normal anatomy and clinical examples..Radiographics. 1995 May;15(3):575-87

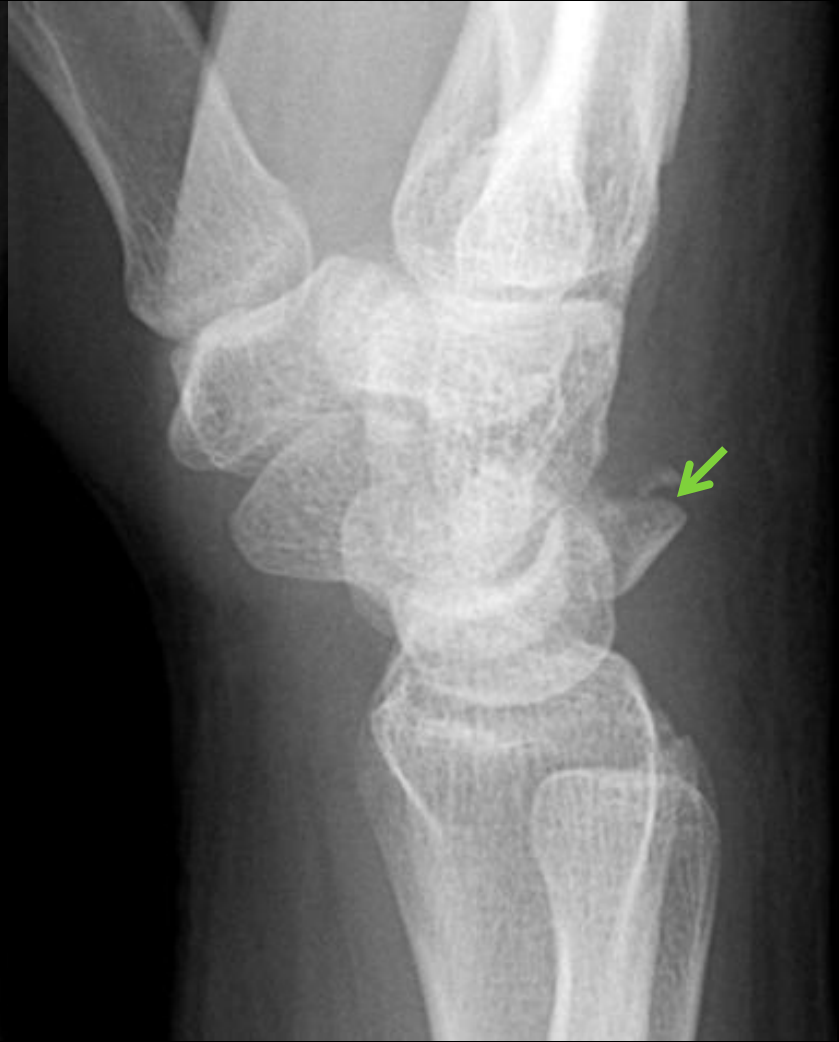
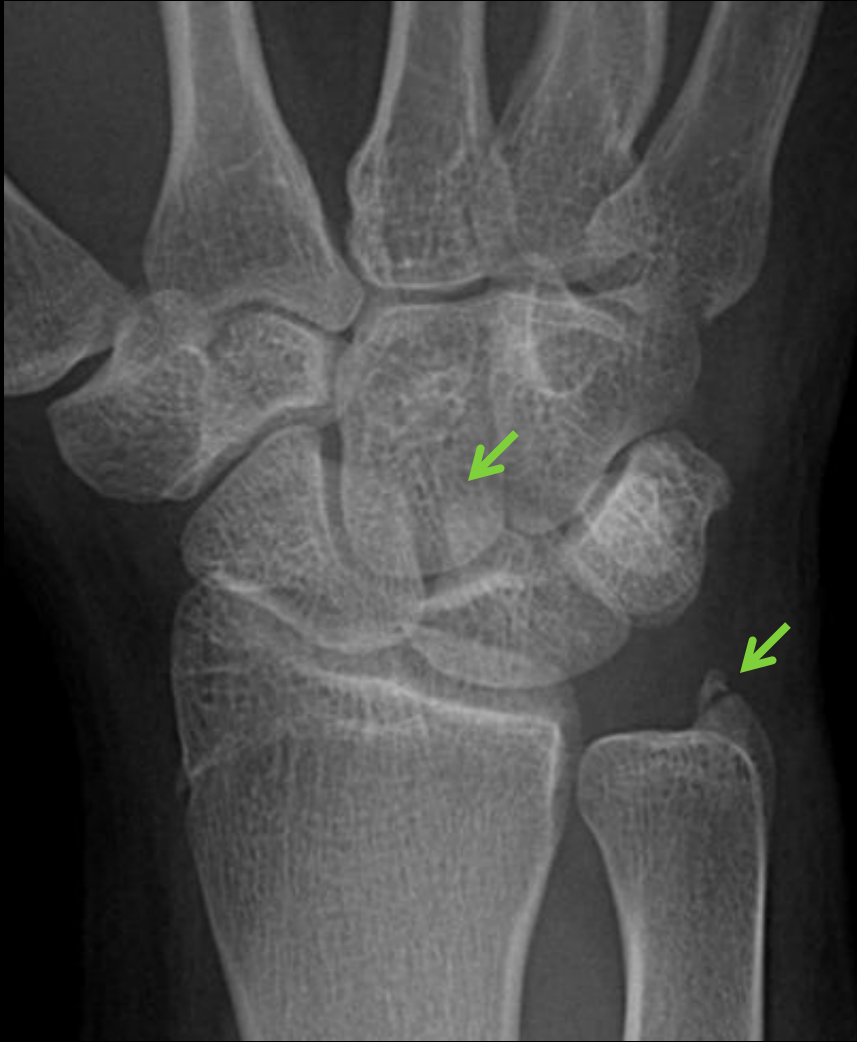


16 y/o with wrist injury, triquetral fx with VISI  
Triquetral fractures may be associated with  
**transscaphoid perilunate dislocations** of the wrist



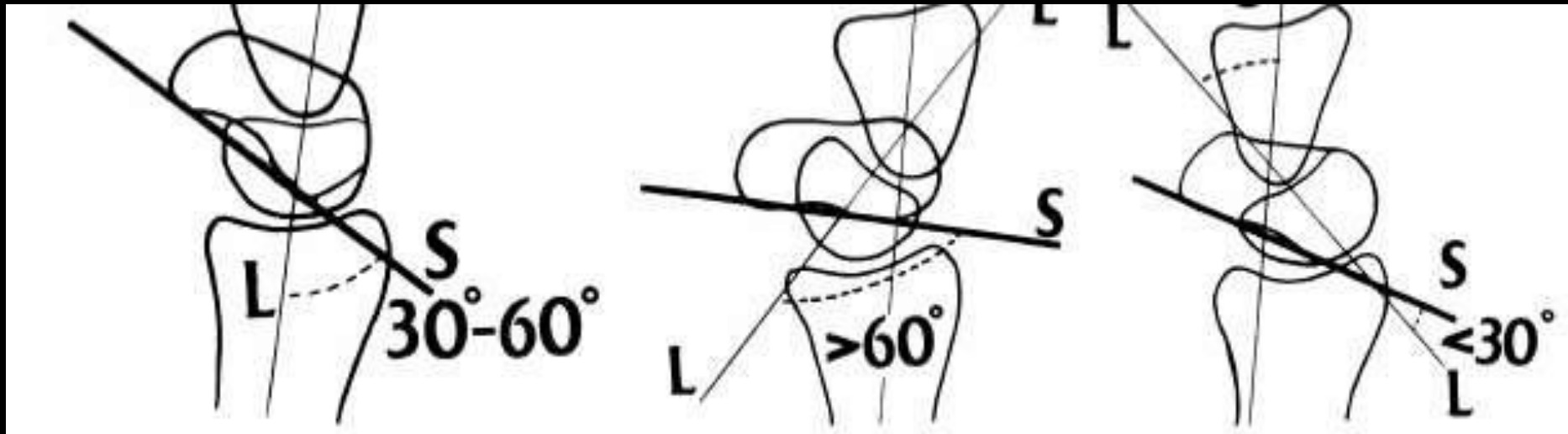




# Normal

# DISI

# VISI



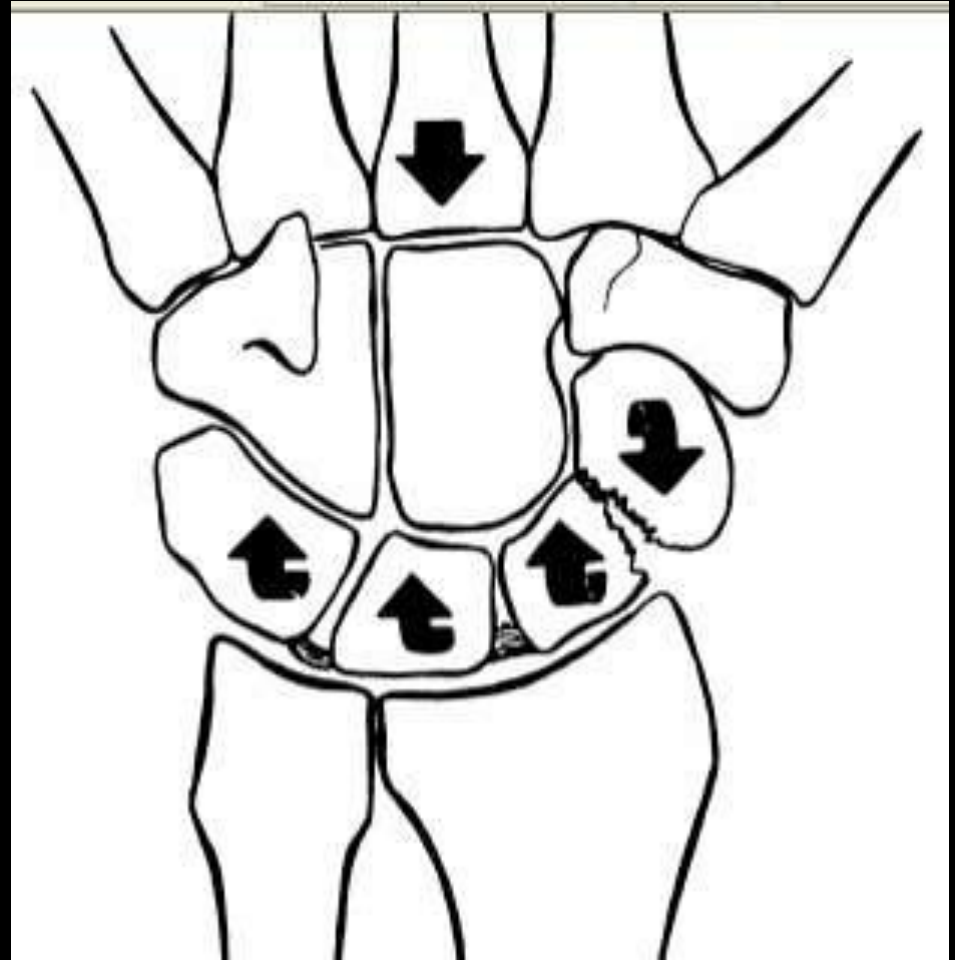
MR imaging of the major carpal stabilizing ligaments: normal anatomy and clinical examples..Radiographics. 1995 May;15(3):575-87

# Patterns of Carpal Instability

- Dissociative (CID)
  - Scapholunate dissociation
  - Lunotriquetral dissociation
  - Scaphoid fractures that are unstable, ununited, or malunited
  - Kienbock's disease
- Non-dissociative (CIND)
  - Radiocarpal
  - Midcarpal
- Complex carpal instability (CIC)
  - Perilunate dislocations
- Adaptive carpal instability (CIA)

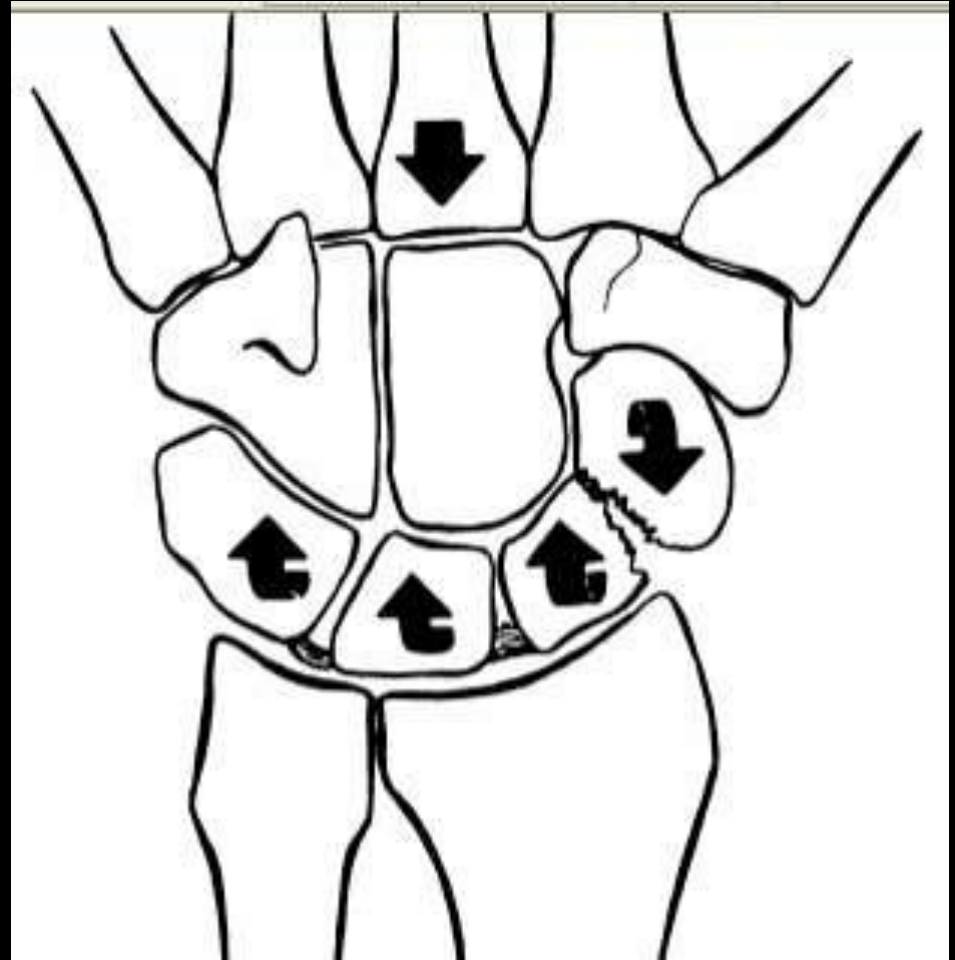
# CID: Scaphoid Fracture

- When 2 (or more) unstable fragments result, the distal fragment rotates with the distal carpal row and the proximal fragment(s) with the proximal carpal row



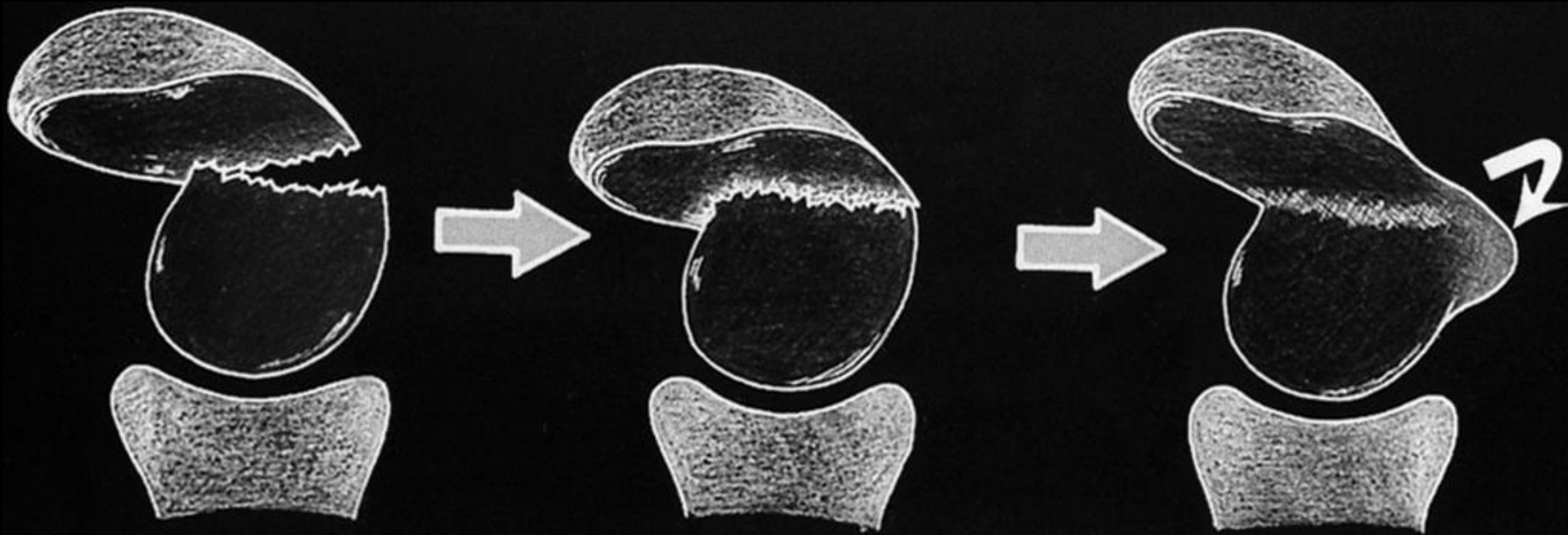

# CID: Scaphoid Fracture

- With an intact SLIL, the proximal scaphoid fragment may rotate dorsally (extend) and the distal scaphoid fragment may flex



## Humpback deformity

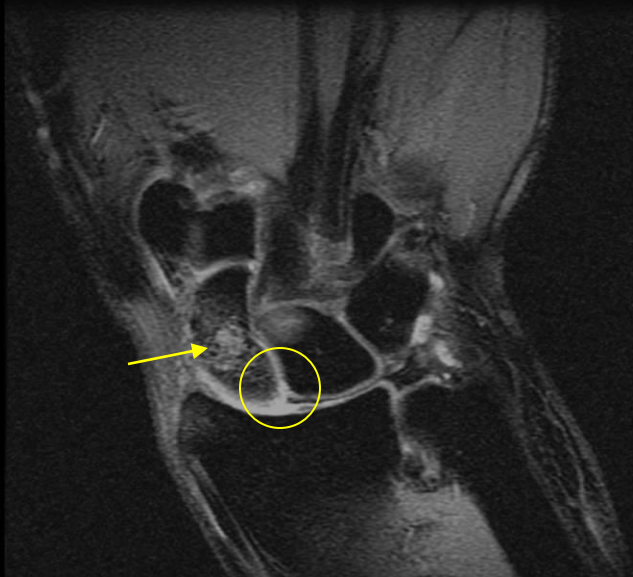
Over time, an unstable fracture nonunion or malunion may appear, with a humpback deformity



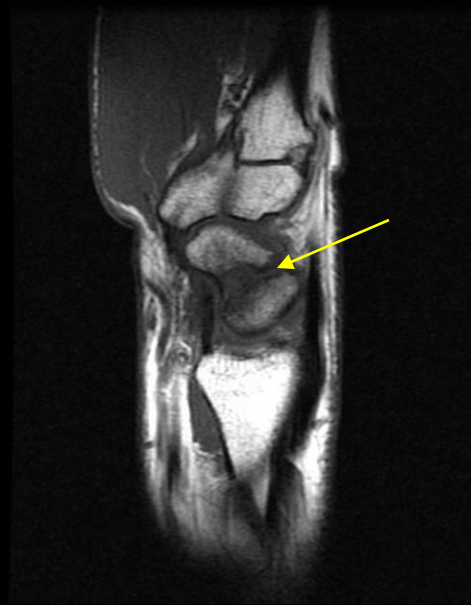
A

# CID: Scaphoid Fracture- 28M with diffuse pain after fall one month ago

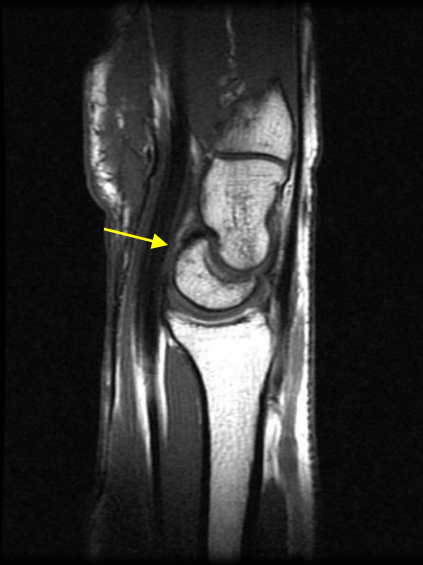9 of 15, Ratio: 6.0, Zoom: 134%



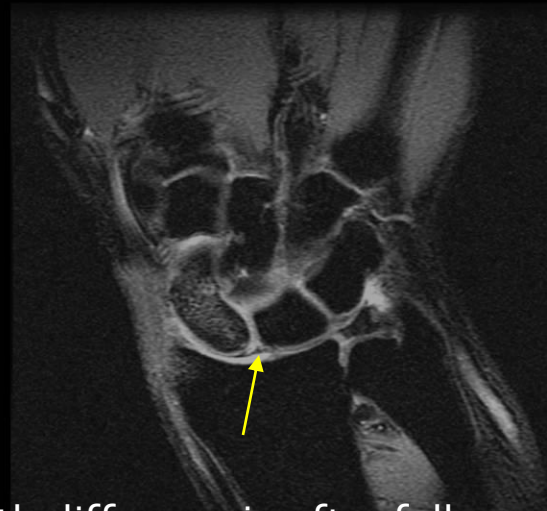4 of 15, Ratio: 6.0, Zoom: 134%



7 of 15, Ratio: 6.0, Zoom: 134%



8 of 15, Zoom: 134%



28M with diffuse pain after fall one month ago



# Scaphoid Fracture: Clinical Presentation

- Mechanism of Injury
  - Hyperextension of the wrist
  - Compressive force (FOOSH)
- Snuff-box pain, LROM, Weak grip
- Age 15 to 40



# Scaphoid Fracture: Clinical Presentation

- 65% of carpal fractures
- 5-12% of scaphoid fractures are associated with other fractures
- Waist fx : 70%
- Proximal pole fx : 20%

# Scaphoid Fracture: Imaging Evaluation

- Radiographs
  - PA, lateral, external oblique, and scaphoid views
- CT
- MR
  - Gado may help evaluate proximal pole blood supply
- Bone scintigraphy

# Complications

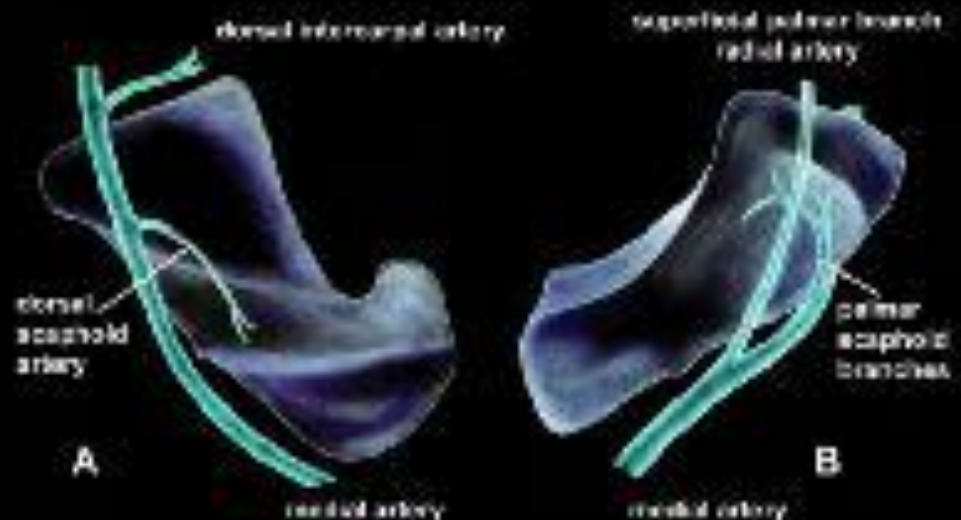
- Nonunion
  - Occurs in 50% of unstable fractures after nonsurgical /inadequate treatment
  - If delay in treatment of > 4wks
  - Long-standing scaphoid non-union leads to carpal collapse, known as scaphoid nonunion advanced collapse (SNAC) wrist

- Malunion

- Osteonecrosis

- More common in proximal pole

- Arthritis



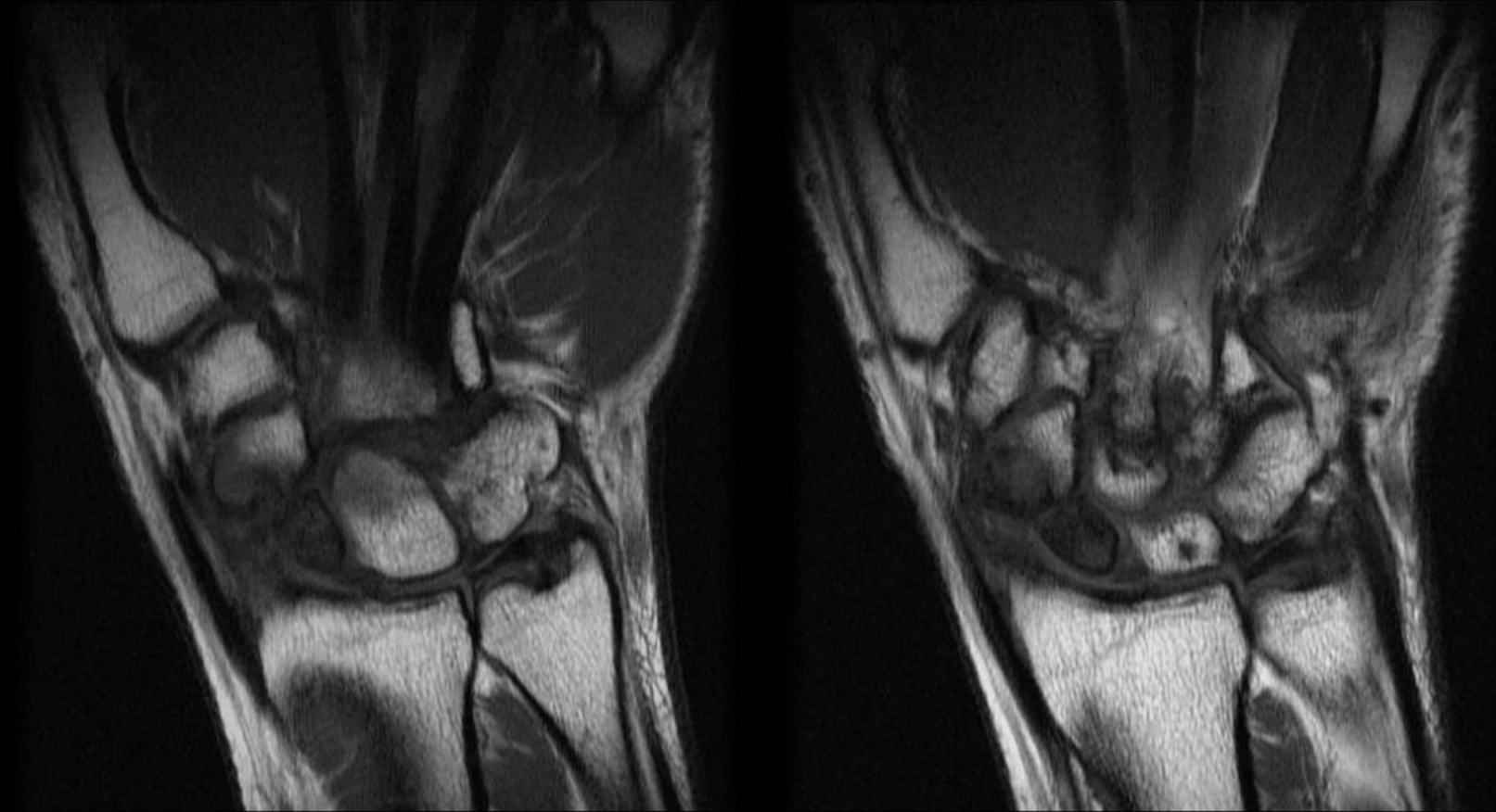
# Treatment of scaphoid fx

- Stable fractures (nondisplaced)
  - Thumb-spica cast
  - 95% healing rate
- Unstable fractures
  - Surgical treatment

# CID: Scaphoid nonunion

9 of 15. Ratio: 6.0. Zoom: 98%

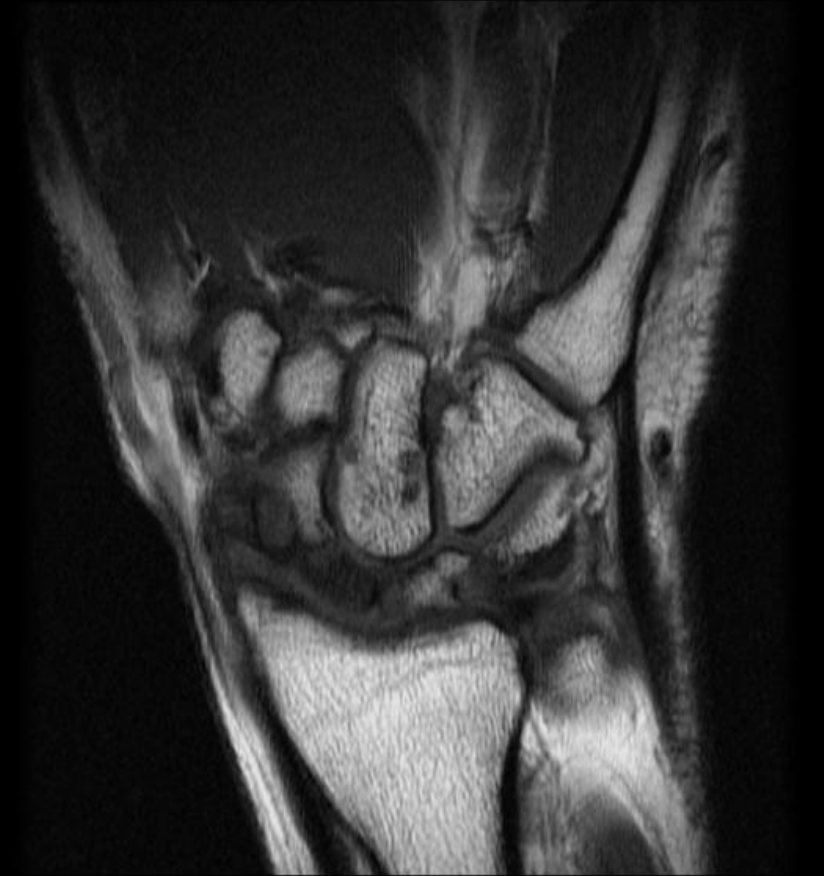8 of 15. Zoom: 98%



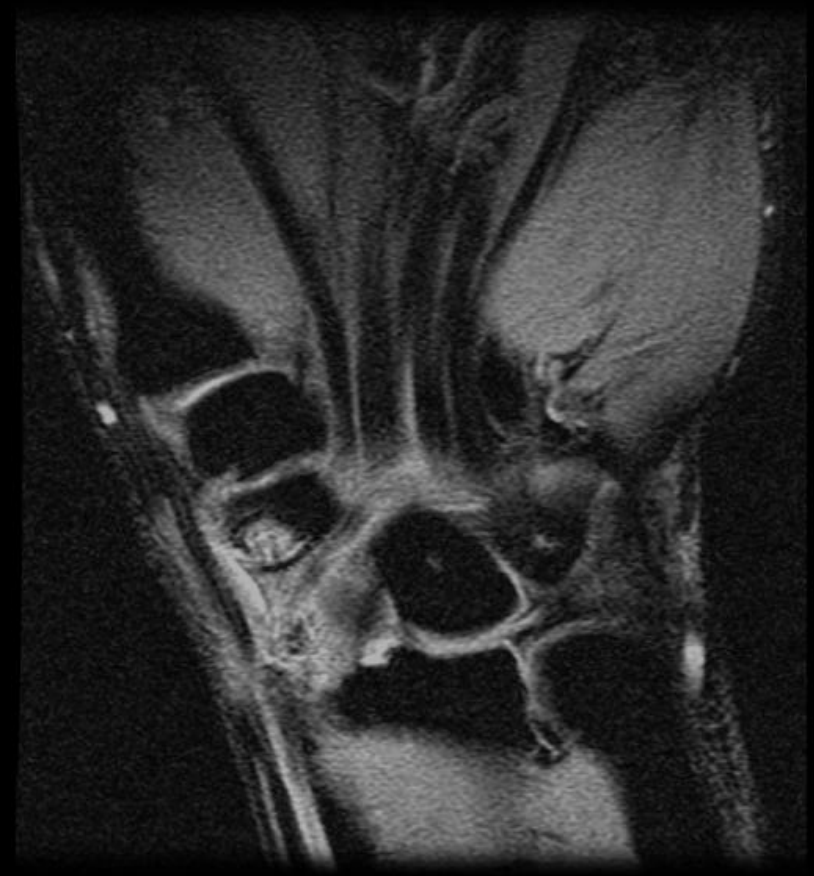35 year old male with direct trauma with a board 3 weeks ago.

# Cystic change in distal pole

7 of 15. Ratio: 6.0. Zoom: 98%

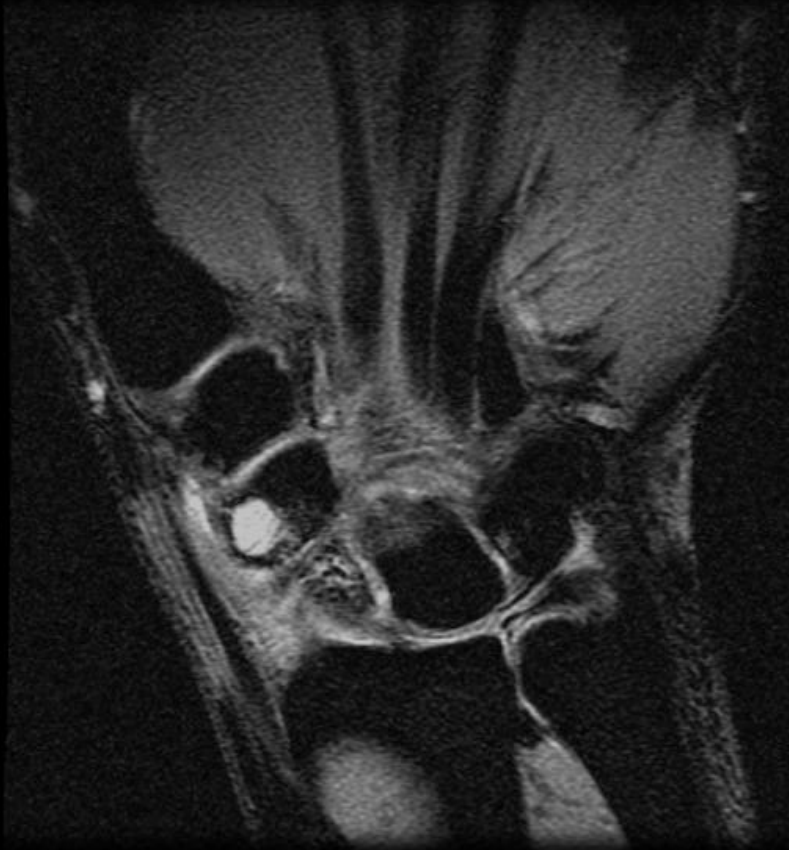

10 of 15. Ratio: 6.0. Zoom: 98%

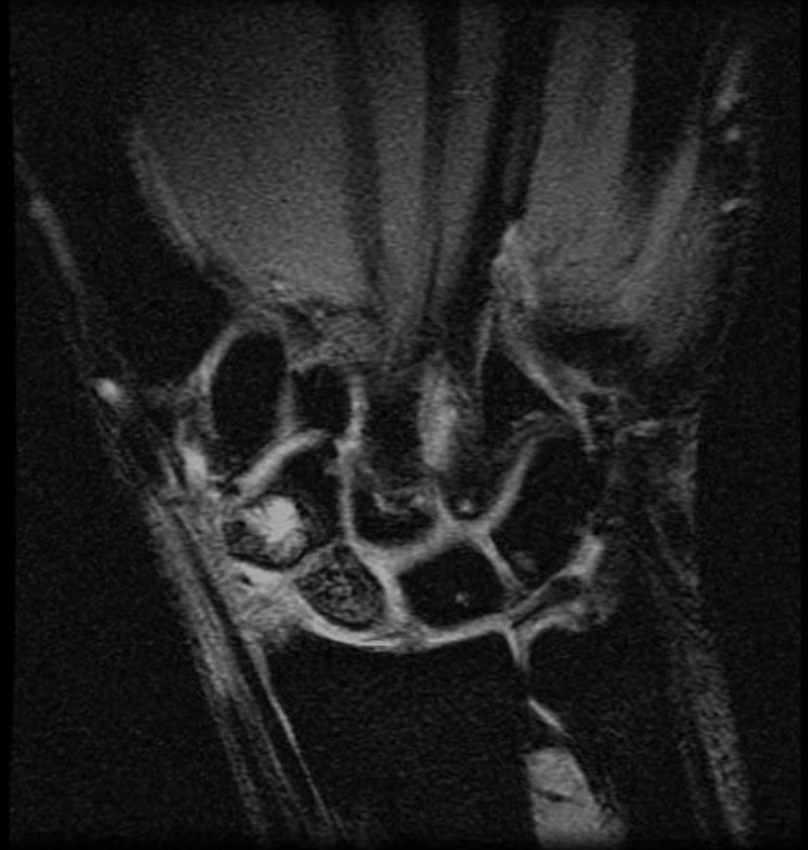

# Scapholunate intact

9 of 15. Ratio: 6.0. Zoom: 98%



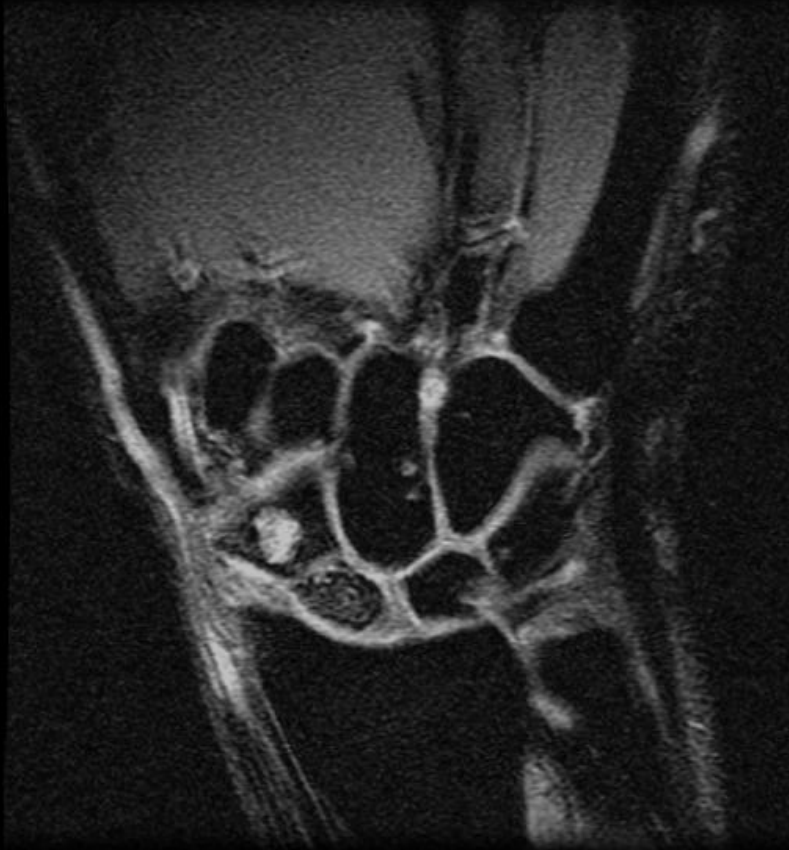8 of 15. Zoom: 98%



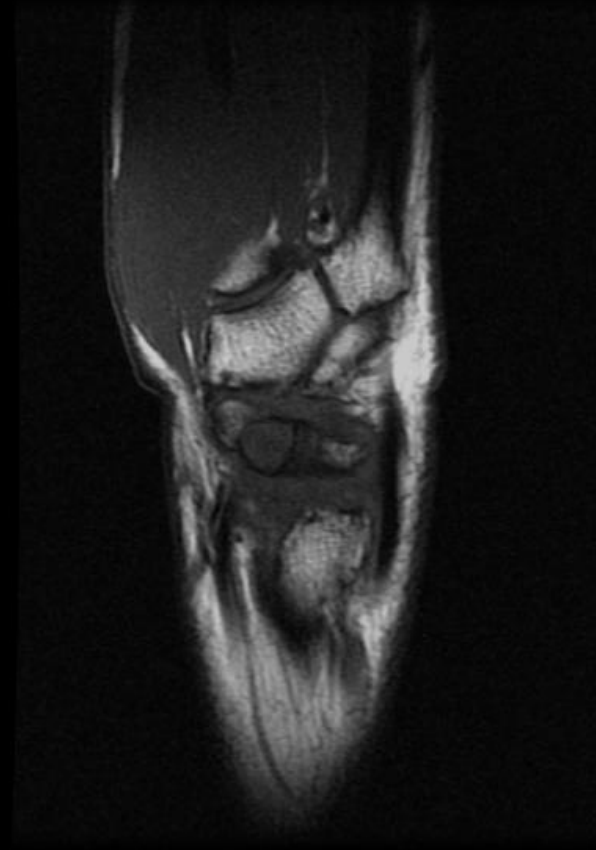


# Humpback deformity

7 of 15. Ratio: 6.0. Zoom: 98%



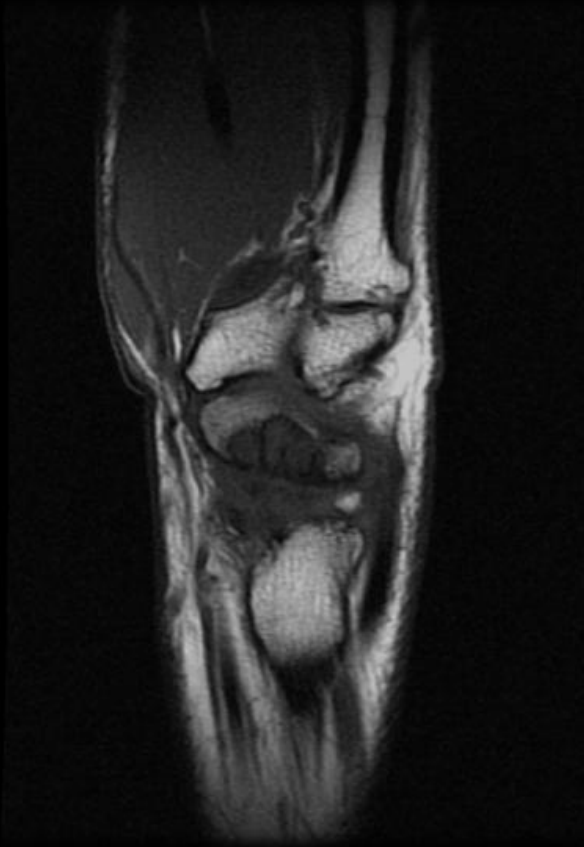
4 of 19. Ratio: 6.0. Zoom: 98%



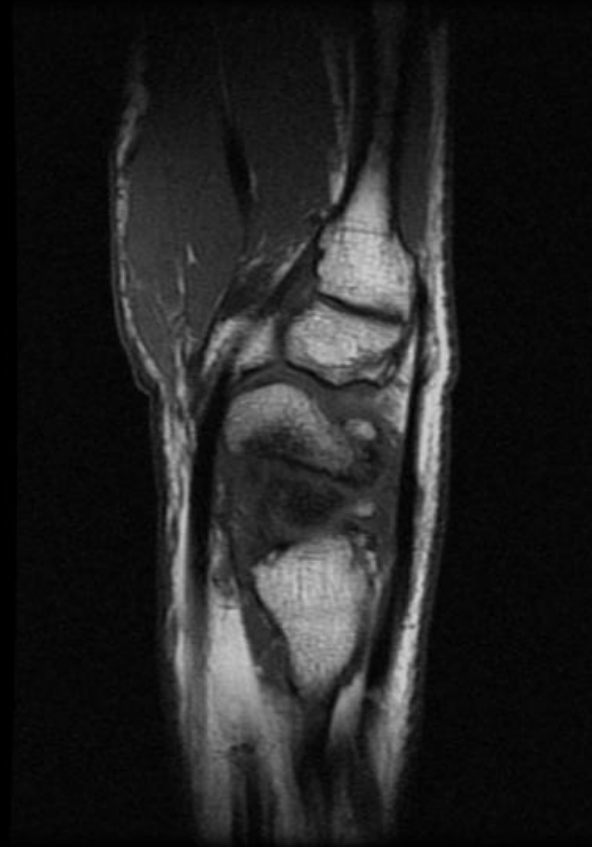


# Humpback deformity- volar tilting distal pole of scaphoid

5 of 19. Ratio: 6.0. Zoom: 98%

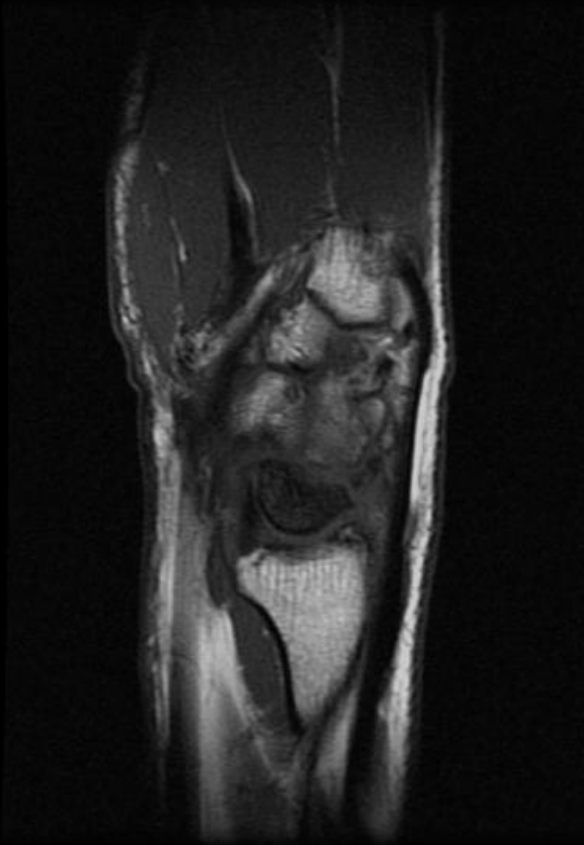


6 of 19. Ratio: 6.0. Zoom: 98%

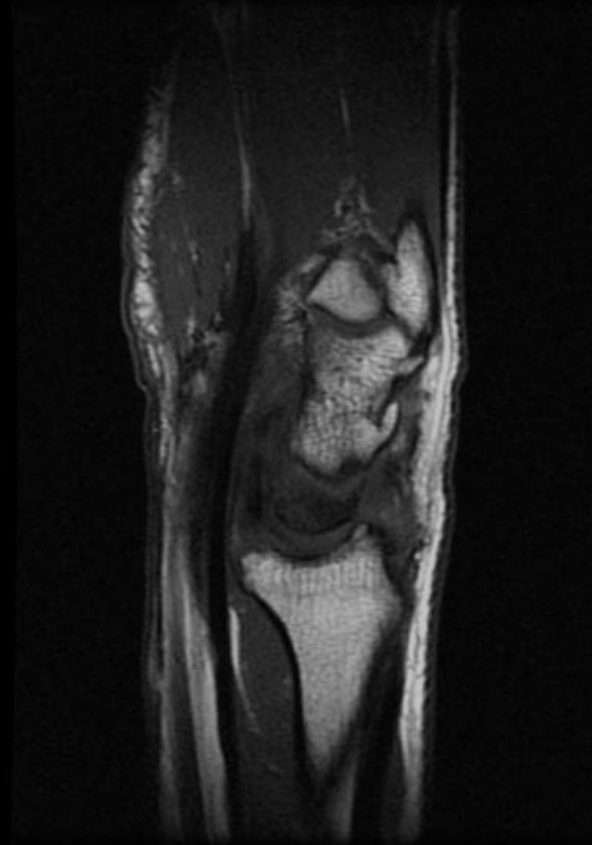

# Dorsal tilting of proximal portion scaphoid

7 of 19. Ratio: 6.0. Zoom: 98%

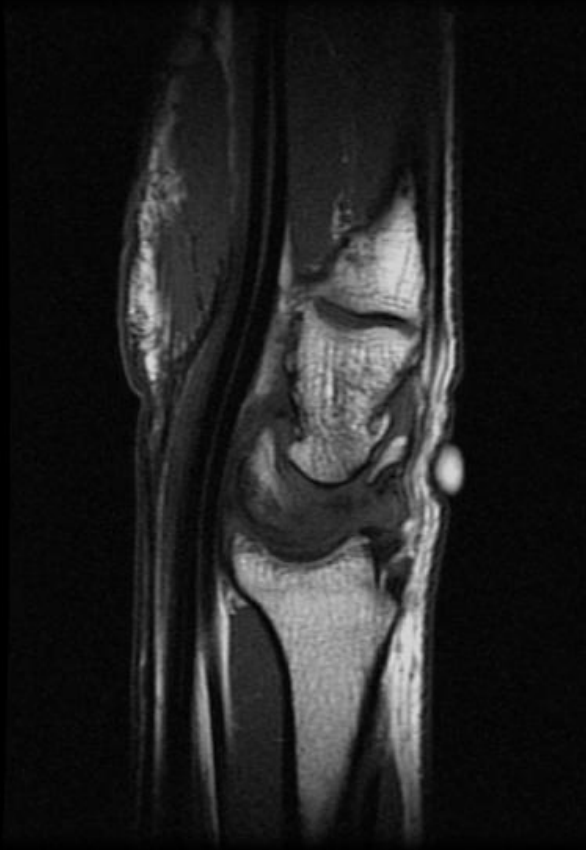


8 of 19. Ratio: 6.0. Zoom: 98%

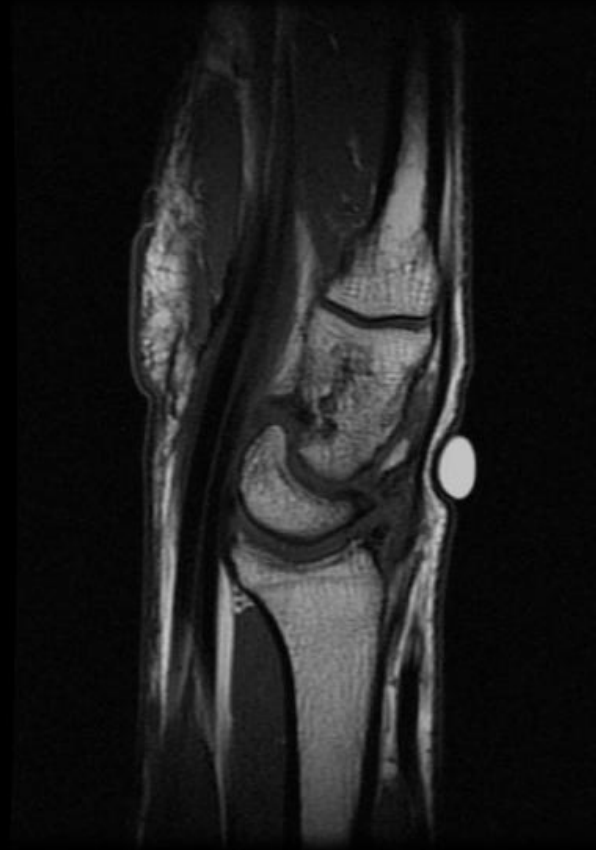

# Dorsal tilting of lunate. Bony fragment

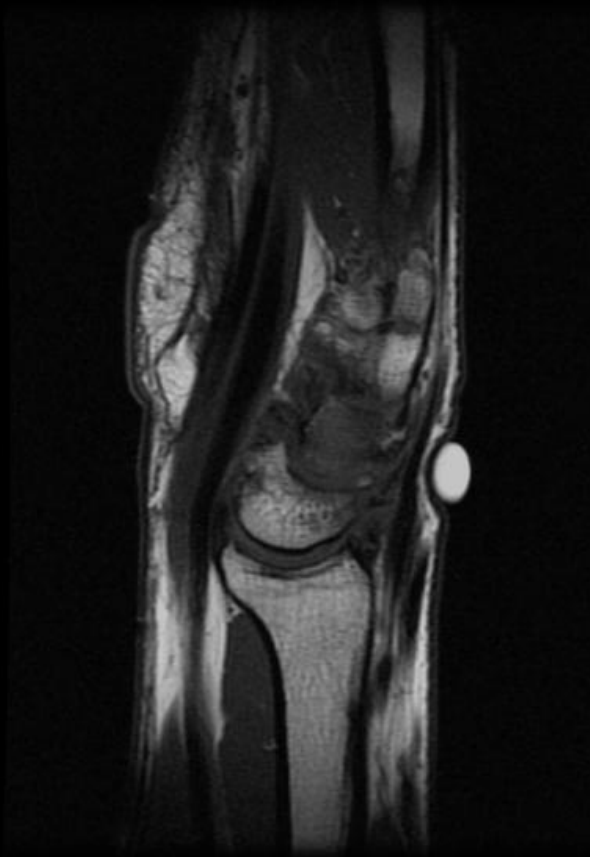
9 of 19. Ratio: 6.0. Zoom: 98%



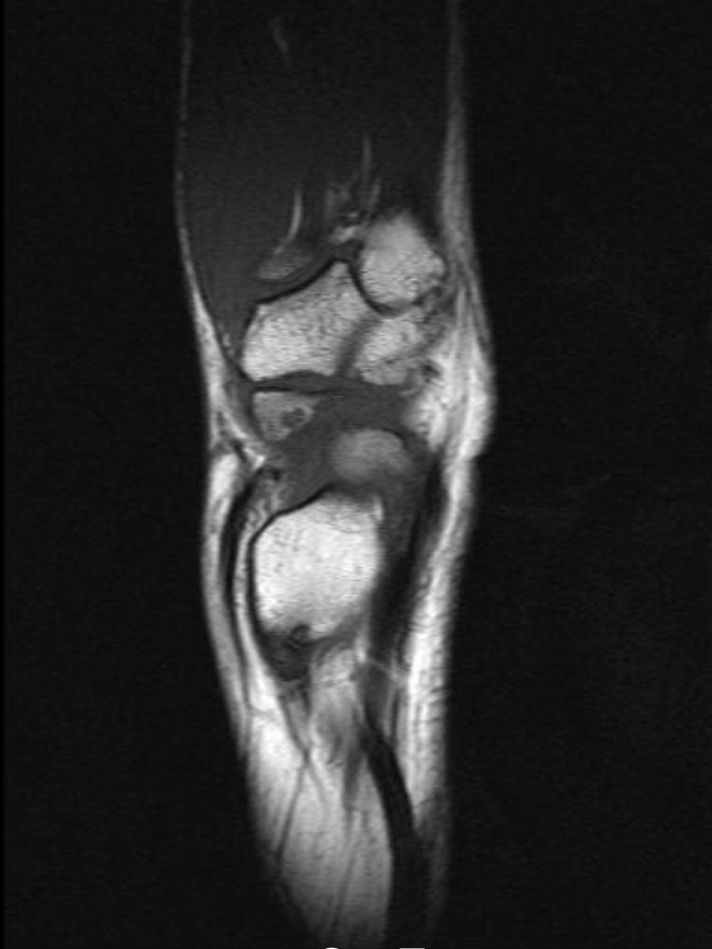10 of 19. Zoom: 98%



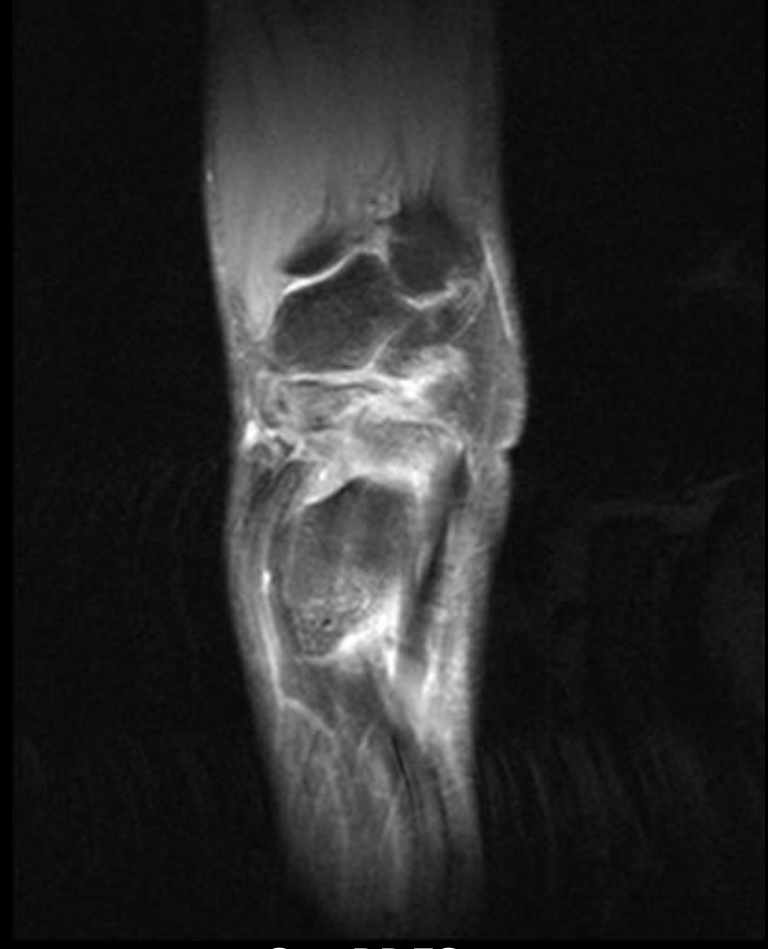
11 of 19. Ratio: 6.0. Zoom: 98%



# Scaphoid Nonunion - DISI - Humpback- another example

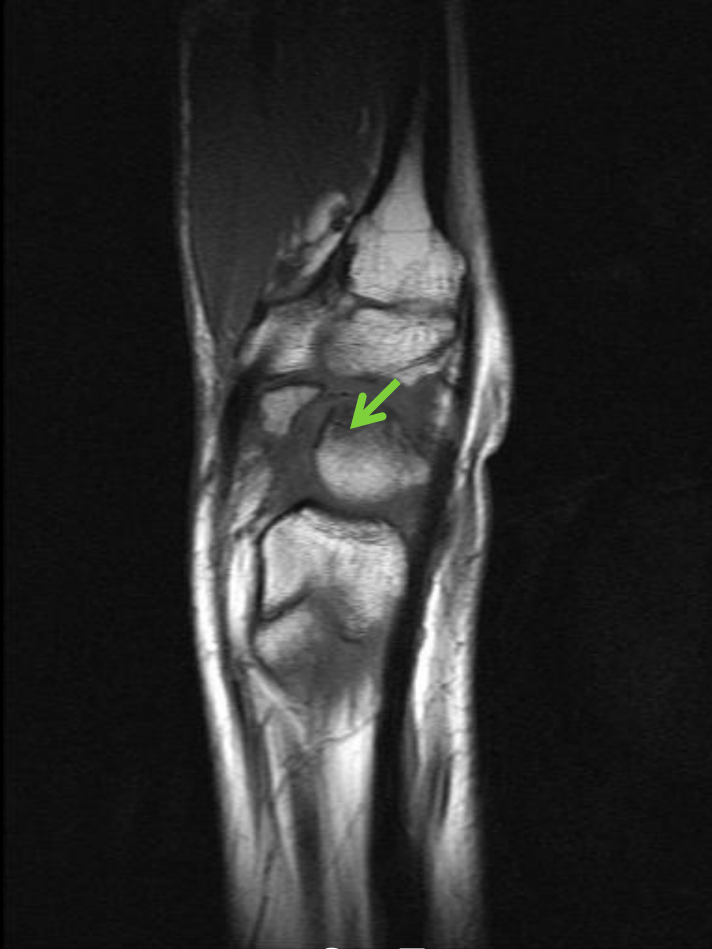

Sag T1

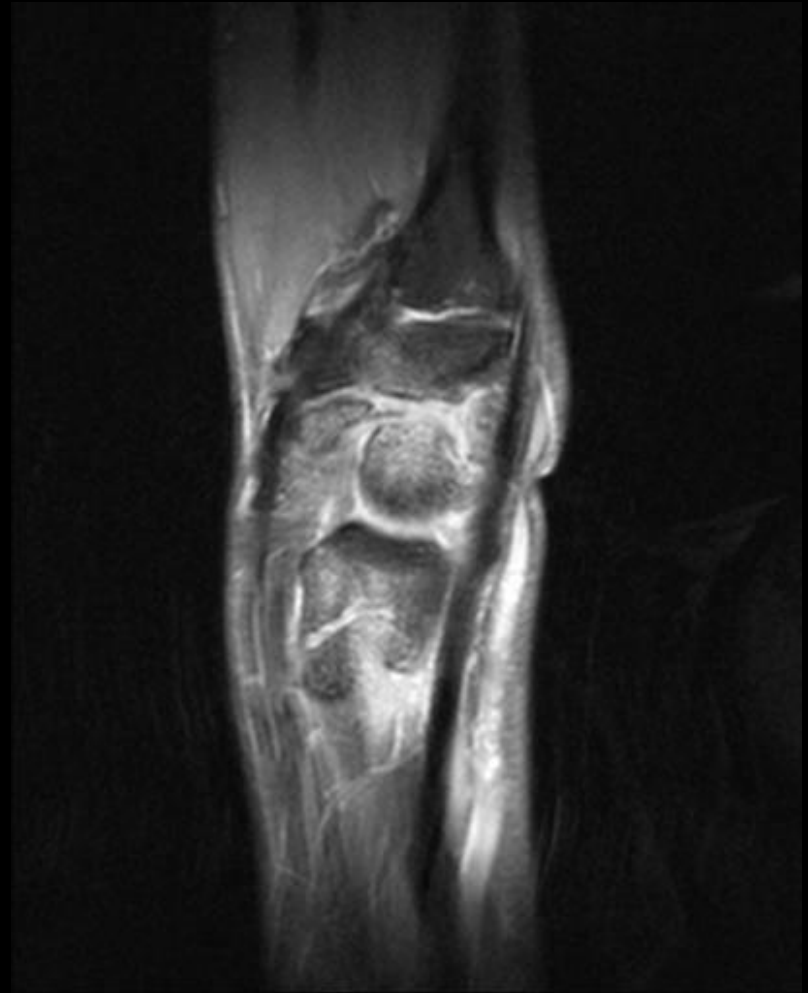

Sag PDFS

# Scaphoid Nonunion - DISI - Humpback

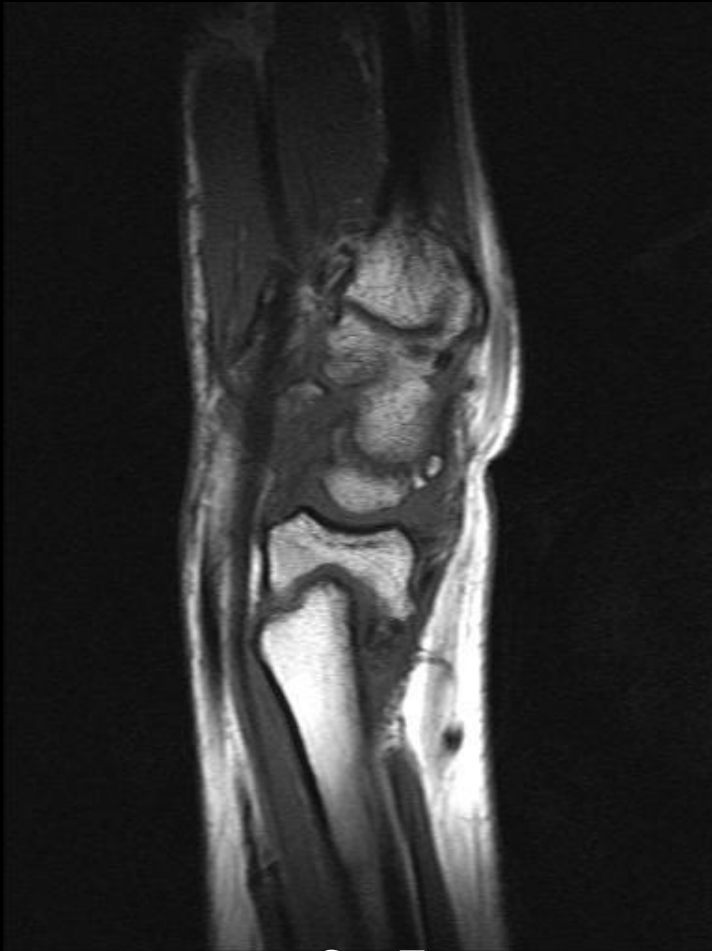

Sag T1

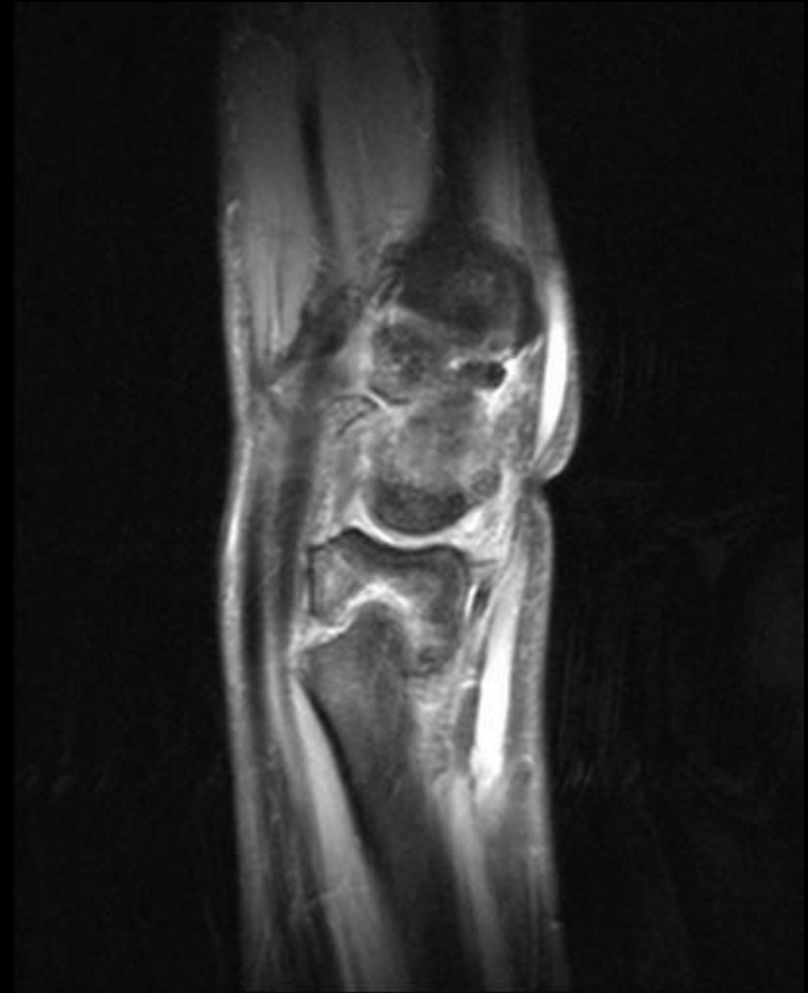

Sag PDFS

# Scaphoid Nonunion - DISI - Humpback



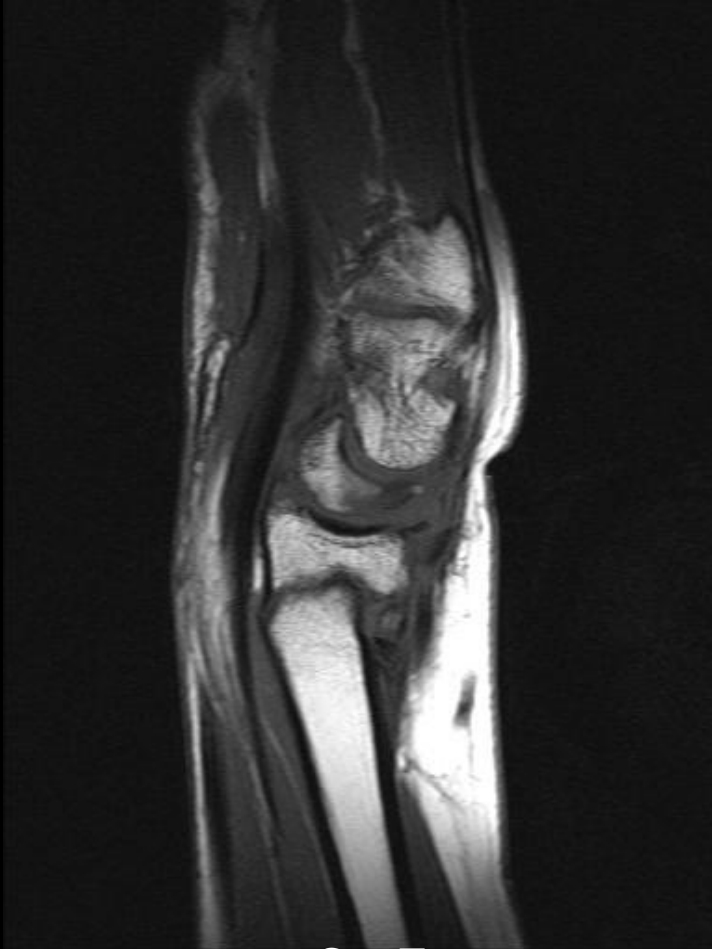Sag T1



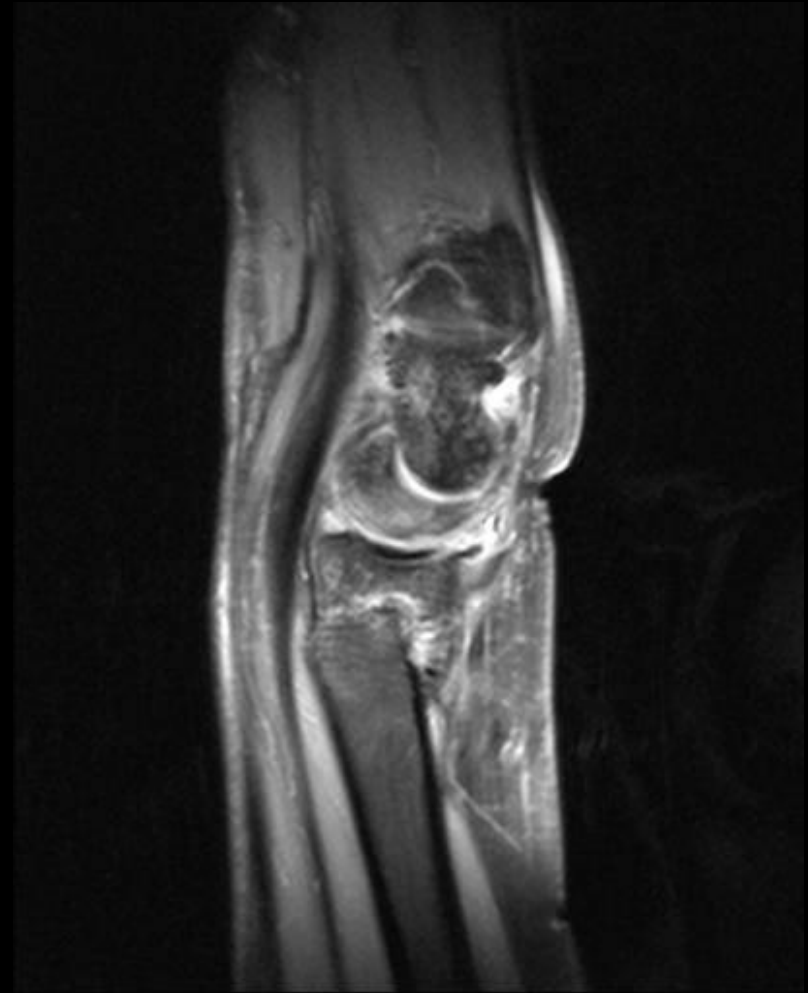Sag PDFS



# Scaphoid Nonunion - DISI - Humpback



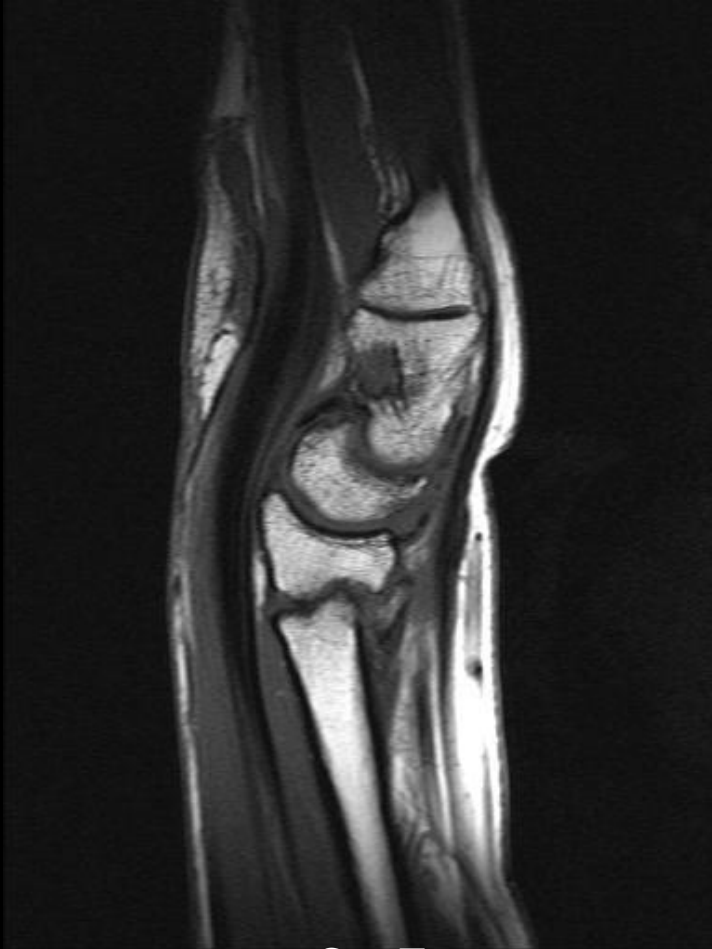
Sag T1



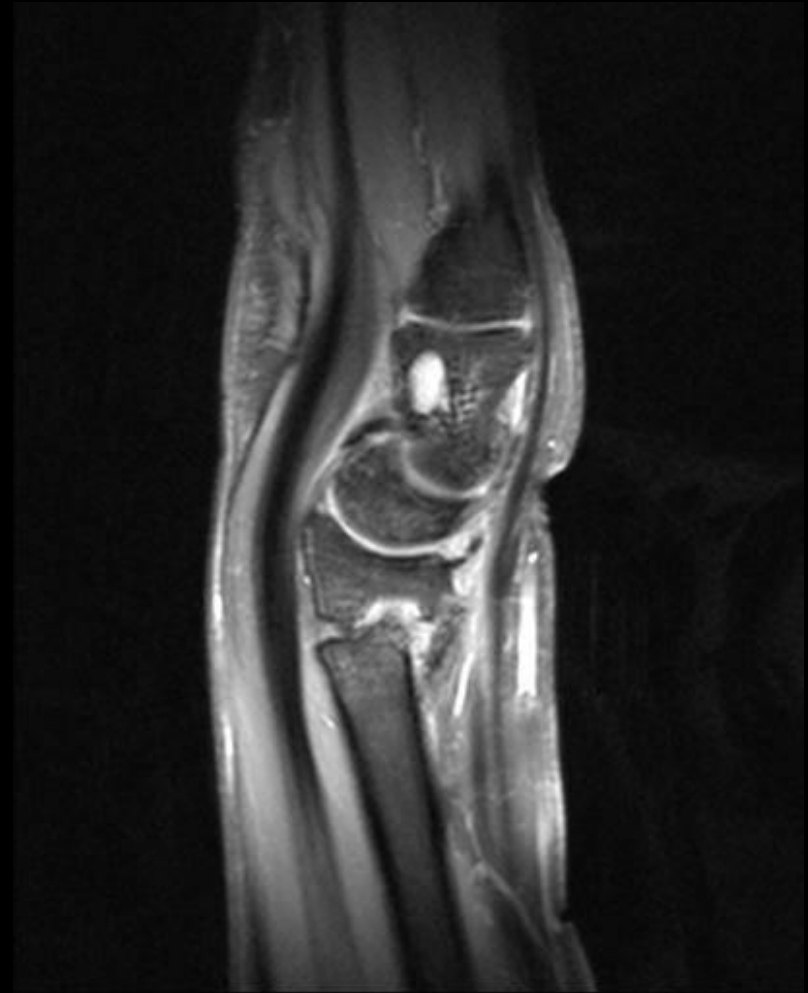
Sag PDFS



# Scaphoid Nonunion - DISI - Humpback

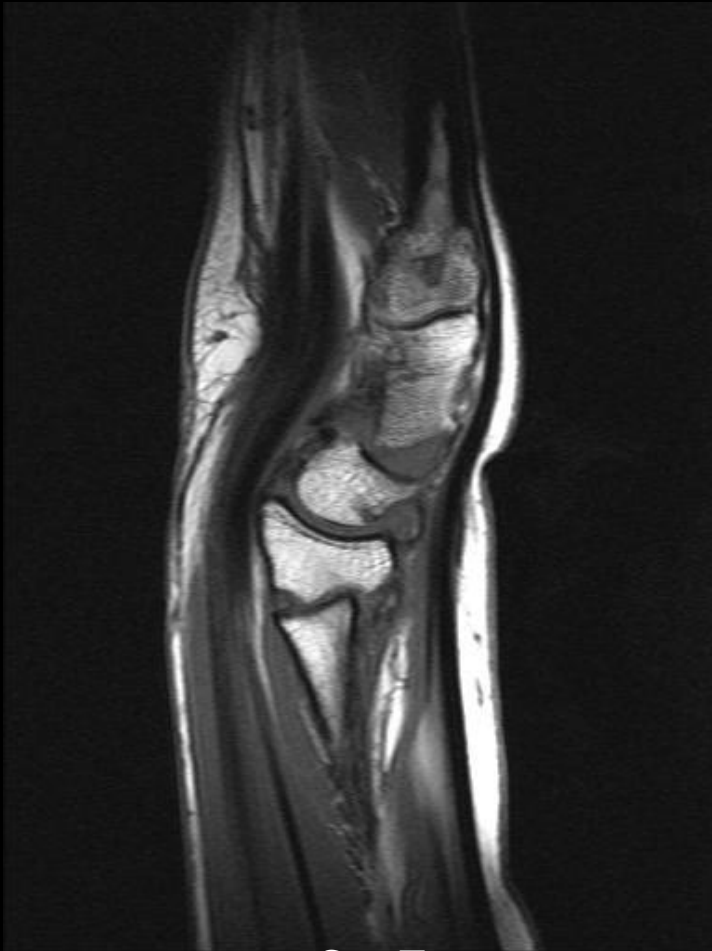

Sag T1

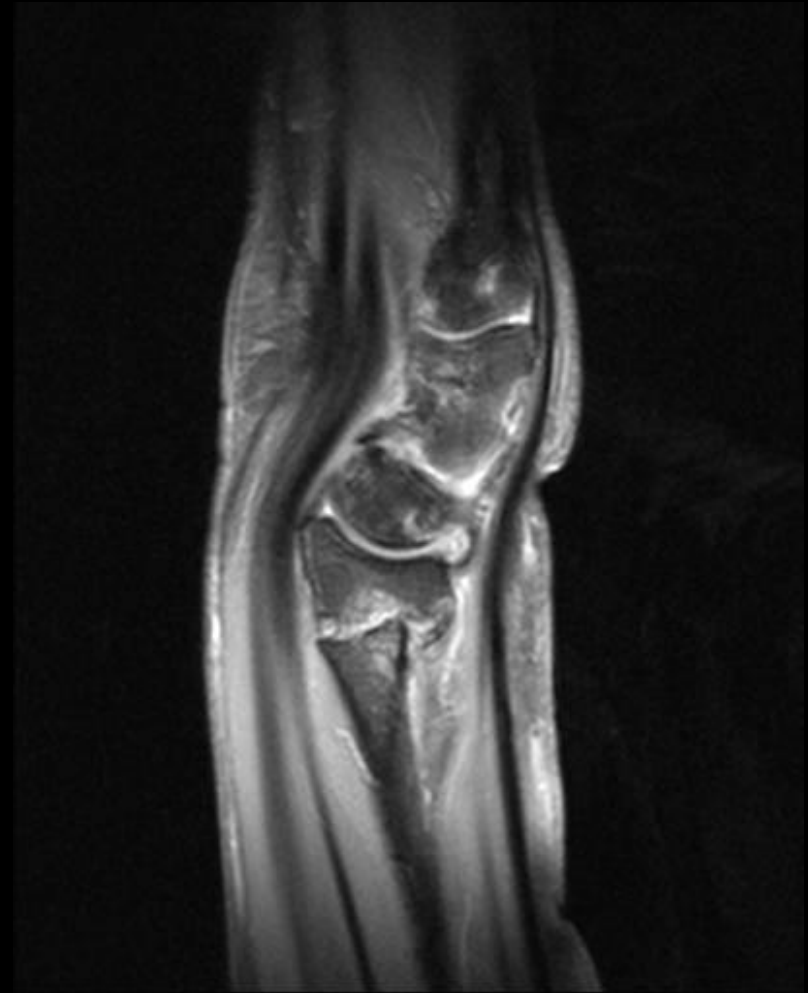

Sag PDFS

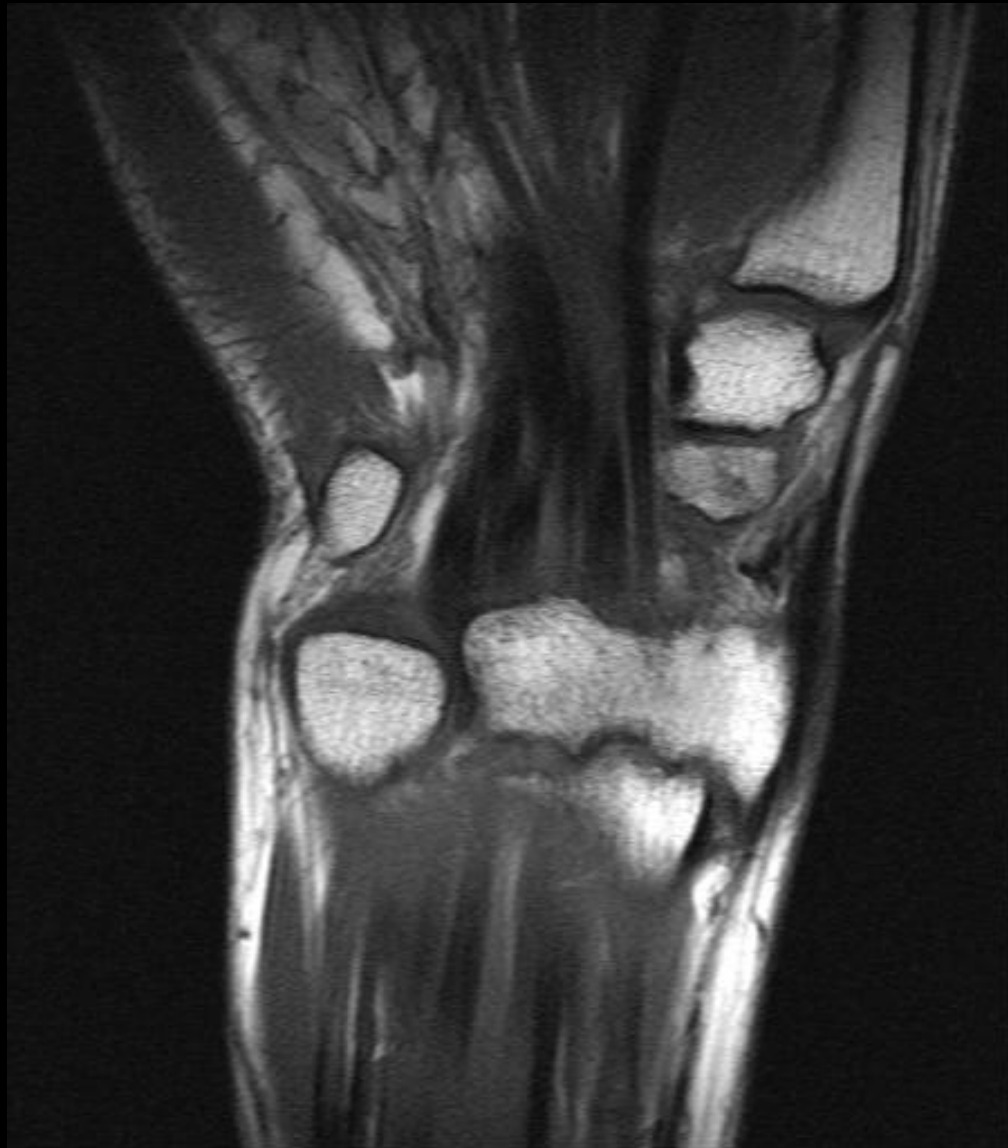# Scaphoid Nonunion - DISI - Humpback

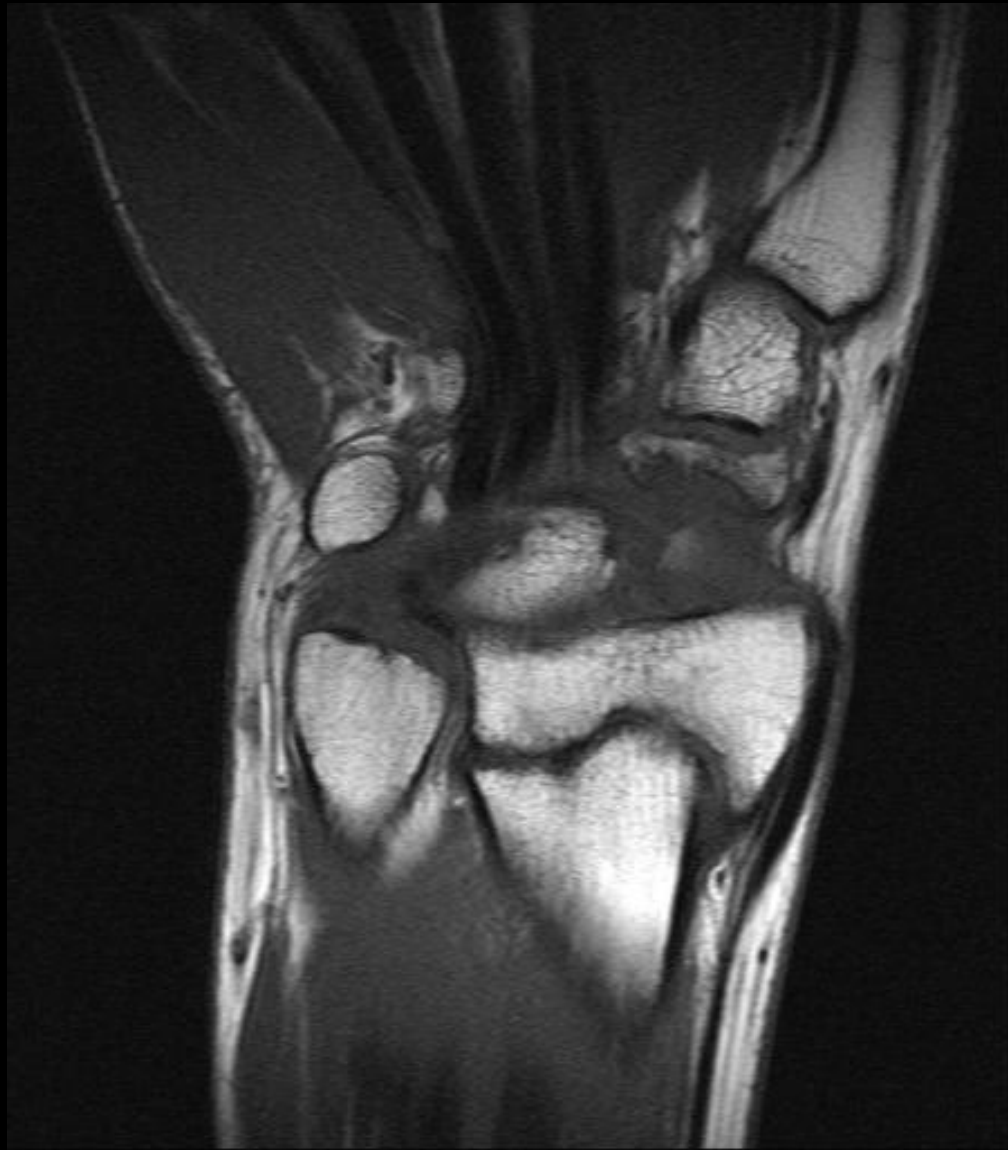

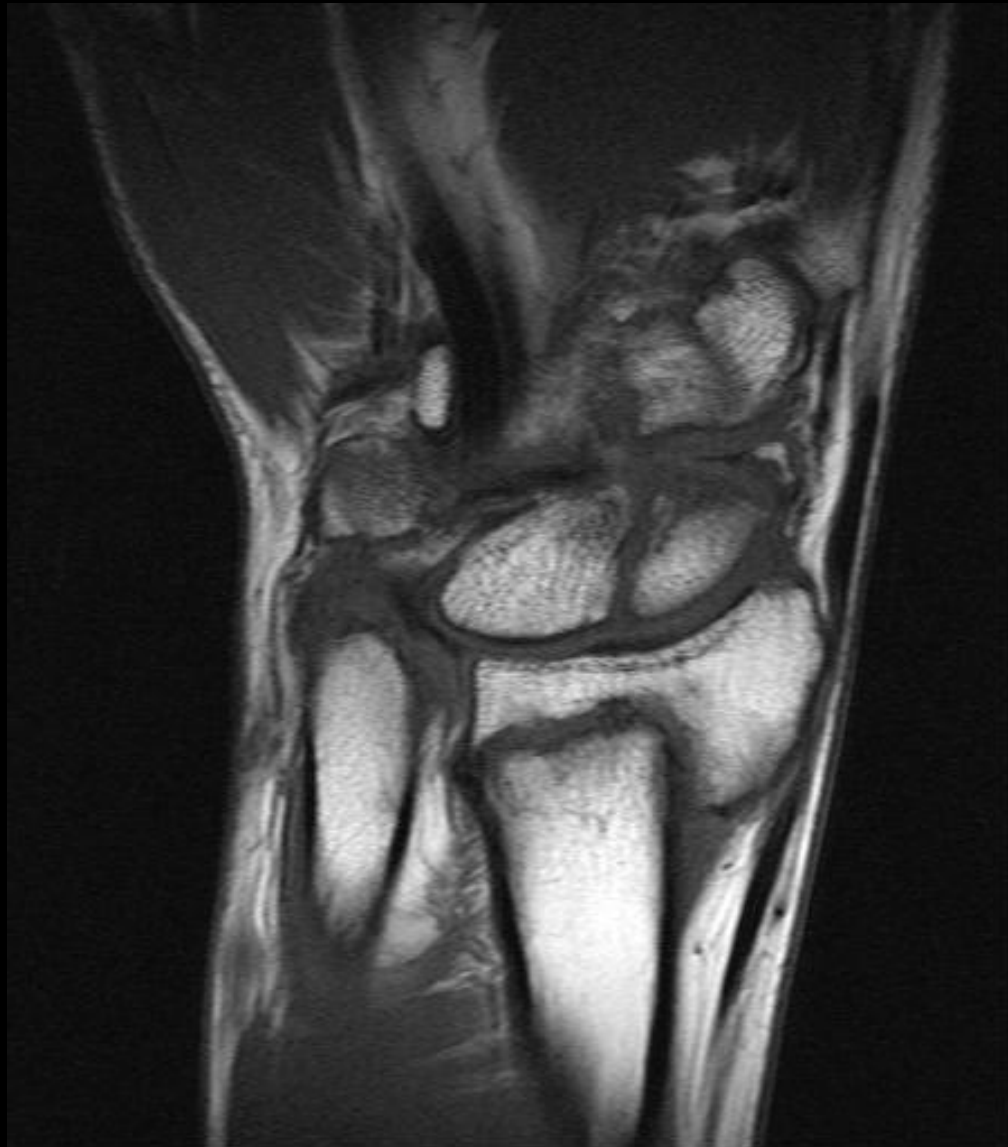Sag T1

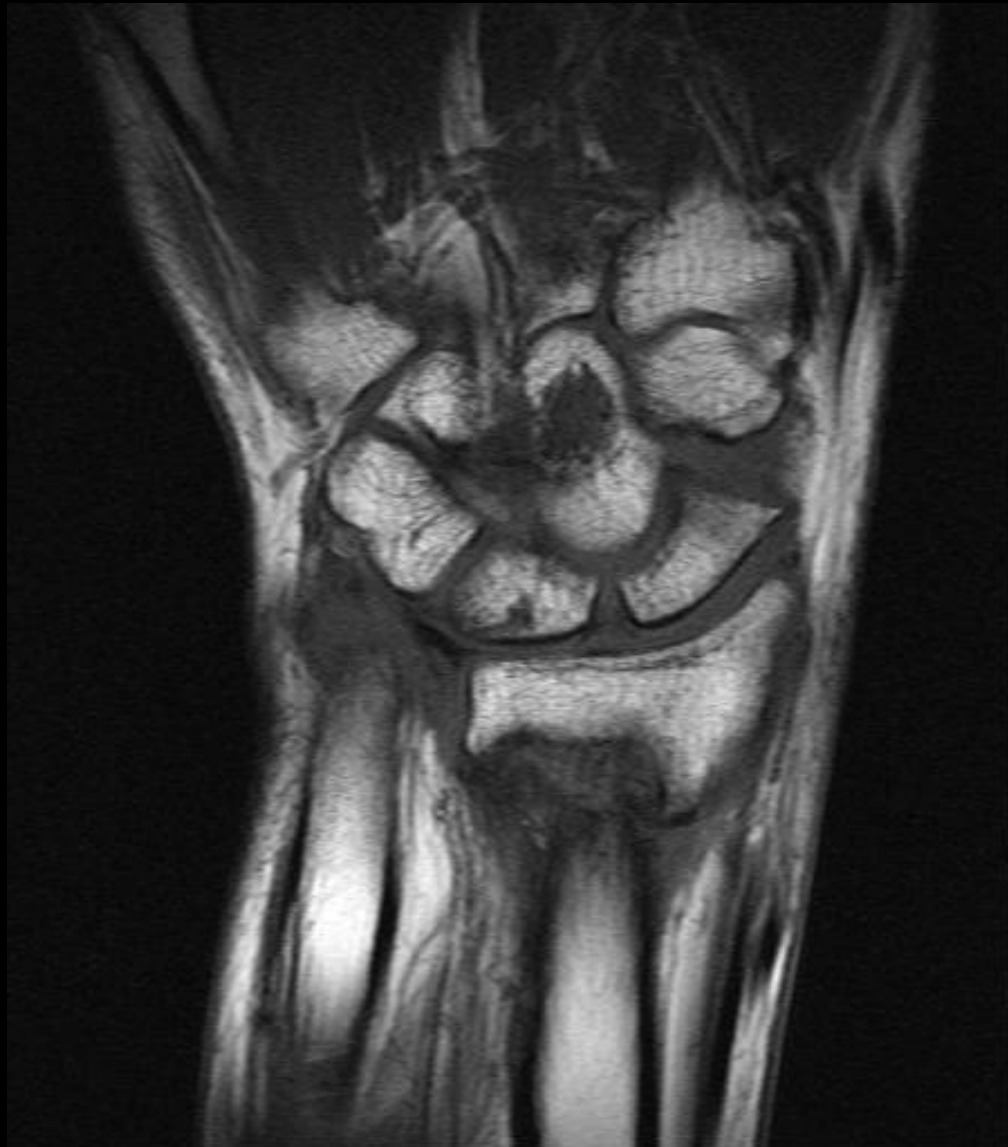

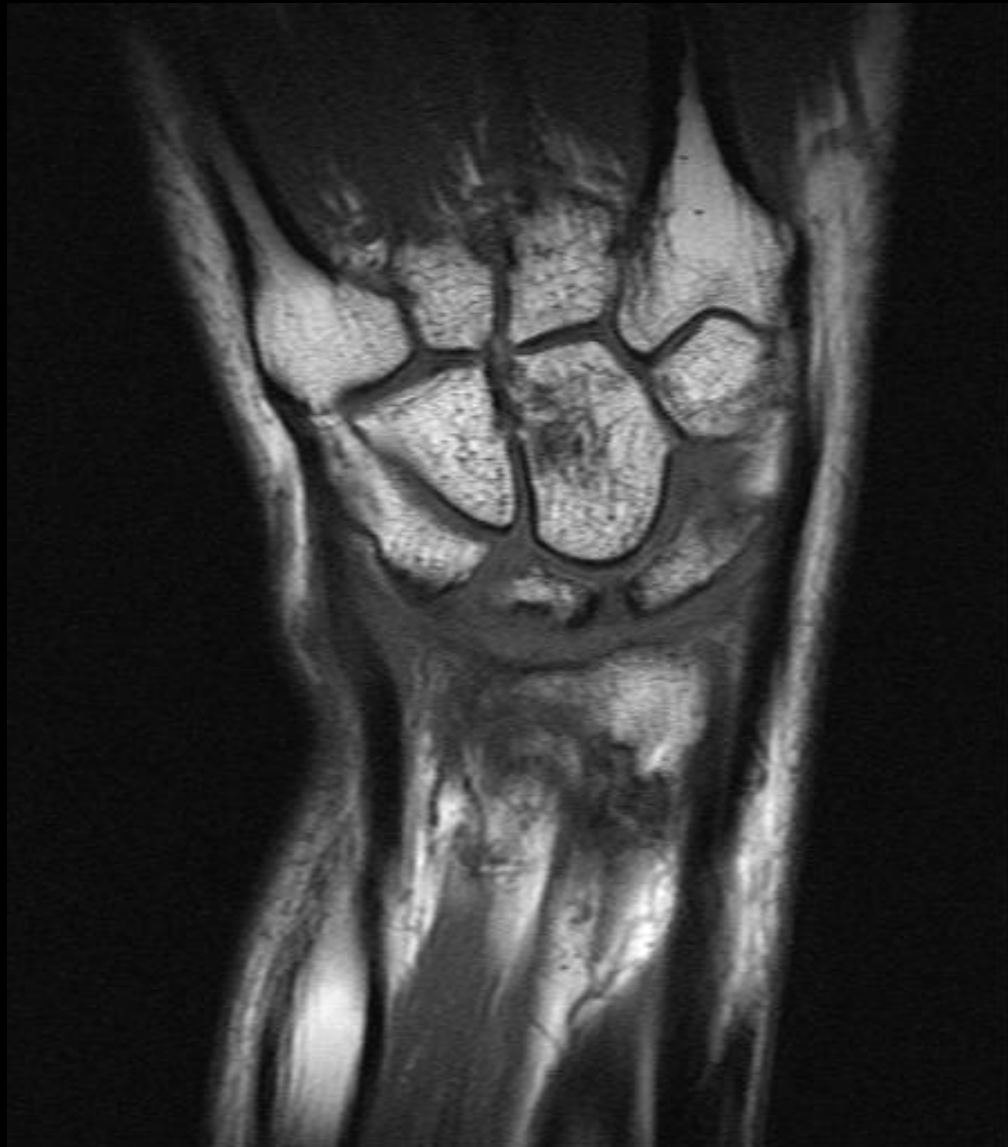Sag PDFS

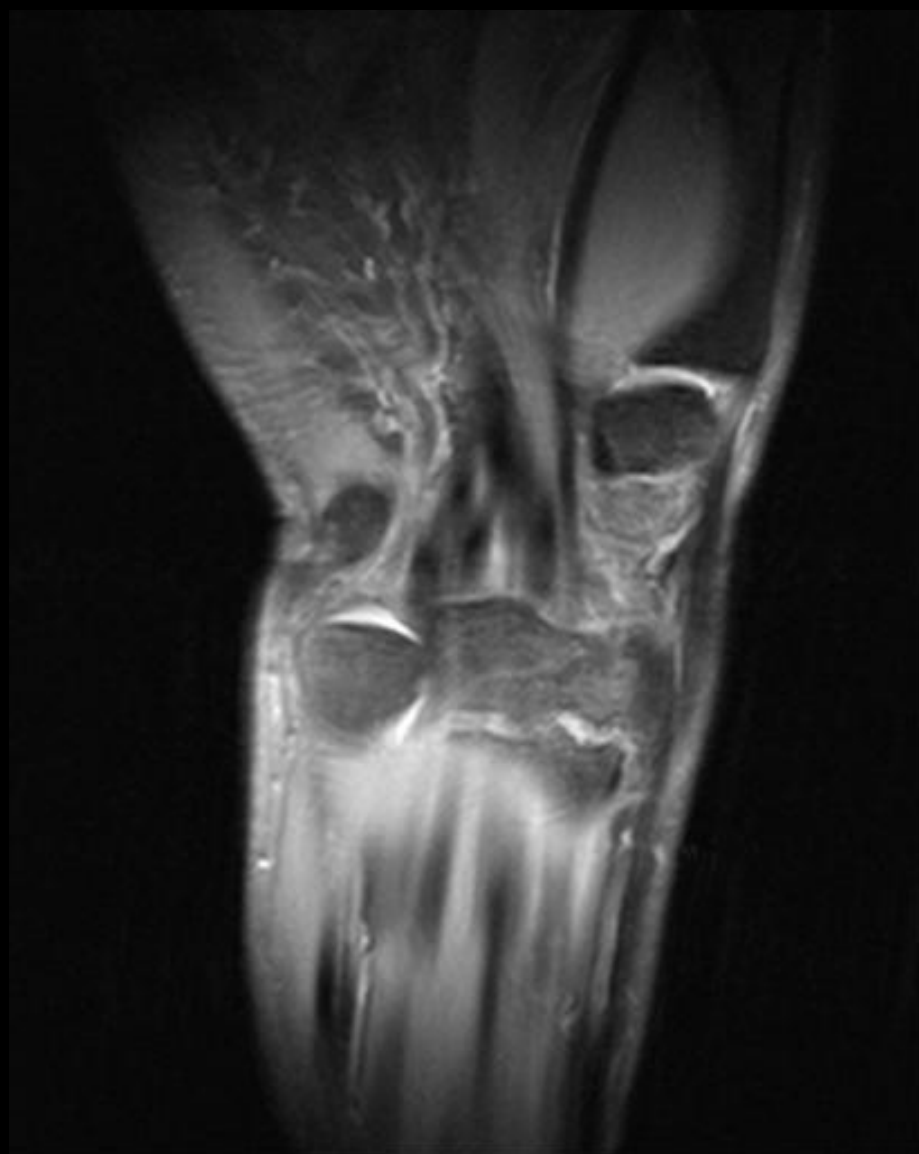



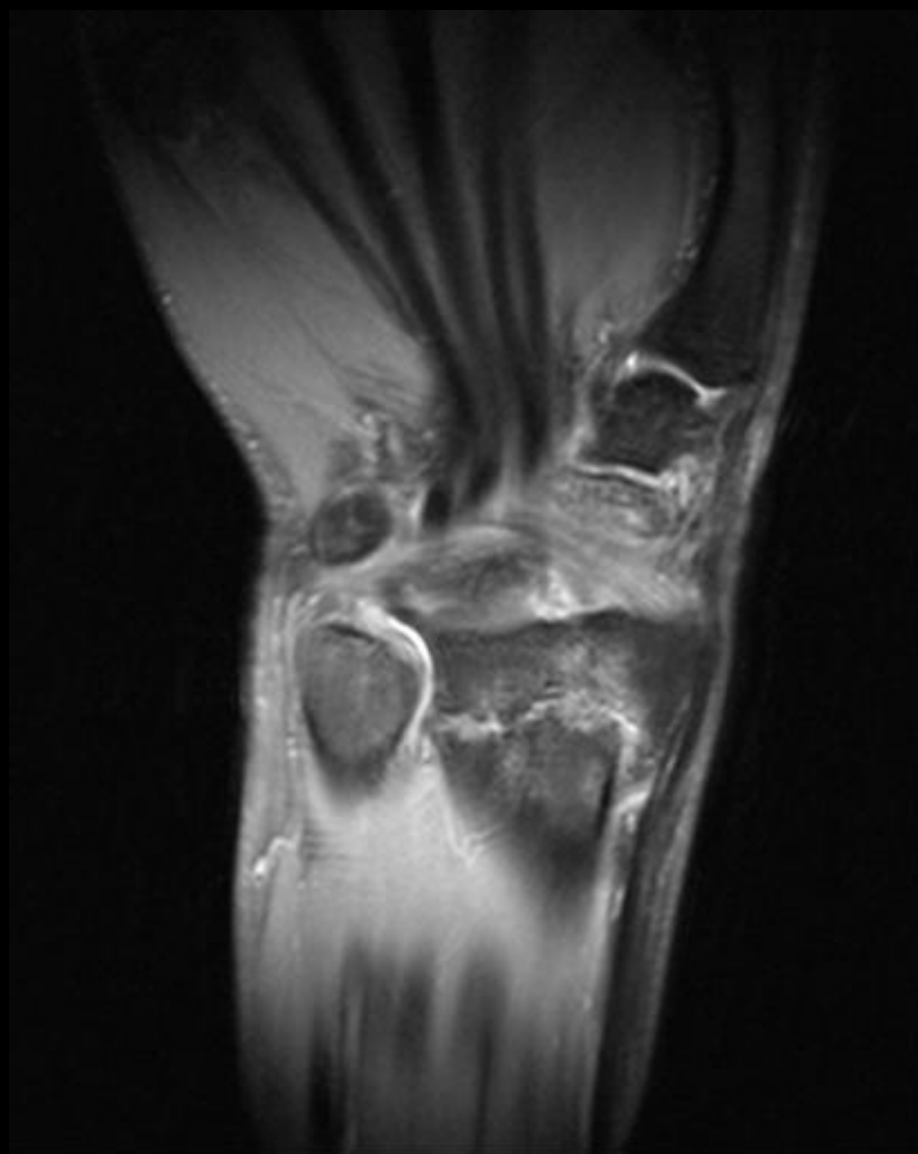


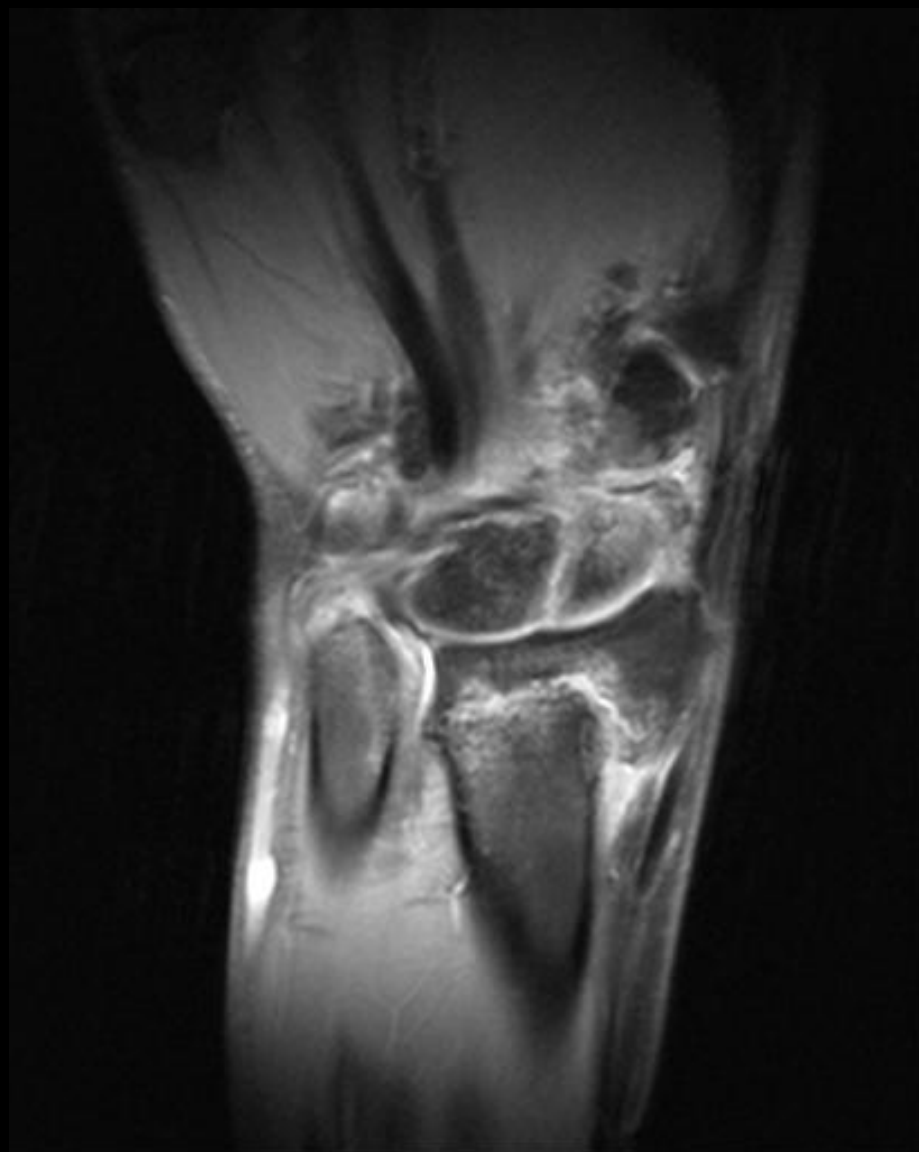


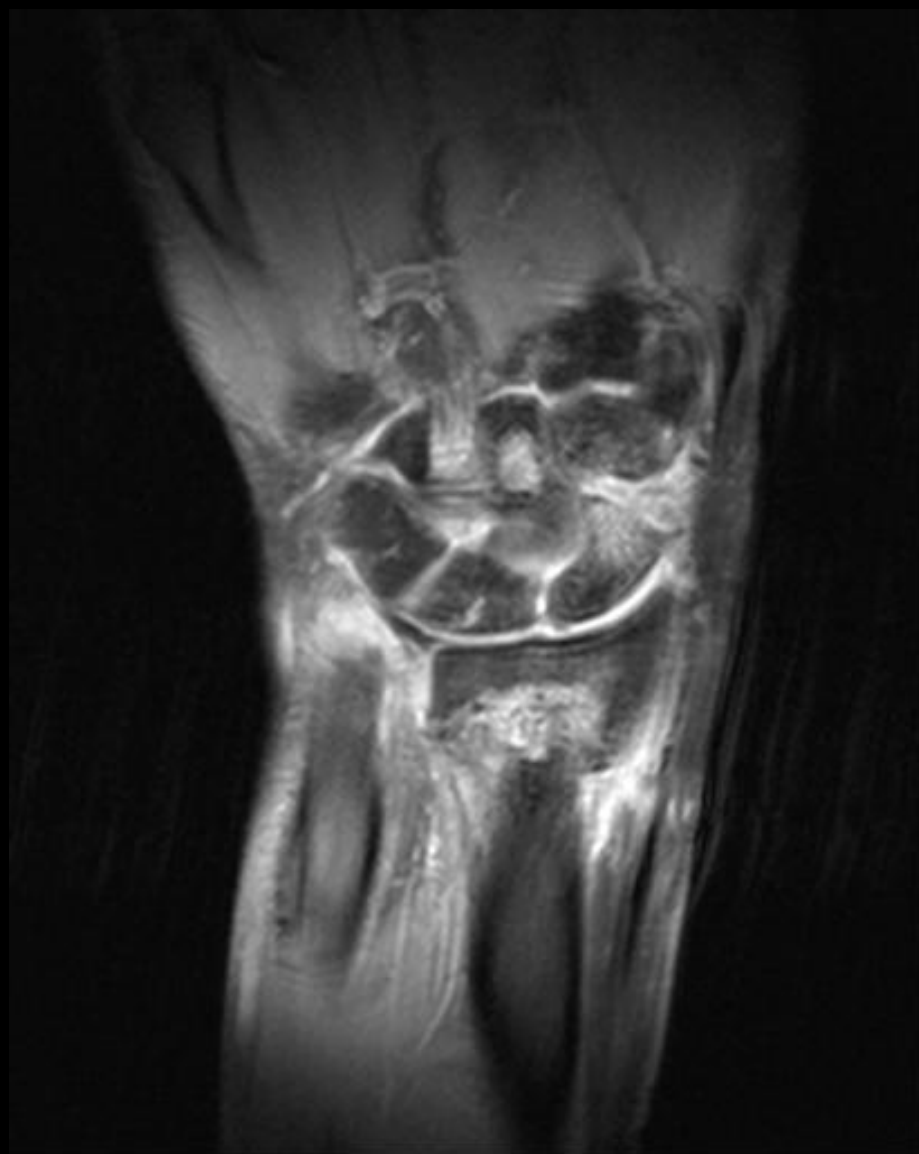


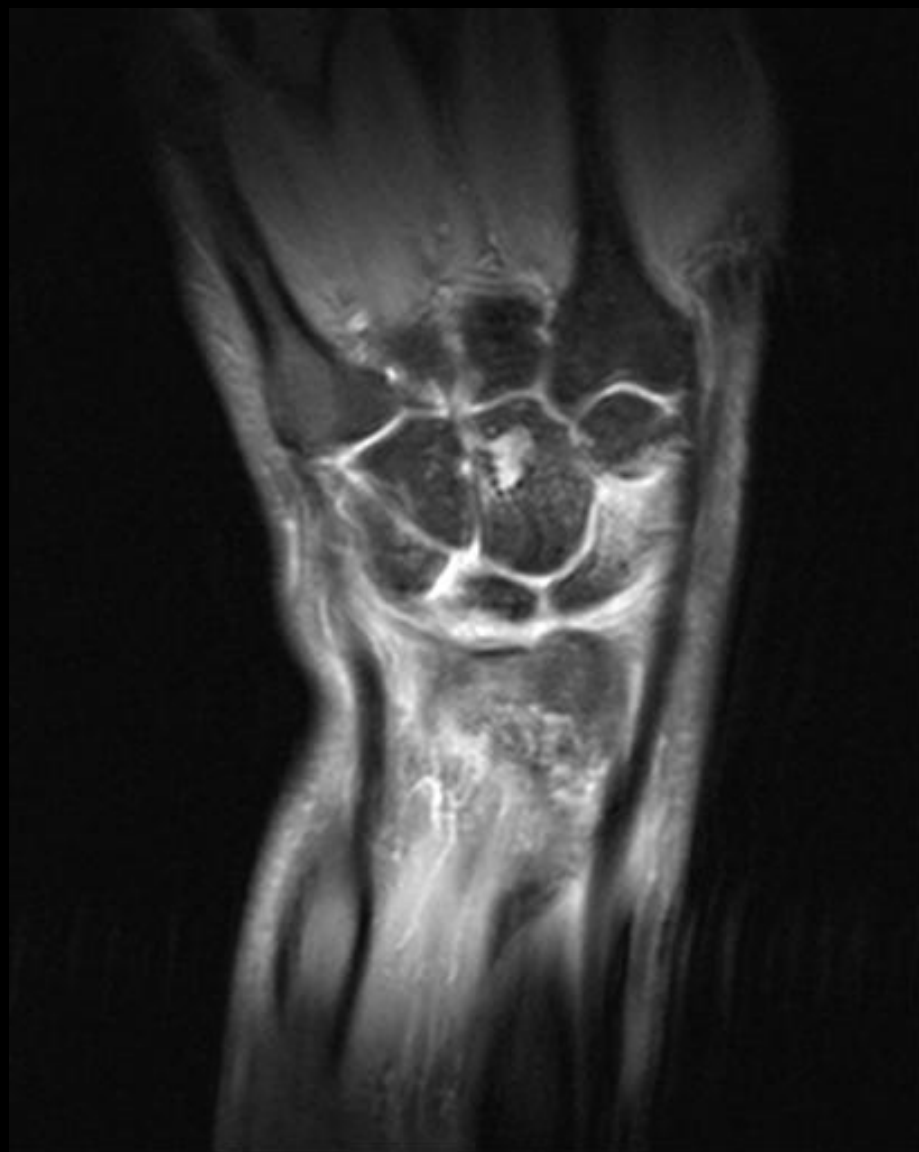











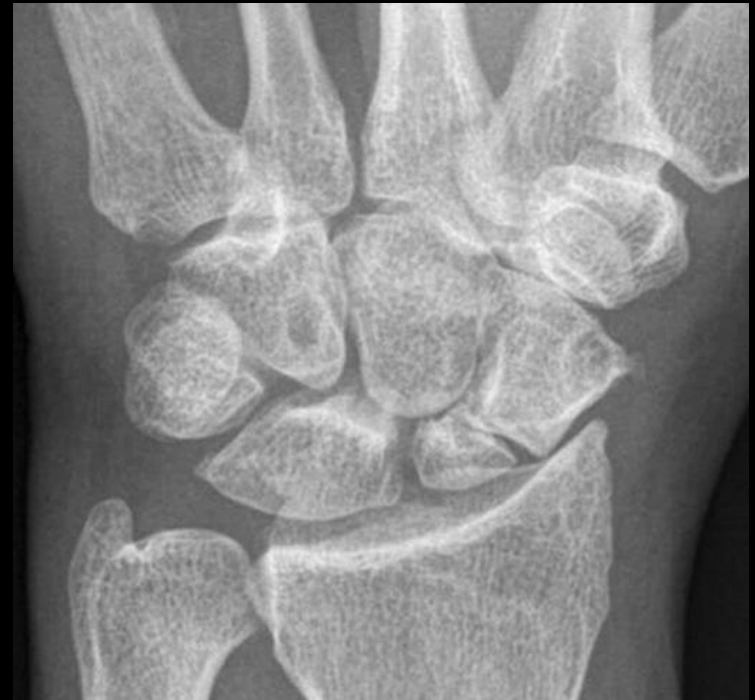
# SCAPHOID FRACTURE: RISK FACTORS FOR INSTABILITY

- vertical fracture line orientation
- fragment displacement  $>1\text{mm}$
- ligamentous instability
- [DISI characterized by scapholunate angle  $> 60$  degrees (normal = 30-60 degrees), or radiolunate or capitolunate angle  $> 15$  degrees (normal = 0 +/- 15 degrees)],
- humpback deformity

# SCAPHOID NON-UNION

- Often due to undiagnosed or undertreated nondisplaced scaphoid fractures.
- Even as late as 6 mo, the fx may heal
- Findings:
  - Sclerosis at fx site
  - Cystic cavitation
  - Displacement more than 1 mm
  - Local tenderness
  - Persistent lucent line >2 mm.
- All nonunions are considered unstable
- Late complications of osteonecrosis of the scaphoid or inadequately treated scaphoid nonunion include a peculiar pattern of osteoarthritis of the wrist....**scaphoid nonunion advanced collapse.**



# SNAC wrist

- Scaphoid Non-Union Advanced Collapse
  - Un-united scaphoid fracture
  - Osteonecrosis of the proximal pole
  - Secondary osteoarthritis between distal scaphoid fragment and radial styloid
  - (+/- DISI)
    - Most patients who have SNAC wrist with nonunion of the middle or distal third also have DISI.

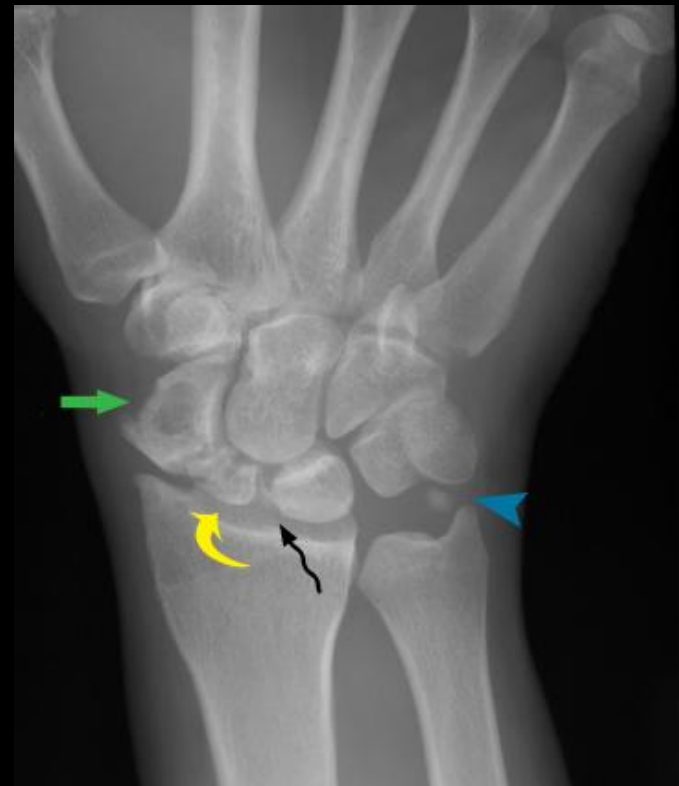# SNAC AND SNAC +

- Radiographic features of SNAC wrist include:
  - non-united scaphoid fracture
  - scaphoid collapse
  - marked osteoarthritis of the radioscaphoid joint
  - the radiolunate joint is usually spared from degenerative involvement
- SNAC+ is longstanding scaphoid non-union with osteonecrosis of the proximal pole and development of secondary radiocarpal osteoarthritis.
- The radiocarpal joint narrowing is between the radial styloid and distal pole of the fractured scaphoid



# SNAC : PLAIN FILM FINDINGS

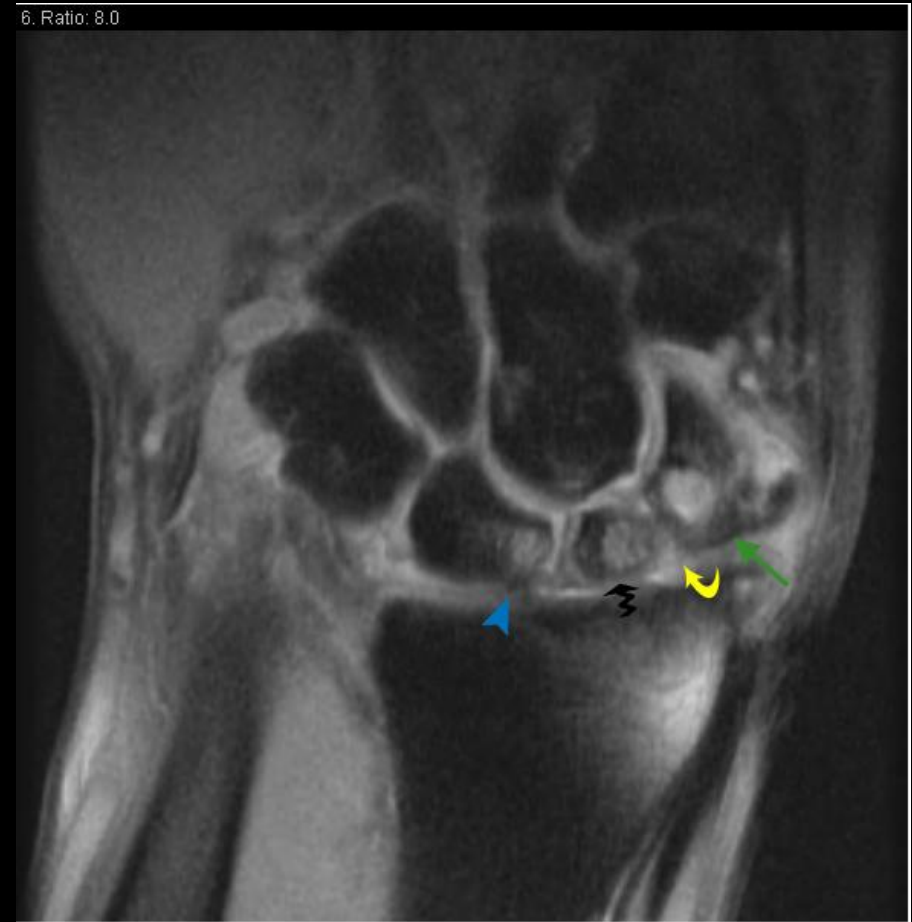
- Non-united scaphoid fracture
- Cystic changes in the distal pole scaphoid (green arrow)
- Small sclerotic proximal pole (curved yellow arrow)
- Scapholunate injury with **small bone fragment noted** (black wavy arrow)
- Remote non-united ulnar styloid fracture (blue arrowhead)



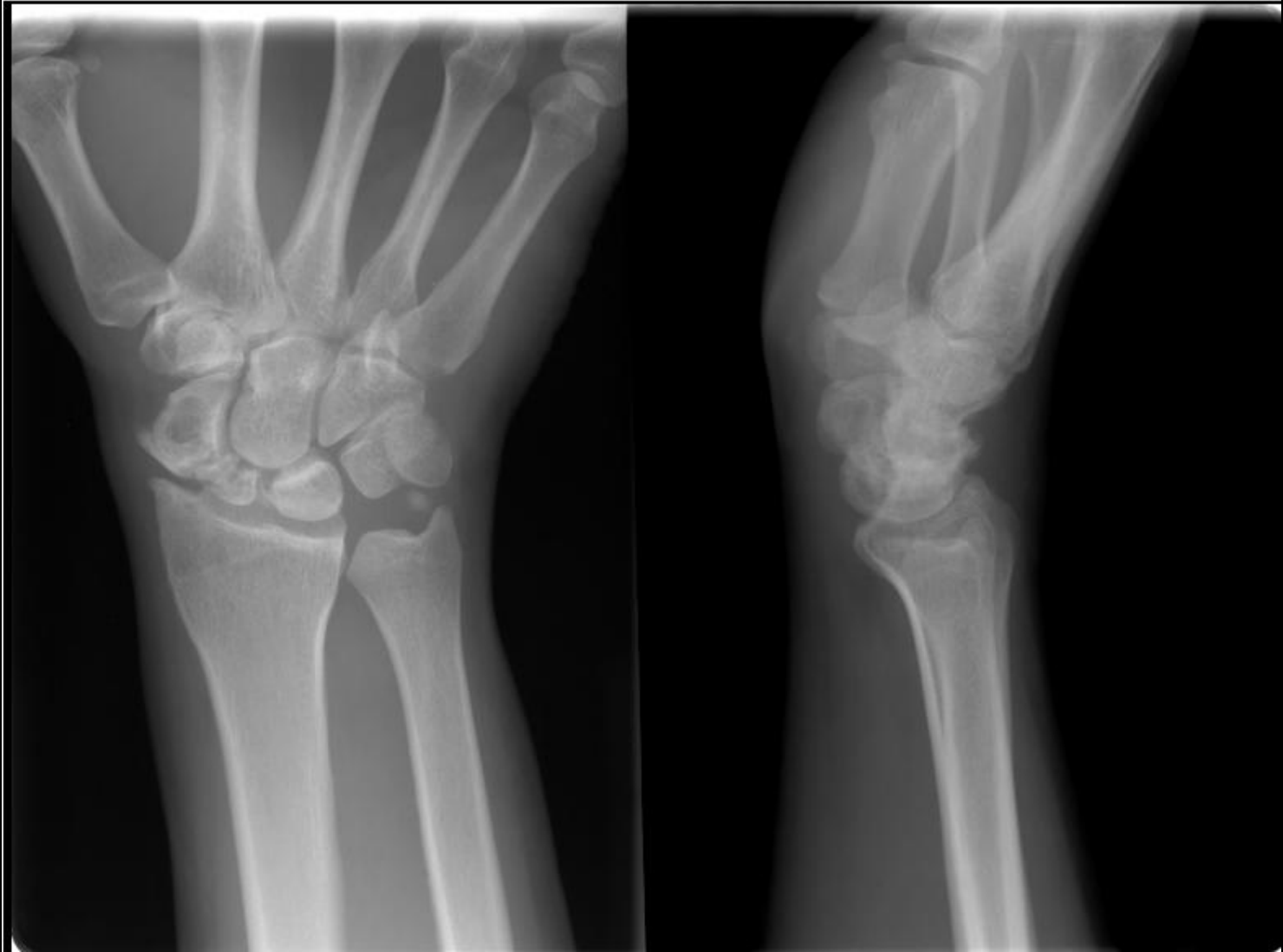48 y.o. male with a remote fall on an outstretched hand. Chronic wrist pain which has been progressive over the past 10 years.

# SNAC: MR FINDINGS

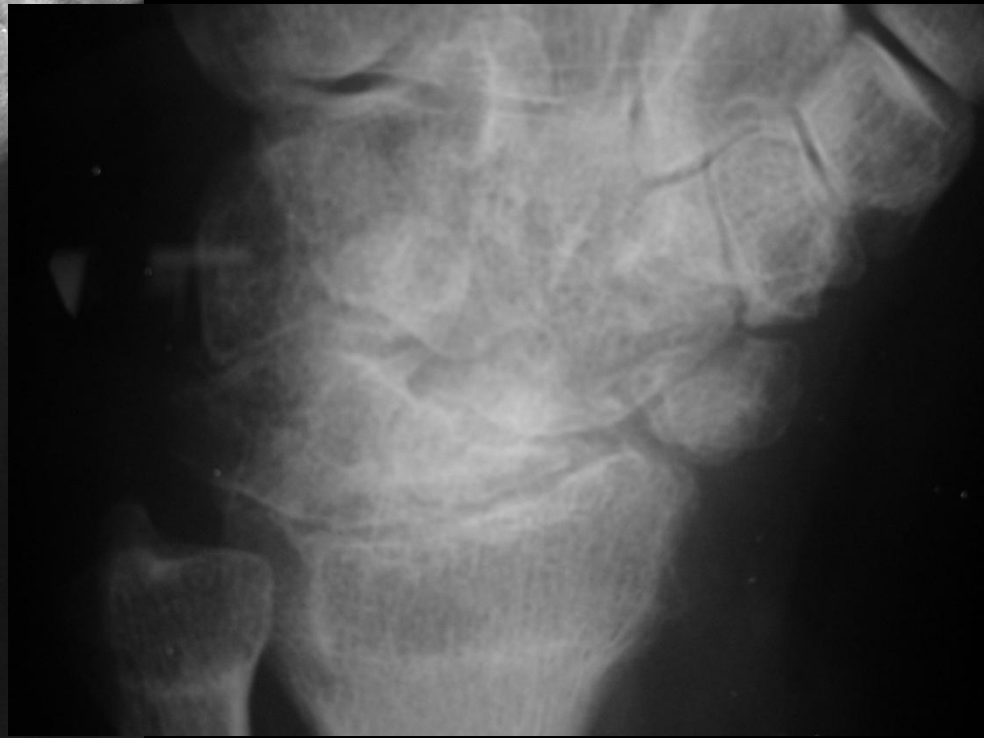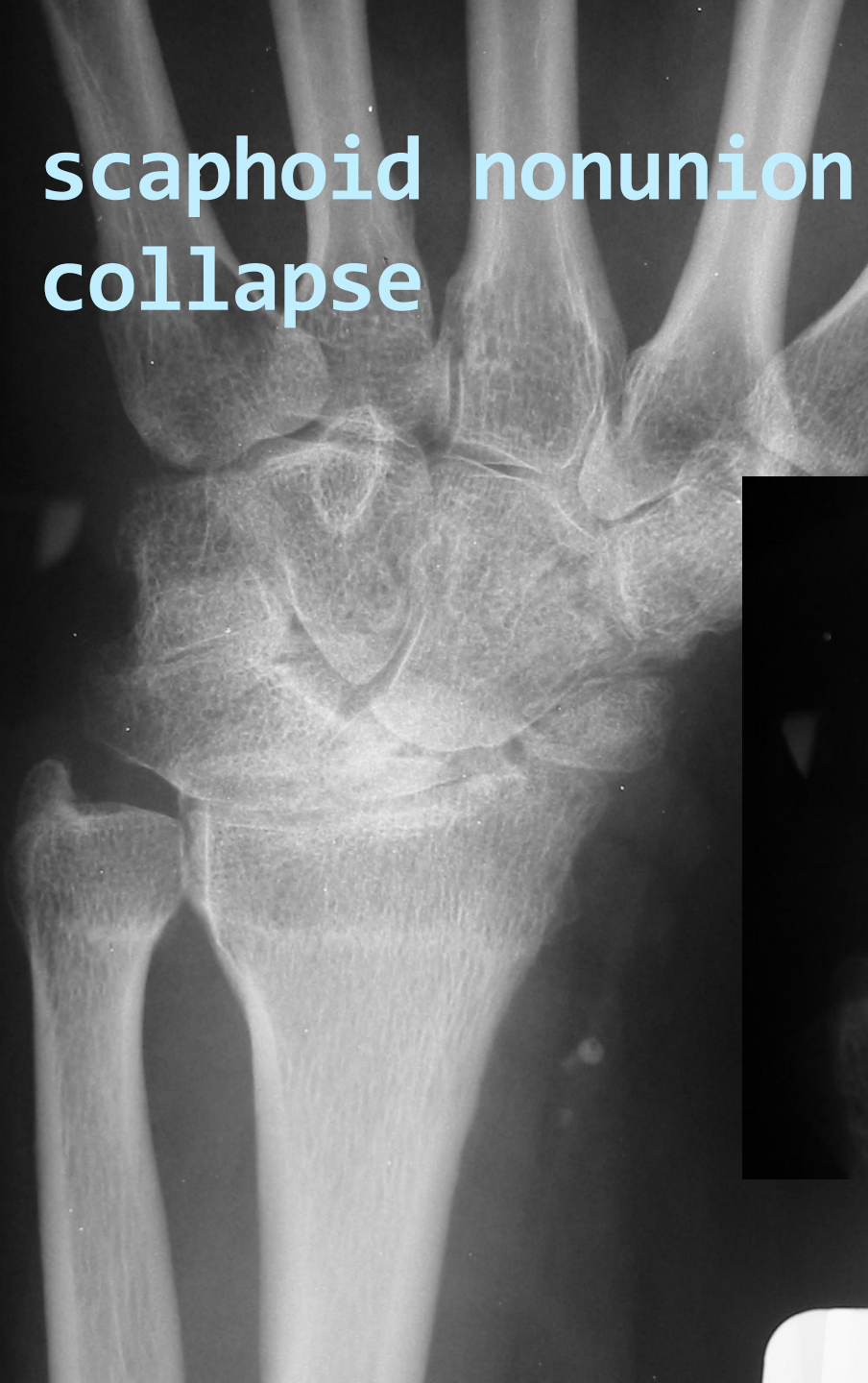- Non-united scaphoid fracture with high signal between the fragments suggestive of pseudoarthrosis (yellow curved arrow)
- Cyst in distal and proximal pole of scaphoid (green arrow)
- Small sclerotic proximal pole (black arrow) of scaphoid with chondral loss at radioscapoid articulation
- Cyst in lunate (blue arrowhead) with adjacent thickening of scapholunate ligament with bone marrow edema at lunate attachment site



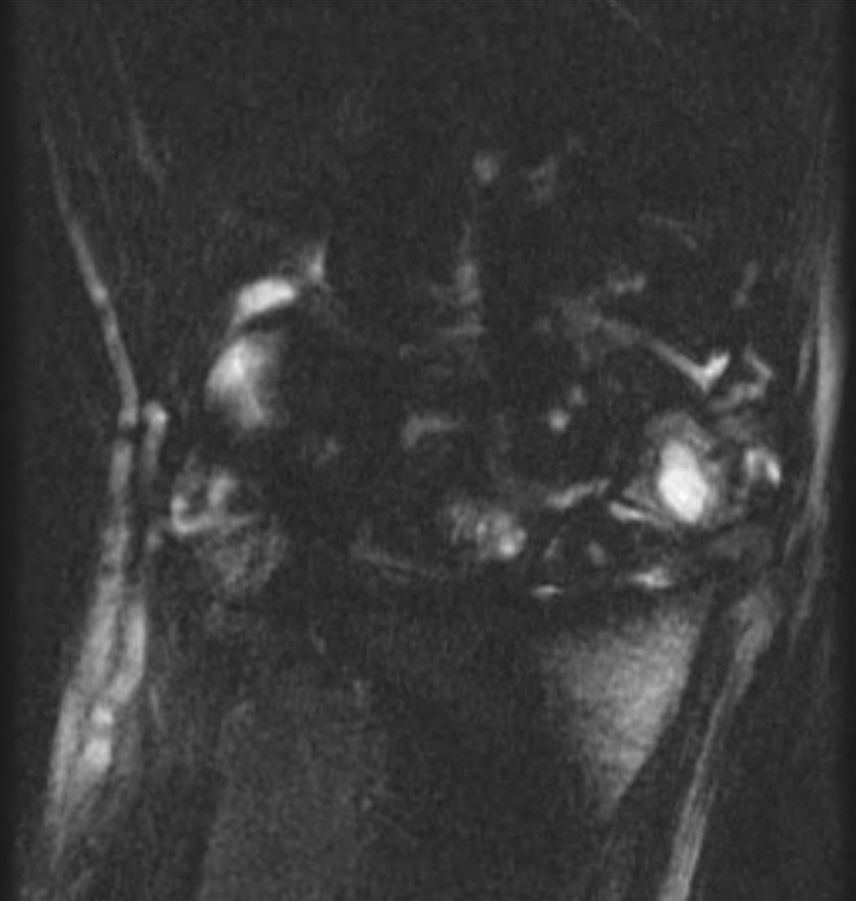1. Ratio: 30.0



**scaphoid nonunion  
collapse**      **advanced**

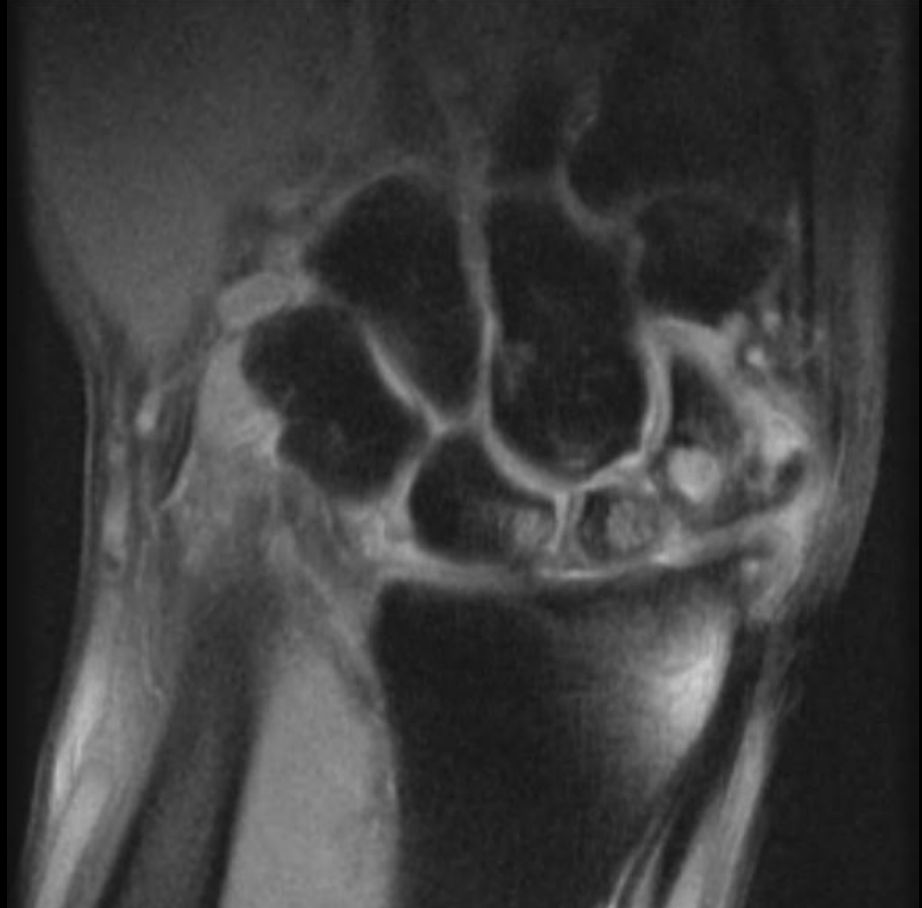

7. Ratio: 8.0



CORT<sub>2</sub>

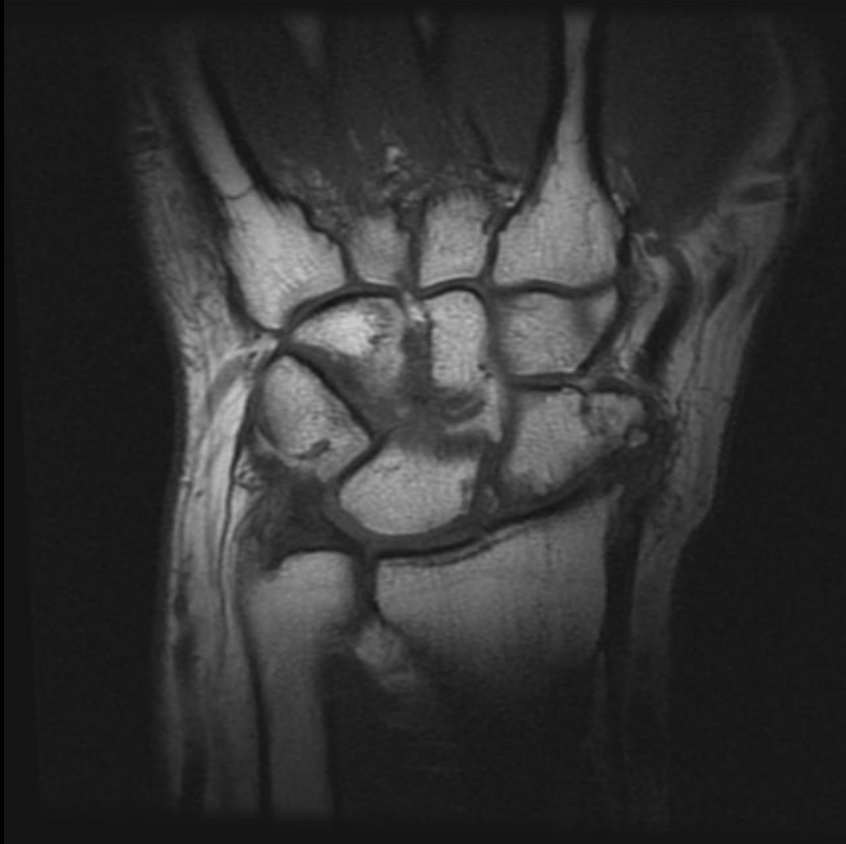6. Ratio: 8.0



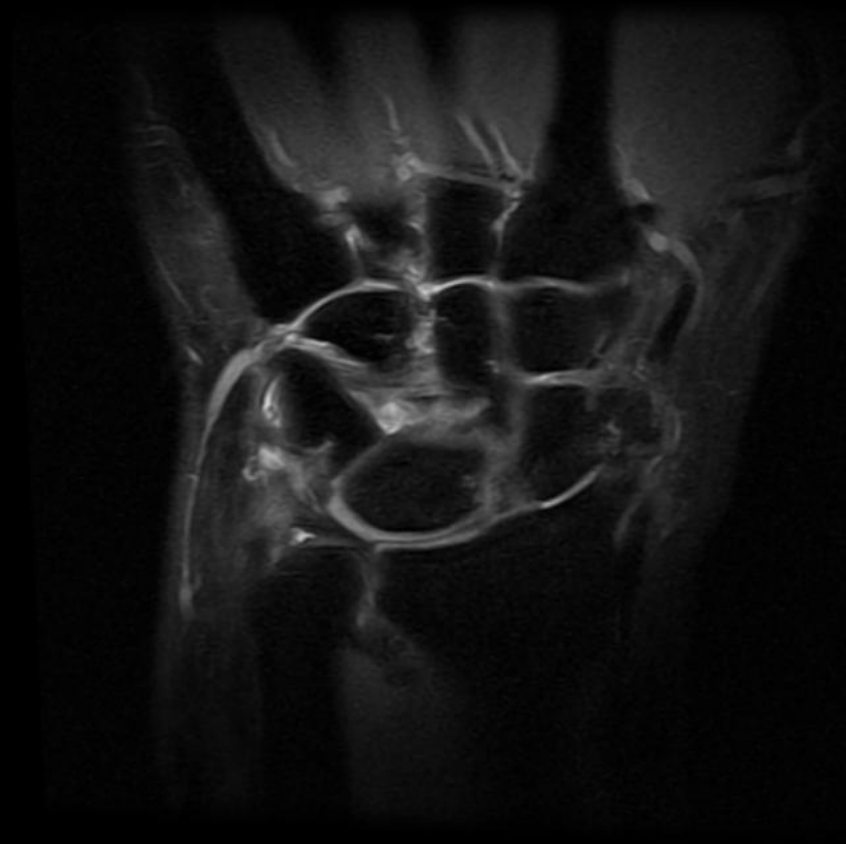COR PD

# scaphoid nonunion advanced collapse

7. Ratio: 8.0

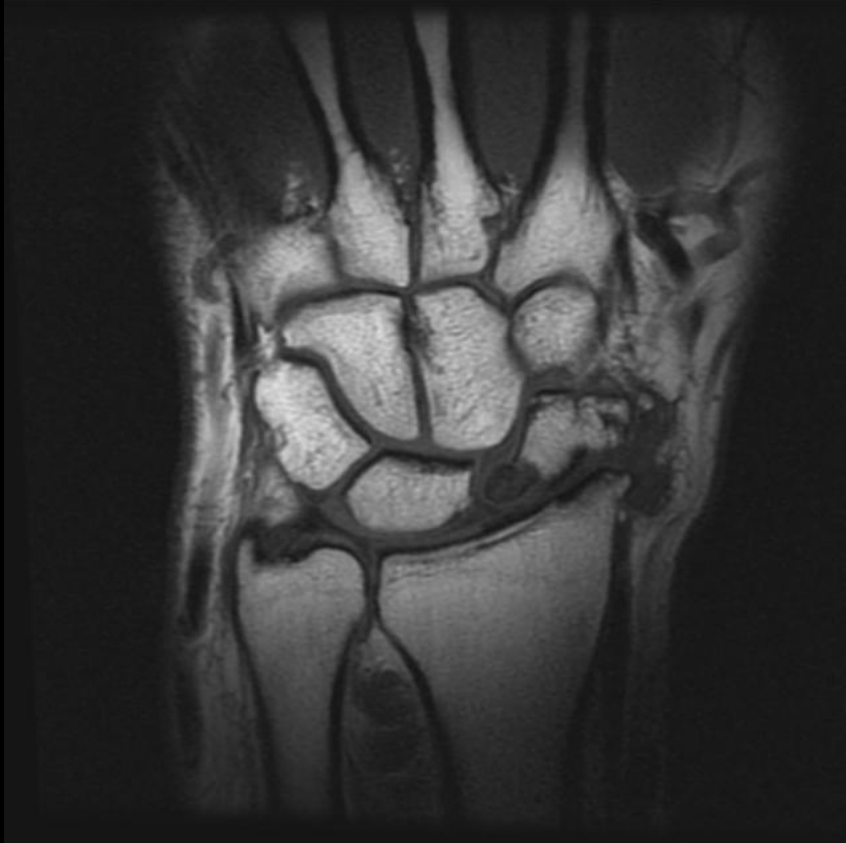

7. Ratio: 8.0

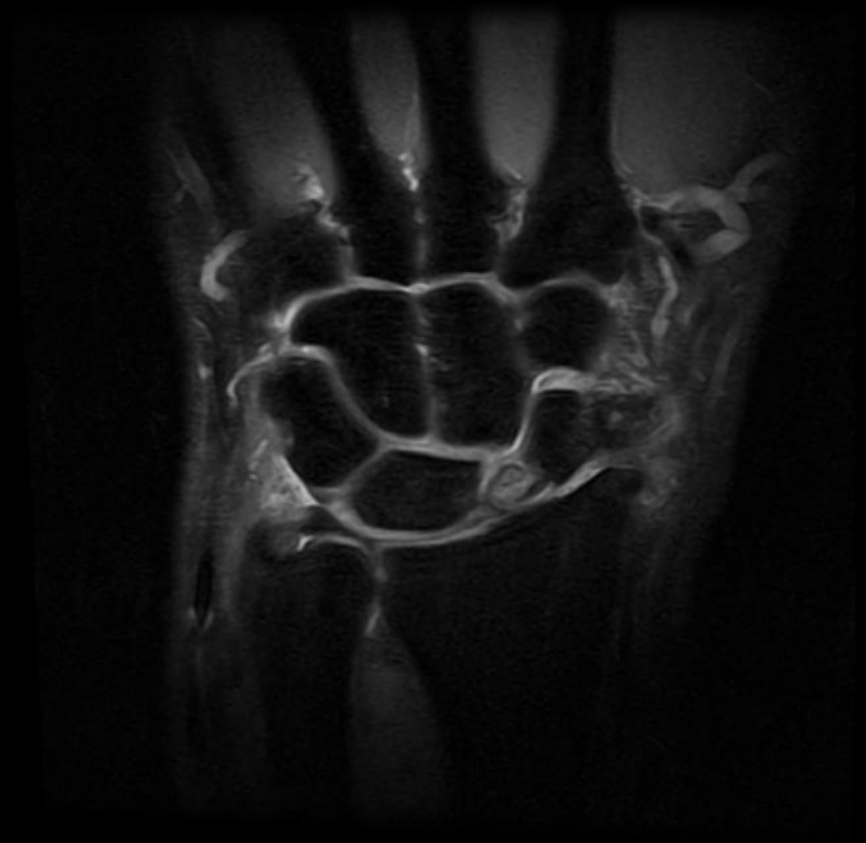


# scaphoid nonunion advanced collapse

8. Ratio: 8.0



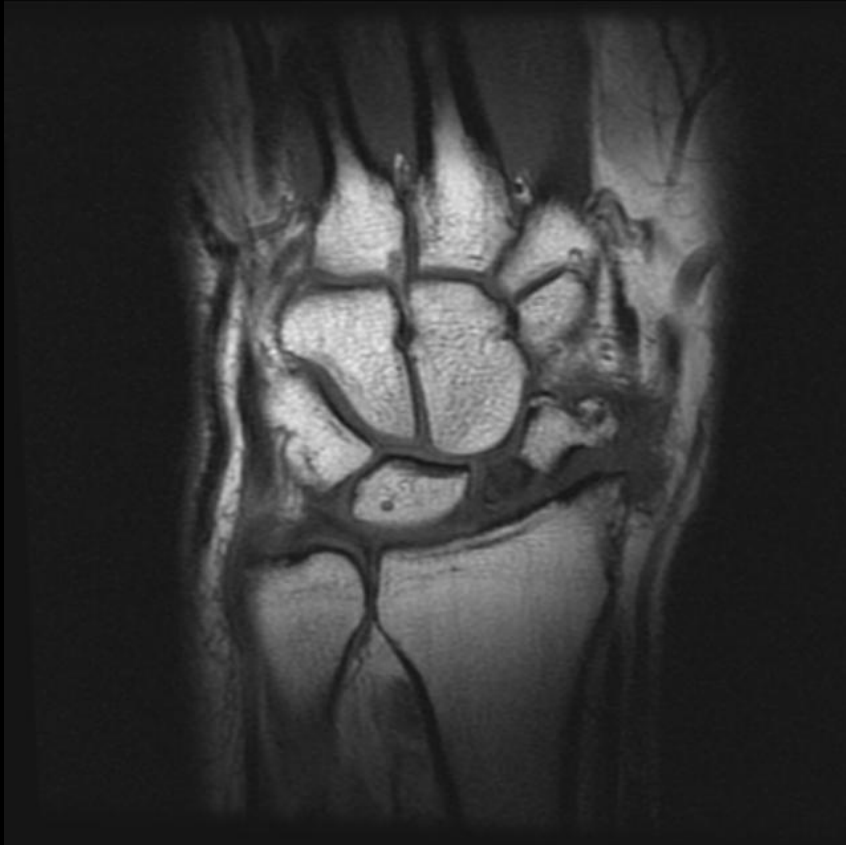
8. Ratio: 8.0



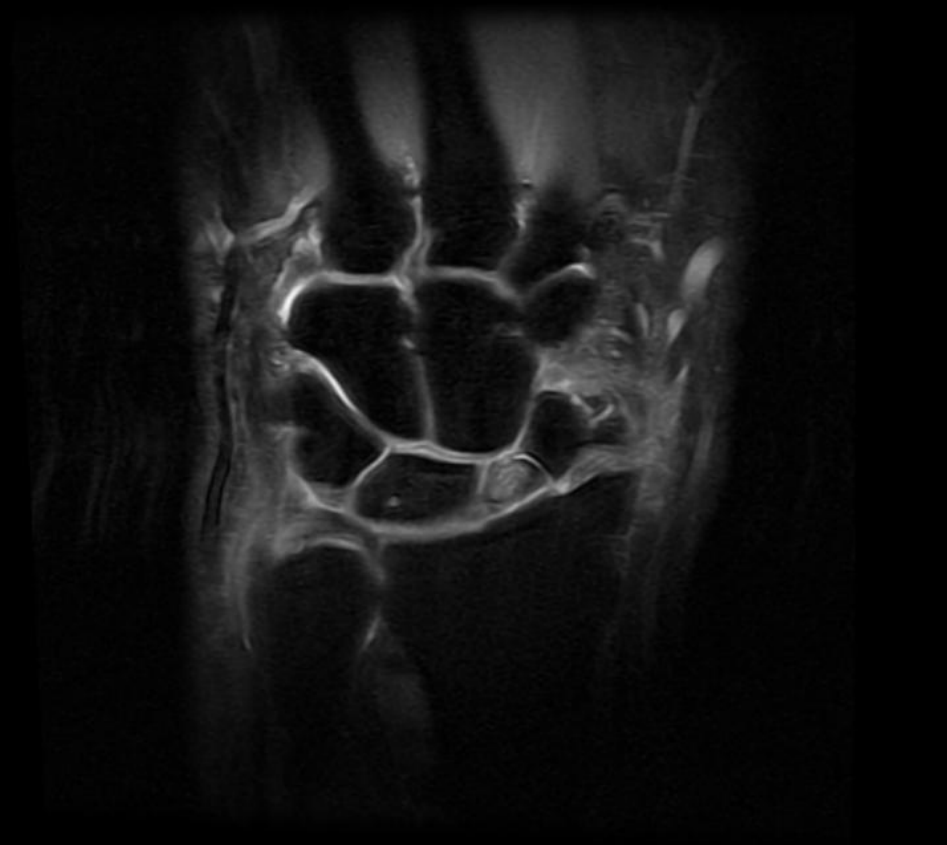


# scaphoid nonunion advanced collapse

9. Ratio: 8.0



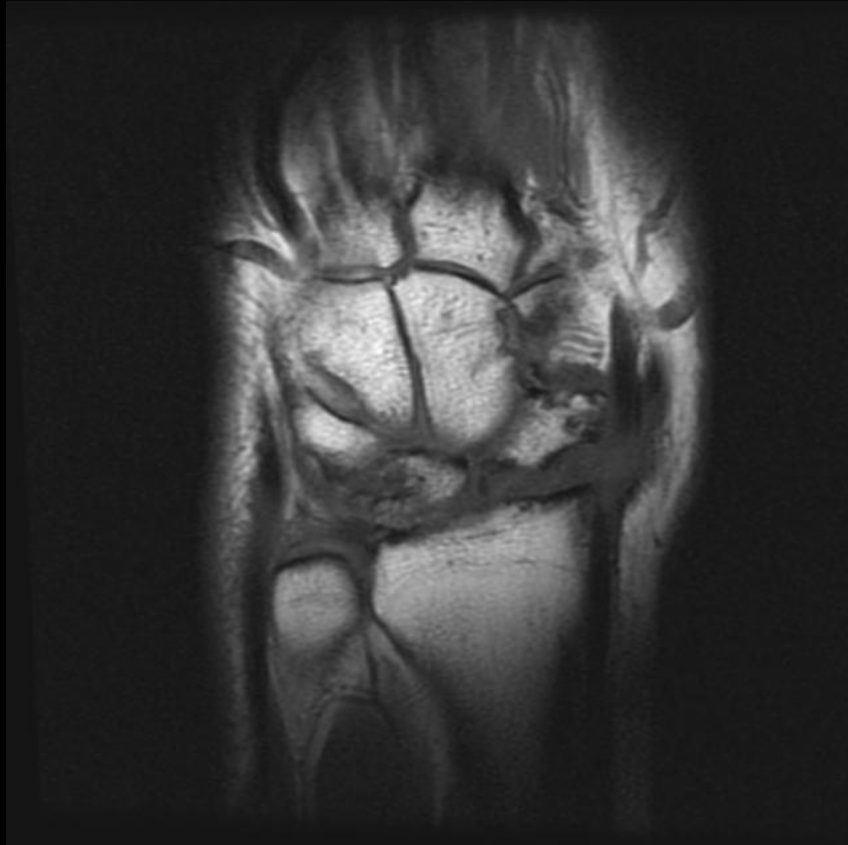9. Ratio: 8.0



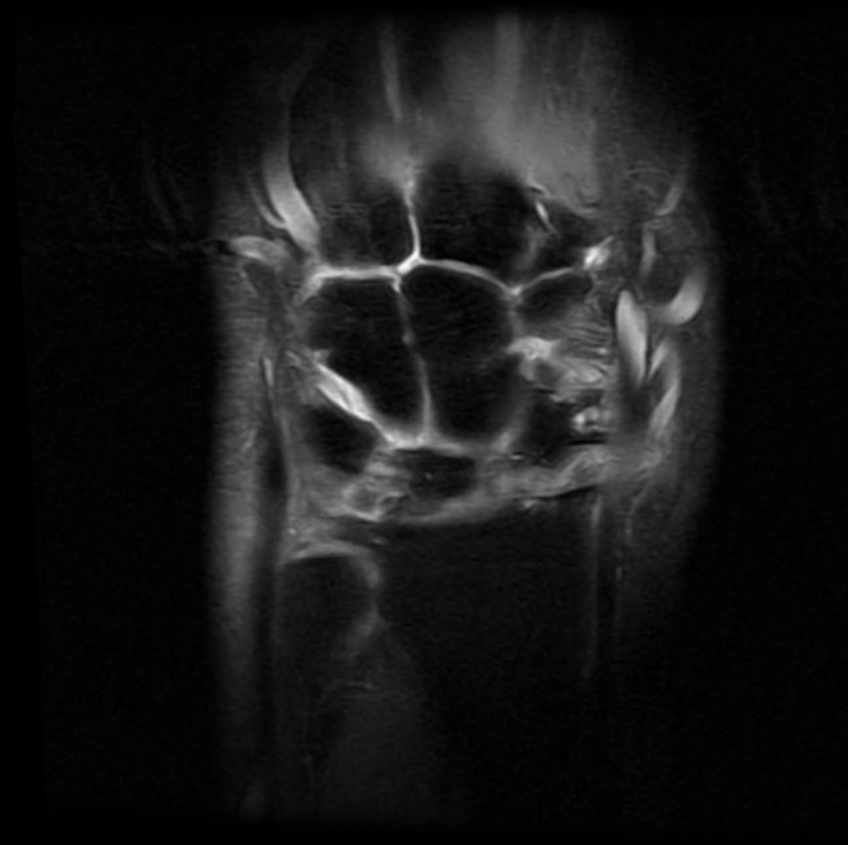


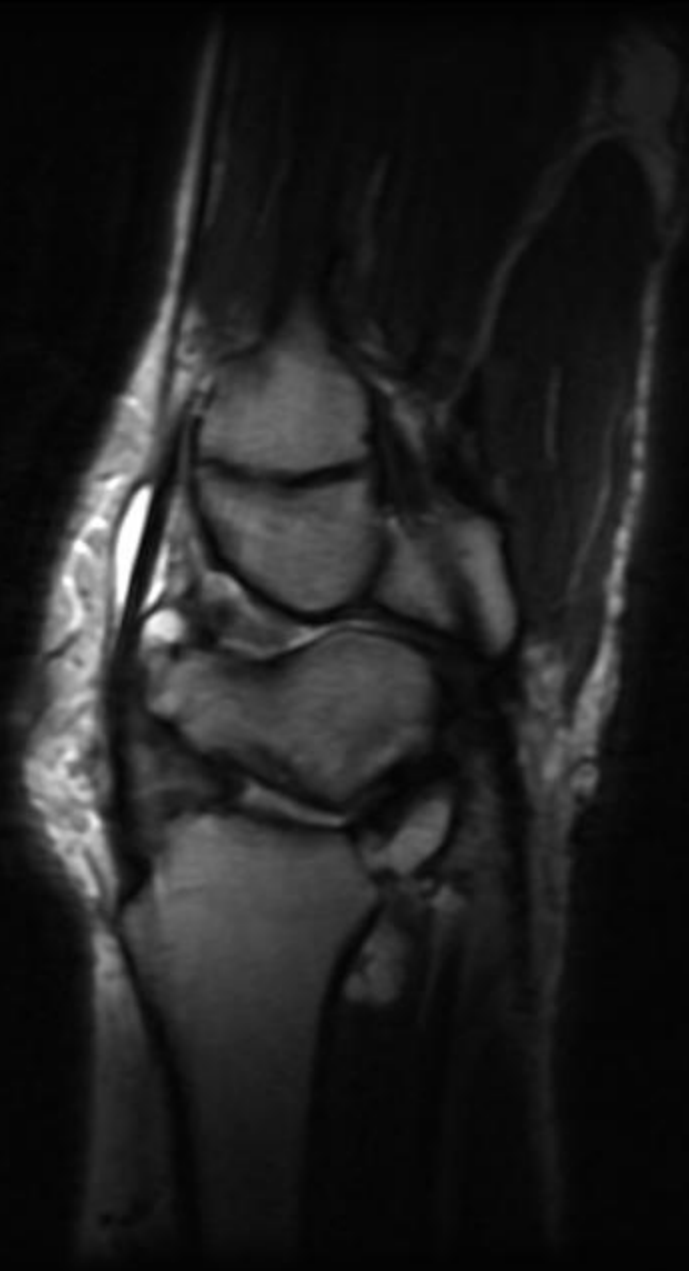
# scaphoid nonunion advanced collapse

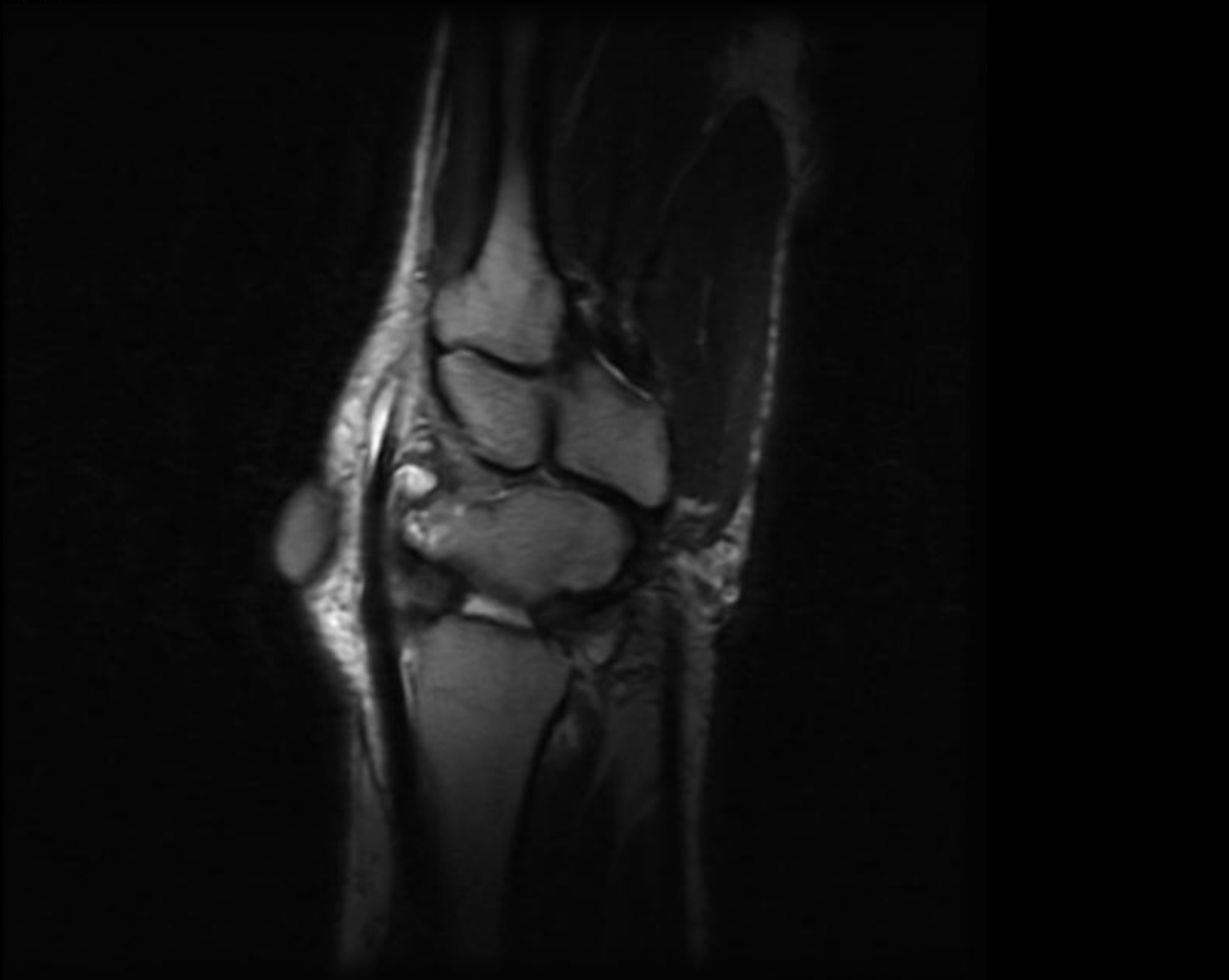
10. Ratio: 8.0



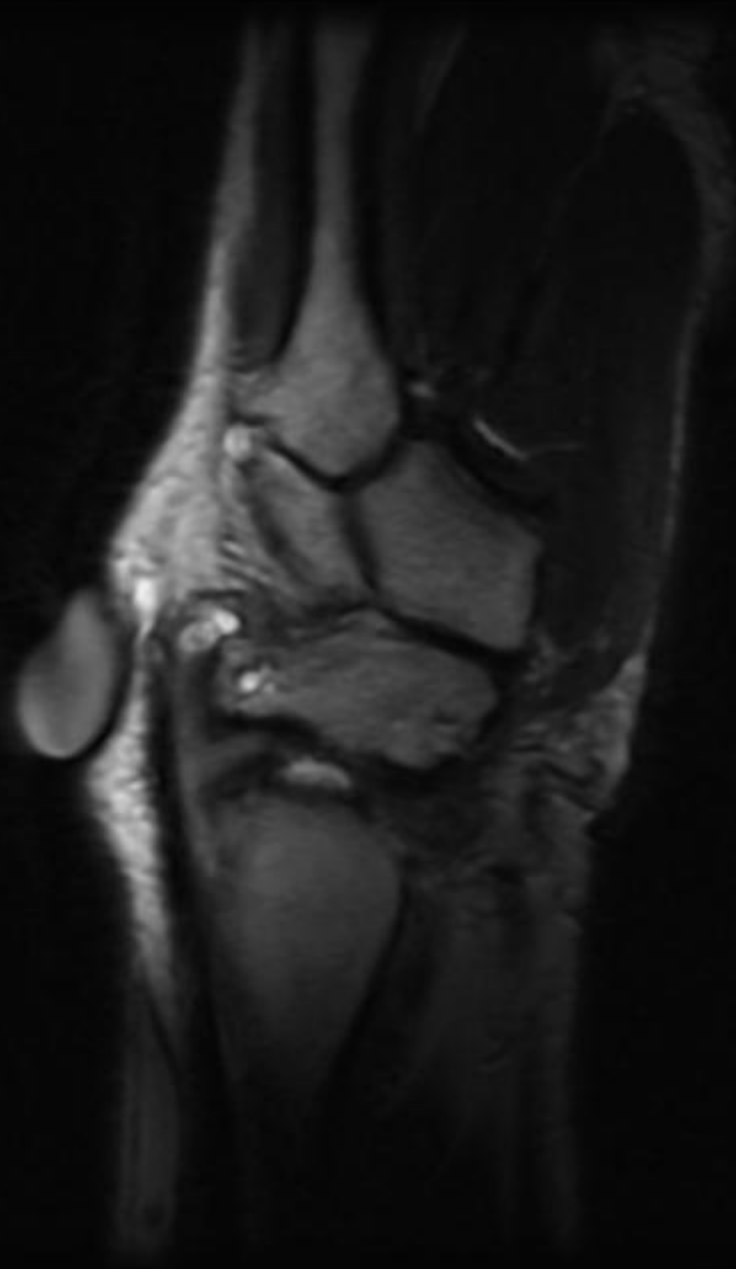
10. Ratio: 8.0







18. Ratio: 8.0

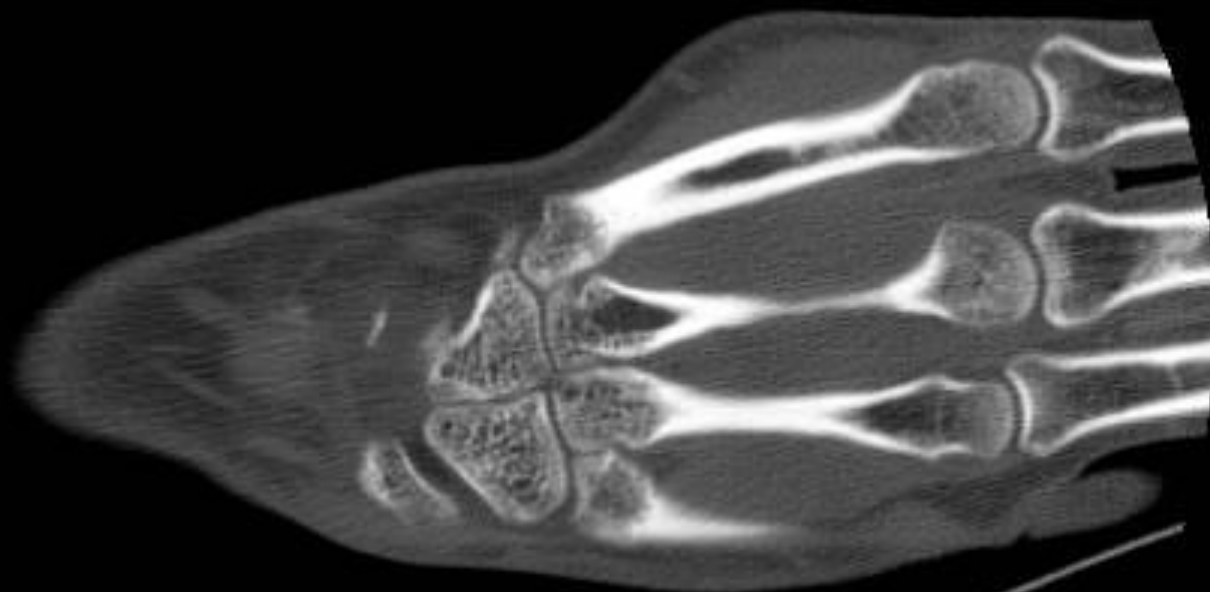


# TREATMENT

- Surgical treatment is usually required for scaphoid non-union.- debridement, reduction, bone graft
- If more severe pseudoarthrosis, AVN or osteoarthritis is present, the rate of union is progressively decreased.
- In severe or late cases, on nonunion, factors, such as the patient's age, occupation, symptoms and needs, are considered when determining whether treatment should involve conservative measures, scaphoid reconstruction or a salvage procedure.

10

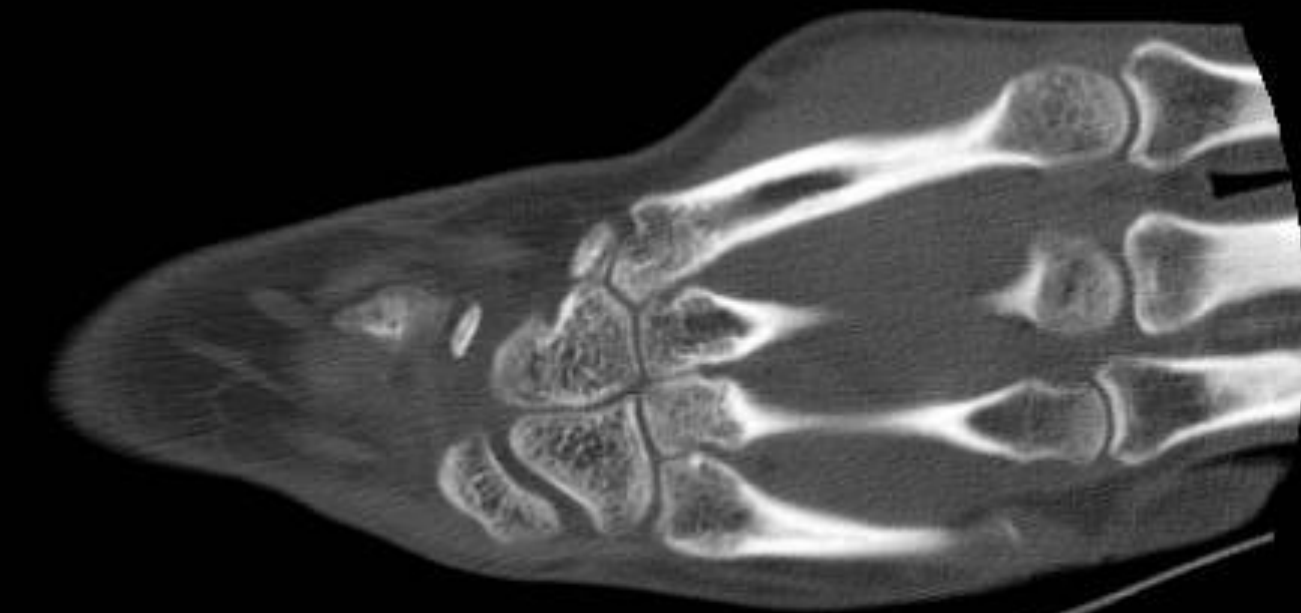SNAC



W 2000 : L 500

11

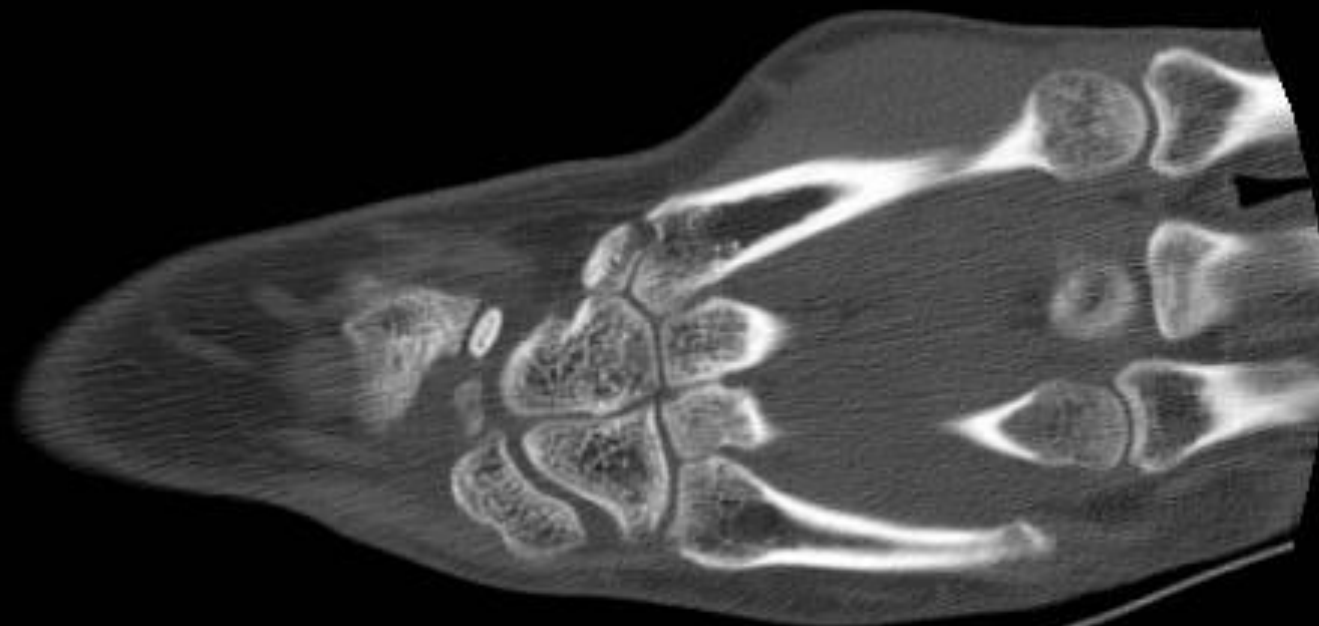# SNAC



W 2000 : L 500

12

SNAC

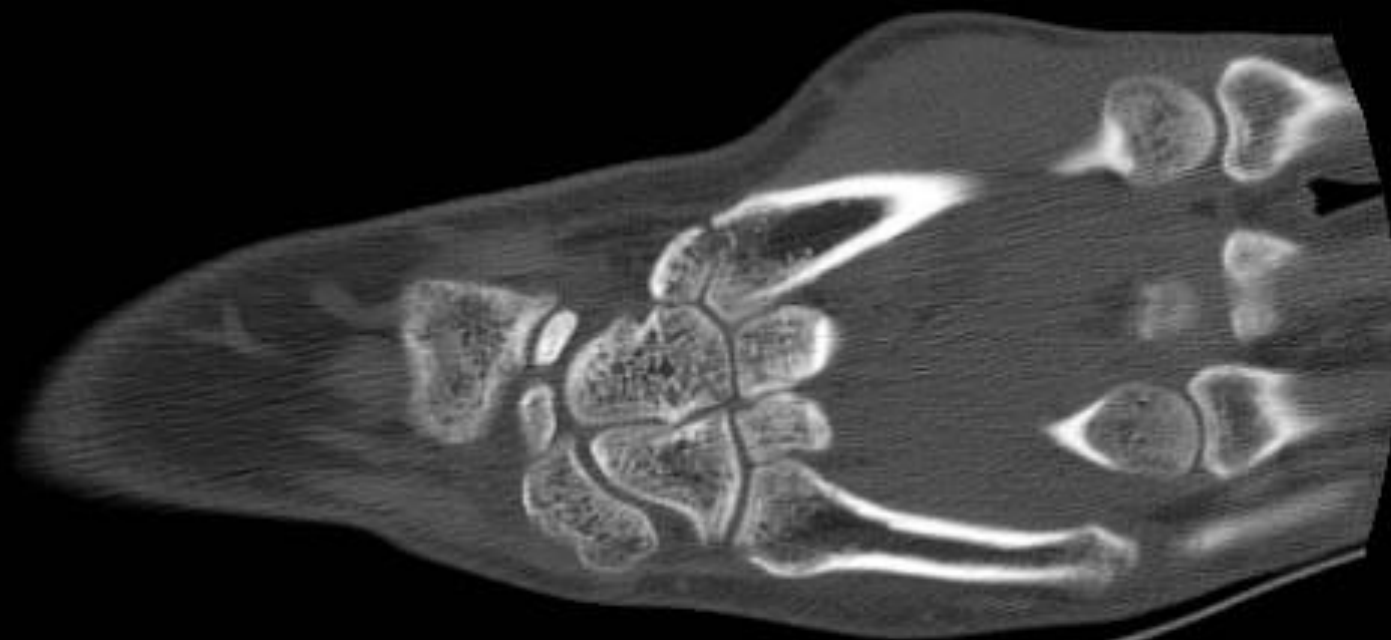

W 2000 : L 500



13

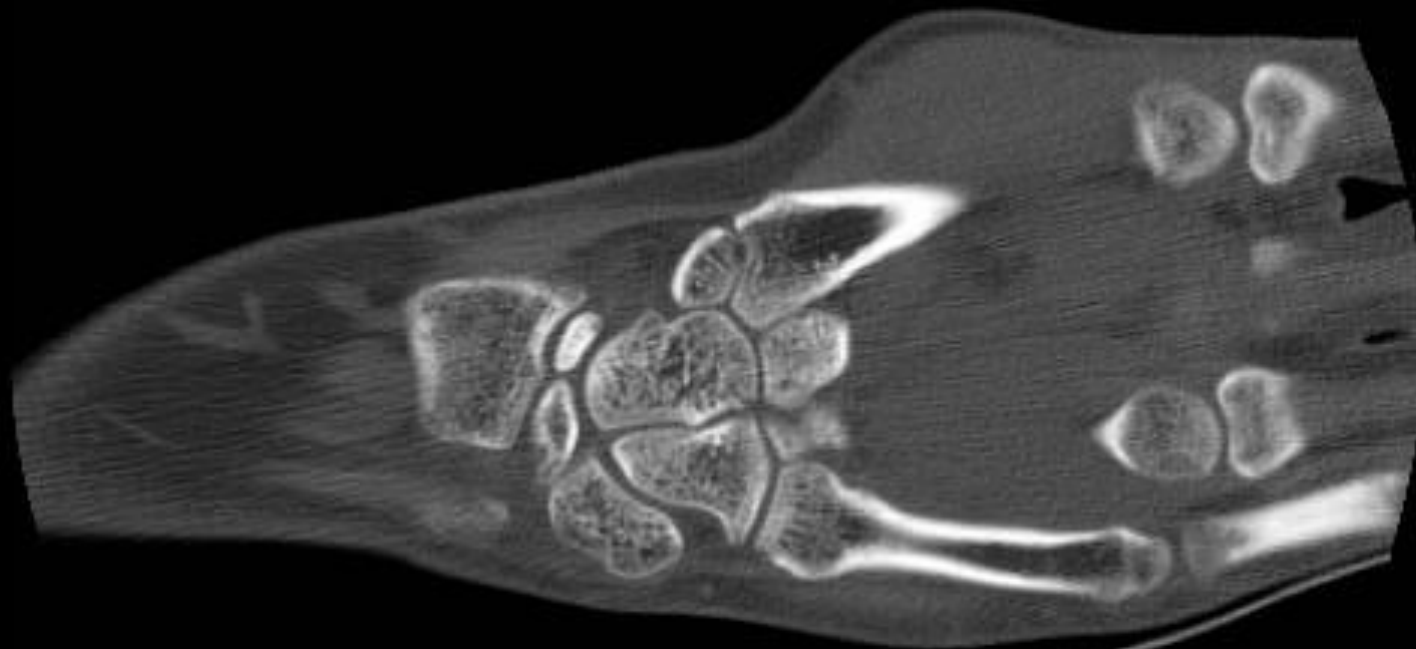
SNAC



W 2000 : L 500

14

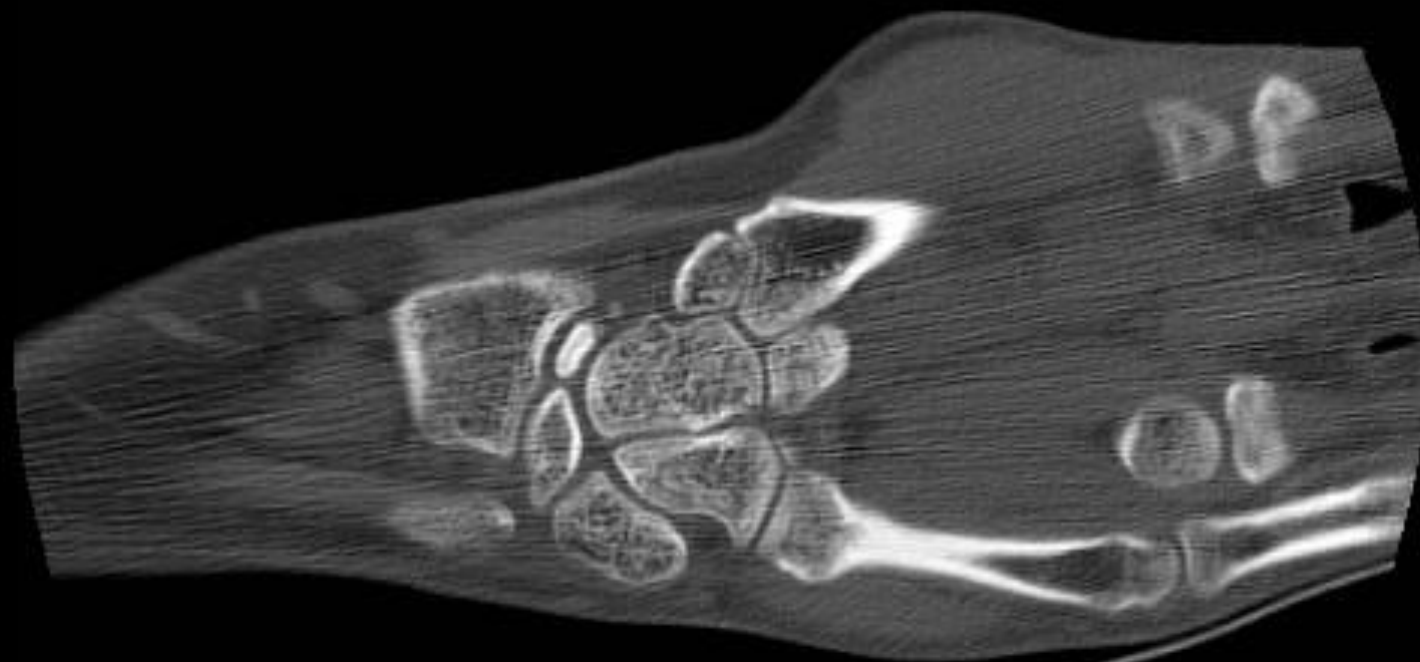
SNAC



W 2000 : L 500

15

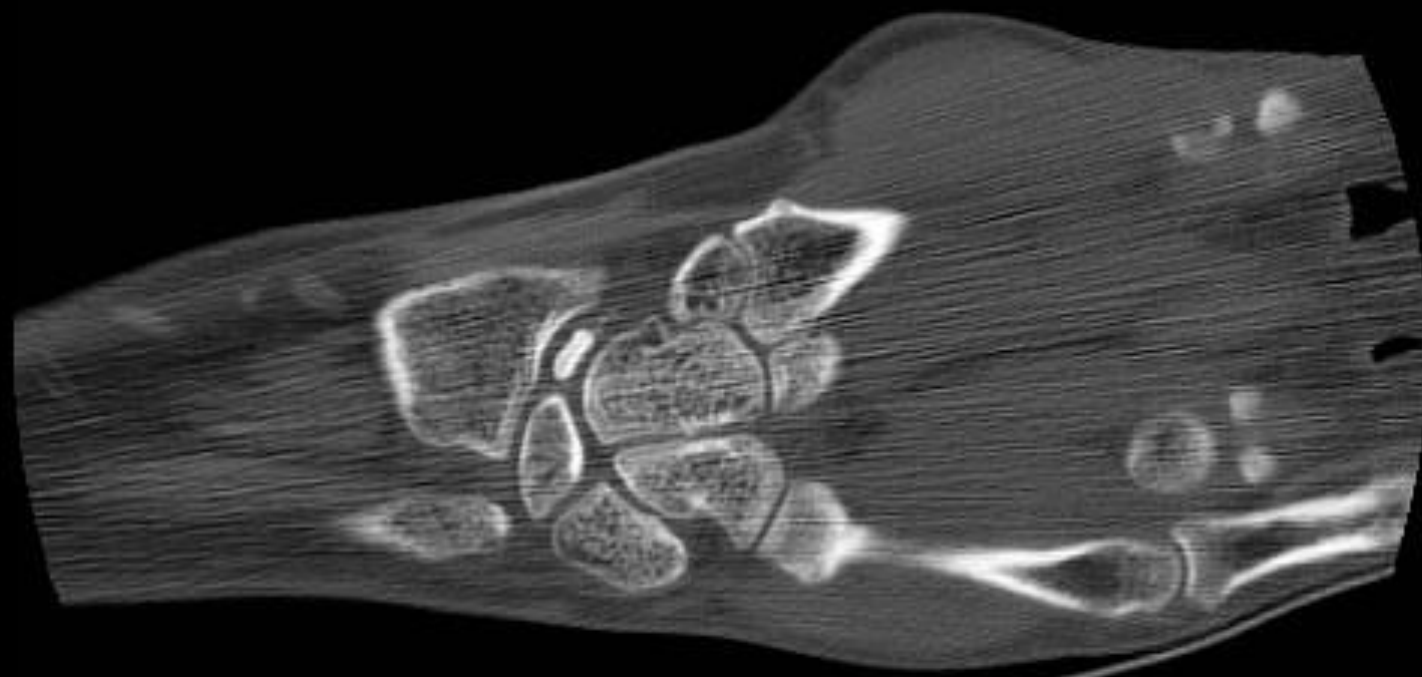
SNAC



W 2000 : L 500

16

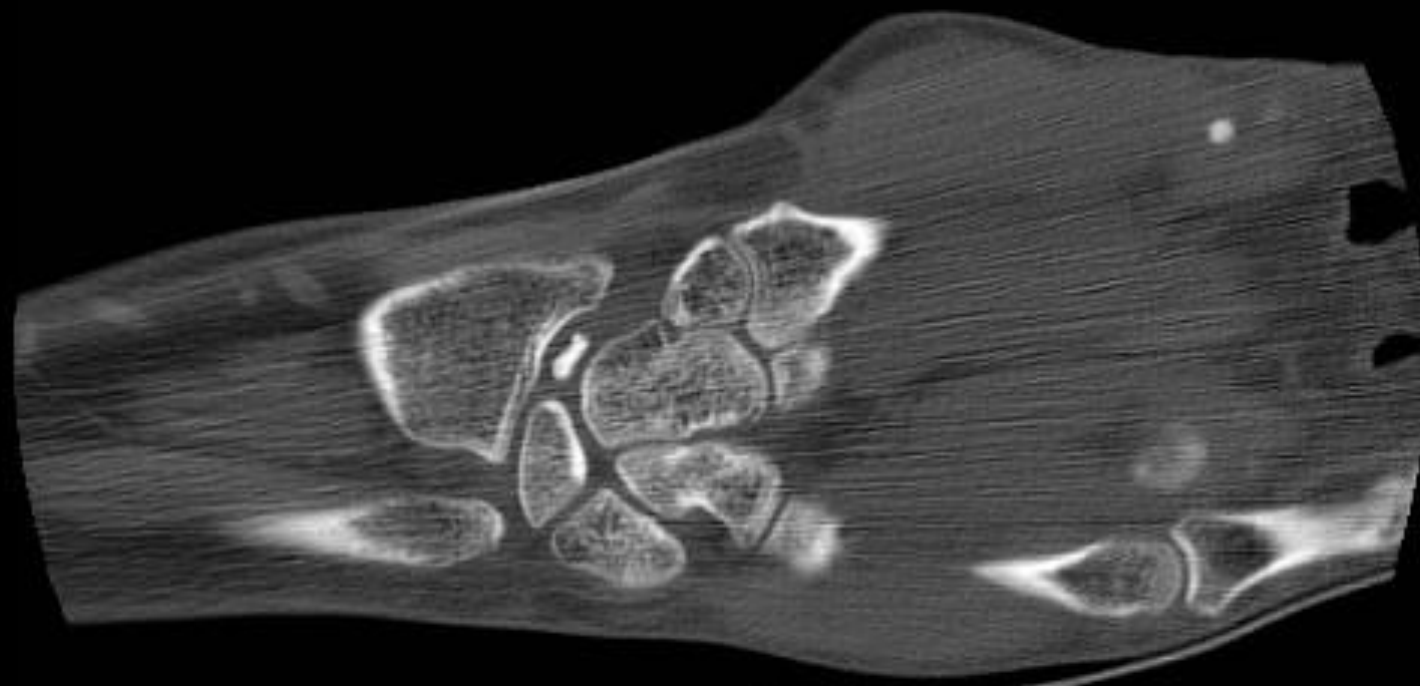
SNAC



W 2000 : L 500

17

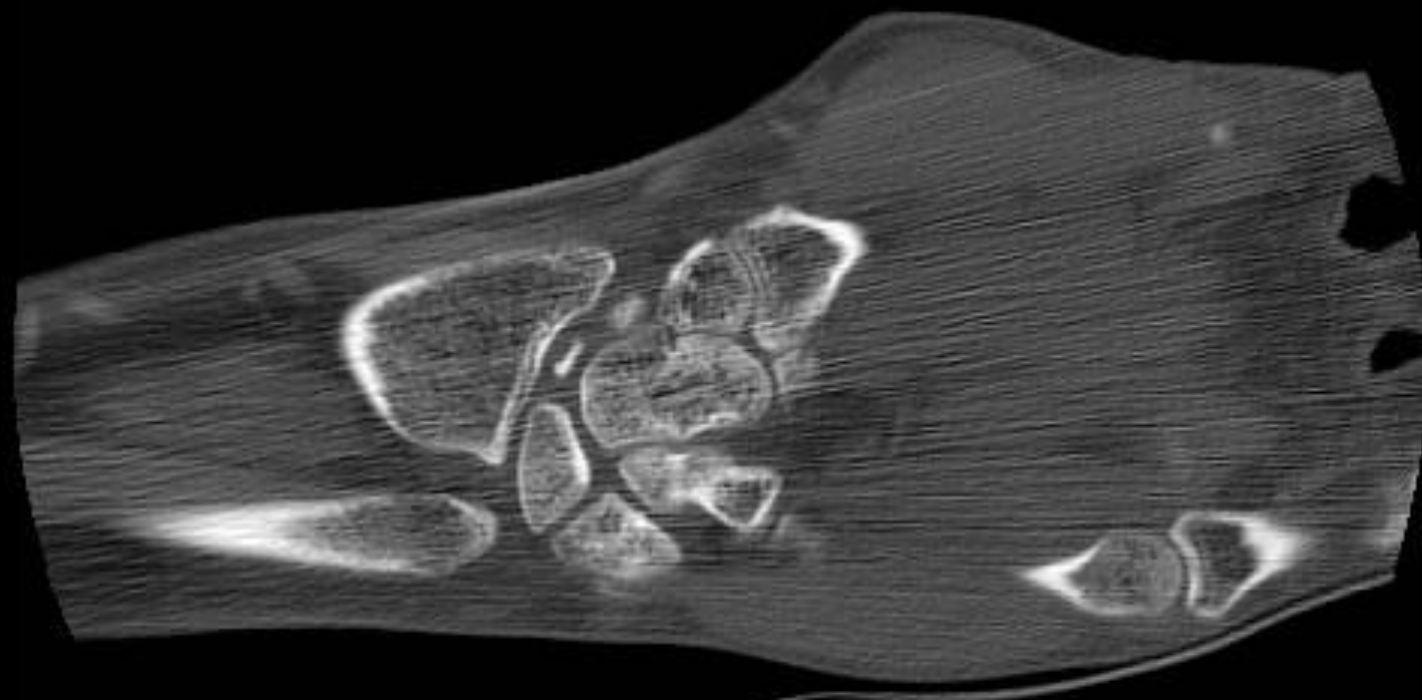
# SNAC



W 2000 : L 500

18

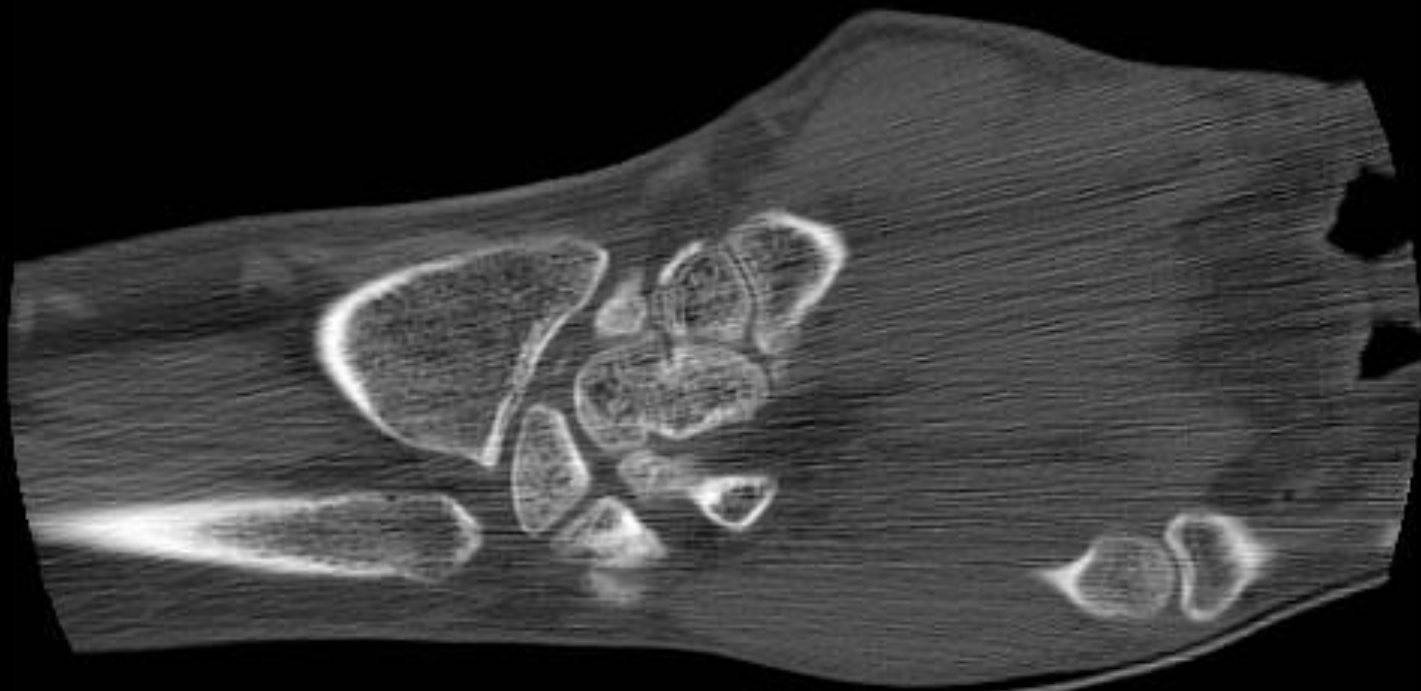
SNAC



W 2000 : L 500

19

SNAC

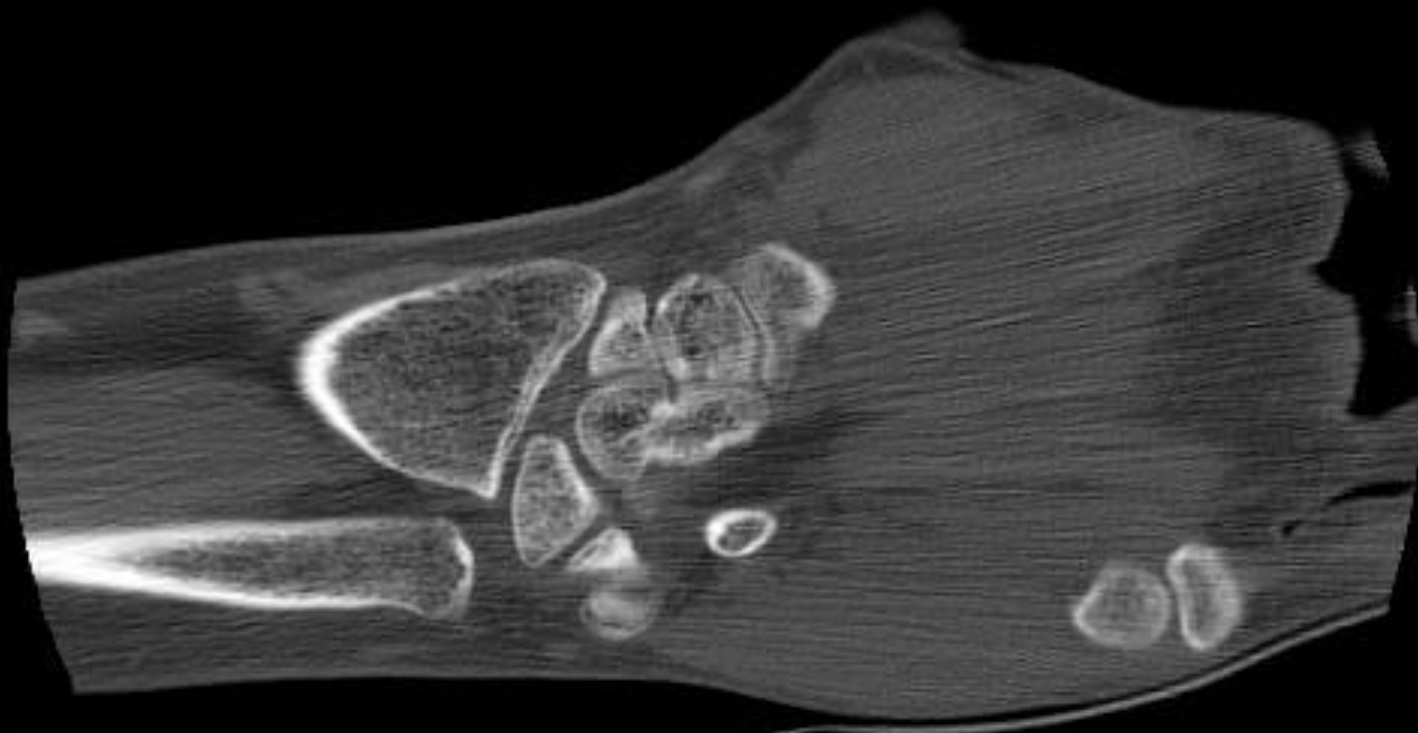


W 2000 : L 500



20

SNAC

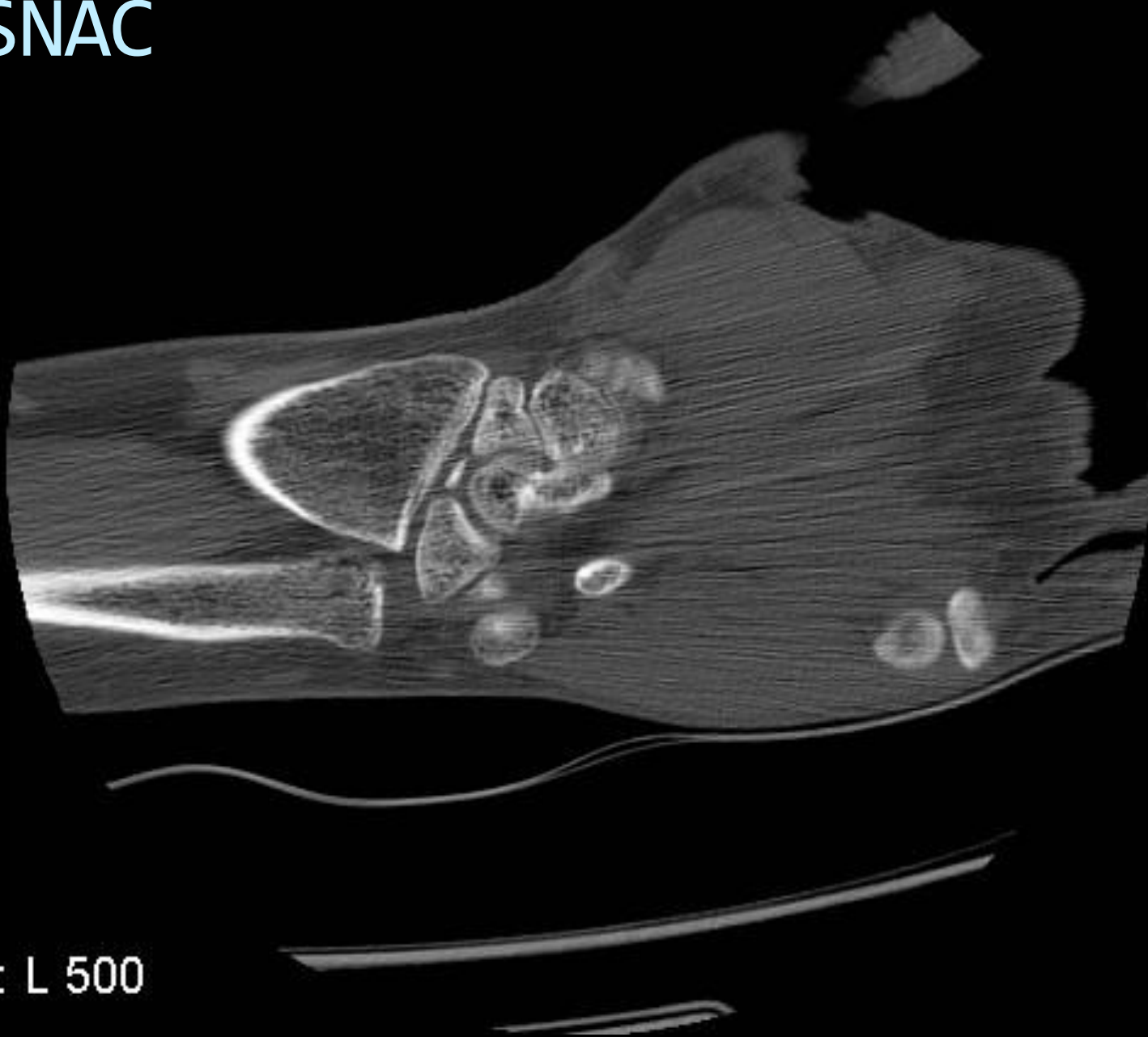


W 2000 : L 500



21

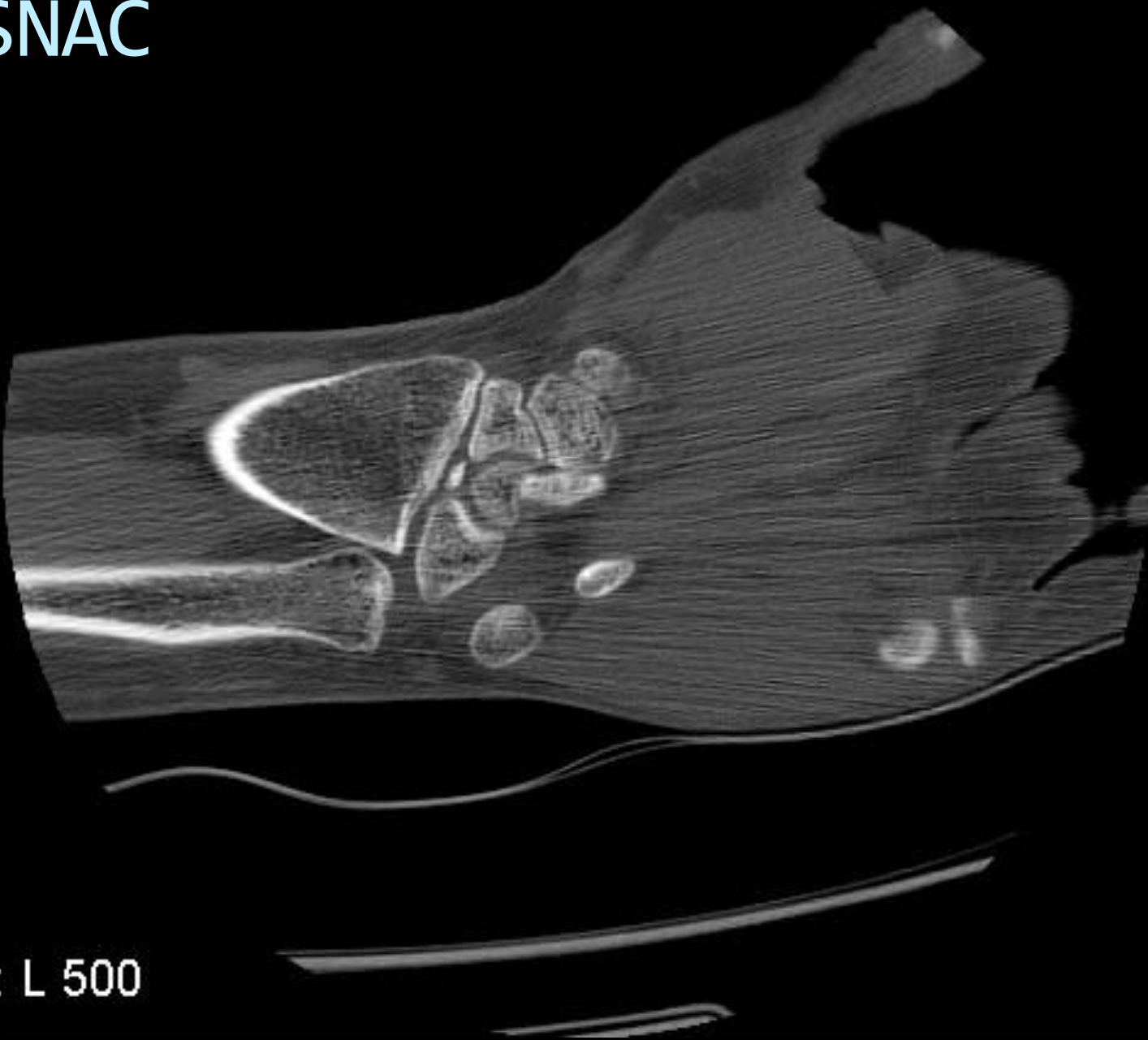
SNAC



W 2000 : L 500

22

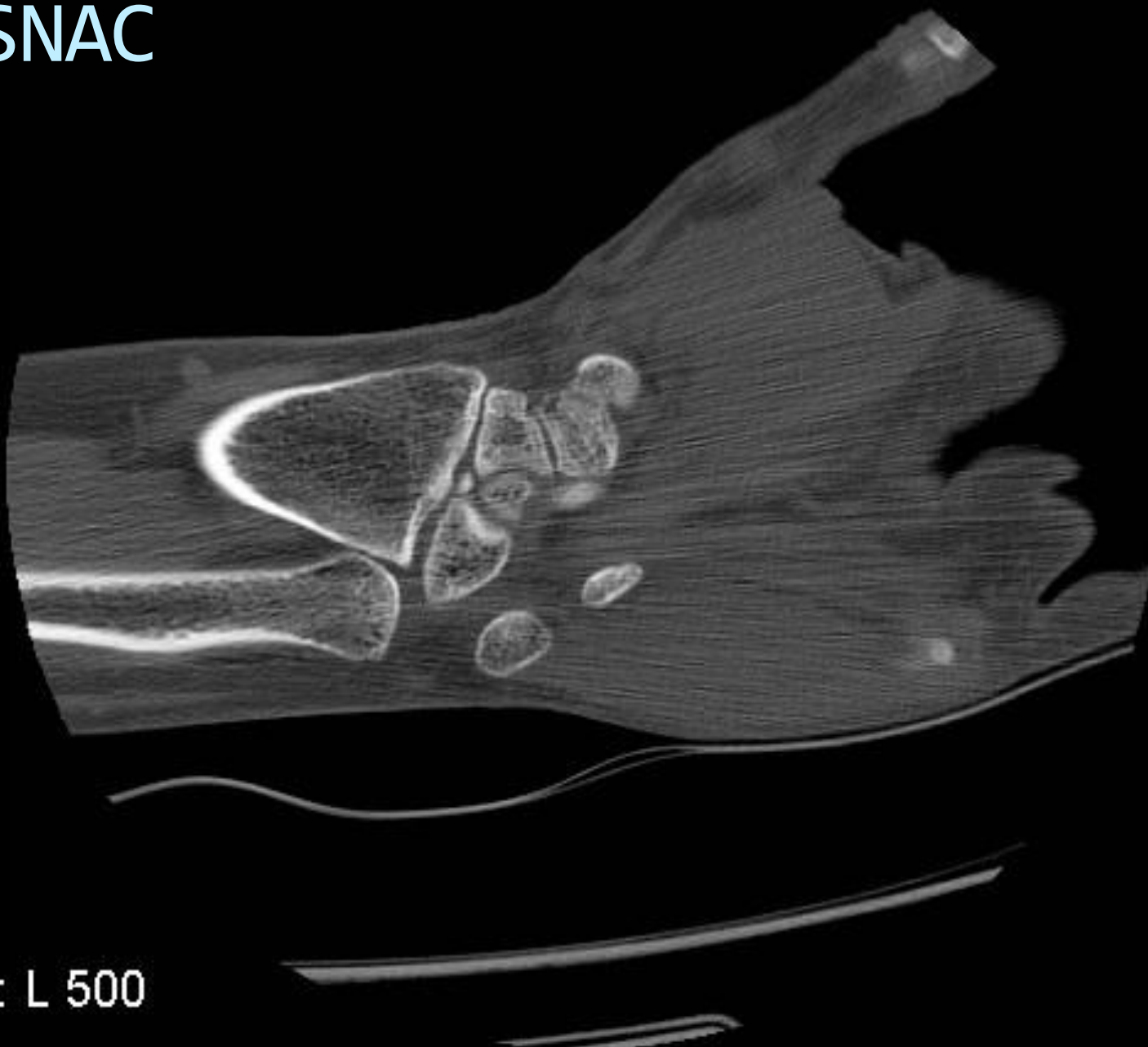
SNAC



W 2000 : L 500

23

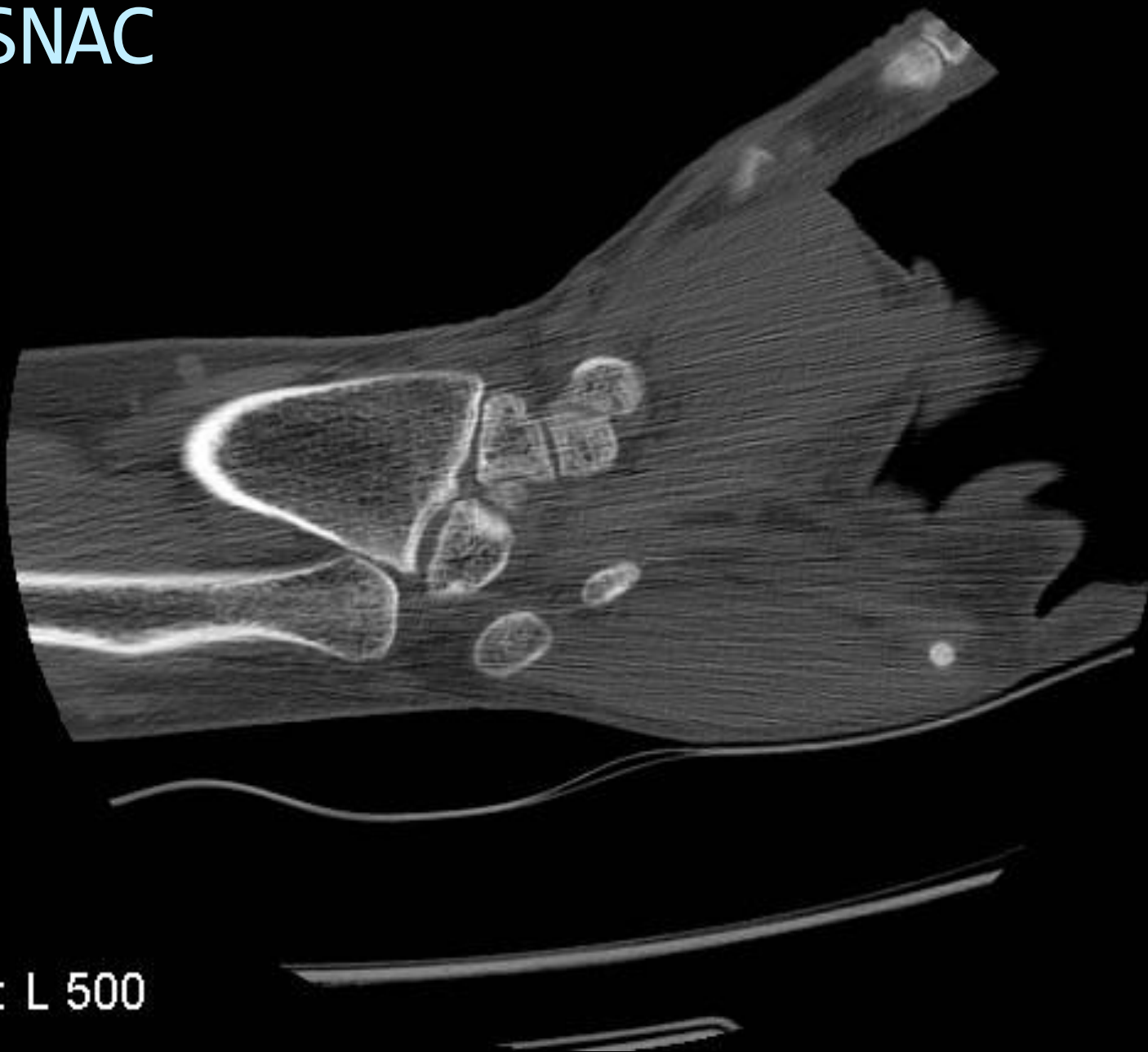
SNAC



W 2000 : L 500

24


SNAC



W 2000 : L 500

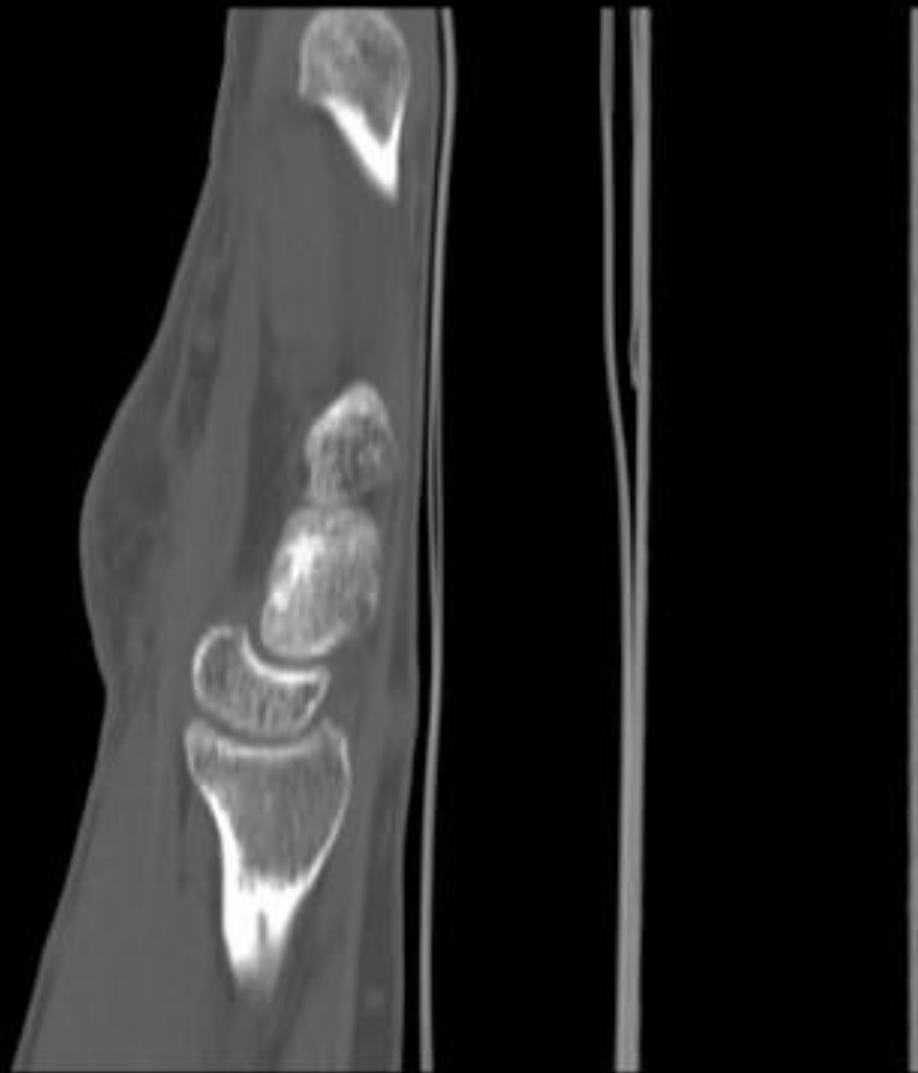
25

SNAC

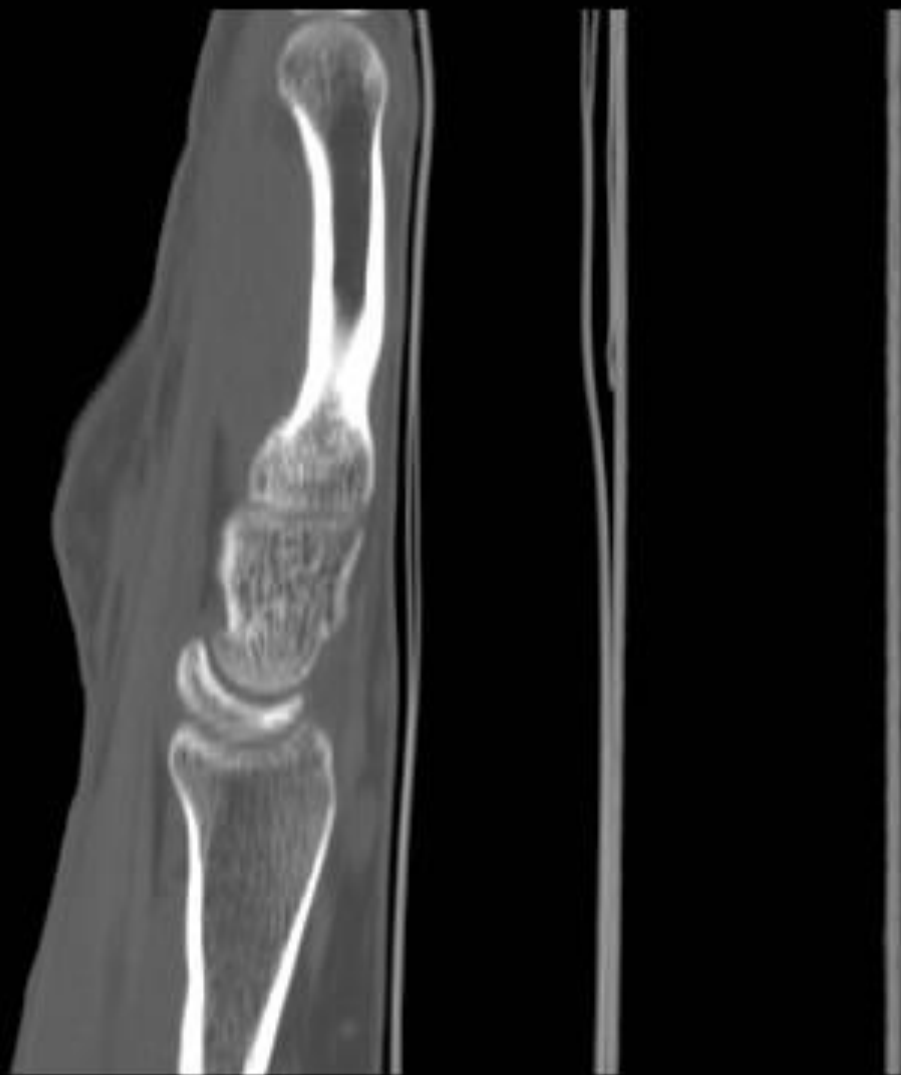

W 2000 : L 500

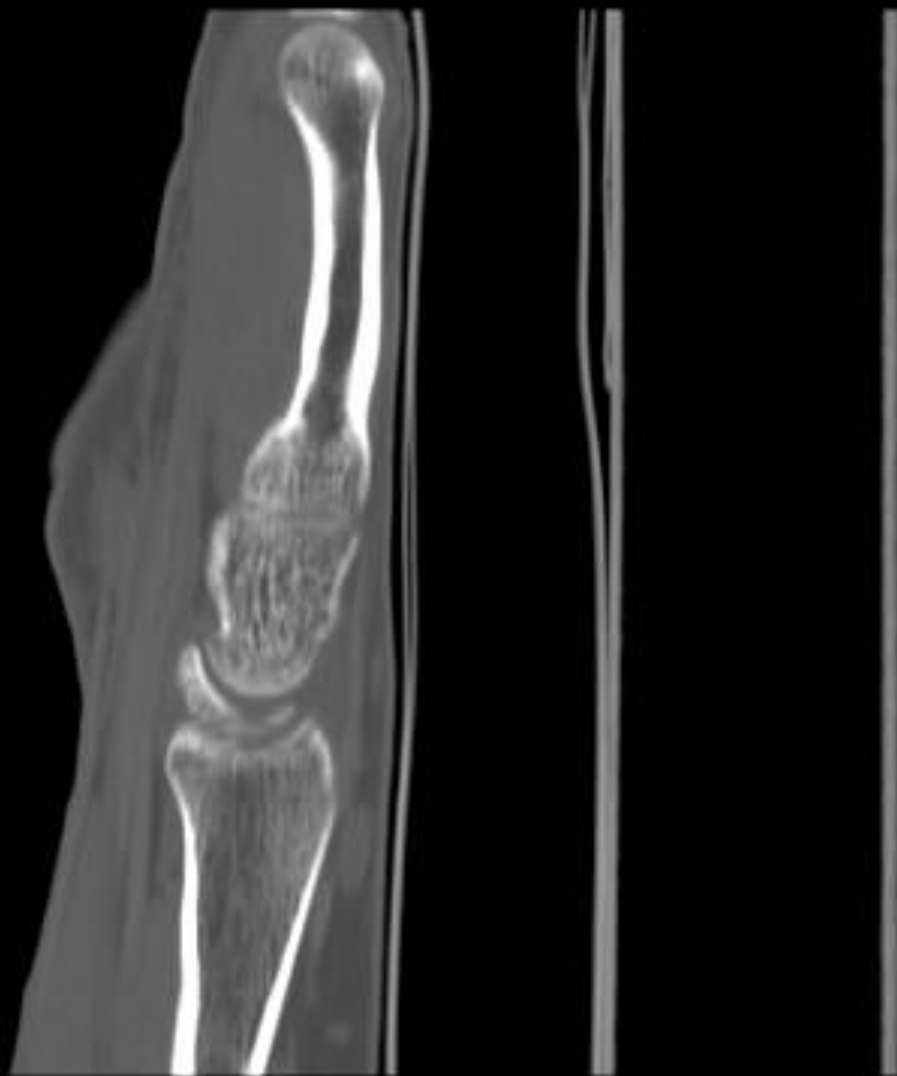## SNAC



## SNAC

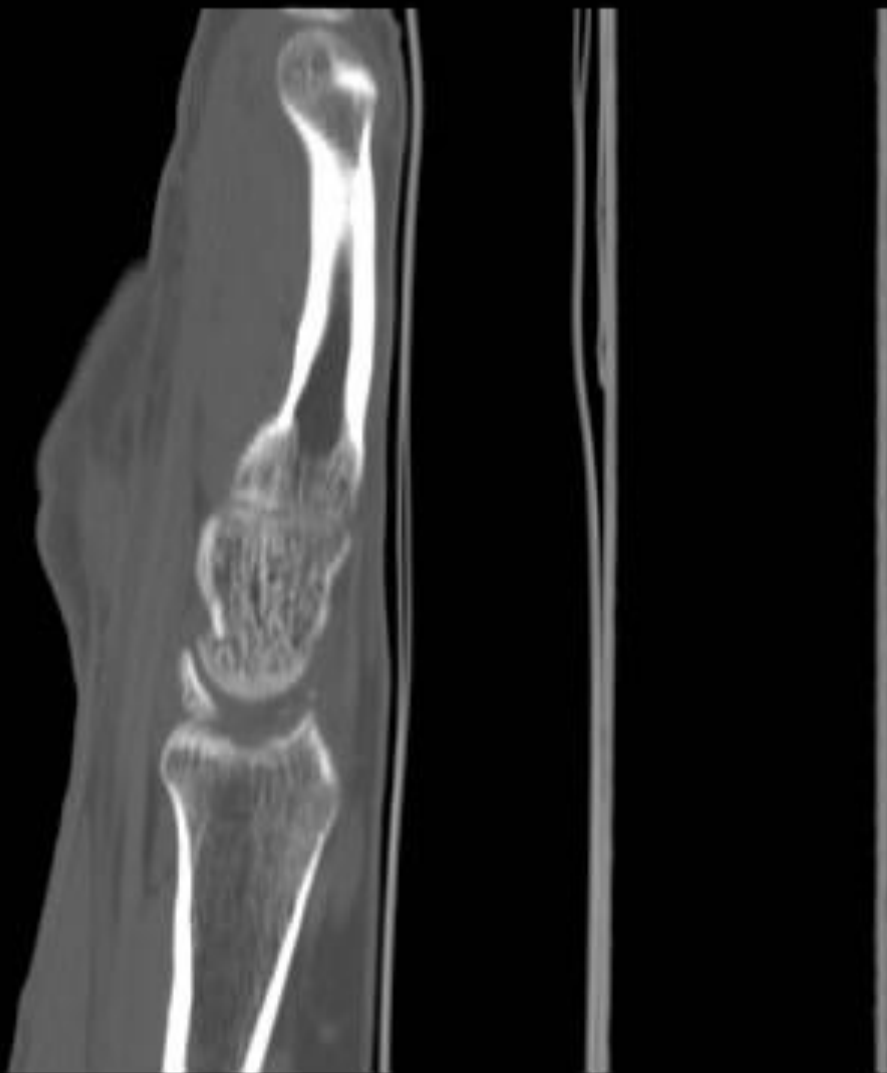

## SNAC

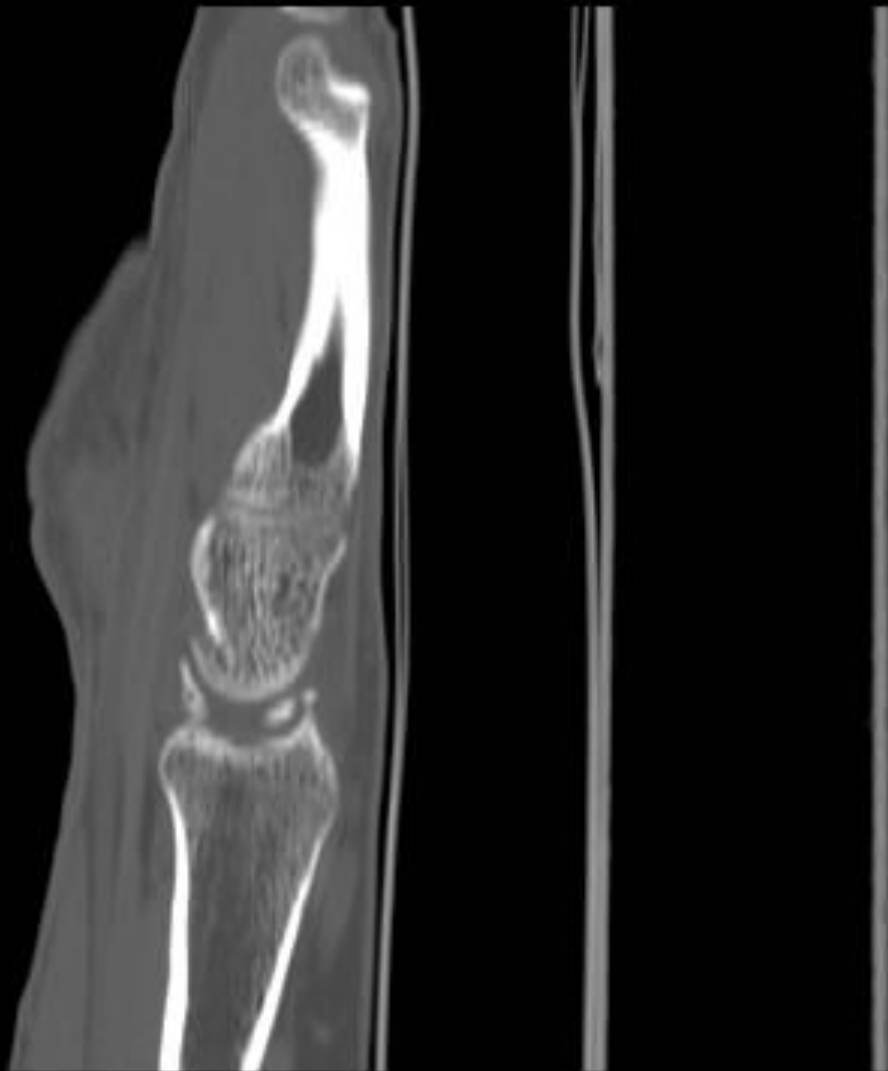



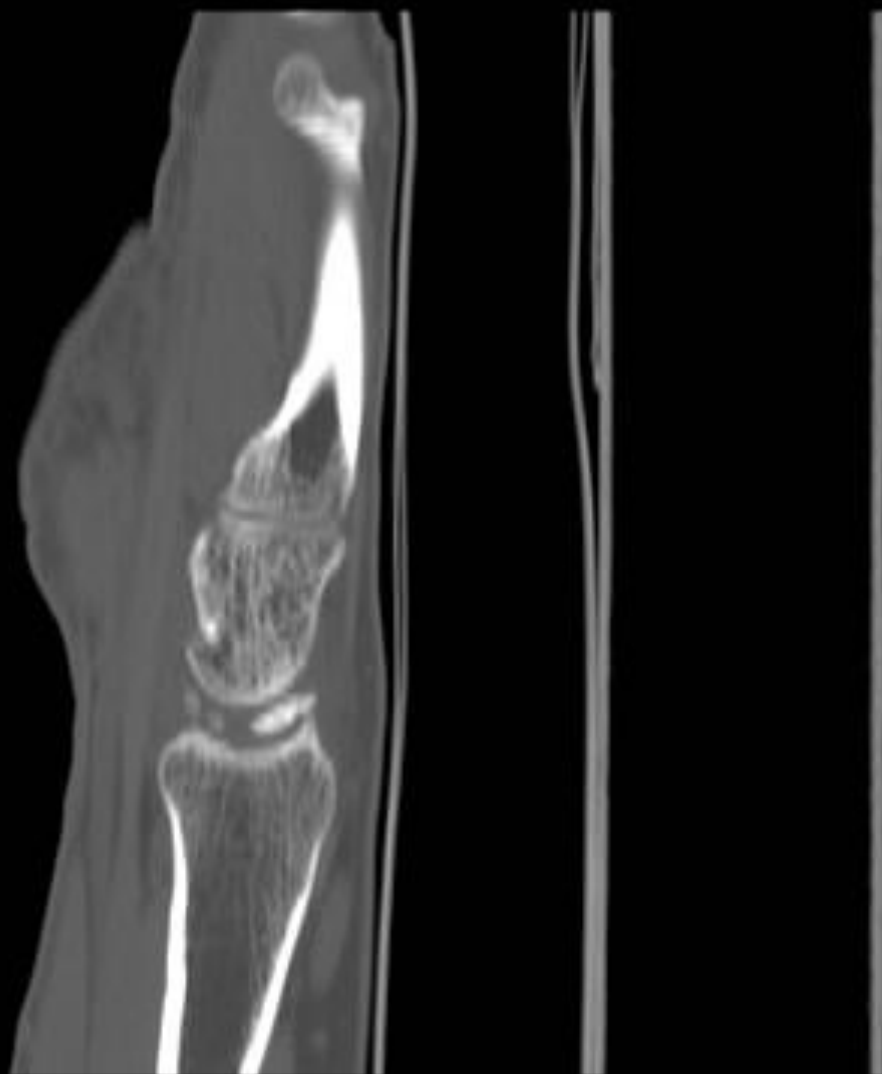## SNAC



## SNAC

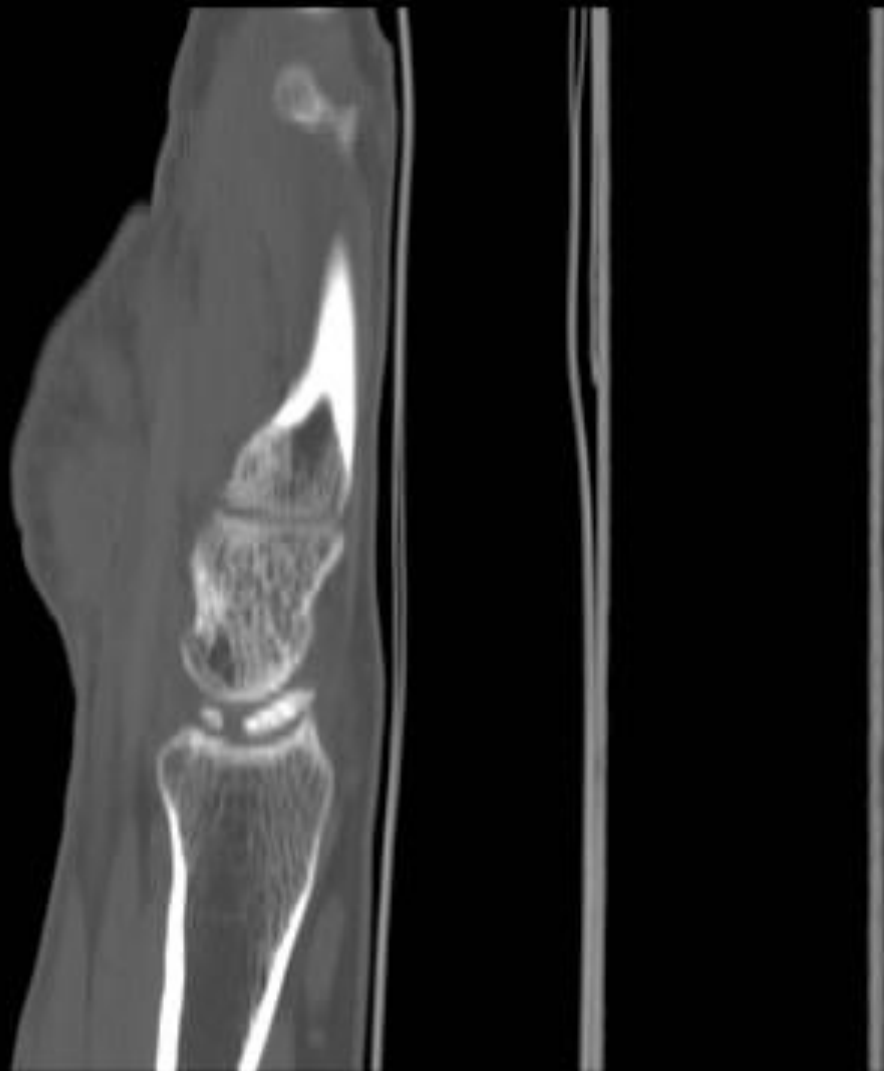

## SNAC



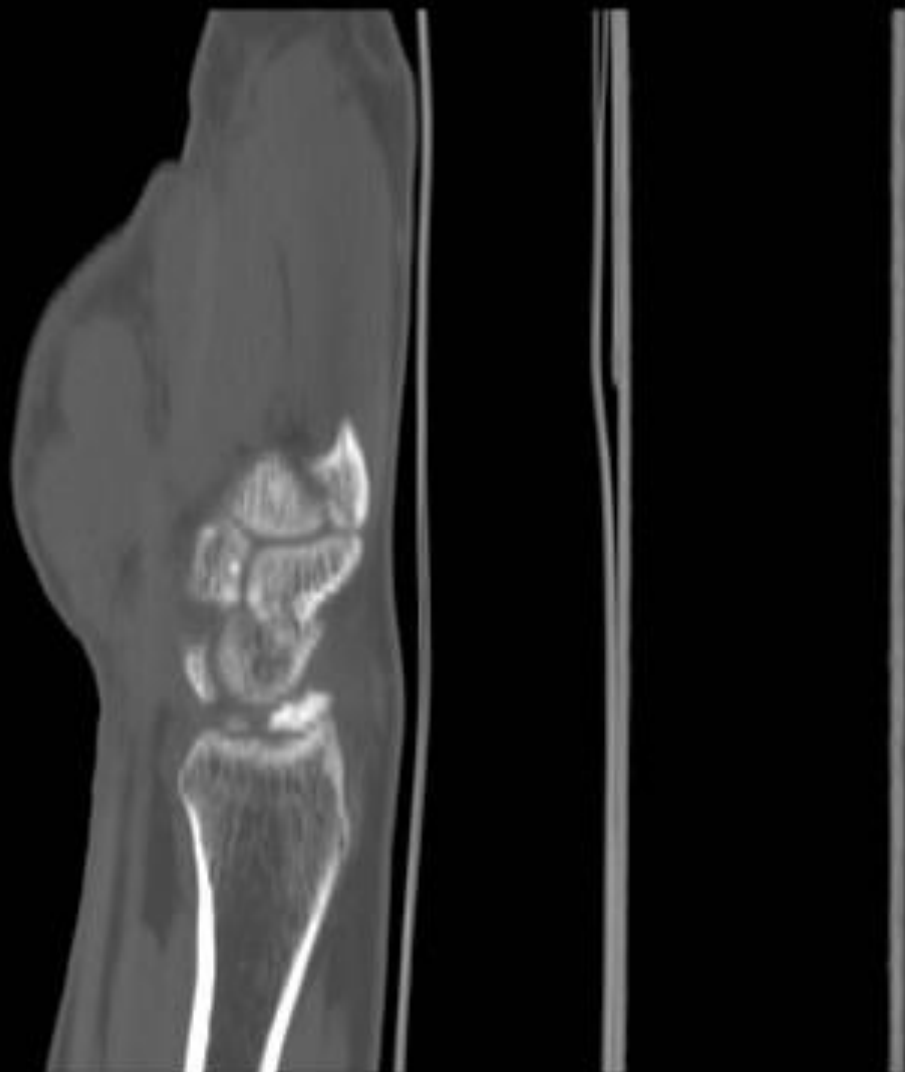37

# SNAC



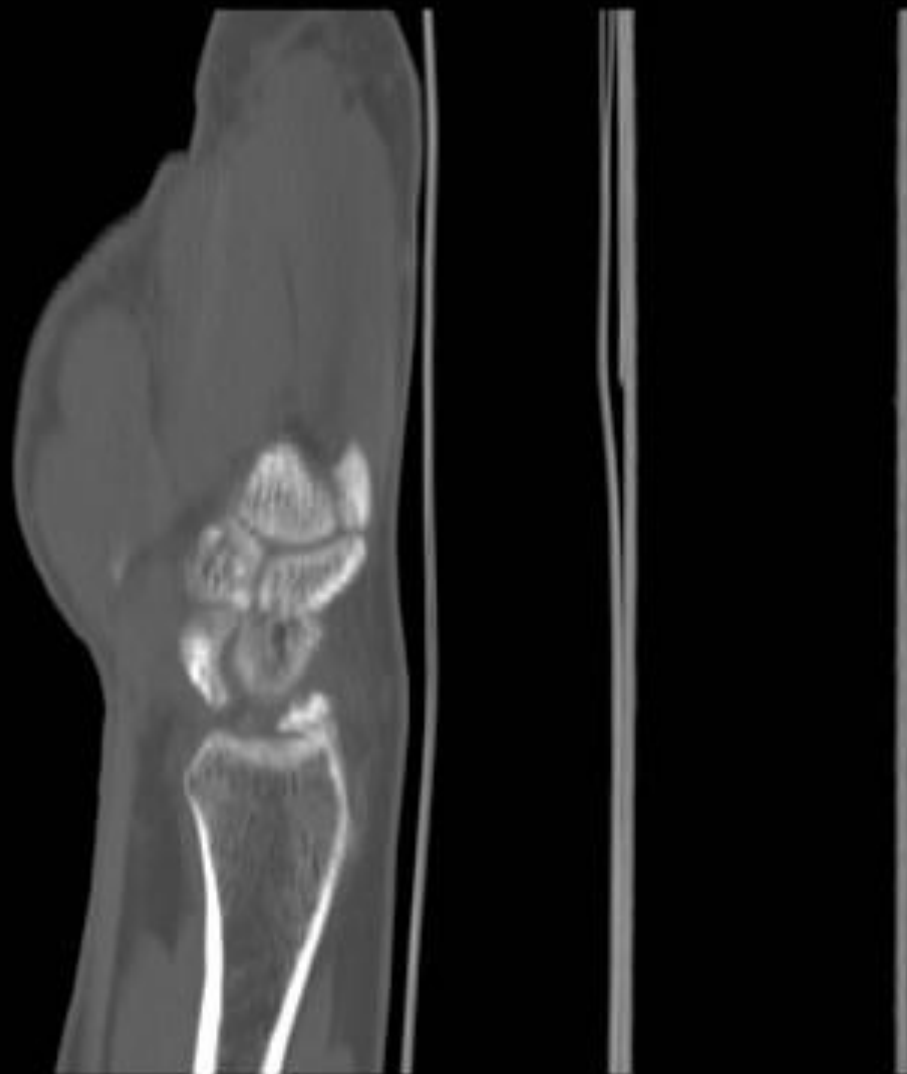41

# SNAC



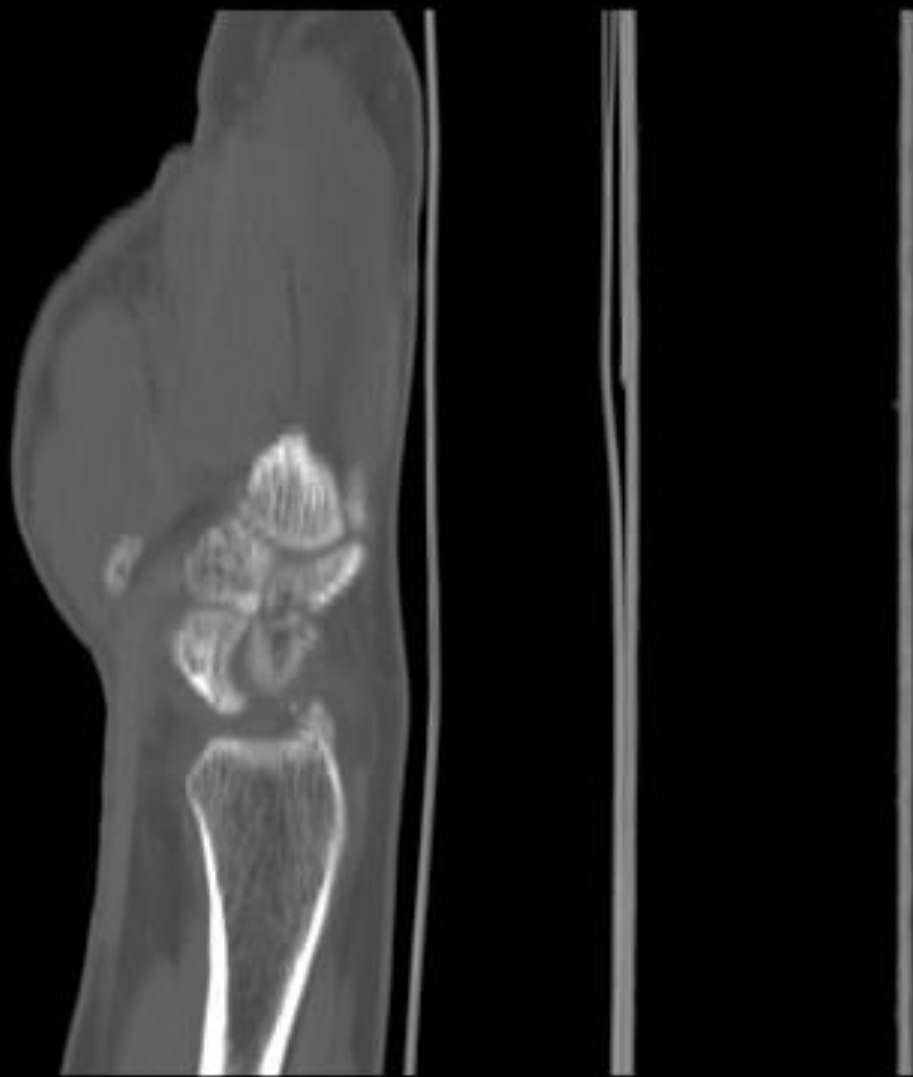
42

# SNAC



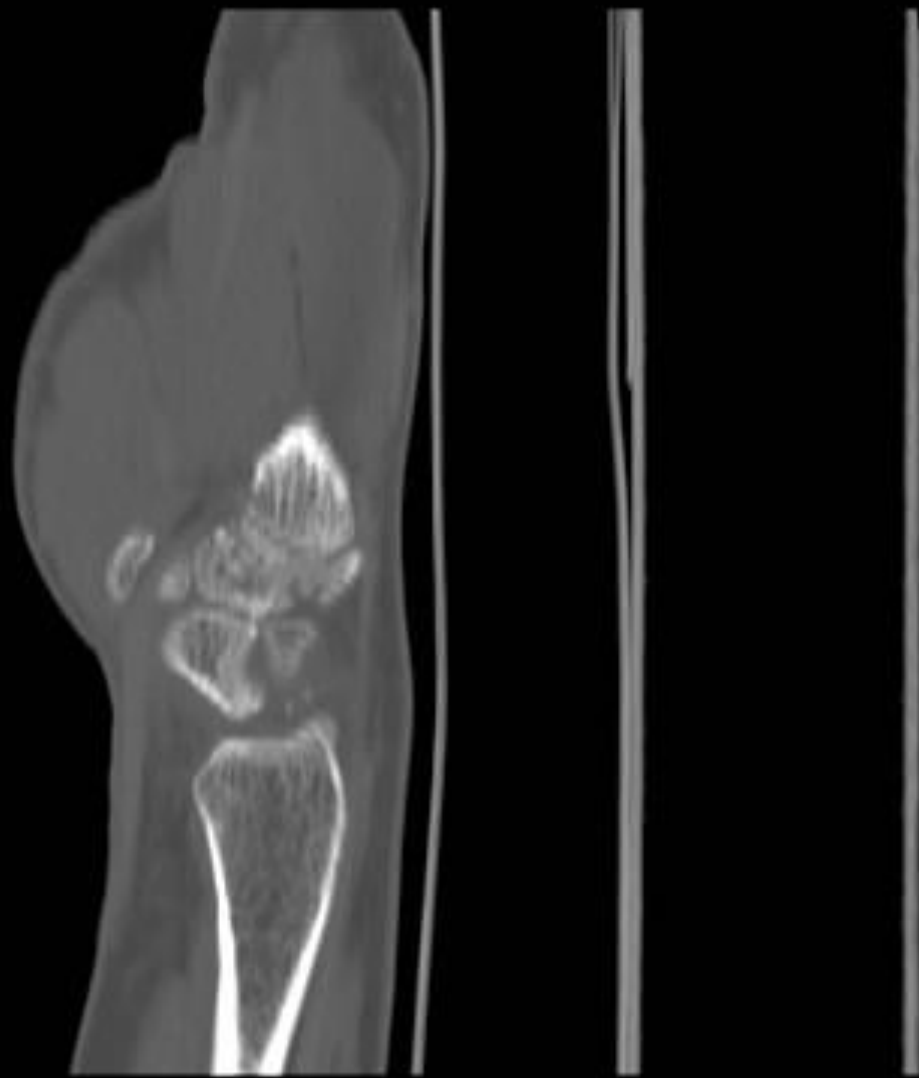
43

# SNAC



W 1993 : L 316

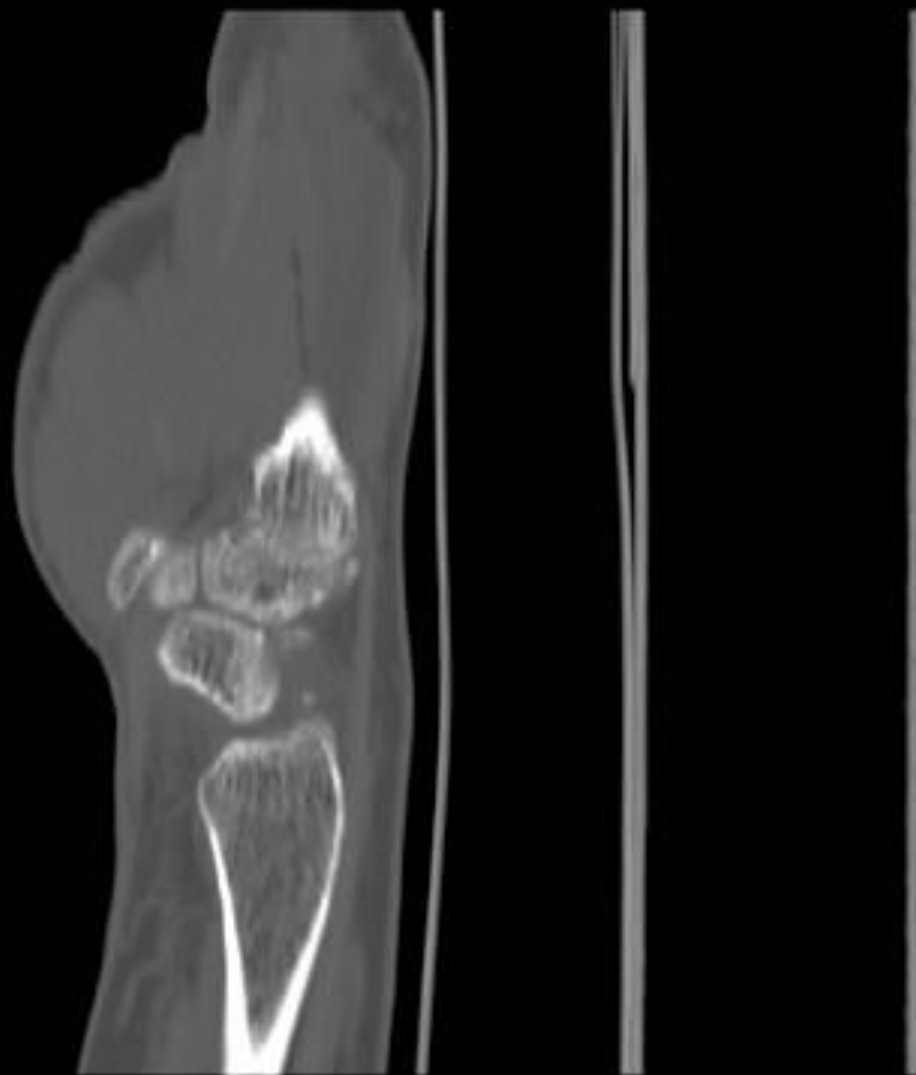## SNAC





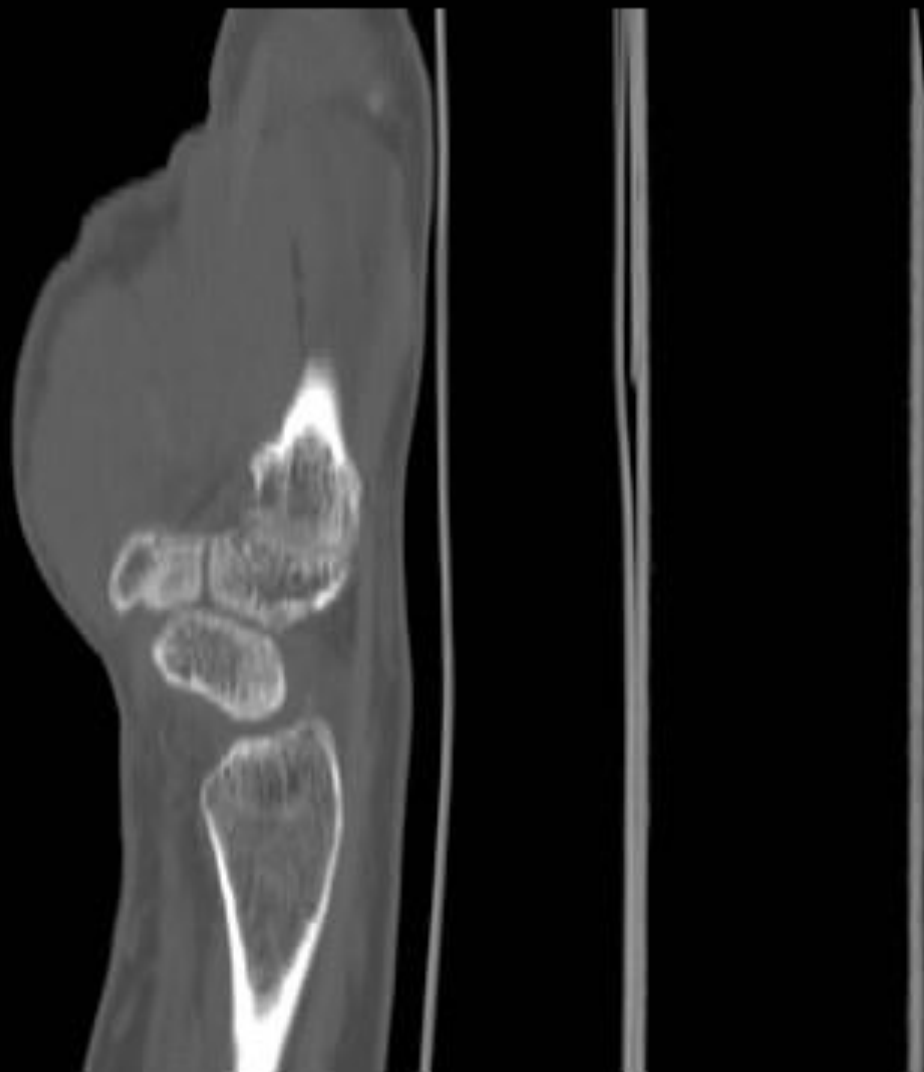
45

SNAC



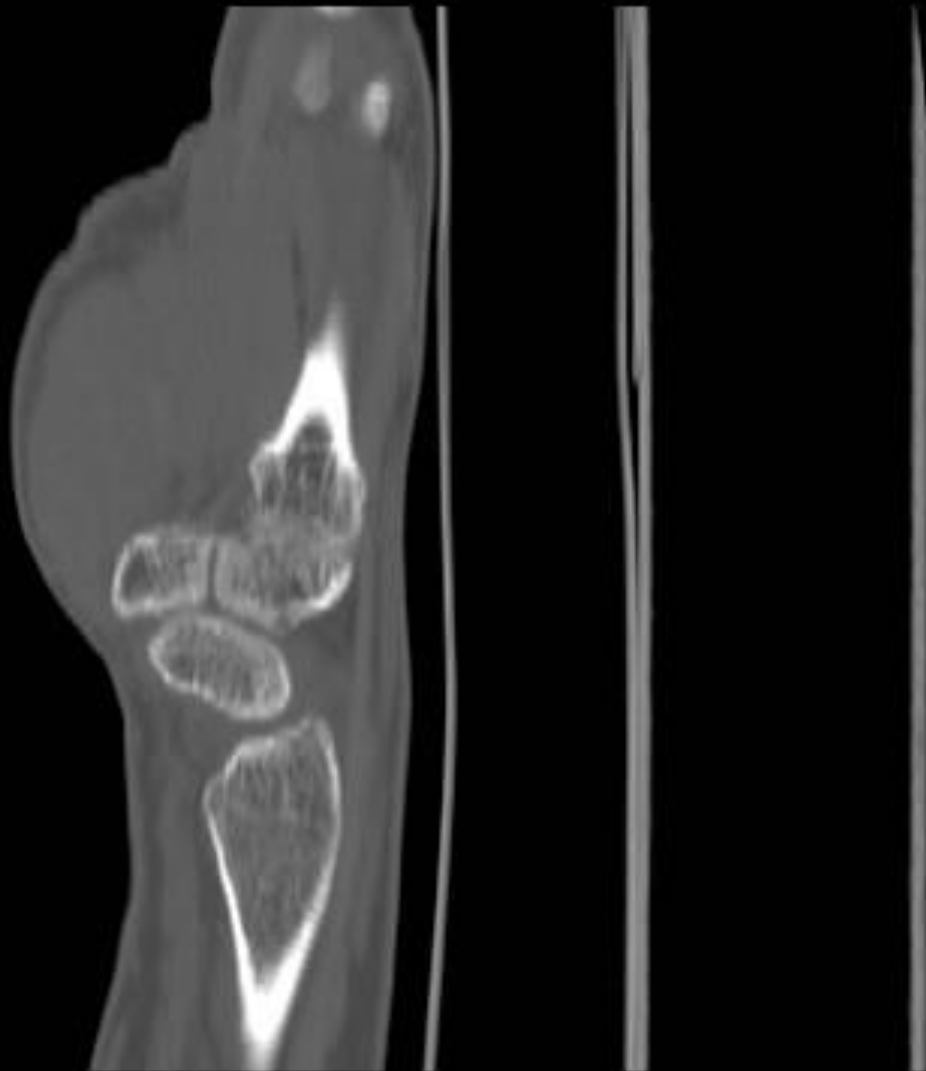
W 1993 : L 316

# SNAC

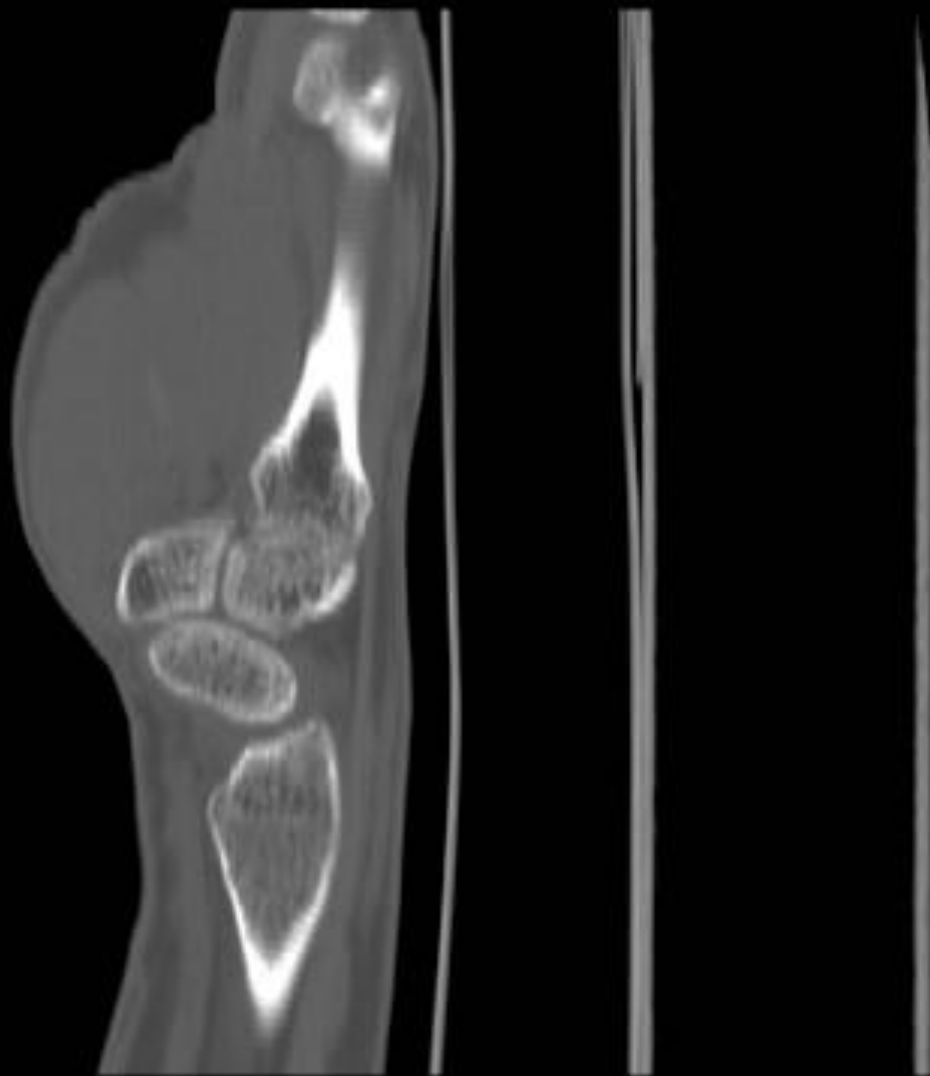

47

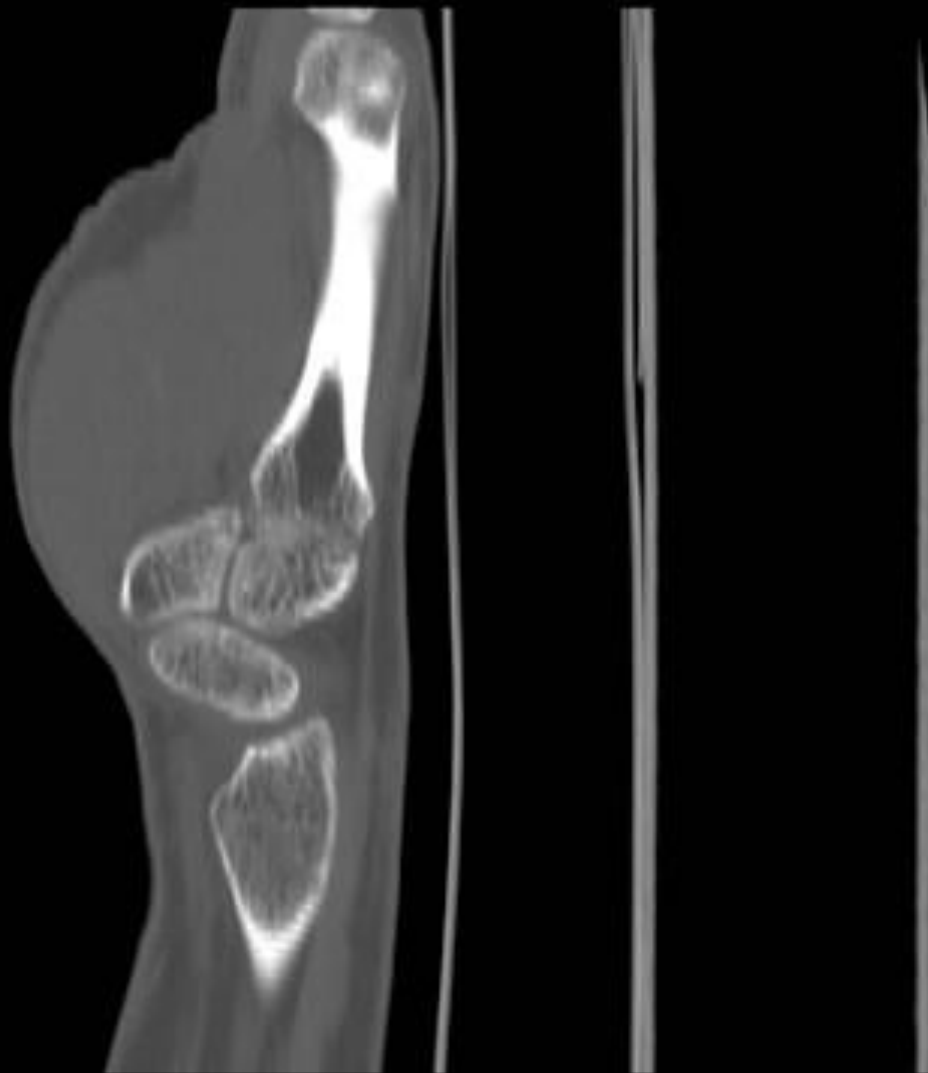# SNAC



# SNAC

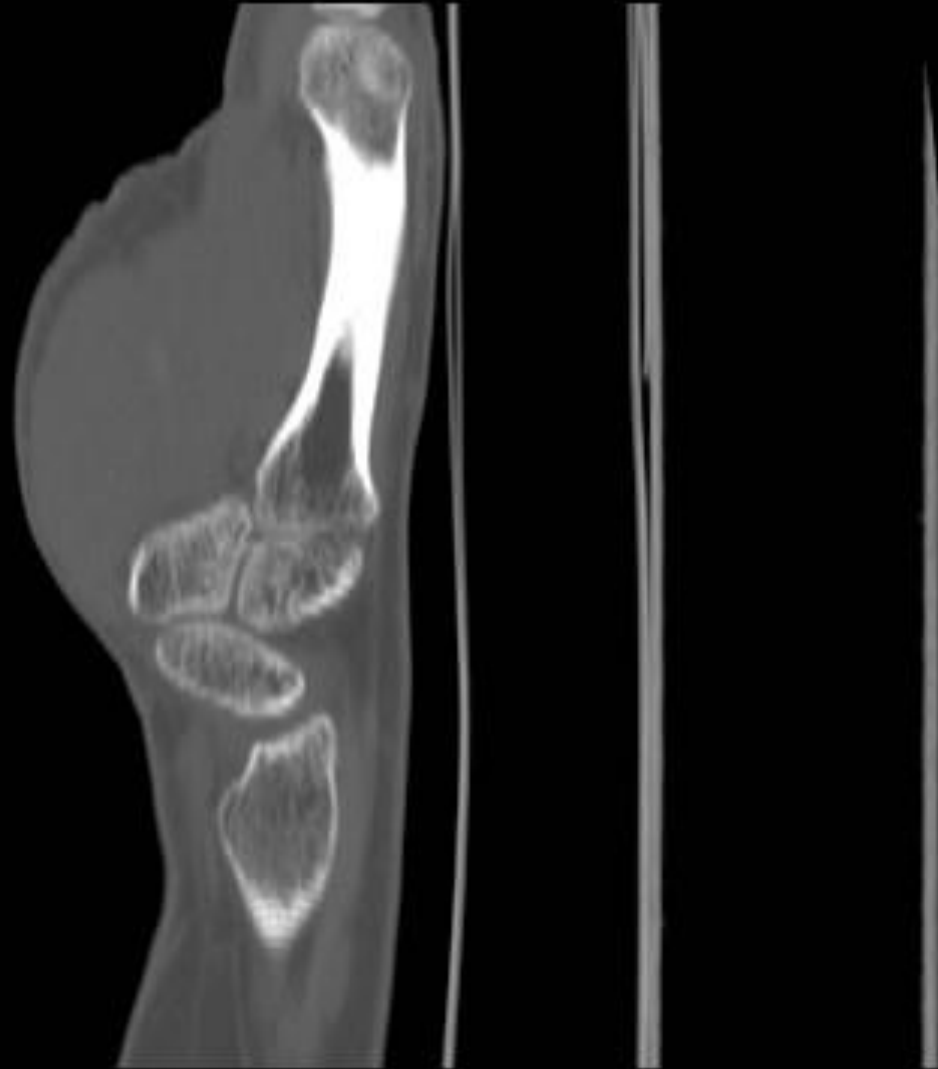


## SNAC



50

SNAC



W 1993 : L 316

# Patterns of Carpal Instability

- Dissociative
  - Scapholunate dissociation
  - Lunotriquetral dissociation
  - Scaphoid fractures that are unstable, ununited, or malunited
  - Kienbock's disease
- Non-dissociative
  - Radiocarpal
  - Midcarpal
- Complex carpal instability
  - Perilunate dislocations
- Adaptive carpal instability

# Kienbock's disease

- FrAGMENTATION and progressive collapse of the lunate bone
  - Disruption of the scapholunate and lunotriquetral interosseous ligaments.
  - Lunate flexes with proximal migration of the triquetrum
  - Either VISI or DISI pattern of instability may develop



# Patterns of Carpal Instability

- Dissociative (CID)
  - Scapholunate dissociation
  - Lunotriquetral dissociation
  - Scaphoid fractures that are unstable, ununited, or malunited
  - Kienbock's disease
- Non-dissociative (CIND)
  - Radiocarpal
  - Midcarpal
- Complex carpal instability (CIC)
  - Perilunate dislocations
- Adaptive carpal instability (CIA)

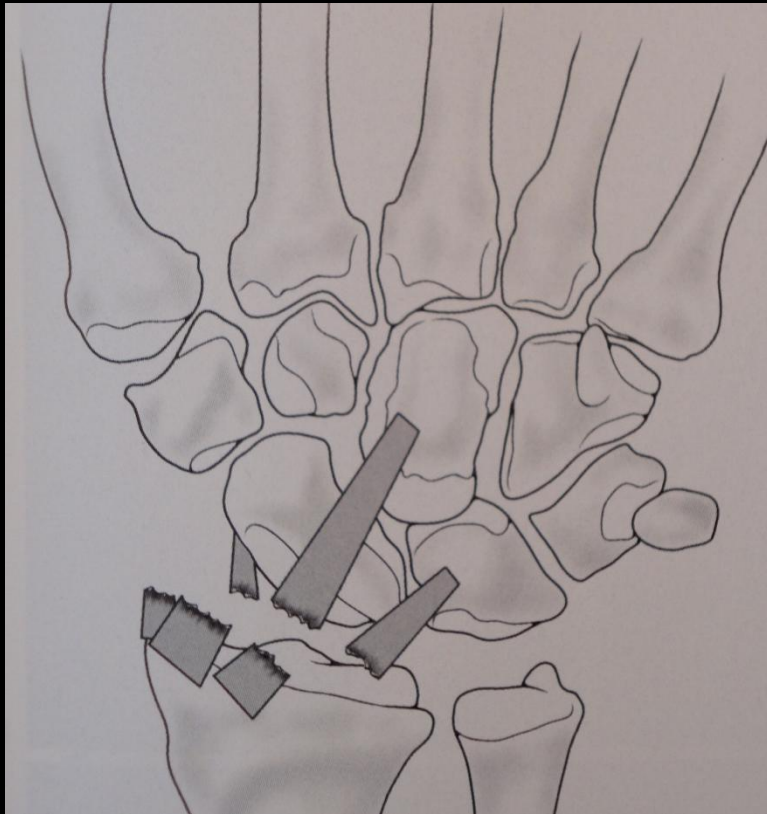
# Patterns of Carpal Instability

- Dissociative (CID)
  - Scapholunate dissociation
  - Lunotriquetral dissociation
  - Scaphoid fractures that are unstable, ununited, or malunited
  - Kienbock's disease
- Non-dissociative (CIND)
  - Radiocarpal
    - Ulnar translocation
    - Dorsal
    - Volar
    - Combination of the above
  - Midcarpal
- Complex carpal instability
  - Perilunate dislocations
- Adaptive carpal instability

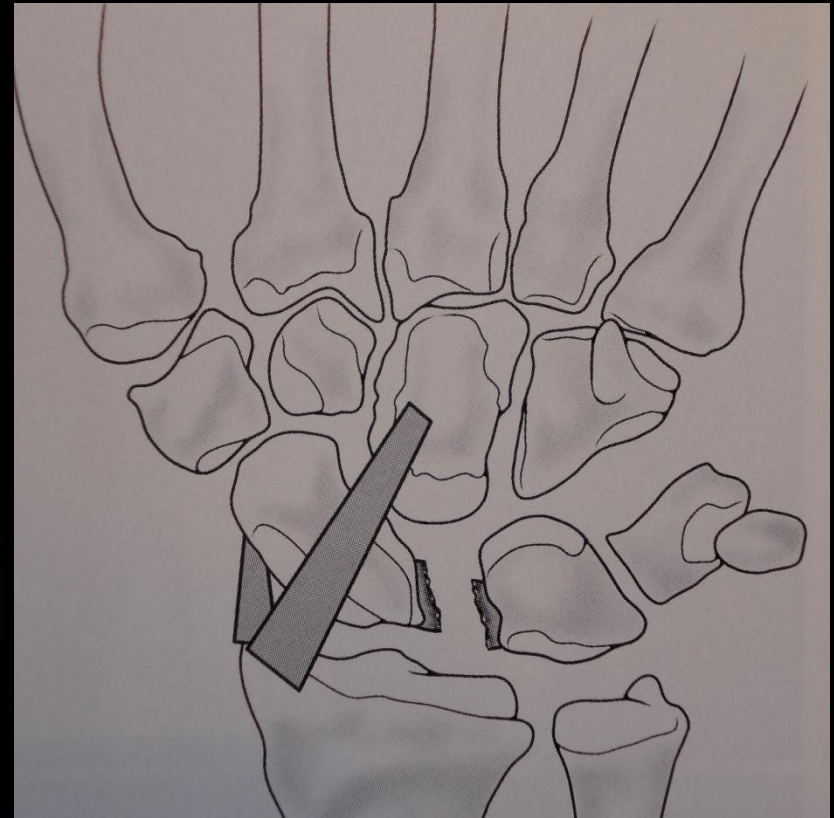
# CIND: radiocarpal

- Can be asstd with articular disorders, injuries, developmental anomalies or prior surgeries (resection of the distal portion of the ulna.
- Instability can be
  - ulnar (ulnar translocation),
  - dorsal
  - volar
  - combinations of some of these
- There are 2 types of ulnar translocation...

# CIND: radiocarpal

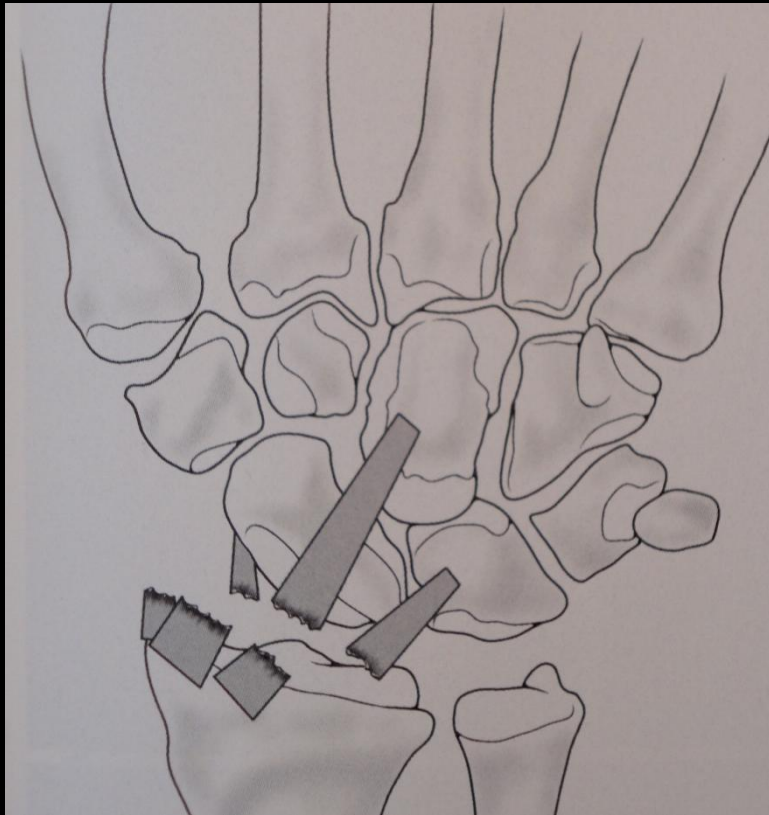


Type I ulnar translocation



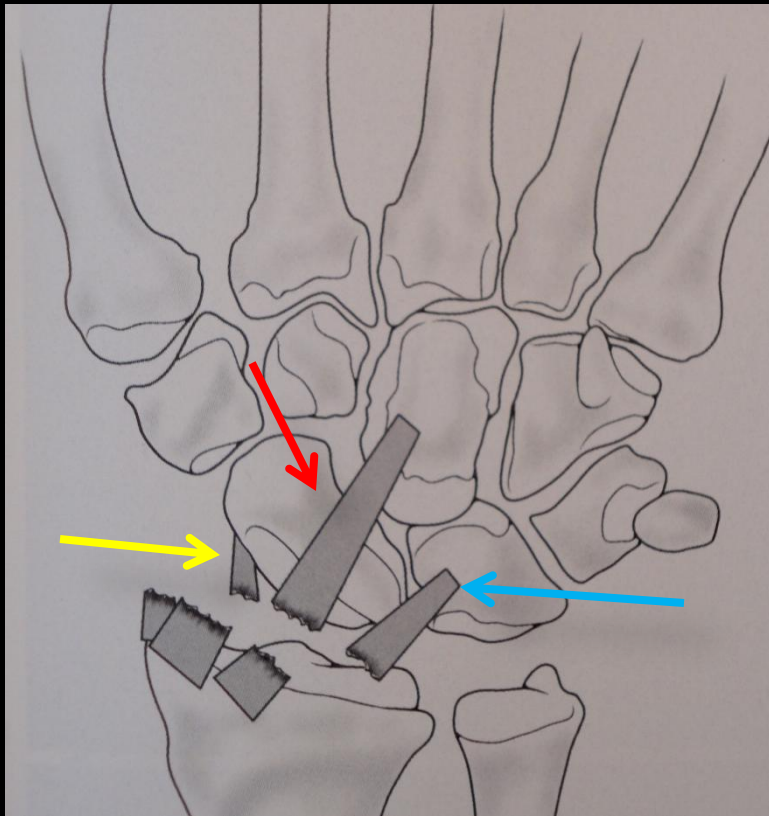
Type II ulnar translocation

# CIND: radiocarpal



- Note: Normally, the radiolunate joint area covers more than 50% of the proximal lunate joint surface.
- Radiolunate contact is decreased with ulnar translocation.

# Radiocarpal CIND: ulnar translocation, type I

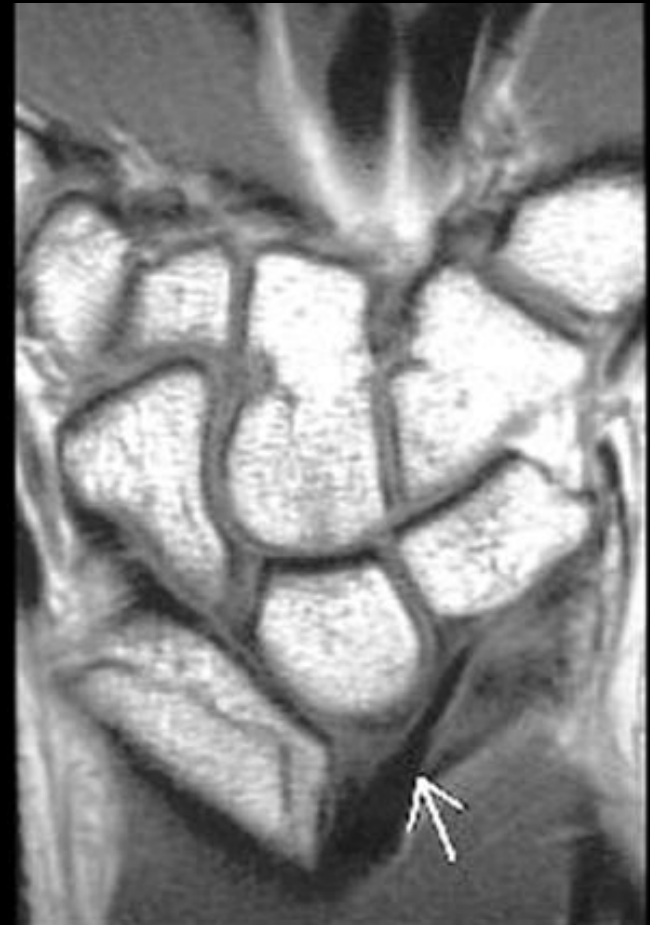

Ligaments disrupted

- Radioscaphoid (RSL)
- Radioscaphocapitate (RSCL)
- radiolunotriquetral (RLTL)
  
- These ligaments resist the tendency to slide down the articular tilt of the radius.

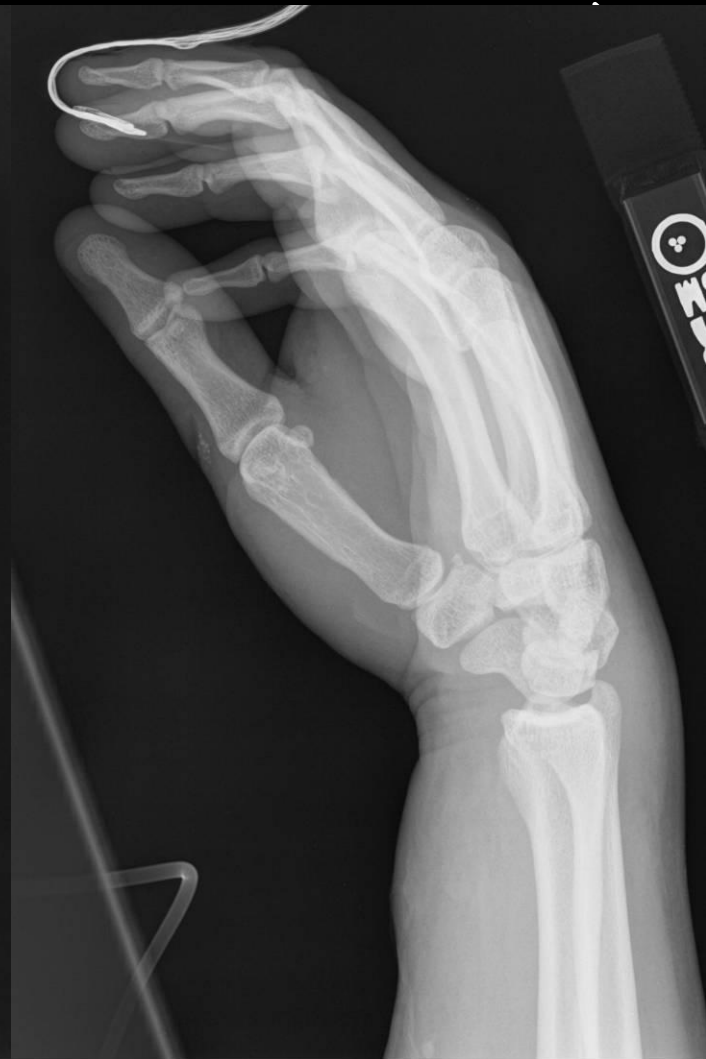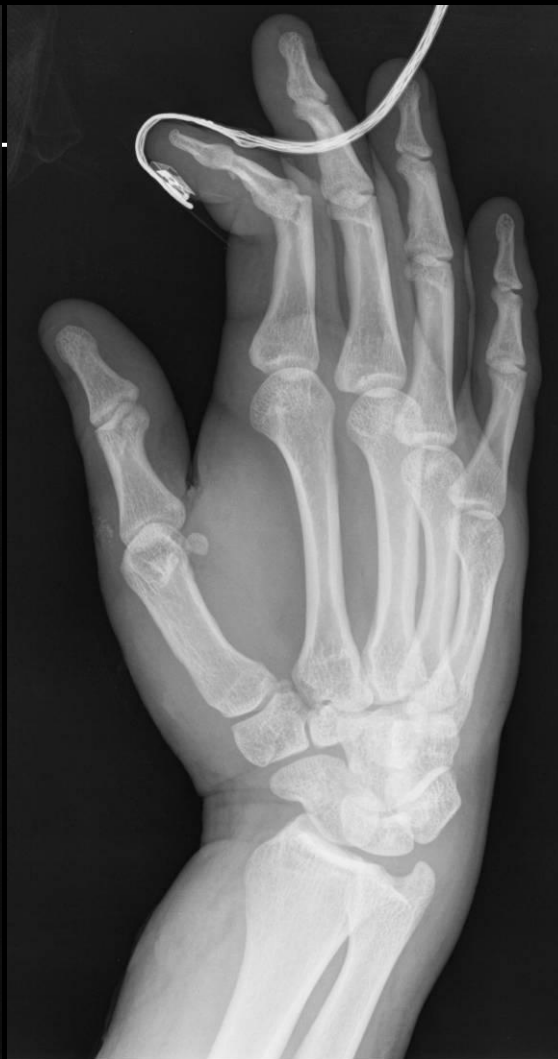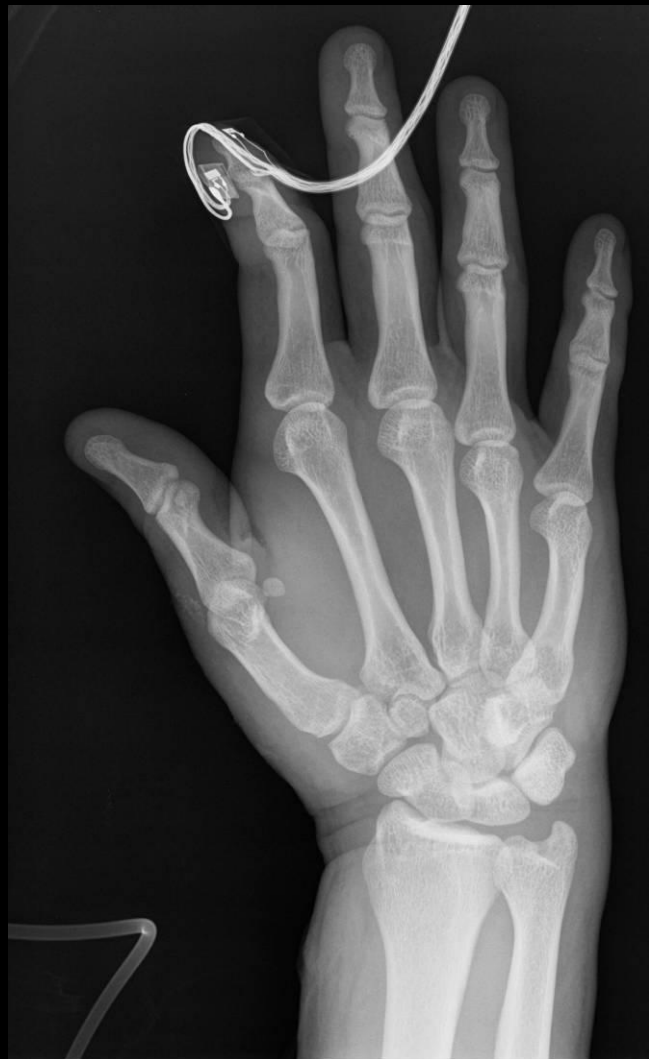# Radiocarpal CIND: ulnar translocation, type I

- Most common causes are rheumatoid arthritis and Medelung's deformity
- Traumatic dislocation is rare
- Iatrogenic (excessive resection of the radial styloid process or of the ulnar head)



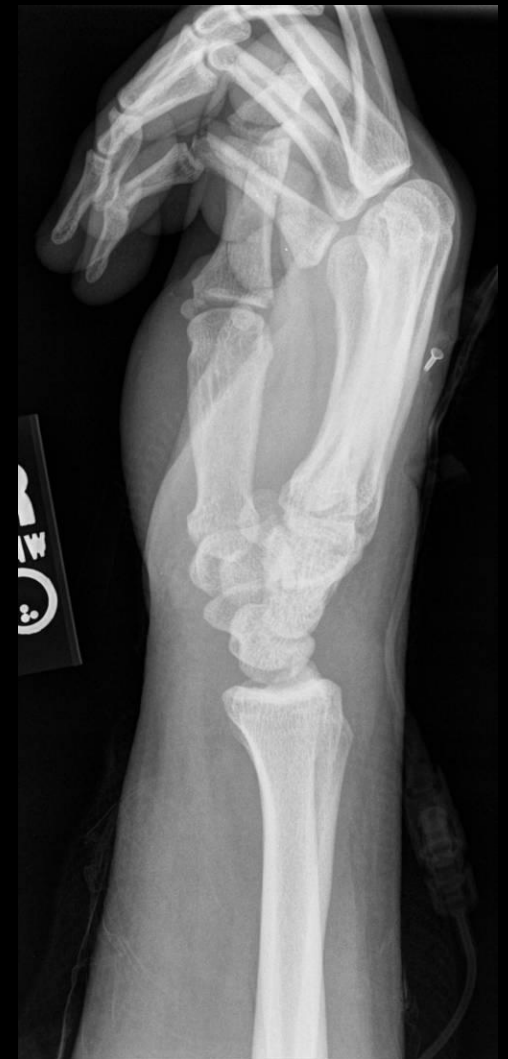
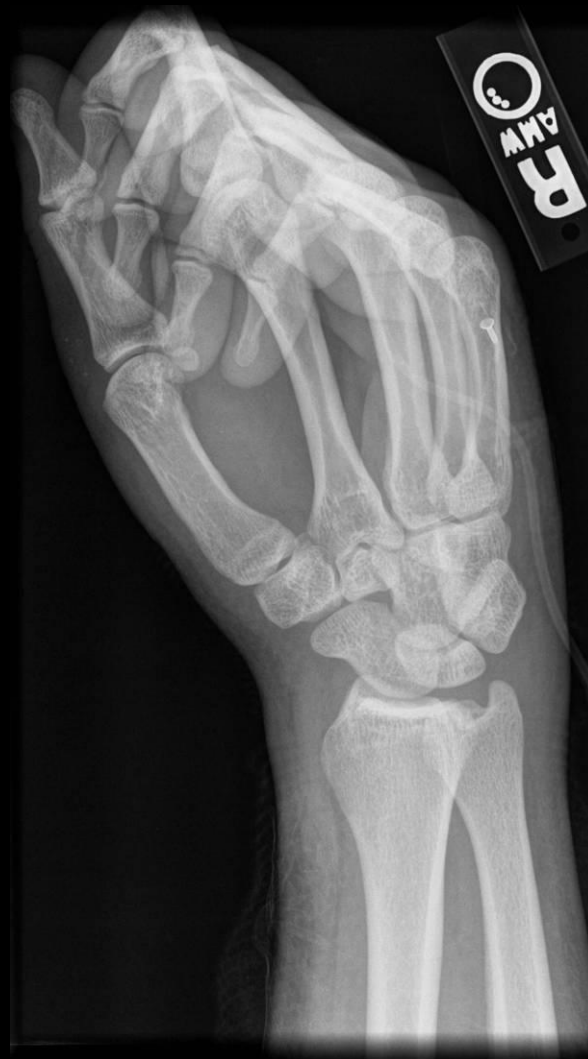
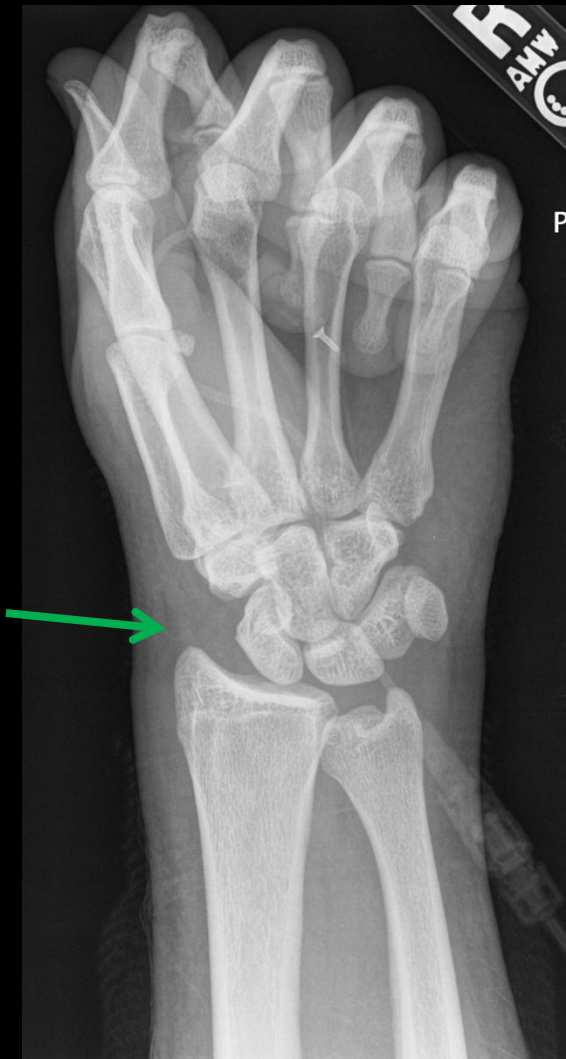Injur 23yo M s/p MVA with wrist pain,  
Injury films - no ulnar  
translocation initially

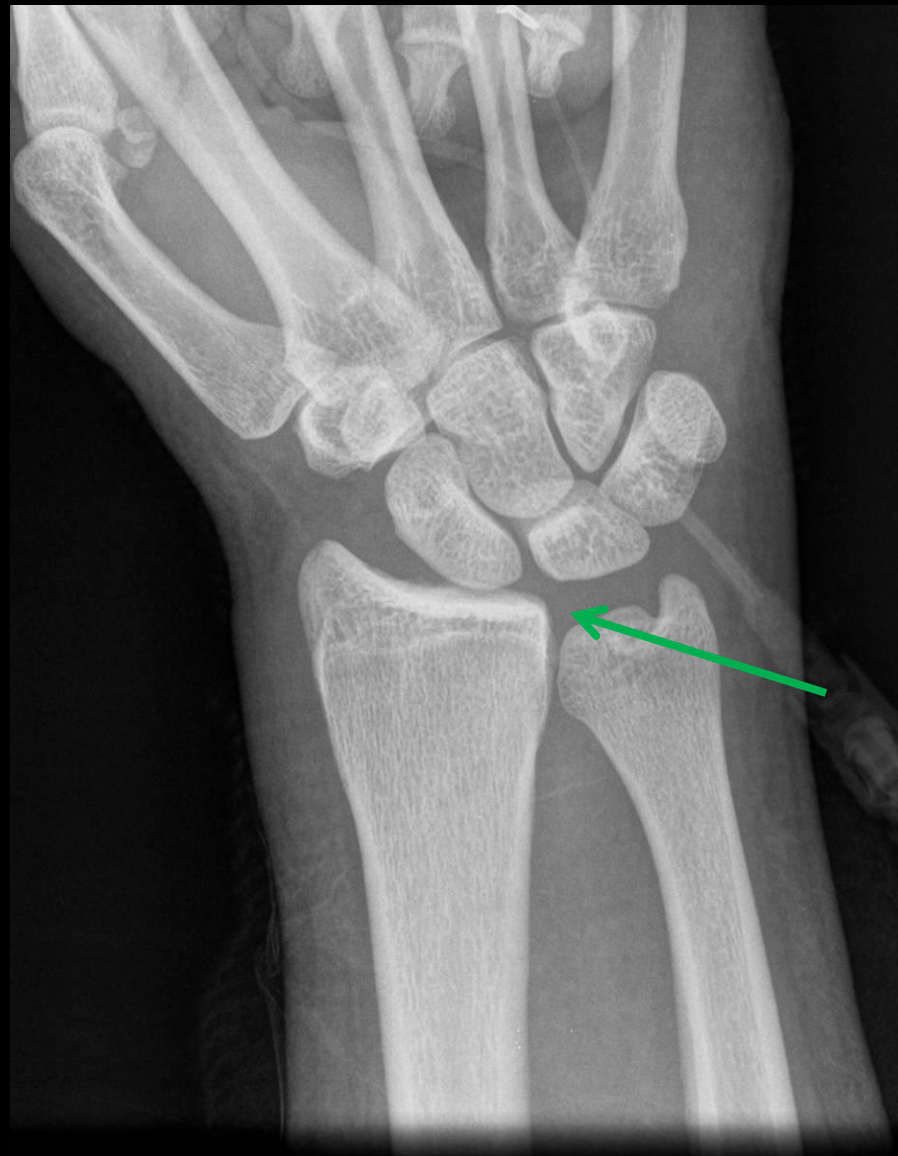
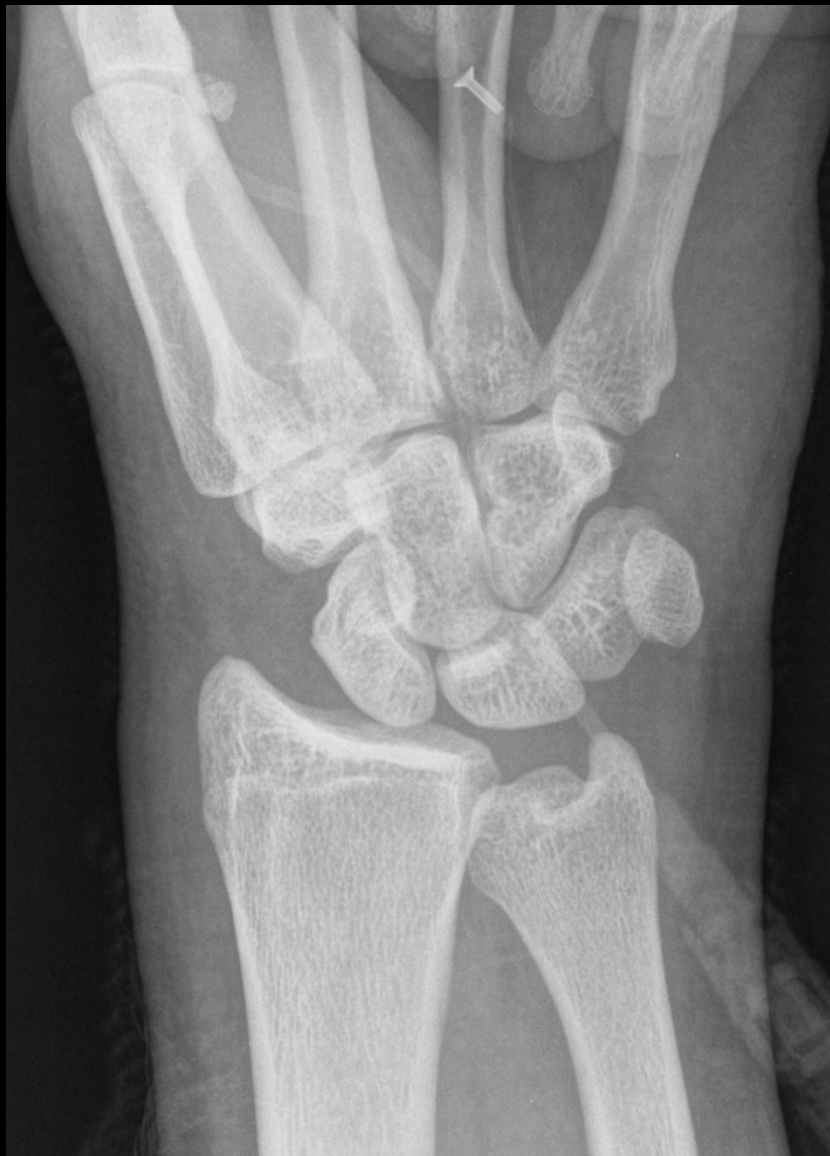


2 weeks later



2 weeks later

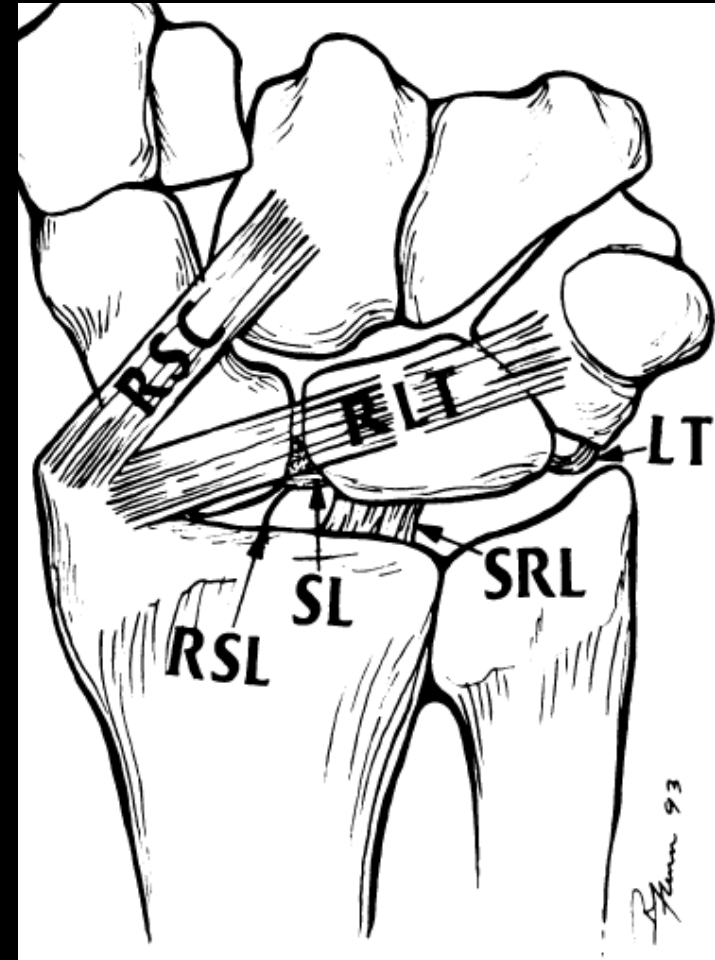


# Extrinsic ligament

- Major radiocarpal stabilizers:
  - Radioscaphocapitate
  - Radiolunotriquetral (aka-long radiolunate)
  - Short radiolunate
- All 3 are intracapsular and extrasynovial

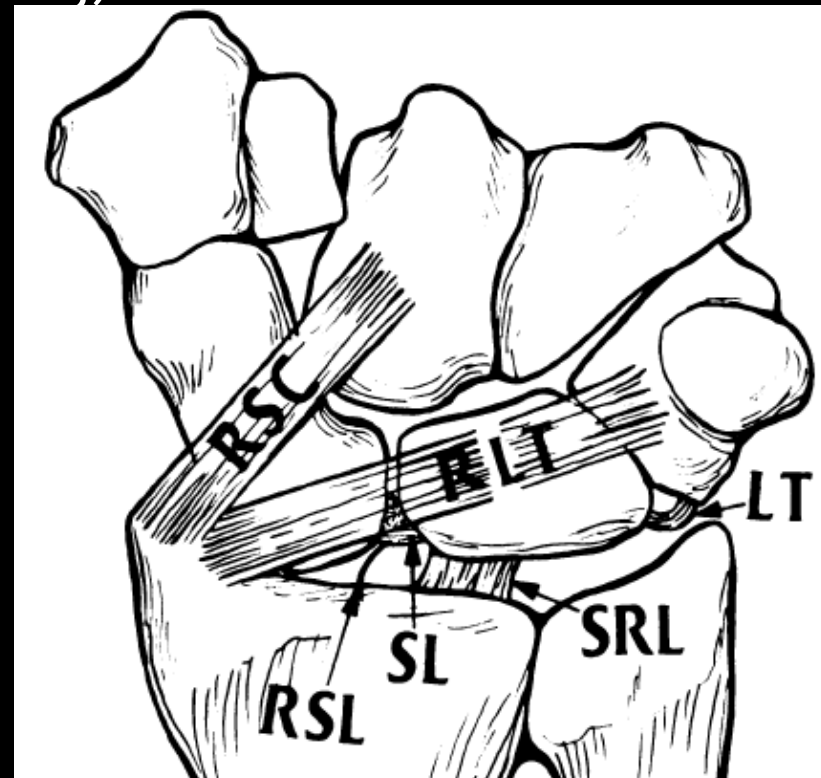
RLT is disrupted in Type II ulnar translocation

RSC and RLT disrupted in Type I ulnar translocation



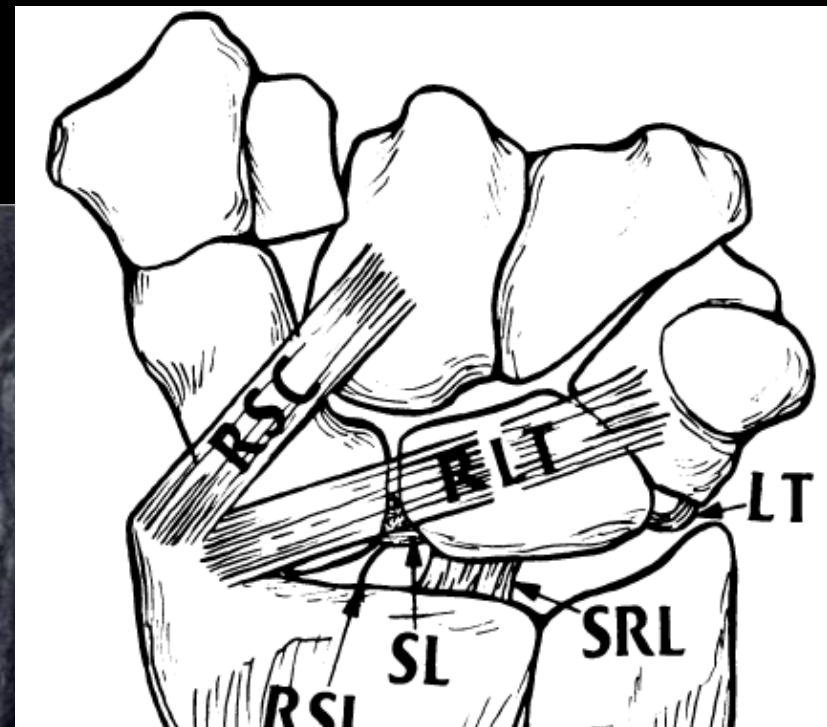
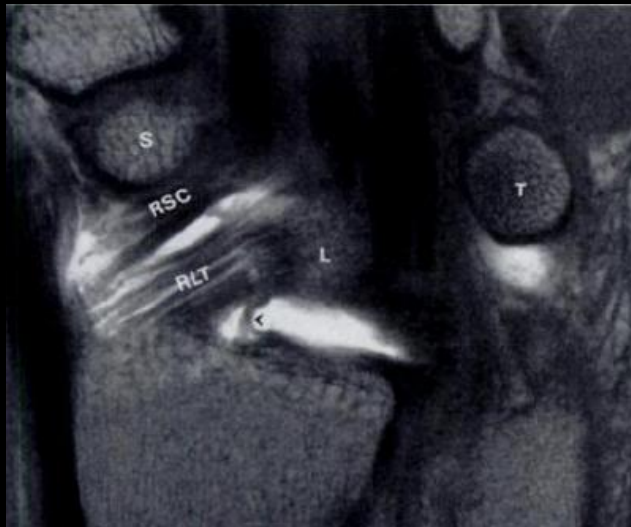# UT I: Extrinsic ligament

- Radioscaphocapitate (**RSC**) ligament
  - Courses from volar radial styloid over waist of scaphoid (without attaching) and attaches to center of capitate



# Extrinsic ligament

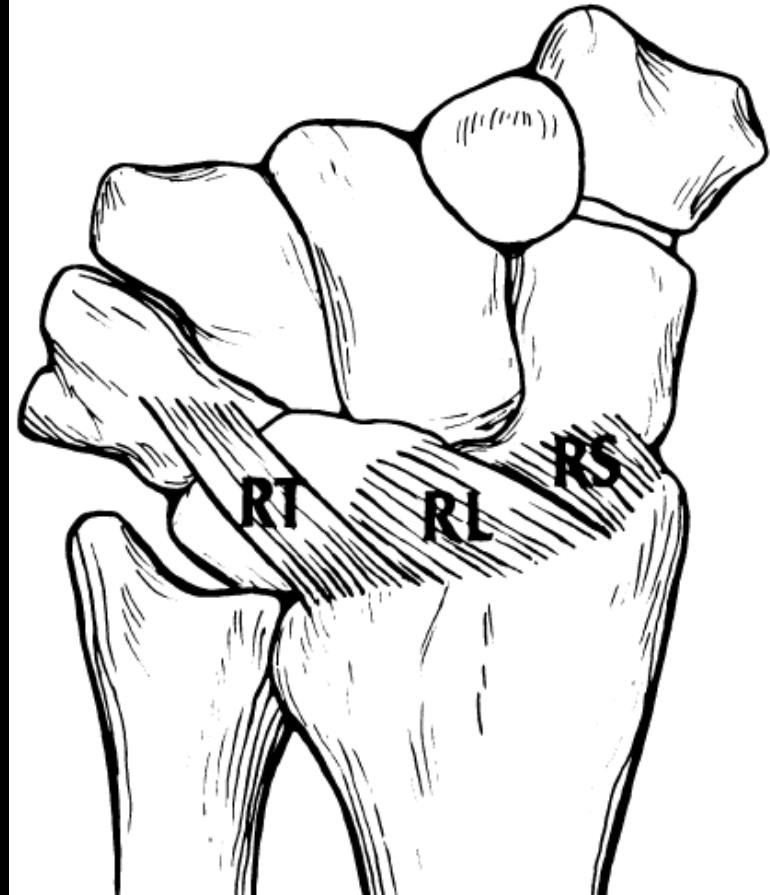
- Radiolunotriquetral (**RLT**) ligament
  - Largest ligament of the wrist
  - Courses from volar radial styloid to attach to the volar lunate and then the triquetrum





# Extrinsic ligament

- Dorsal Extrinsic Wrist Ligaments
  - Dorsal Radiocarpal Ligament
    - 3 parts:
      - Radioscaphoid
      - Radiolunate
      - Radiotriquetral



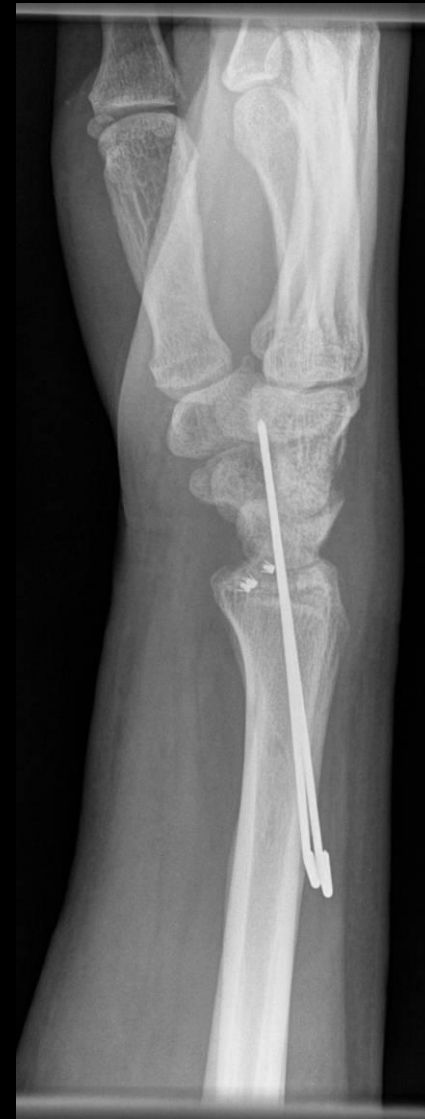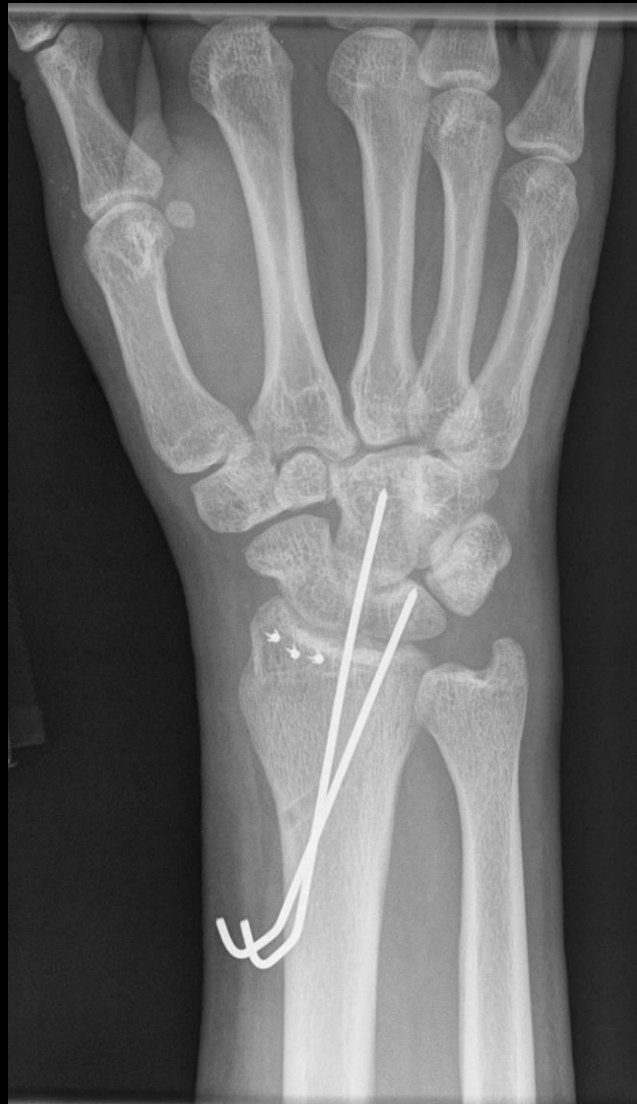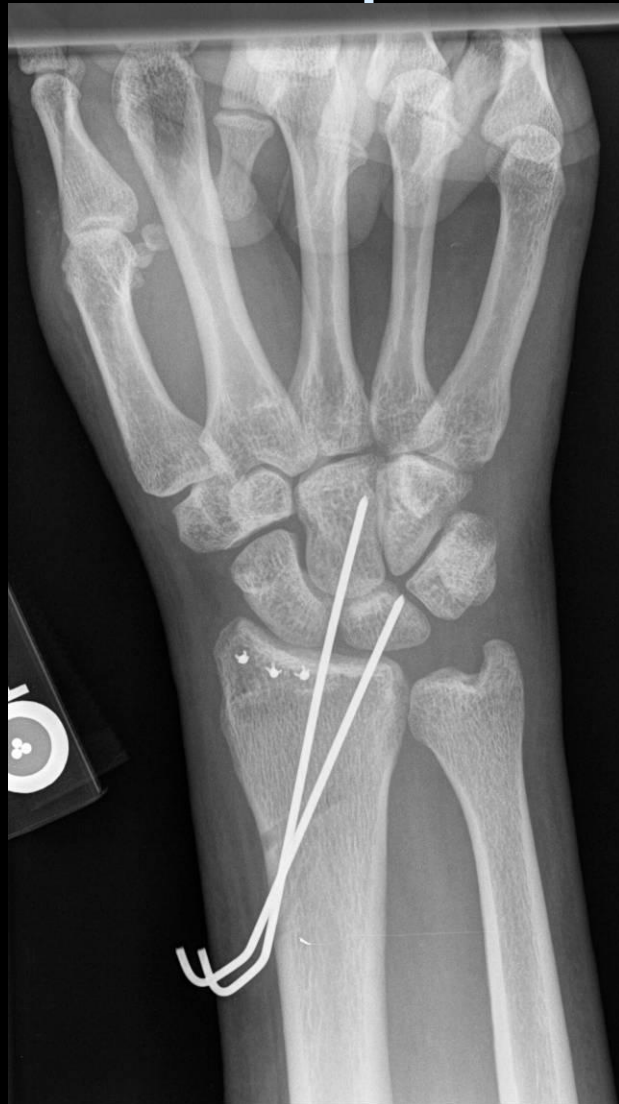# CIND: ulnar translocation

Treatment:

- Ligament reconstruction or radiocarpal arthrodesis

# CIND: ulnar translocation I

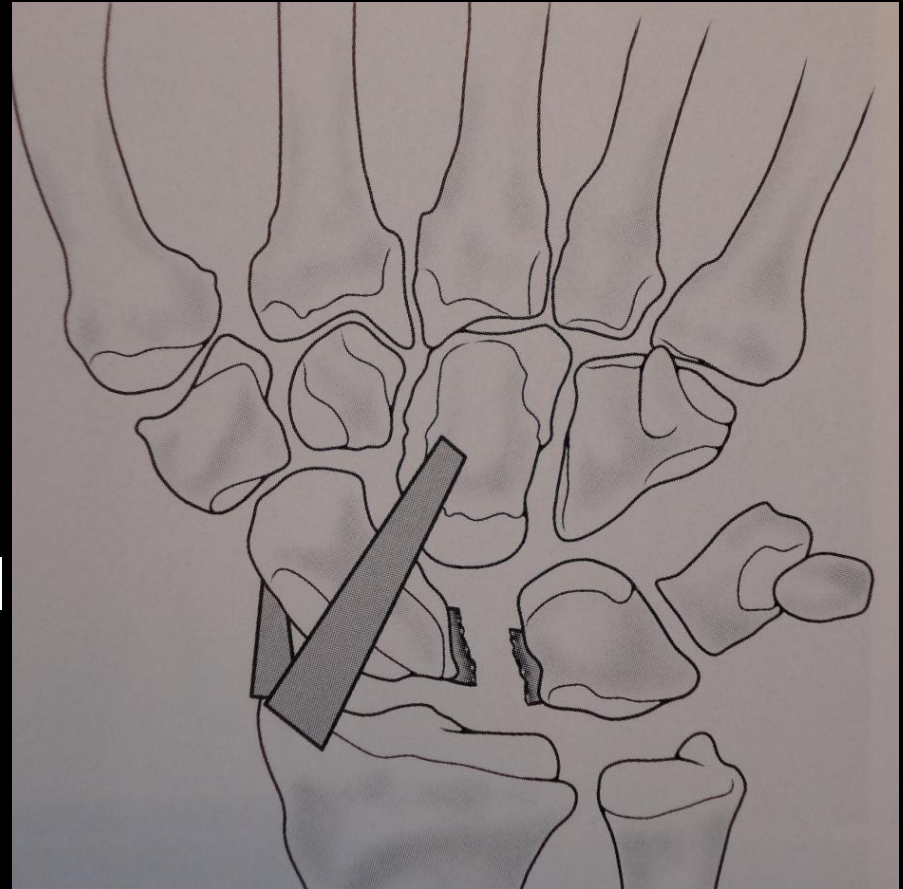
Post op





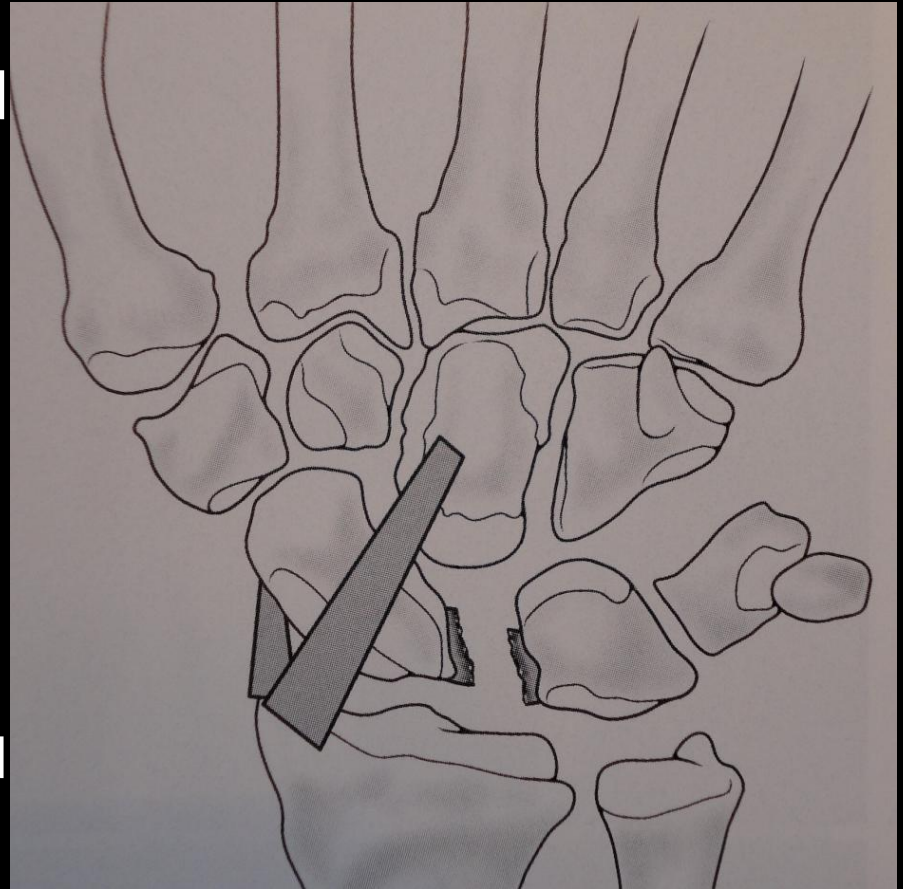
# CIND: ulnar translocation, type II

- Scaphoid remains in place, lunate and triquetrum slide in an ulnar direction
- SLL tear
- The radiolunotriquetral ligament (RLTL) is disrupted (not shown)



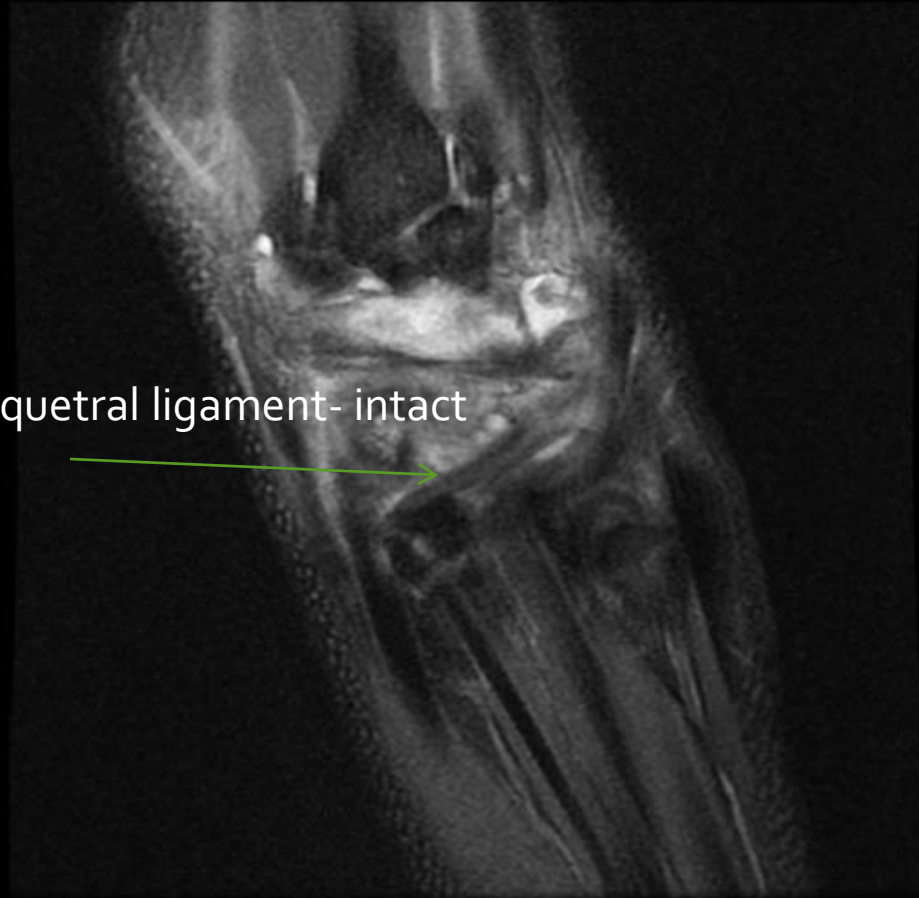
# CIND: ulnar translocation, type II

- Although this is classified as CIND, it has features of BOTH CIND and CID (and therefore could be classified as carpal instability complex (CIC))
  - $CIC = CIND + CID$
  - Aside : CIC includes perilunate dislocations and their sequelae



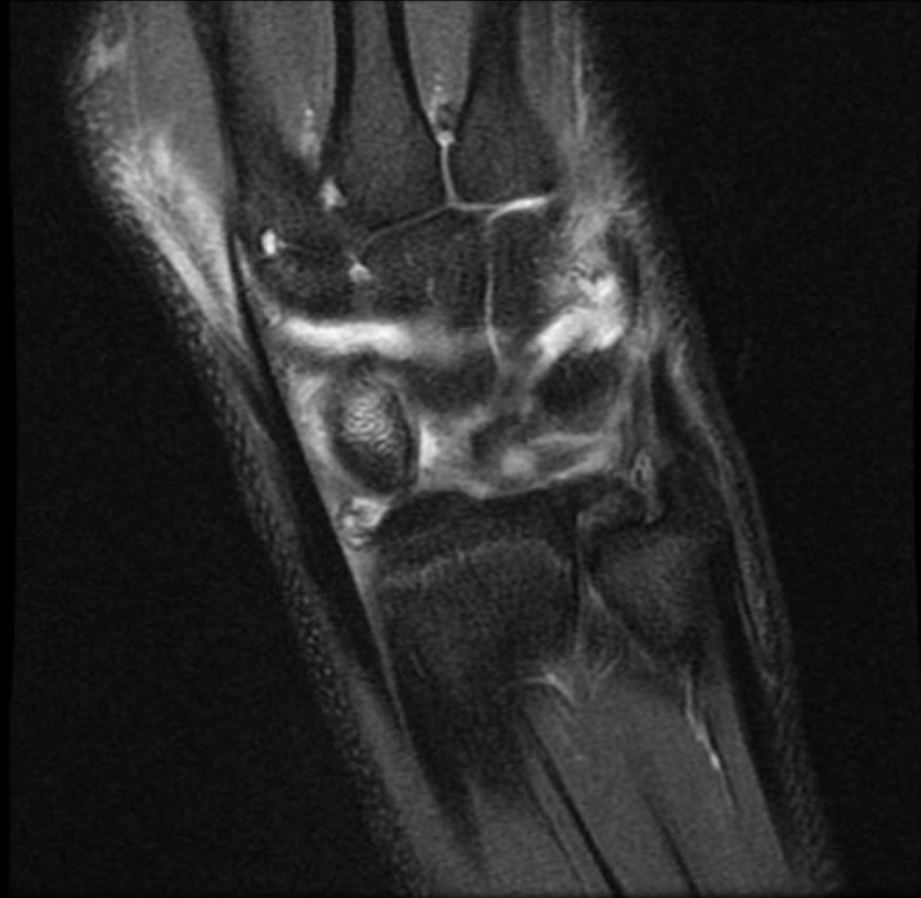
Tele case – no history

# CIND/CIC: ulnar translocation, type II

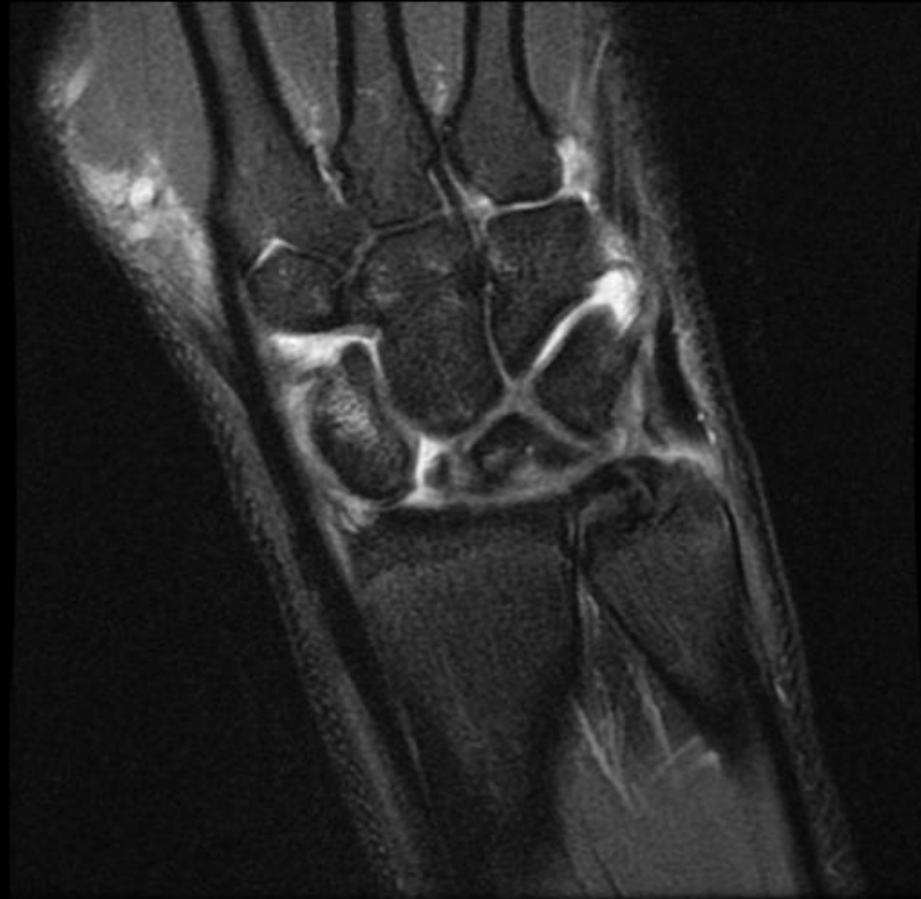

(extrinsic) Dorsal radiotriquetral ligament- intact

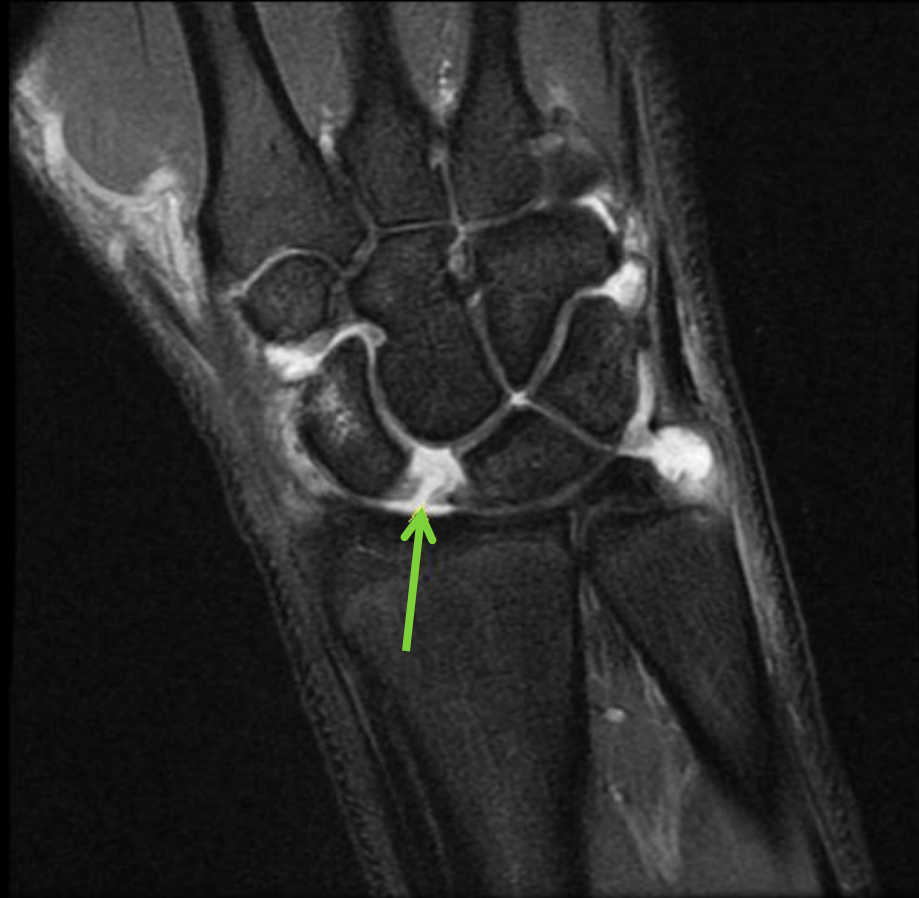
CIND/CIC: ulnar  
translocation, type II



CIND/CIC: ulnar  
translocation, type II

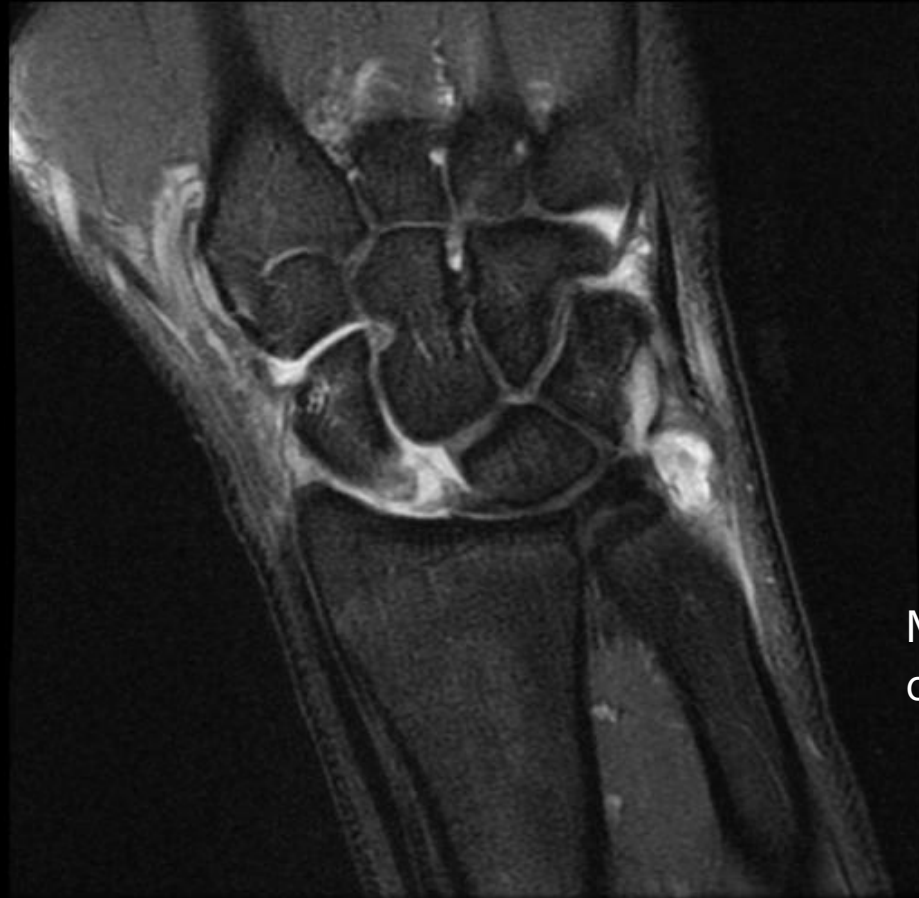

# CIND/CIC: ulnar translocation, type II



Torn SLL

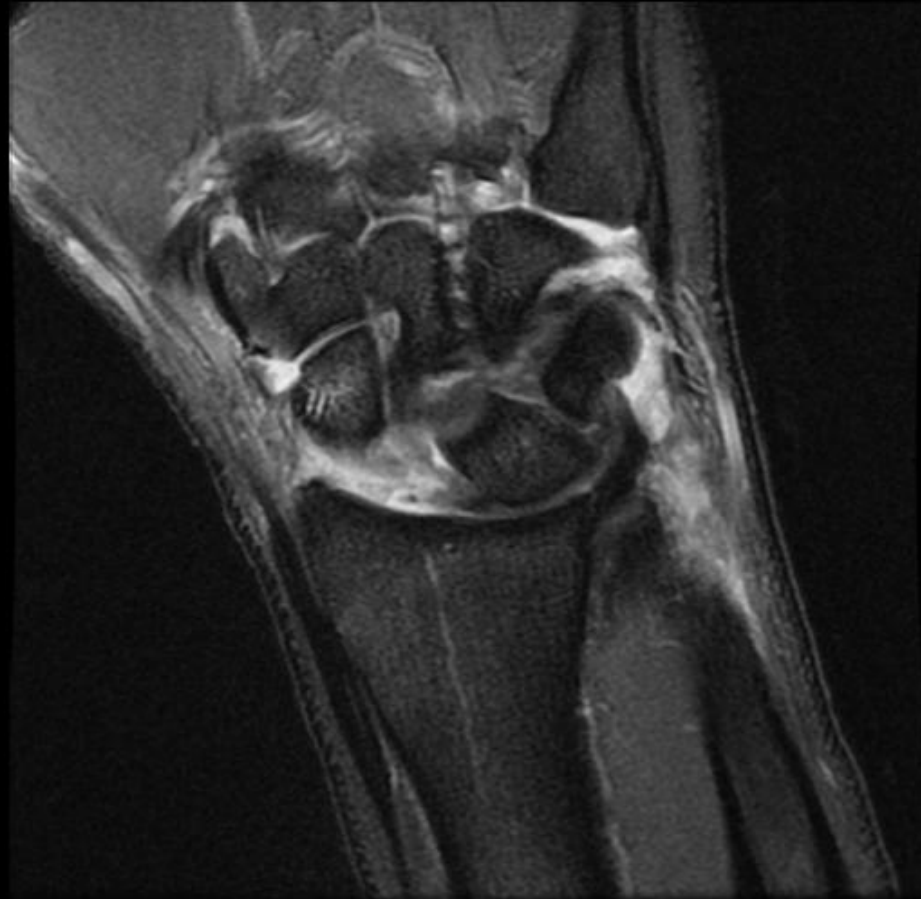# CIND/CIC: ulnar translocation, type II



Mild uncovering  
of the lunate

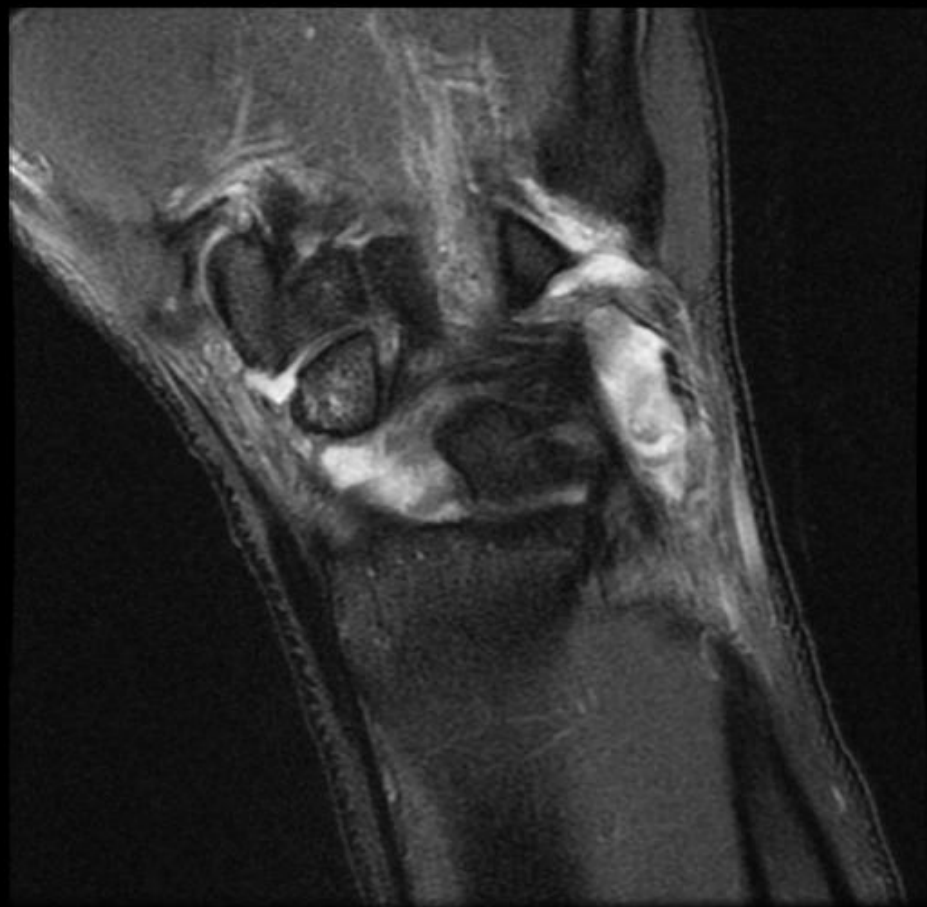


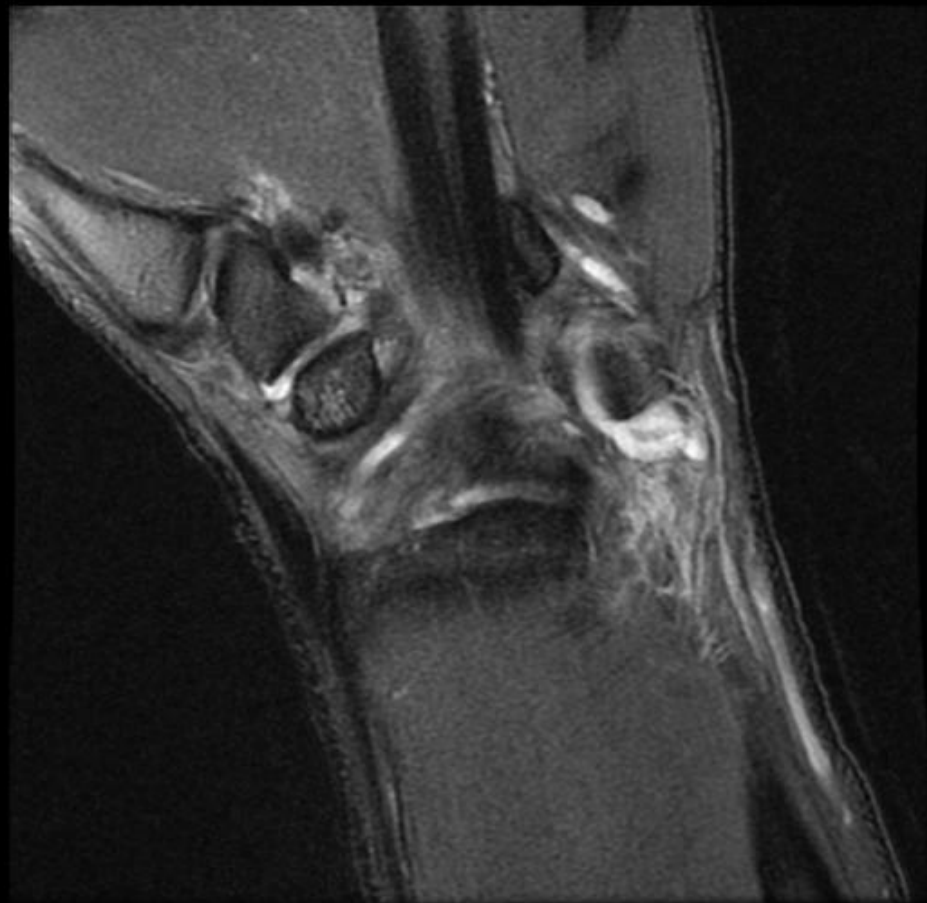CIND/CIC: ulnar  
translocation, type II

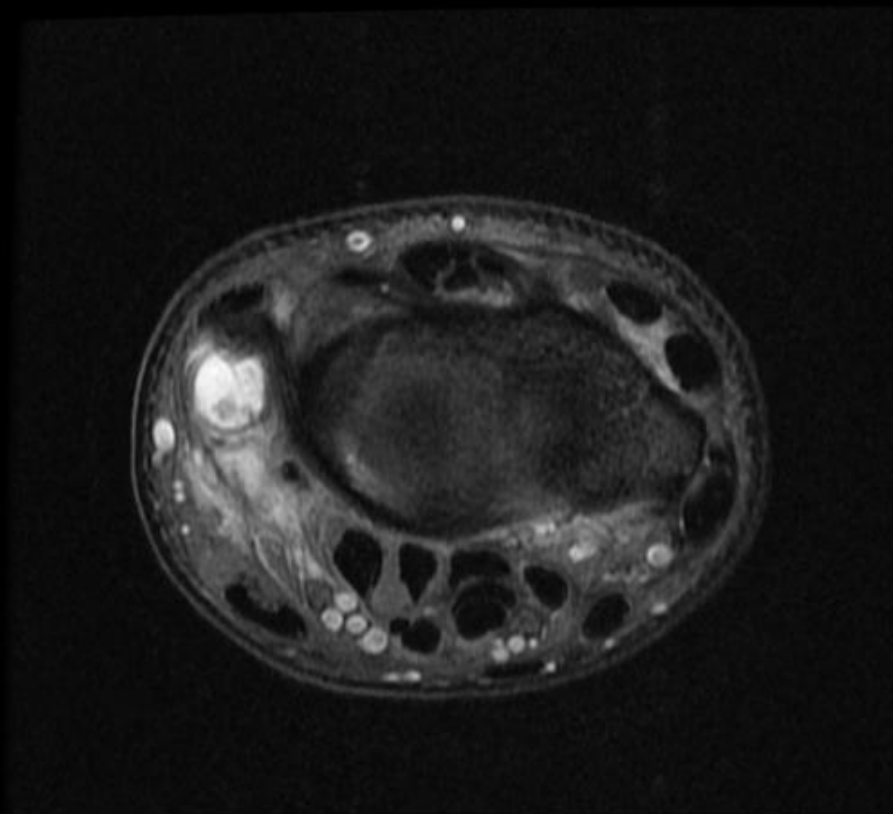


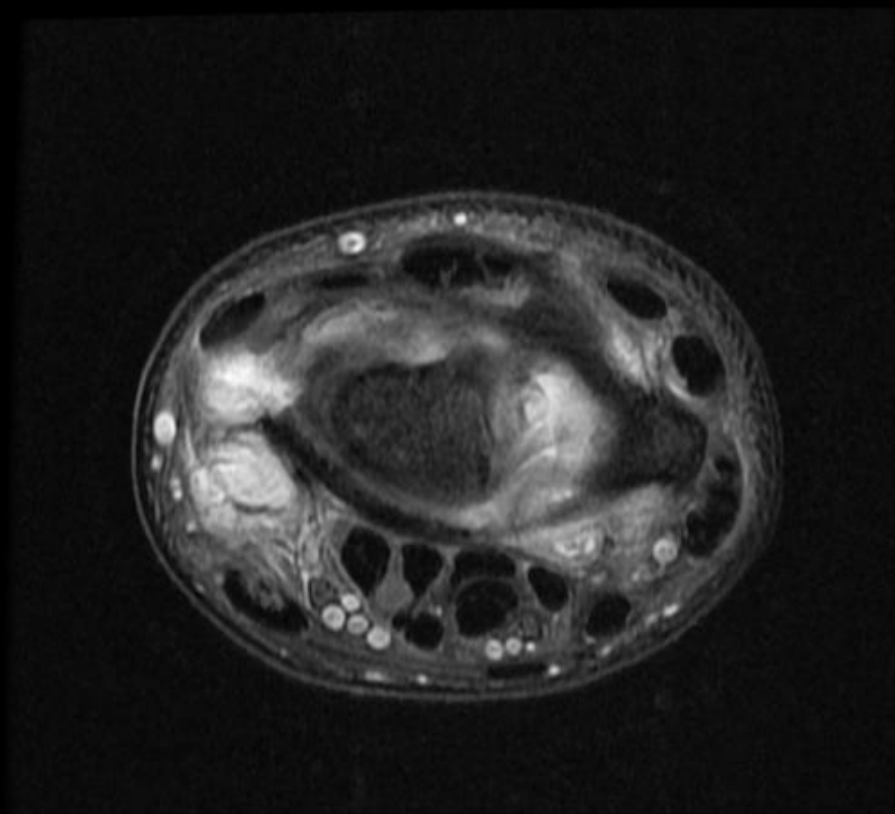
CIND/CIC: ulnar  
translocation, type II



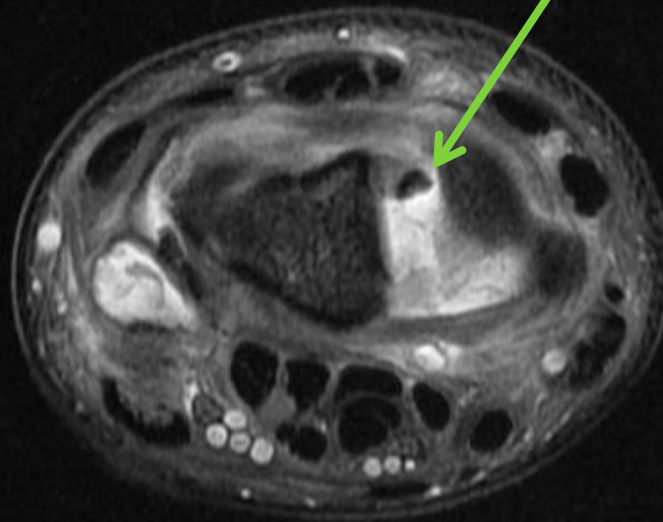


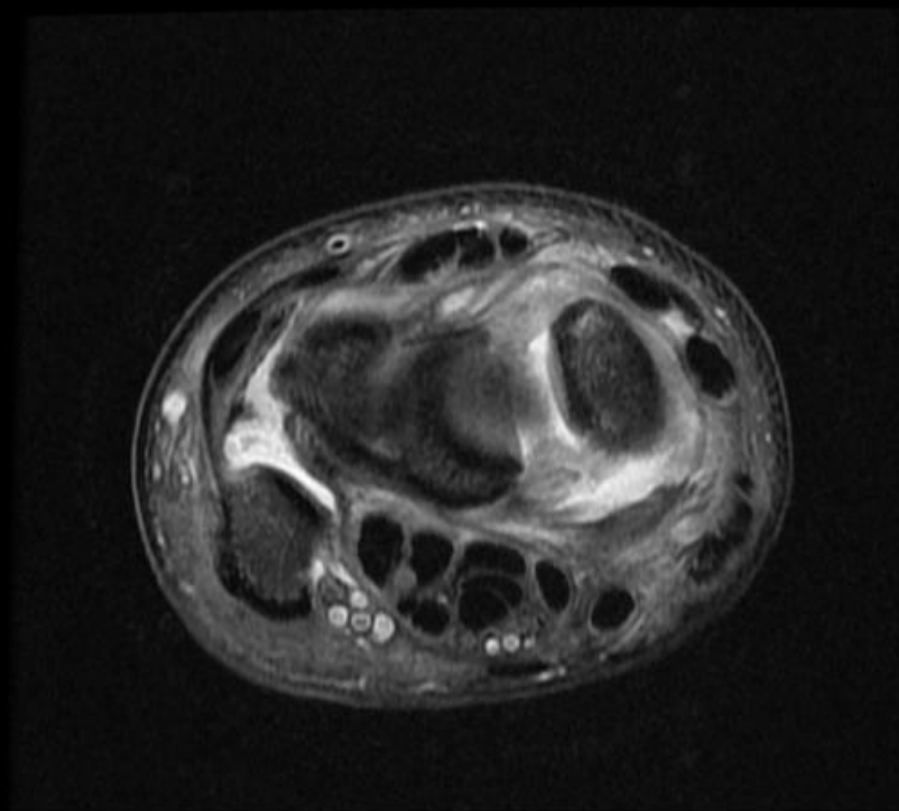






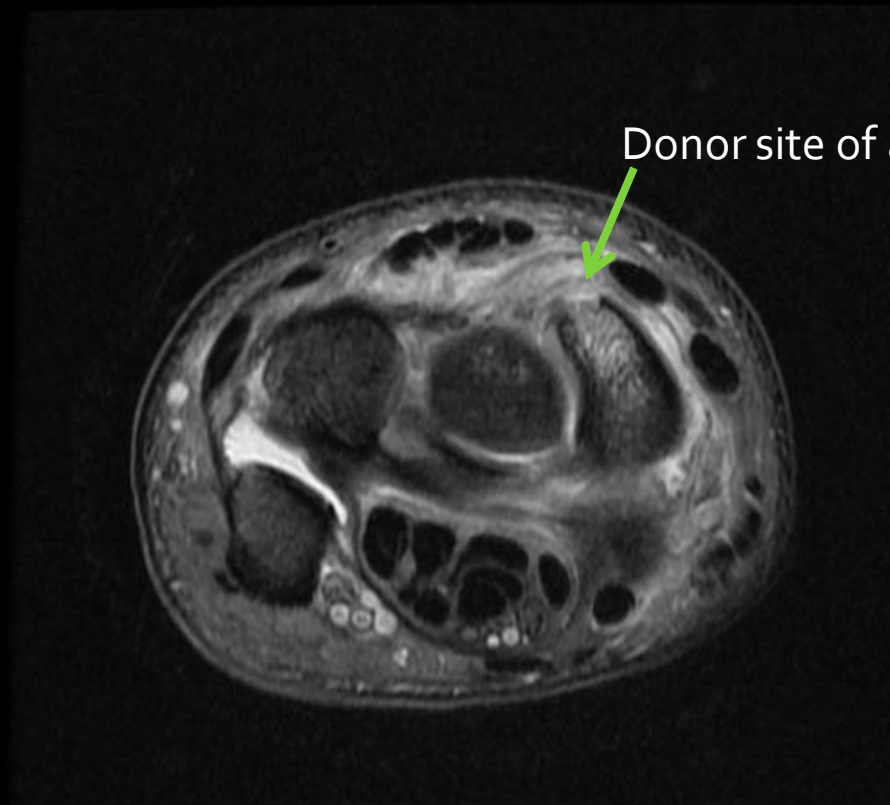
avulsion fragment of the scaphoid  
in the dorsal SLL (torn)



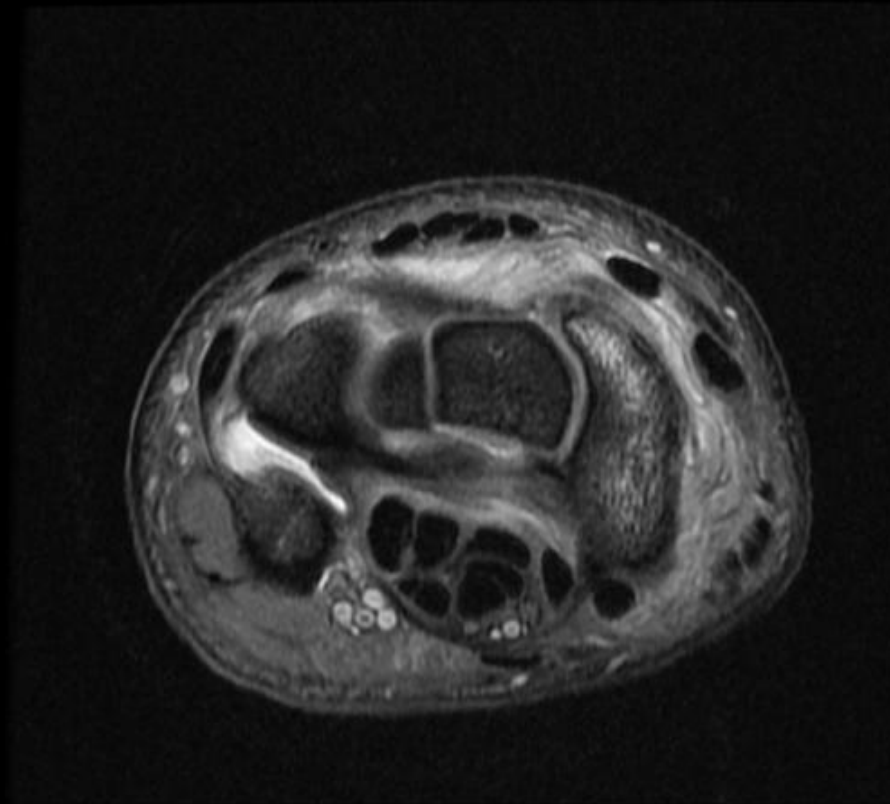




Dorsal scaphotriquetral ligament is torn

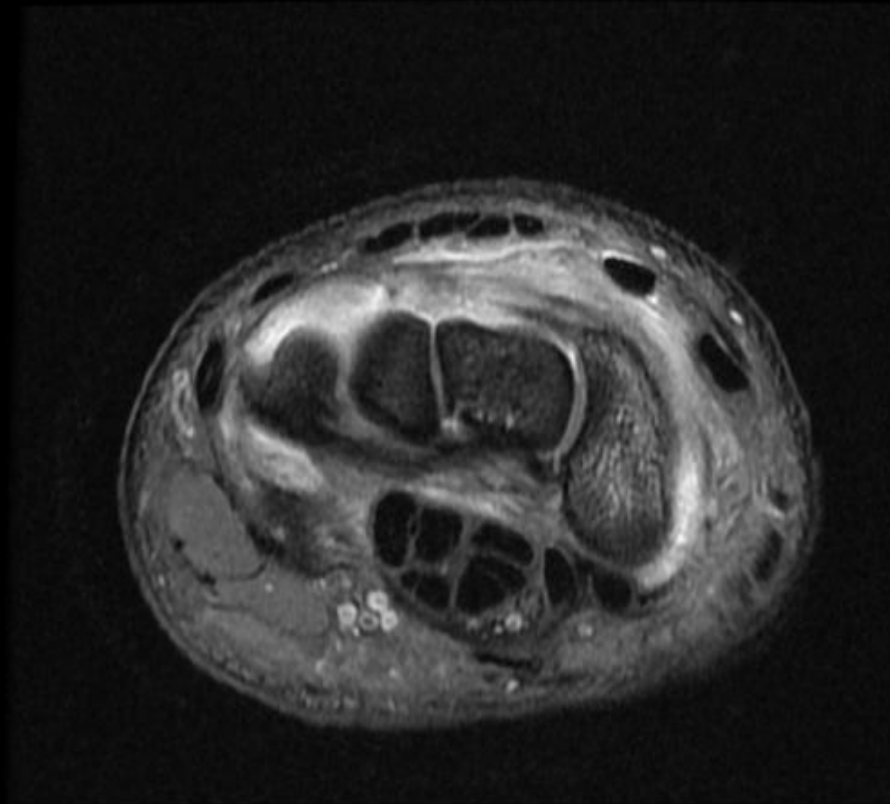


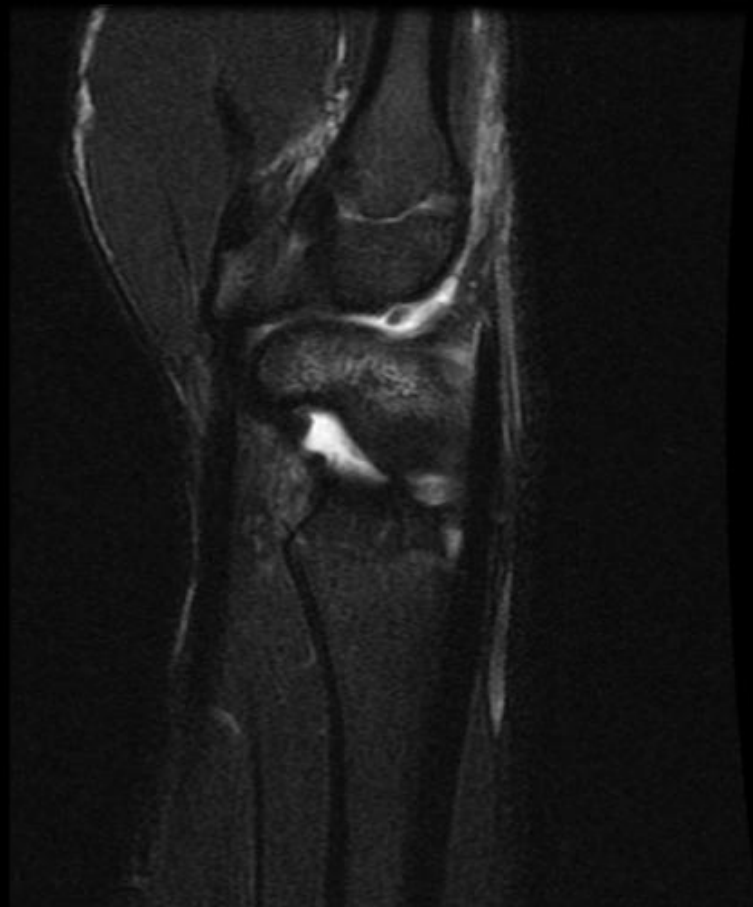## Dorsal scaphotriquetral ligament

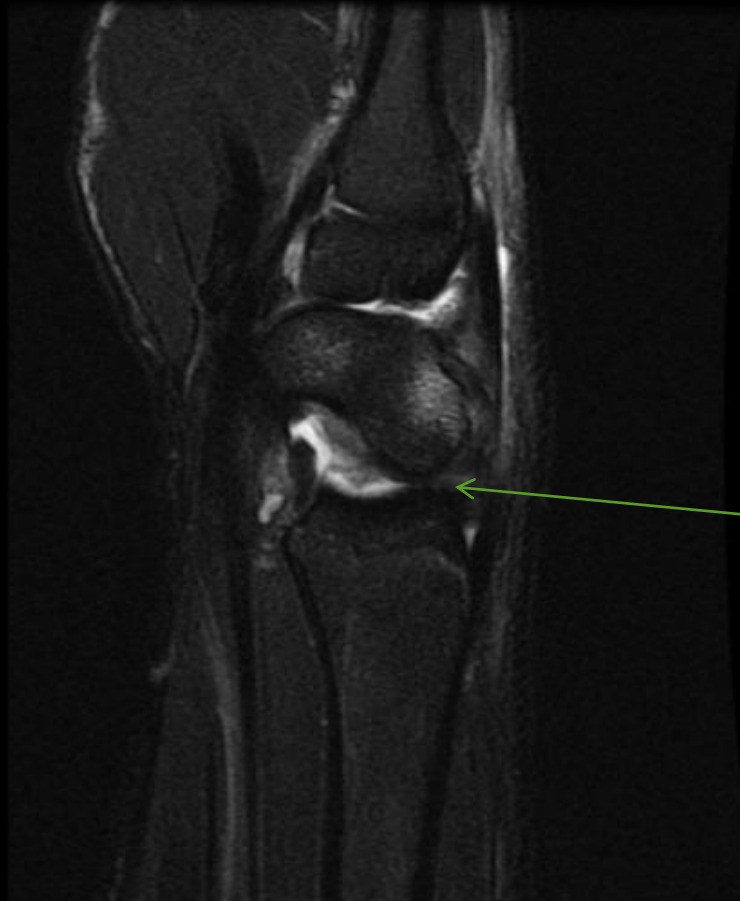


# ulnar translocation, type II

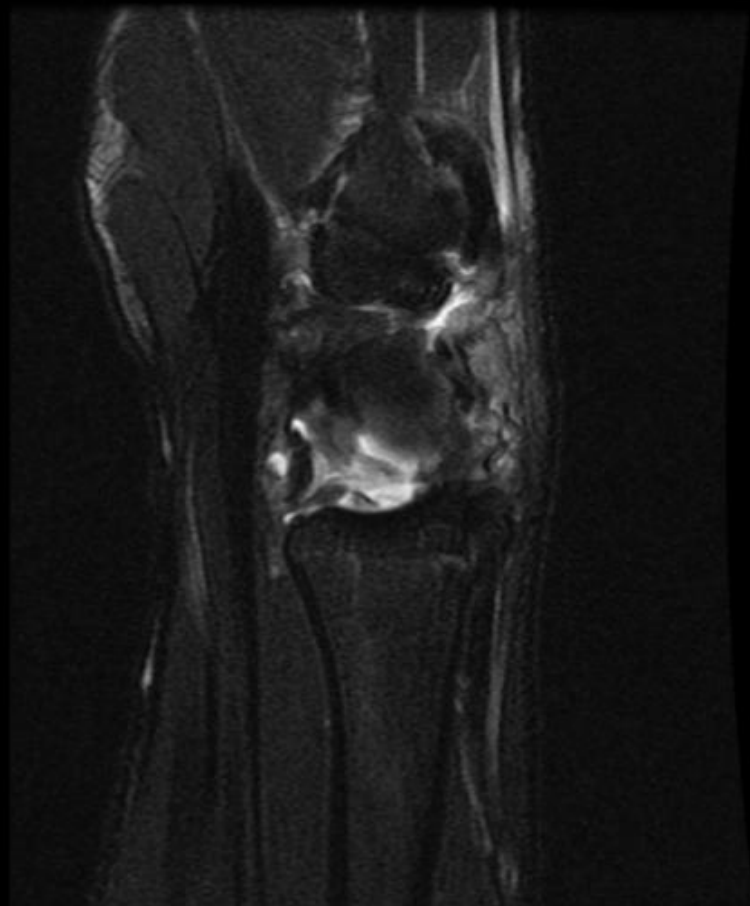
Dorsal scaphotriquetral ligament

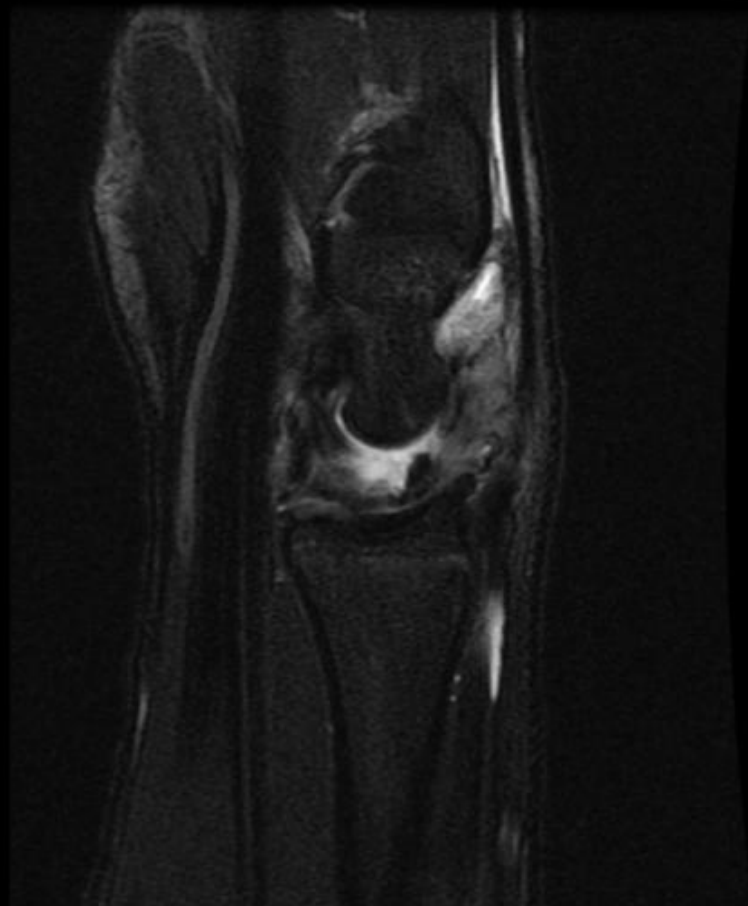


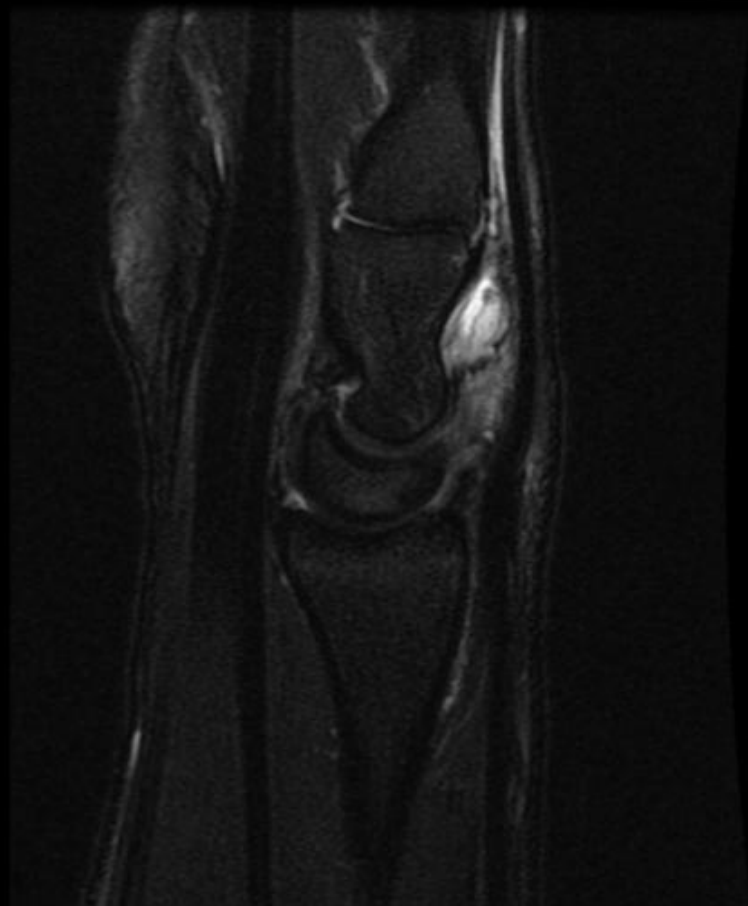




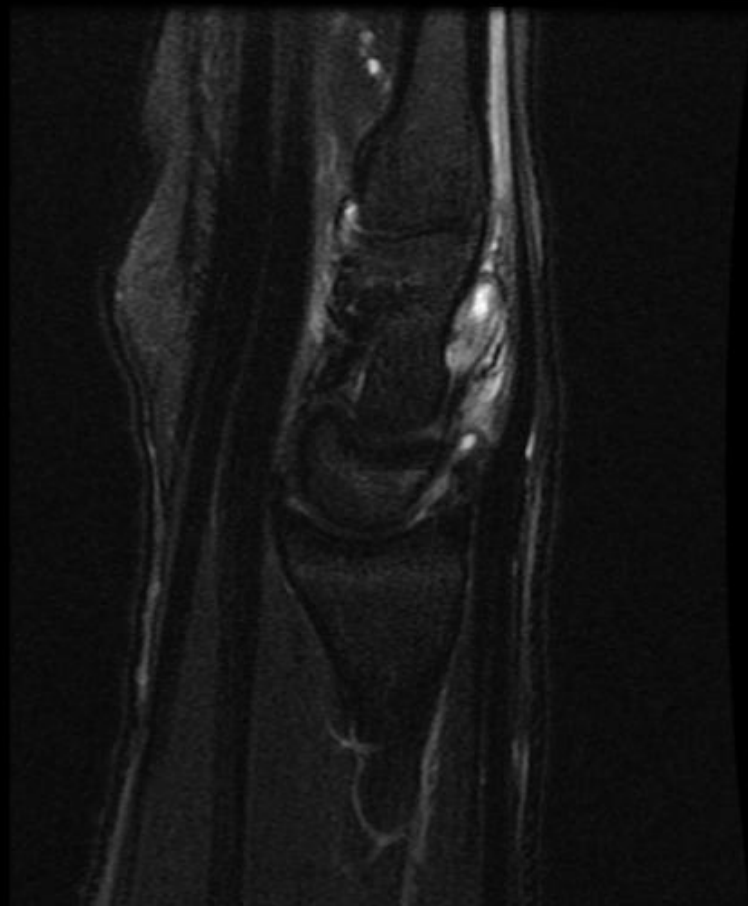
Dorsal subluxation  
of scaphoid

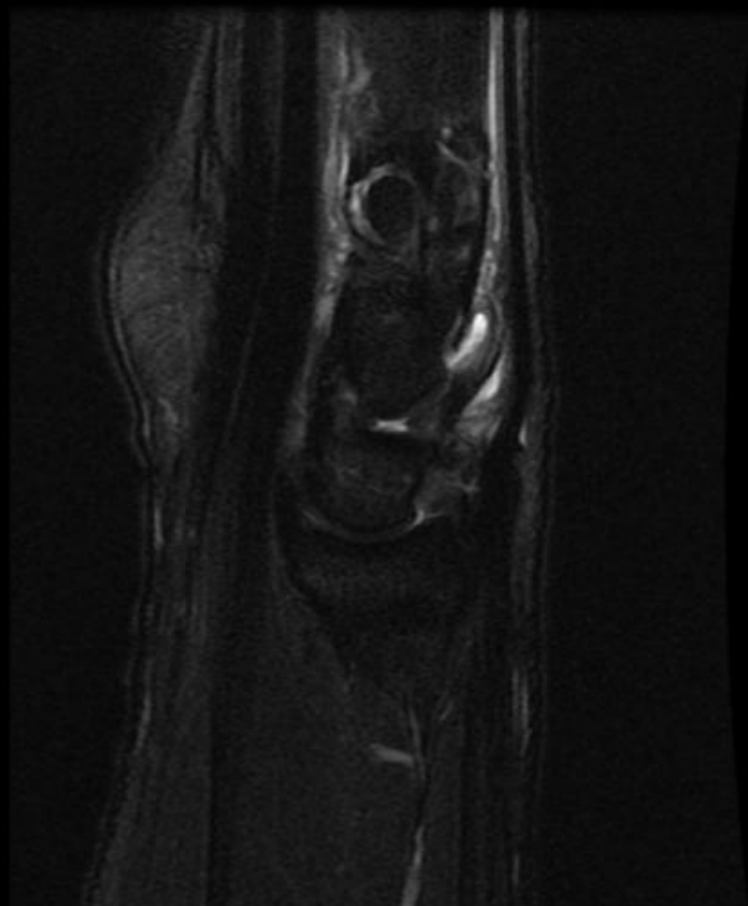










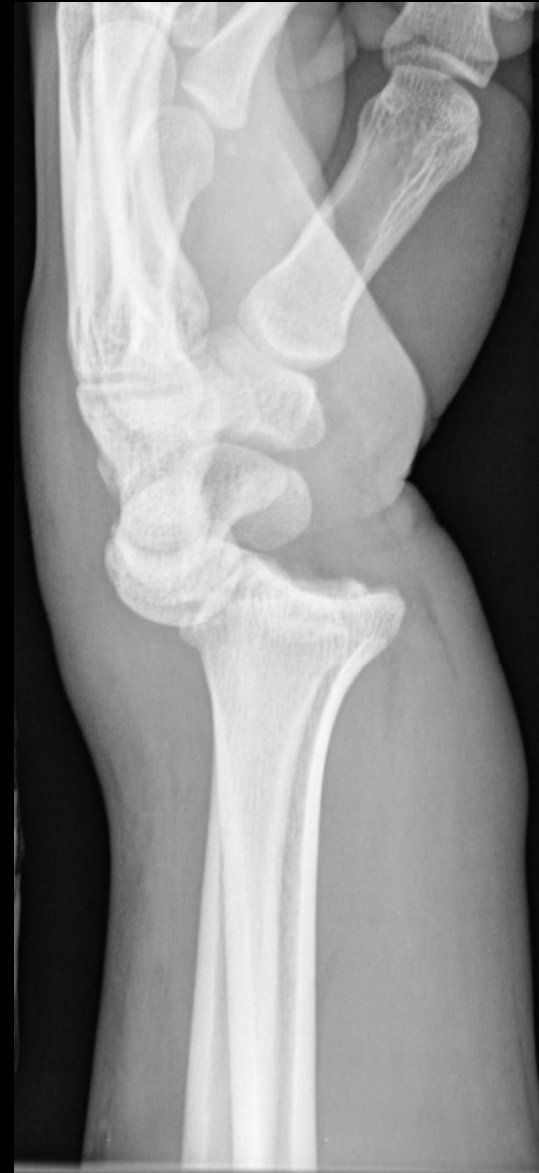

# Summary of Findings:

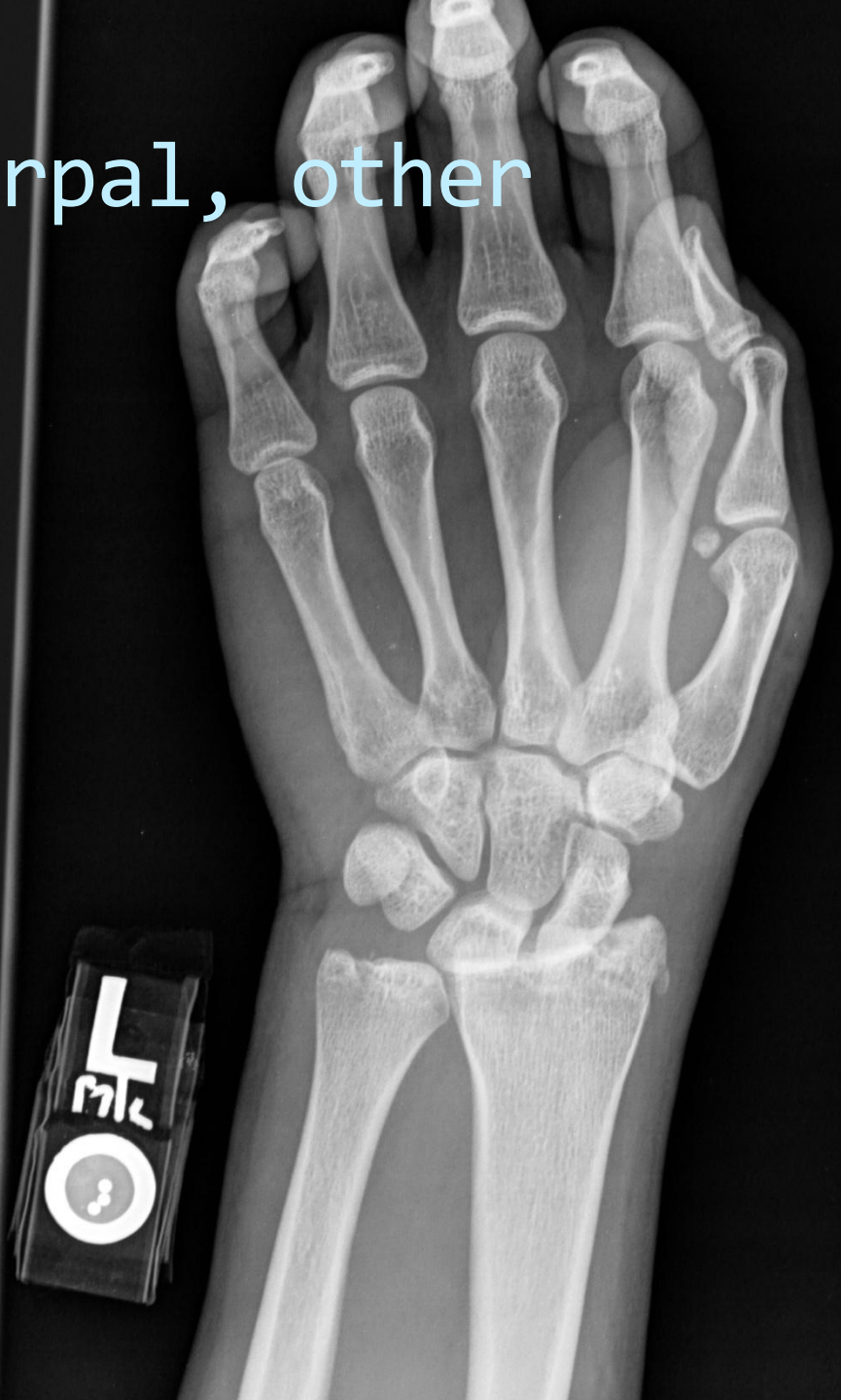- Complete tear of the SLIL with scaphoid avulsion fragment
- Marked widening of the scapholunate interosseous space
- ulnar translocation of the lunate and triquetrum at the radiocarpal joint (radiocarpal instability)
- Dorsal subluxation of the scaphoid with respect to the distal radius
- Lunate is mildly dorsally tilted

# CIND: radiocarpal, other

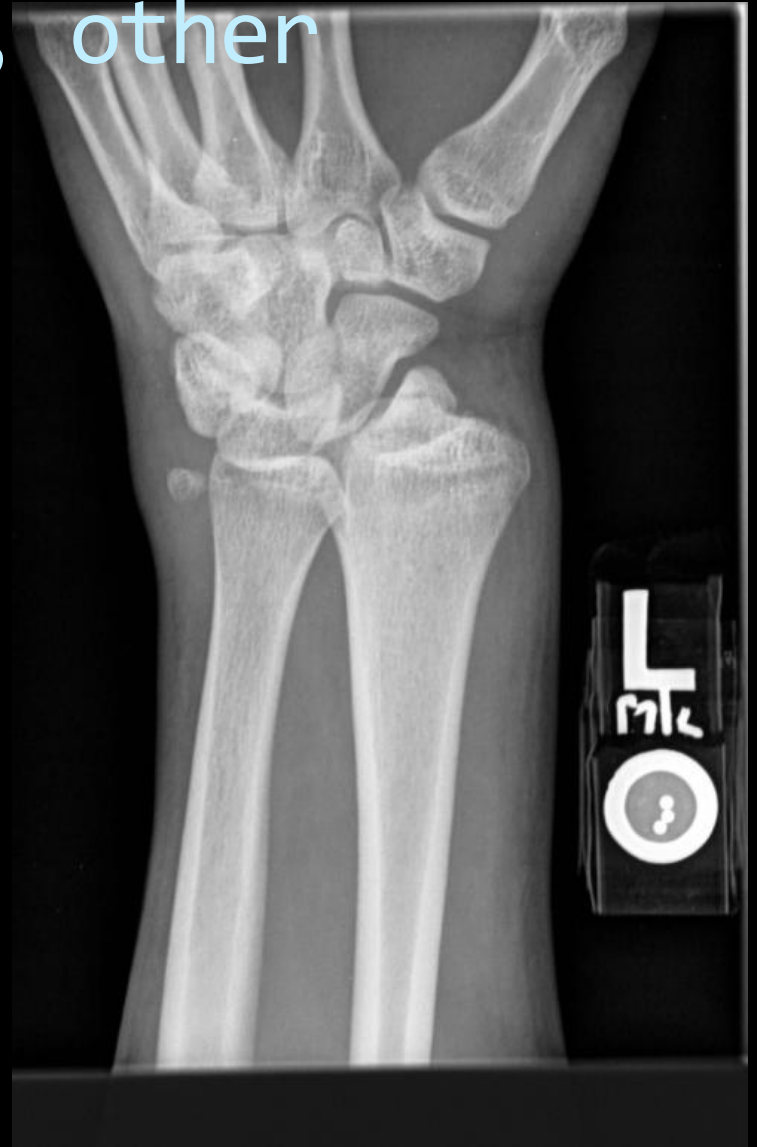- Other patterns are rare
- Volar
- dorsal
- Those associated with displaced or badly malunited fx's of the distal radius.
- Ex. Dorsal tilt of distal radius → extension of the entire proximal row.
  - The distal row shifts into flexion to compensate
  - A kind of caral instability complex (CIA)



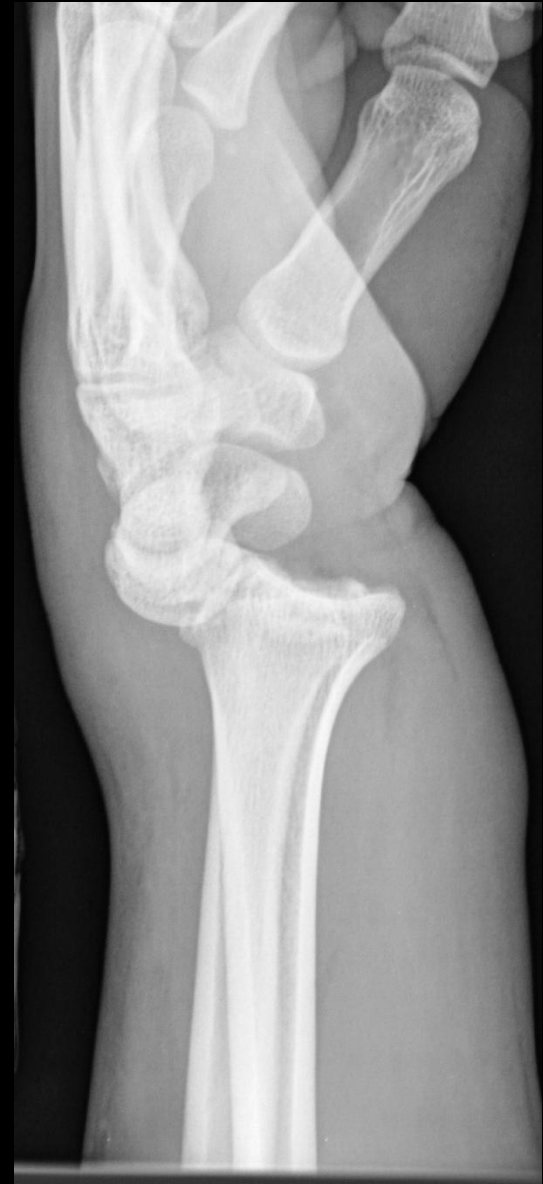CIND: radiocarpal, other



CIND: radiocarpal, other



CIND: radiocarpal, other



CIND: radiocarpal, other





CIND: radiocarpal, other



# Association between Extrinsic and Intrinsic Carpal Ligament Injuries at MR Arthrography and Carpal Instability at Radiography: Initial Observations

[Expand](#)

Nicolas H. Theumann, MD, Ghazal Etehami, MD, Bertrand Duvoisin, MD, Max Wintermark, MD, Pierre Schnyder, MD, Nicolas Favarger, MD and Louis A. Gilula, MD

+ Author Affiliations

Address correspondence to N.H.T. (e-mail: [Nicolas.Theumann@chuv.ch](mailto:Nicolas.Theumann@chuv.ch)).

[« Previous](#) | [Next Article »](#)  
[Table of Contents](#)

## This Article

Published online before print  
 January 19, 2006, doi:  
 10.1148/radiol.2383050013  
 March 2006 Radiology, 238,  
 950-957.

[Abstract](#) Free  
[Figures Only](#)  
[» Full Text](#)  
[Full Text \(PDF\)](#)

- [Classifications](#)

Original Research  
[Musculoskeletal  
 Imaging](#)

- [Services](#)

## Purpose:

To retrospectively compare the presence or absence of carpal instability on radiographs with the findings of magnetic resonance (MR) arthrographic evaluation of intrinsic and extrinsic ligament tears in patients with chronic wrist pain.

## Materials and Methods:

The institutional review board approved this study and did not require informed consent. Signs of carpal instability were assessed on static and dynamic radiographs of the wrist obtained in 72 patients (24 female, 48 male; mean age, 36 years; age range, 14–59 years) with posttraumatic wrist pain. MR arthrography was subsequently performed. Two musculoskeletal radiologists independently analyzed the radiographs and MR images. Each intrinsic and extrinsic ligament was individually evaluated for the presence of a ligament tear. The extent of the tear also was recorded. Interobserver agreement regarding MR arthrographic findings was tested by calculating  $\kappa$  statistics. Statistical comparison between radiography and MR arthrography was performed by using the Fisher exact test.

## Results:

Twenty-five triangular fibrocartilage complex, 18 (five partial, 13 complete) scapholunate ligament, and 25 (10 partial, 15 complete) lunotriquetral ligament tears were visualized. Twenty-two (all complete) extrinsic ligament tears were detected: two radial collateral ligament, 10 radioscaphocapitate ligament, and 10 radiolunotriquetral ligament tears. Interobserver agreement regarding intrinsic and extrinsic ligament tear detection at MR arthrography was excellent ( $\kappa = 0.80$ ). Nineteen patients had evidence of carpal instability on radiographs. Fourteen (52%) of 27 patients with at least one complete intrinsic lesion had no sign of carpal instability. On the other hand, the association of scapholunate ligament and/or lunotriquetral ligament and extrinsic ligament tears was significantly correlated ( $P < .001$ ) with carpal instability at radiography.

## Conclusion:

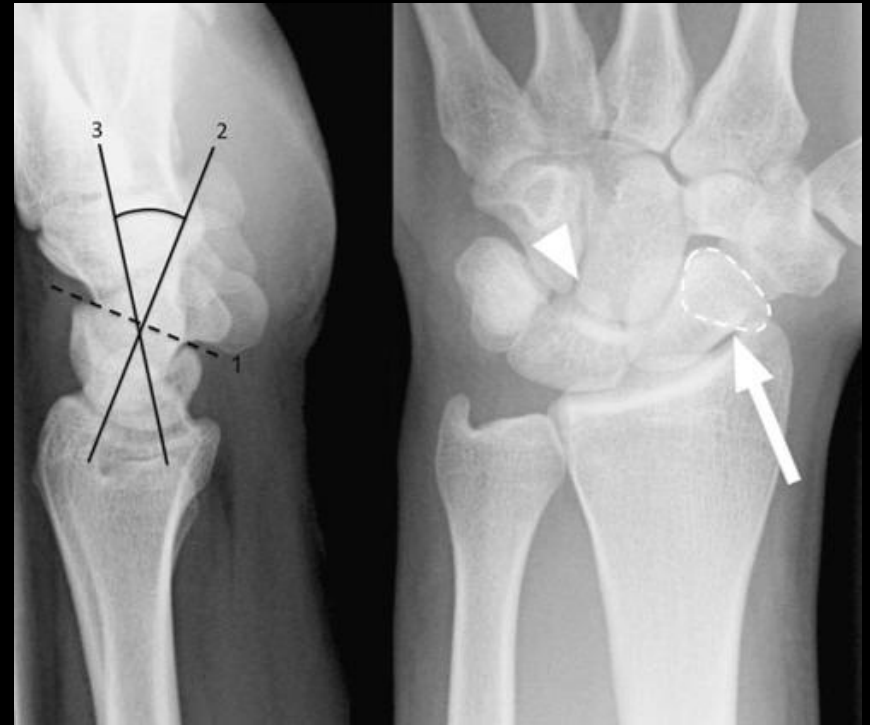
The presence or absence of carpal instability on radiographs depends on the association between intrinsic and extrinsic ligament tears—even partial ones—rather than on the presence of intrinsic ligament tears alone, even when the tears are complete.

# Patterns of Carpal Instability

- Dissociative (CID)
  - Scapholunate dissociation
  - Lunotriquetral dissociation
  - Scaphoid fractures that are unstable, ununited, or malunited
  - Kienbock's disease
- Non-dissociative (CIND)
  - Radiocarpal
  - Midcarpal
- Complex carpal instability (CIC)
  - Perilunate dislocations
- Adaptive carpal instability (CIA)

# CIND: midcarpal instability (MCI)

- MCI is a group of conditions that is a source of ongoing debate in terms of its etiology, terminology, classification, and treatment.
- Instability of the proximal carpal row with both radiocarpal and midcarpal joint alterations are characteristic

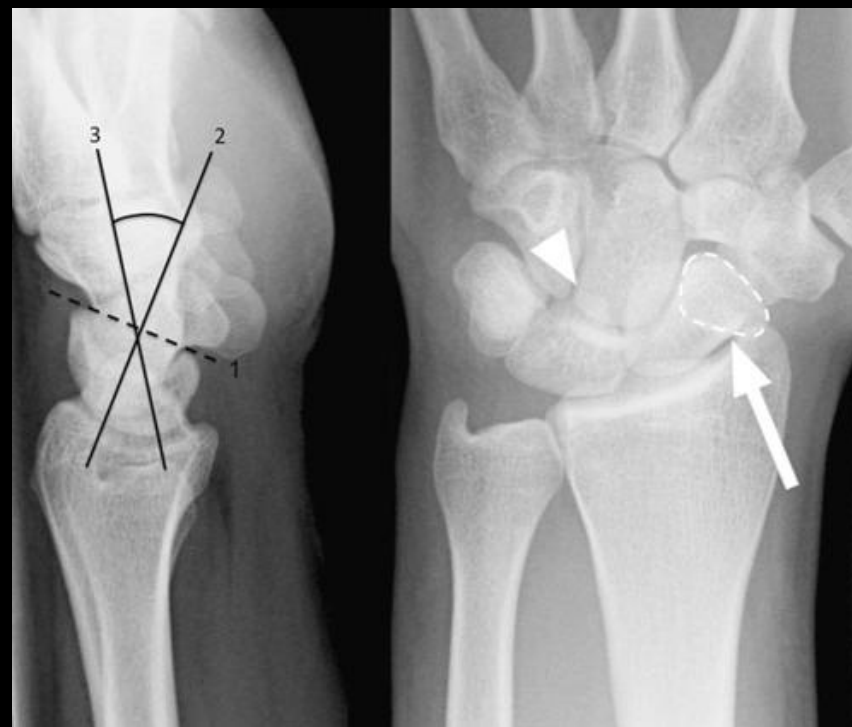


Andoni et al. Skeletal Radiol. May14,2010.

# CIND: midcarpal instability (MCI)

Major ligaments involved:

- Triquetro-hamate-capitate



Andoni et al. Skeletal Radiol. May14,2010.

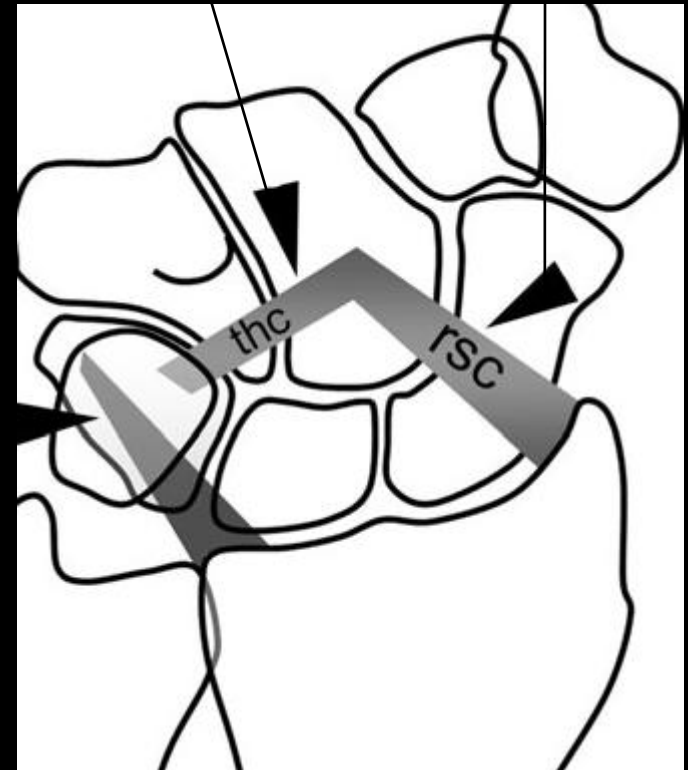
# Main extrinsic ligaments involved MCI

Ex vivo and in vivo evidence shows that deficiency of these 2 ligaments results in Palmar MCI- Andoni et al.

- Anteromedial scaphocapitate and scaphotrapeziotrapezoid (STT) ligaments have a role too.
- The palmar ligaments are demonstrated at the front of this “transparent” diagram

Dorsal radiotriquetral ligament

Palmar arcuate ligament

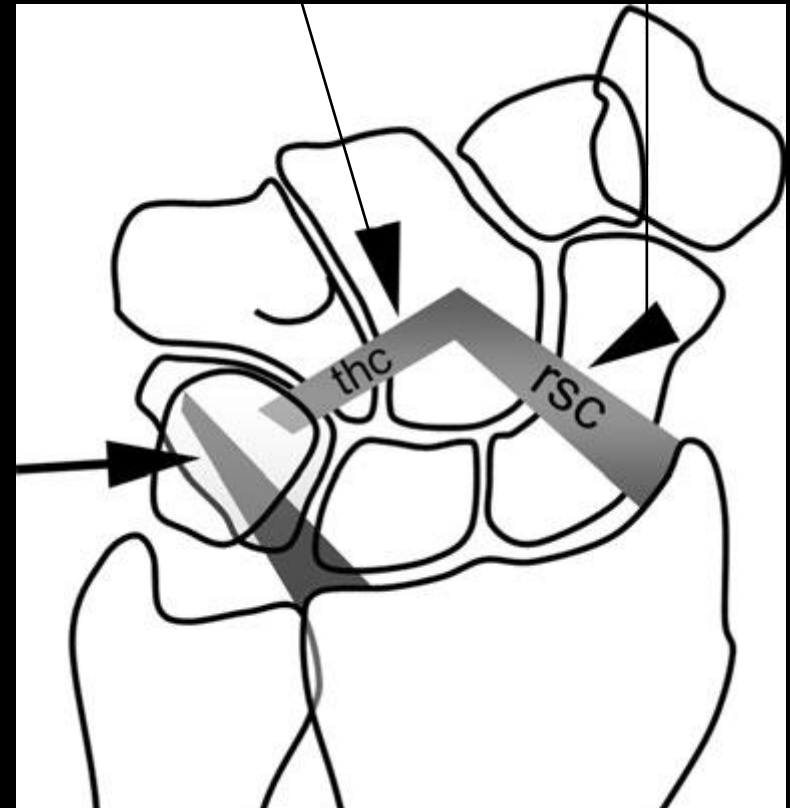


- Principle extrinsic ligaments prone to dysfunction in midcarpal instability

### Dorsal radiotriquetral ligament

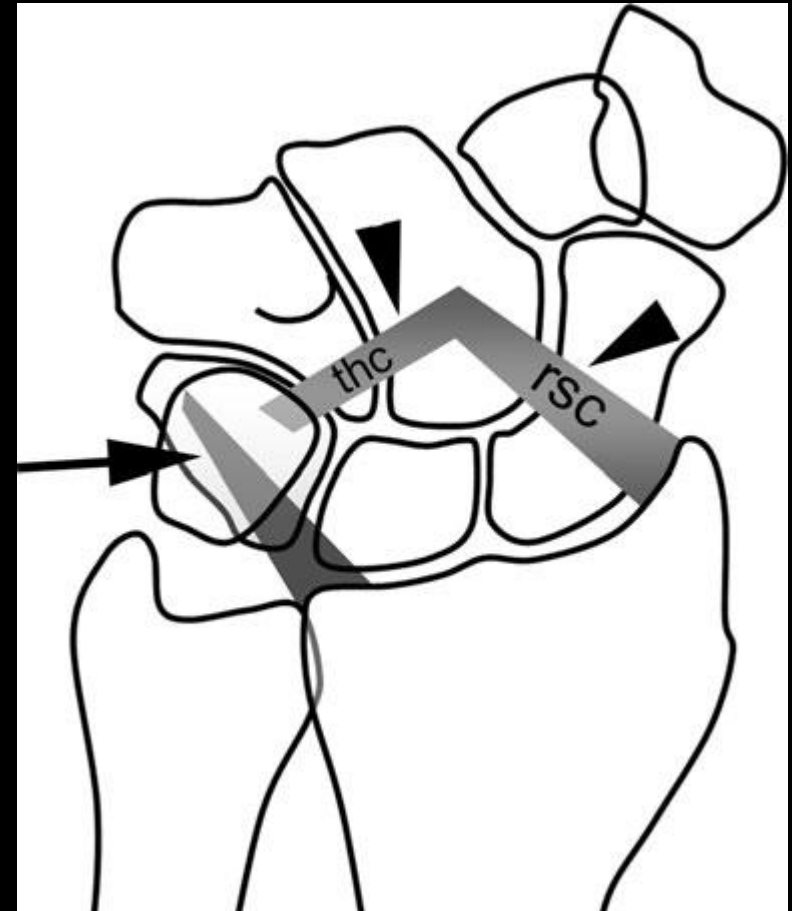
- The palmar ligaments are demonstrated at the front of this “transparent” diagram

### Palmar arcuate ligament



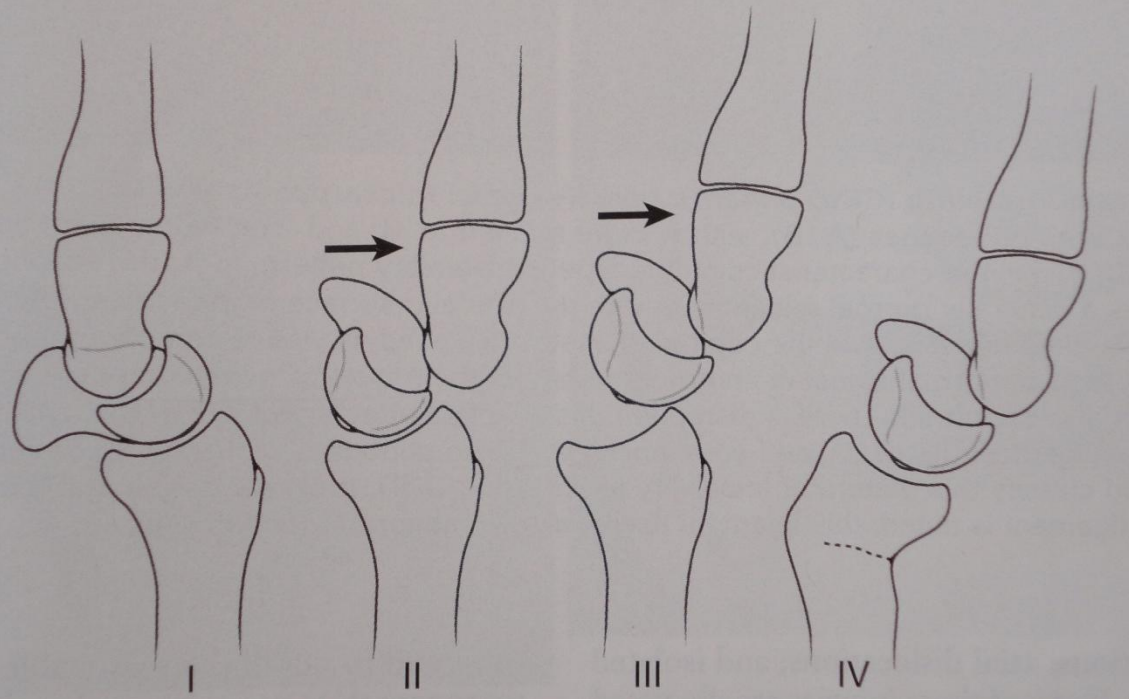
## MCI: palmar arcuate ligament

- Resists the tendency during axial loading for the **distal** carpal row to rotate into **extension** and the **proximal** carpal row into **flexion** .
- Has two limbs:
  - Triquetro-hamate-capitate
  - scaphocapitate





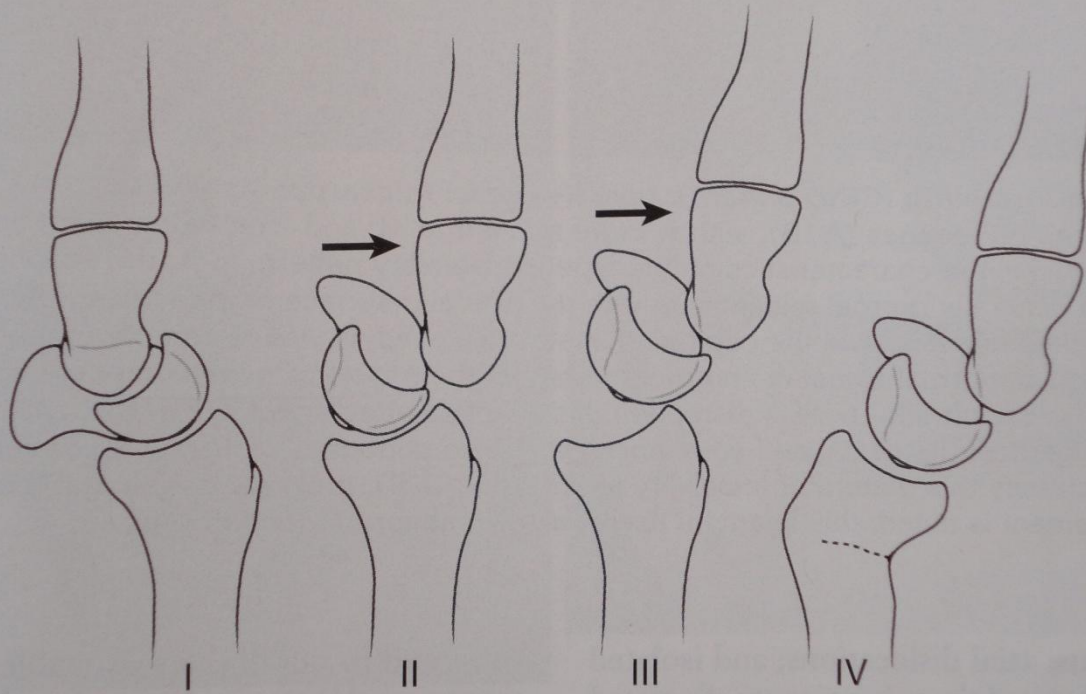
Midcarpal Instability (CIND Pattern)



Resnick et al. IDJ. 2<sup>nd</sup> ed.

- Type I: palmar midcarpal instability (PMCI)
- volar flexion of the entire proximal row → VISI deformity.
  - Most common type
  - c/o painful clunking wrist

Midcarpal Instability (CIND Pattern)

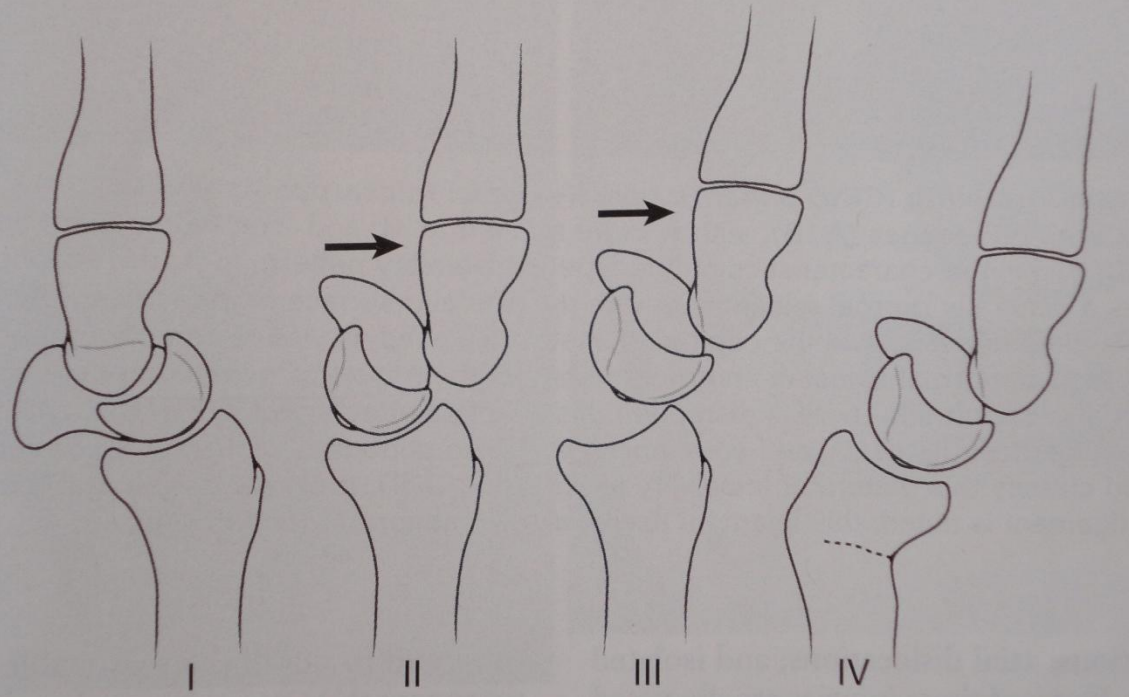


Resnick et al. IDJ. 2<sup>nd</sup> ed.

## Type II: Dorsal midcarpal instability

- Dorsal subluxation of the capitate and dorsal tilting of the scaphoid and lunate
- Includes:
  - Capitulate instability pattern (CLIP)
  - Chronic capitulate instability (CCI)

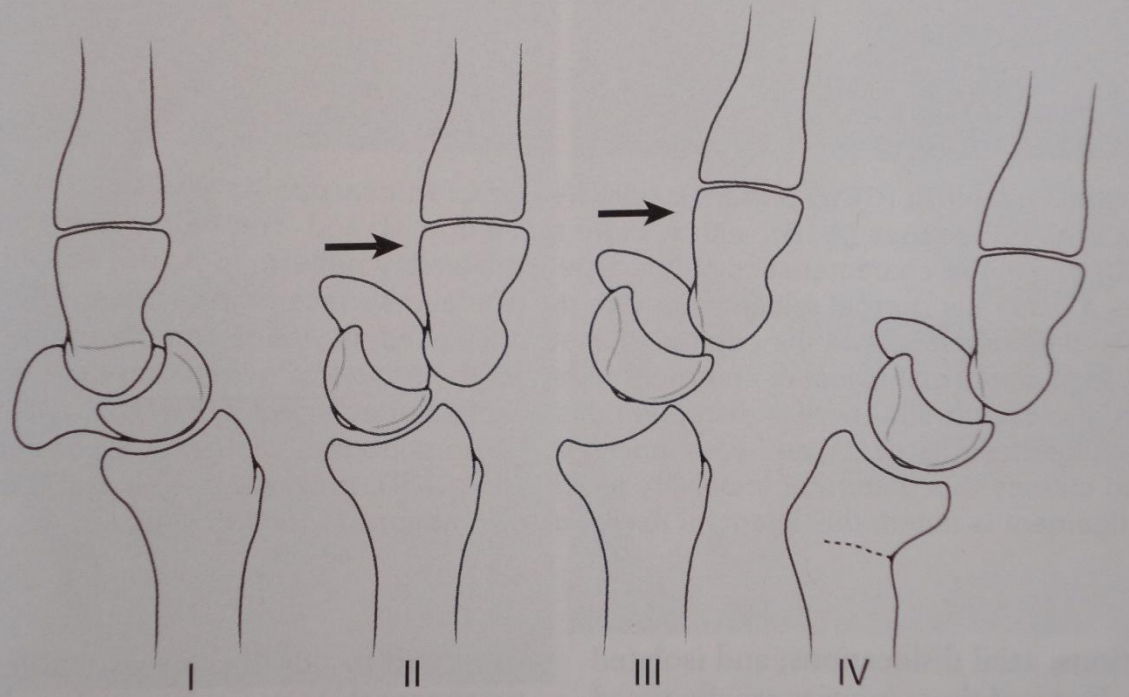
Midcarpal Instability (CIND Pattern)



Type III: Dorsal and Palmar midcarpal instability

- exaggeration of the dorsal MCI with additional dorsal subluxation of the scaphoid and lunate

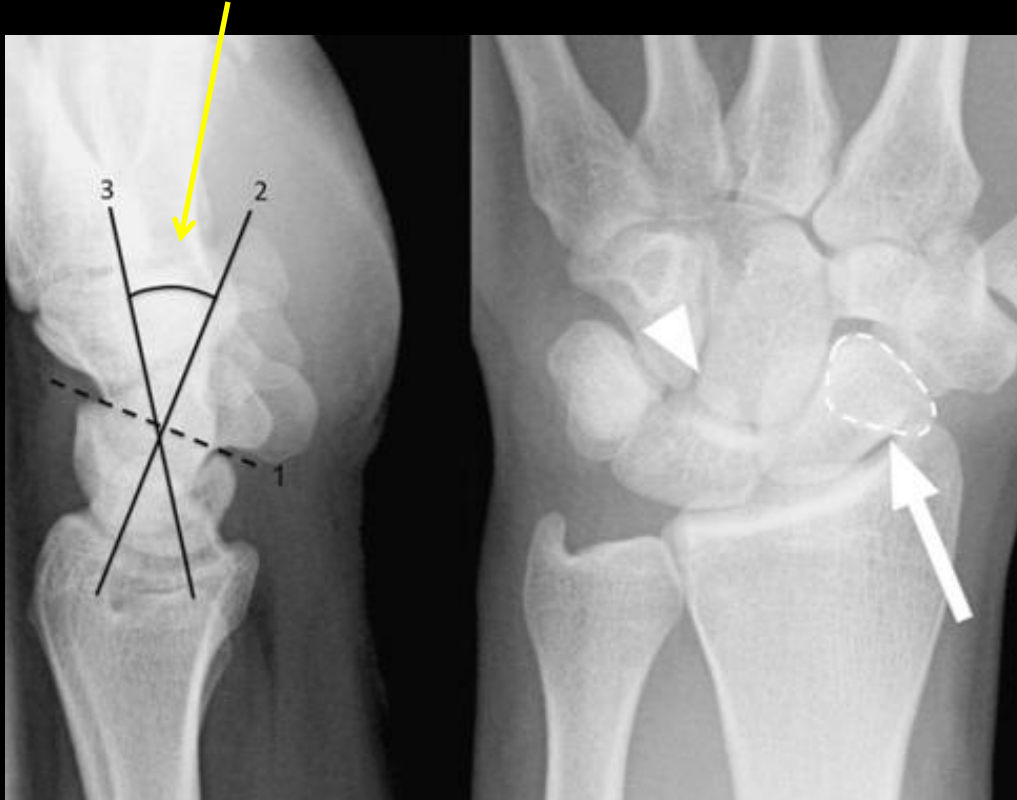
Midcarpal Instability (CIND Pattern)



- Type IV: Extrinsic midcarpal instability
- asstd with prior radial fx's with persistent dorsal angulation of the radius
  - Dorsal displacement of carpal bones is related to stretching of the dorsal ligaments.
  - Thus, this could also be classified as (CIA)

# Proximal Midcarpal Instability (PMCI)

Capitolunate angle  $30^\circ$  (nl  $<30$ )



MCI demonstrating flexion of the proximal carpal row.

This is sometimes confusingly referred to as a mild VISI deformity because of the flexed lunate.

However, a full VISI deformity, with rupture of the lunotriquetral ligament, typically results in a reduction of the scapholunate angle

However, the entire **proximal carpal row (including the scaphoid) is flexed** – evidenced here by the ring sign (dashed outline, arrow) and the posterior apex of the lunate is rotated distally (arrowhead) – **AND the scapholunate angle is normal**

Scapholunate angle  $50^\circ$   
(normal)

Skeletal Radiol  
DOI 10.1007/s00256-010-0941-1

REVIEW ARTICLE

**Midcarpal instability: a radiological perspective**

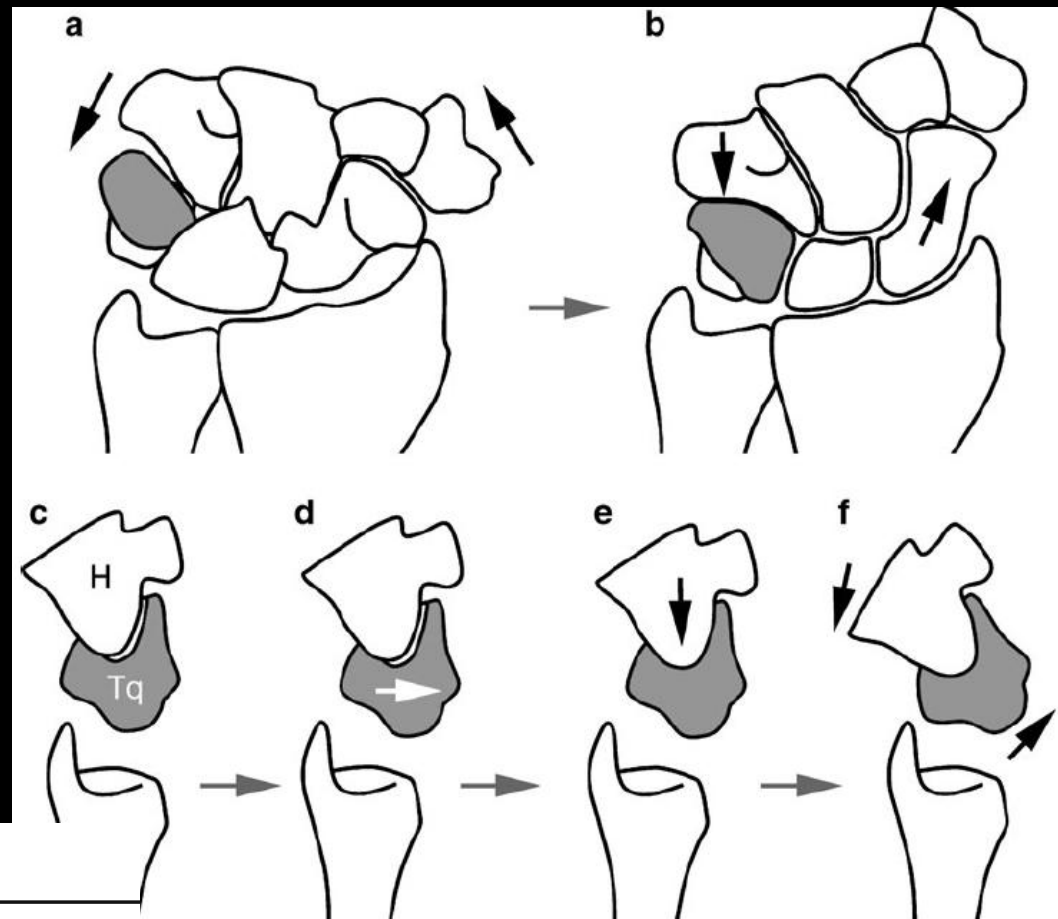
Andoni Paul Toms · Adrian Chojnowski · John G. Cahir

# Catch up clunk in PMCI

Radial deviation

Ulnar deviation

During radial to ulnar deviation, the proximal row sags towards the palm without extending until the triquetrohamate joint engages and forces the proximal carpal row into extension



Skeletal Radiol  
DOI 10.1007/s00256-010-0941-1

REVIEW ARTICLE

## Midcarpal instability: a radiological perspective

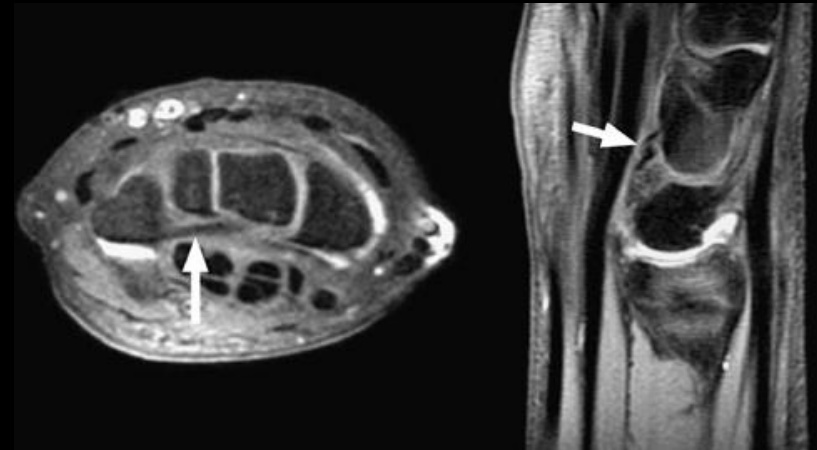
Andoni Paul Toms • Adrian Chojnowski • John G. Cahir



# CIND: midcarpal

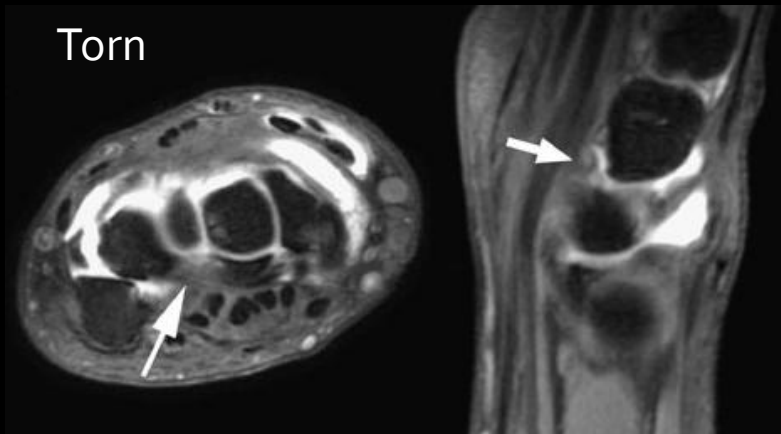
- Normal ulnar limb of palmar arcuate (triquetrohamatecapitate) ligament

Normal



- Torn triquetrohamatecapitate ligament in a patient with MCI

Torn



# CIND: midcarpal

- Conclusions of Andoni et al.:
- Association of abnormalities demonstrated on MRI with the diagnosis of MCI has yet to be demonstrated.
- Pattern of injury is probably more complex than simple isolated injuries.
- Defects in the extrinsic carpal ligaments that cause MCI, and the resulting dysfunctional carpal mechanics can be demonstrated with US and MR arthrography
  - But the accuracy of these techniques, and therefore the role they may play in the management of patients with MCI, has yet to be determined.



# Patterns of Carpal Instability

- Dissociative
  - Scapholunate dissociation
  - Lunotriquetral dissociation
  - Scaphoid fractures that are unstable, ununited, or malunited
  - Kienbock's disease
- Non-dissociative
  - Radiocarpal
  - Midcarpal
- Complex carpal instability
  - Perilunate dislocations
- Adaptive carpal instability

# CIC:

- Includes CID+ CIND cases
- 5 patterns of dislocation:
  - Dorsal perilunate dislocation (lesser arc injury)
  - Dorsal perilunate fracture-dislocations (greater arc injury)
  - Volar perilunate dislocations
  - Axial dislocations
  - Isolated carpal bone dislocations

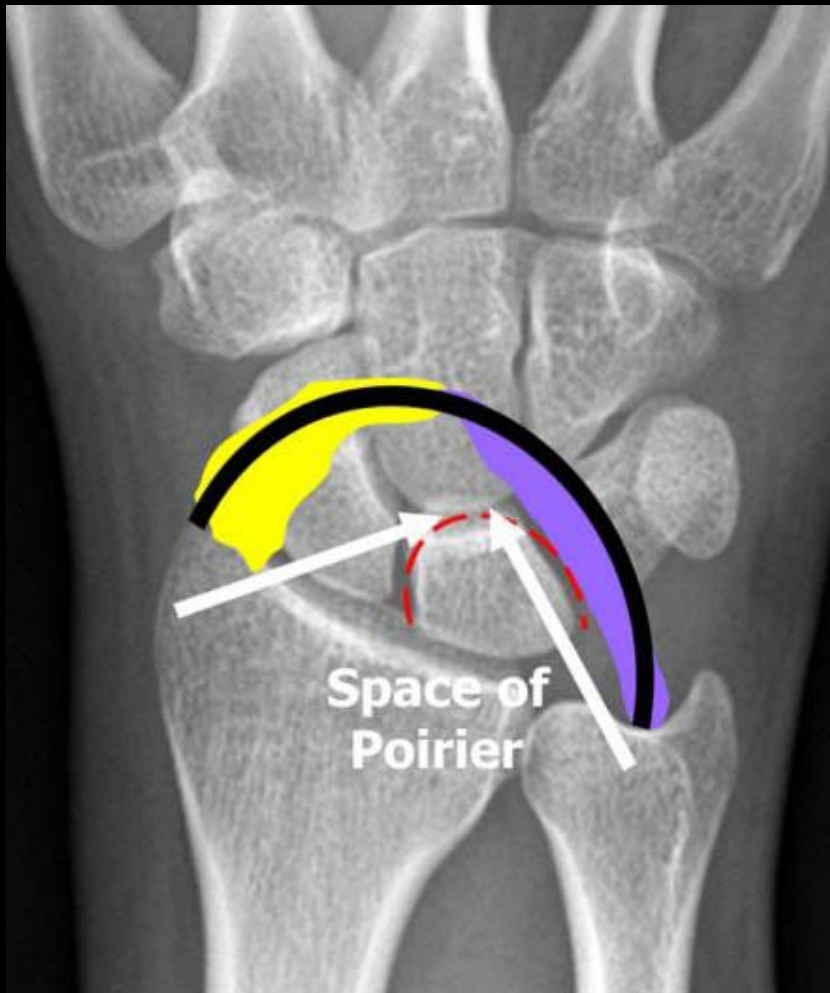
# CIC:

- Most typical example is the result of failed treatment of a perilunate dislocation.
- Ex. Perilunate injuries create both radiocarpal and intercarpal injuries which if not treated properly → chronic SLD and LTD (CID patterns), AND ulnar translation of the lunate (CIND pattern)
  - Usually involves both intrinsic and extrinsic radiocarpal ligaments
  - Failure to obtain stability of the joints of the proximal row may result in chronic CID type carpal collapse

# CIC:

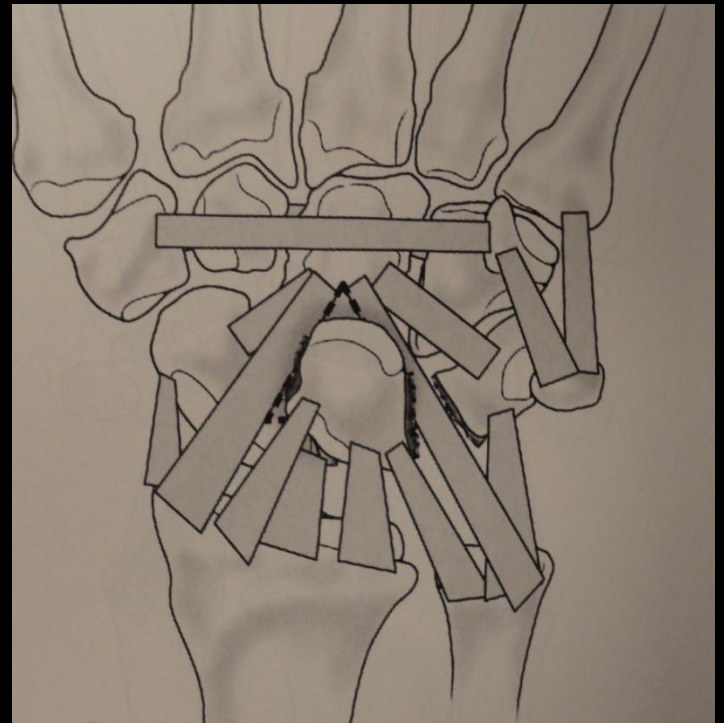
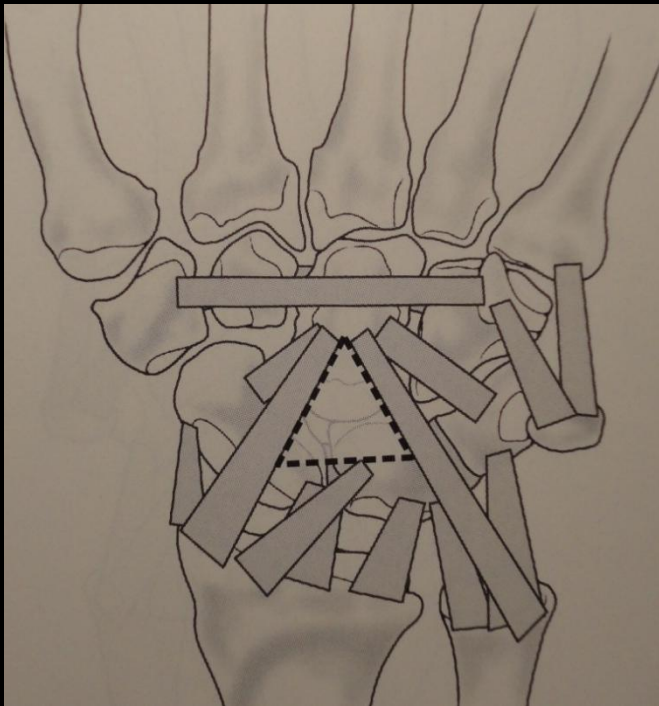
- If the Extrinsic lig's do not heal (after perilunate dislocation) or are ineffective, there is a tendency to develop radiocarpal CIND (ulnar translocation)
  - Need surgical stabilization of both causes of instability—
    - ie. midcarpal fusion with tightening of the dorsal and volar radiocarpal ligaments
    - If there is substantial cartilage wear, then formal wrist fusion is better.
- Typically, a DISI deformity appears.

# Greater and Lesser Arc Injuries



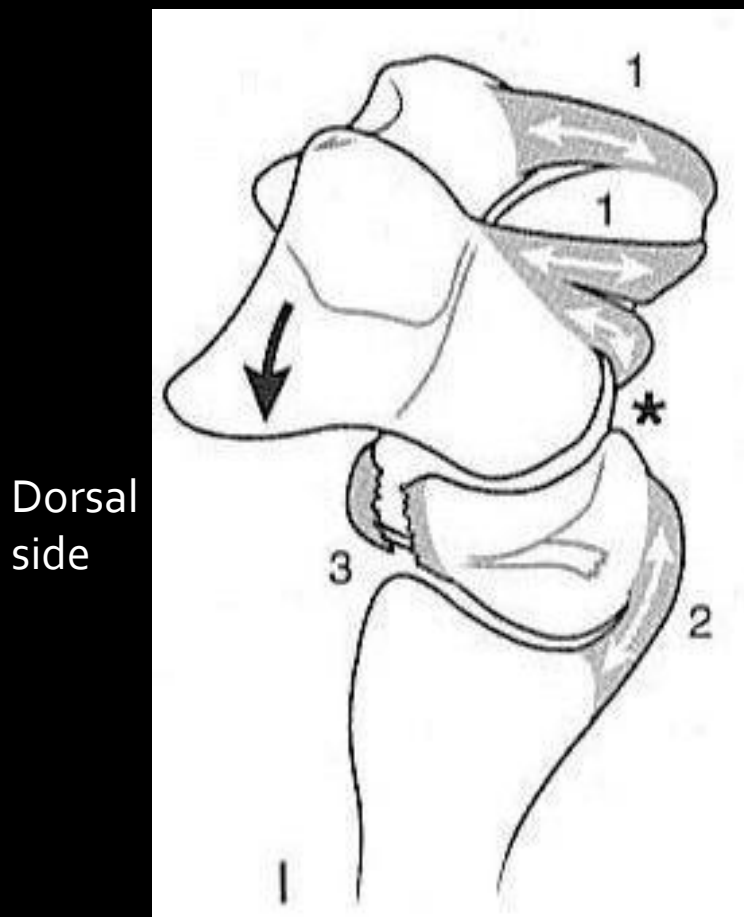
- lesser arc injury : pure ligamentous perilunar injury
  - Some disagreement exists regarding some of the stages of perilunate instability
- greater arc injury: transosseous variants (transscaphoid, transcapitate, tranhamate, transtriquetral fracture-dislocation)
- Various combinations are seen clinically

# Space of Poirer



Volar intrinsic ligaments

# Perilunate Instability



Stage I – Scapholunate dissociation

-Injury to radial side of wrist leads to injury to scaphoid lunate interosseous ligament

-scaphoid is pulled into extension

\* Space of Poirer (“pear”) is opened- a weak triangular region in which the volar capsule is not reinforced by ligaments.

# Perilunate Instability

Stage II – Lunocapitate dislocation (Perilunate)

- Dorsal translocation or dislocation of distal row relative to capitate

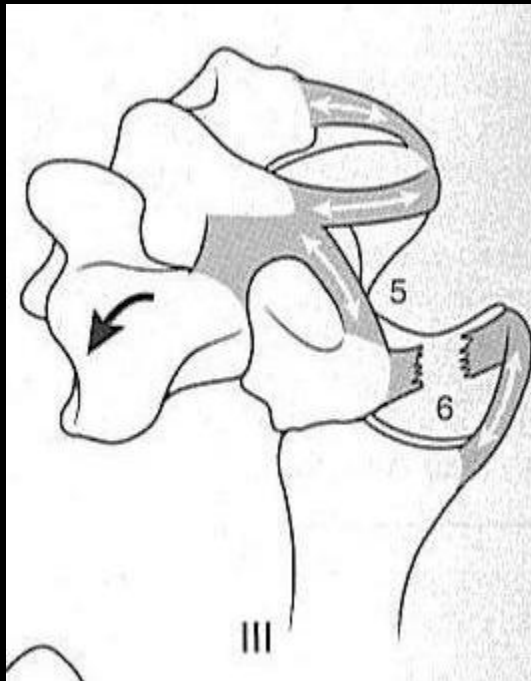
Dorsal  
side





# Perilunate Instability

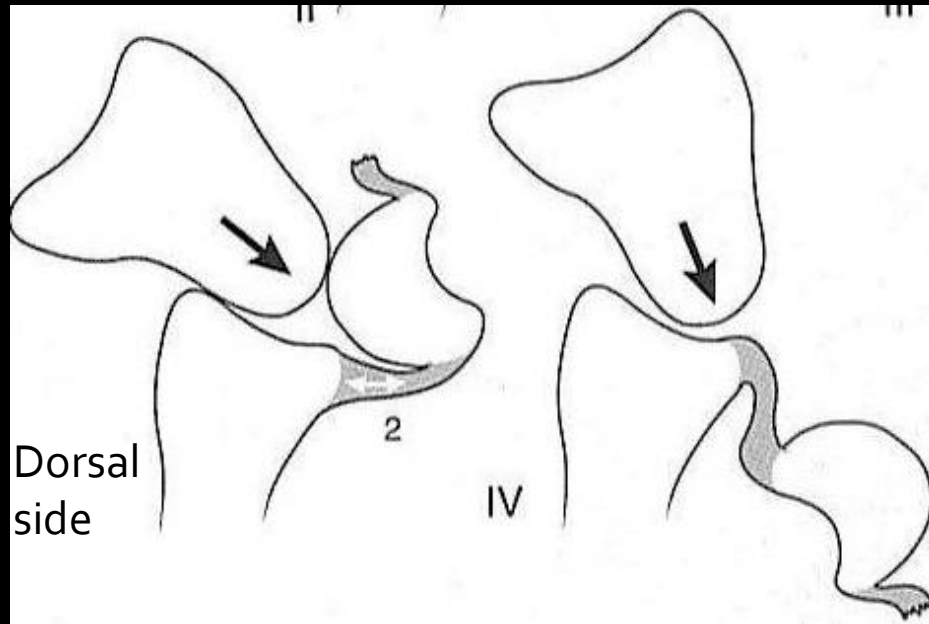
Dorsal  
side



Stage III – Lunotriquetral  
disruption (Midcarpal)

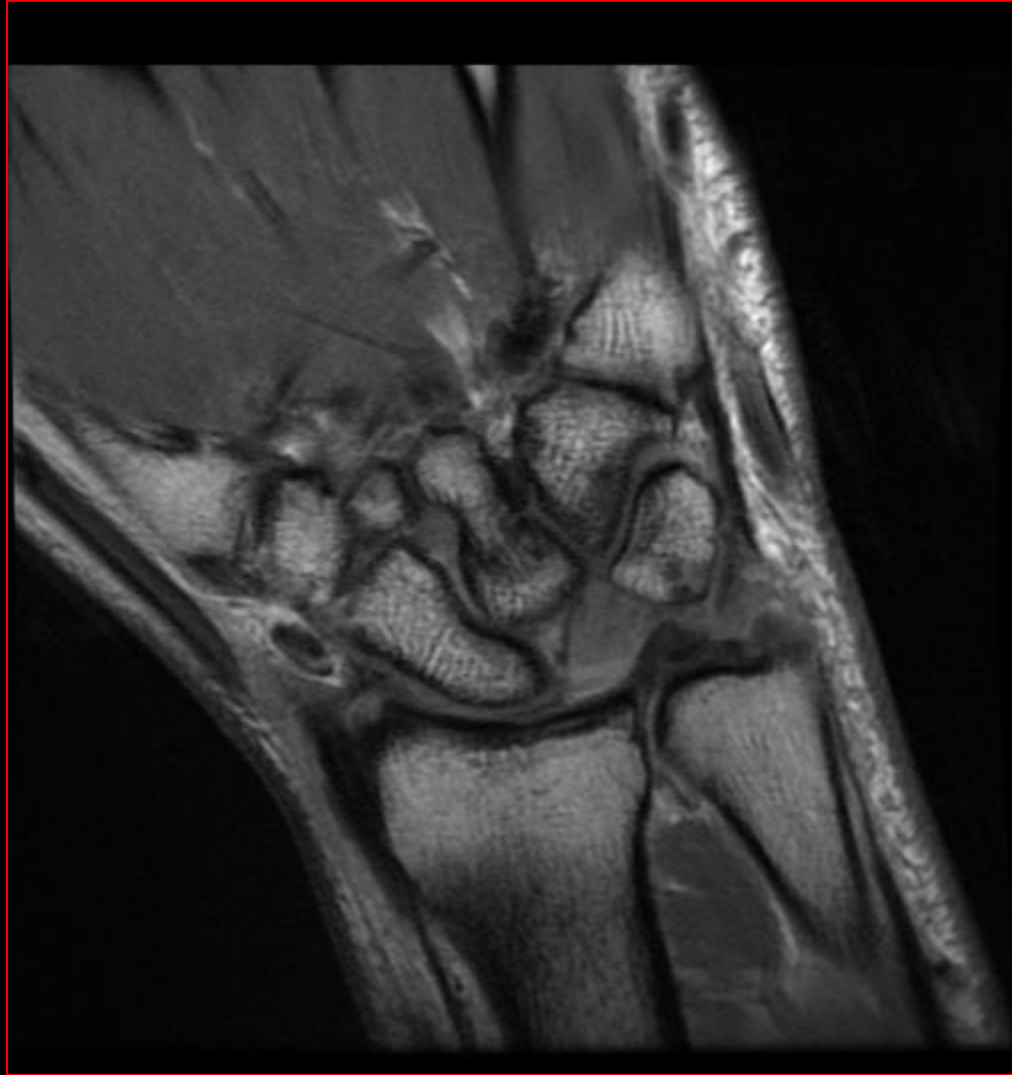
- Triquetrum separates from the lunate owing to displacement of the capitate causing disruption of the lunotriquetral interosseous ligament

# Perilunate Instability

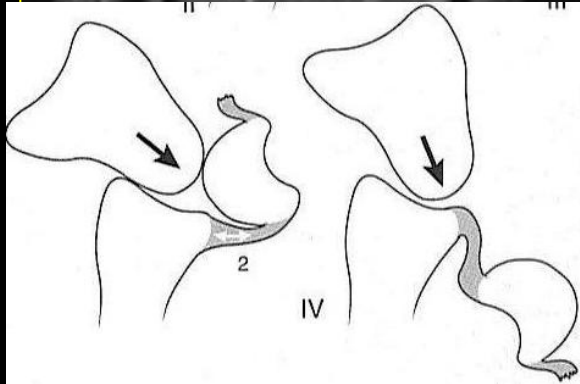
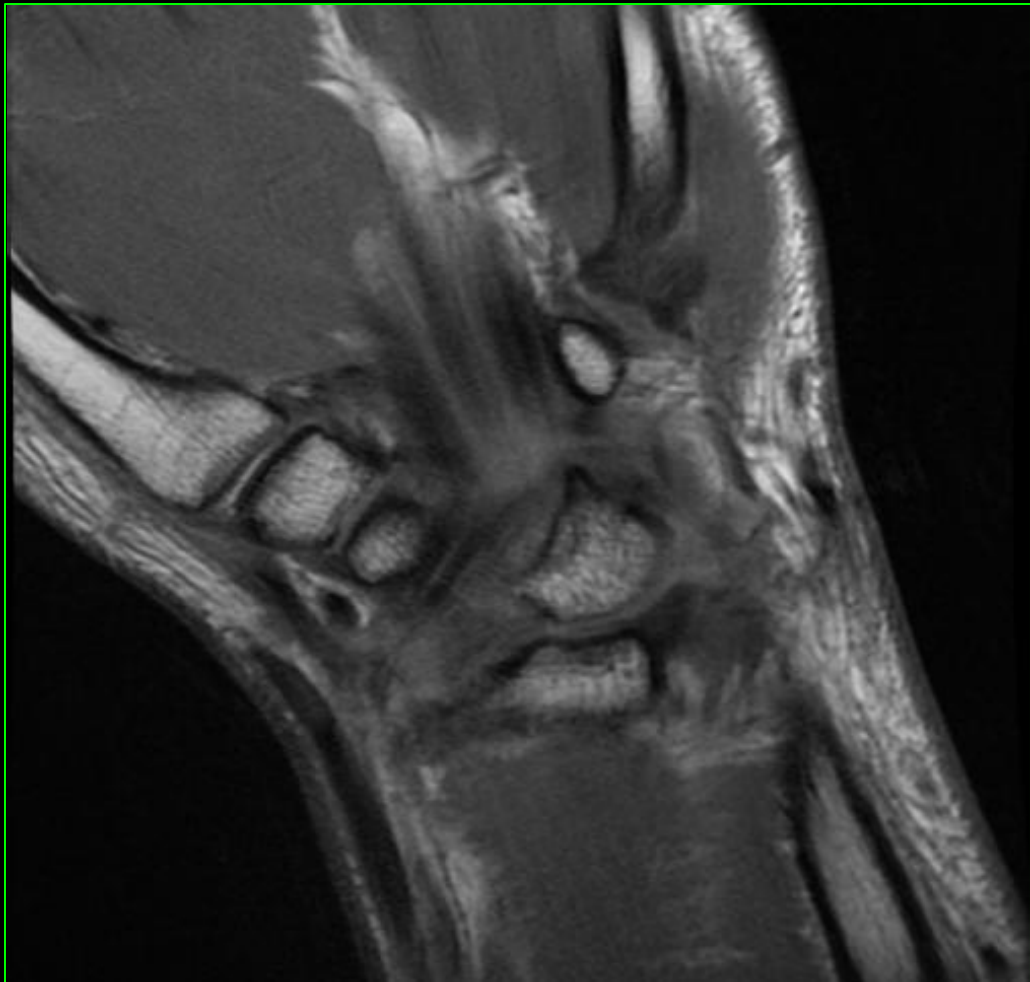
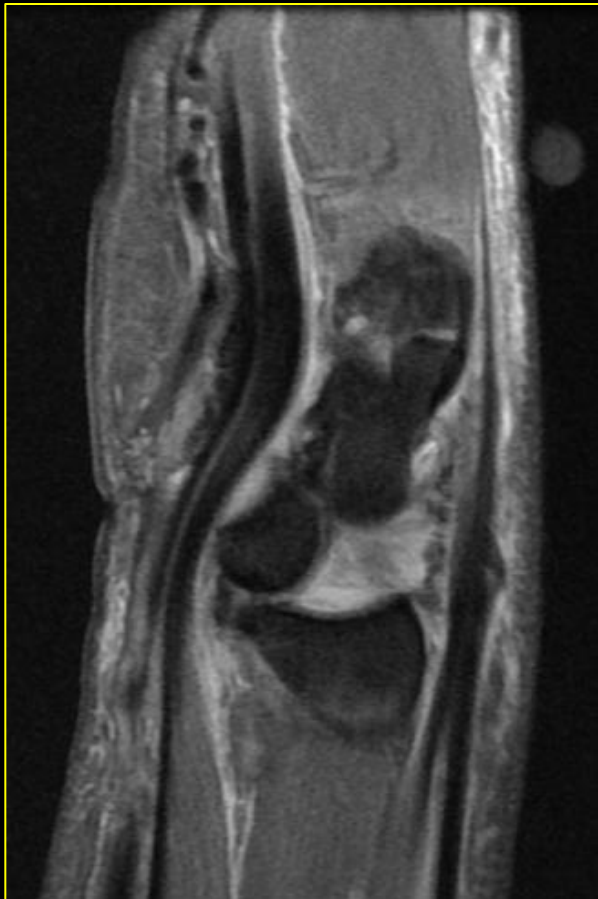


Stage IV – Lunate dislocation (Final Step)

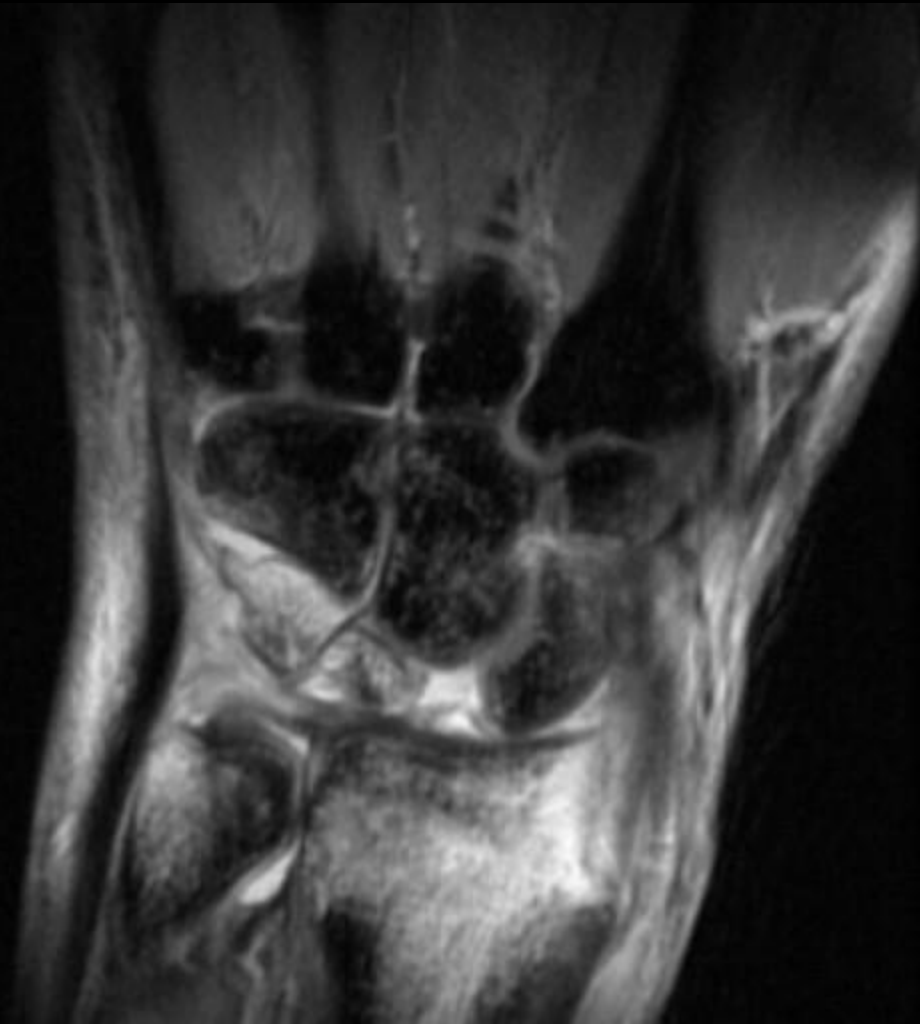- Dorsally dislocated capitate contacts lunate, causing palmar dislocation in a rotary fashion



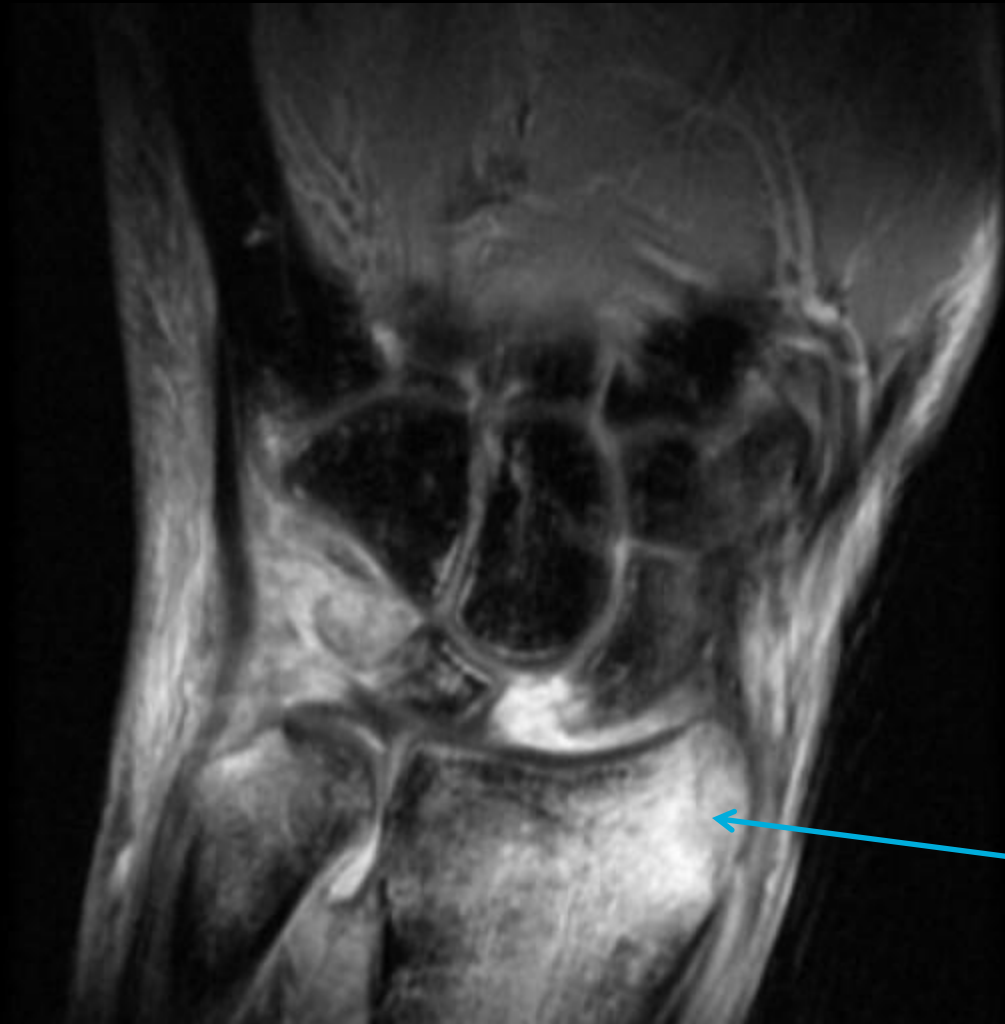- 41 year old female with wrist pain

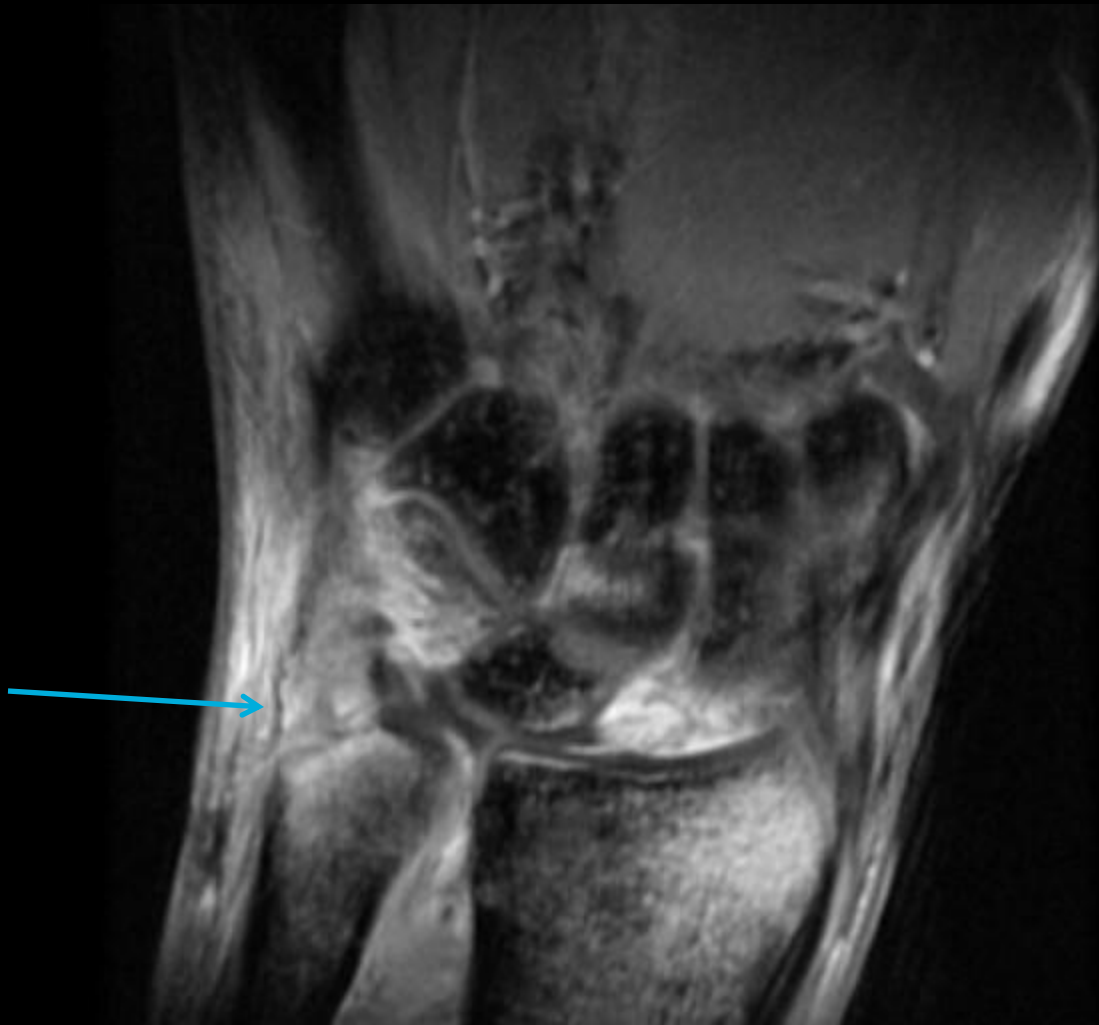

Greater arc injury

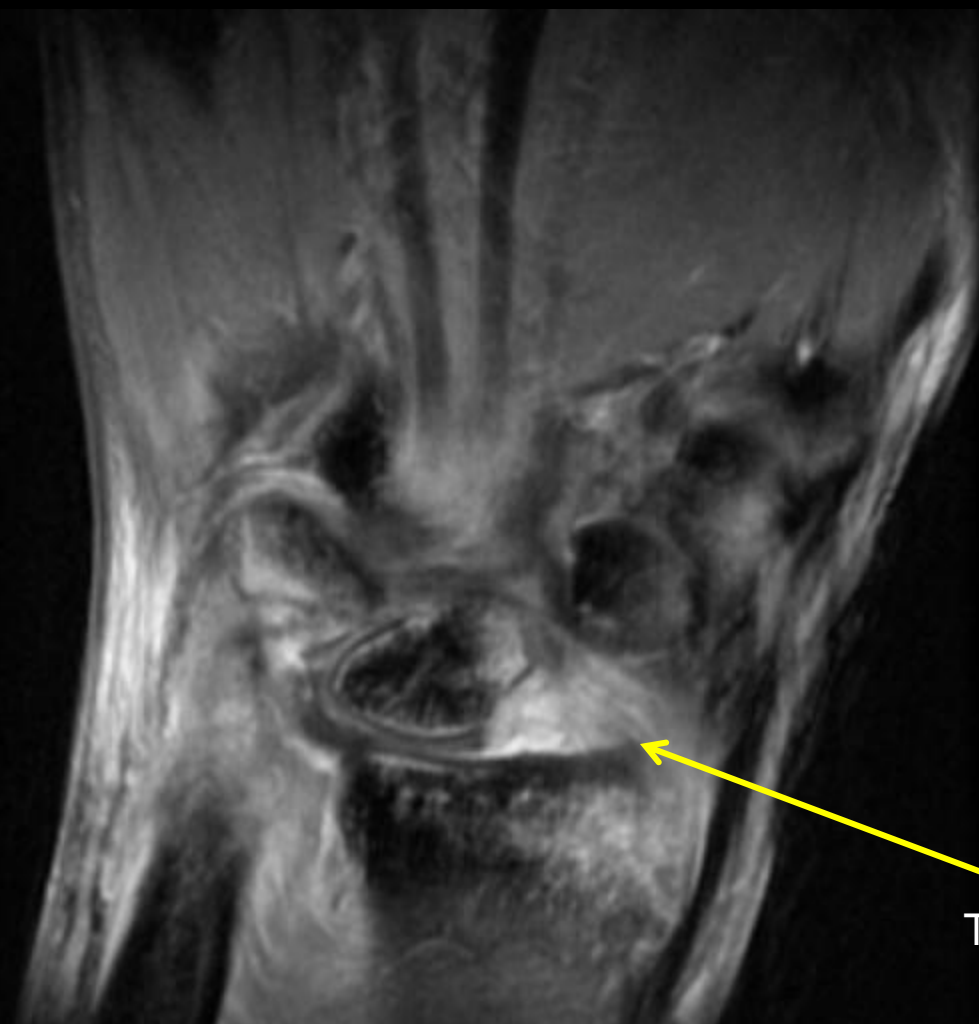

30 year-old male , Fall 1 month ago with wrist dislocation. c/o  
Pain and edema

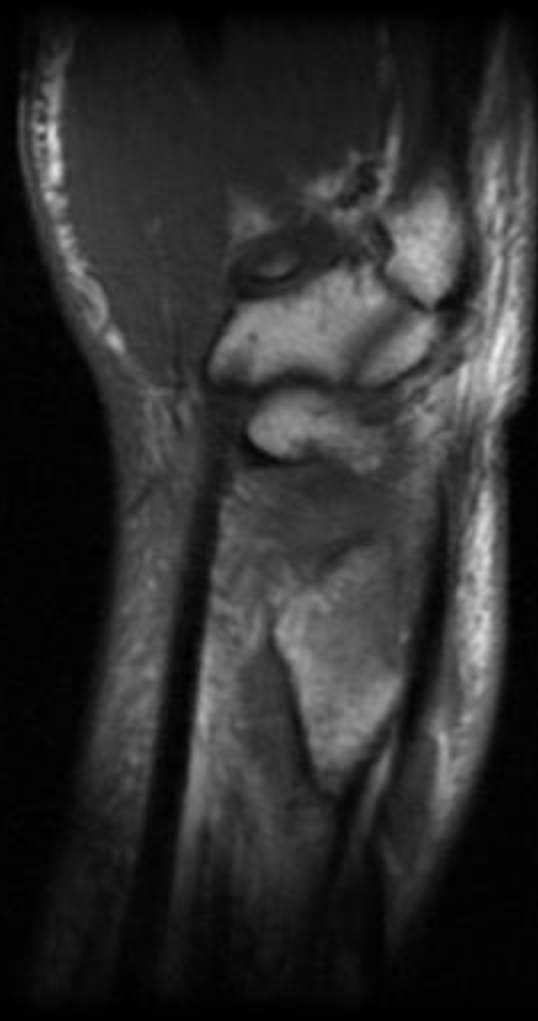


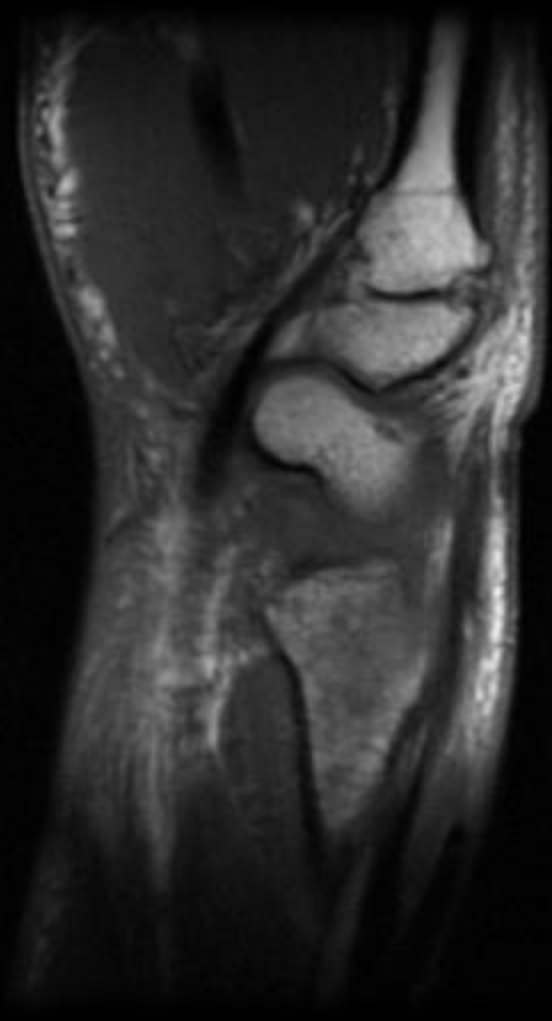


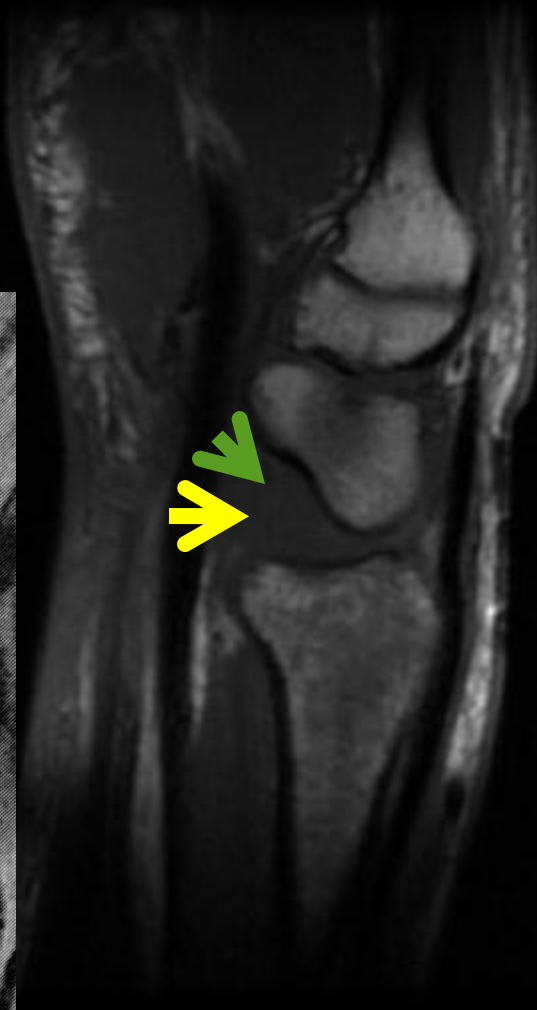
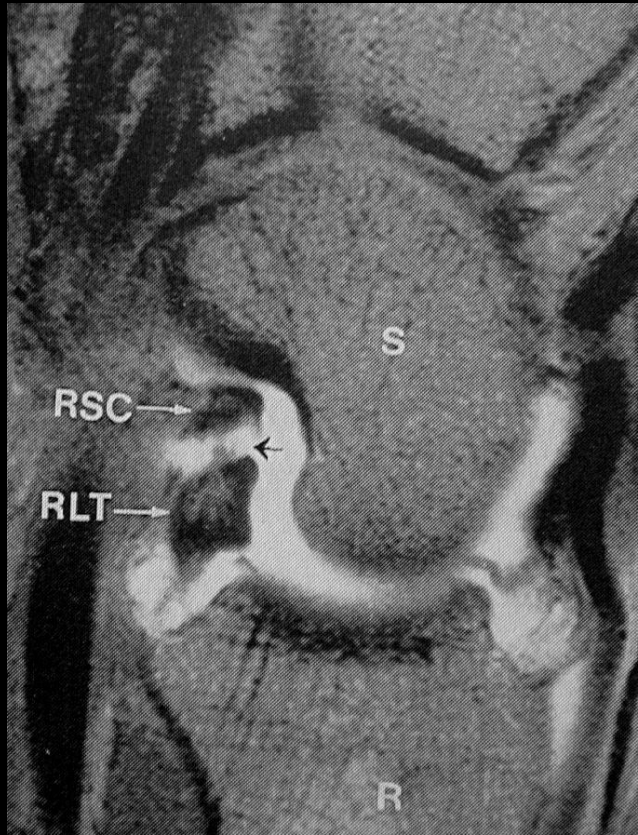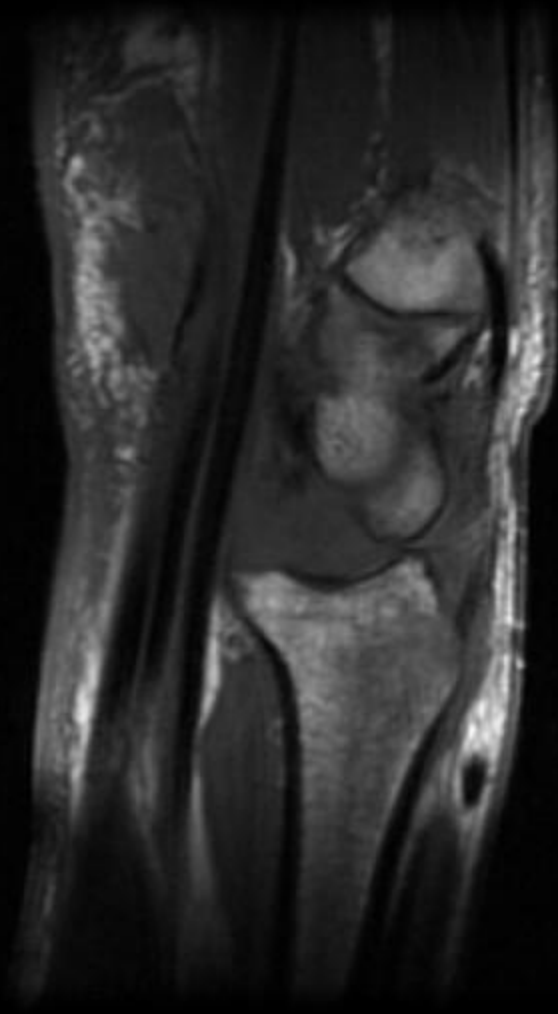


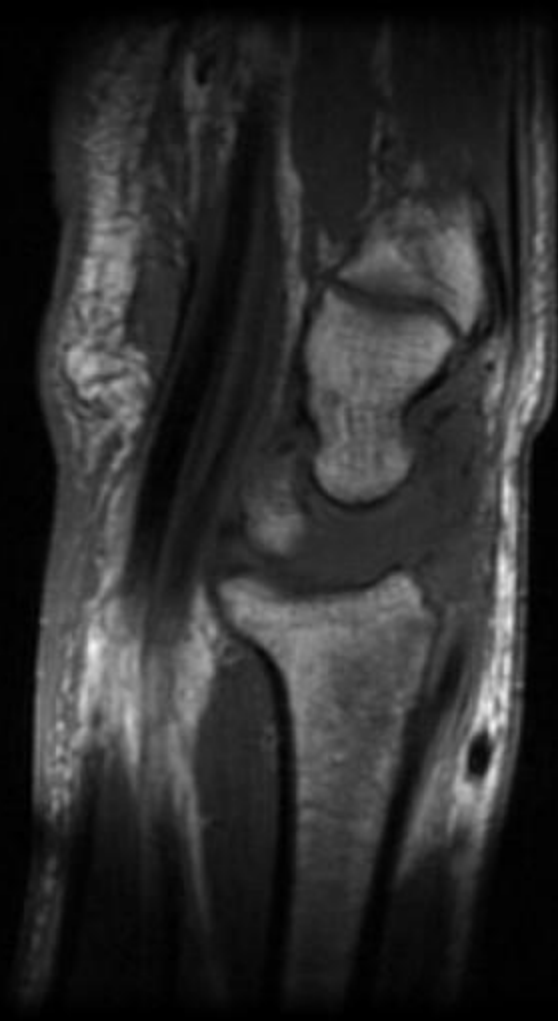
Torn radiolunotriquetral

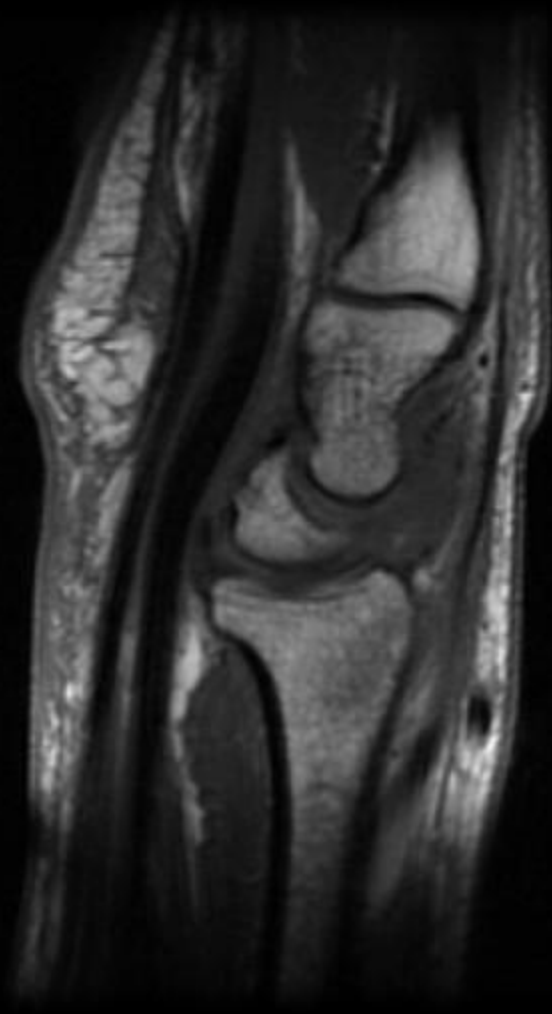

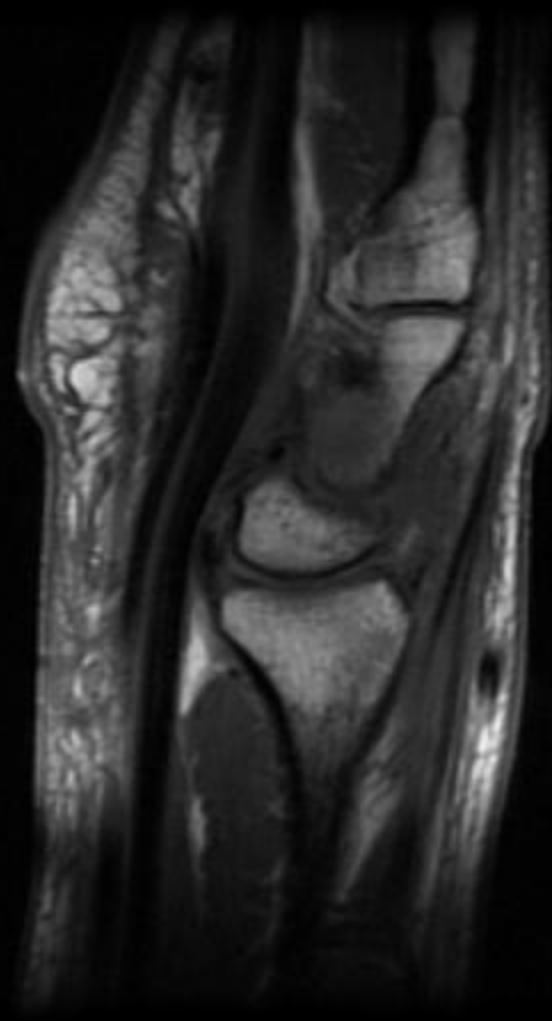





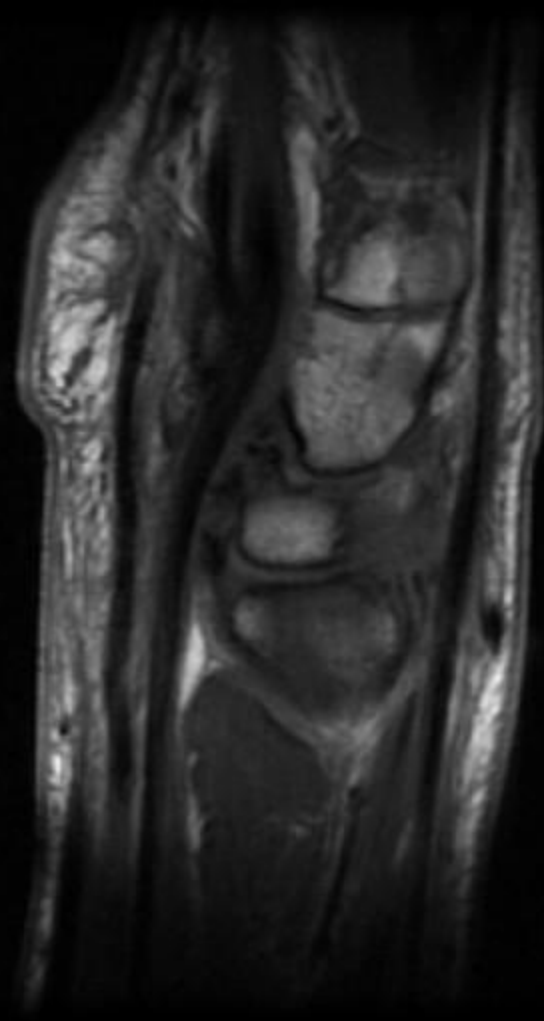


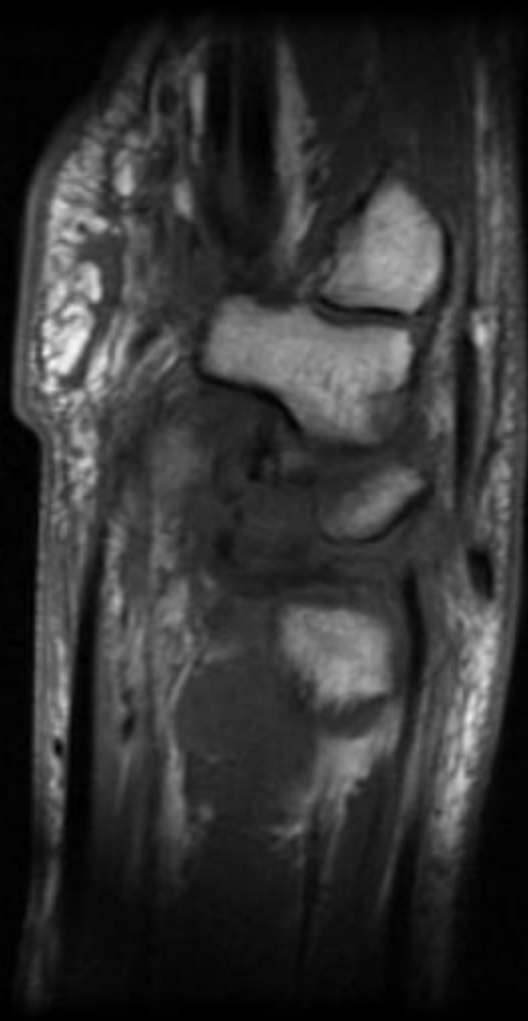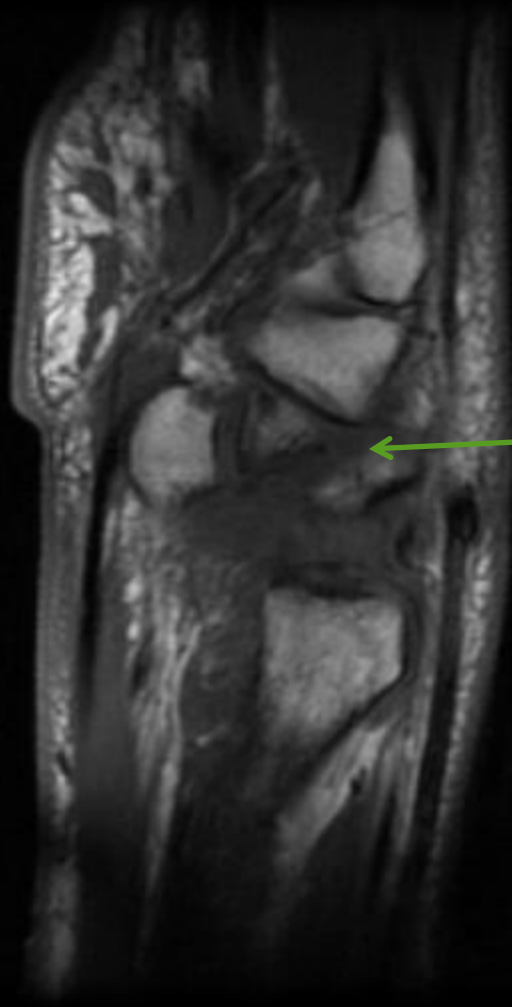




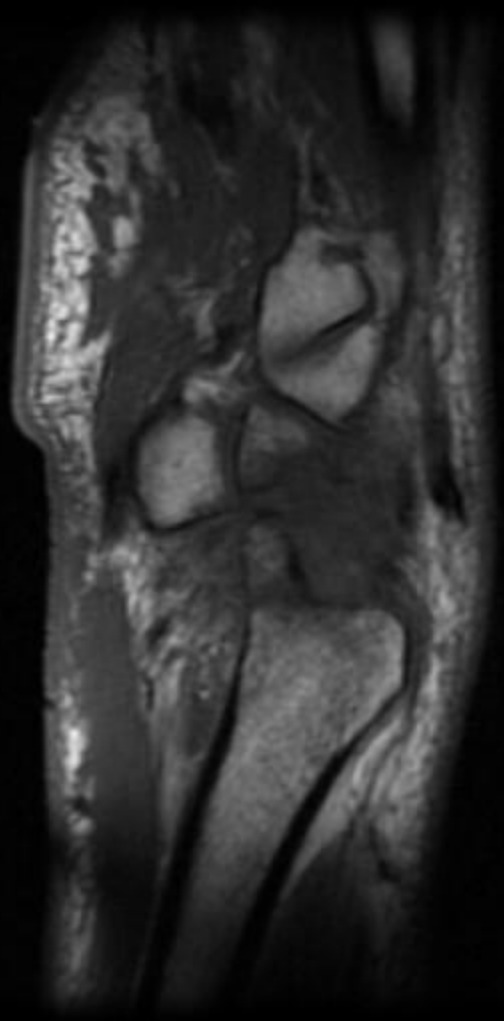








Triquetral fracture



# CIC:

## Findings:

- Disruption of
  - Scapholunate interosseous ligament with DISI
  - Volar Radioscaphocapitate ligament (CIND- like)
  - Volar Radiolunotriquetral ligament (CIND -like)
- Fractures of
  - Radial styloid
  - Triquetrium (CID like)
  - Ulnar styloid

# Diagnosis

- Complex wrist injury
- Injury involving
  - Greater and Lesser Arcs
- Trans-radial styloid, trans-triquetral perilunate instability with ulnar styloid fracture and residual DISI
  - soft tissue injuries = S-L, R-S-C, R-L-T disruption

# Patterns of Carpal Instability

- Dissociative
  - Scapholunate dissociation
  - Lunotriquetral dissociation
  - Scaphoid fractures that are unstable, ununited, or malunited
  - Kienbock's disease
- Non-dissociative
  - Radiocarpal
  - Midcarpal
- Complex carpal instability
  - Perilunate dislocations
- Adaptive carpal instability

# Adaptive Carpal Instability

- Change in carpal alignment adapting to the pathologic change outside of the carpal bones and their ligaments.
  - Ex. malunion of the a distal radial fx results in tilting of the carpal bones to maintain a straight light between the distal radius and the metacarpals.
  - Typical pattern is a DISI type alignment.

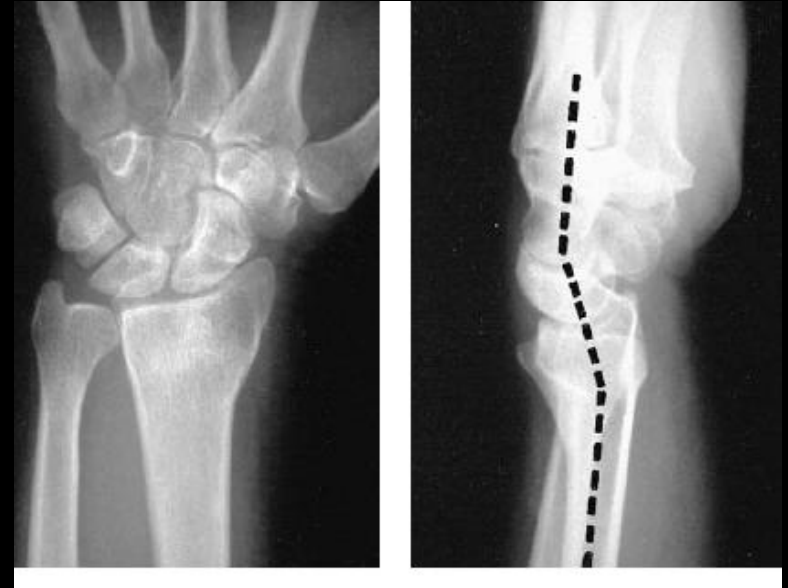

# Adaptive Carpal Instability

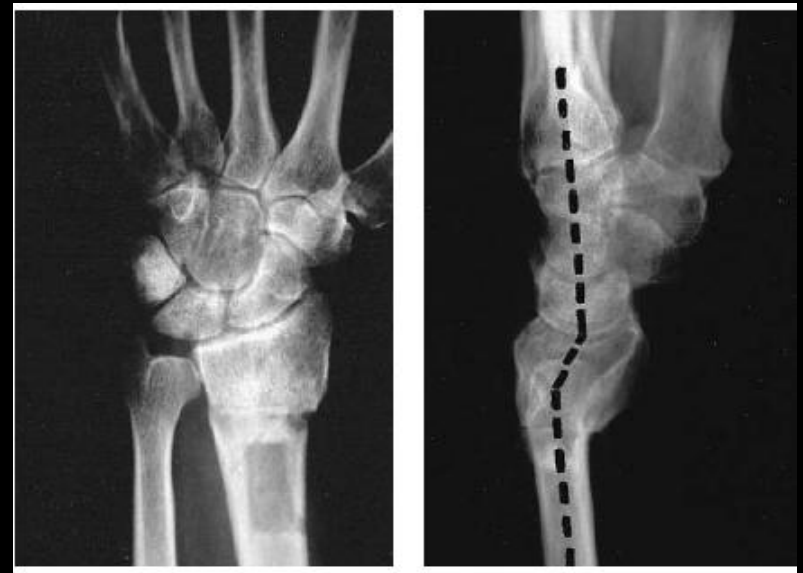- Consequences of adaptive carpal instability
  - Altered carpal kinetics, overloading the cartilage, arthritis
- Tx: Osteotomy. However, if there is associated radiocarpal ligament disruption or stretched after injury, ligament reconstruction or radiolunate or radioscapolunate arthrodesis is needed in addition.
- The effects of dorsally angulated distal radius fractures on carpal kinematics. Park MJ. J Hand Surg [Am]. 2002 Mar;27(2):223-32.

# CIA

- Top: malunited Colles' fracture with dorsal angulation of the distal radius. The axes of the lunate, capitate and metacarpals is not parallel.

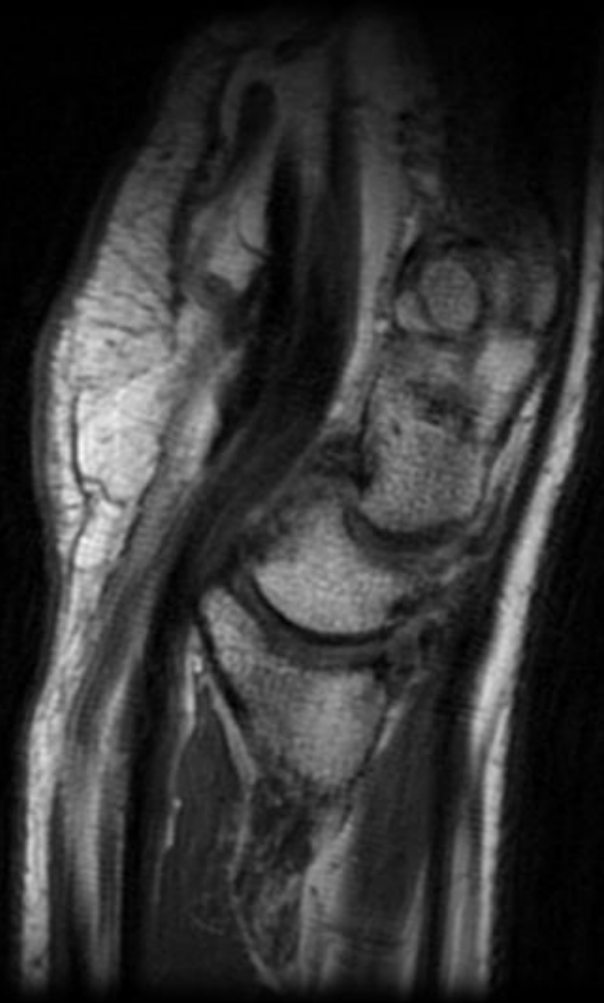


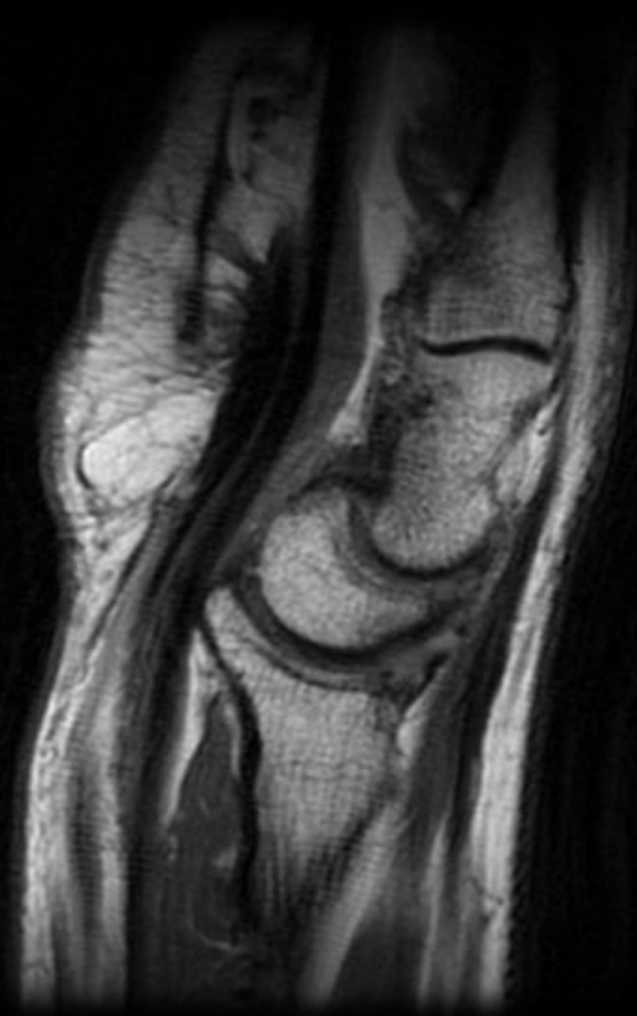- Bottom: corrected malunion with osteotomy. The carpal bones are now collinear.

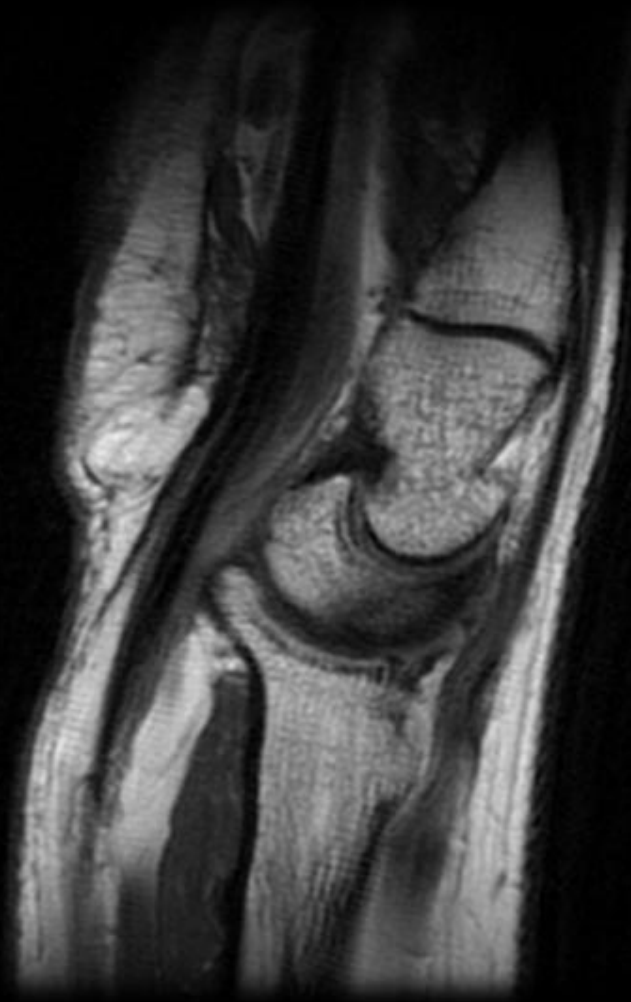


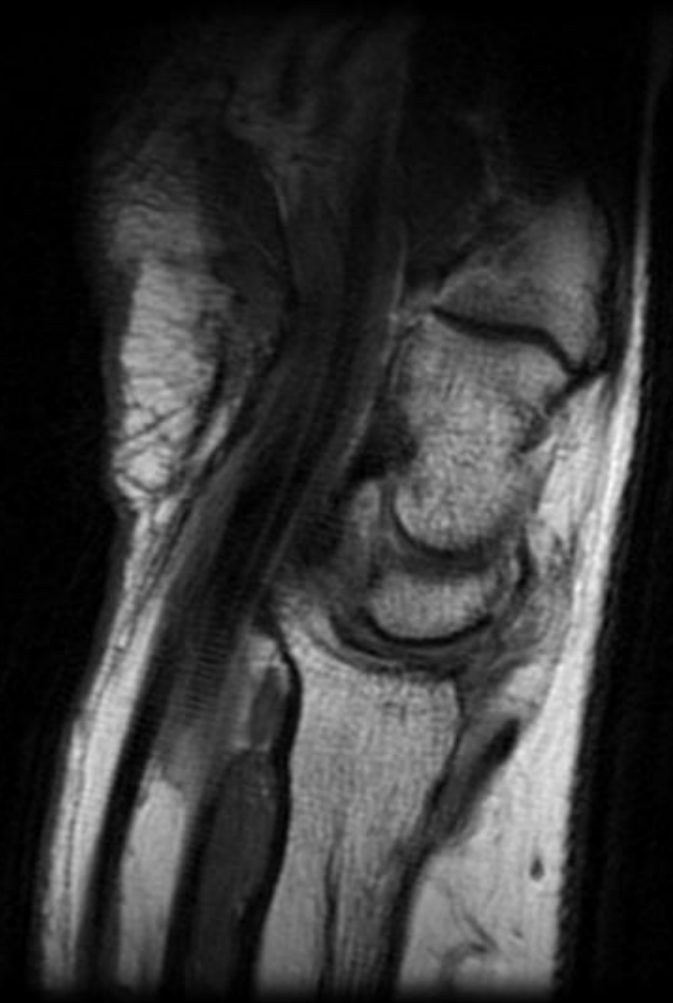
# Adaptive Carpal Instability

10 of 21. Ratio: 6.0. Zoom: 105%









# Treatment of carpal instabilities

- No single treatment
- Must meet needs of individuals by considering:
  - Chronicity (healing potential of the lig. involved)
  - Constancy (dynamic or static)
  - Etiology (traumatic, congenital, or inflammatory)
  - Location (site of the major dysfunction – radiocarpal, midcarpal, intercarpal, carpo-metacarpal)

- Thank you!
- Special thanks to Tudor Hughes.



# REFERENCES

- Goldfarb CA, Yin Y, Gilula LA et al. Wrist Fractures: What the Clinician Wants to Know. *Radiology* 2001; 219:11-28.
- Mann FA, Wilson AJ, Gilula LA. Radiographic Evaluation of the Wrist: What does the Hand Surgeon Want to Know. *Radiology* 1992; 184:15-24.
- Resnick, D. *Diagnosis of Bone and Joint Disorders*. 4<sup>th</sup> Ed. Vol. 2. W.B. Saunders. 2002. 1310-1311, 1611. (Vol 3: 2847, Vol. 4: 3645)