

COALITION

Julie L. Rutledge, M.D.

What is a coalition?


Coalition Against Ridiculous
Coalition Against Stupid People

A coalition is a concept for a bony cartilaginous, or fibrous connection between two or more bones.

Synostosis: bony coalition

Synchondrosis: cartilaginous coalition

Syndesmosis: fibrous coalition



Objectives

- Tarsal Coalition
 - History
 - Etiology
 - Clinical Presentation
 - Anatomy
 - Imaging
 - Treatment

- Carpal Coalition

TARSAL COALITION

HISTORY

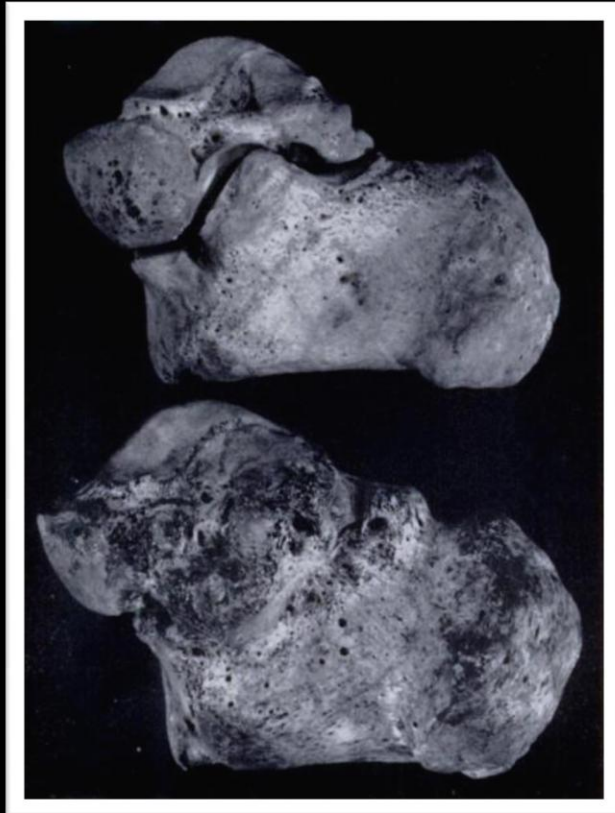History – Tarsal Coalition

Syntarsus



History – Tarsal Coalition

- Have been identified for several hundred years
- Heiple and Lovejoy reported a tarsal coalition in the foot of a pre-Columbian Indian skeleton circa 1000 A.D.



Medial aspects of the talus and calcaneus (normal superior and talocalcaneal coalition inferior) from an Indian skeleton. Complete synostosis is present

History -- Tarsal Coalition

- First recognized in the eighteenth century -- The first written description of a tarsal coalition is attributed to Buffon in 1769
- The first radiographic demonstration of tarsal coalition was by Kirrmisson in 1898, only 3 years after the discovery of x-rays
- R. I. Harris and Thomas Beath made the first widely known report identifying tarsal coalition as a cause of a painful, rigid flatfoot in 1948. Since then, coalition began to be viewed as a clinically significant entity

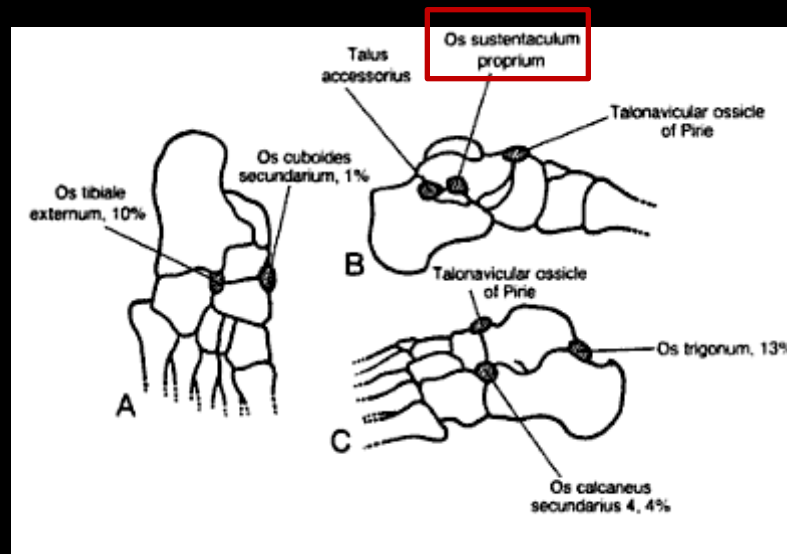
ETIOLOGY

Etiology -- Tarsal Coalition

Several theories of tarsal coalition etiology have been proposed:

1. Pfizzner (1896):

- Suggested accessory ossicles commonly found in the area of tarsal coalition were responsible for bar formation. Felt that a congenital tarsal coalition is formed from the incorporation of accessory ossicles into the normal tarsal bones on either side of a joint
 - Primary evidence was that the **os sustentaculum proprium** accessory bone occurs at the site of the middle facet of the subtalar joint



Ossicles responsible for formation of tarsal coalitions according to Pfizzner.

Etiology – Tarsal Coalition

2. Leboucq:

- Suggested that congenital coalition results from the failure of differentiation and segmentation of primitive mesenchyme
 - This theory attributes congenital coalitions to a heritable defect or to an insult in the first trimester of pregnancy
 - Supported by identification of such anomalies in fetuses

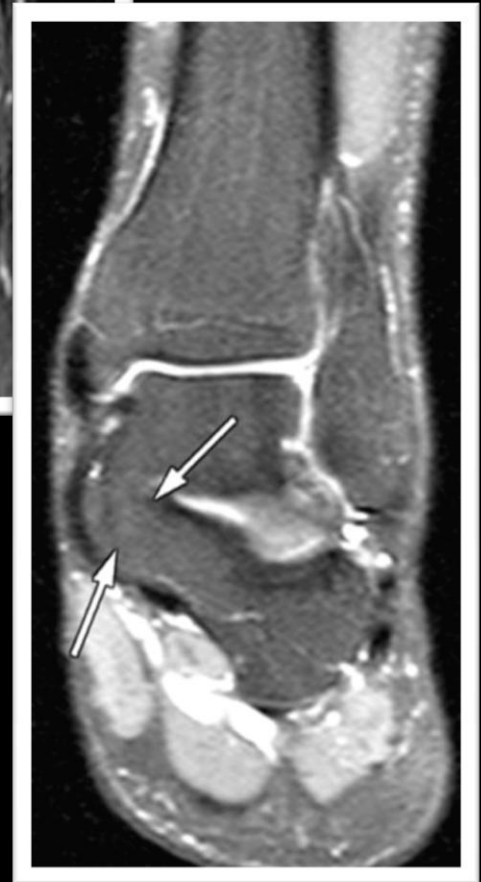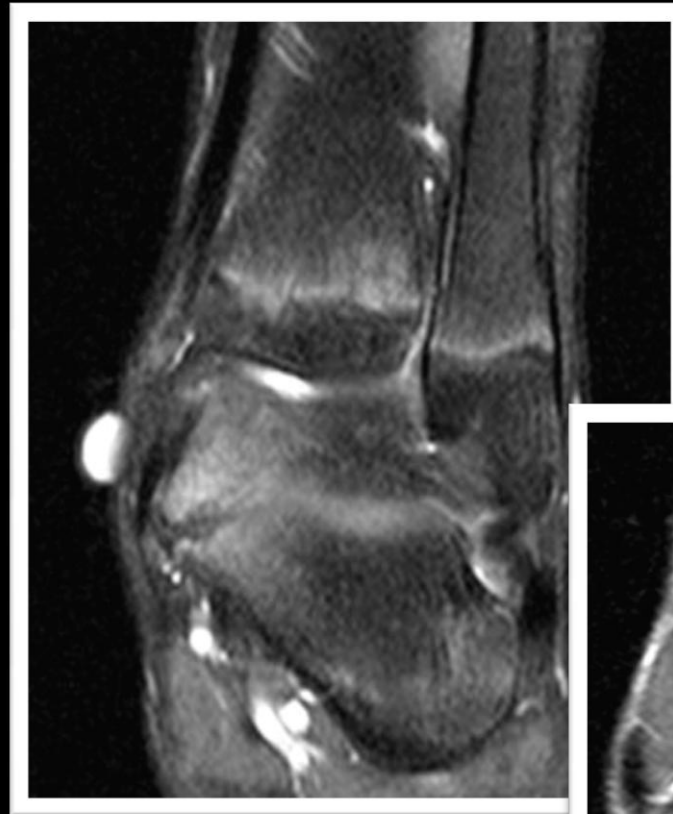Etiology -- Tarsal Coalition

- The generally accepted theory is that congenital coalition is caused by an autosomal dominant inheritance pattern with variable, if not nearly full penetrance that results in the failure of differentiation and segmentation of primitive mesenchyme
 - Review of first-degree relatives of patients who possessed symptomatic flatfoot found that 39% had asymptomatic coalitions
- Can be congenital or acquired
 - Acquired tarsal coalition may result from arthritis, infection, trauma, and neoplasms, among others

Tarsal Coalition

- Tarsal coalition is best thought of as a continuum, progressing from fibrous to osseous as the patient ages, often demonstrating different coexistent histologic stages

- Talonavicular coalitions begin to ossify in children aged 3-5 years
- Calcaneonavicular coalitions begin to ossify in children aged 8 – 12 years
- Talocalcaneal coalitions begin to ossify in adolescents aged 12 – 16 years



Tarsal Coalition

- Usually an isolated anomaly
 - Small fraction of coalitions are associated with carpal coalition, symphalangism (ankylosis of the phalangeal joints), clubfoot, Apert's syndrome, and fibular hemimelia (partial or total absence of the fibula)

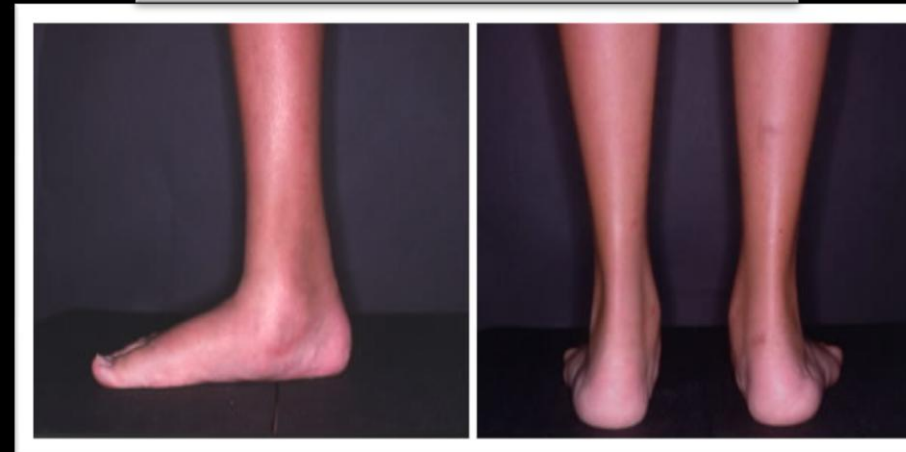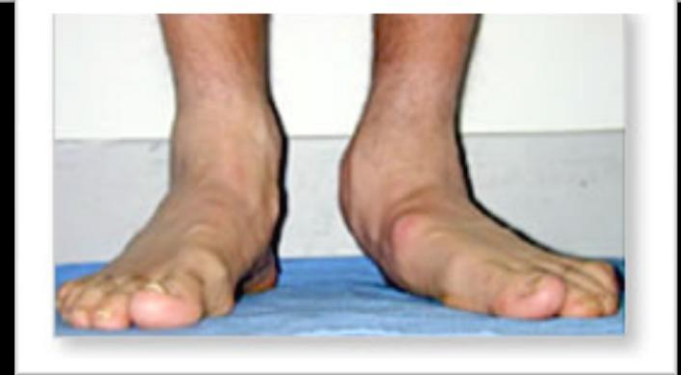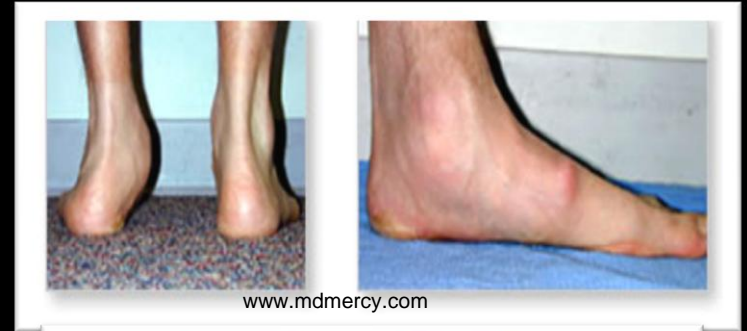Clinical Presentation

Prevalence – Tarsal Coalition

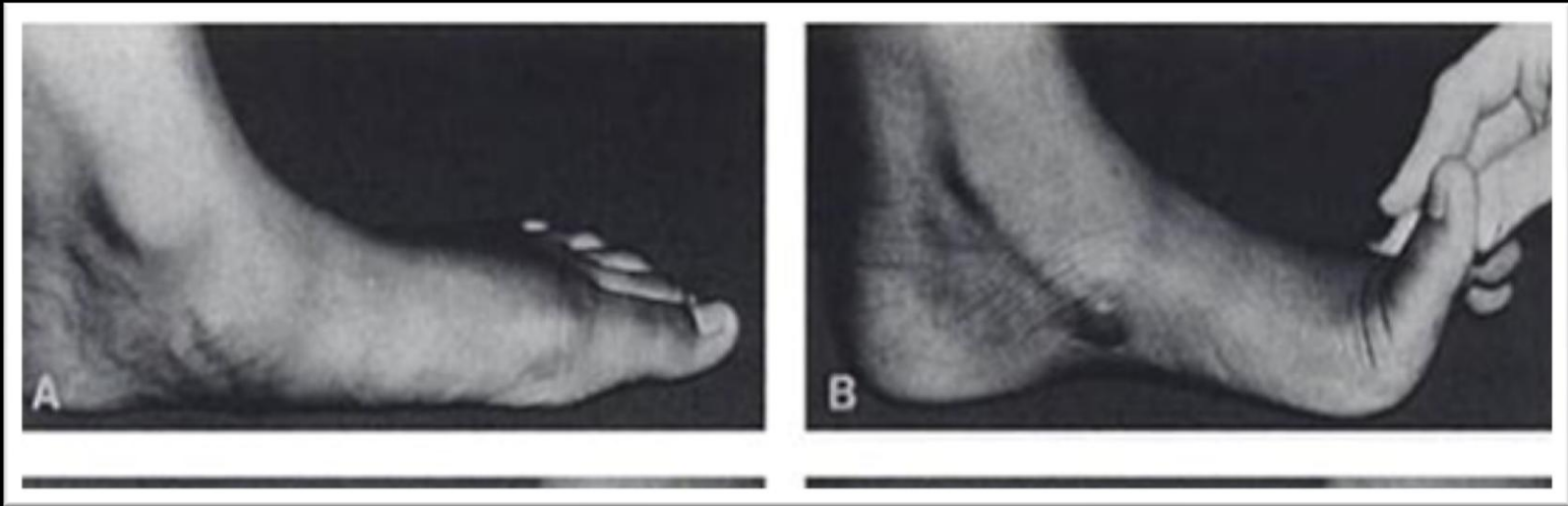
- True prevalence of tarsal coalition is not known
- Estimates range from far less than 1% of the population to approximately 1 - 2 %
- Probable slight male predominance
- Bilateral in 50% of patients
- Approximately 90% of all tarsal coalitions are talocalcaneal or calcaneonavicular coalitions with calcaneonavicular coalitions being more common

Clinical Presentation – Tarsal Coalition

- Clinical presentations are variable
- Usually presents in the second decade
- Symptoms may include:
 - Chronic pain
 - Rigid flat foot deformity (~ 50% of patients)
 - Peronal spastic flatfoot
 - History of recurrent ankle sprains
- Patients who are not highly active may present later in life and some affected individuals may never become symptomatic
- Complications include fracture, tendinosis/tenosynovitis, osteoarthritis

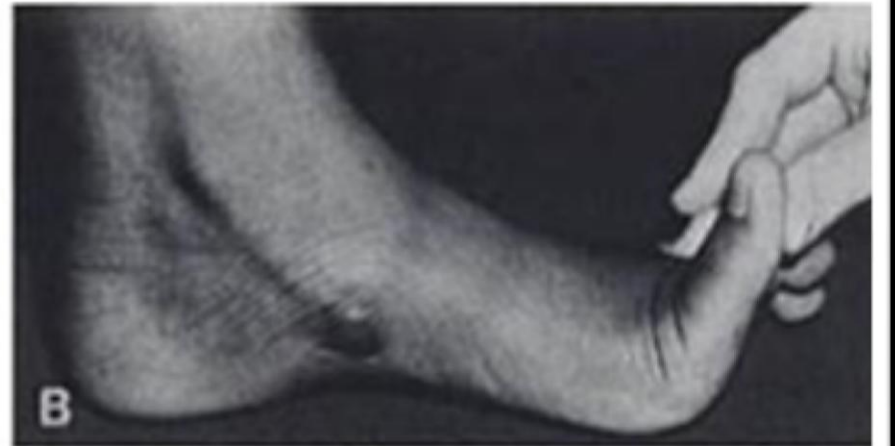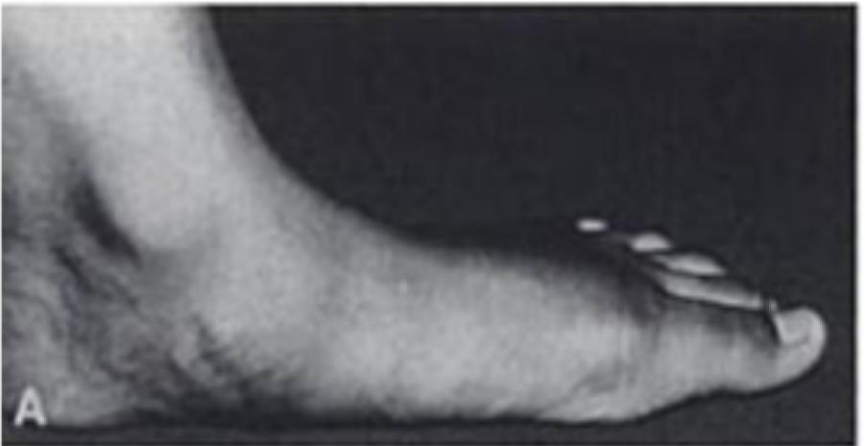
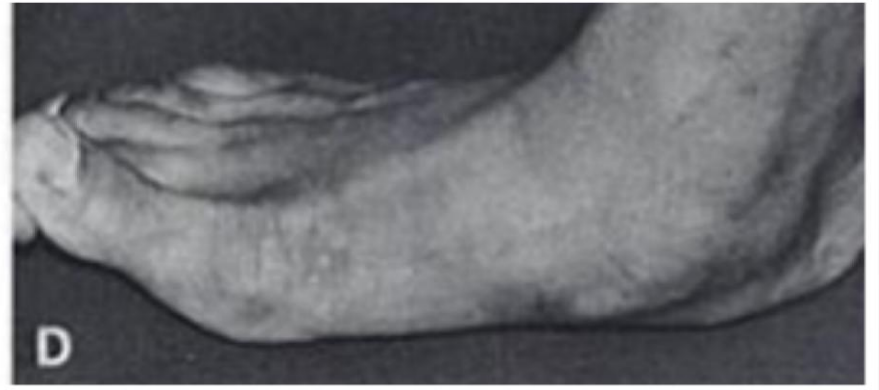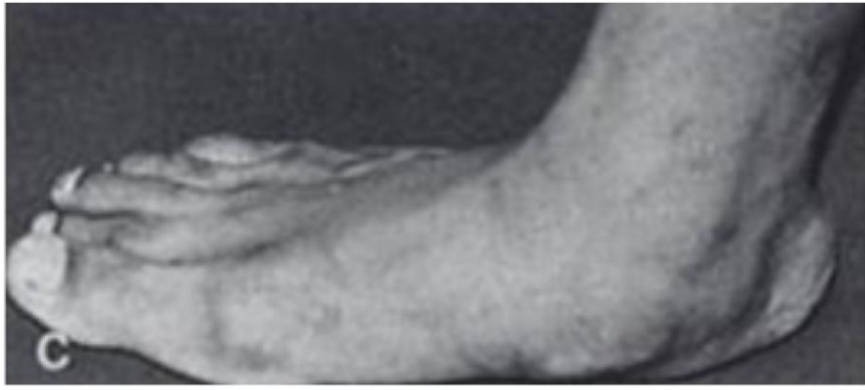


Clinical Presentation – Hubscher Maneuver

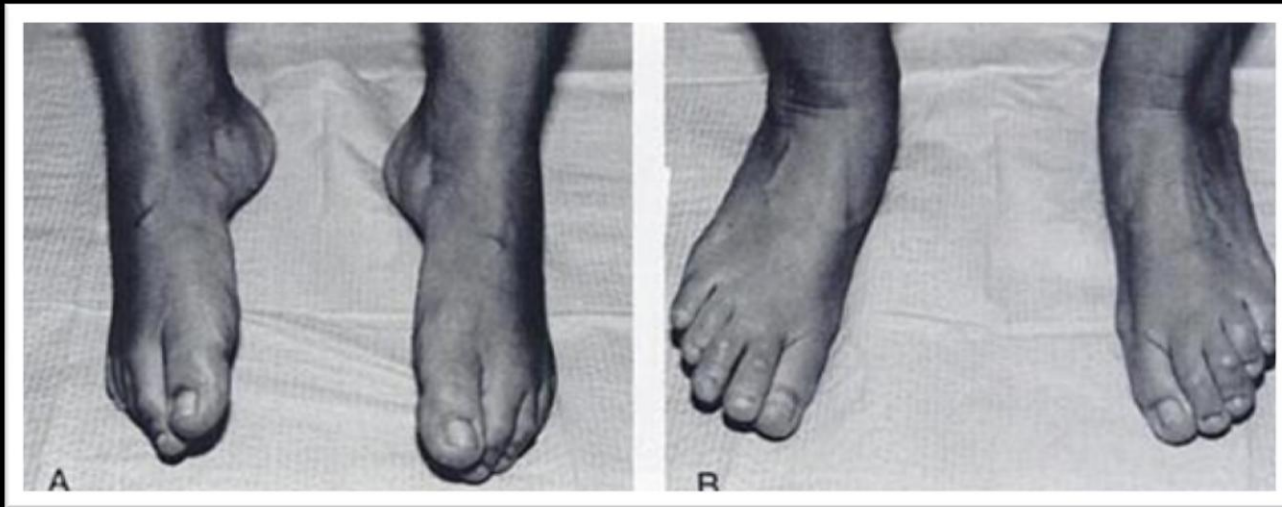


- If a pes valgo planus deformity is present (which is seen with the typical peroneal spastic flatfoot), the *Hubscher maneuver* or the *toe test of Jack* can be performed
- The Hubscher maneuver involves passive dorsiflexion of the hallux while the patient stands. When the hallux is dorsiflexed, the medial cord of the plantar aponeurosis and the flexor hallucis longus tendon are tightened
 - If the pes valgo planus deformity is flexible, as in the above photos, the medial longitudinal arch with increase in height and the hindfoot will supinate

Clinical Presentation – Hubscher Maneuver



Clinical Presentation

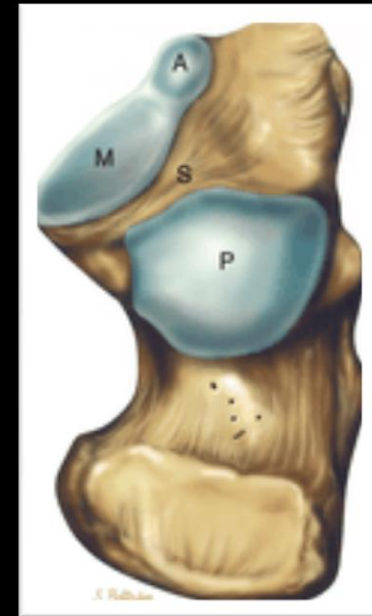

- Limitation of subtalar and midtarsal joint motion is common with tarsal coalition and is typically the most obvious clinical finding
- Active inversion and eversion movement of the foot can be evaluated. The flexibility demonstrated above strongly suggests a flexible pes valgo planus deformity and no tarsal coalition

ANATOMY

Anatomy – Calcaneus

- On its superior surface, there are 3 smooth facets: anterior, middle, and posterior facets
 - Talocalcaneal coalition most commonly involves the middle facet at the level of the sustentaculum tali
- These facets articulate with corresponding articular facets on the inferior surface of the talus to form 2 subtalar joints: Talocalcaneonavicular (Anterior) and Posterior subtalar joints
- The anterior and middle facets of the calcaneus are located on the medial side of the calcaneus and are sometimes continuous with each other
- The middle and posterior facets are separated by the sinus tarsi

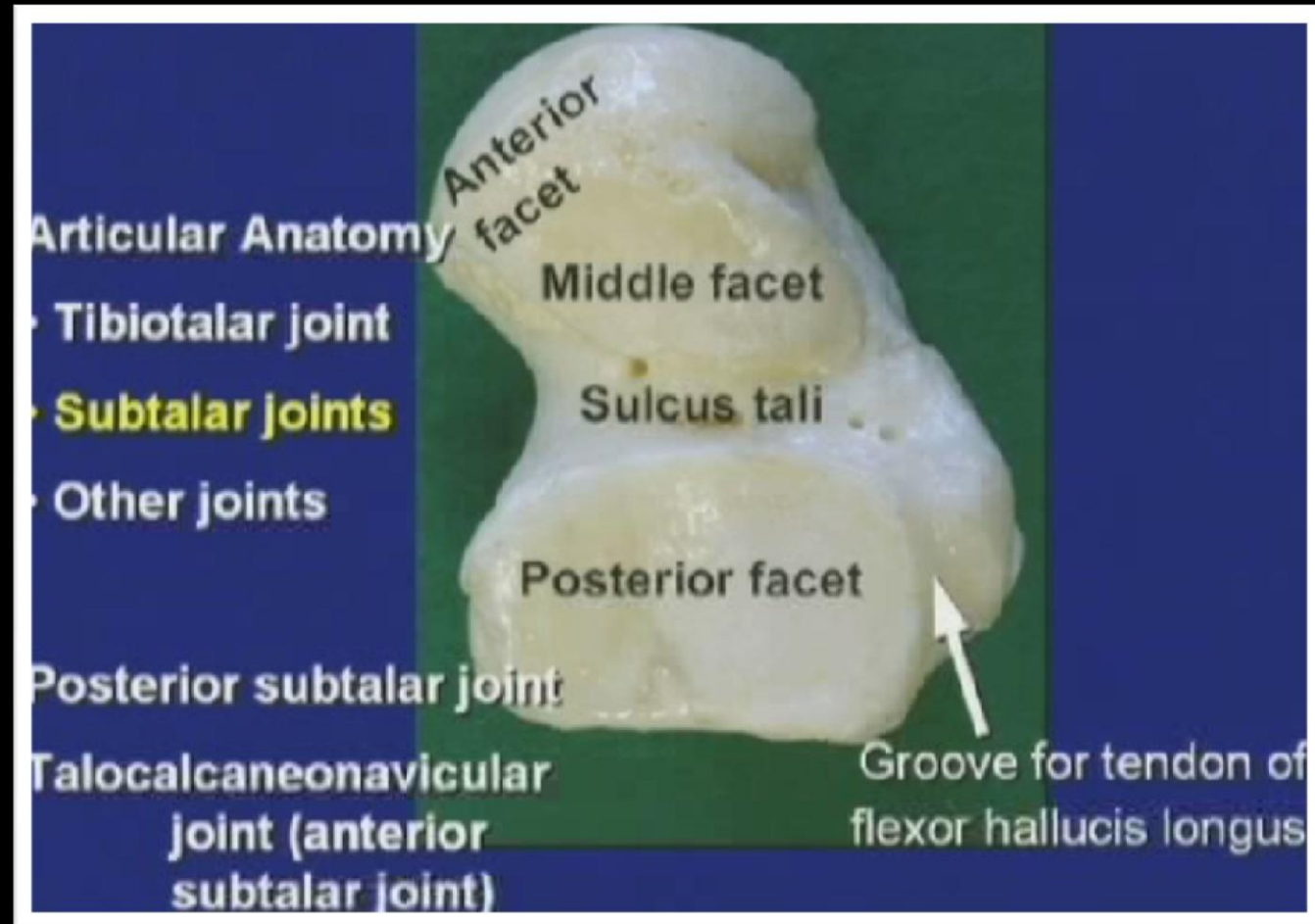


Drawing of the superior surface of the calcaneus demonstrates the anterior (A), middle (M), and posterior (P) facets of the calcaneus.

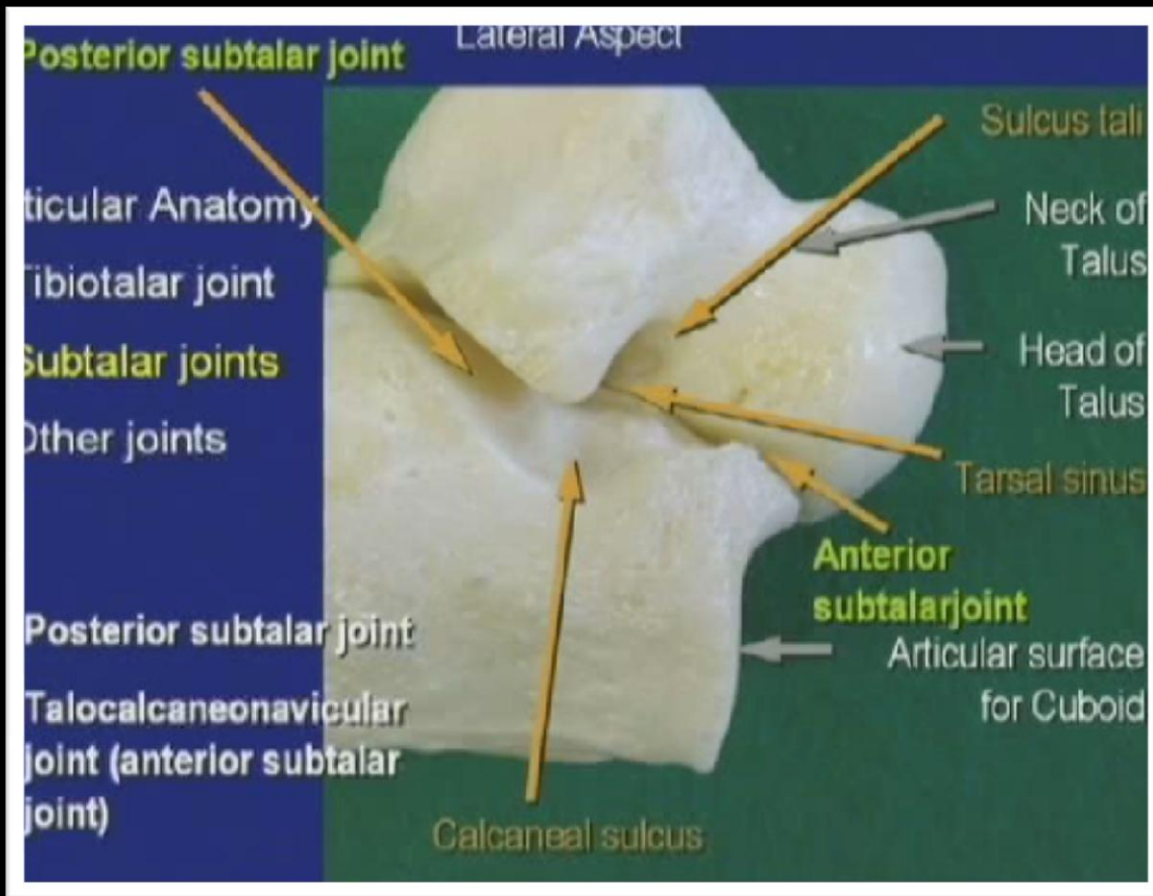
Daftary, et al. *Fractures of the Calcaneus: A Review with Emphasis on CT. Radiographics.* 9/2005. 1215-1226.

Anatomy – Talus

- Anterior and Posterior subtalar joints typically don't communicate with one another – usually indicative of abnormality of the supporting structures



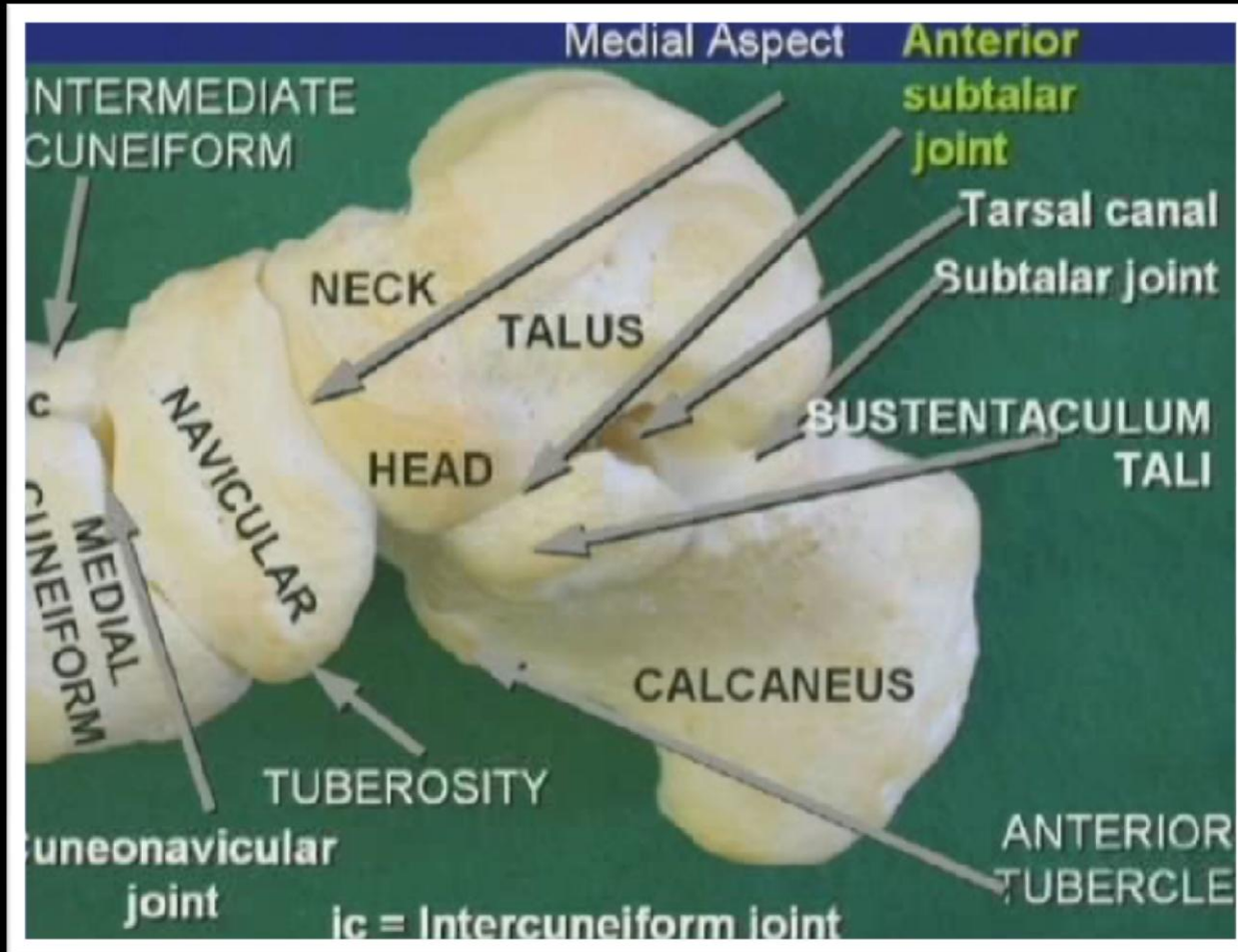
Anatomy – Talus



Lateral Aspect of the Ankle:

- Posterior Subtalar Joint
- Portion of the Anterior Subtalar Joint with anterior facets of the calcaneus and talus visualized

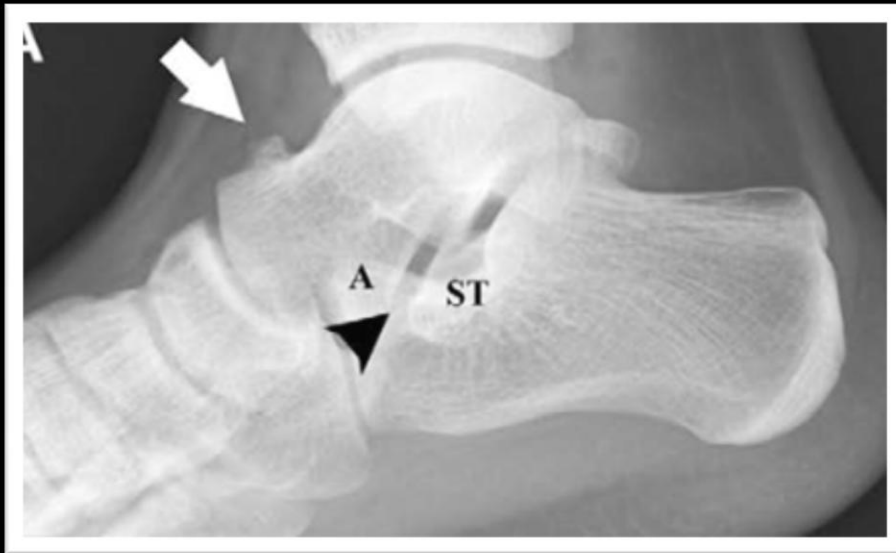
Anatomy – Talus



Medial Aspect of Ankle:

- Broad sustentaculum tali passes beneath the head of the talus
- Anterior subtalar joint extends vertically between the talus and navicular and then posteriorly over the sustentaculum tali to the sinus tarsi

Anatomy – Plain Radiography

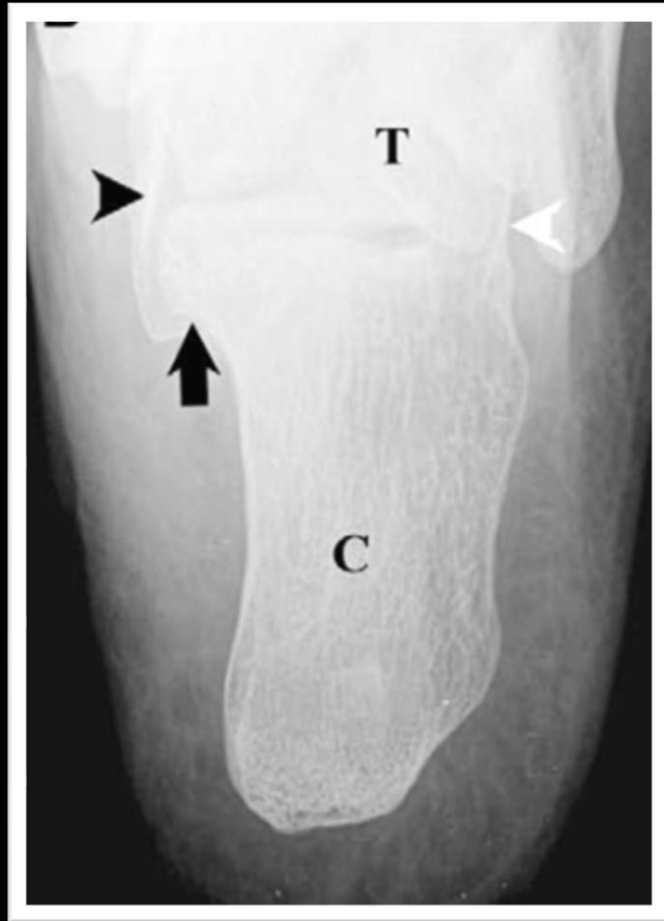


- Lateral radiograph demonstrates the normal appearance of the sustentaculum tali (ST), which forms a rectangle below the middle subtalar facet (arrowhead)

- Anterior process of the calcaneus (A) forms a triangle

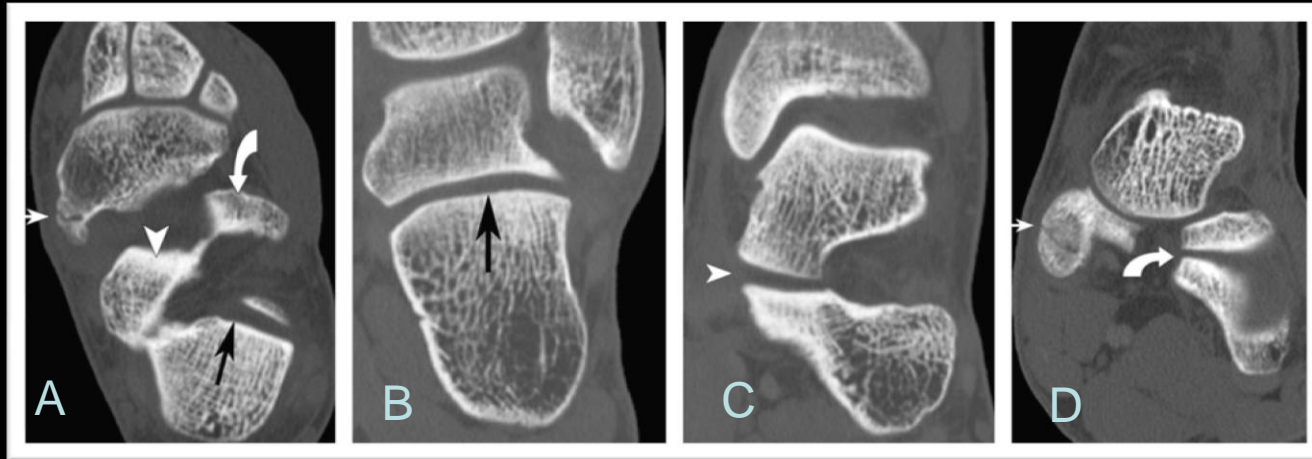
* *Caveat.* In the context of a flatfoot deformity, the anterior process may come close to the navicular, but it maintains its normal triangular contour as opposed to the squared contour seen in calcaneonavicular coalition

Anatomy – Plain Radiography



- Harris – Beath view demonstrates normal contours of the undersurface of the sustentaculum tali (*arrow*), the middle subtalar facet (*black arrowhead*), and the posterior subtalar facet (*white arrowhead*)

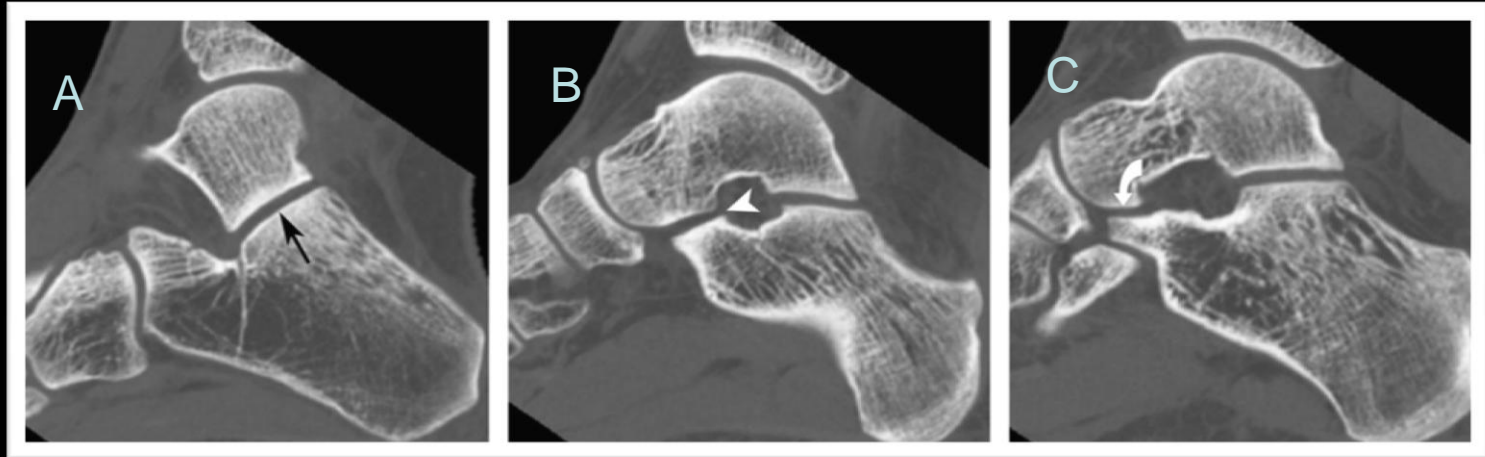
Anatomy – Axial and Coronal CT



CT with 3D Rendering of the Tendons of the Foot and Ankle: Technique, Normal Anatomy, and Disease. Choplin et al. RadioGraphics. March 2004, 24, 343-356.

- A. Axial – Posterior calcaneal facet (black arrow) well depicted at the level of the talocalcaneal articulations. Anterior (curved white arrow) and middle (arrowhead) facets not as well depicted
- B. Coronal – Posterior facet (black arrow)
- C. Coronal – Middle facet (white arrowhead)
- D. Coronal – Anterior facet (curved arrow)

Anatomy – Sagittal CT



CT with 3D Rendering of the Tendons of the Foot and Ankle: Technique, Normal Anatomy, and Disease. Choplin et al. RadioGraphics. March 2004, 24, 343-356.

- A. Posterior facet (black arrow)
- B. Middle facet (arrowhead)
- C. Anterior facet (curved arrow)

IMAGING

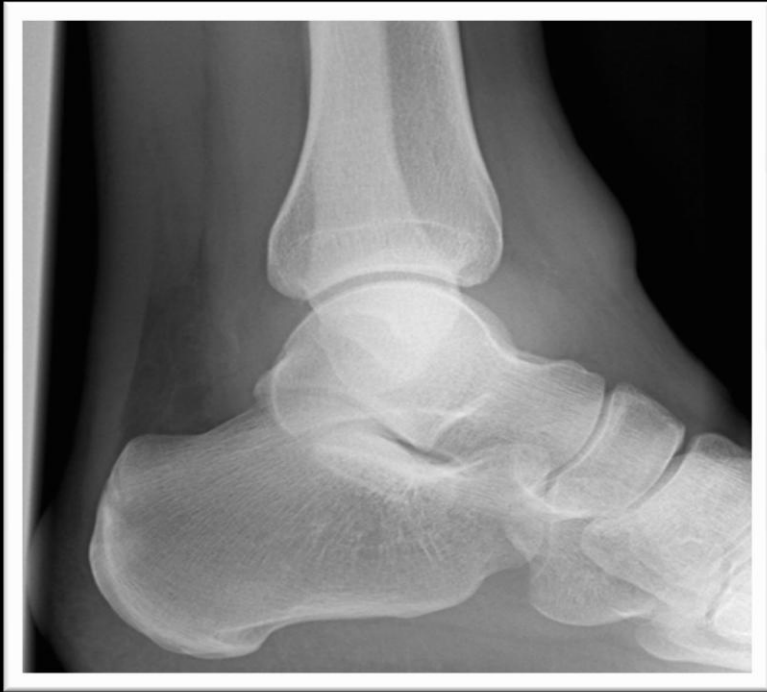Talocalcaneal Coalition

Imaging – Talocalcaneal Coalition

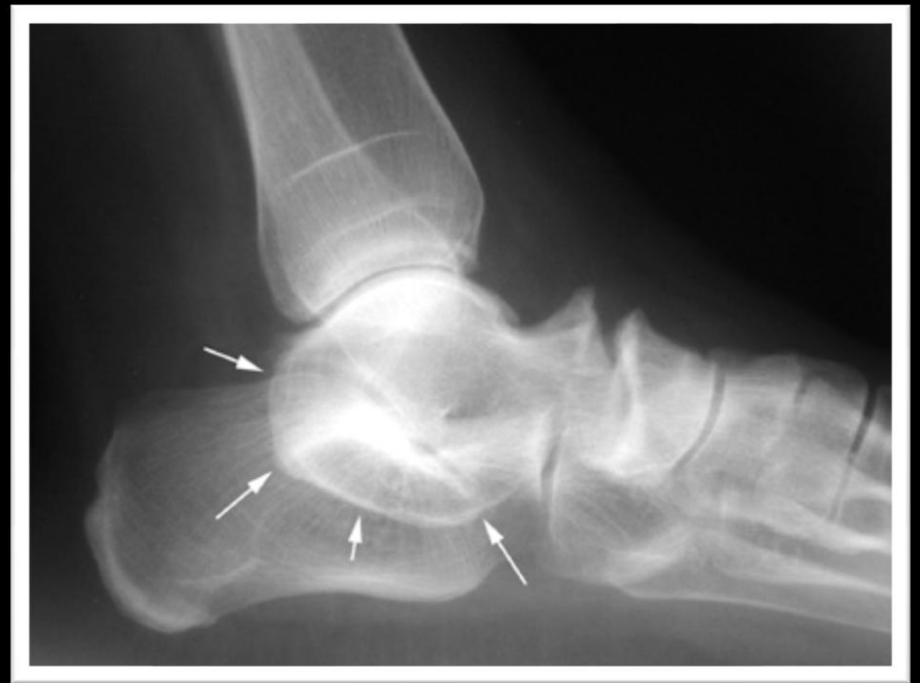Continuous C-Sign

- Formed by the medial outline of the talar dome and the inferior outline of the sustentaculum tali
- Normally, the C-line is not continuous and is broken by the posterior margin of the sustentaculum tali

Continuous C-Sign



Normal



Continuous C-Sign

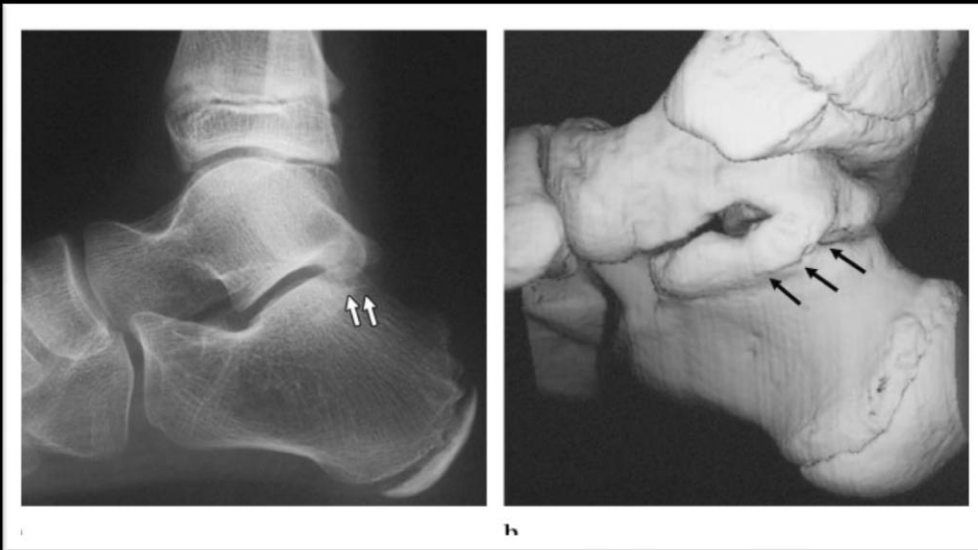
Akira Taniguchi, MD
Yasuhito Tanaka, MD
Kunihiko Kadono, MD
Yoshinori Takakura, MD

C Sign for Diagnosis of Talocalcaneal Coalition¹

Radiology 2003, 228: 501 - 505

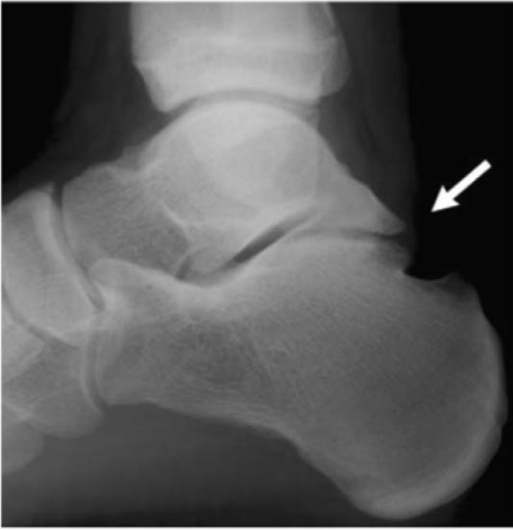- Concluded that the C Sign was useful only in patients with a talocalcaneal coalition of large size and in those with mature bones
 - Studied 41 patients with talocalcaneal coalitions and 41 controlled subjects matched according to sex and age
 - Overall sensitivity of the C sign was 49% and specificity was 91%
 - Sensitivity of the C sign in patients younger than 12 years of age was as small as 5% (vs. 70% sensitivity in patients 21 years and older)

- This study also evaluated the diagnostic value of joint irregularity.
 - Sensitivity and specificity of joint irregularity for the diagnosis of coalition were high and were considered to be useful.

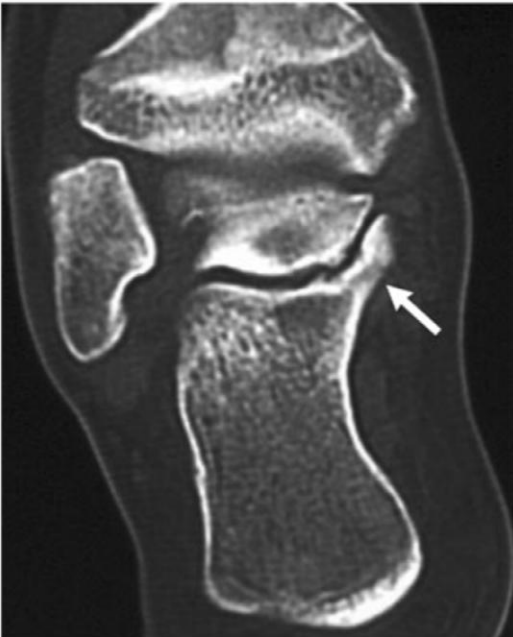

Lateral Radiograph: Slight irregularity in the posteromedial portion of the posterior talocalcaneal joint.

3D CT Image: Confirmation of the talocalcaneal coalition.

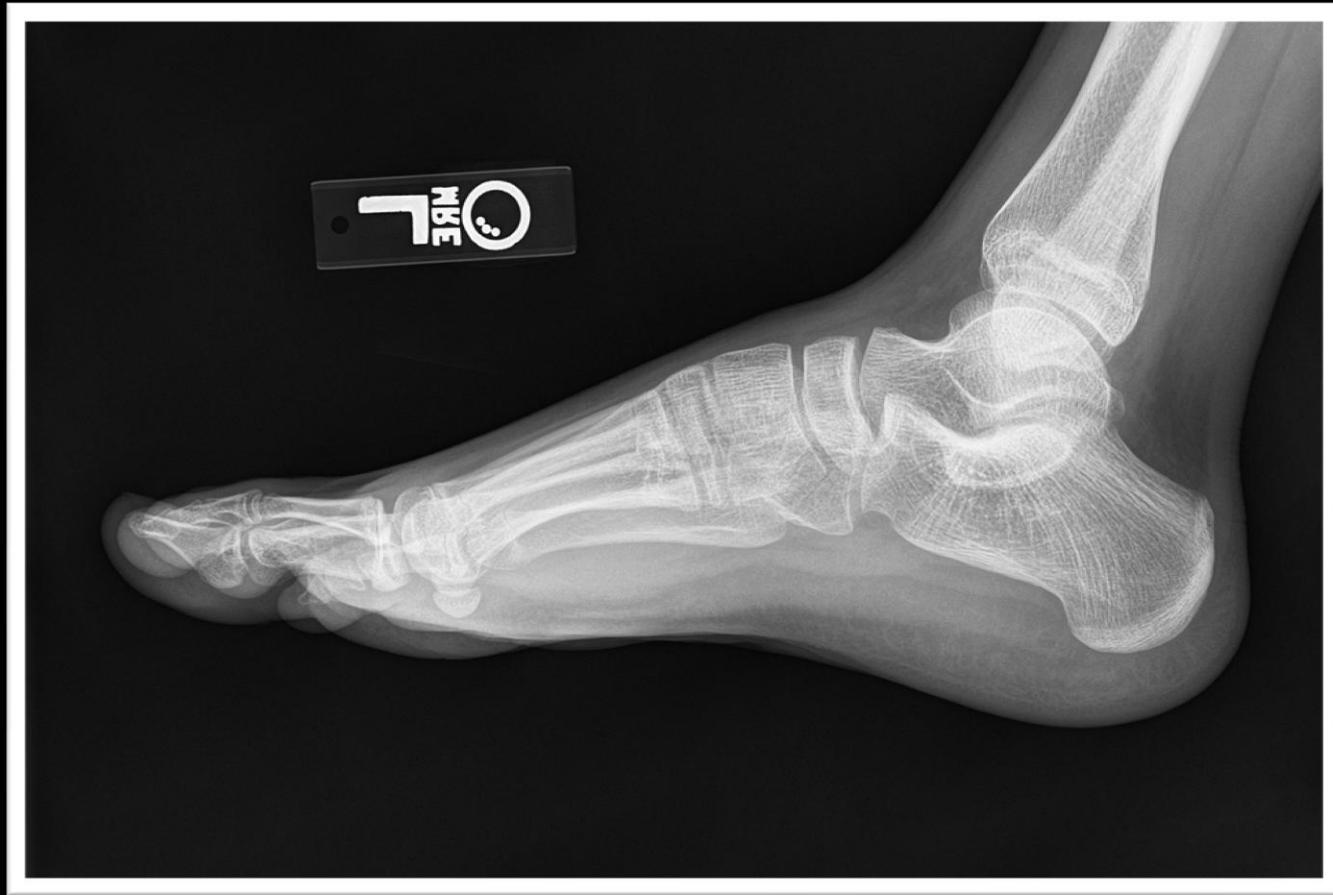

Lateral radiograph: Irregularity involving the posterior portion of the posterior subtalar joint.



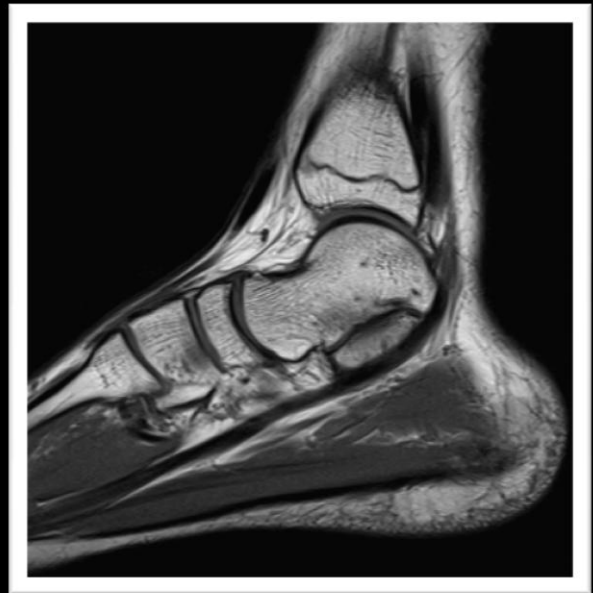
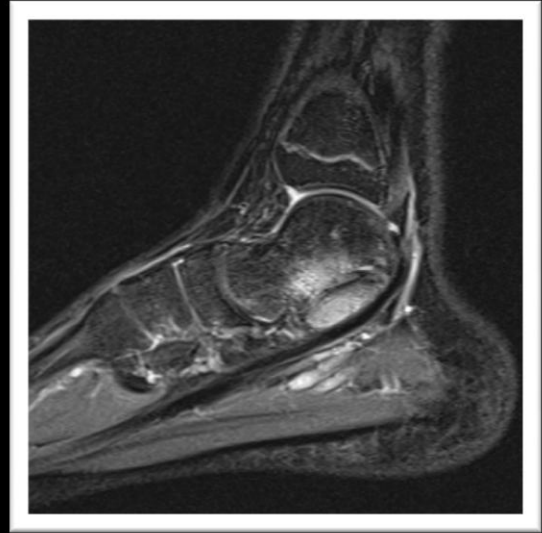
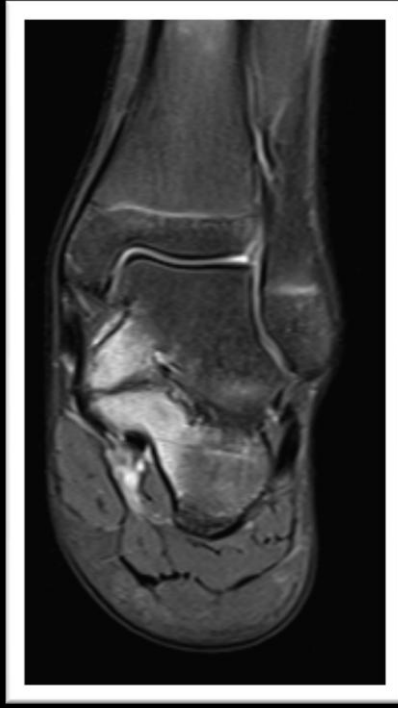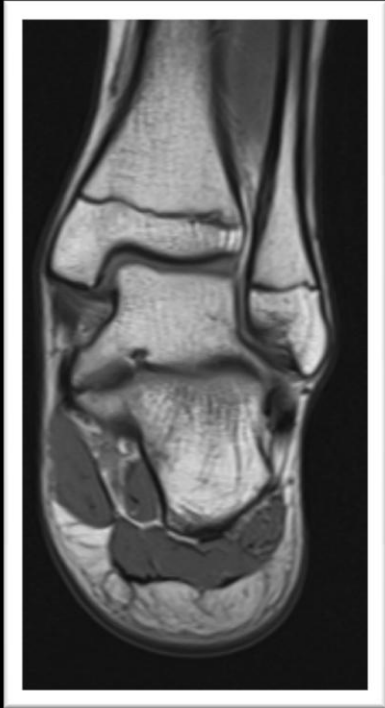Coronal CT Image: Talocalcaneal coalition.

Example



15 year old male from Scripps with foot pain

Example

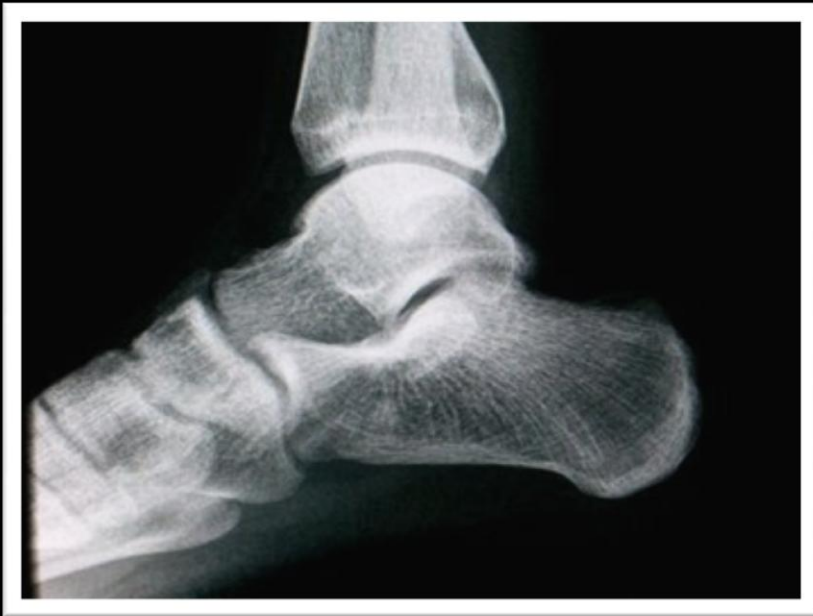

Imaging – Talocalcaneal Coalition

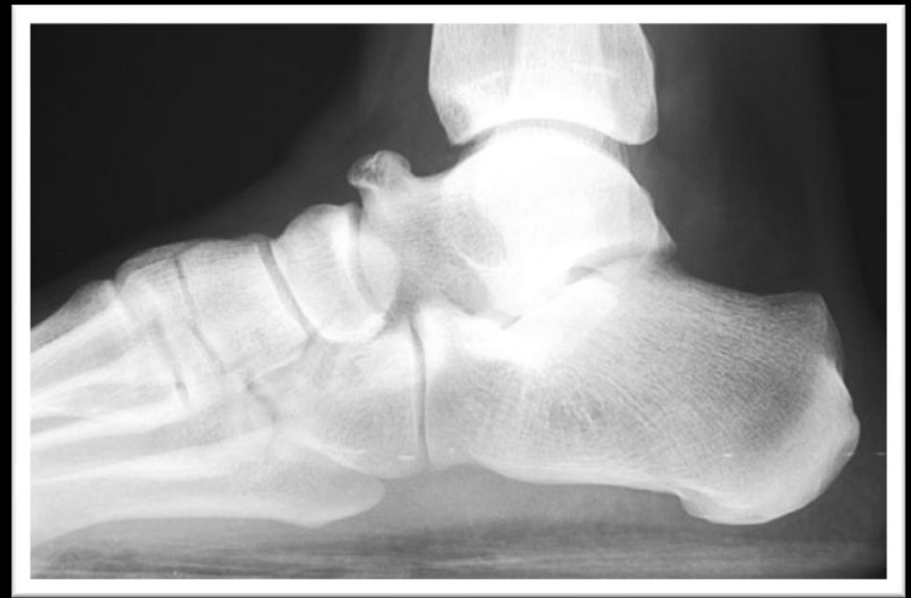Talar Beaking

- Produced by dorsal subluxation of the navicular secondary to subtalar rigidity
- Results in elevation of the periosteum below the talonavicular ligament along with subperiosteal proliferation and the production of a “beak” at the dorsal surface of the talar head
- Can be seen with either a talonavicular or a calcaneonavicular coalition
- Nonspecific but may be seen in other conditions associated with abnormal motion at the talonavicular joint (i.e. rheumatoid arthritis)

Talar Beaking

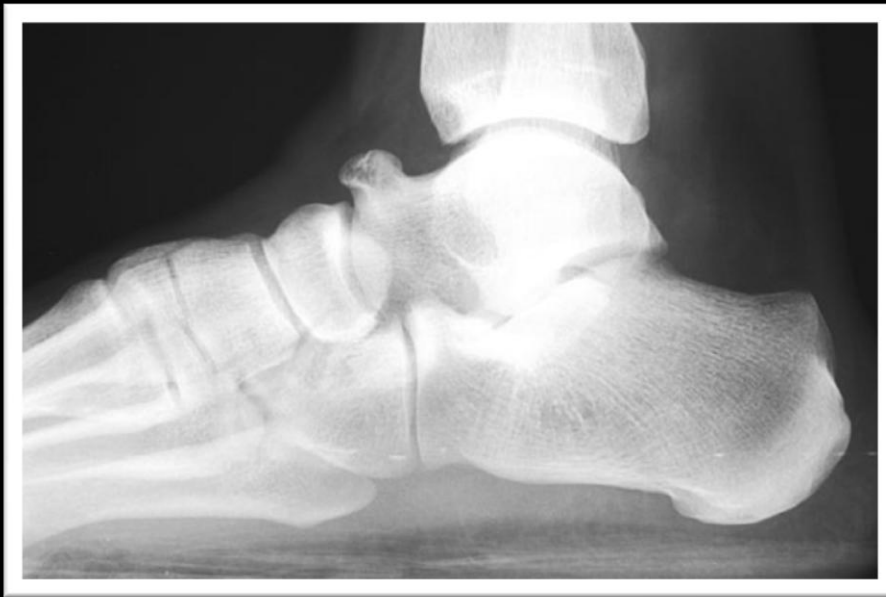

Normal



Talar Beaking

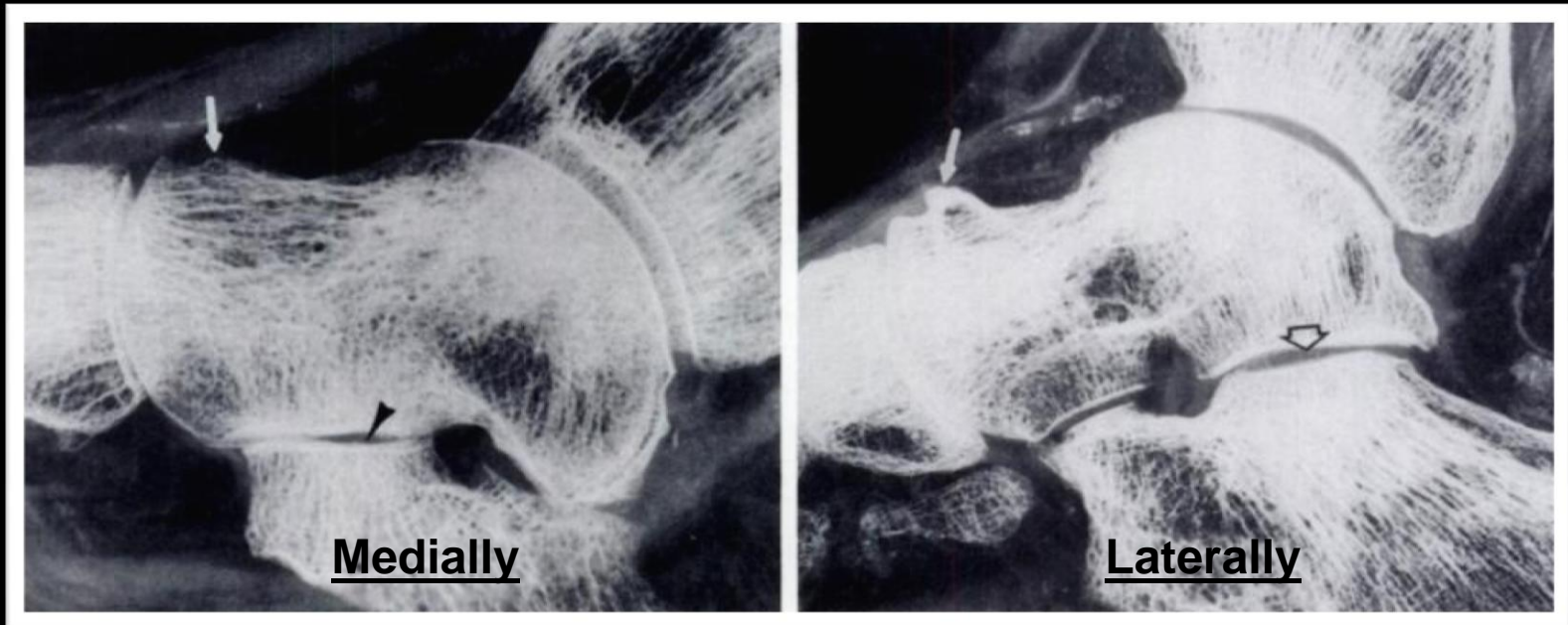
Three Different Types of Prominences on the Dorsal Margin of the Distal Talus



1.) Talar Beak

- Can indicate coalition
- Usually large and triangular in shape
- Arises in the region of the talar ridge, slopes distally, and ends at or near the articular margin of the talonavicular joint
- Flares upward and away from the navicular

Three Different Types of Prominences on the Dorsal Margin of the Distal Talus

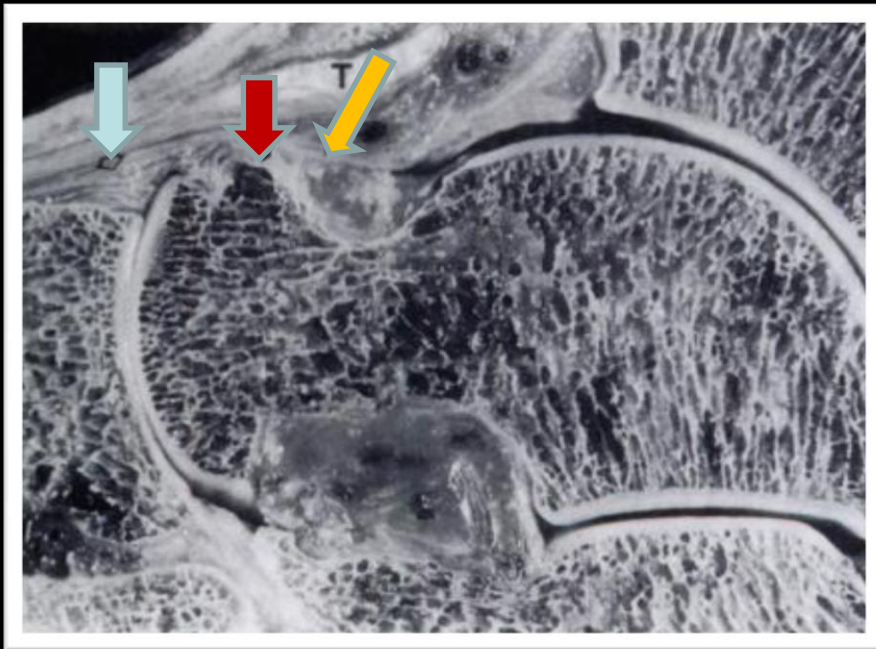


Resnick, D. Talar ridges, osteophytes, and beaks: A radiographic commentary. Radiology 151. (2): 329 – 332. 1984.

2.) Talar Ridge

- Normal variant
- Located at the normal osseous anterior attachment of the tibiotalar joint capsule
- Centered more proximally on the talar neck -- located several millimeters from the articular surface of the talar head
- More prominent laterally than medially

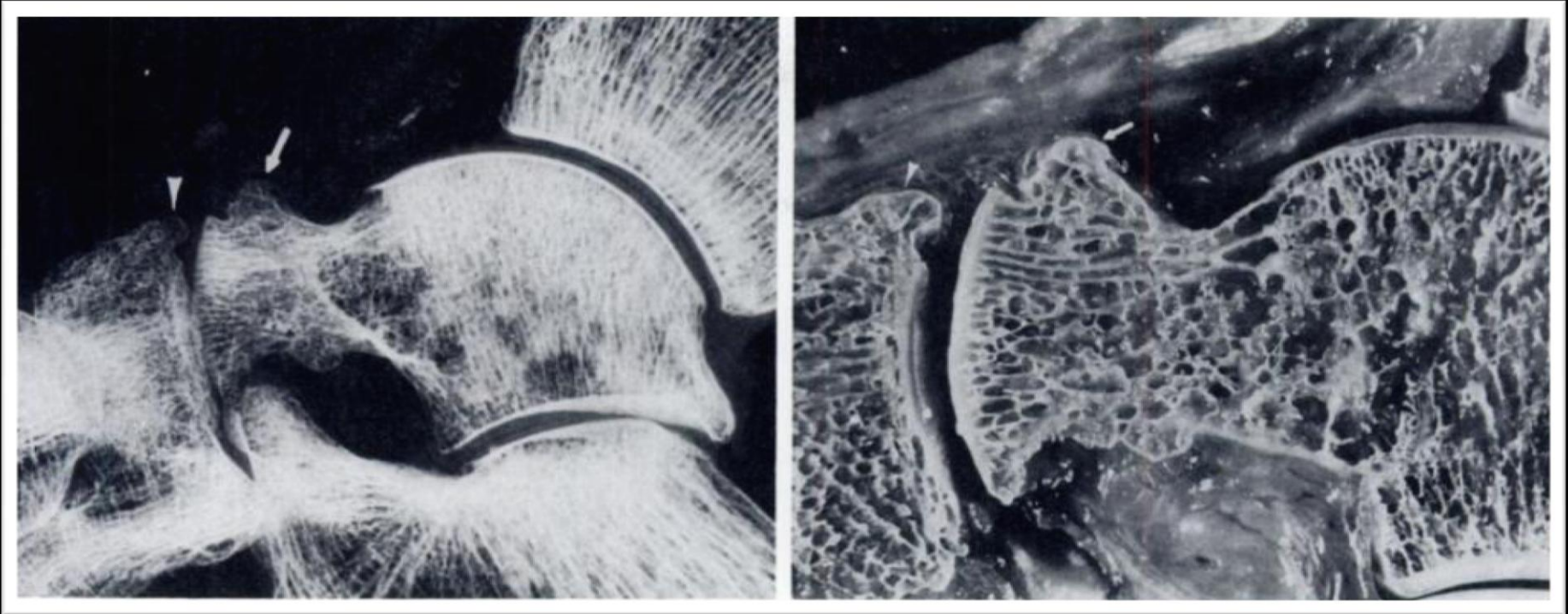
Three Different Types of Prominences on the Dorsal Margin of the Distal Talus



2.) Talar Ridge

- A photograph of the previous cadaveric foot demonstrating the talonavicular ligament (blue arrow) and capsule of the talocrural joint (yellow arrow) extend to the talar ridge (red arrow). The anterior tibialis tendon (T) is also seen

Three Different Types of Prominences on the Dorsal Margin of the Distal Talus

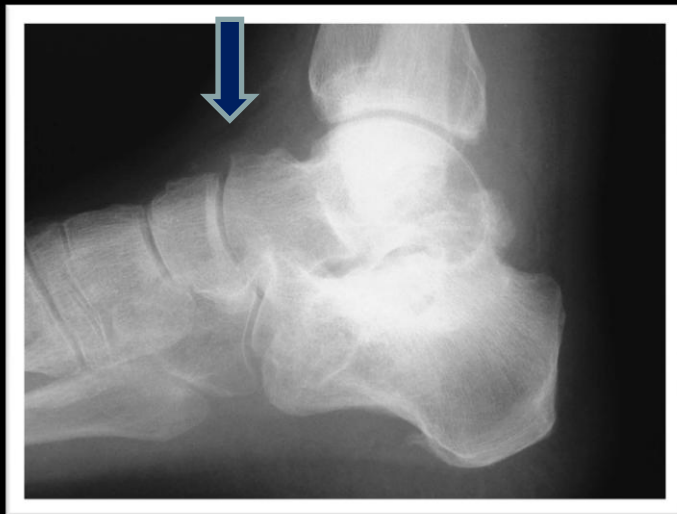
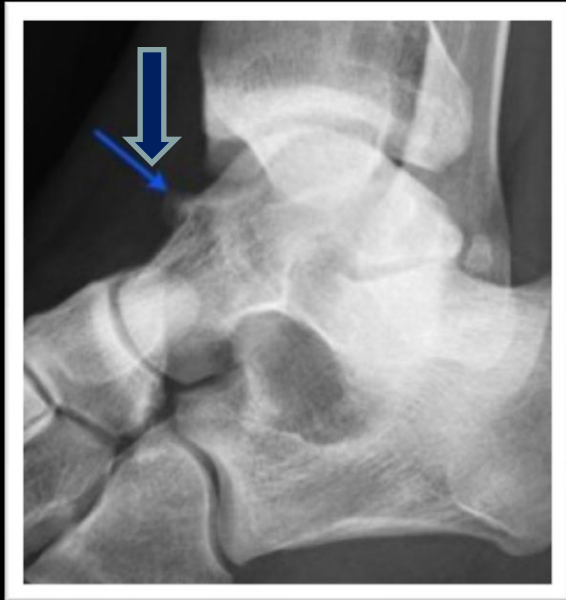
Resnick, D. Talar ridges, osteophytes, and beaks: A radiographic commentary. *Radiology* 151. (2): 329 – 332. 1984.

2.) Talar Beak – Hypertrophied

- Talar ridge can hypertrophy as a response to abnormal traction related to the capsular or ligamentous attachments.
- Generally only differs in size from the normal talar beak – located several millimeters from the talar head articular surface
- Occurs in American football players, rugby players and ballet dancers as well as within DISH

Three Different Types of Prominences on the Dorsal Margin of the Distal Talus



3.) Talar Osteophytes

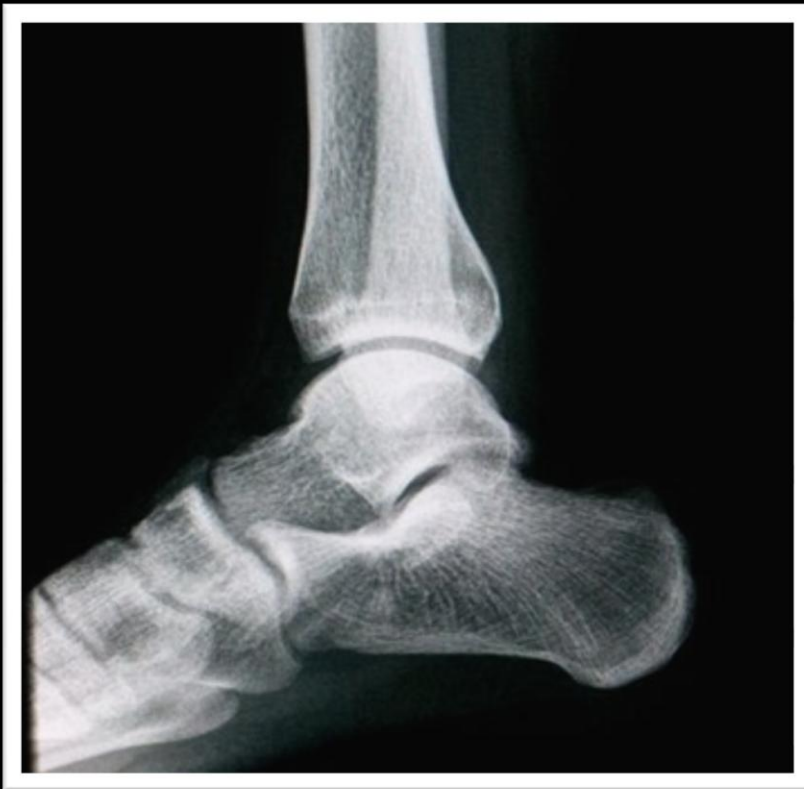- Can be apparent at the distal margin of the trochlea
- Not uncommon in athletes, especially baseball catchers – abnormal compression of apposing surfaces of talus and tibia due to forced dorsiflexion that occurs during squatting
- Can also be seen in the distal talus at the margin of the talonavicular joint in association with osteoarthritis – usually small and do not extend to the area of the talar ridge
- Look for accompanying dorsal navicular osteophytes

Imaging – Talocalcaneal Coalition

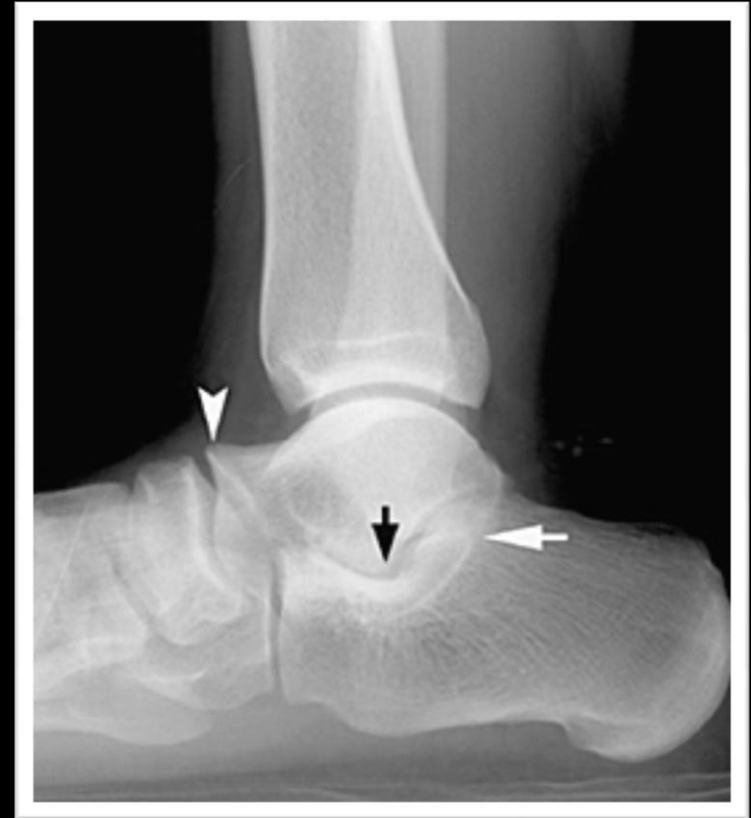Broadening of the Lateral Process of the Talus

- Present in 40 – 60% of patients with talocalcaneal coalition
- Thought to be related to valgus angulation of the talus

Broadening of the Lateral Process of the Talus



Normal



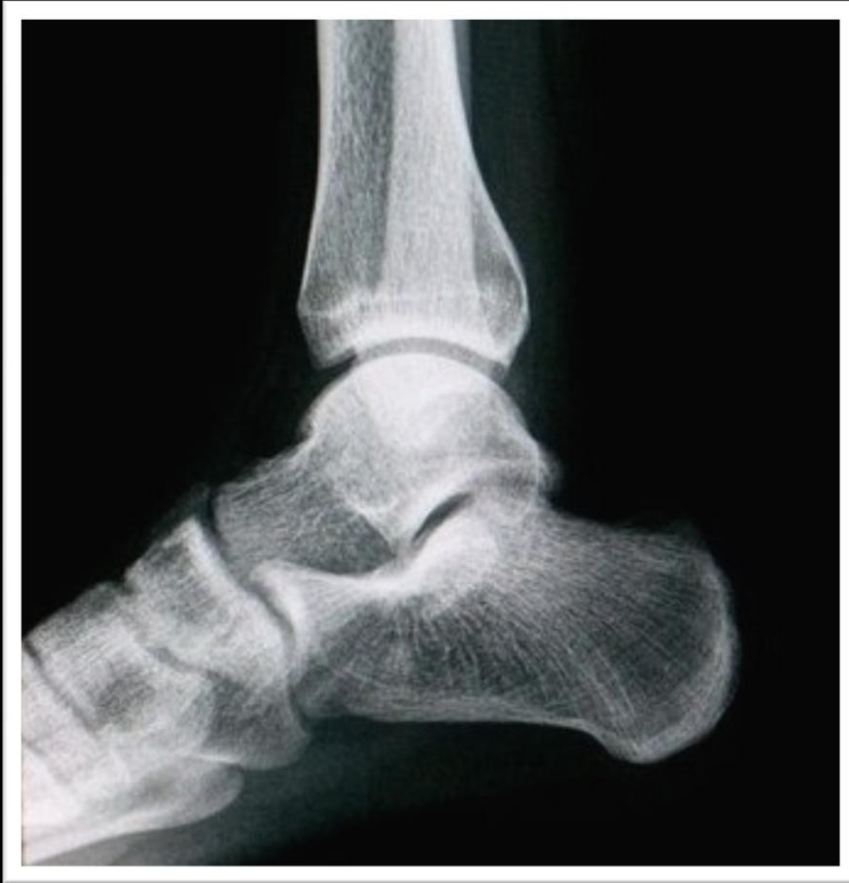Broadening of the Lateral Process of the Talus

Imaging – Talocalcaneal Coalition

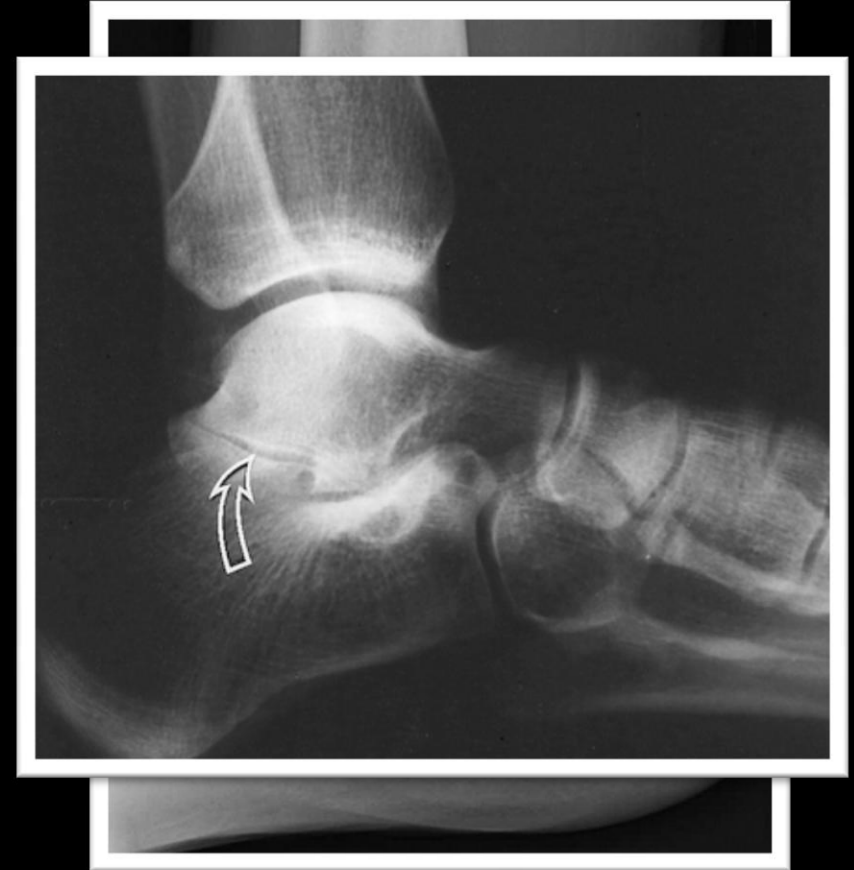Narrowing of the Posterior Subtalar Joint

- Can be seen in up to 50 – 60% of patients with or without secondary signs of coalition
- Represents degenerative arthritis or a non-tangential position of the articular surface as a result of calcaneal eversion

Narrowing of the Posterior Subtalar Joint



Normal



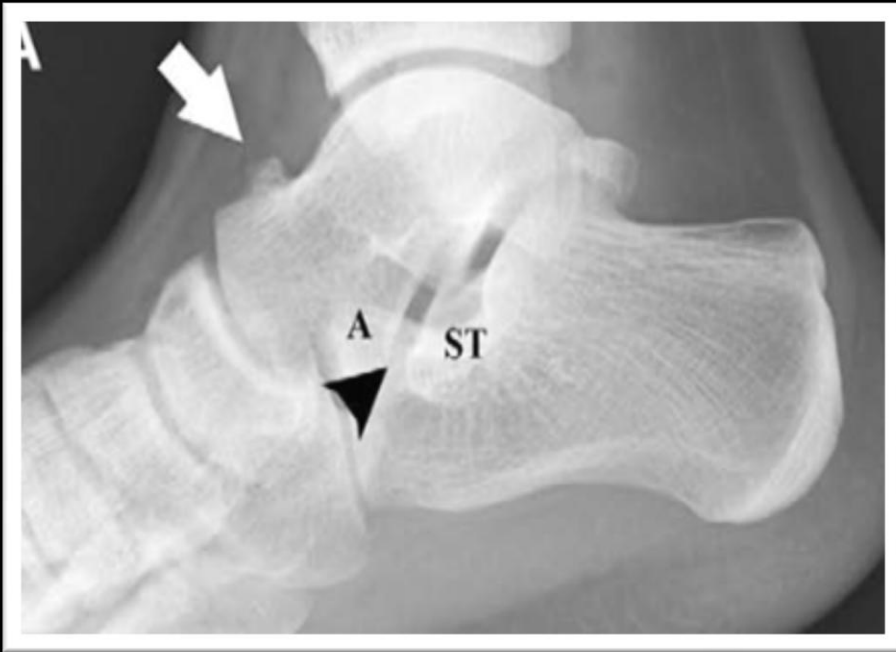Posterior Subtalar Joint
Narrowing

Imaging – Talocalcaneal Coalition

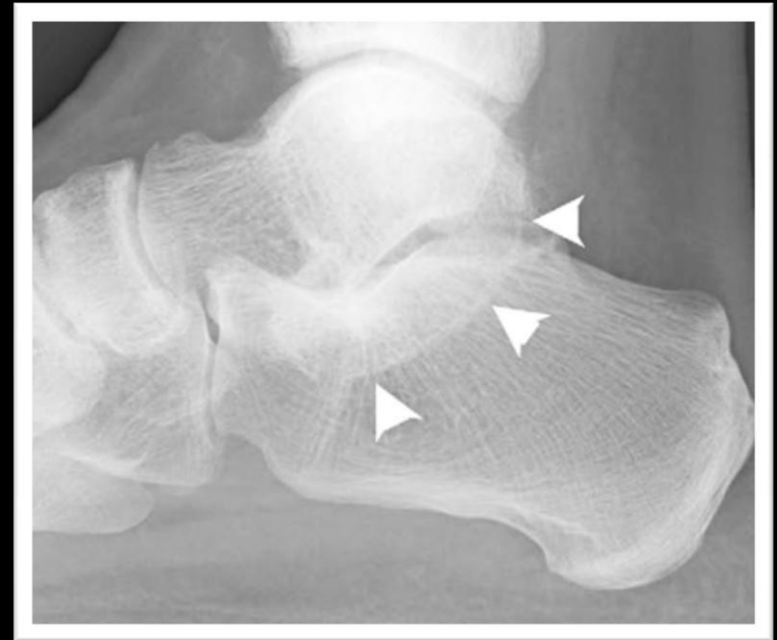Absent Middle Facet Sign

- Normally, the middle facet articular surfaces and the joint space between them are visible in the normal foot on a well-positioned lateral radiograph
 - Posterior subtalar joint must be well seen in profile
- This joint space is not visible in cases of subtalar coalition due either to a complete bony bar or to the obliquity of the narrow cleft between the bones in a nonosseous coalition
- Reported sensitivity and specificity range from 75% and 90%, respectively

Absent Middle Facet Sign



Normal



Absent Middle Facet Sign

Imaging – Talocalcaneal Coalition

Concave Undersurface of the Talar Neck and Asymmetry of the Talocalcaneal Joint

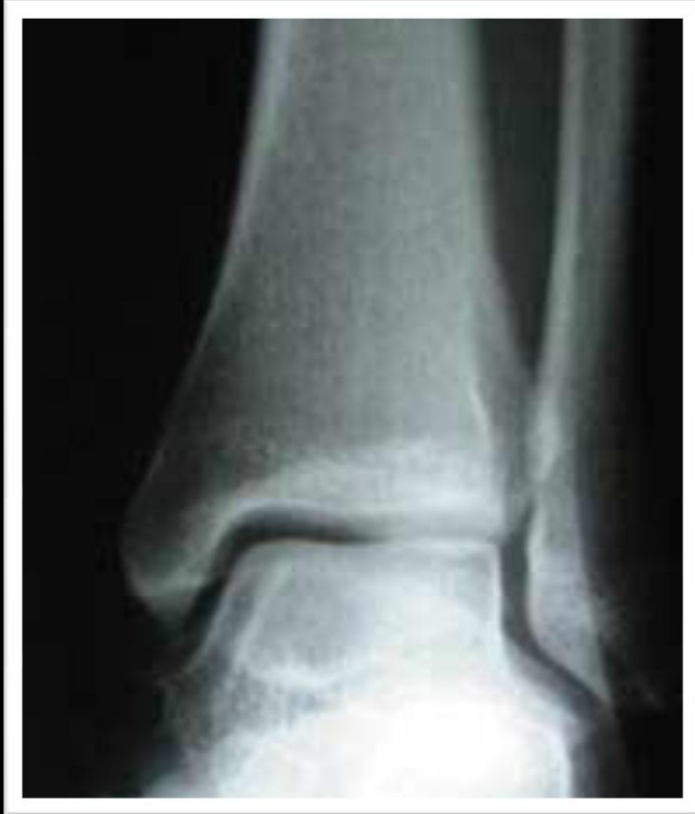- Comparison views are helpful for detection of this sign

Imaging – Talocalcaneal Coalition

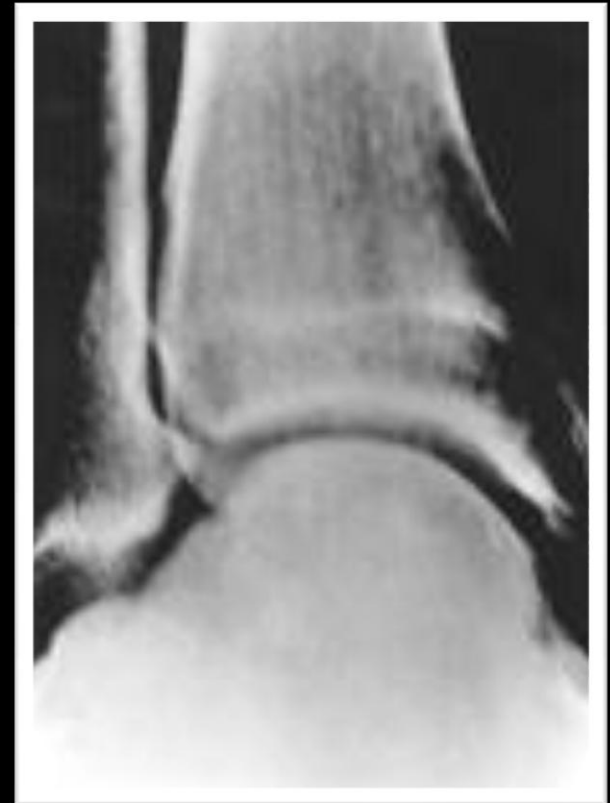Ball – and- Socket Ankle Joint

- Presumably resulted from an adaptation of the ankle joint to provide inversion and eversion function that is restricted at the talocalcaneal articulation
- Usually fully developed by 5 years of age
- Secondary osteoarthritis may appear later in a ball-and-socket joint
- Ball-and-socket joint may accompany other congenital anomalies, such as genu valgum, hypoplasia/aplasia of the fibula, absence or fusion of rays, and short extremities
- Ball-and-socket joint may also result from acquired midfoot disorders

Ball-And-Socket Joint

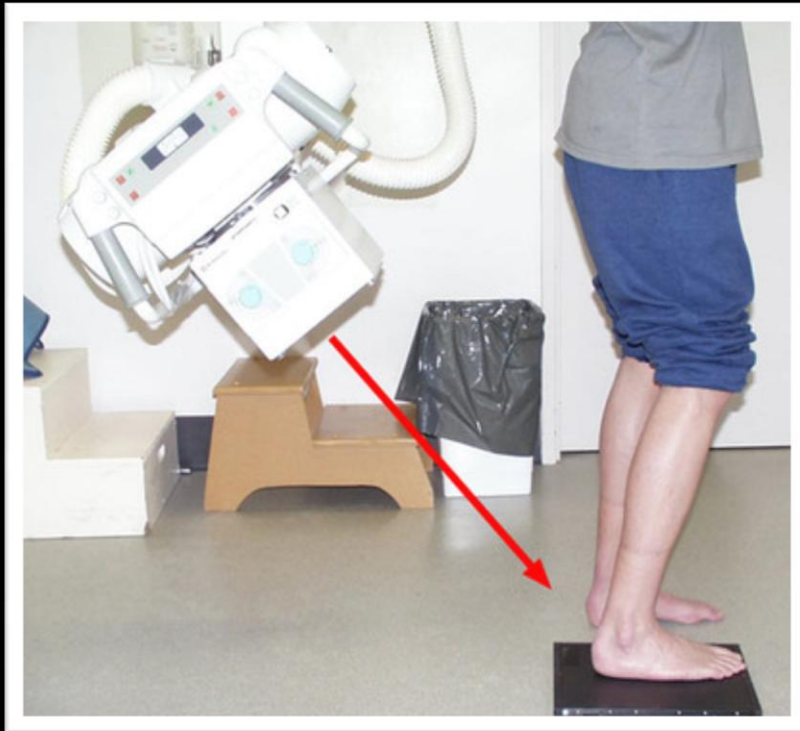

Normal



Ball-And-Socket Joint

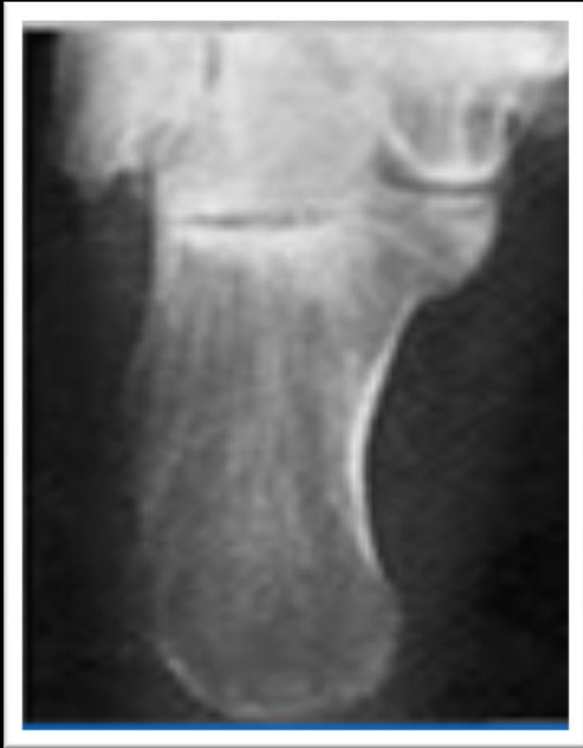Imaging – Talocalcaneal Coalition



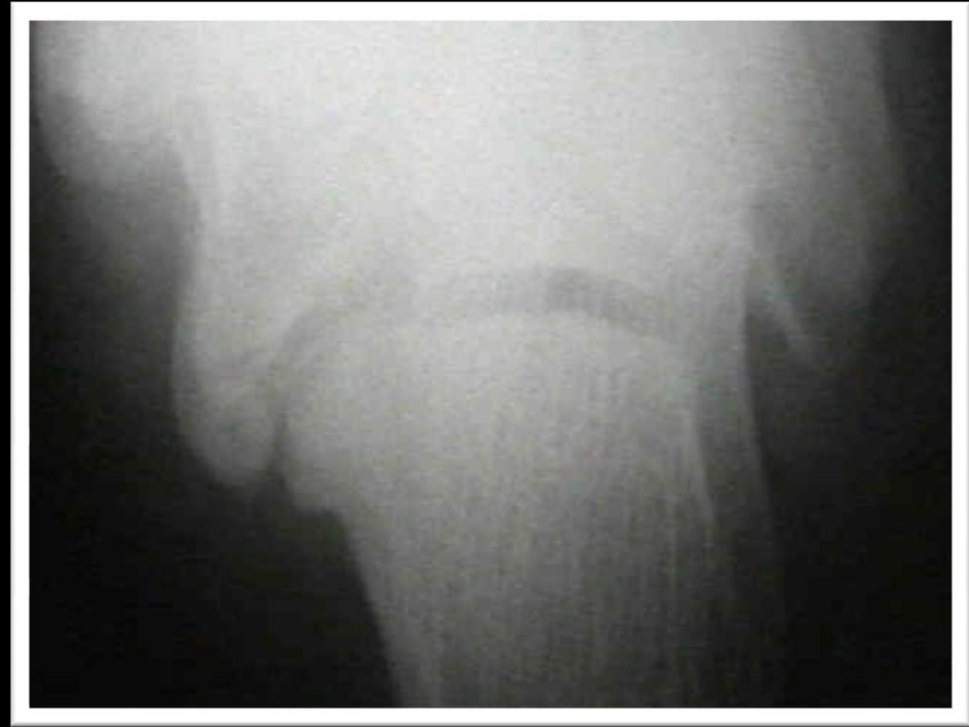Harris-Beath View:

- Demonstrates the calcaneal body, middle and posterior facets of the subtalar joints
- Patient Position: Patient is erect with knee slightly bent; the foot flat on the cassette
- X-Ray beam is directed 45° toward the midline of the calcaneus

Talocalcaneal Coalition – Harris-Beath View

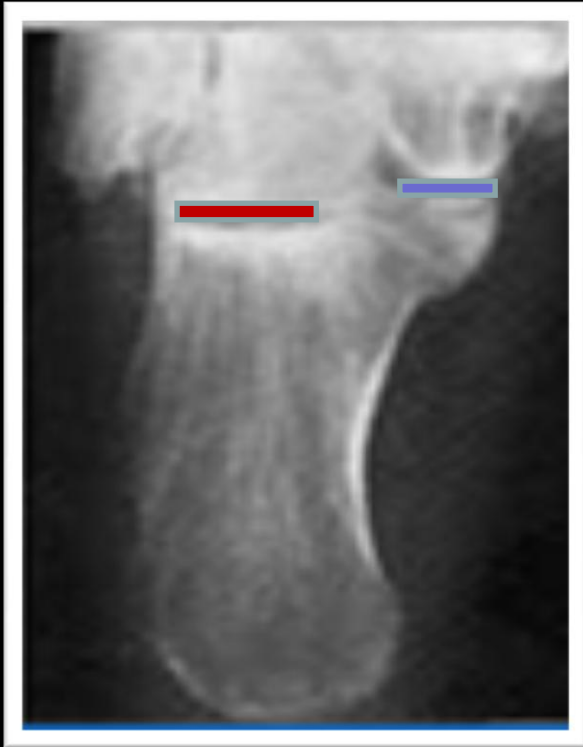

Normal

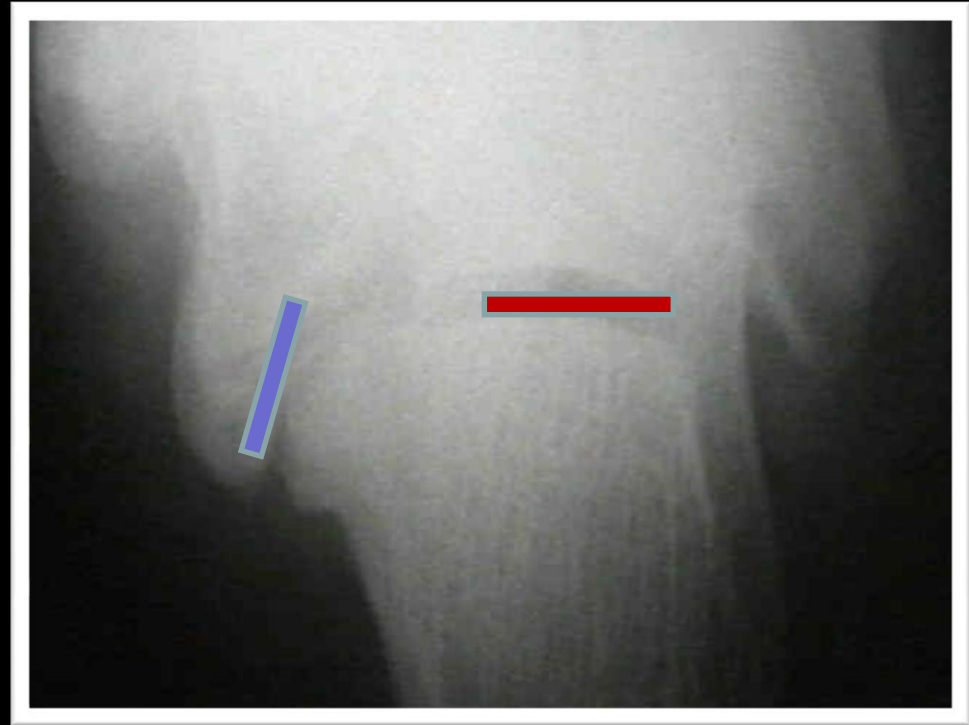


Talocalcaneal Coalition

Talocalcaneal Coalition – Harris-Beath View



Normal

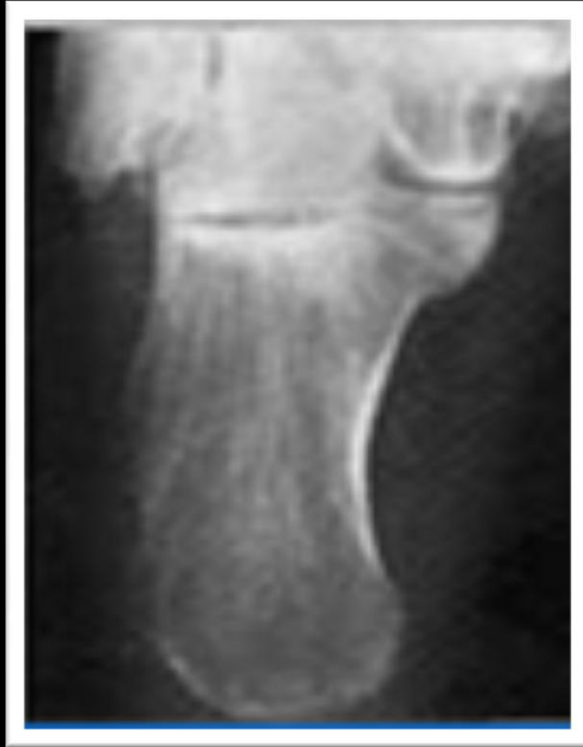

Talocalcaneal Coalition

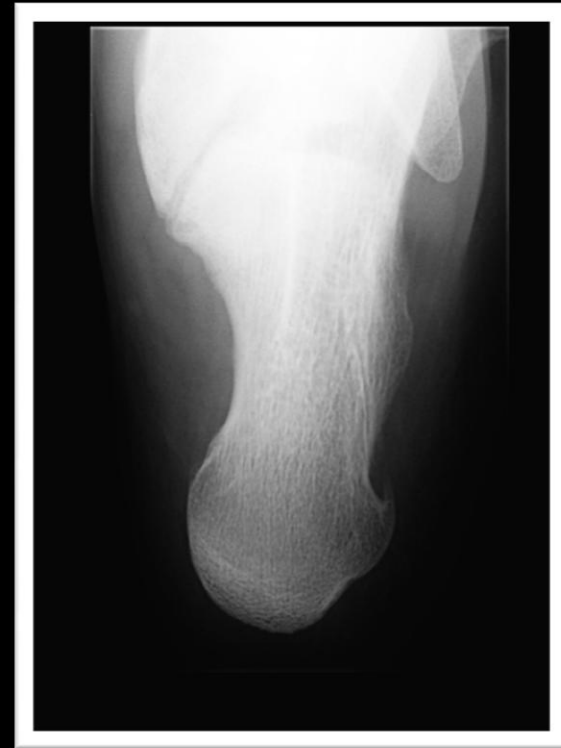Middle Facet / Posterior Facet

The anterior facet is in a different plane and is not seen on the Harris view because it is obscured by the talar head.

Talocalcaneal Coalition – Harris-Beath View

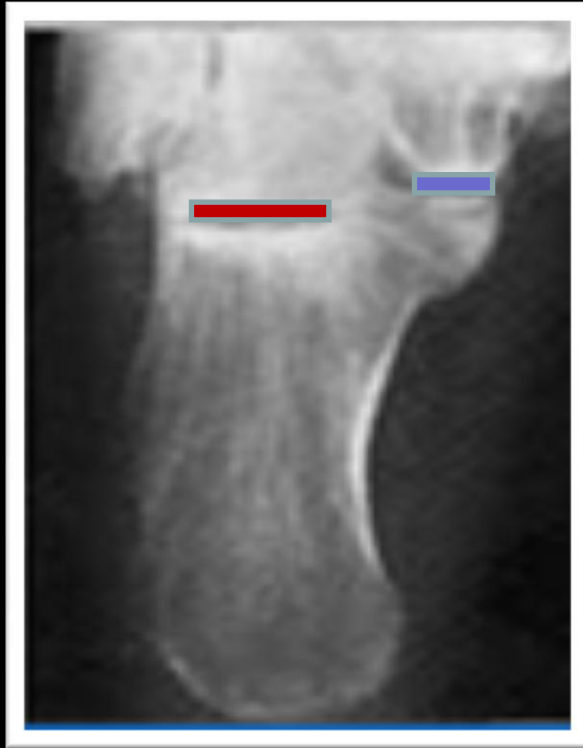

Normal

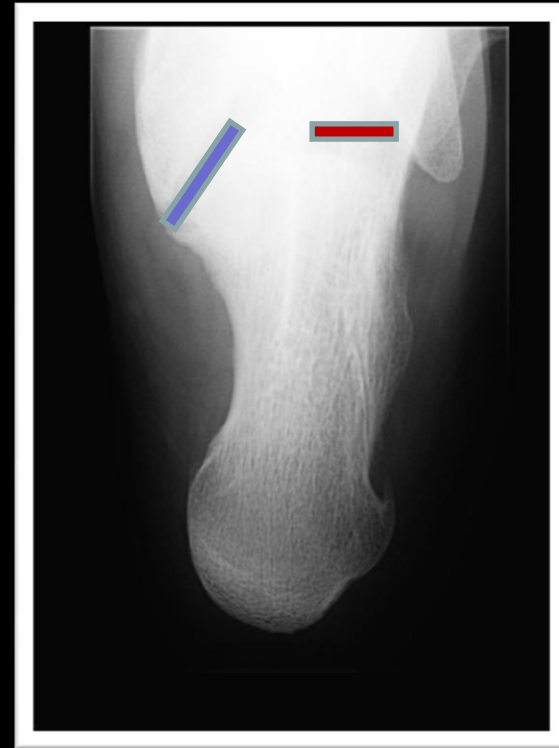


Talocalcaneal Coalition

Talocalcaneal Coalition – Harris-Beath View



Normal

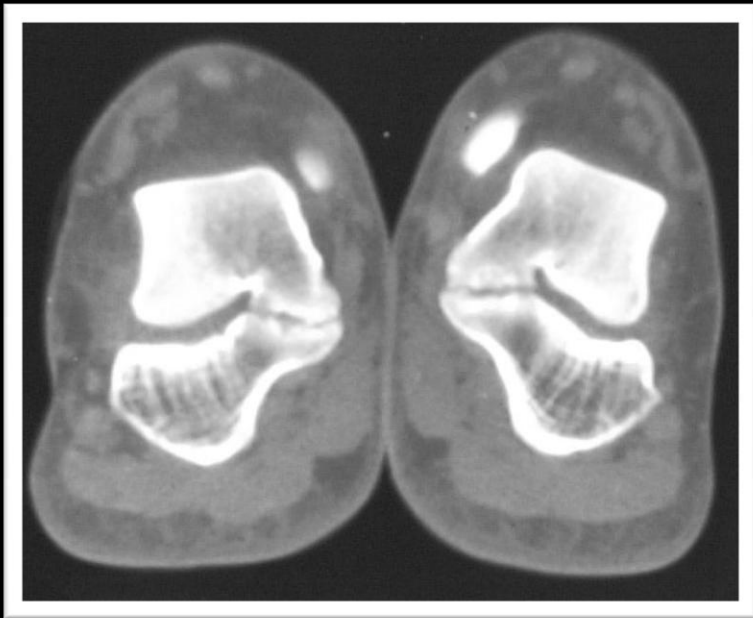


Talocalcaneal Coalition

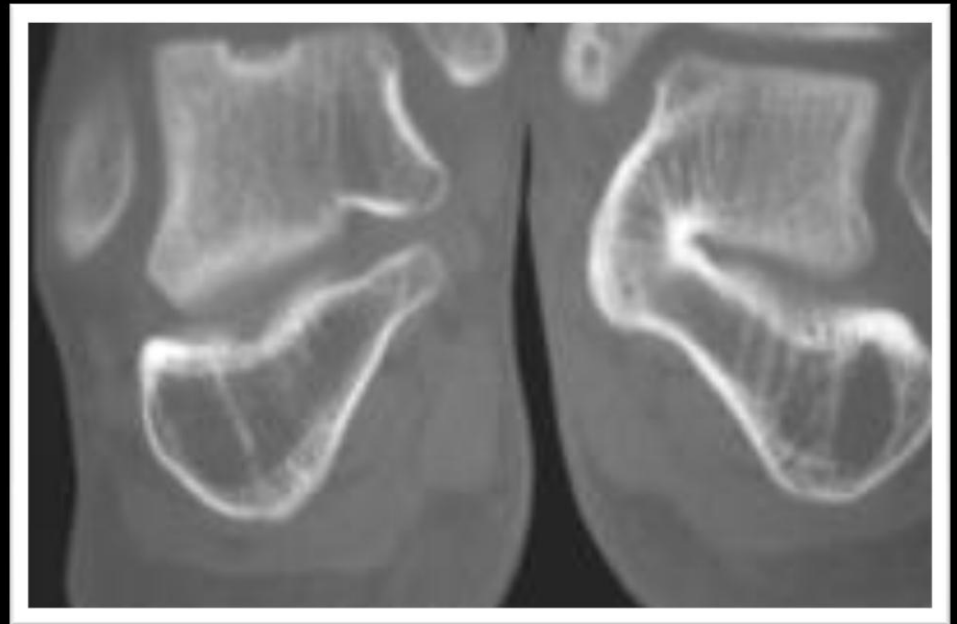
Middle Facet / Posterior Facet

The anterior facet is in a different plane and is not seen on the Harris view because it is obscured by the talar head.

CT Imaging – Talocalcaneal Coalition



Non-Osseous

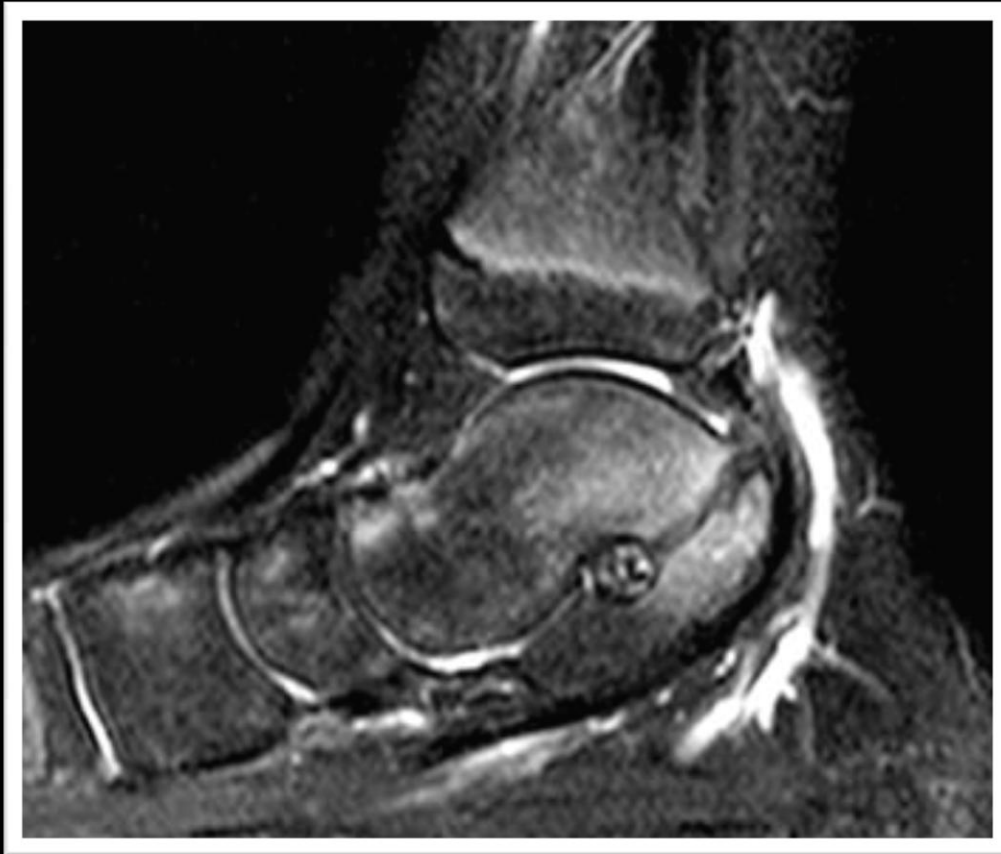

Osseous

Talocalcaneal Coalition --MR Appearance

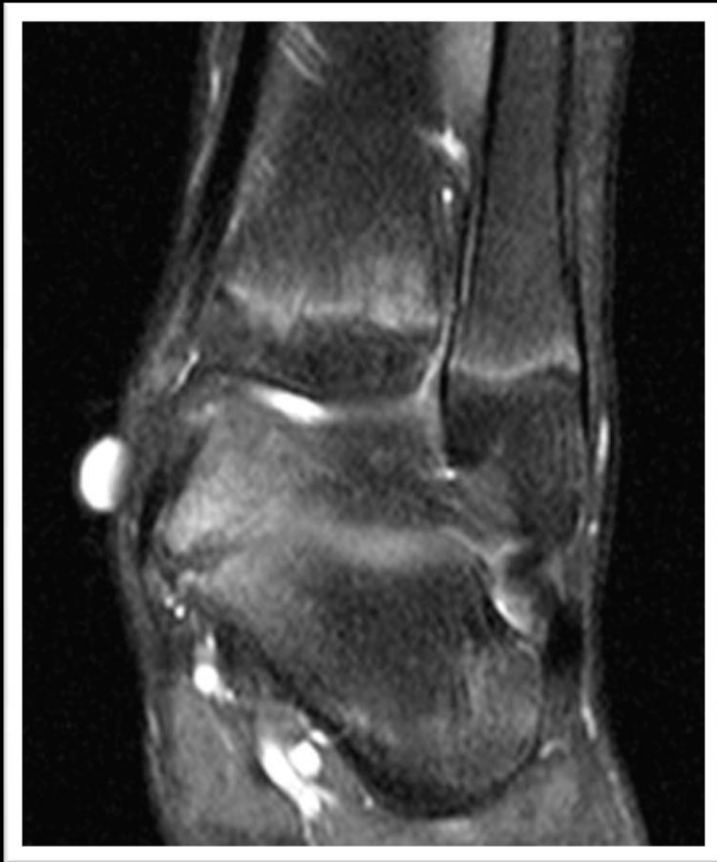- MR signs include:
 - Solid marrow continuity associated with bony coalition
 - Abnormal close approximation of the bones involved in the coalition with associated subchondral sclerosis and subchondral cysts at a synchondrosis or syndesmosis
 - Reactive subchondral marrow edema

MR Imaging – Fibrocartilagenous Talocalcaneal Coalition



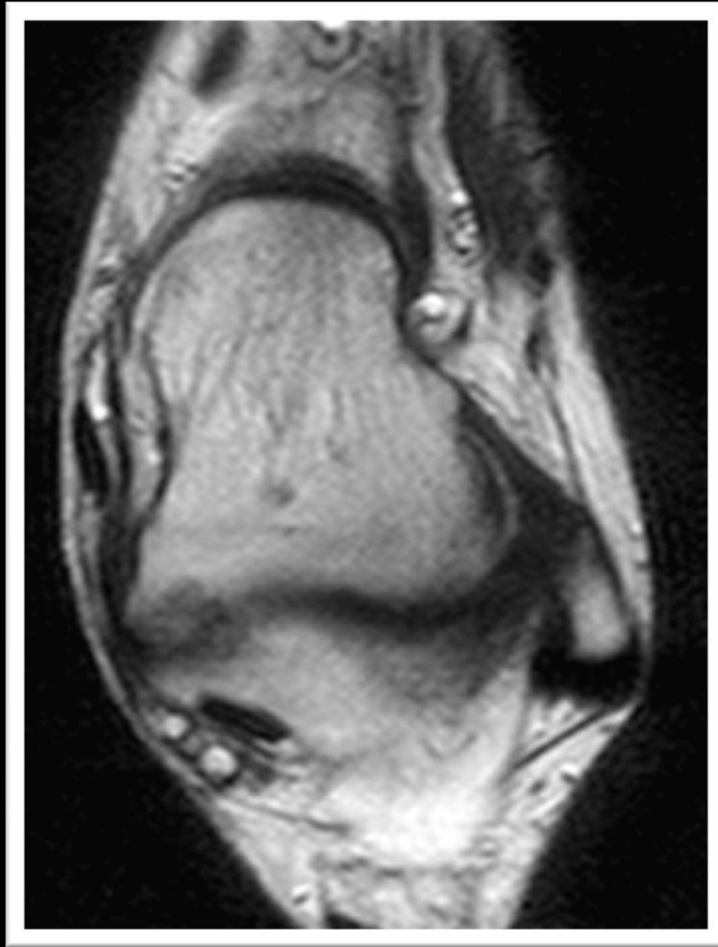
Sagittal fat-suppressed T2-weighted image demonstrates joint and subchondral bone irregularity as well as subarticular marrow edema at the posterior facet

MR Imaging – Fibrocartilagenous Talocalcaneal Coalition



Coronal fat suppressed PD-weighted image demonstrates joint narrowing with suchondral bony irregularity, subcortical marrow edema, and bony hypertrophy at the far medial aspect of the posterior facet of the subtalar joint

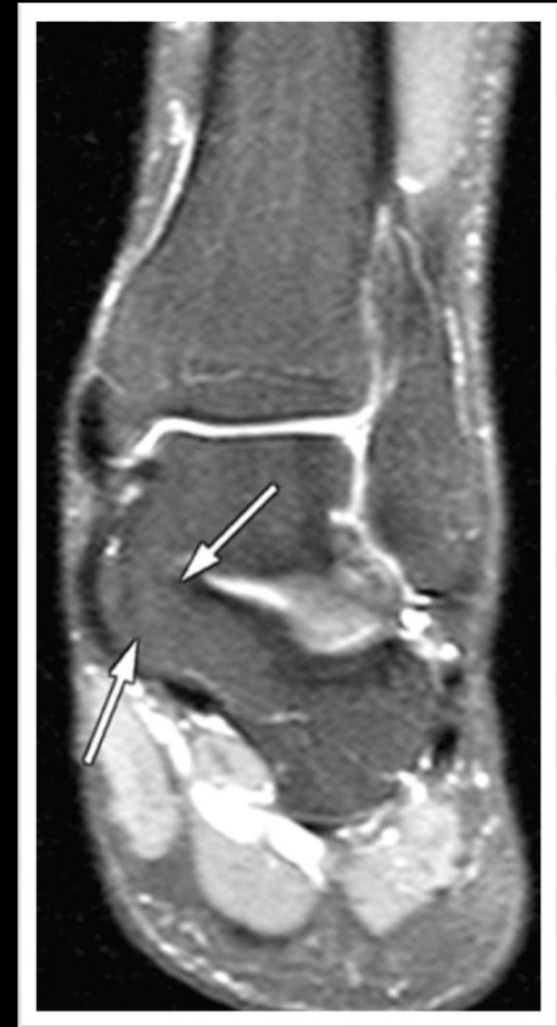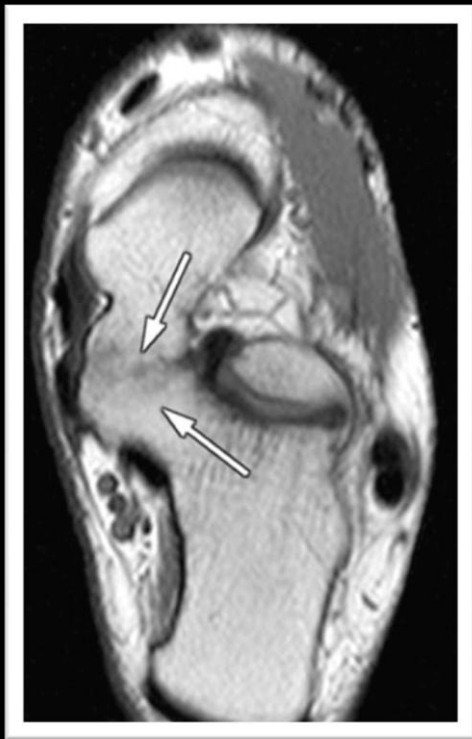MR Imaging – Fibrocartilaginous Talocalcaneal Coalition



Axial T2-weighted image demonstrates articular irregularity at the far medial aspect of the posterior facet of the subtalar joint and hypertrophy of the bordering talus and calcaneus

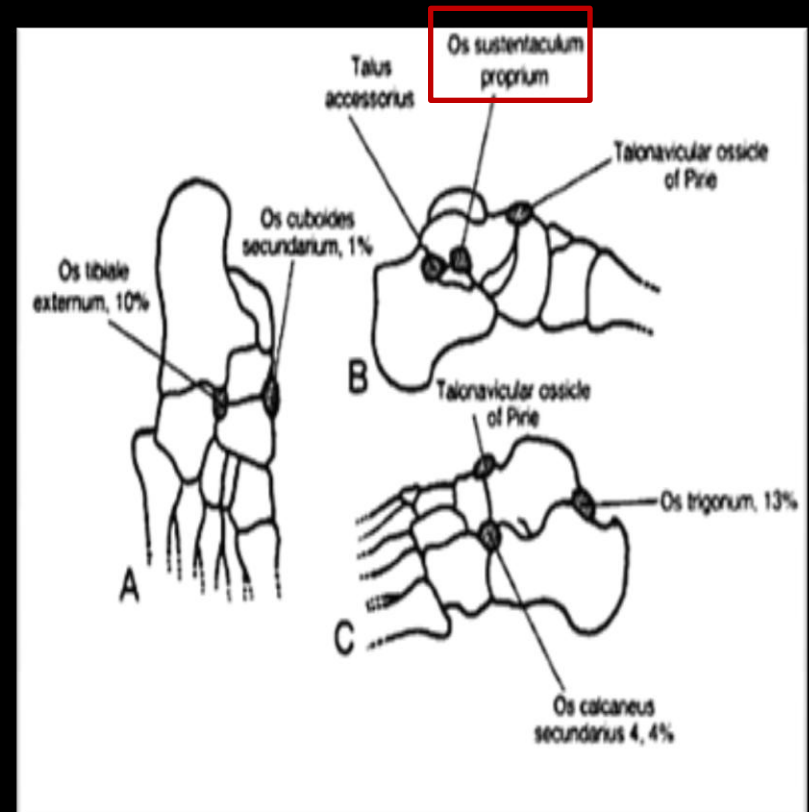
MR Imaging – Osseous Talocalcaneal Coalition

Coronal fat suppressed PD-weighted and axial T1-weighted images demonstrate a solid osseous fusion at the middle facets



Os Sustentaculum

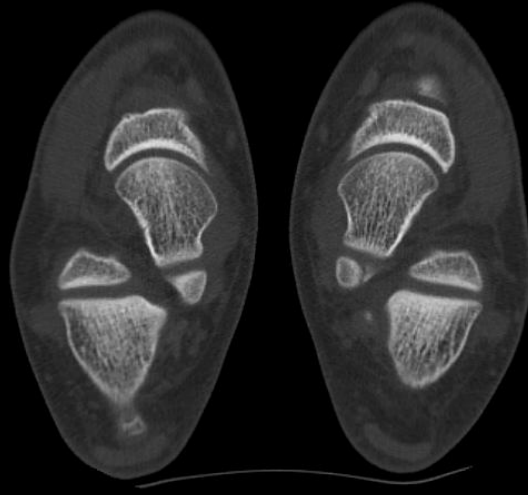
- Rare accessory bone located at the posterior end of the sustentaculum tali
- Estimated to be found in 0.3% of the population
- Usually bridged to the calcaneus via a fibrous or fibrocartilaginous tissue
- Majority of patients who have accessory bones in their feet are asymptomatic
 - Etiology of pain is not clear: may result from shearing stress forces across the synchondrosis between the os or related to osteoarthritic changes



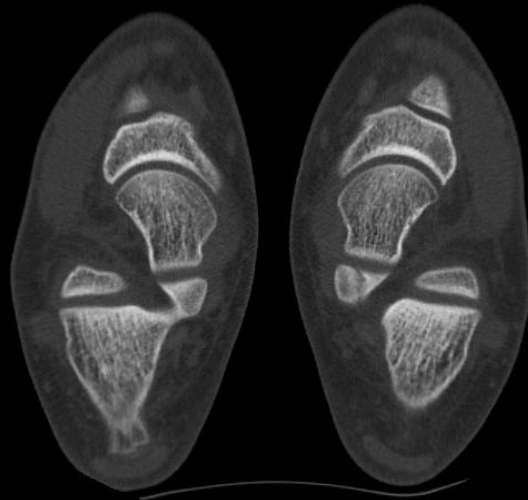
Os Sustentaculum

- A variant of the os has been called the “*assimilated os sustentaculi*” or “*articulatio talo-calcanea*”
 - Accessory joint formed between the bony projections at the sustentaculum tali and the adjacent talus
 - Speculation that the os may incorporate to the sustentaculum tali at the end of the growth period, representing in a fused variety of the condition
 - A talocalcaneal bridge occurring at the posterior end of the sustentaculum tali may be attributed to this ossicle fusing with both bones
- * ***Harris and Beath suggested that an assimilated os may be associated with subtalar coalition and peroneal spastic flatfoot***

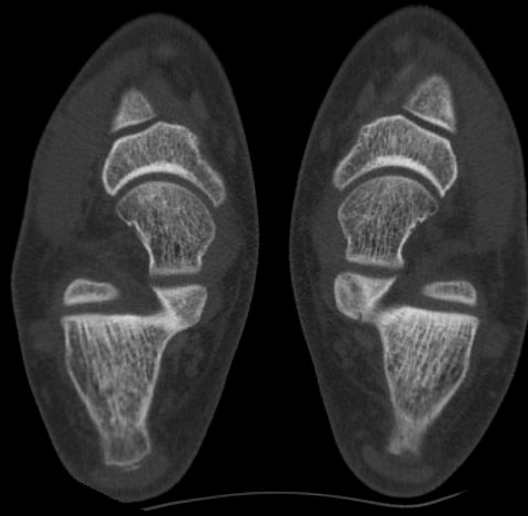
Os Sustentaculum



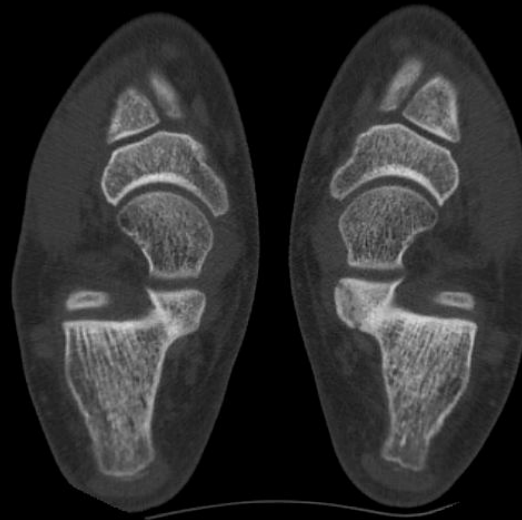
Os Sustentaculum



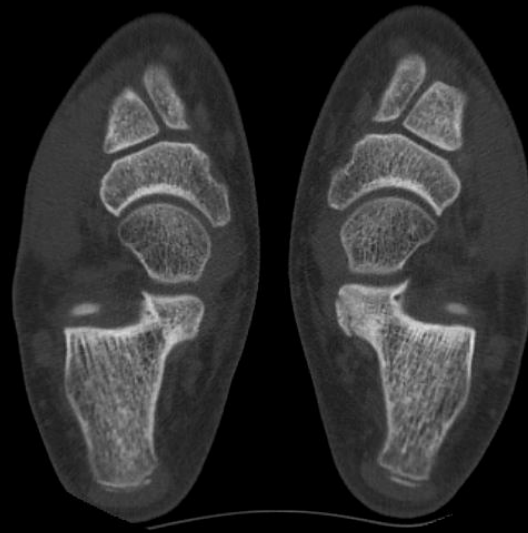Os Sustentaculum



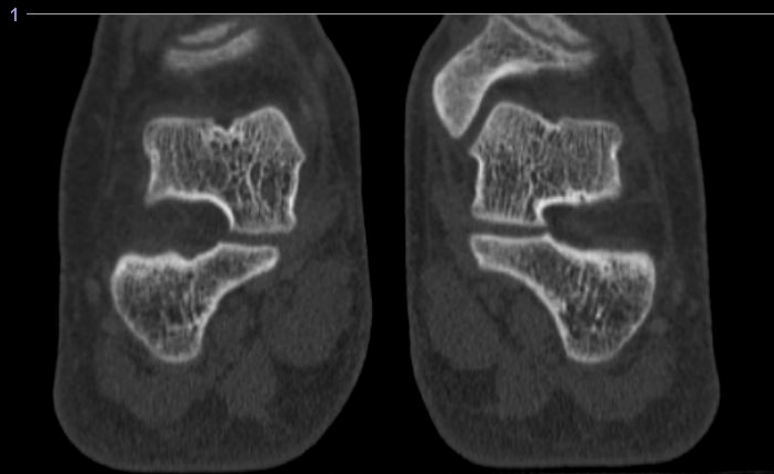
Os Sustentaculum



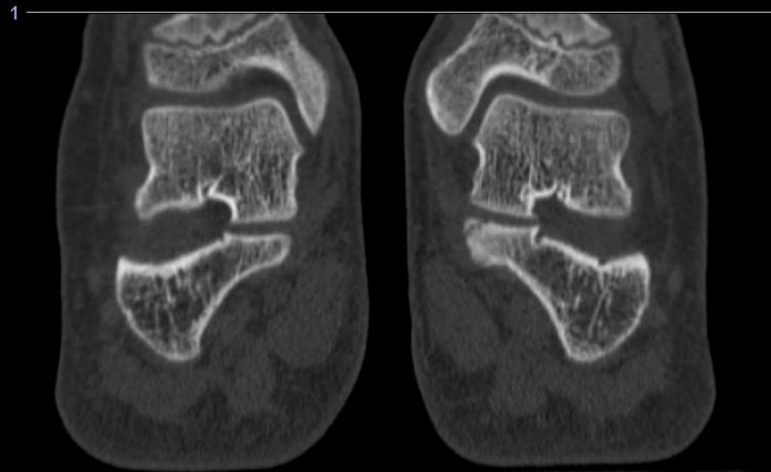
Os Sustentaculum



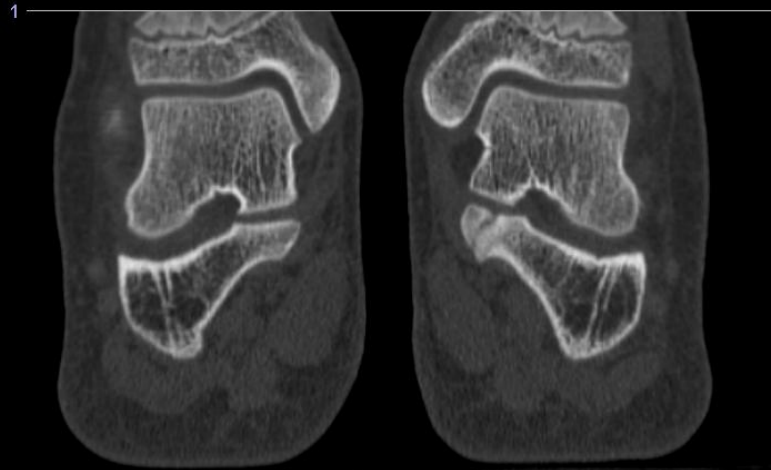
Os Sustentaculum



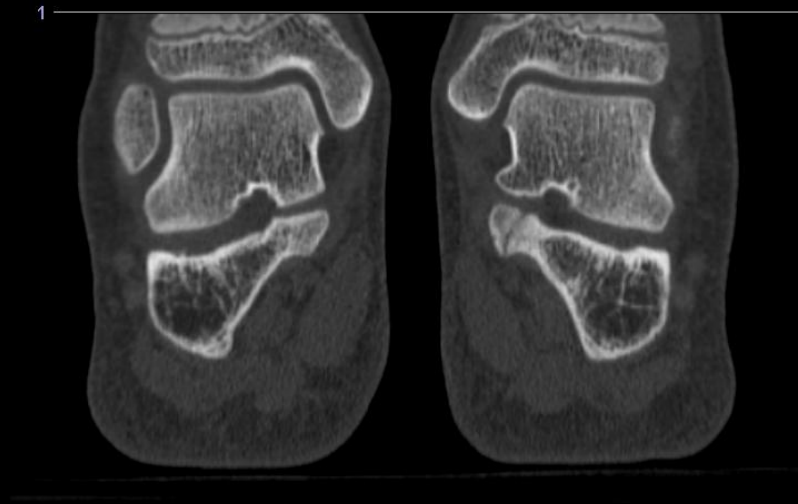
Os Sustentaculum



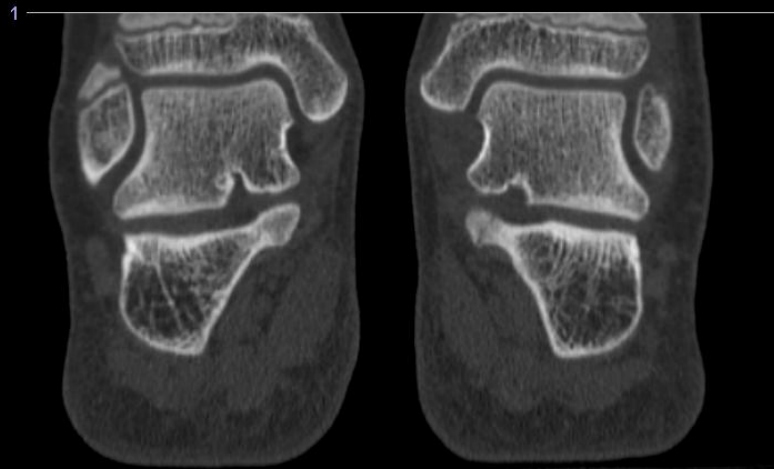
Os Sustentaculum



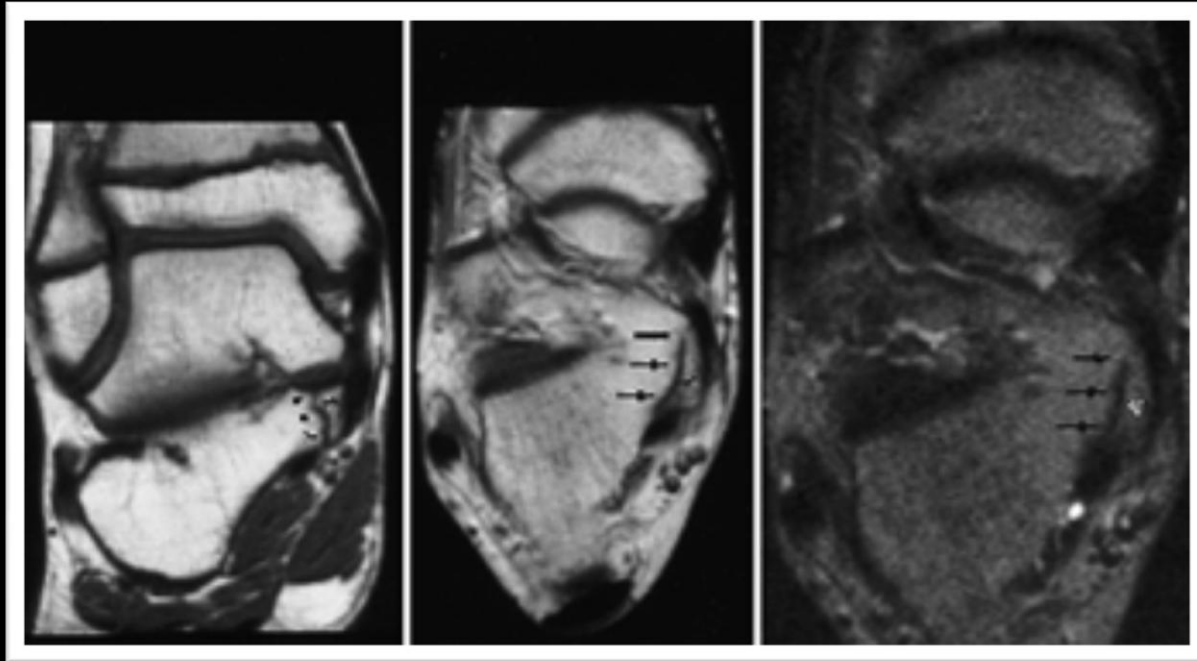
Os Sustentaculum



Os Sustentaculum



Os Sustentaculum



The os is distinguished from the calcaneus and sustentaculum tali by a low-signal line (*arrows*)

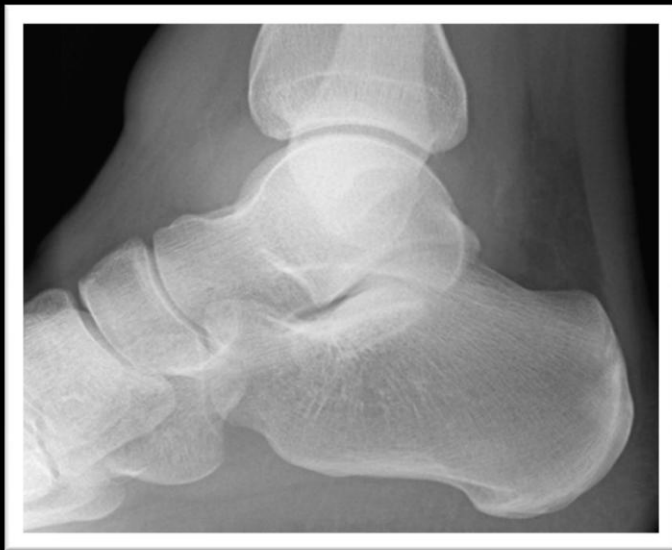Calcaneonavicular Coalition

Imaging – Calcaneonavicular Coalition

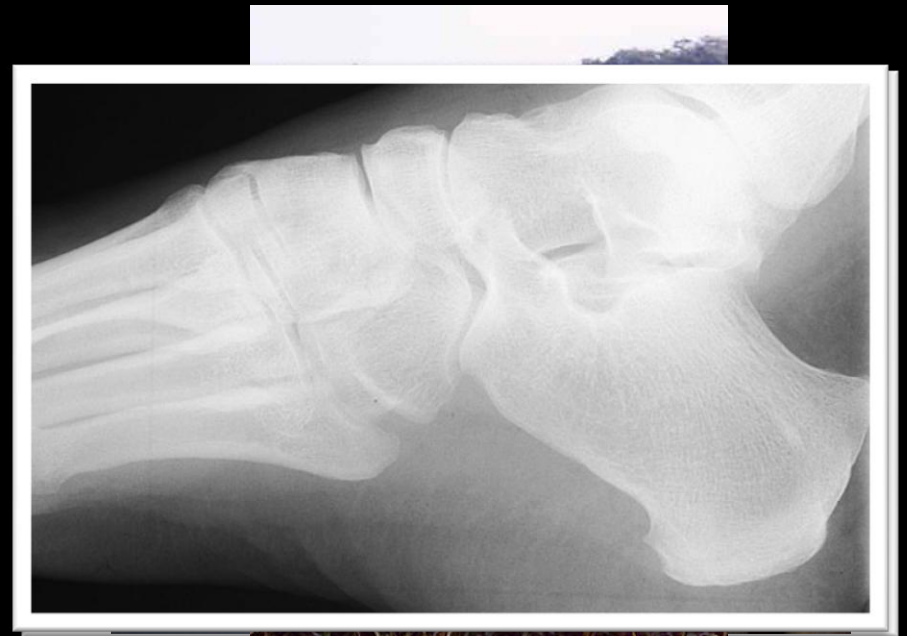“Anteater Nose” Sign

- Elongation of the normally triangular anterior process of the calcaneus, resulting in squaring of the anterior process like a snout of an anteater
- Originally reported to have a 72% sensitivity and 90% specificity
 - Subsequent report found only a 10% sensitivity

“Anteater Nose” Sign



Normal



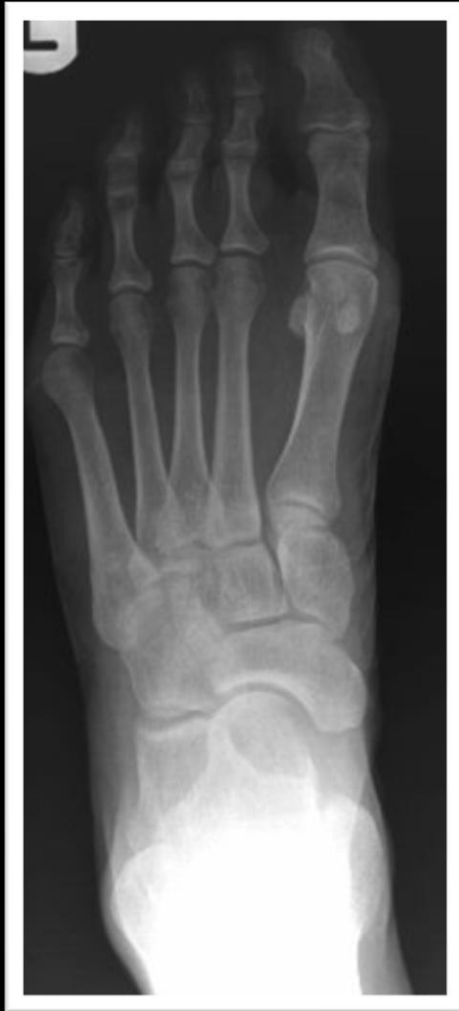“Anteater Nose” Sign

Imaging – Calcaneonavicular Coalition

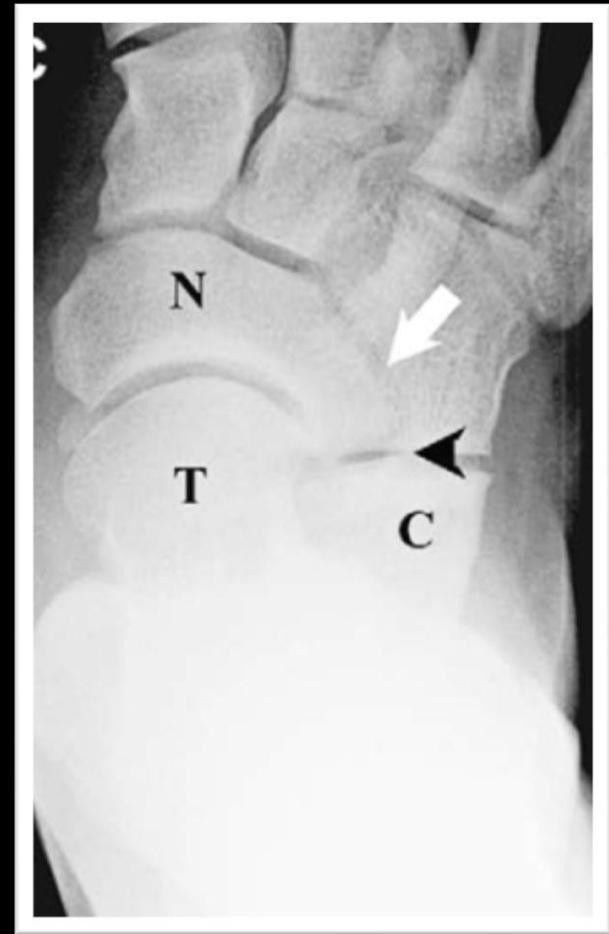Elongated Navicular Sign (Reverse Anteater's Nose Sign)

- Visible on AP radiographs of the foot
- Normally, the lateral margins of the navicular and the talar head are aligned
- With a calcaneonavicular coalition, the navicular extends further laterally and the AP dimension of the lateral portion tends to be smaller than at the medial portion of the navicular
- Originally reported to have a sensitivity of 50% and specificity of 100% although a subsequent report found only a sensitivity of 18%

Elongated Navicular Sign (Reverse Anteater's Nose Sign)

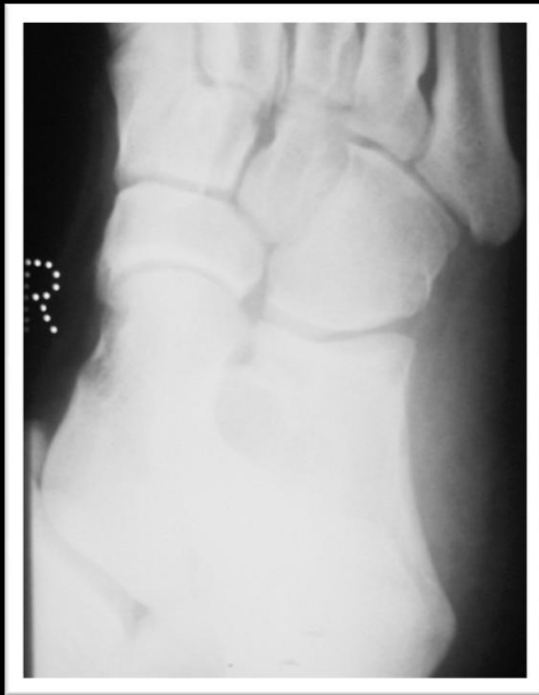

Normal

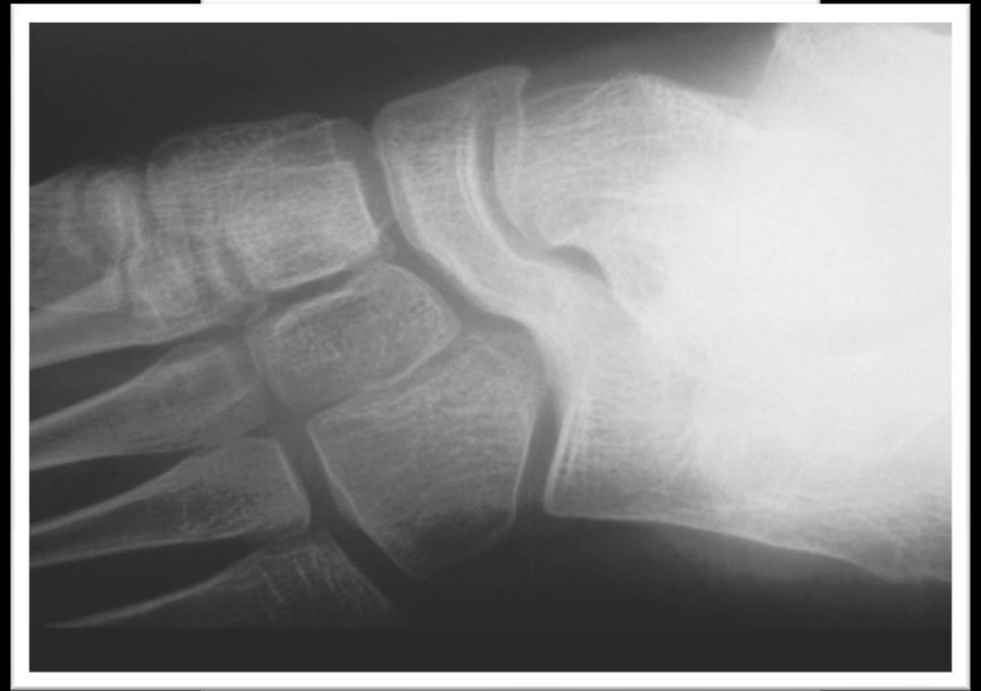

Reverse Anteater's Nose Sign

Calcaneonavicular Coalition



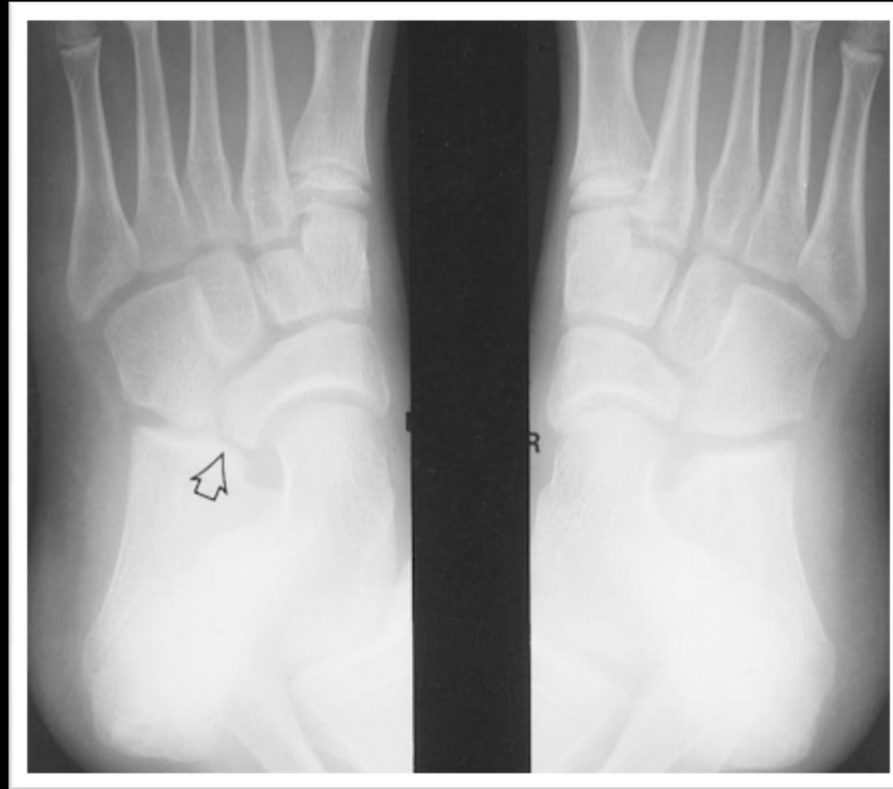
Normal



Calcaneonavicular Coalition

Courtesy of Tudor Hughes, M.D.

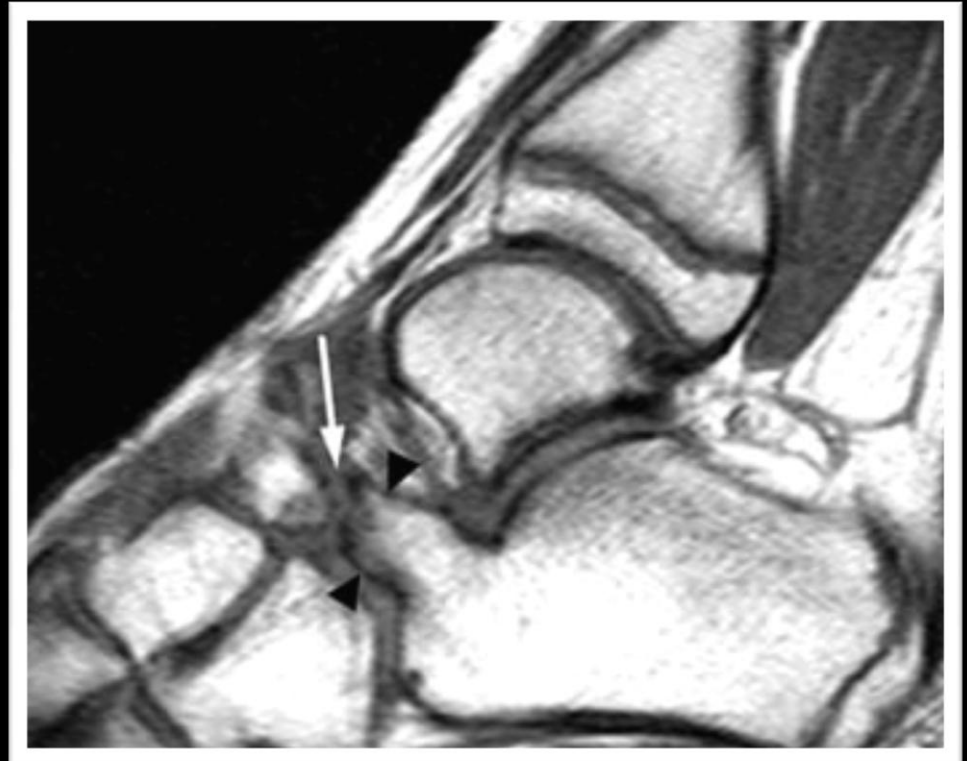Calcaneonavicular Coalition



Oblique radiographs of a 11 year old boy demonstrate a nonosseous coalition on the left.

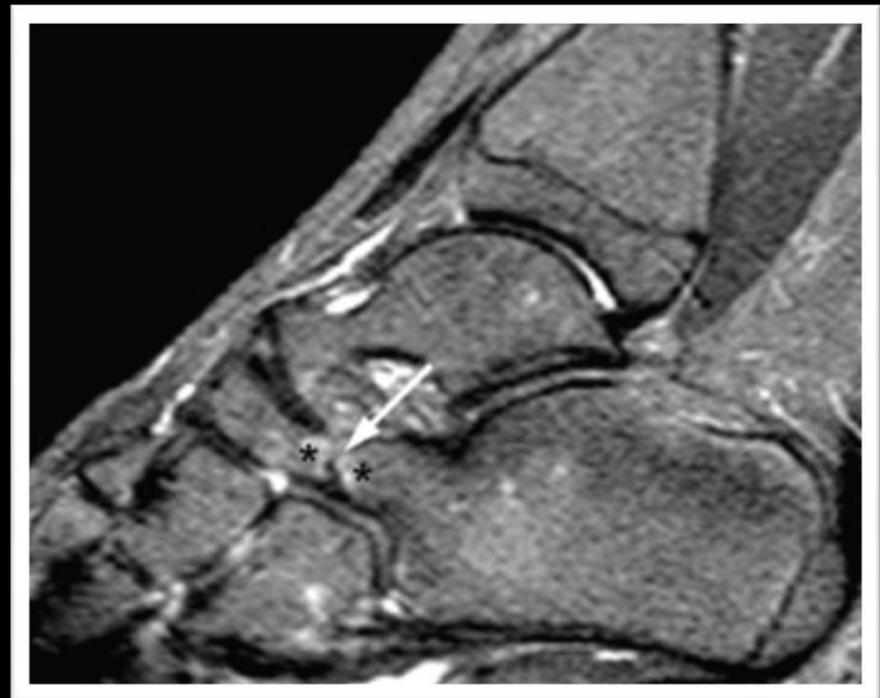
MR Imaging – Fibrocartilaginous Calcaneonavicular Coalition

- Sagittal T1-weighted image demonstrates an elongated and broadened anterior process of the calcaneus where it demonstrates an irregular articulation with the navicular (“anteater’s nose”)



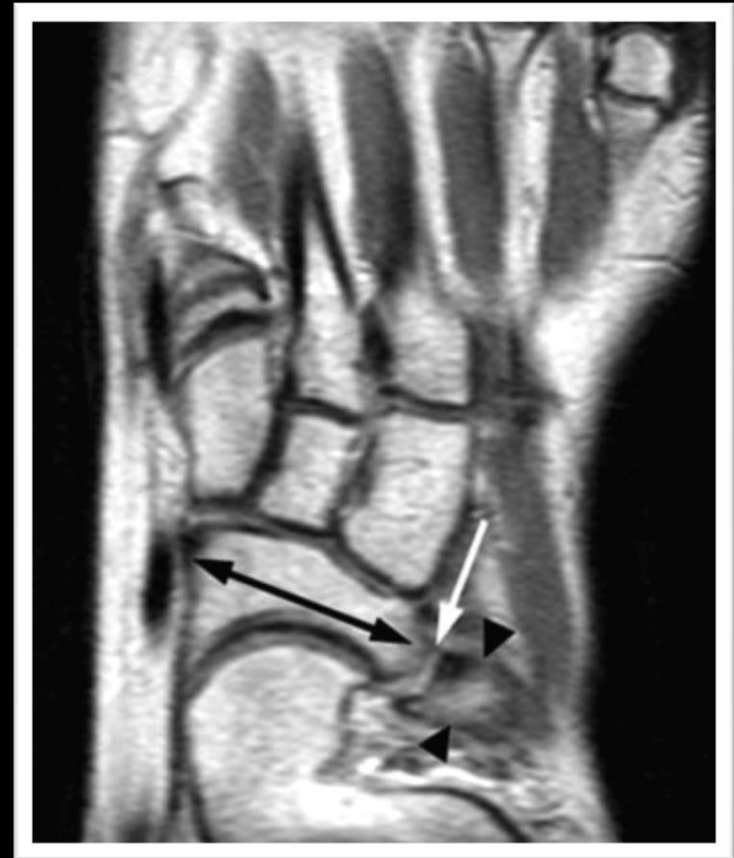MR Imaging – Fibrocartilagenous Calcaneonavicular Coalition

- Sagittal STIR image demonstrates bony hypertrophy and subarticular marrow edema at the abnormal calcaneonavicular articulation



MR Imaging – Fibrocartilagenous Calcaneonavicular Coalition

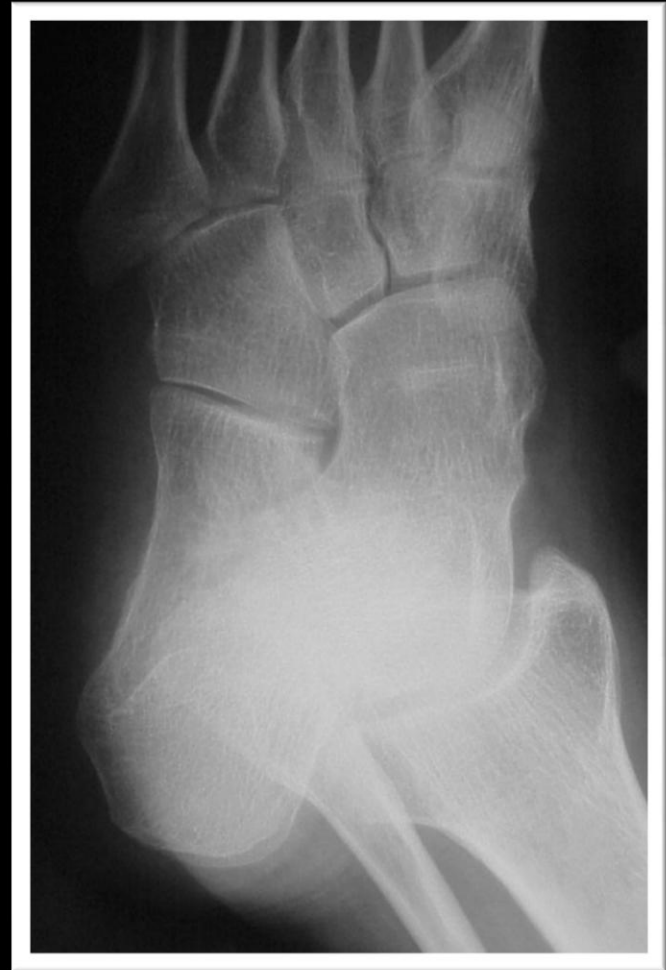- Axial T1-weighted image demonstrates the slightly widened mediolateral dimension of the navicular (black arrow), which tapers laterally and articulates (white arrow) with the enlarged anterior process of the calcaneus (arrowheads)



Other Tarsal Coalitions

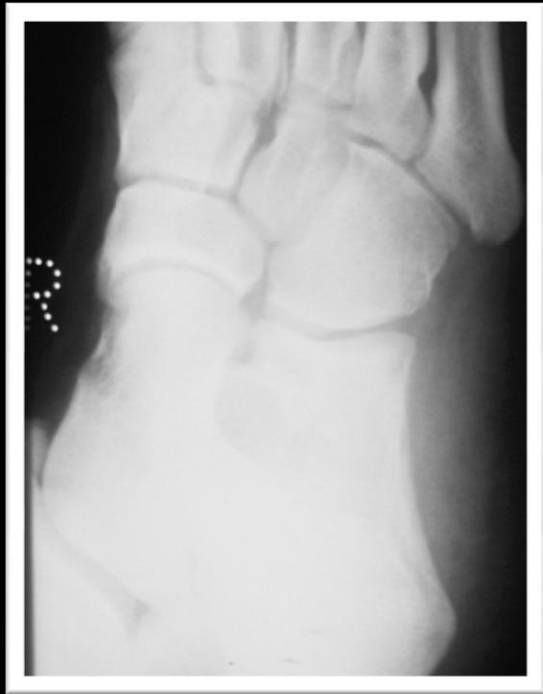Talonavicular Coalition

- May be transmitted in an autosomal dominant or autosomal recessive fashion
- May be associated with anomalies of the little finger
- Onset of symptoms usually occurs at 5 years of age
- Patients may be asymptomatic or may have pain or peroneal spasm

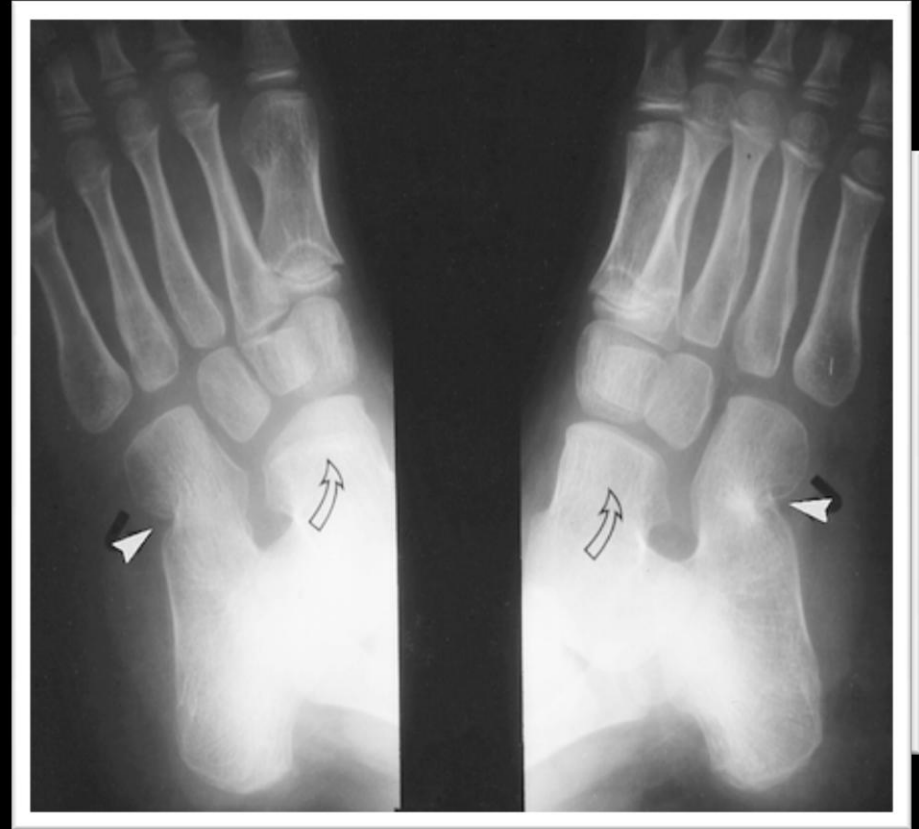


Courtesy of Tudor Hughes, M.D.

Calcaneocuboid Coalition

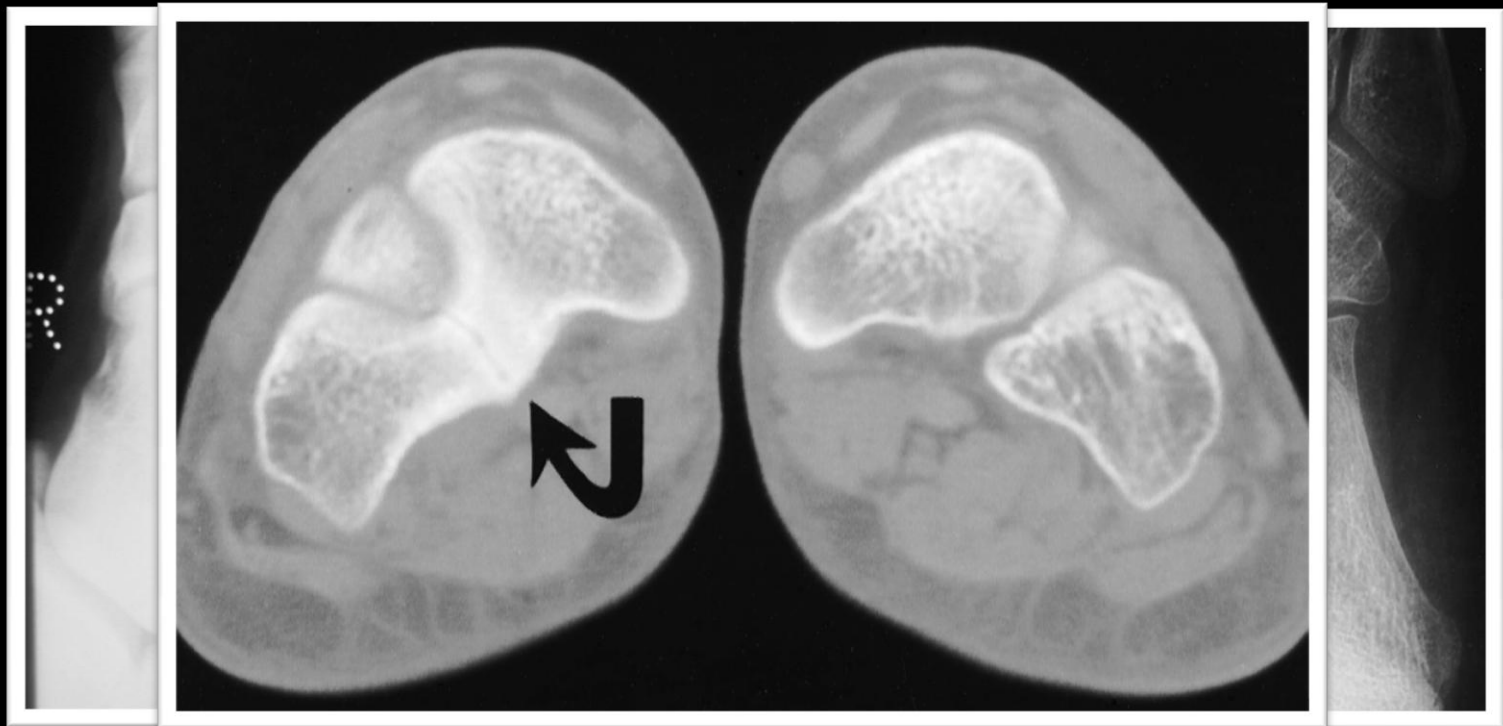


Normal



Calcaneocuboid Coalition

Cubonavicular Coalition

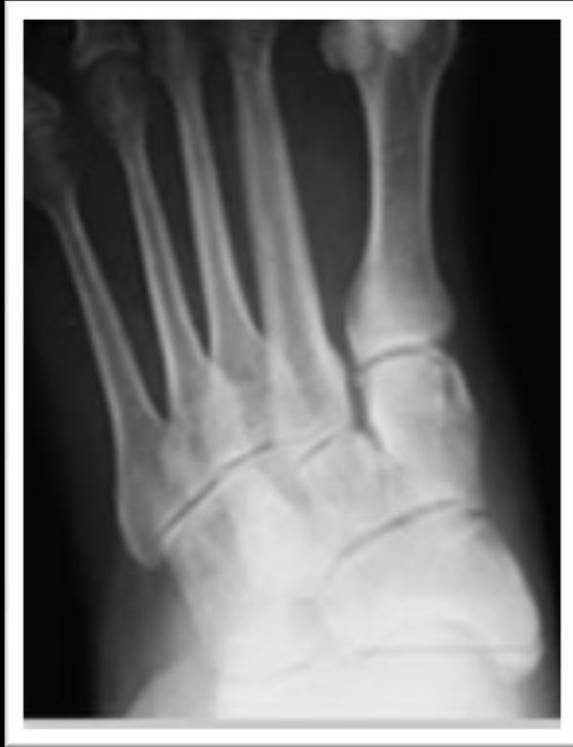

Normal

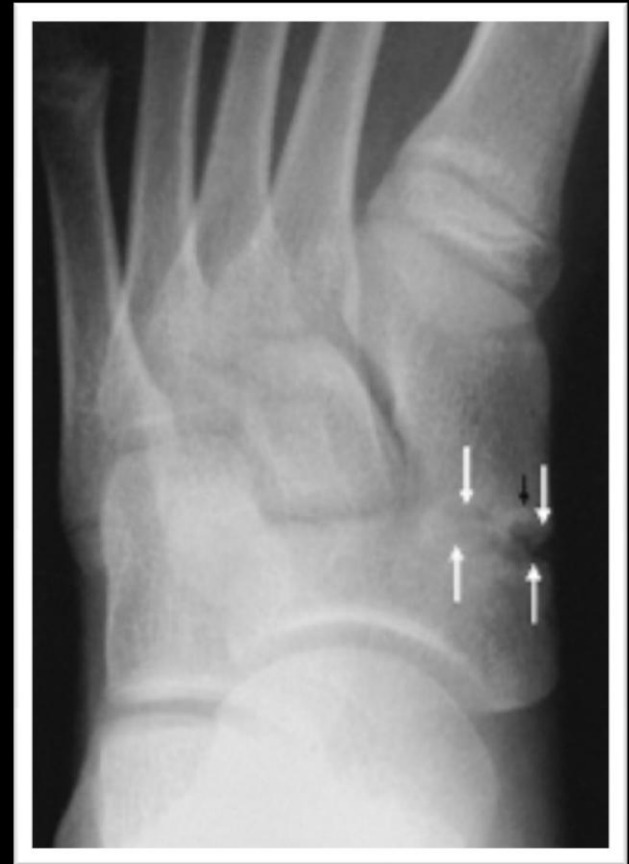Cubonavicular Coalition

Congenital Tarsal Coalition: Multimodality Evaluation with Emphasis on CT and MR Imaging. Newman et al. RadioGraphics. March 2000. 20, 321-332.

Naviculocuneiform Coalition



Normal



Naviculocuneiform Coalition

TREATMENT

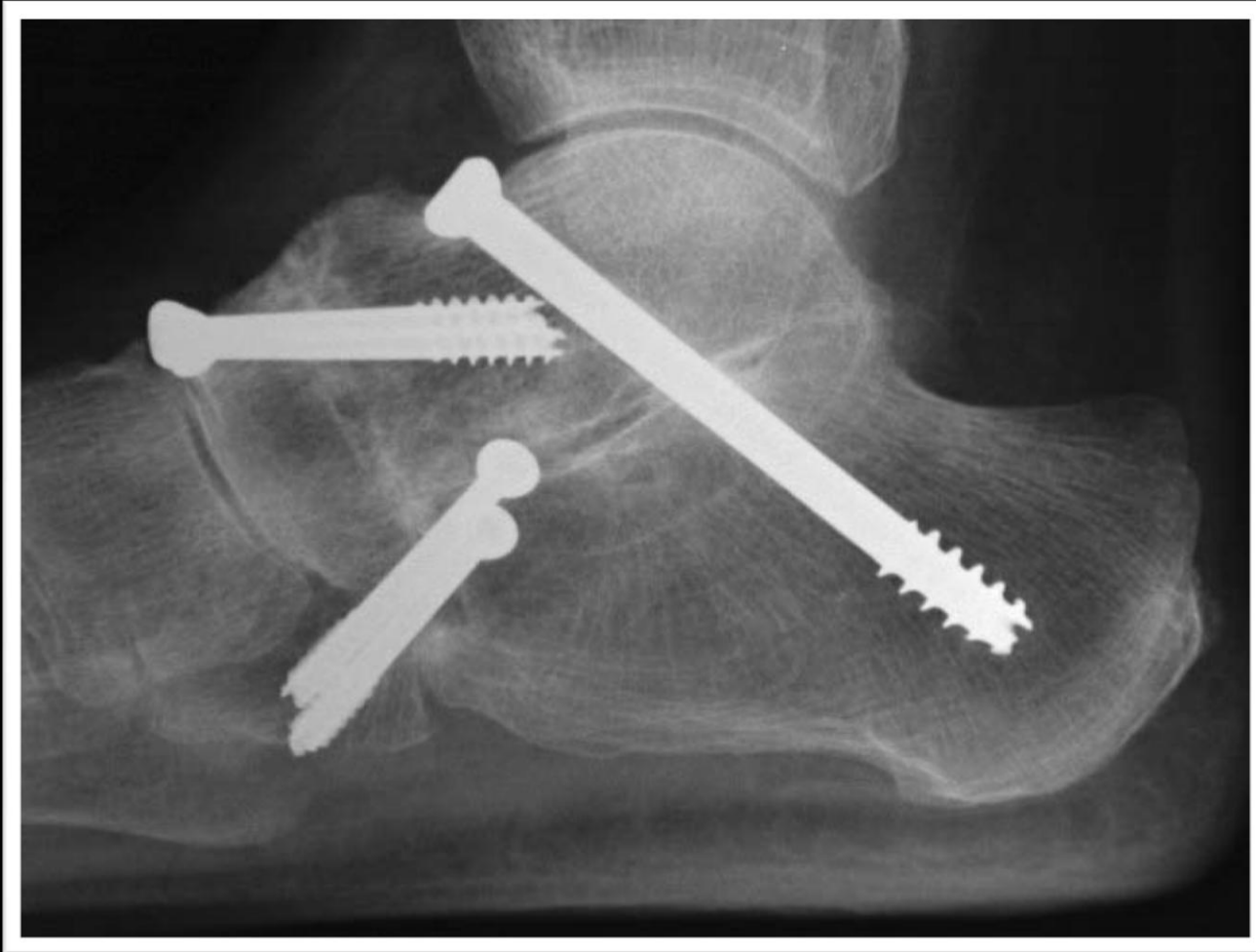
Treatment – Talocalcaneal Coalition

- Conservative treatment, such as below the knee weight bearing cast for 3-6 weeks, is usually effective in only 1/3 of patients
- Surgical Indications:
 - Excision: Resection is the treatment of choice in patients under 16 years of age if no degenerative changes are present
 - The middle facet coalition should be less than 50%
 - Resection is approached medially with the middle facet exposed by retraction of the flexor hallucis longus tendon. The prominent joint is resected and fat is interposed.
 - Fusion: More than 50% involvement of the middle facet or when degenerative changes are present
 - Failed resections are salvaged by subtalar fusion or triple arthrodesis
 - Triple arthrodesis may be indicated when symptoms are severe and degenerative changes are present

Treatment – Calcaneonavicular Coalition

- Non-Operative Treatment:
 - Symptomatic tarsal coalitions are initially treated conservatively
 - Immobilization followed by orthotic support is often sufficient
- Indications for Surgery:
 - If symptoms persist, then surgical intervention may be indicated
 - Amenable to resection with most patients doing well
 - Procedure described by Badgley and Cowell includes an anterolateral approach over the coalition, resection of at least 1 cm of the coalition, interposition of the head of the extensor digitorum brevis muscle, and avoidance of the talonavicular joint to prevent the subluxation of the navicular over the talar head
 - Patients with degenerative changes in the tarsal joints undergo arthrodesis

Example of Triple Arthrodesis



Standard triple arthrodesis includes the subtalar, talonavicular, and calcaneocuboid joints

Post-Operative Follow-Up

- Immobilization for 3 weeks in a non weight-bearing cast followed by 3 weeks of partial immobilization with a non weight-bearing cast and range-of-motion exercises out of the cast
- Followed by gradual advance to full weight-bearing and range-of-motion exercises with physiotherapy

Carpal Coalition

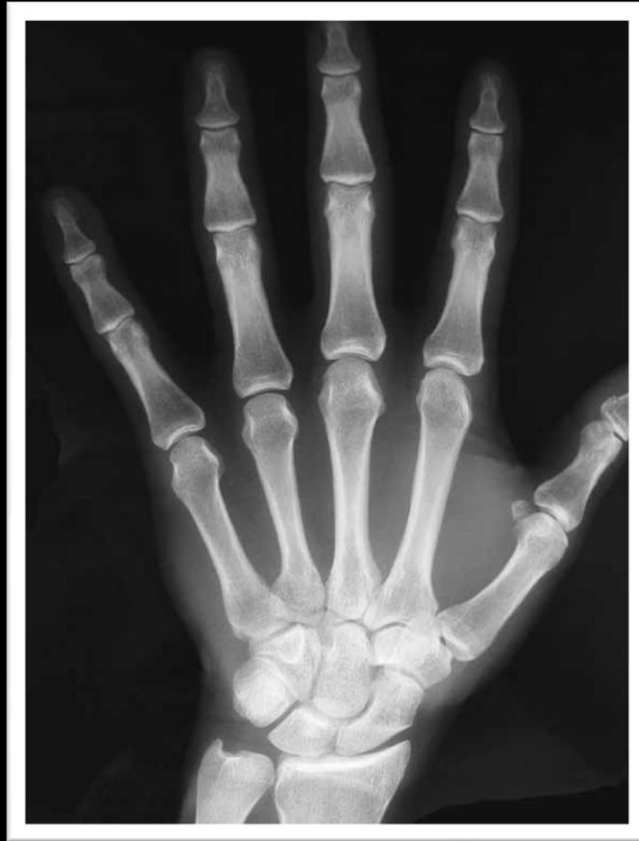Carpal Coalition

- May be an isolated finding or as part of a congenital malformation syndrome (i.e. Ellis van Creveld syndrome, arthrogyrosis, symphalangia, diastrophic dwarfism, Turner's syndrome)
- As a rule, isolated fusions involve bones in the same carpal row (proximal or distal), whereas syndrome-related fusions may affect bones in different rows (proximal and distal)
- Can be congenital or acquired (i.e. infection, arthritides, trauma, and surgery)
- With movement lost between the fused carpal bones, compensatory increase in motion at the surrounding joints predisposes to recurrent sprains and carpal bossing
- Increased risk of fracture in the presence of a fused carpus

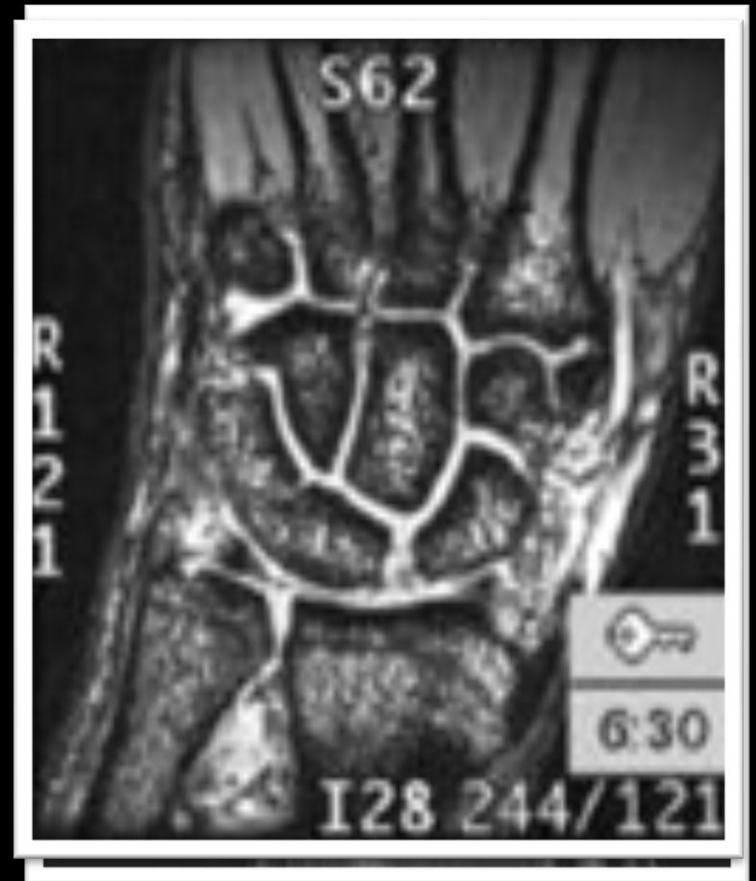Carpal Coalition

- More common in men and in blacks
- Coalition is bilateral in up to 60% of patients
- Patients usually present between 6 and 15 years of age
- Most common site of isolated fusion is between the triquetrum and the lunate bones, which occurs in 0.1 to 1.6% of the general population
 - Widening of the scapholunate interosseous space is a common finding in cases of lunotriquetral fusion, although the scapholunate interosseous ligament is usually intact

Imaging – Lunotriquetral Coalition



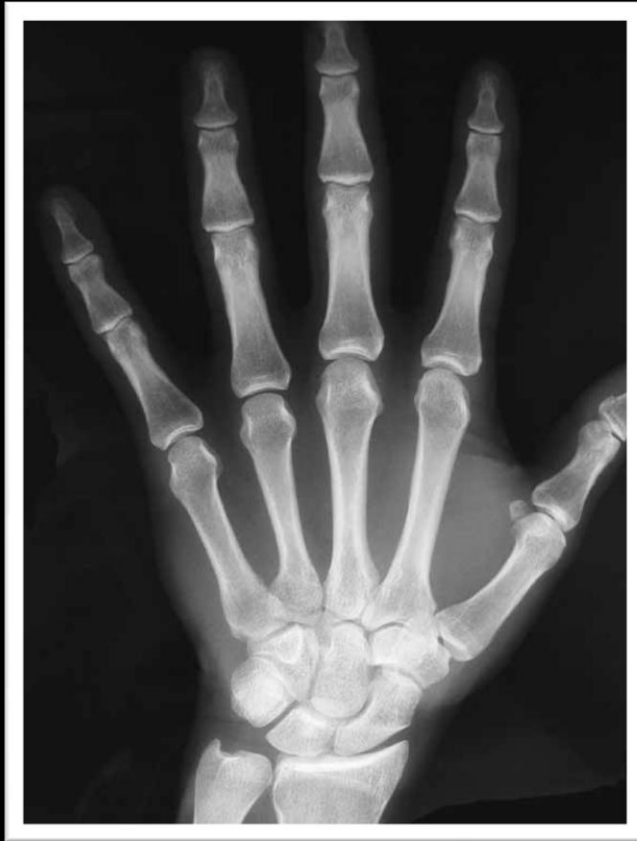Normal



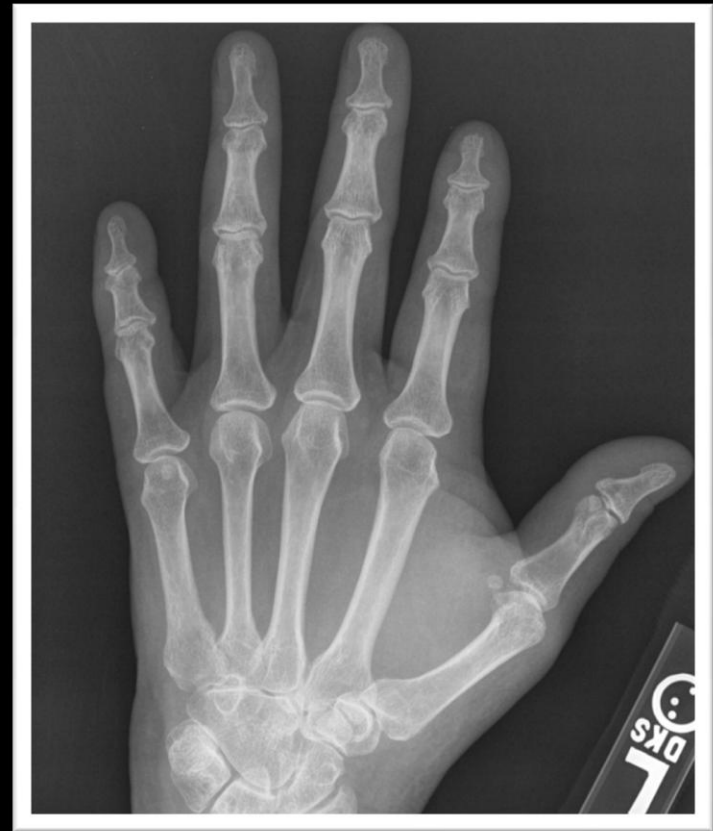Lunotriquetral Coalition

Courtesy of Tudor Hughes, M.D.

Imaging – Capitate-Hamate Coalition



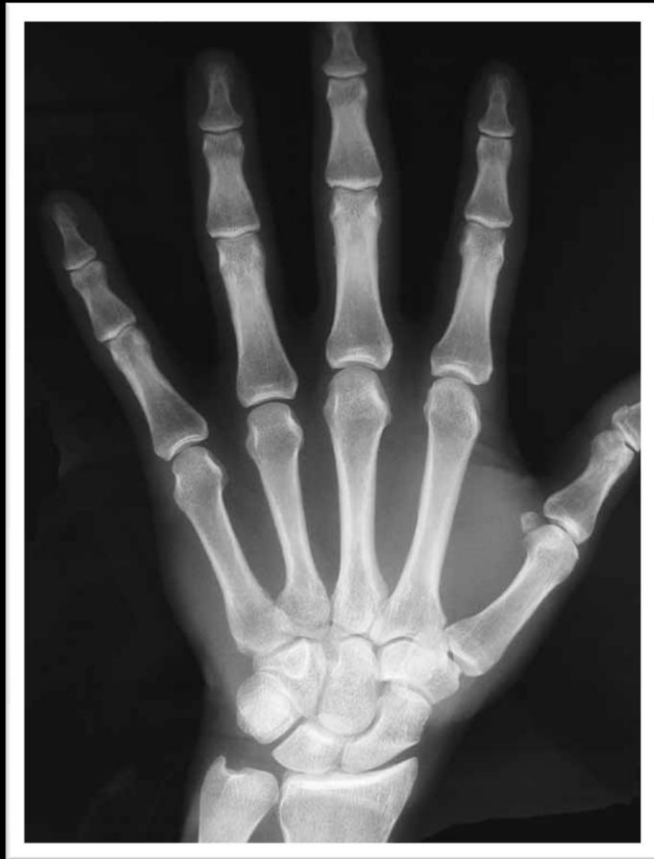Normal



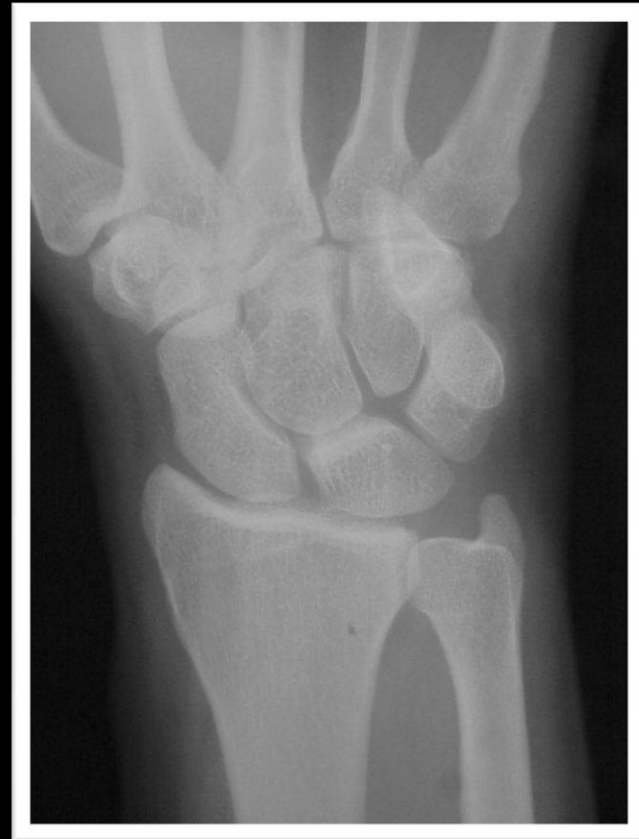Capitate-Hamate Coalition

Courtesy of Tudor Hughes, M.D.

Imaging – Pisiform-Hamate Coalition

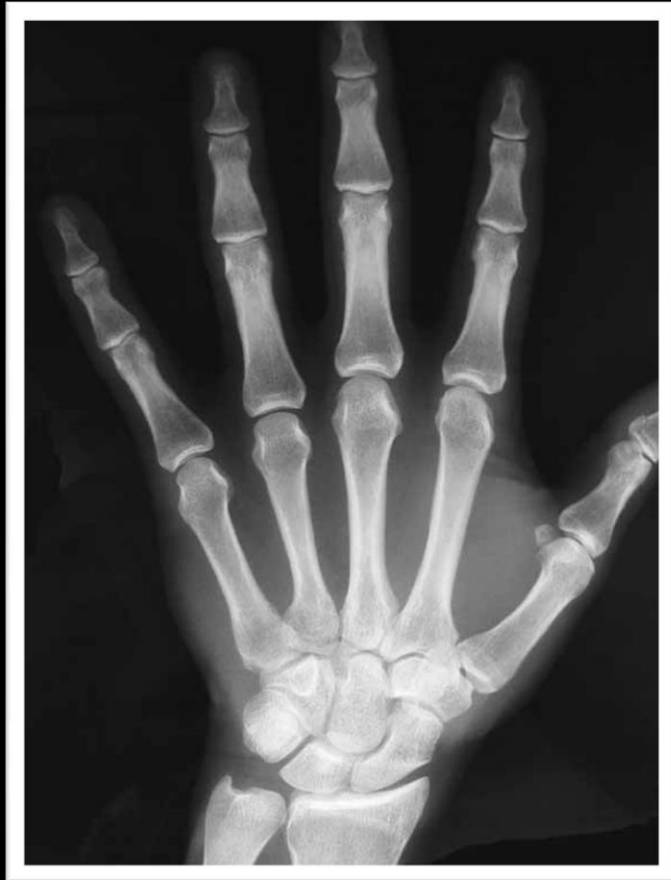

Normal

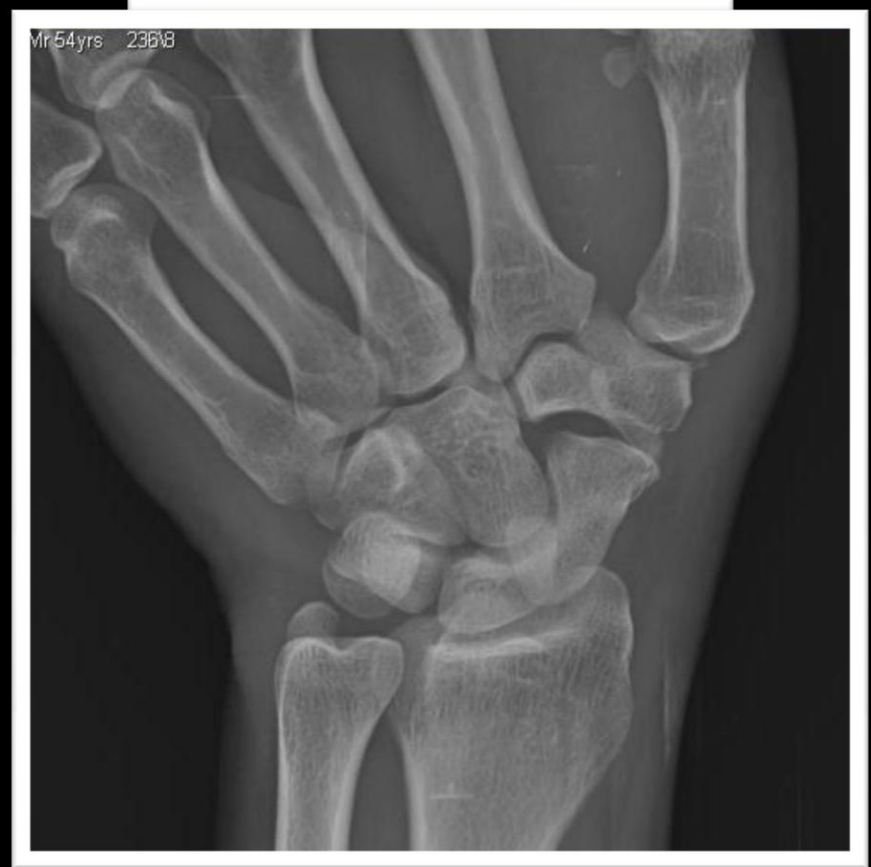

Pisiform-Hamate Coalition

Imaging – Trapezium-Trapezoid Coalition



Normal



Trapezium-Trapezoid Coalition

Summary

- Tarsal Coalition
 - History
 - Etiology
 - Clinical Presentation
 - Anatomy
 - Imaging
 - Treatment

- Carpal Coalition

Questions ?

References

- Heiple and Lovejoy. *The Antiquity of Tarsal Coalition: Bilateral Deformity in a Pre-Columbian Indian Skeleton. The Journal of Bone and Joint Surgery.* 1969; 41: 979-983.
- 2009 *Internal Derangements of Joints: MR Imaging with Arthroscopic Correlation, Dr. Resnick's Lecture – Bones, Joints, Bursae: MRI – Normal and Abnormal*
- Crim, Julia. *Imaging of Tarsal Coalition. Radiologic Clinics of North America. Volume 46, Issue 6 (November 2008)*
- McGlamry's comprehensive textbook of foot and ankle surgery, Volume 2. Alan S. Banks, E. Dalton McGlamry. Pages 1000 – 1001.
- C-sign for Diagnosis of Talocalcaneal Coalition. Taniguchi et al. *Radiology* 2003; 228: 501-505.
- Resnick, D. *Talar ridges, osteophytes, and beaks: A radiographic commentary. Radiology* 151. (2): 329 – 332. 1984.
- Daftary, et al. *Fractures of the Calcaneus: A Review with Emphasis on CT. Radiographics.* 9/2005. 1215-1226.
- *CT with 3D Rendering of the Tendons of the Foot and Ankle: Technique, Normal Anatomy, and Disease. Choplin et al. RadioGraphics.* March 2004, 24, 343-356.
- *Diagnosis of Bone and Joint Disorders. Donald Resnick, M.D. 2002, Fourth Edition. 4592 – 4599.*

References

- *Congenital Tarsal Coalition: Multimodality Evaluation with Emphasis on CT and MR Imaging.* Newman et al. *RadioGraphics*, 20, March 2000. 321-332.
- *Naviculo-Medial Cuneiform Coalition.* *J Korean Radiol Soc* 2005; 53; 381-386.
- *Os Sustentaculi: Depiction on MR Images.* Bencardino et al. *Skeletal Radiology* (26): 505 – 506, 1997.
- www.mdmercy.com
- www.radsources.com
- www.seattlechildrens.org
- www.image-echographie.net