

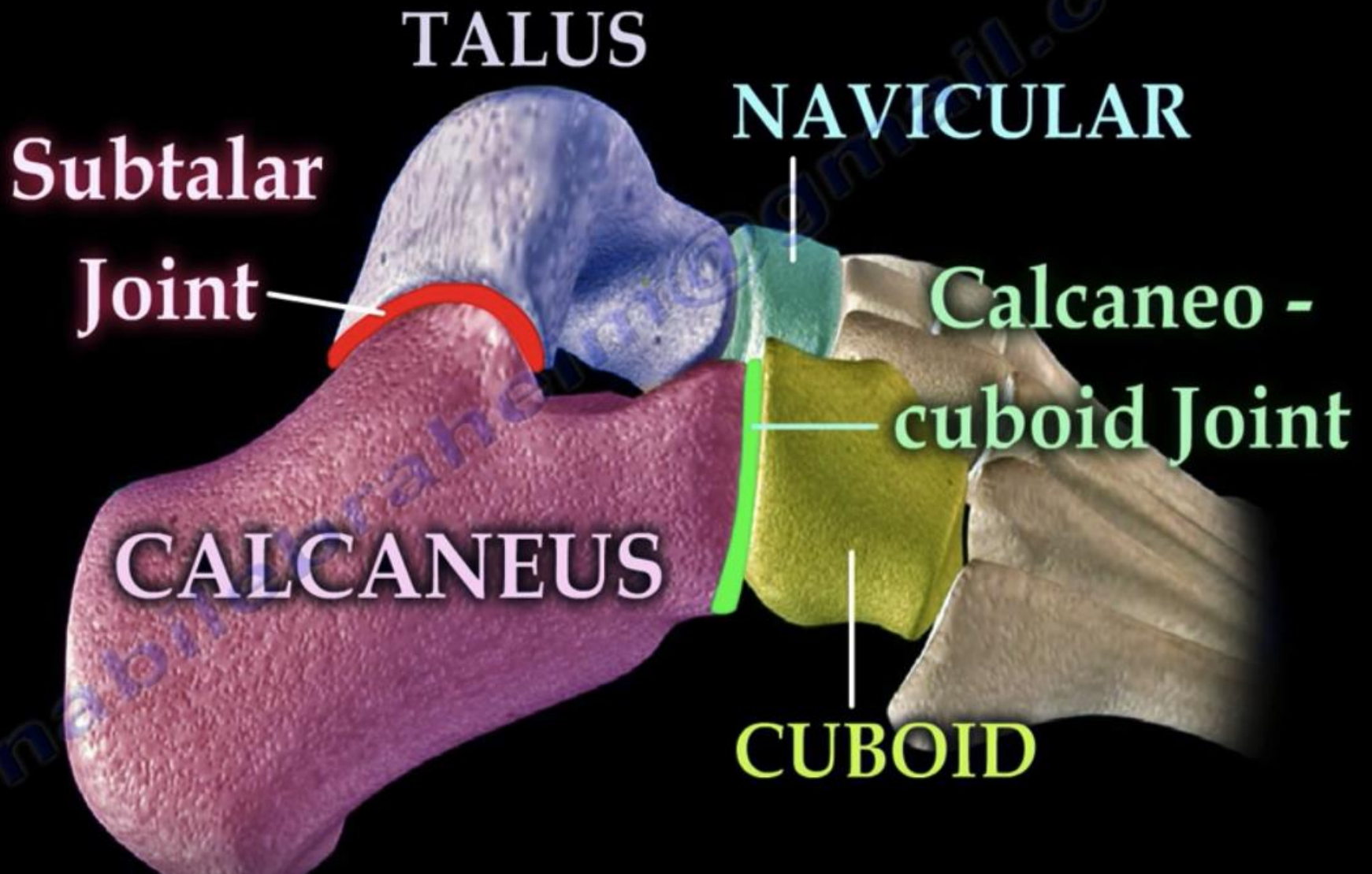
You Tube: Steph Curry Ankle Breaker





Hind Foot Trauma

Syed Ali MD



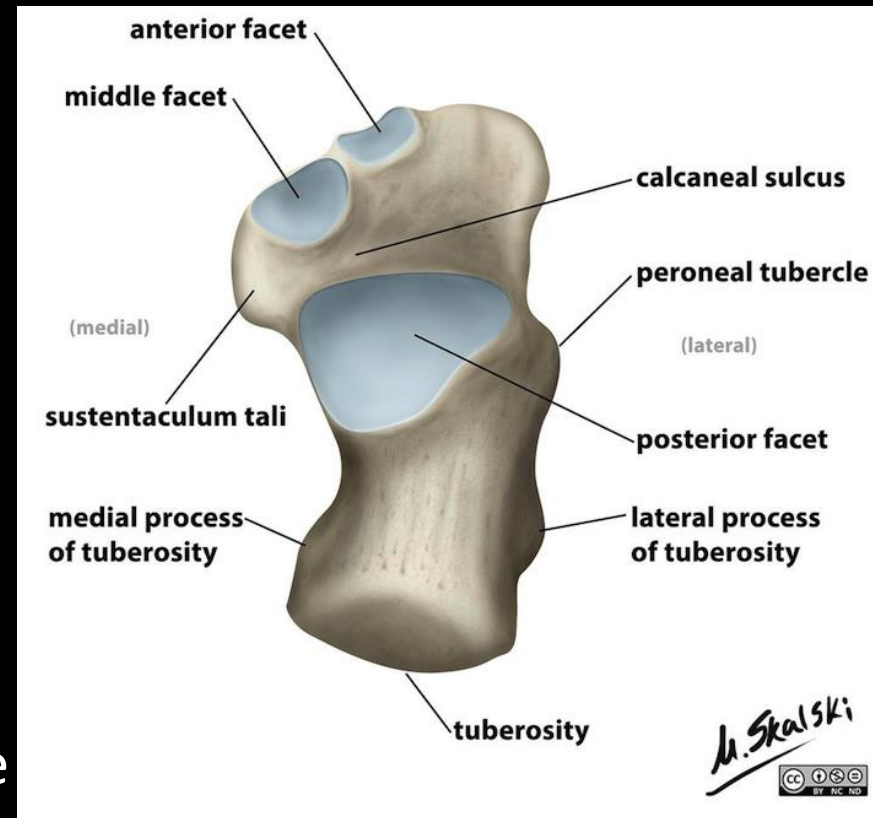
Calcaneus Articulations

- Subtalar Joint: Superiorly, the calcaneus articulates with the talus at the **talocalcaneal joint** making contact at anterior, middle and posterior facets.
- Chopart Joint: Anteriorly, the calcaneus articulates with the navicular (**talocalcaneonavicular joint**) and the cuboid (**calcaneocuboid joint**) bones.

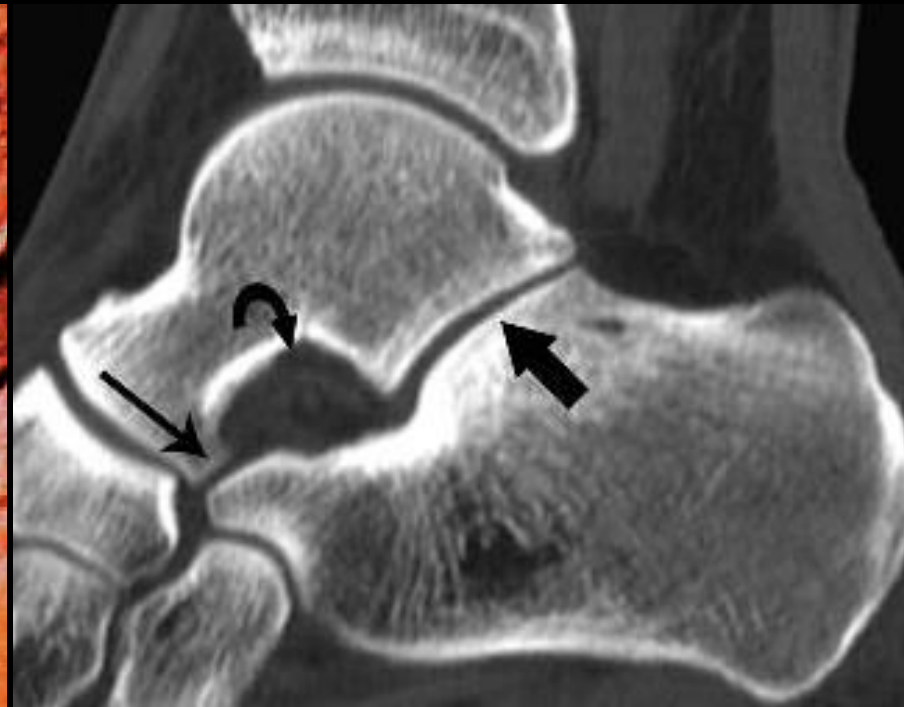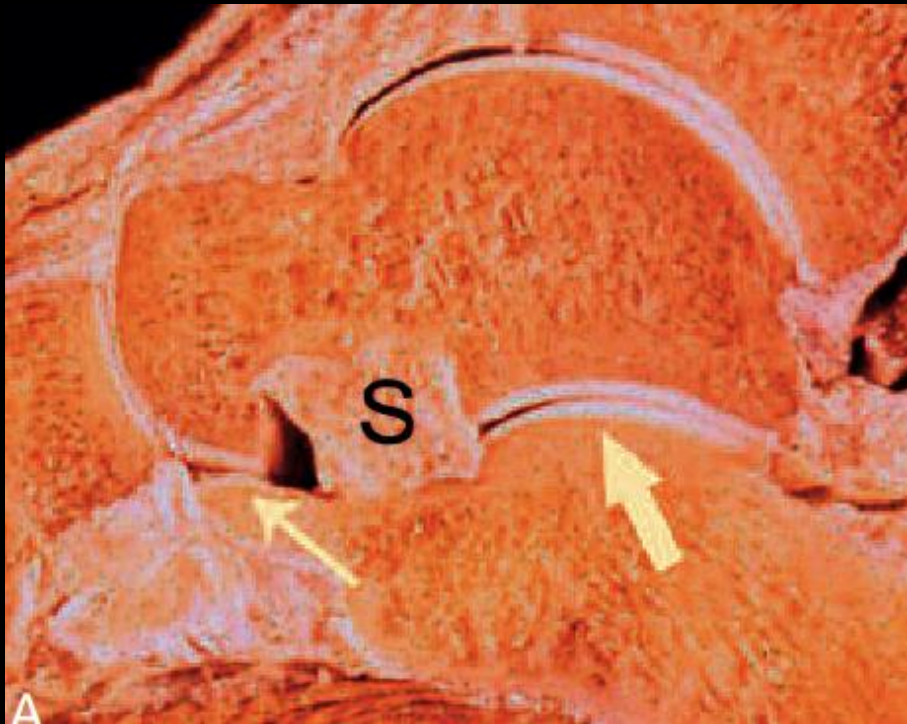
SUBTALAR JOINT

Superior Surface

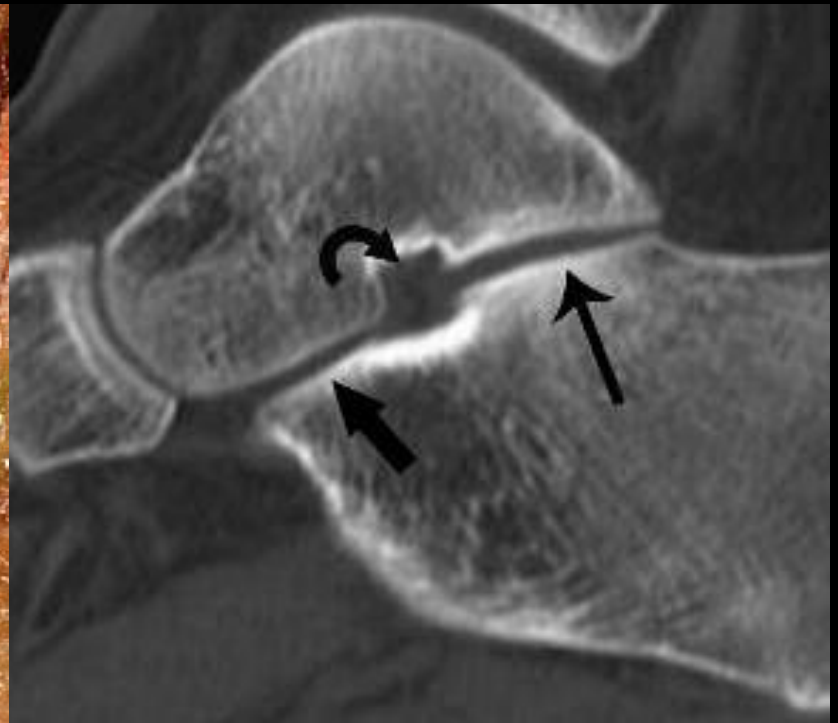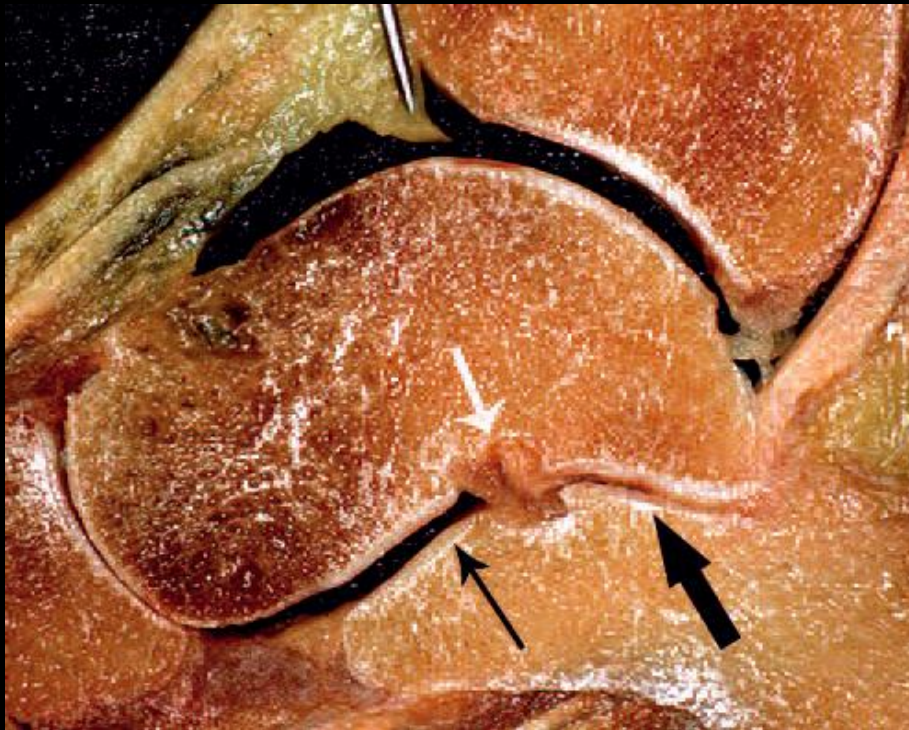- 4 articulating surfaces
- Posterior, middle, and anterior facets
- Calcaneal sulcus
- Sinus tarsi: calcaneal sulcus and talus
- Middle facet supported by sustentaculum Tali
- Anterior facet supported by the calcaneal beak.
- Triangular anterior surface of the calcaneus articulates with the cuboid



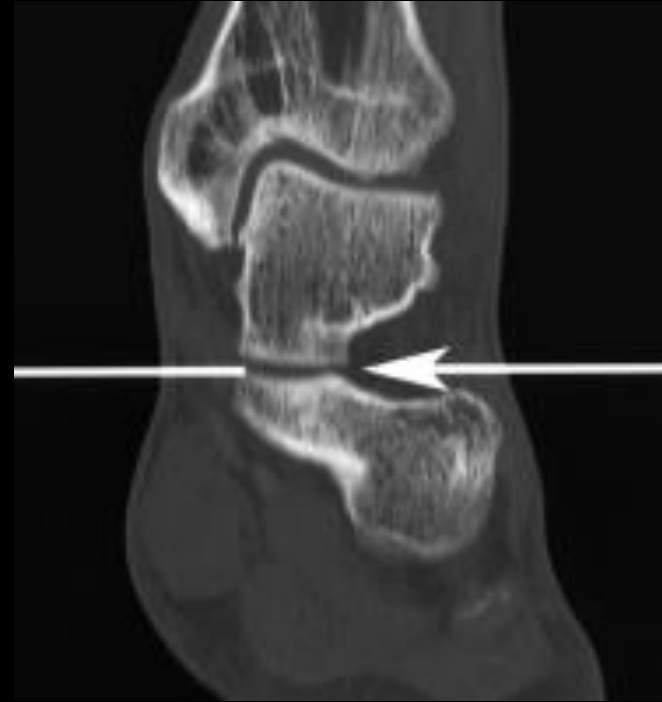
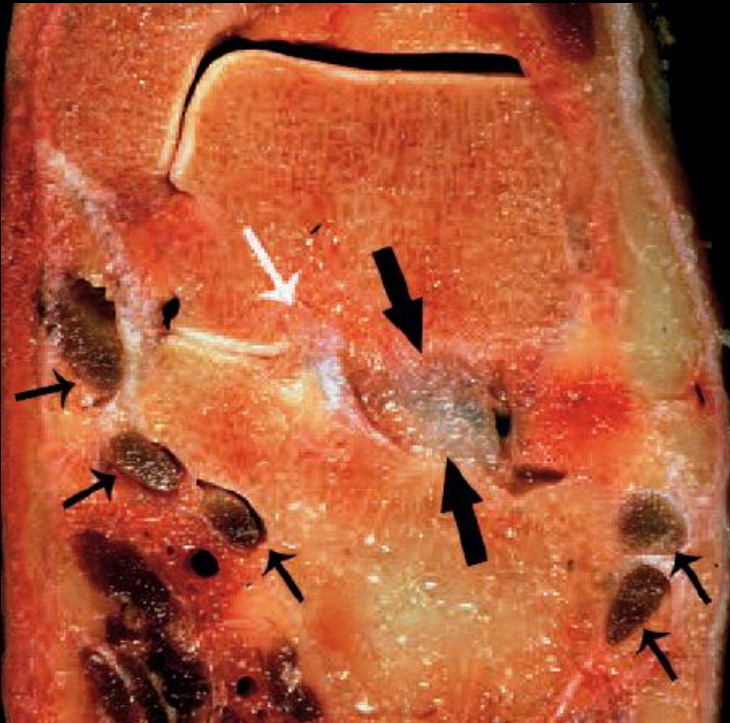
Subtalar Joint



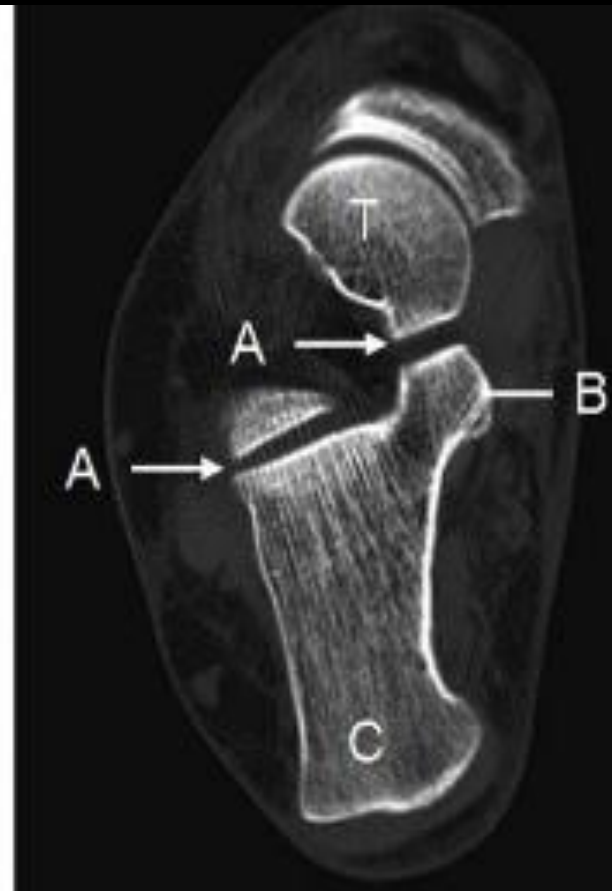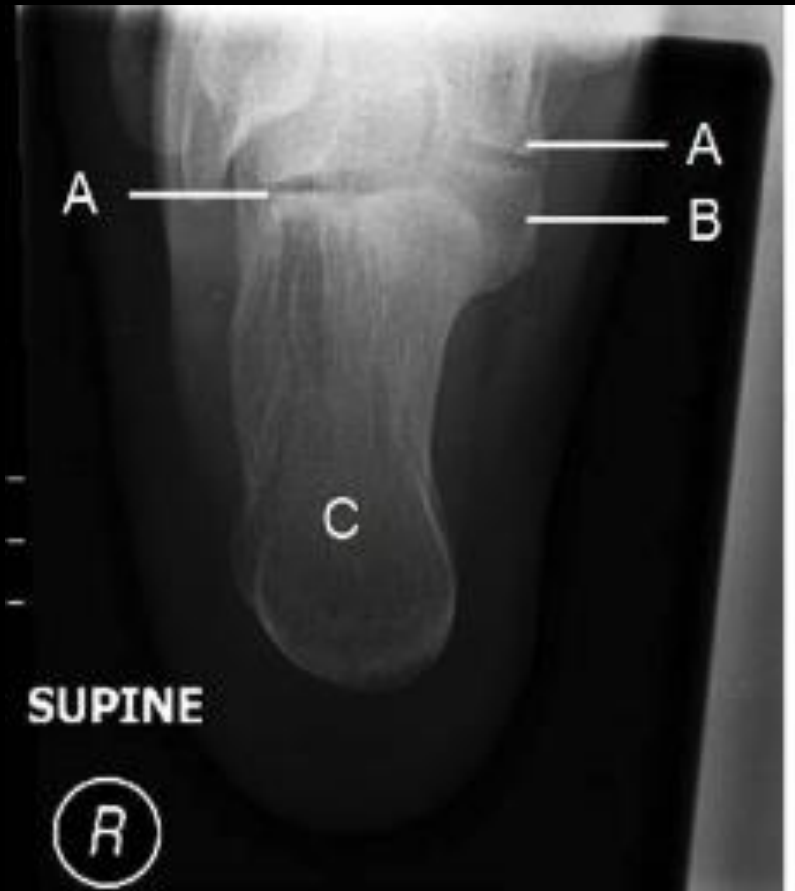Subtalar Joint



Subtalar Joint

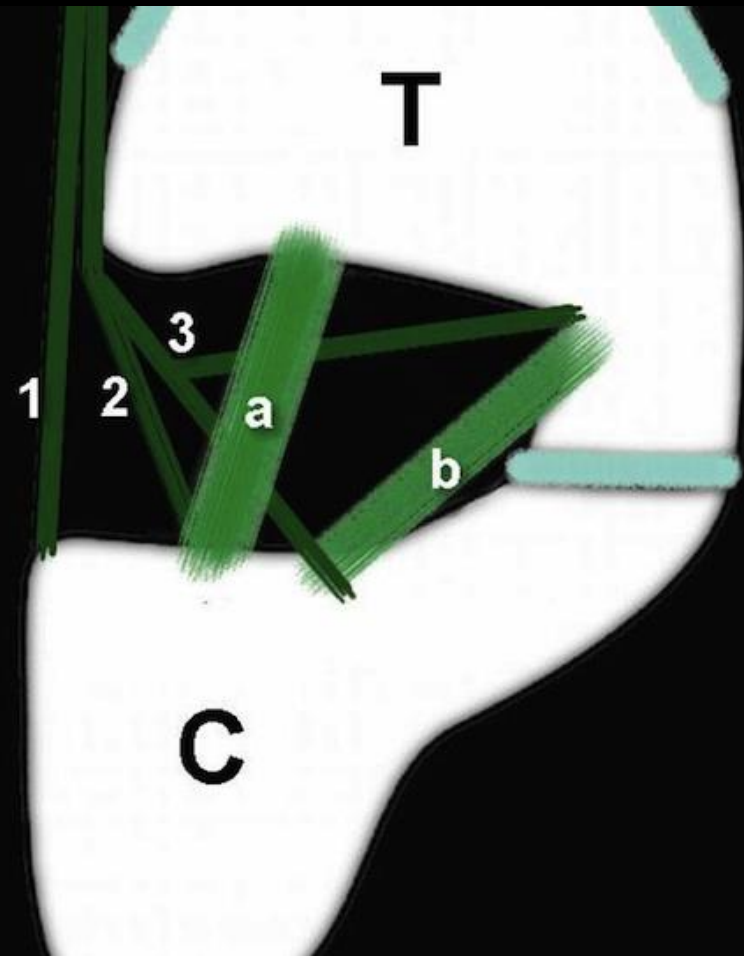


Subtalar Joint (Harris View)

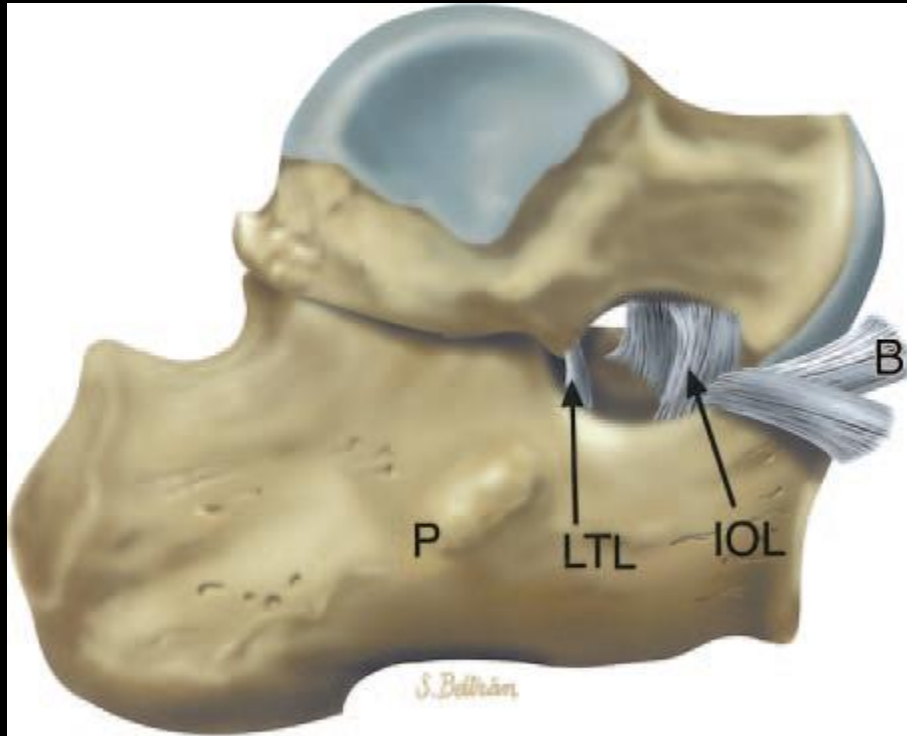


Subtalar Ligaments

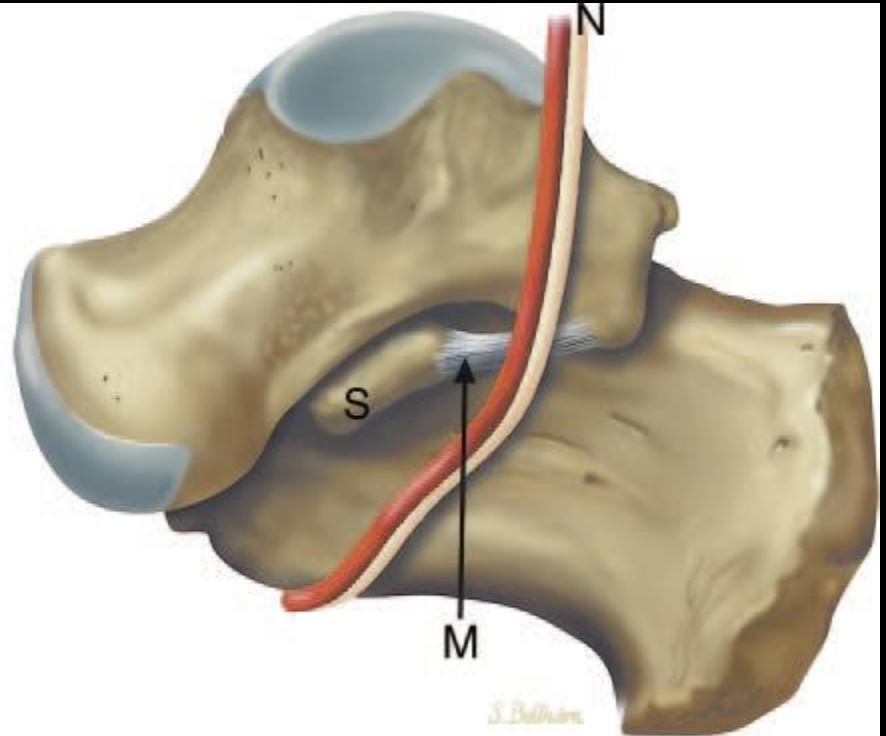
- Tarsal sinus ligaments, including:
 - a) Cervical ligament
 - b) Talocalcaneal interosseous ligament
 - c) Medial and Lateral Talocalcaneal ligaments
 - 1) Lateral,
 - 2) Intermediate, and
 - 3) Medial roots of the inferior extensor retinaculum



Medial and Lateral Talocalcaneal ligaments

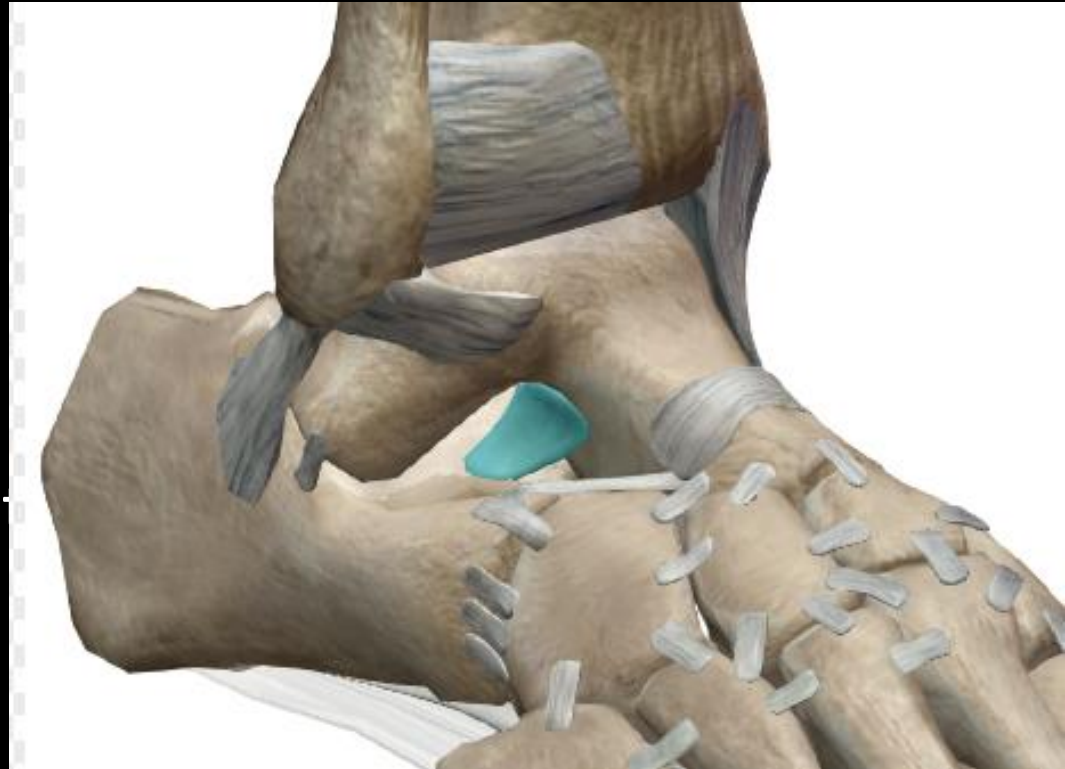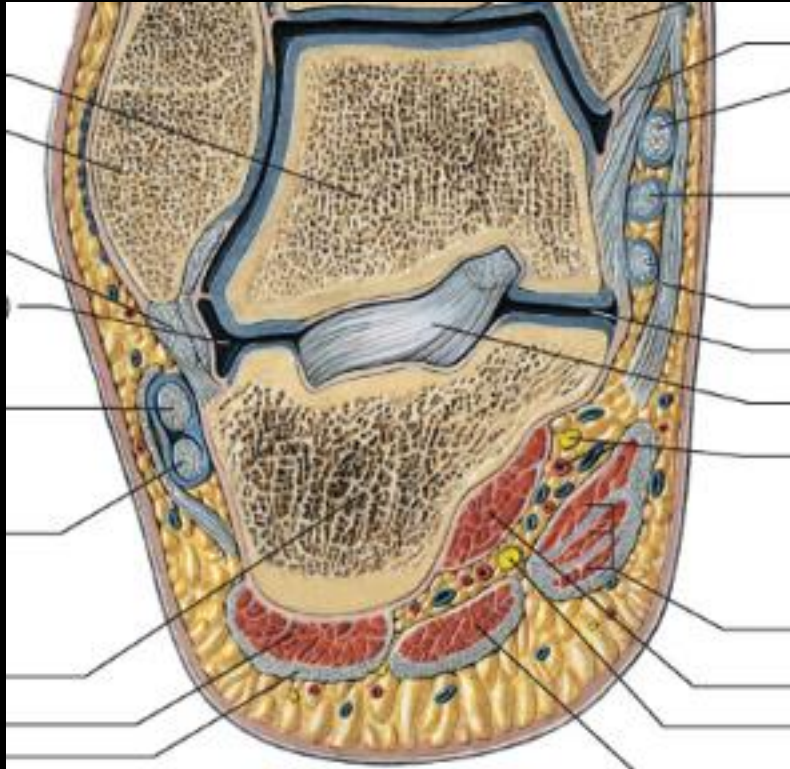


3.

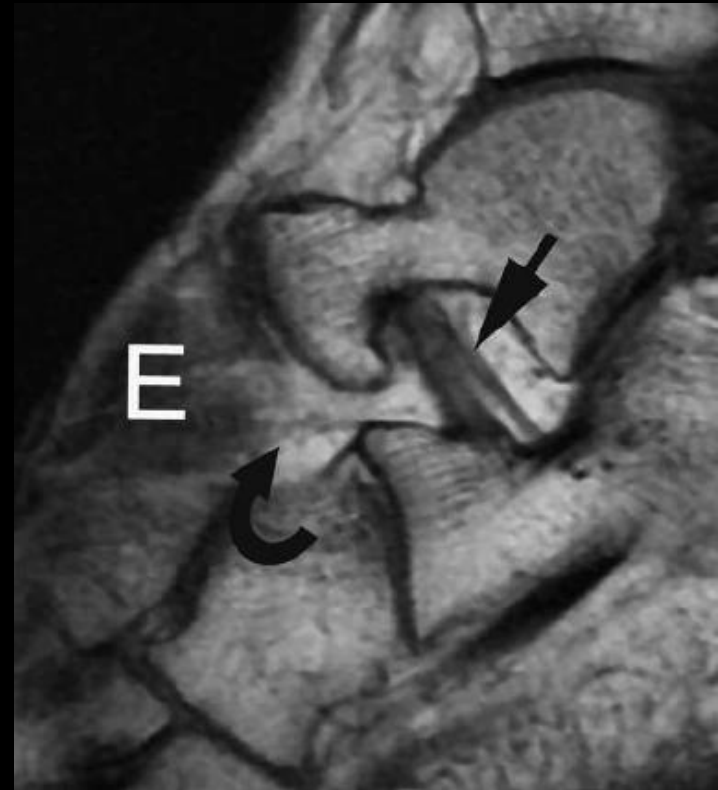
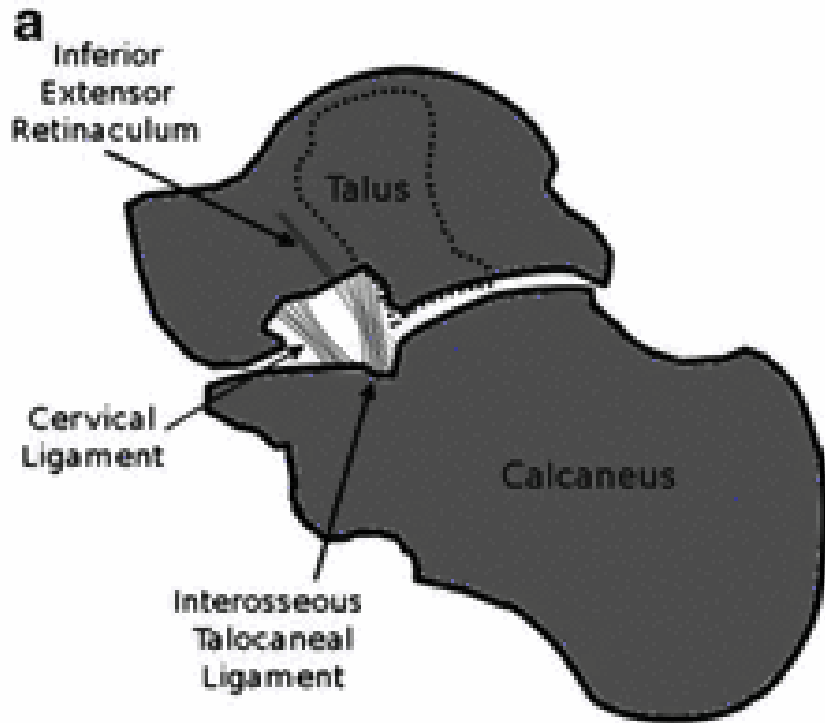


4.

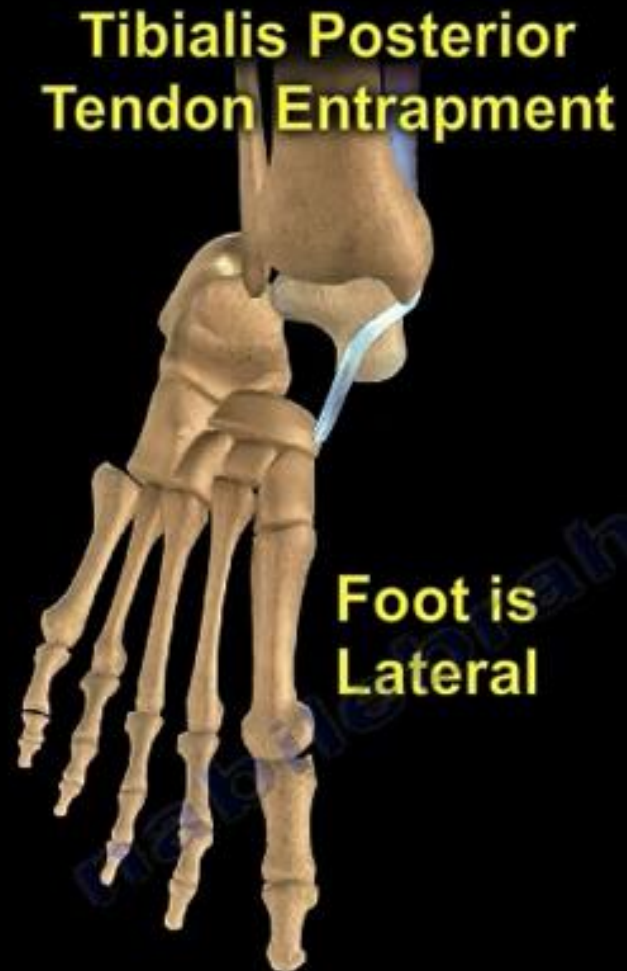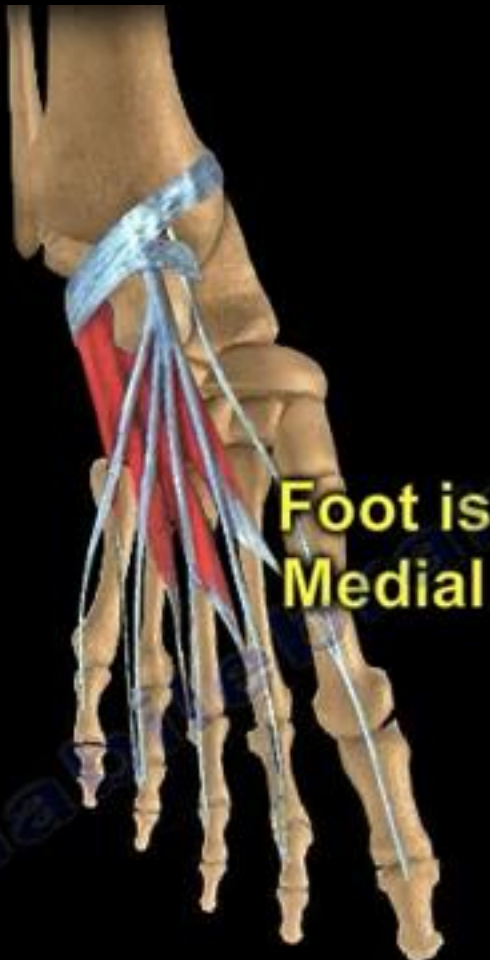
Interosseous Talocalcaneal Ligament



Cervical Ligament



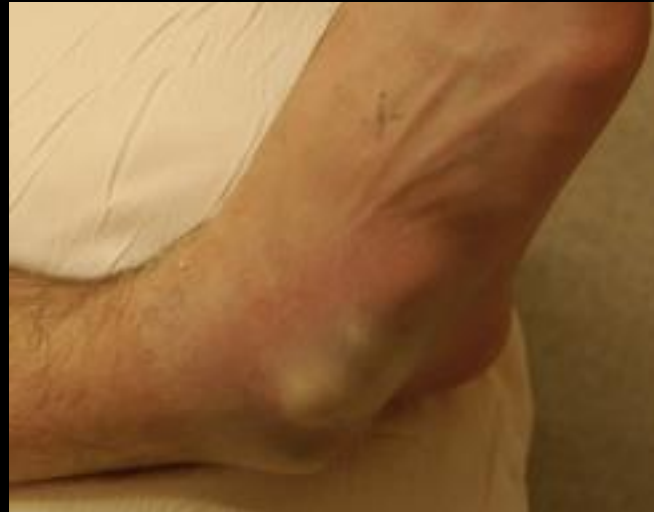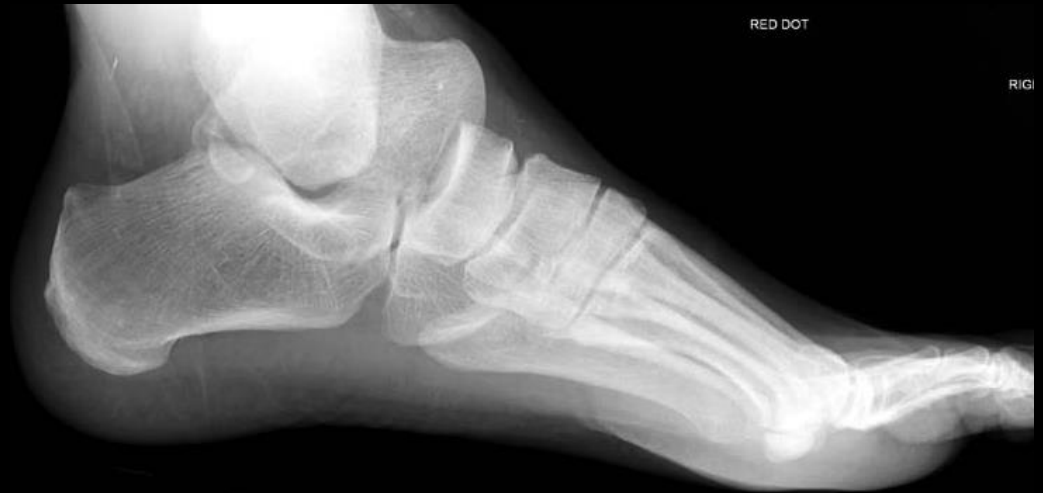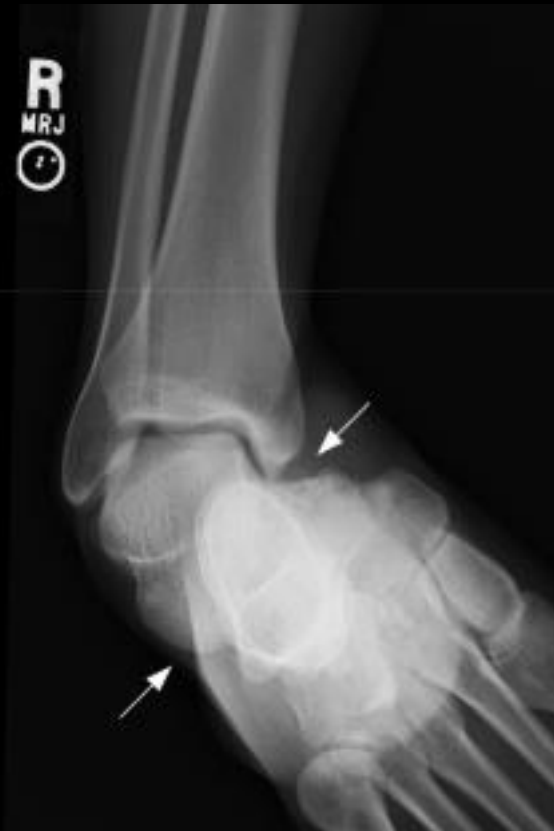Subtalar Dislocation (peritalar or hindfoot dislocation)



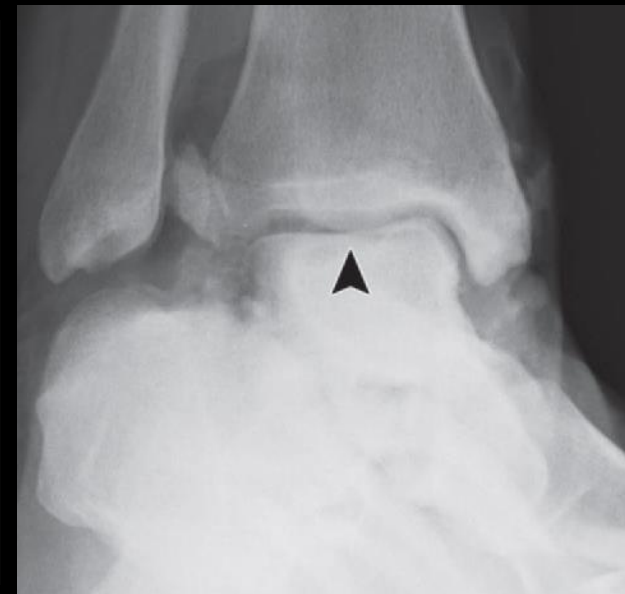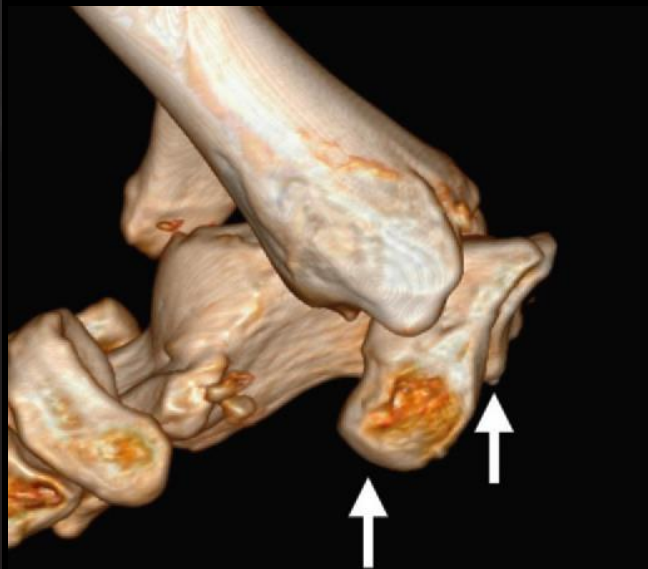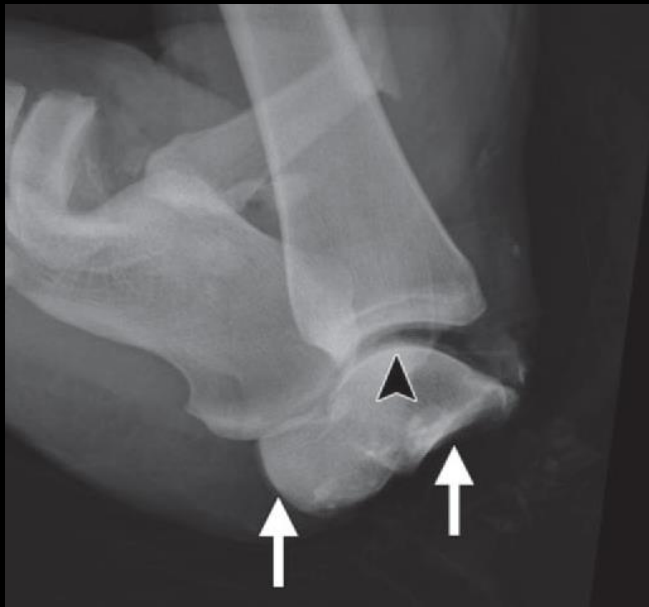
Subtalar Dislocation

- 65% to 80% are medial dislocations
- Remaining are lateral dislocations
- Case reports of anterior or posterior dislocations
- Osteochondral Fractures: up to 100% of lateral dislocations and 12%–38% medial dislocations
- Routine postreduction CT has been recommended to detect these fractures more accurately

Medial Subtalar Dislocation



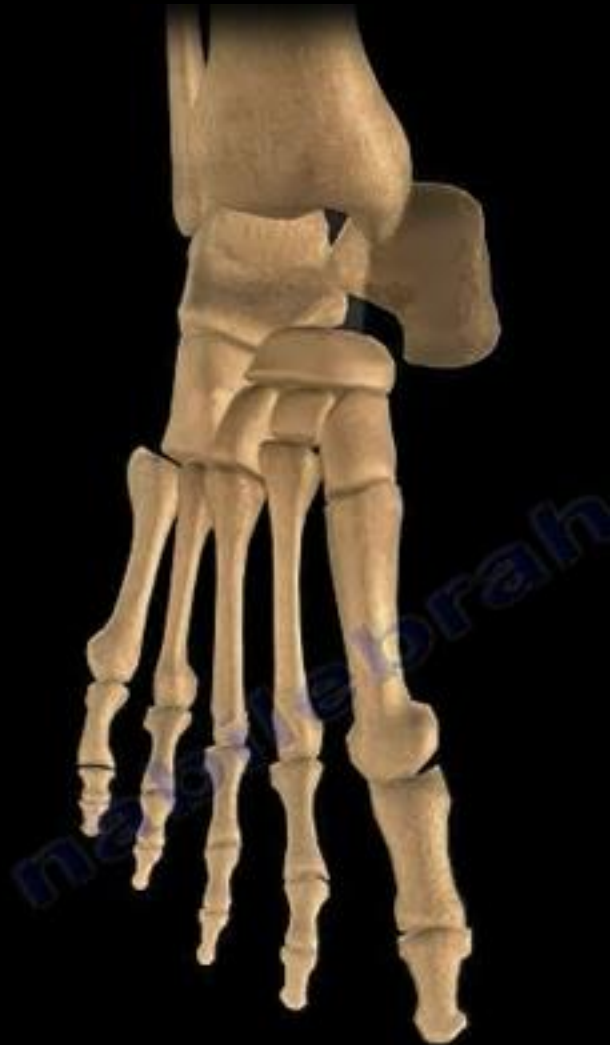Lateral Subtalar Dislocation



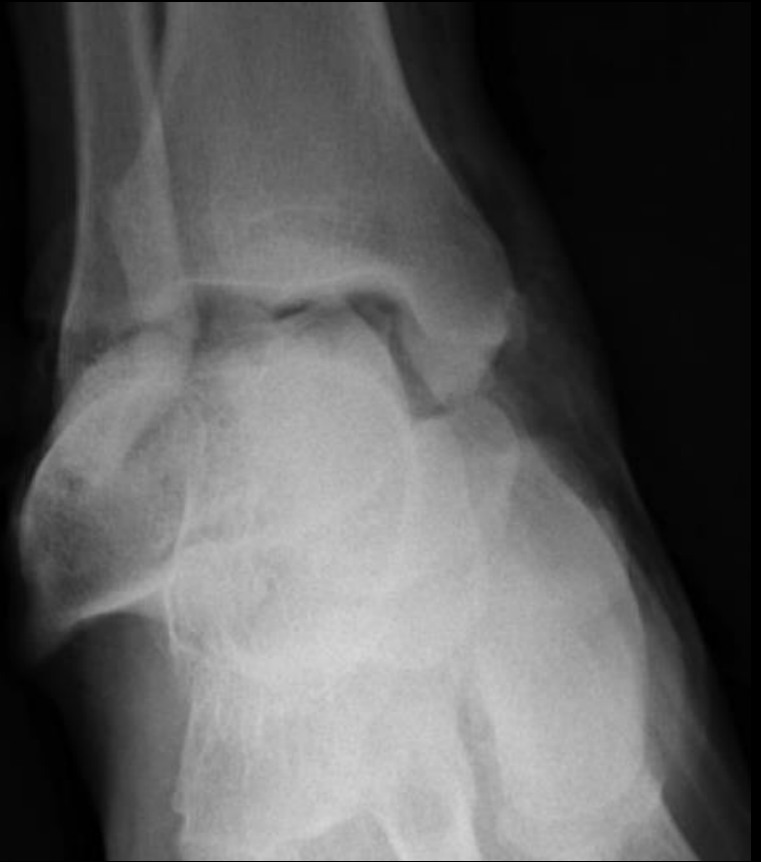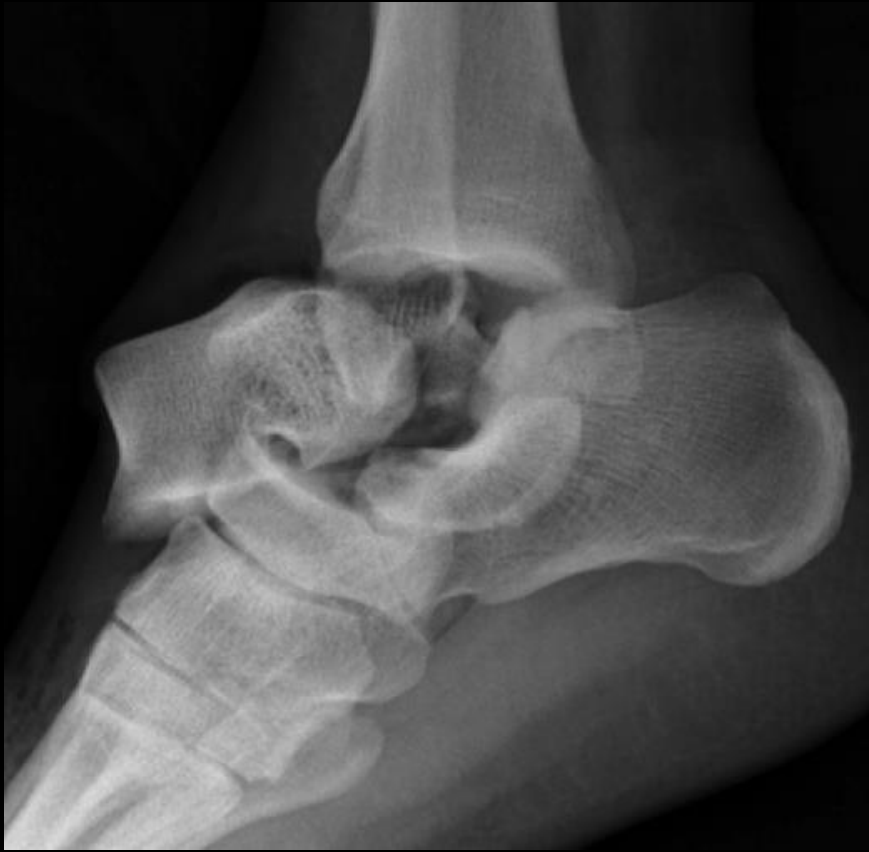Lateral Subtalar dislocation

Total Dislocation(pan-talar and luxatio tali totalis)

- Dislocation of the talus from all its articulations,
- Uncommon
- Devastating injury resulting from high-energy trauma.
- Almost all are open injuries.
- Avascular necrosis and osteomyelitis



Total Dislocation



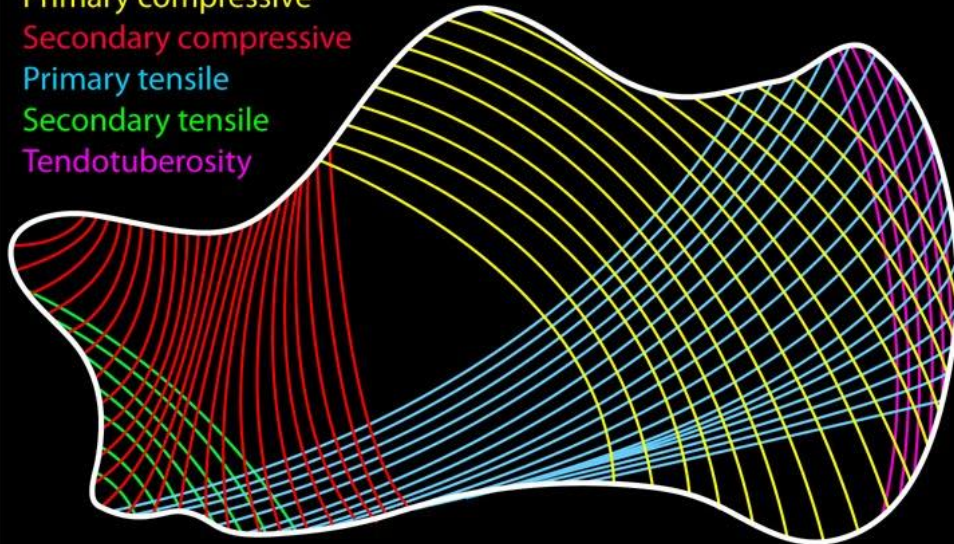
You Tube: Steph Curry Chris Paul

State Farm[™] We offer disability insurance!

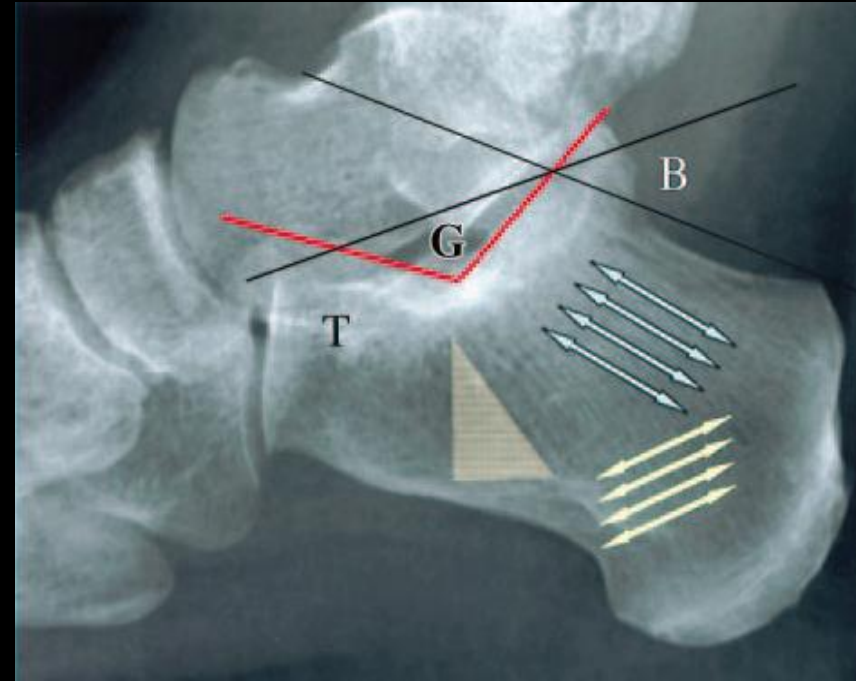
Calcaneus

Tensile trabeculae and Compression trabeculae

Primary compressive
Secondary compressive
Primary tensile
Secondary tensile
Tendotuberosity

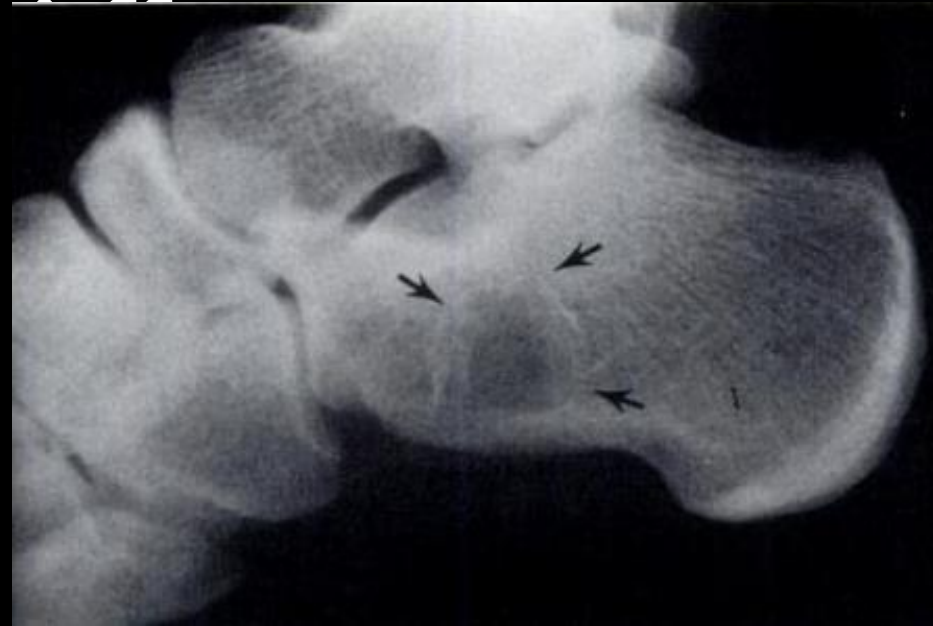

©Behrang Amini, MD/PhD



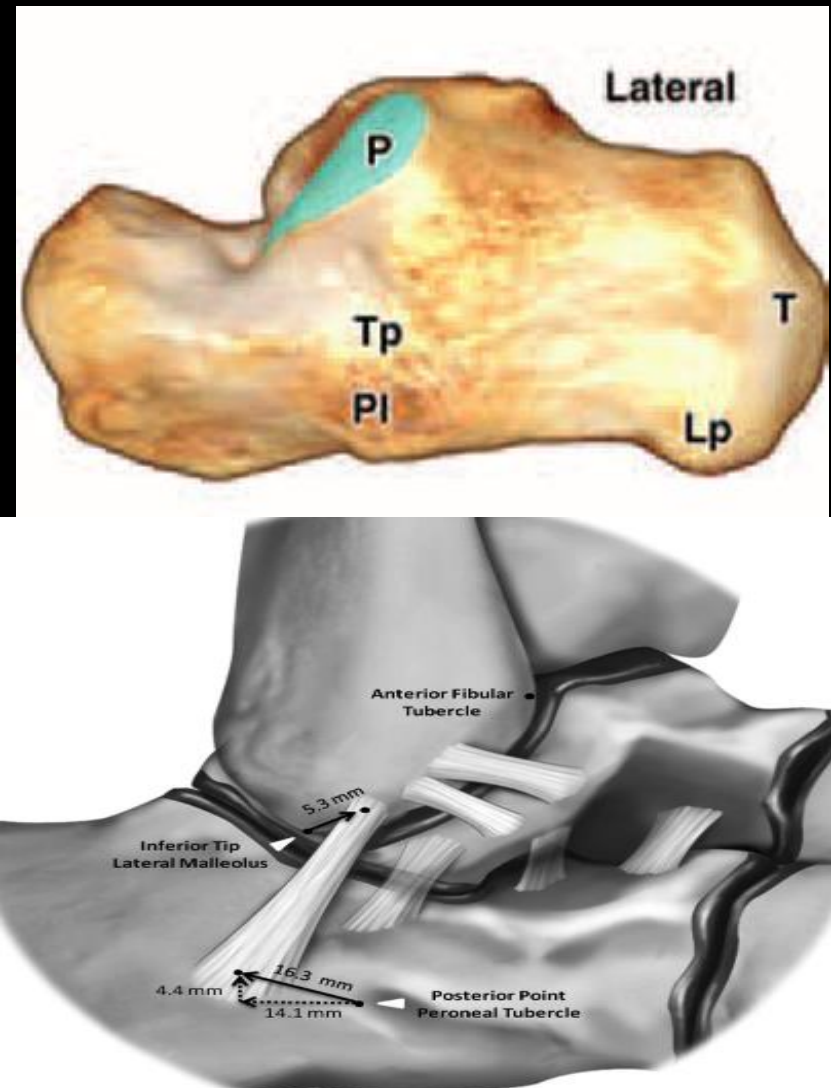
“Pseudocyst”

- “Pseudocyst” of the calcaneus



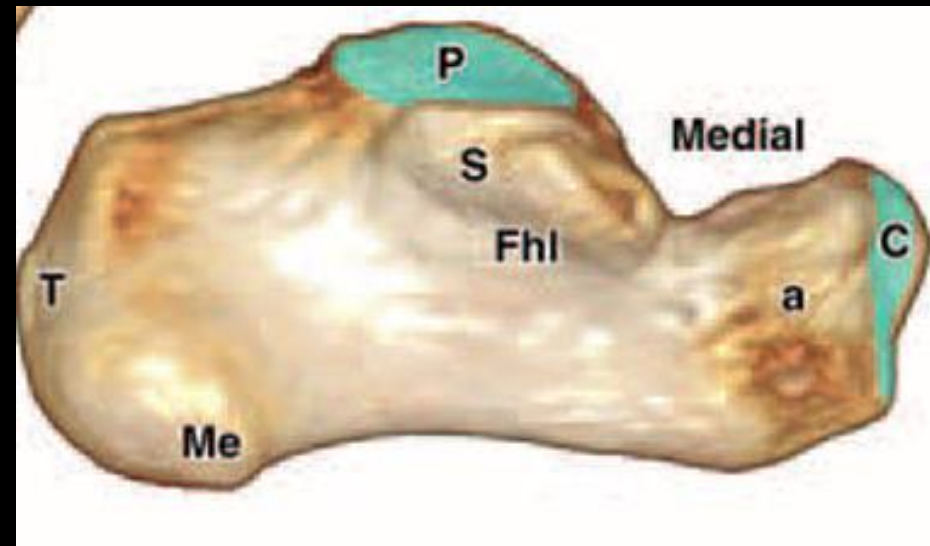
Lateral surface

- Flat and subcutaneous
- Central peroneal tubercle (PB and PL)
- Retrotrochlear Eminence
- Calcaneofibular ligament posteriorly
- Lateral talocalcaneal ligament attaches anterosuperiorly

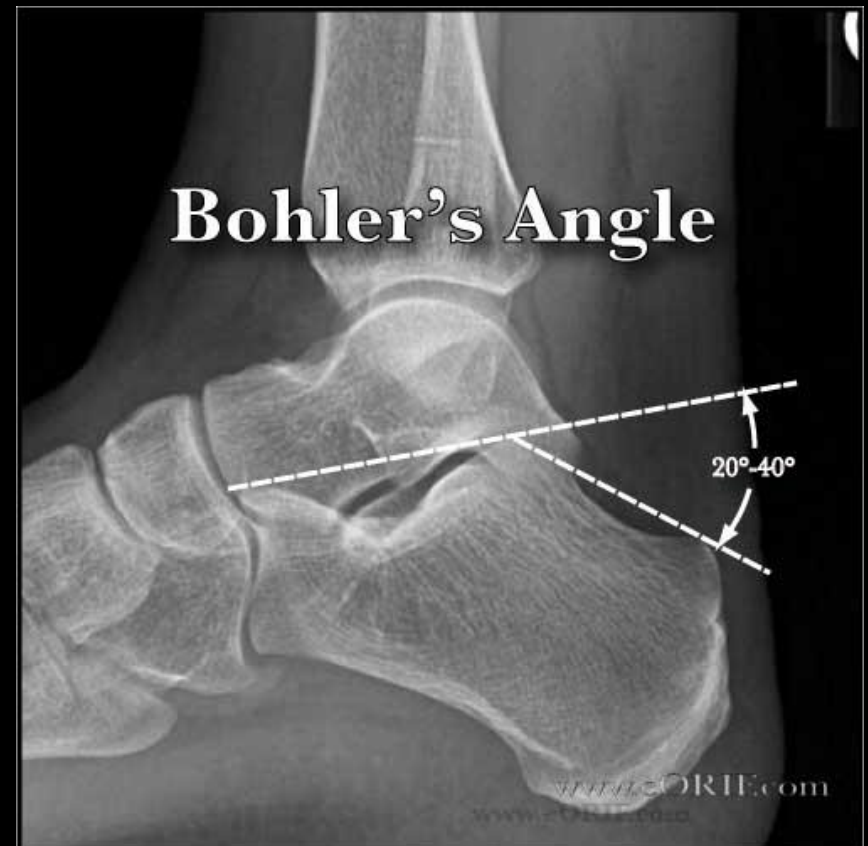

Medial Surface

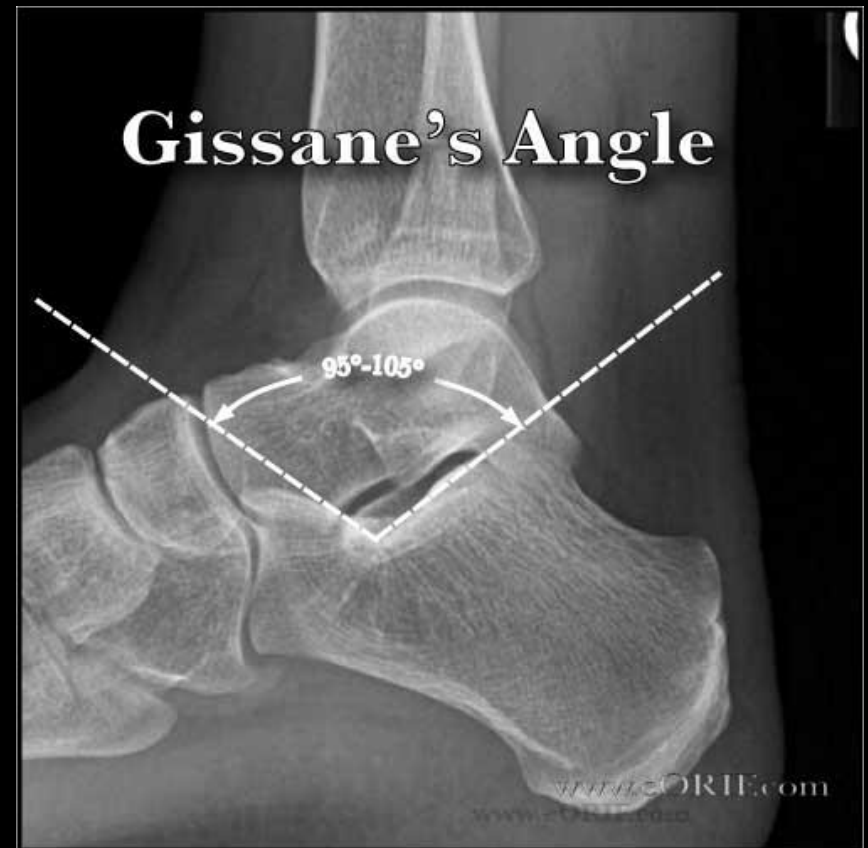- Sustentaculum tali is at the anterior aspect of the medial surface.
- Groove inferior to it transmits the flexor hallucis longus tendon.
- Neurovascular bundle runs adjacent to the medial border of the calcaneus



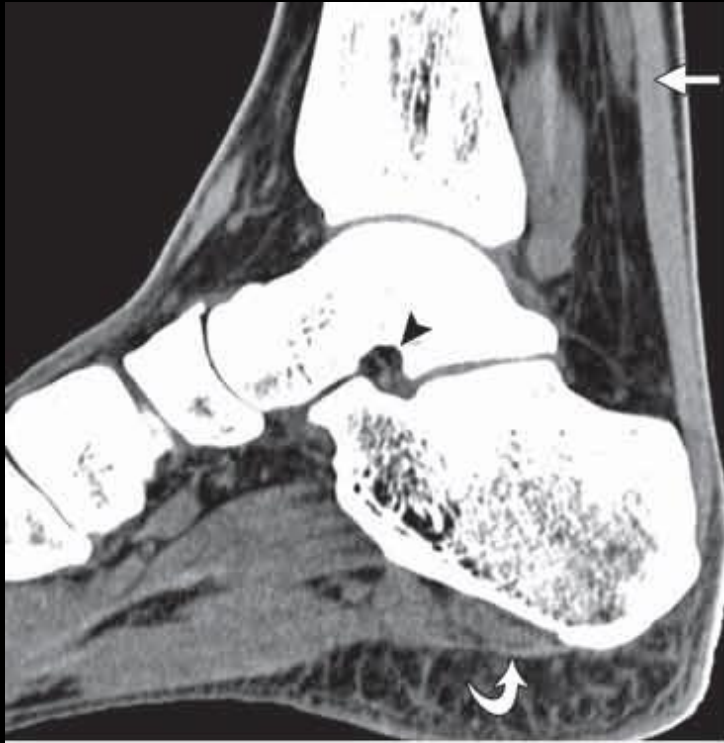- Normal Bohler angle:
20°- 40
- BA < less than 20°
Posterior facet collapse
from an underlying
fracture



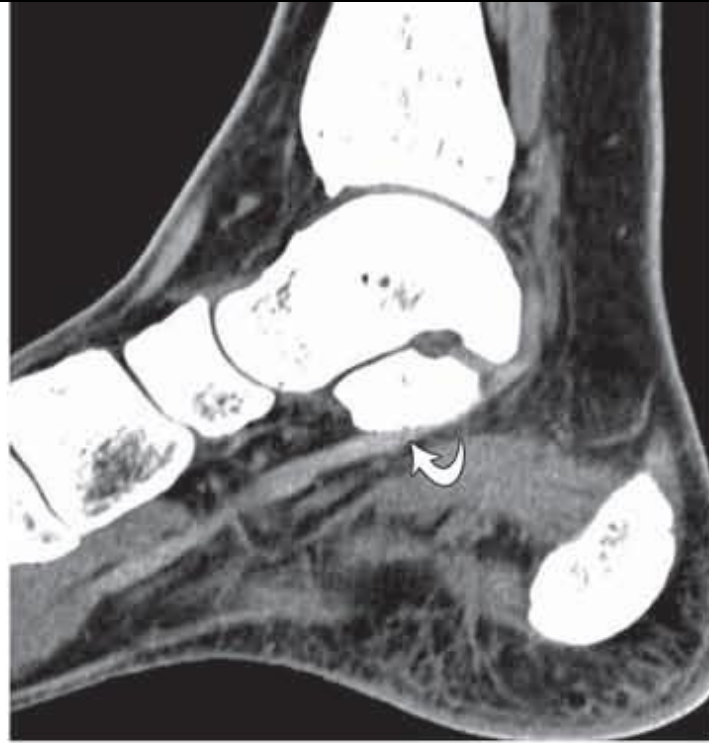- Normal Critical angle of Gissane: 95-105
- - CAG > 130°: Posterior facet collapse from an underlying fracture



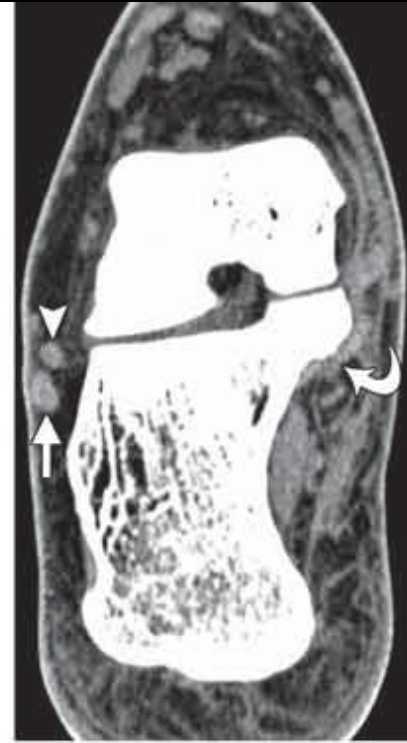Tendons



a.



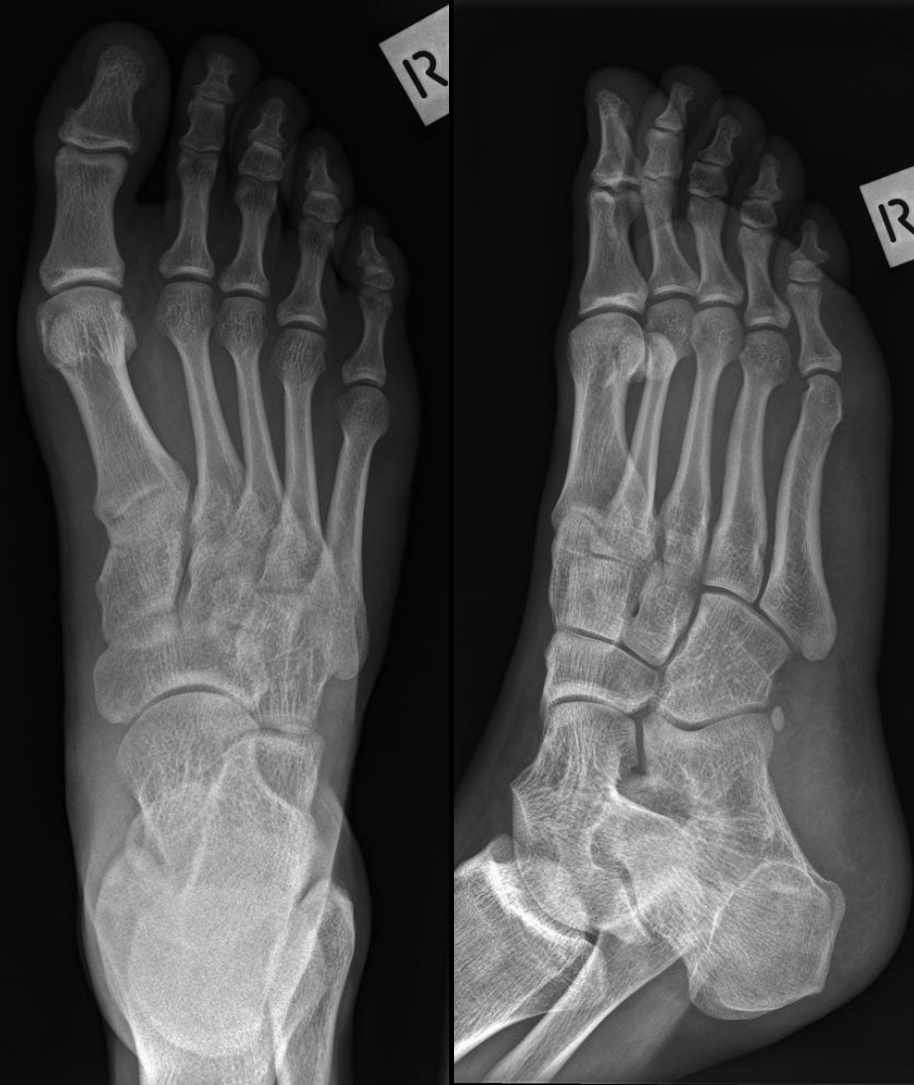b.



c.

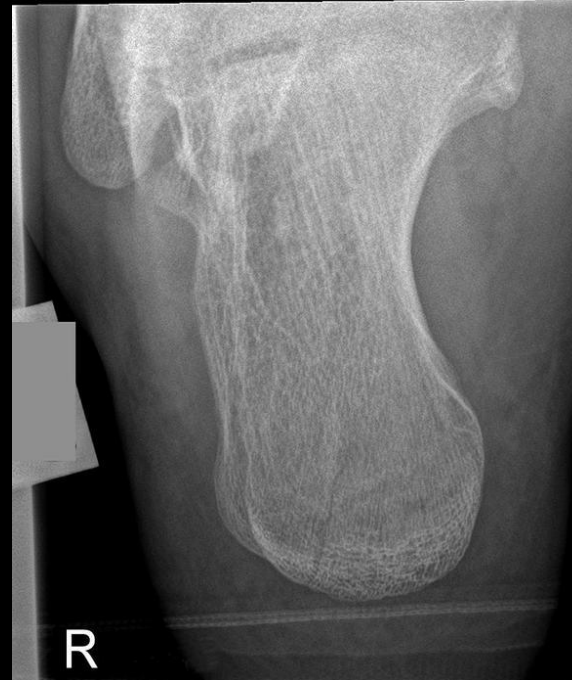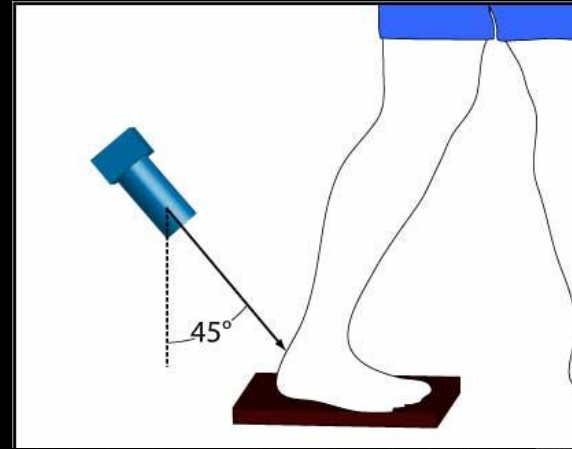
Radiographic Views

- (a) anteroposterior and oblique views assessment of the calcaneocuboid joint
- (b) axial view of the heel (Harris view), and
- (c) Brodens View: dorsiflexion and internal rotation of the foot to better visualize the subtalar joint and posterior facet.
- (d) spine, contralateral foot and knee



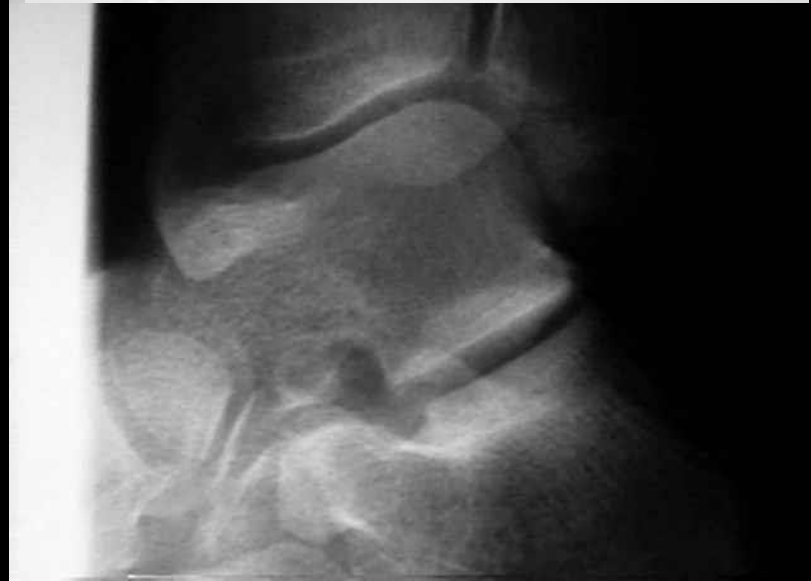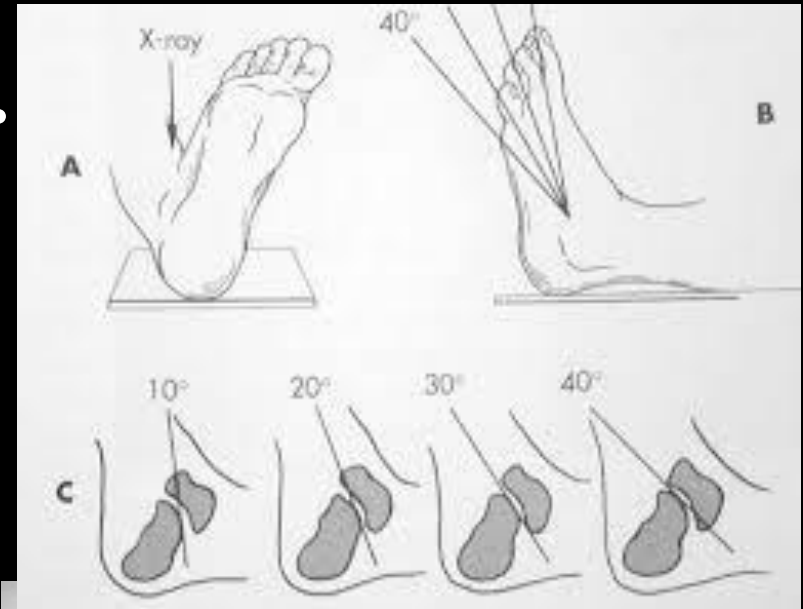
Harris Beath View

- Difficult in acute setting
- Demonstrates body of the calcaneus, middle facet of the subtalar joint and sustentaculum tali
- Heel width
- (Harris RI, JBJS 1948:30Br:624)



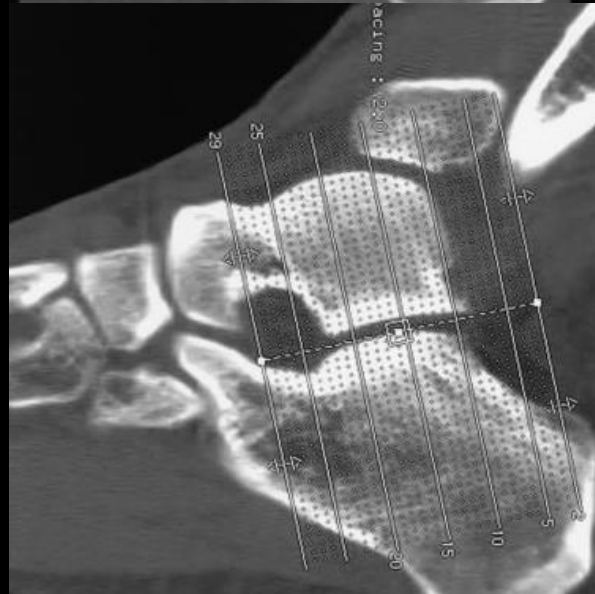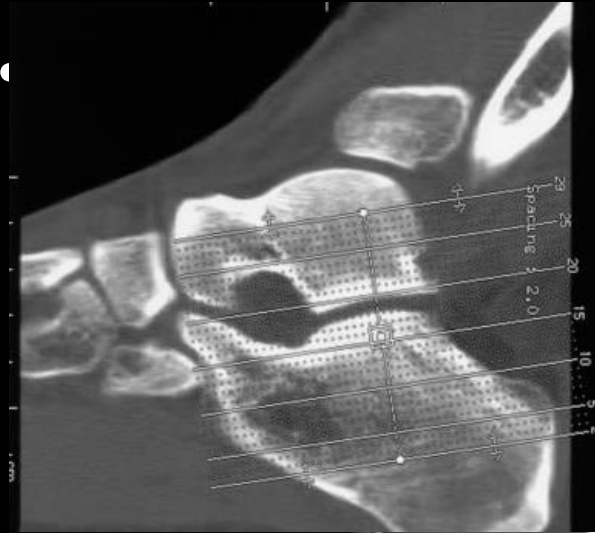Broden's View

- Better visualize subtalar joint
- Supine w/ foot rests on the film cassette with neutral dorsiflexion;
- Entire lower leg and foot is internally rotated 45 deg;
- Central beam directed toward the lateral malleolus;
- Films are obtained at 10, 20, 30, and 40 deg. of cephalic tilt
- (Bruden Acta Radiol 31:85;1949).



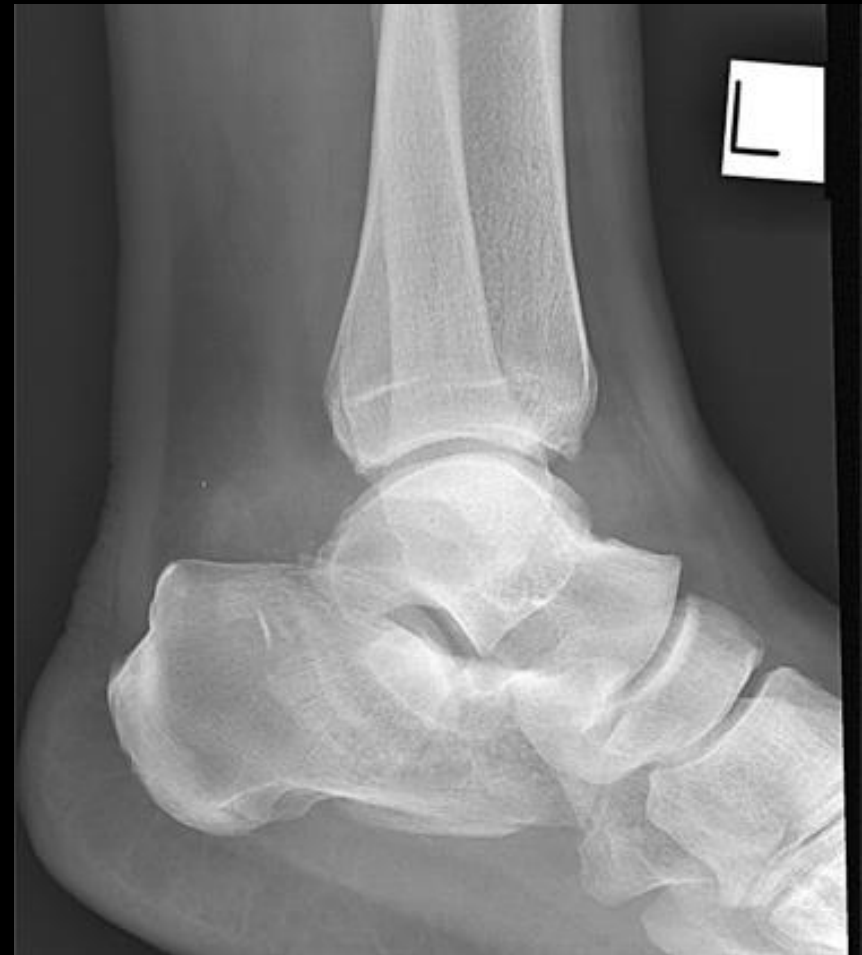CT scan

- For fracture classification, particularly with the Sanders classification
- Reformat images parallel and perpendicular to the posterior facet off the sagittal reformatted images.



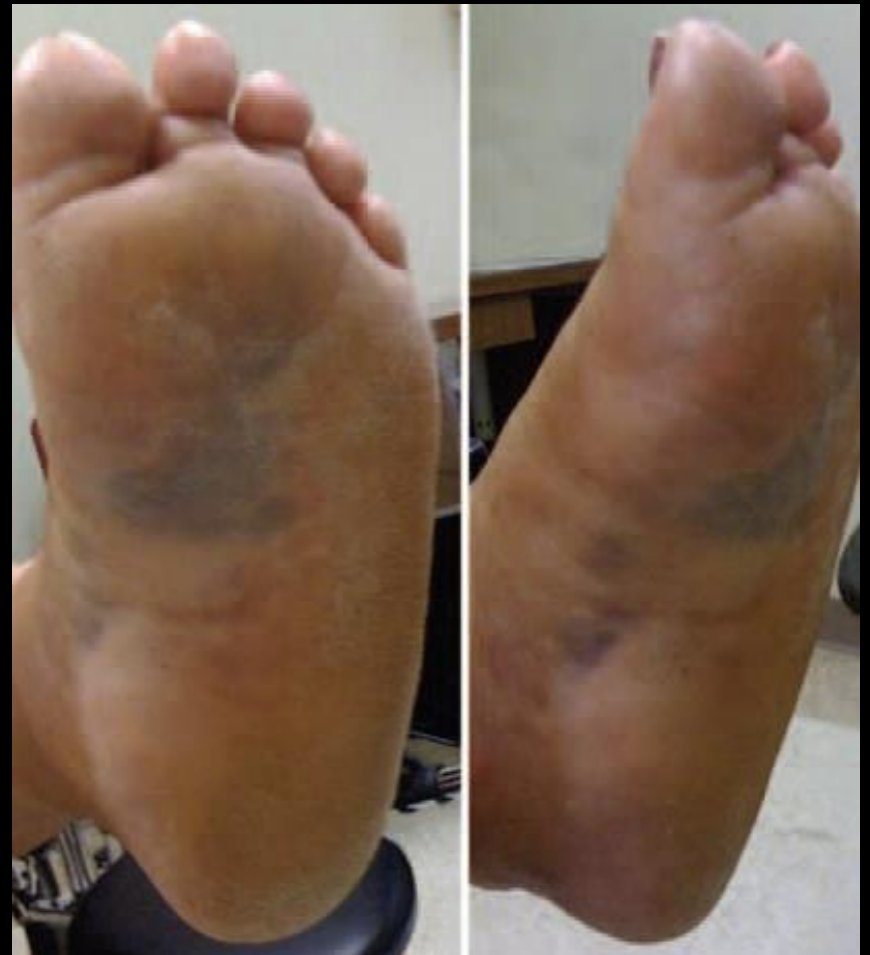Calcaneal Fractures

- Most common tarsal bone to be fractured
- 60% of fractures involving the tarsal bones
- 1%–2% of all fractures
- 17% open fractures
- Axial loading in men 30–60 years old
- Poor outcomes.

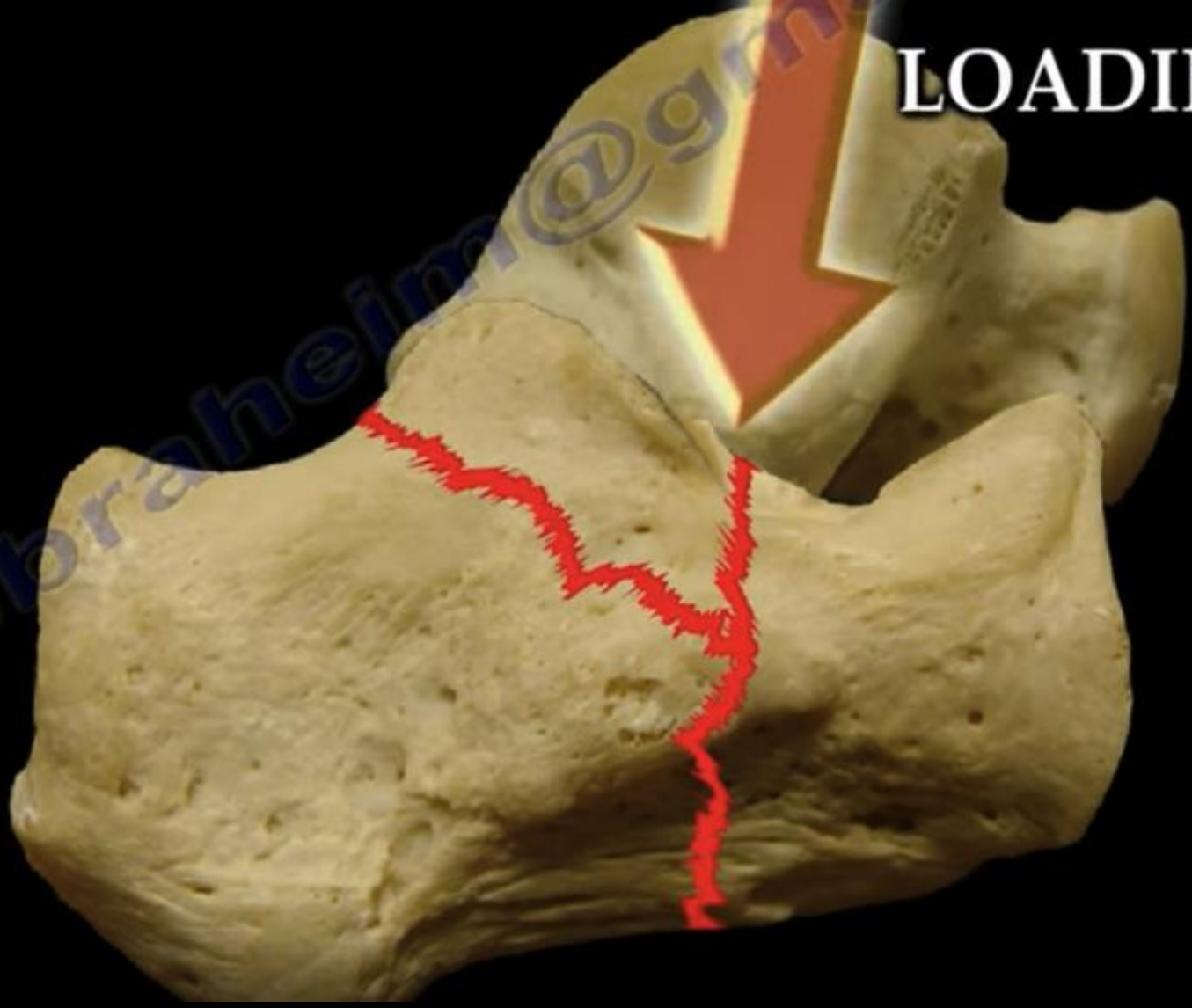


Calcaneal Fractures

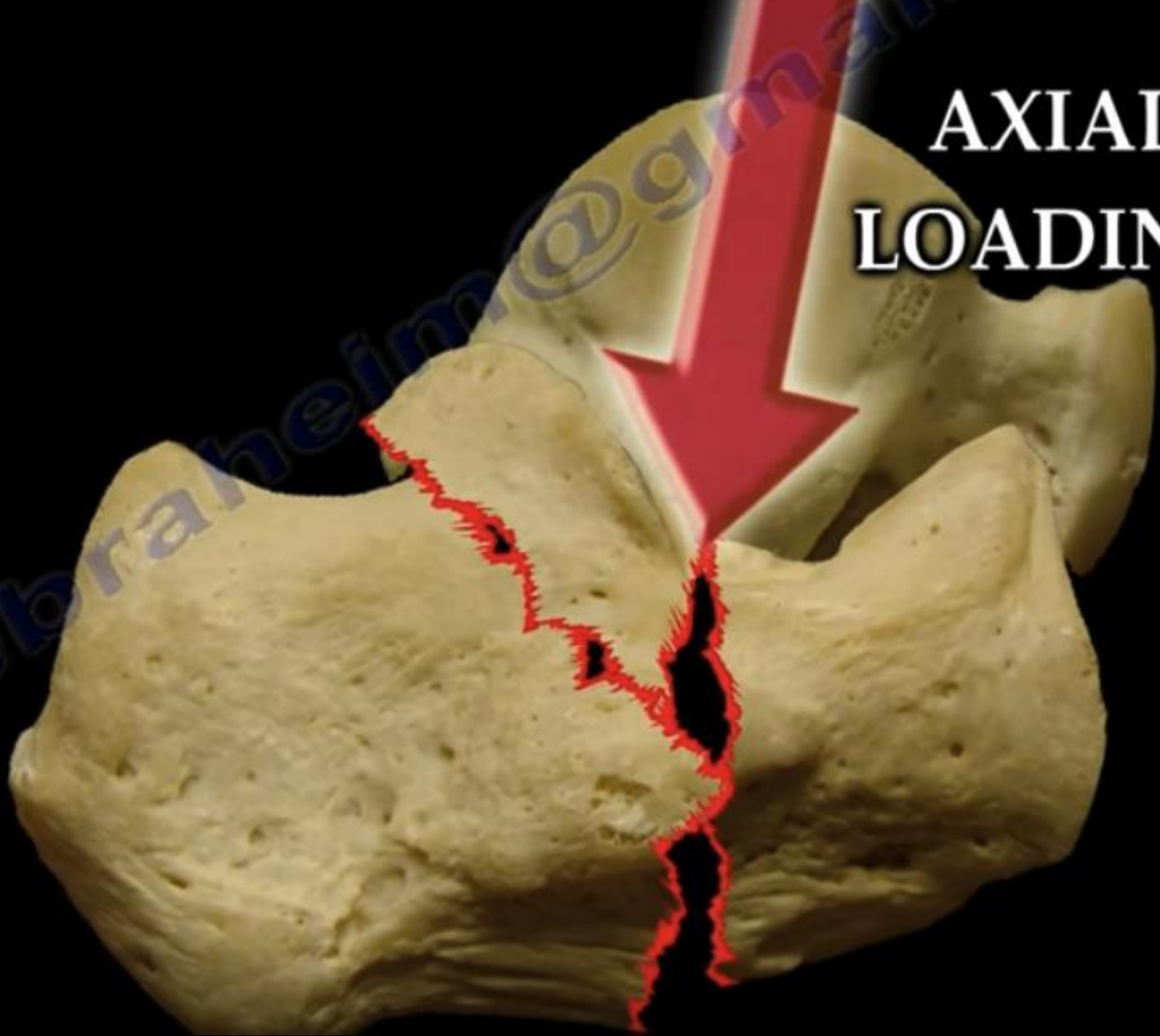
- “Mondor sign” :
haematoma that is
formed and extending
distally along the sole of
the foot.
- Considered
pathognomonic for
calcaneal fracture.



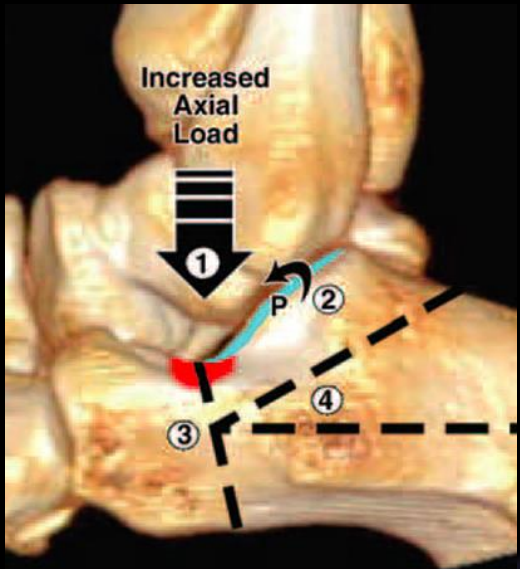
**AXIAL
LOADING**



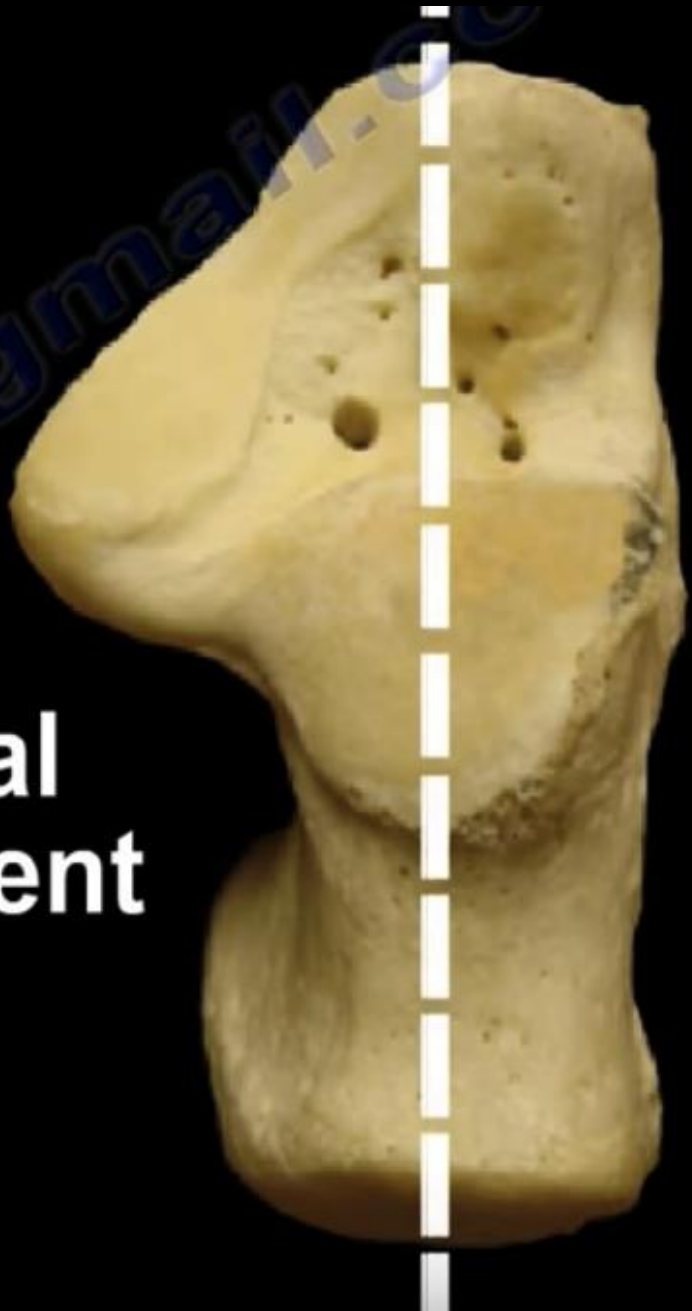**AXIAL
LOADING**



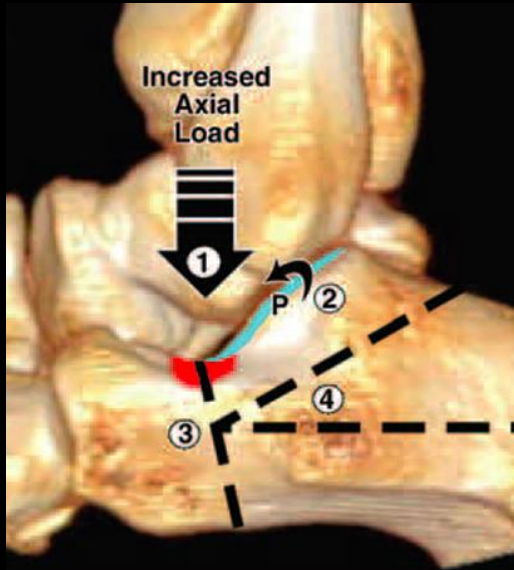
Pathoanatomy



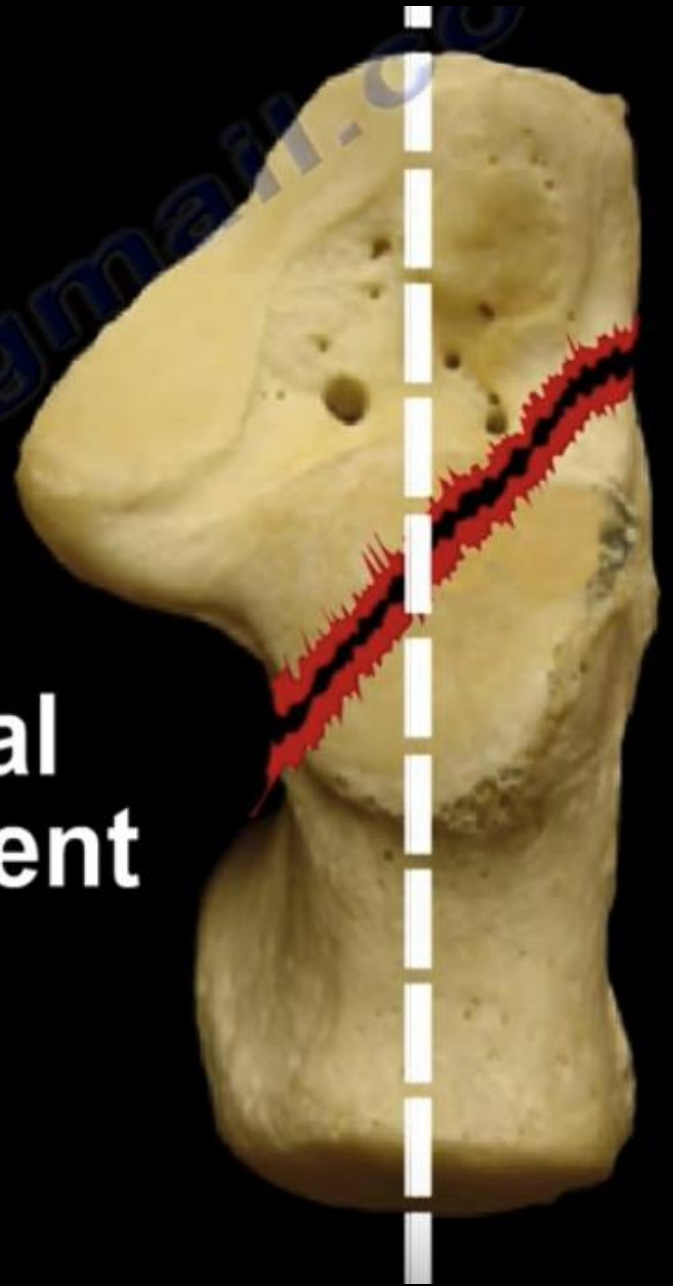
Normal Alignment



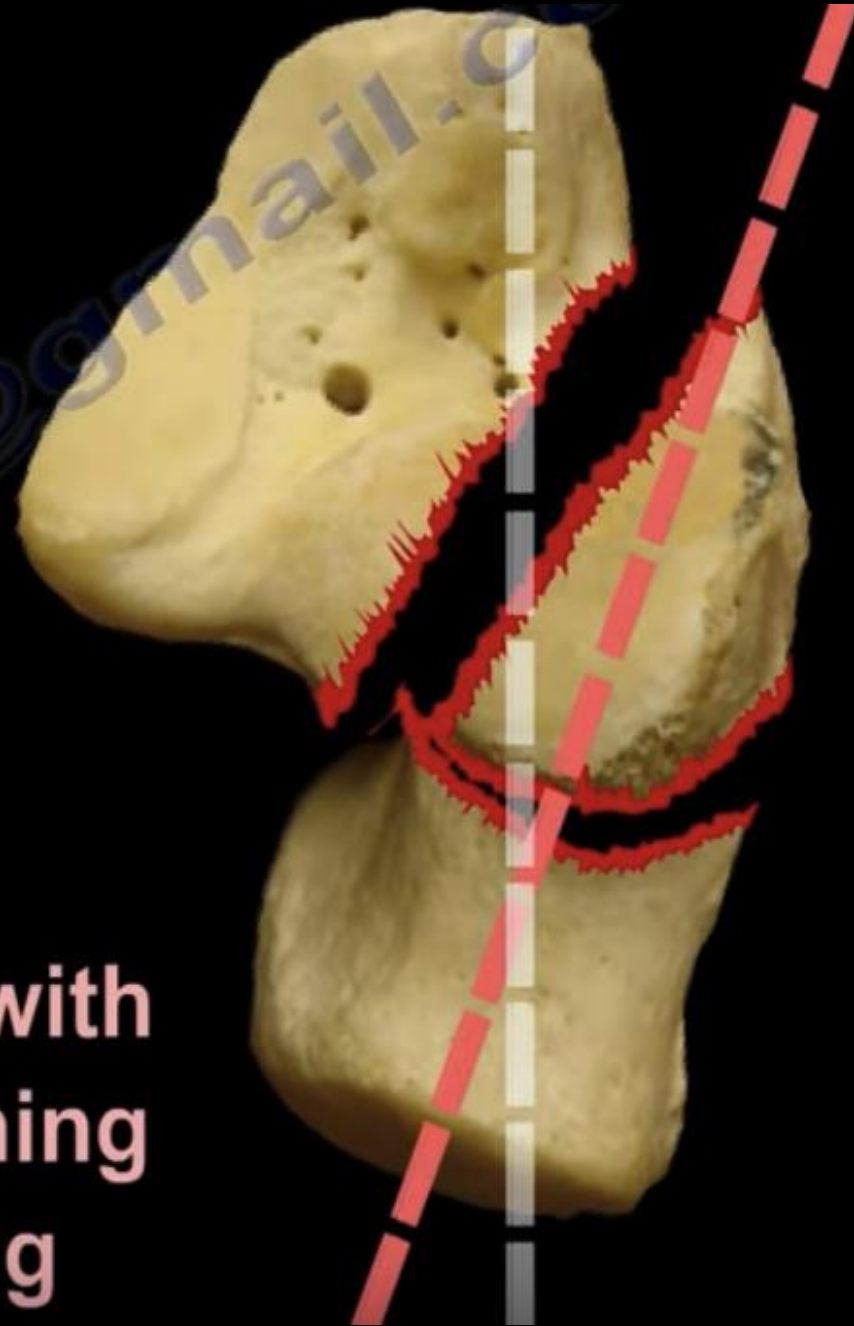
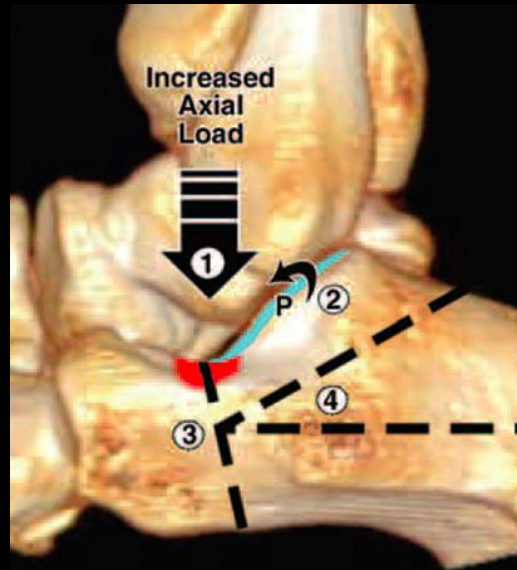
Pathoanatomy



Normal Alignment



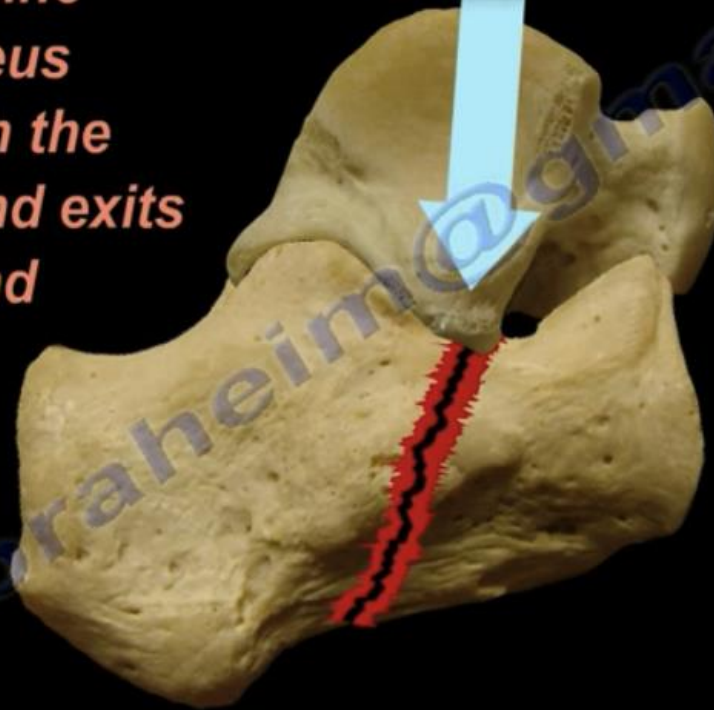
Pathoanatomy



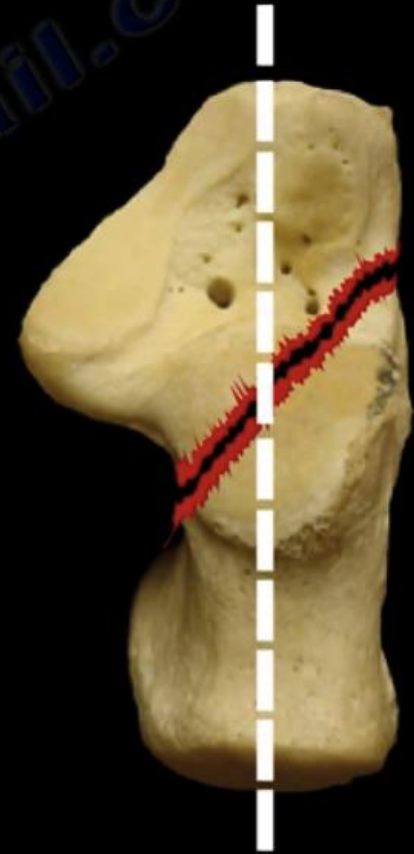Heel in Varus with
height shortening
and widening

Primary fracture line splits the calcaneus obliquely through the posterior facet and exits anterolaterally and posteromedially.

Joint Depression



Lateral View



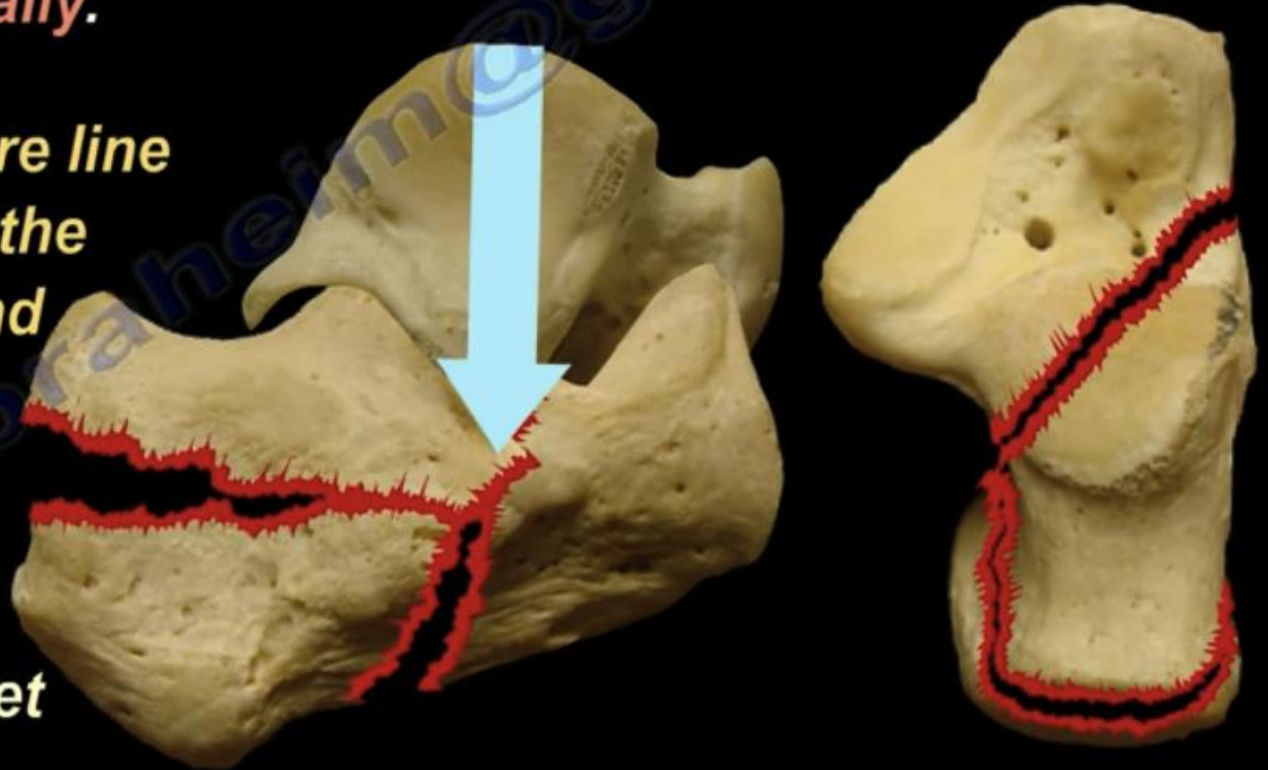
Superior View

Essex - Lopresti Tongue Type

Primary fracture line exits anterolaterally and posteromedially.

Secondary fracture line appears beneath the posterior facet and exits posteriorly through the tuberosity.

The posterior facet is attached to the

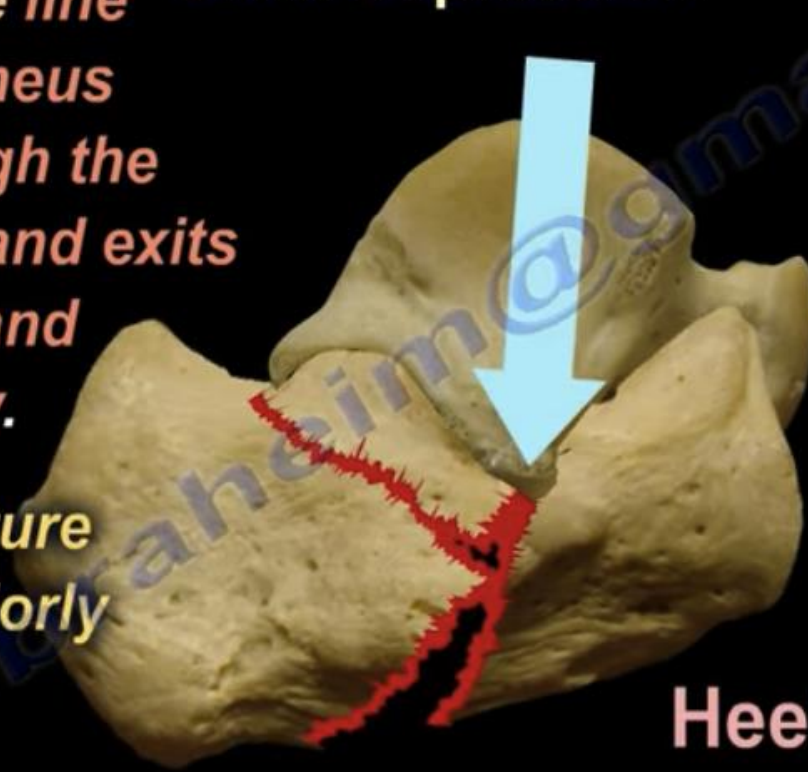


Primary fracture line splits the calcaneus obliquely through the posterior facet and exits anterolaterally and posteromedially.

Secondary fracture line exits superiorly just behind the posterior facet.

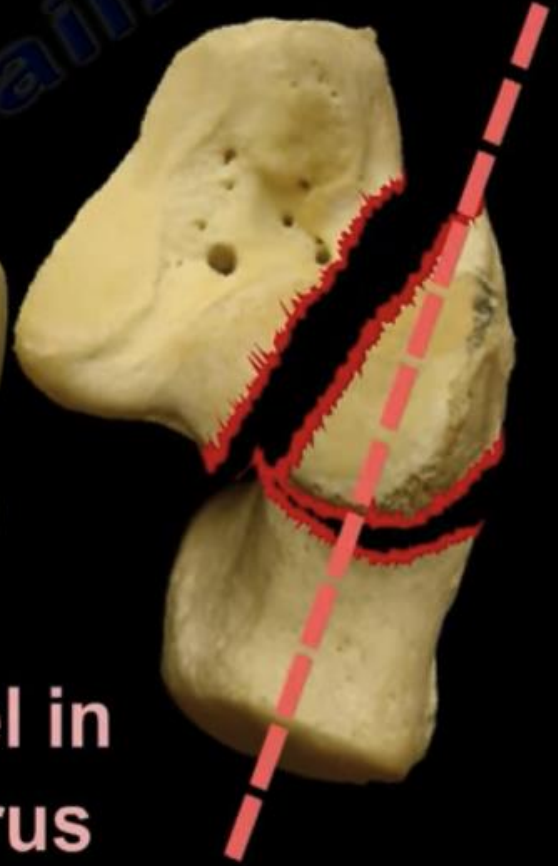The posterior facet is a free

Joint Depression



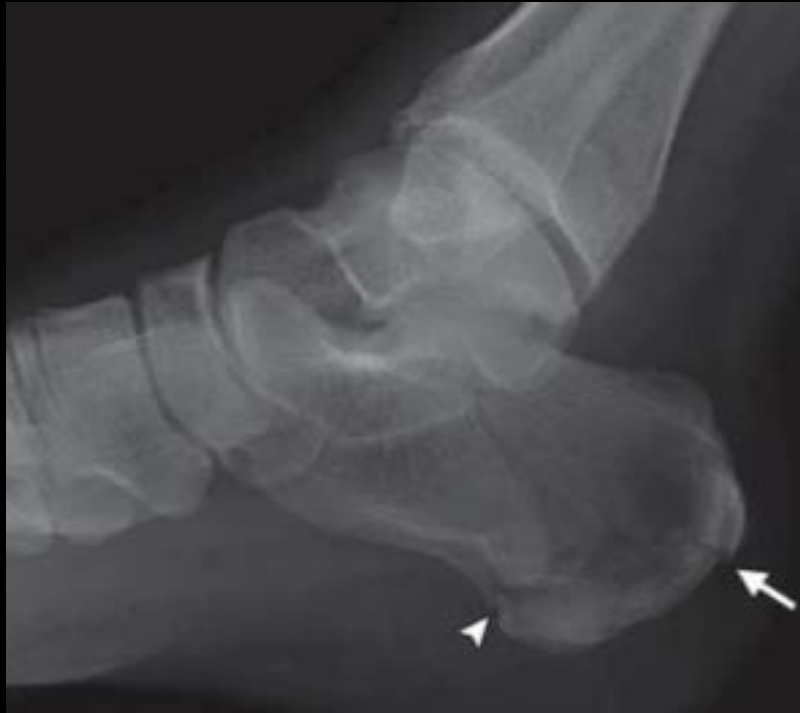Lateral View

Heel in Varus

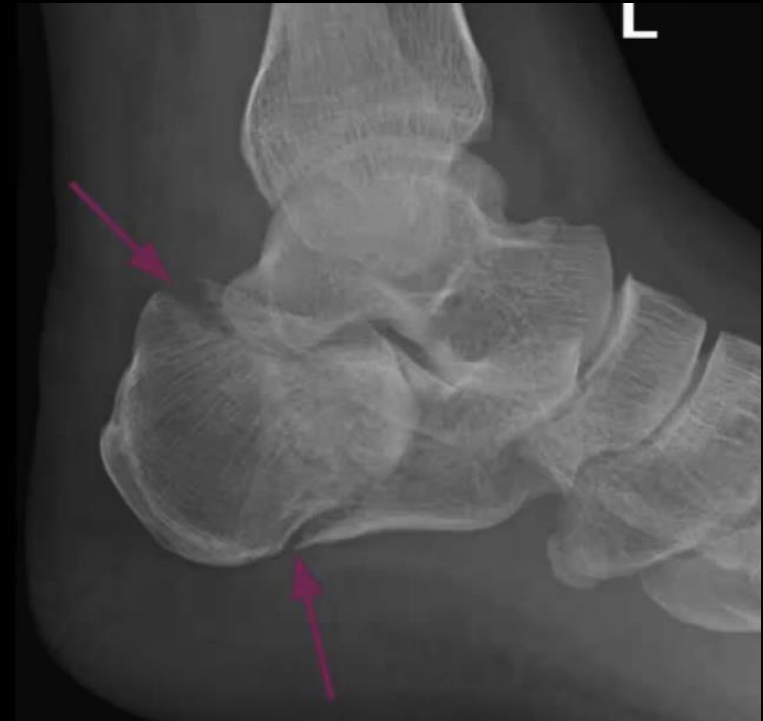

Superior View

Essex-Lopresti classification system

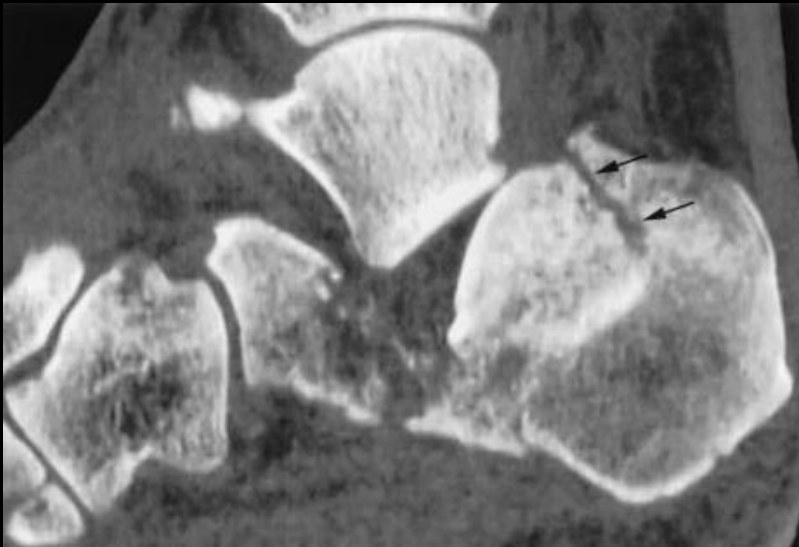


tongue type fracture

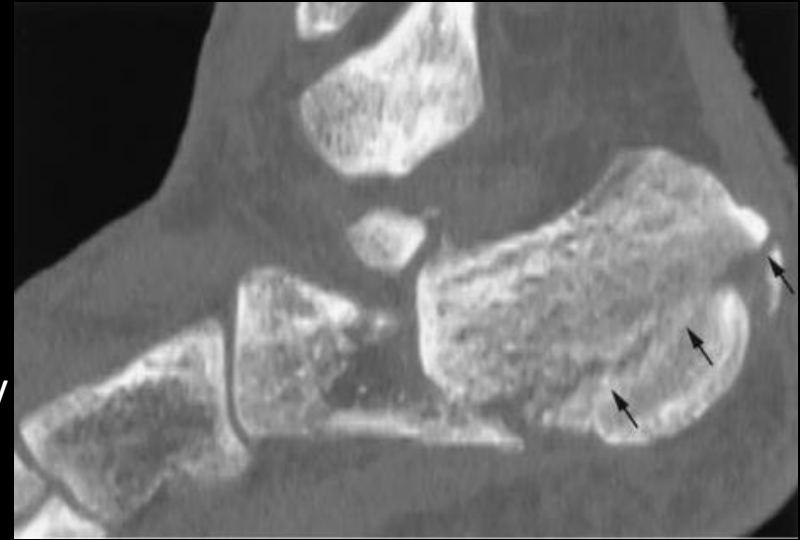


depression type fracture

Essex-Lopresti classification system



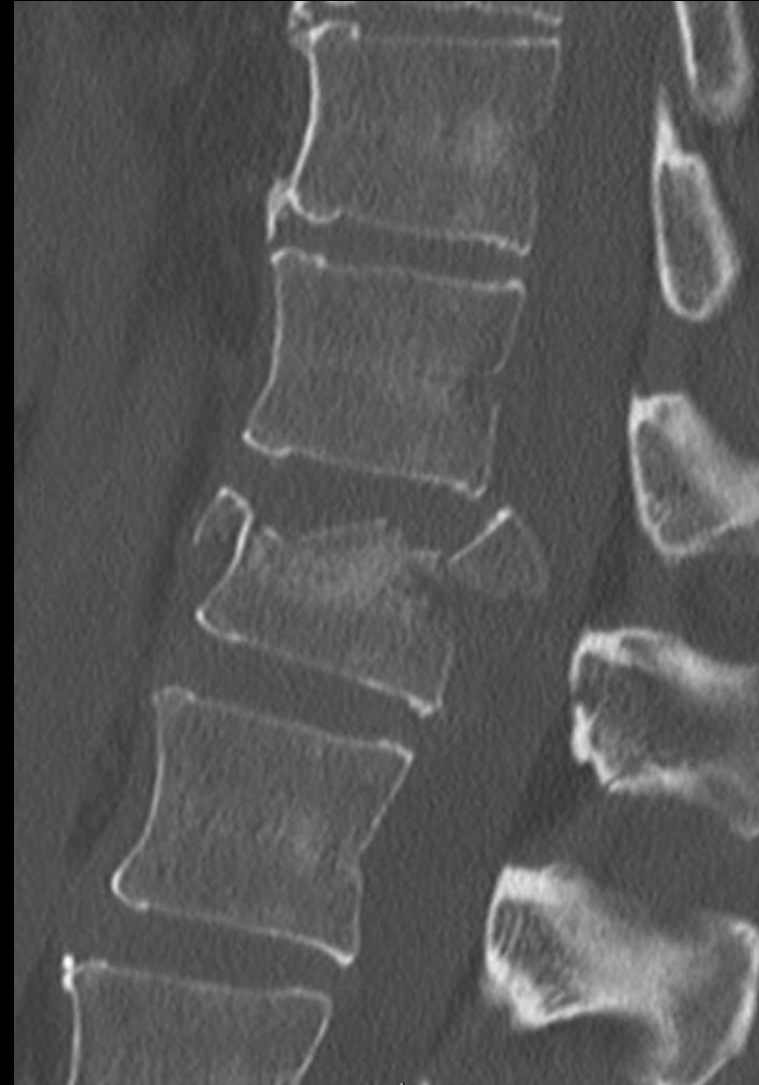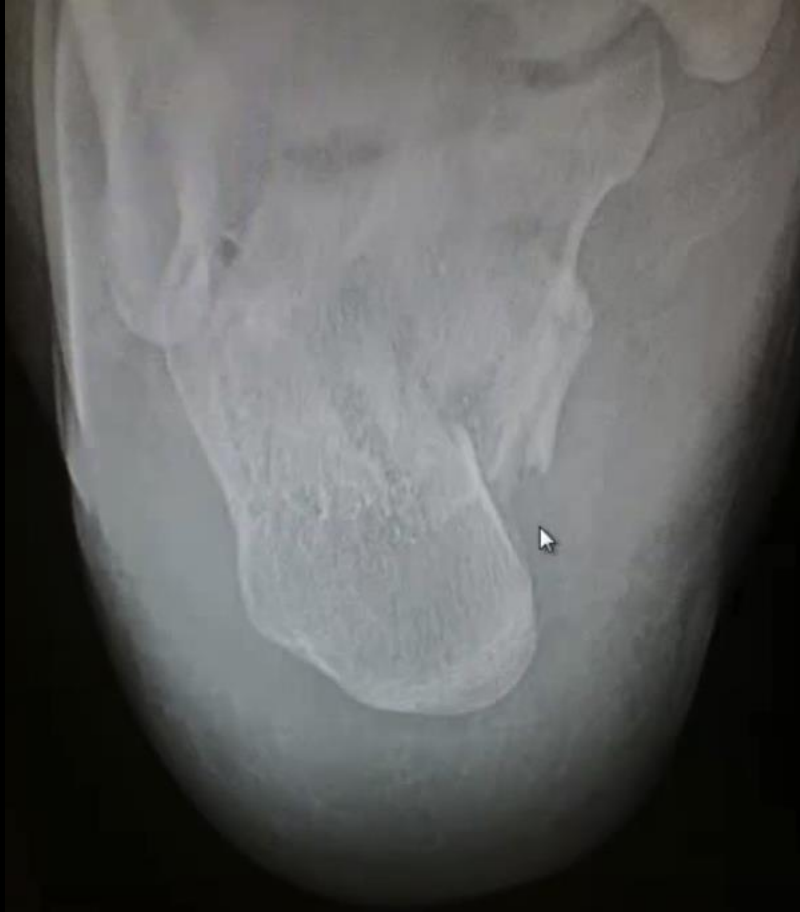depression type fracture



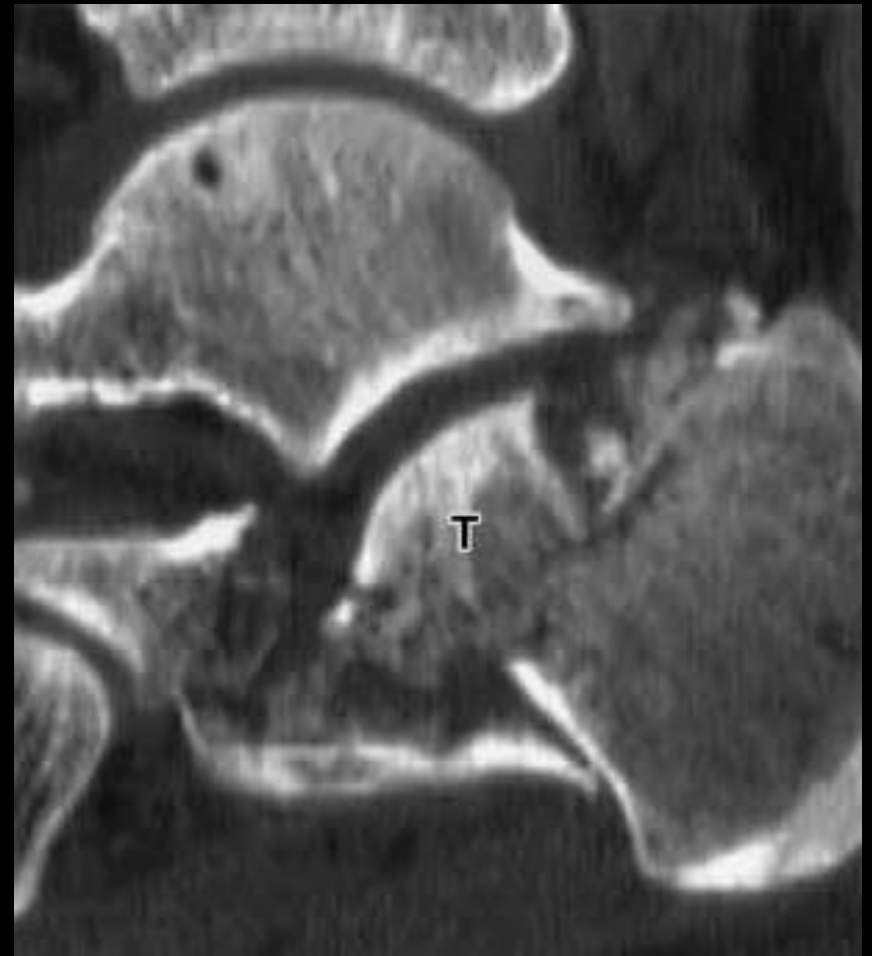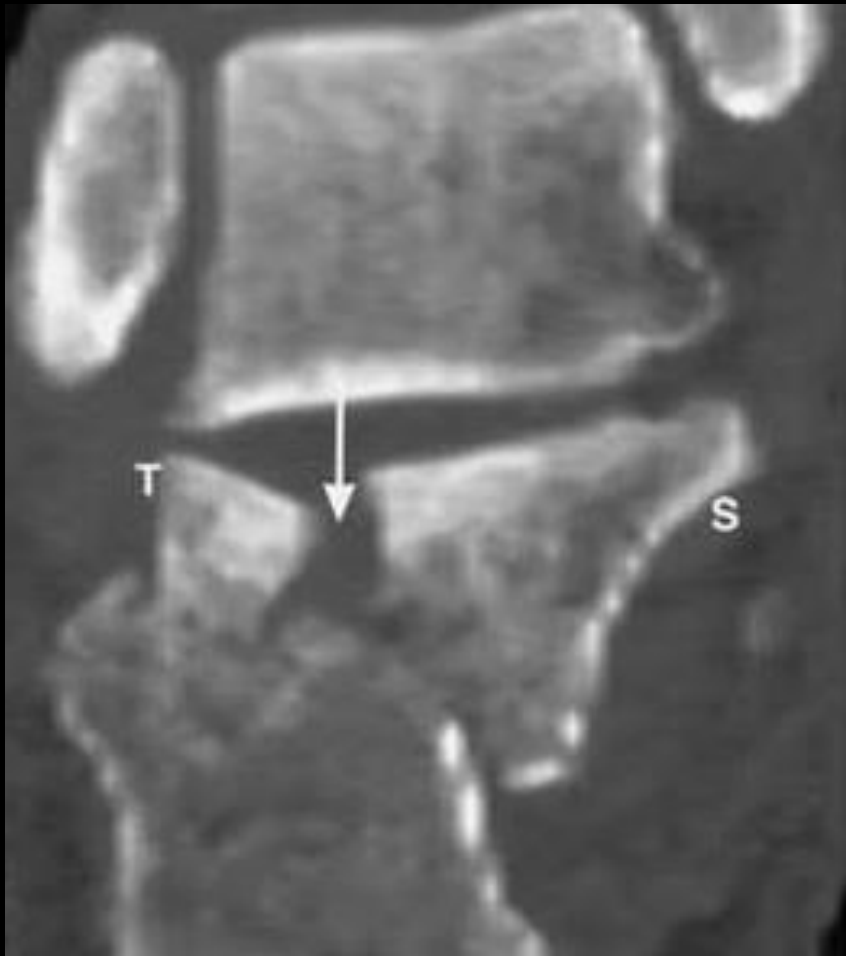tongue type fracture

y

Burst fracture of the L1 vertebral body

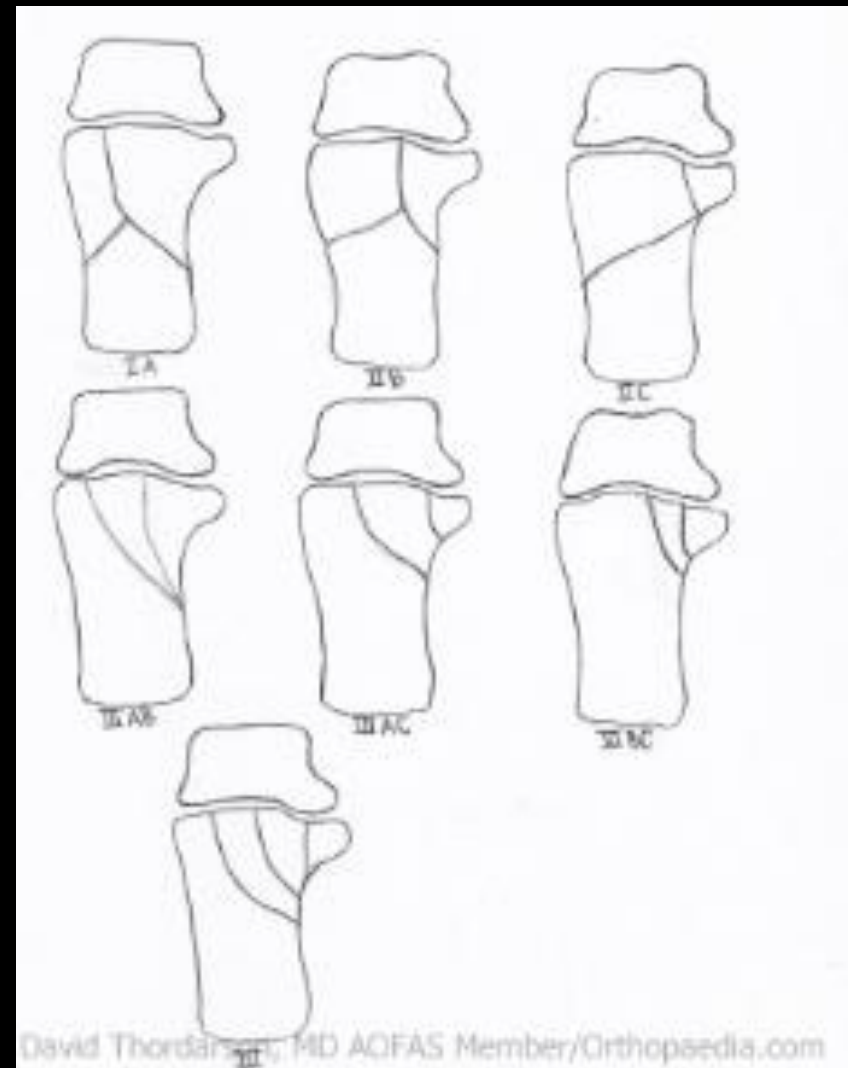


Sagittal shear fracture



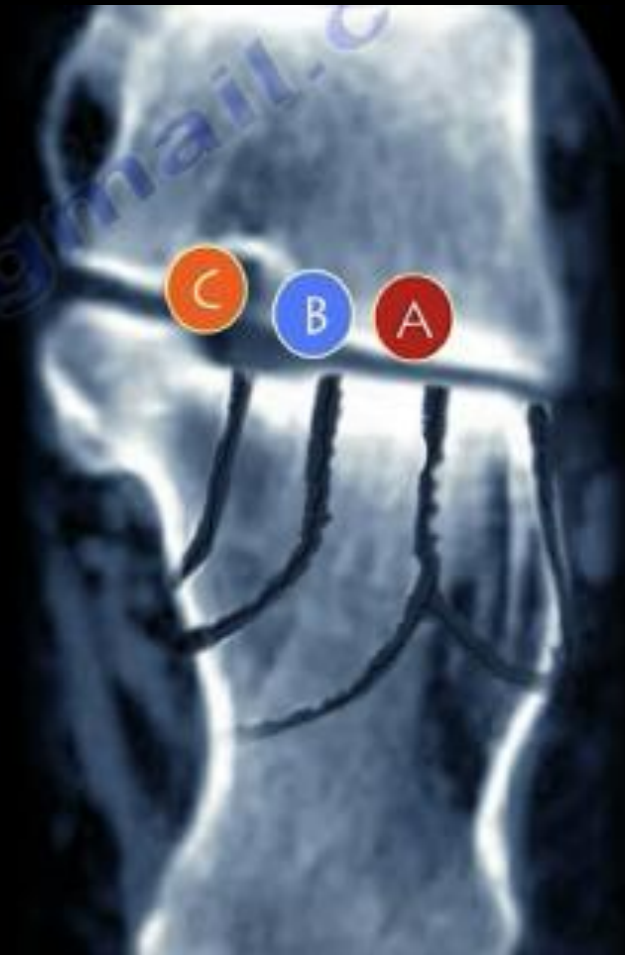Sander's Classification

- Type I - Non-displaced (<2mm)
- Type II - Two articular fragments
- Type III - Three articular fragments
- Type IV - More than three articular fragments



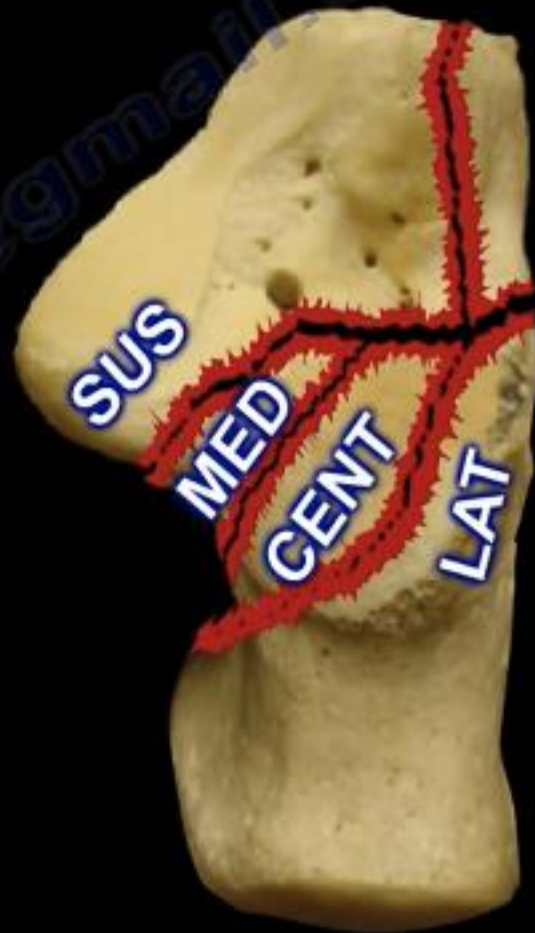Sander's Classification

- three primary fracture lines (A, B, C) through the posterior facet divide the calcaneus into four fragments (lateral, central, medial and sustentacular).



Sanders Classification

- three primary fracture lines (A, B, C) through the posterior facet divide the calcaneus into four fragments (lateral, central, medial and sustentacular).

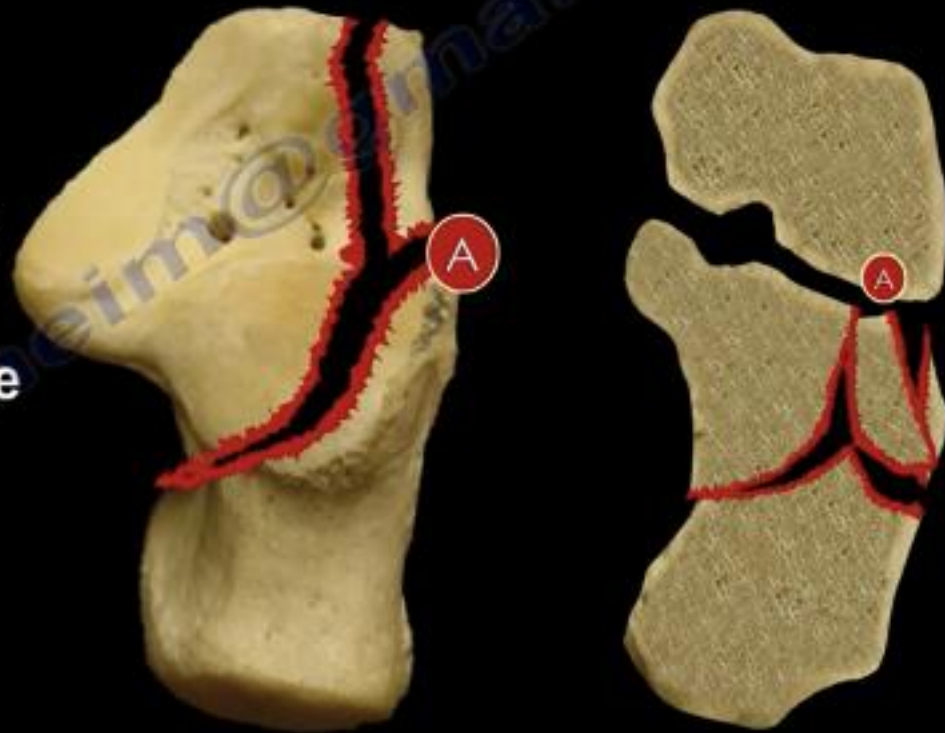

Sanders Classification

A PRIMARY FRACTURE LINE A

Type IIA

Two-part fracture of the posterior facet, with primary fracture line A is lateral.

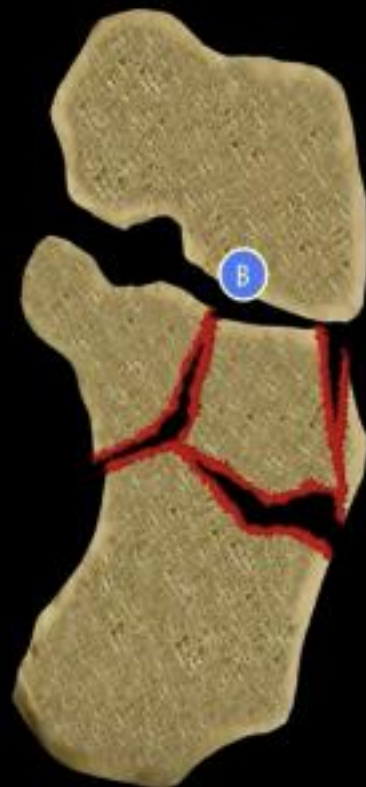
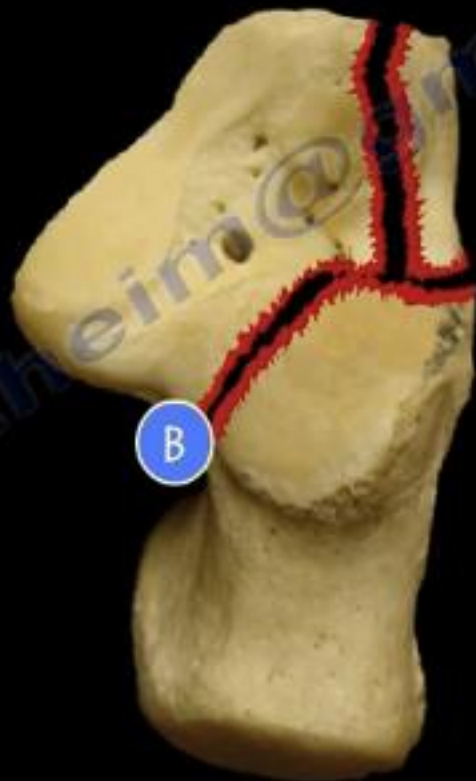

Sanders Classification

B PRIMARY FRACTURE LINE B

Type IIB

Two-part fracture of the posterior facet, with primary fracture line B is central.

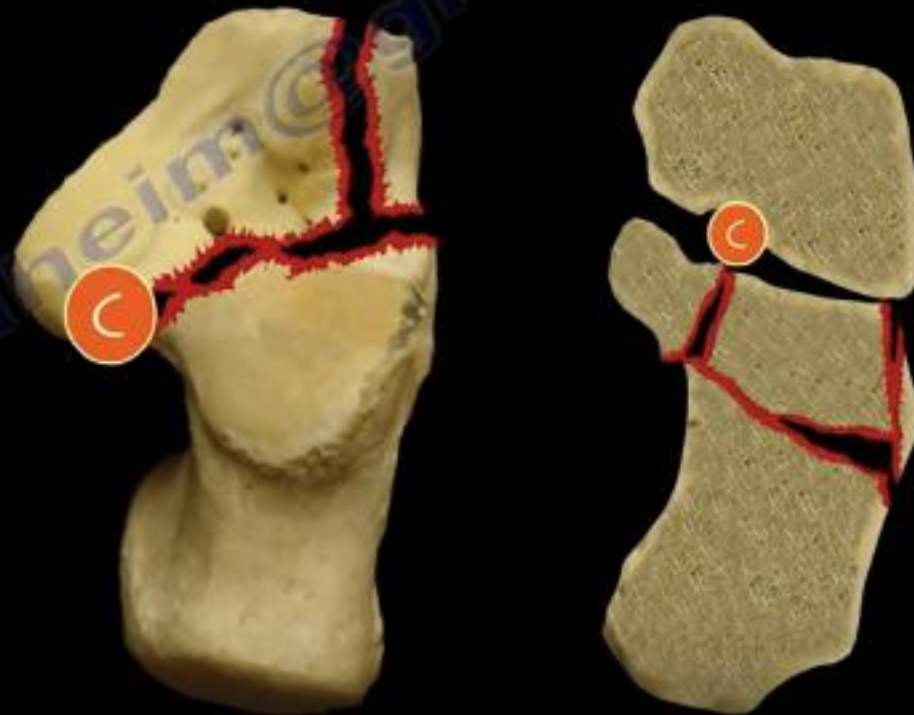

Sanders Classification

PRIMARY FRACTURE LINE C

Type IIC

Two-part fracture of the posterior facet, with primary fracture line C is medial.



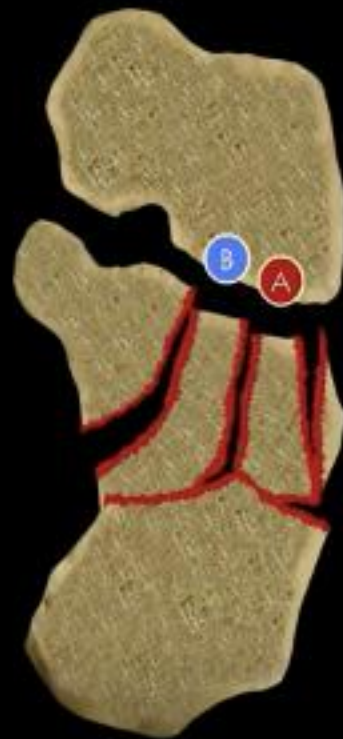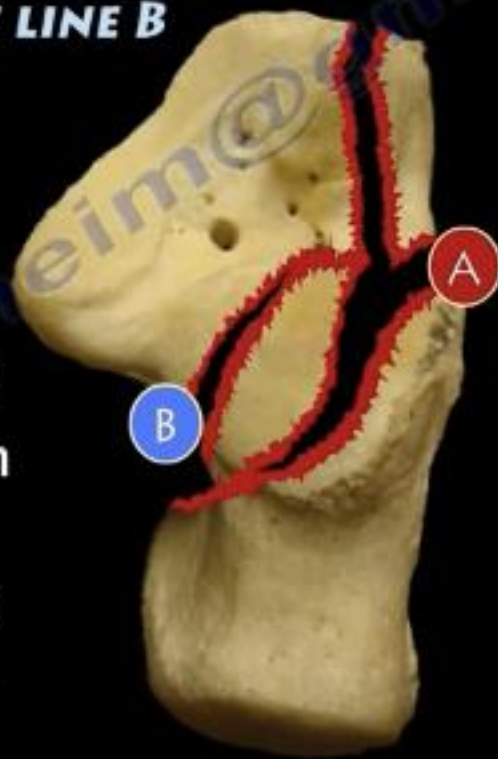
Sanders Classification

A PRIMARY FRACTURE LINE A

B PRIMARY FRACTURE LINE B

Type III AB

Three - part fracture of the posterior facet with a centrally depressed fragment, with primary fracture lines A and B.

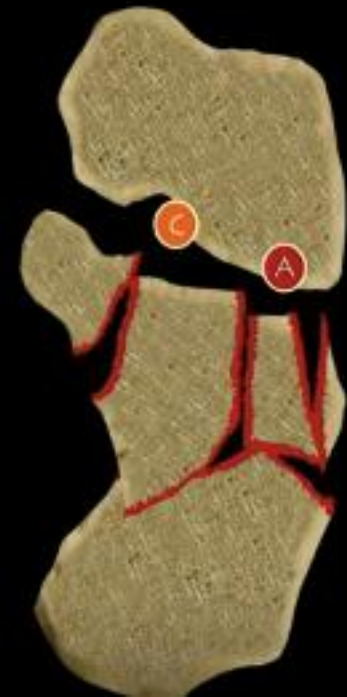
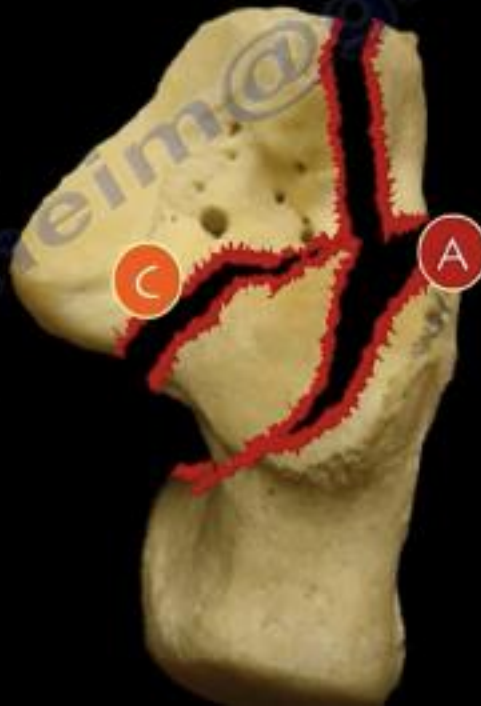
A PRIMARY FRACTURE LINE A

C PRIMARY FRACTURE LINE C

Type III AC

Three - part fracture of the posterior facet with a centrally depressed fragment, with primary fracture lines A and C.



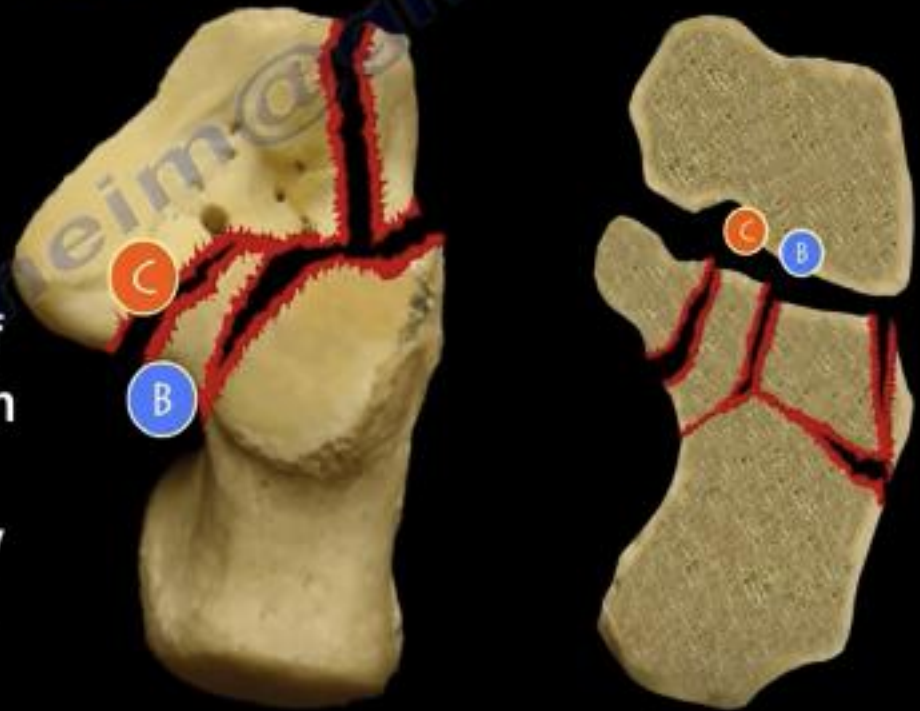
Sanders Classification

B PRIMARY FRACTURE LINE B

C PRIMARY FRACTURE LINE C

Type III BC

Three - part fracture of the posterior facet with a centrally depressed fragment, with primary fracture lines B and C.



Sanders Classification

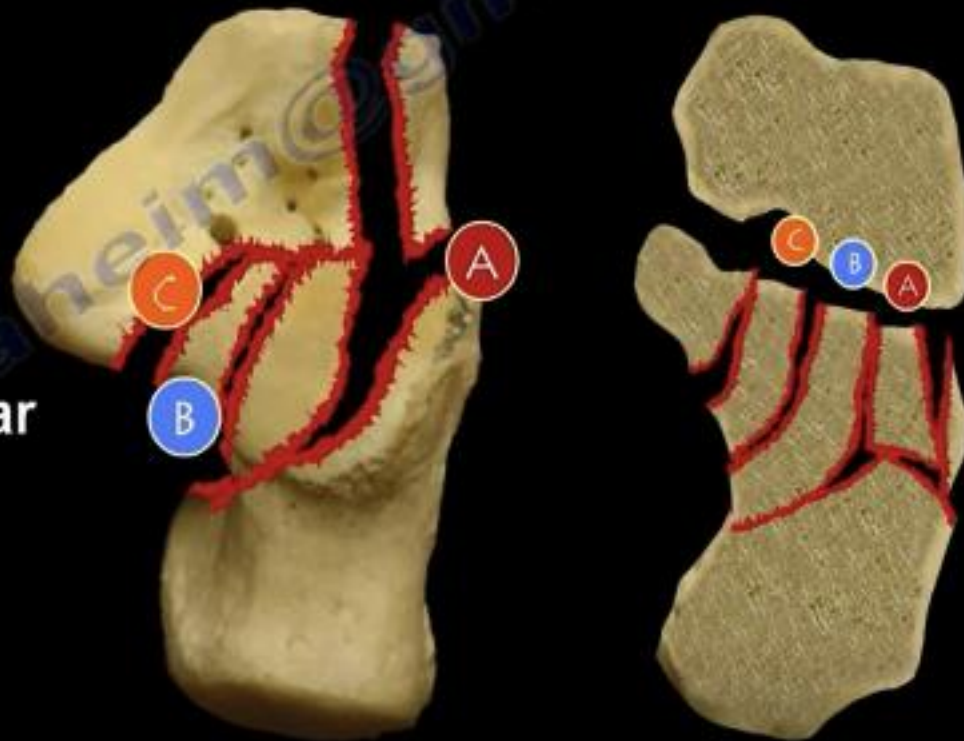
A PRIMARY FRACTURE LINE A

C PRIMARY FRACTURE LINE C

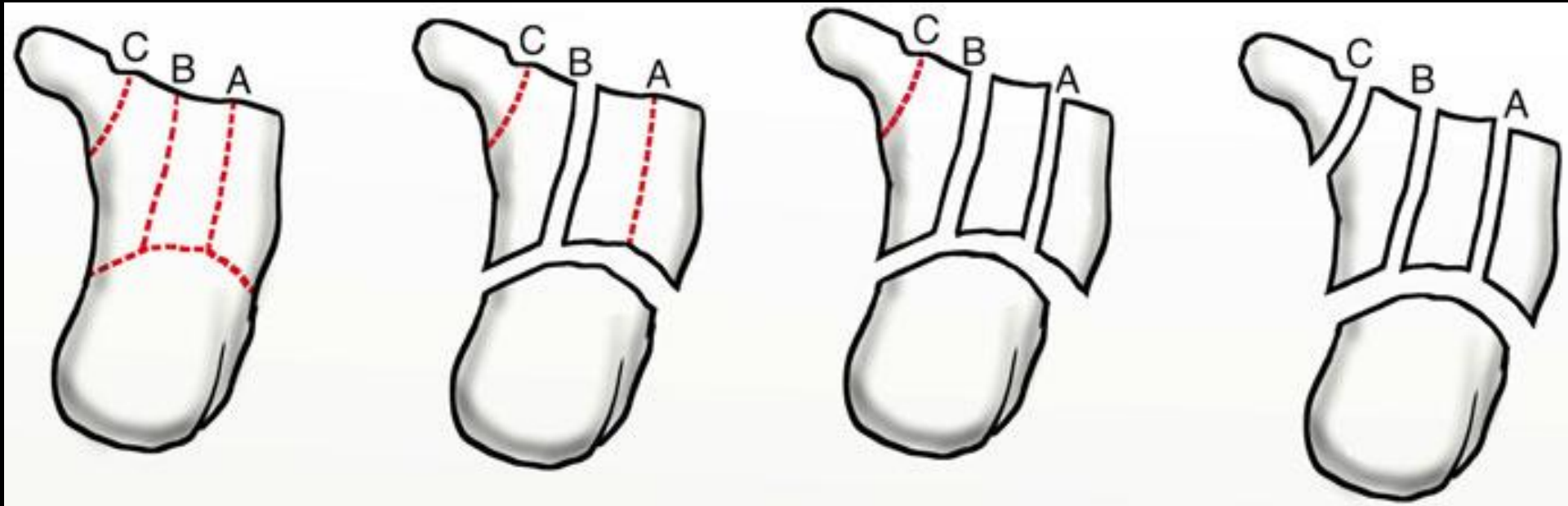
B PRIMARY FRACTURE LINE B

Type IV

Four - part articular fractures; highly comminuted.



Calcaneus Fractures



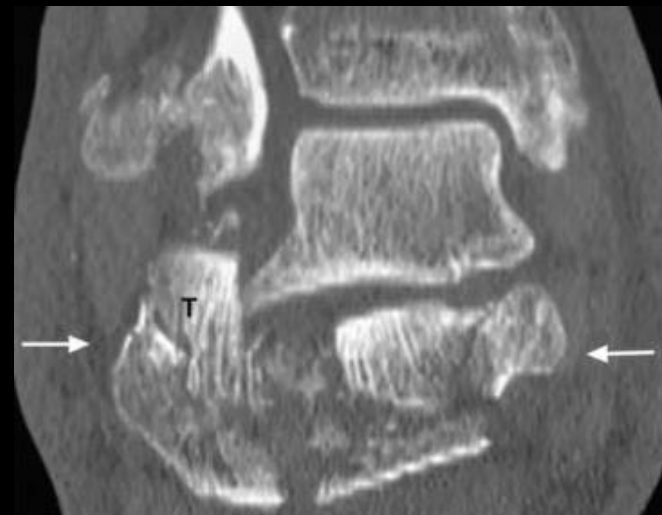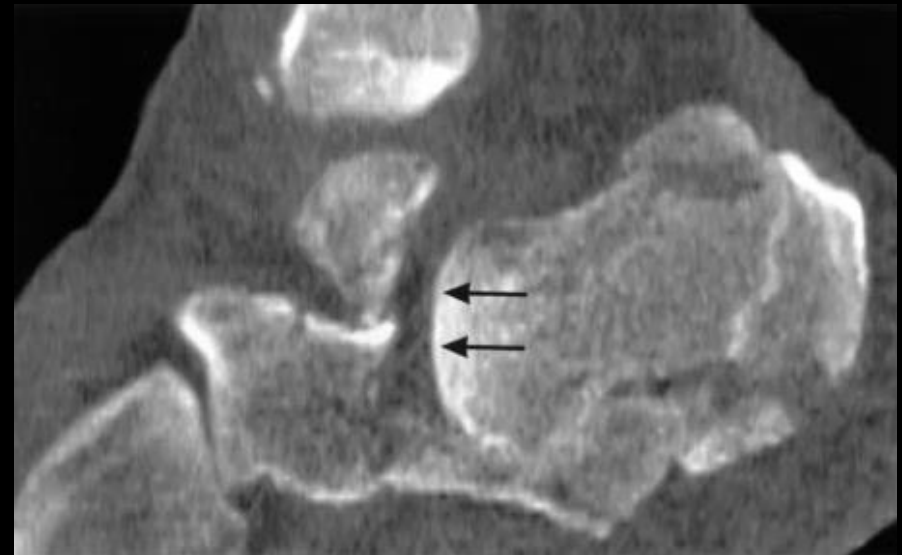
The higher the fracture number, the worse the result.

Sanders et al

- Type I fracture were treated without surgery
- Type II and type III fractures who underwent surgery experienced excellent or good clinical results in 73% and 70% of cases, respectively
- Only 9% of patients with type IV fractures had excellent or good clinical results after surgical treatment.
- Sanders et al have shown that although anatomic reduction is necessary for a good clinical outcome
- Success is not guaranteed, possibly related to cartilage necrosis at the time of injury.

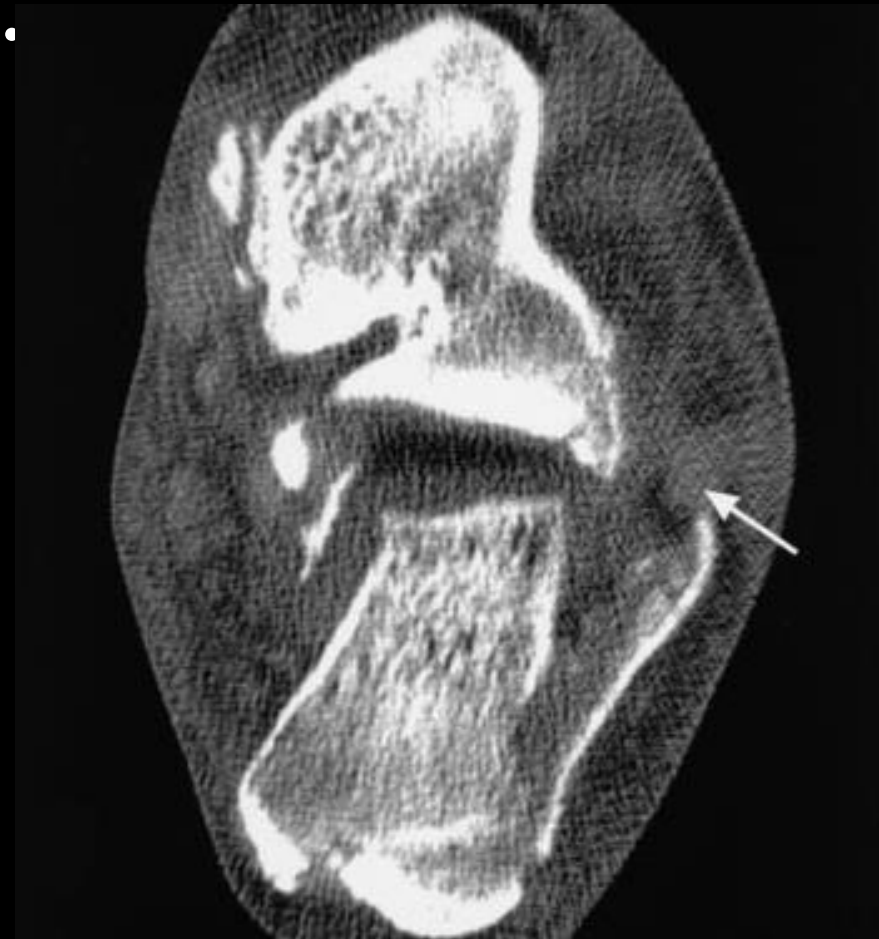Typical Features

- (a) Loss of height due to impaction and rotation of the tuberosity fragment,
- (b) increase in width due to lateral displacement of the tuberosity fragment, and
- (c) disruption of the posterior facet of the subtalar joint



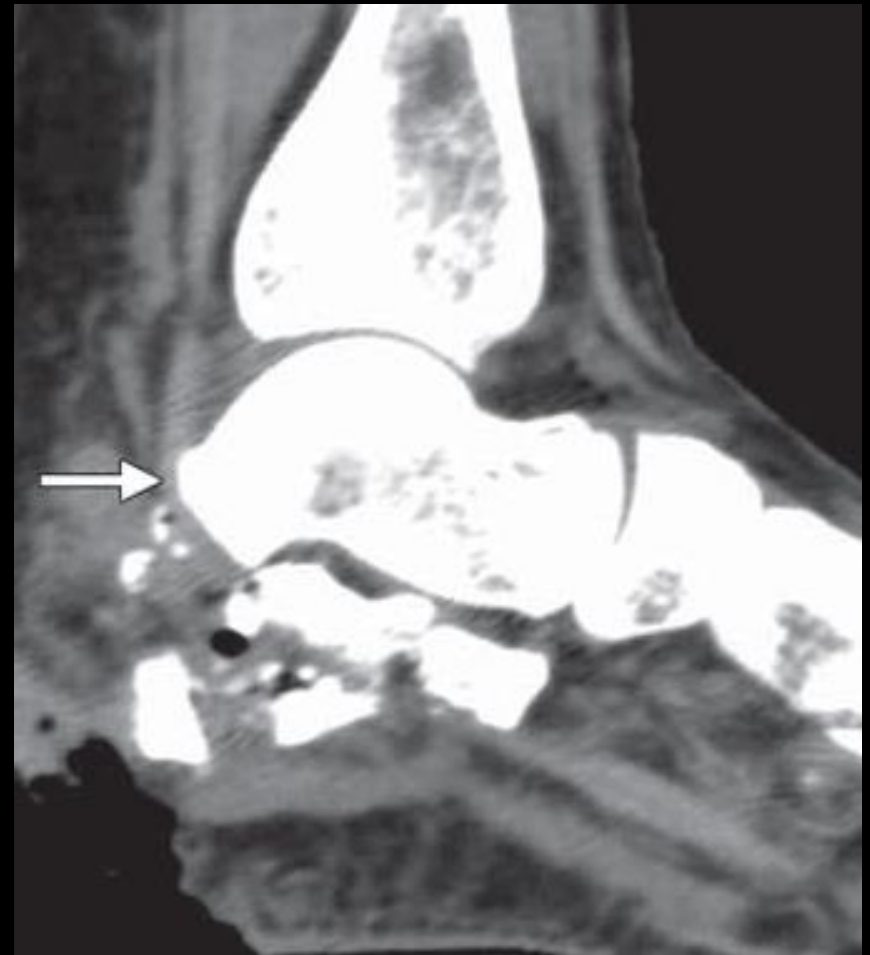Complications

- **Extraosseous abnormalities**
- **Tendons injured** by sharp fracture fragments or entrapped between them.
- **Tendon entrapment** can be an impediment to reduction
- Medially, there are greater stretching forces, which result in **fracture blister formation**
- **Compartment syndromes** can occur and may be unrecognized
- Axial load mechanism, calcaneal fractures can be associated with **burst fractures of the spine**



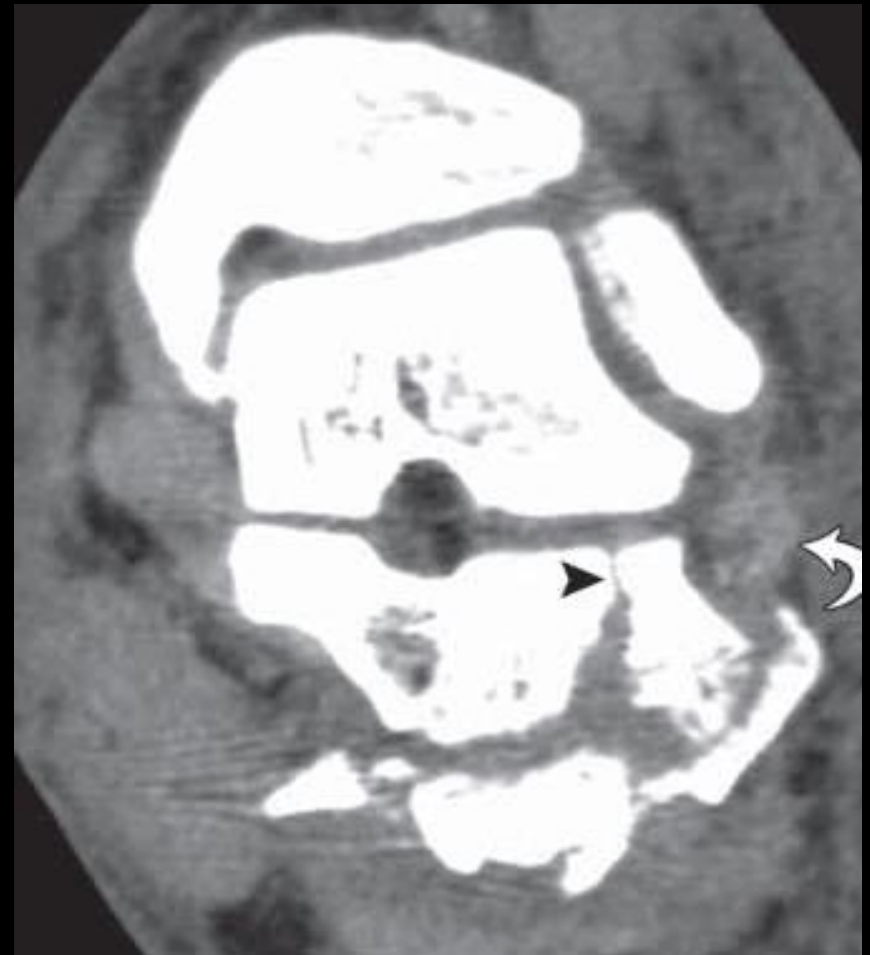FHL tendon entrapment

- **Tendon injury:** may result from the entrapment of fibers between fracture fragments
- **FHL tendon entrapment** along its course through a severely comminuted open calcaneal fracture

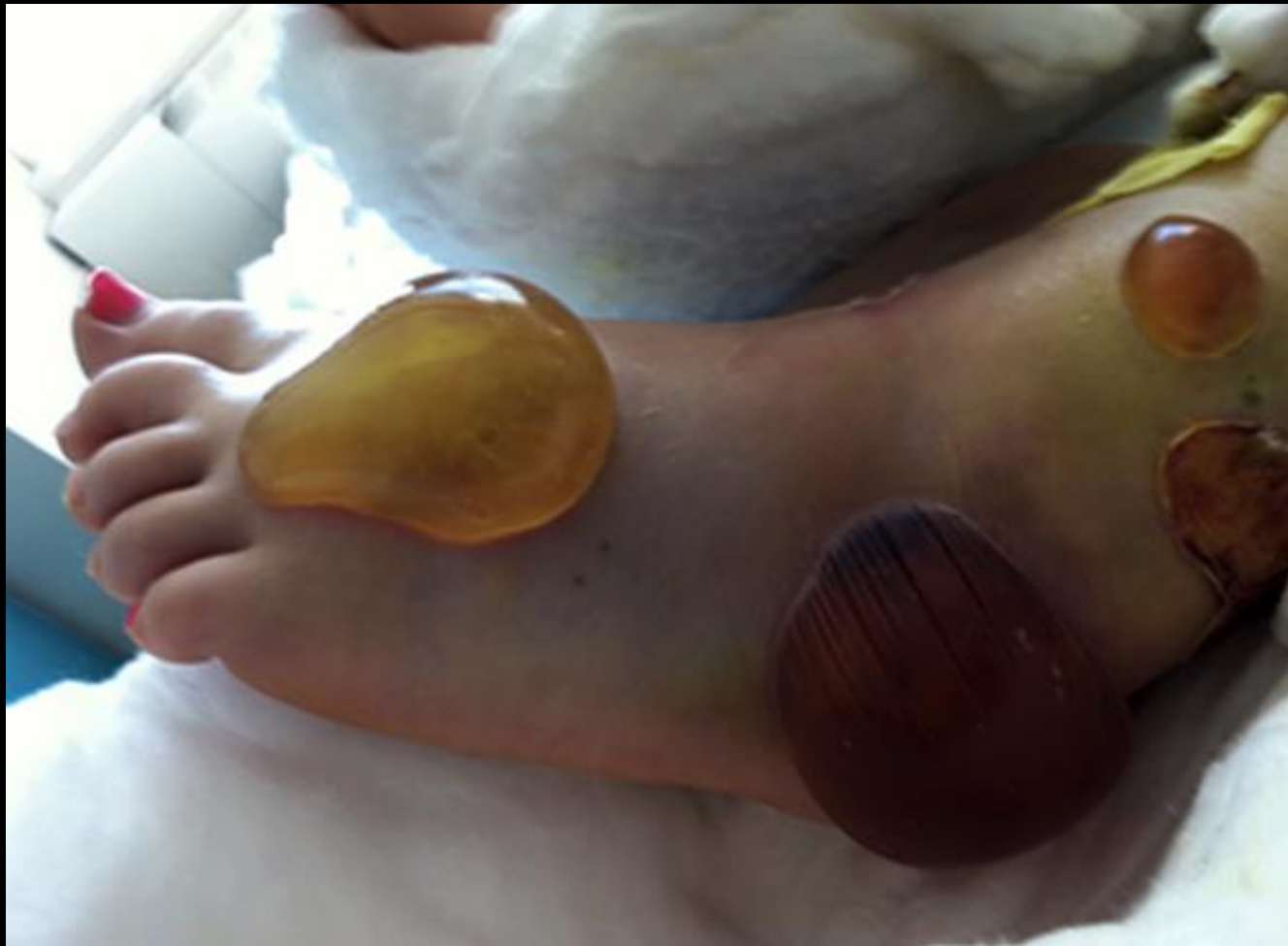

Peroneus longus tendon entrapment

- **Peroneus longus tendon entrapment** of the peroneus longus tendon caused by “blowout” of the lateral aspect of the calcaneus. A Sanders type IIA intraarticular calcaneal fracture is also noted.

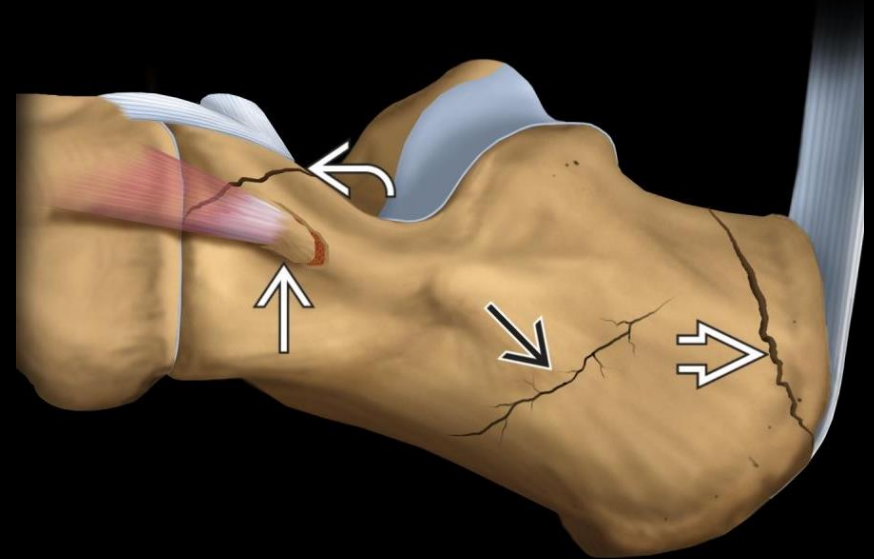


Fracture Blister

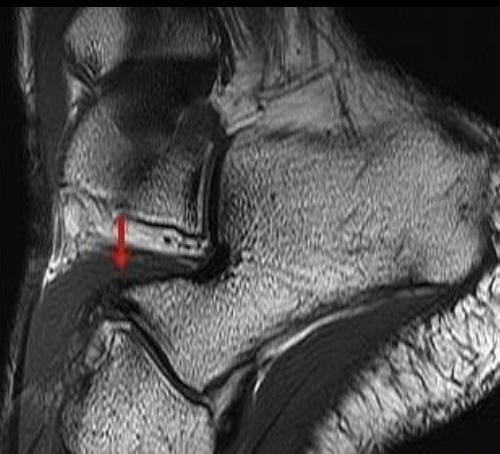
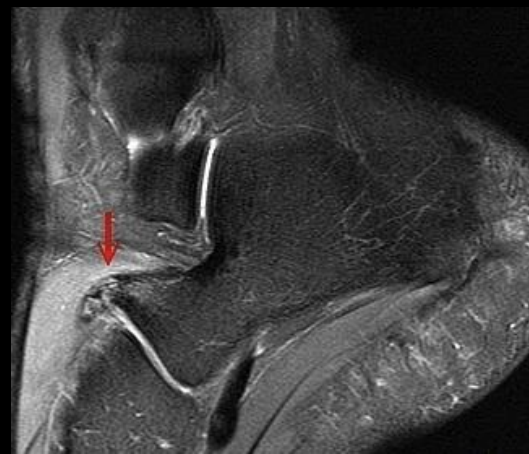
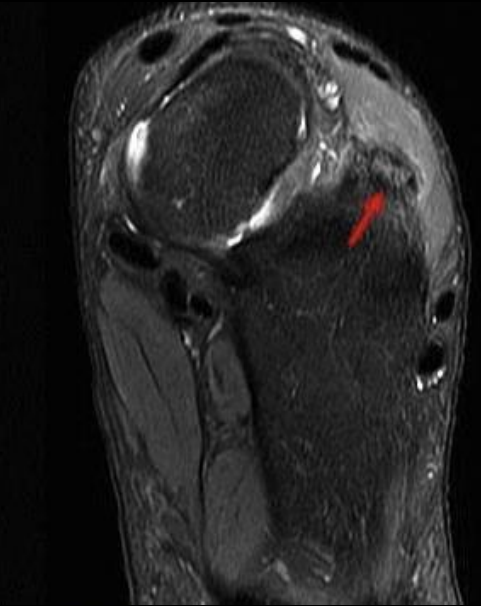
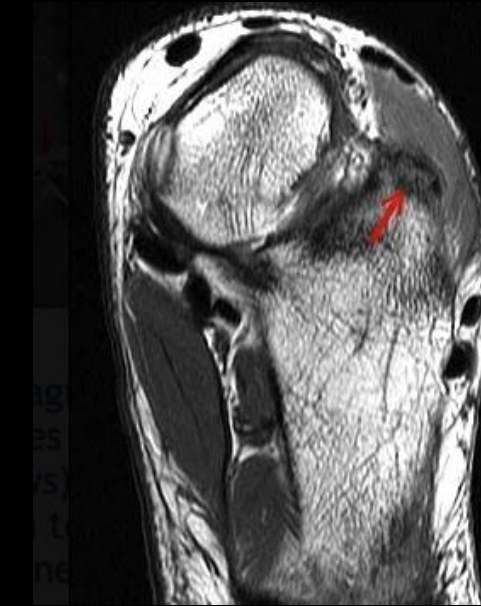
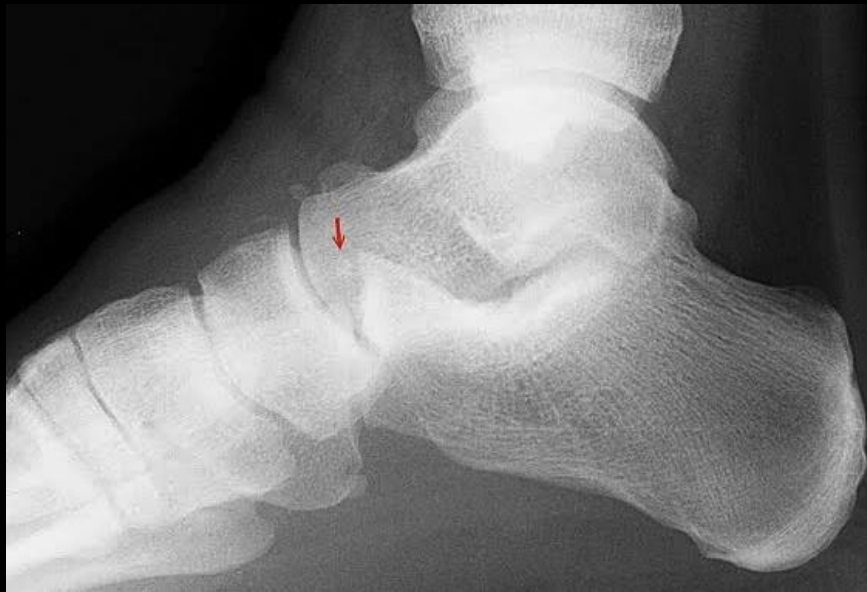

Extra-articular Fractures

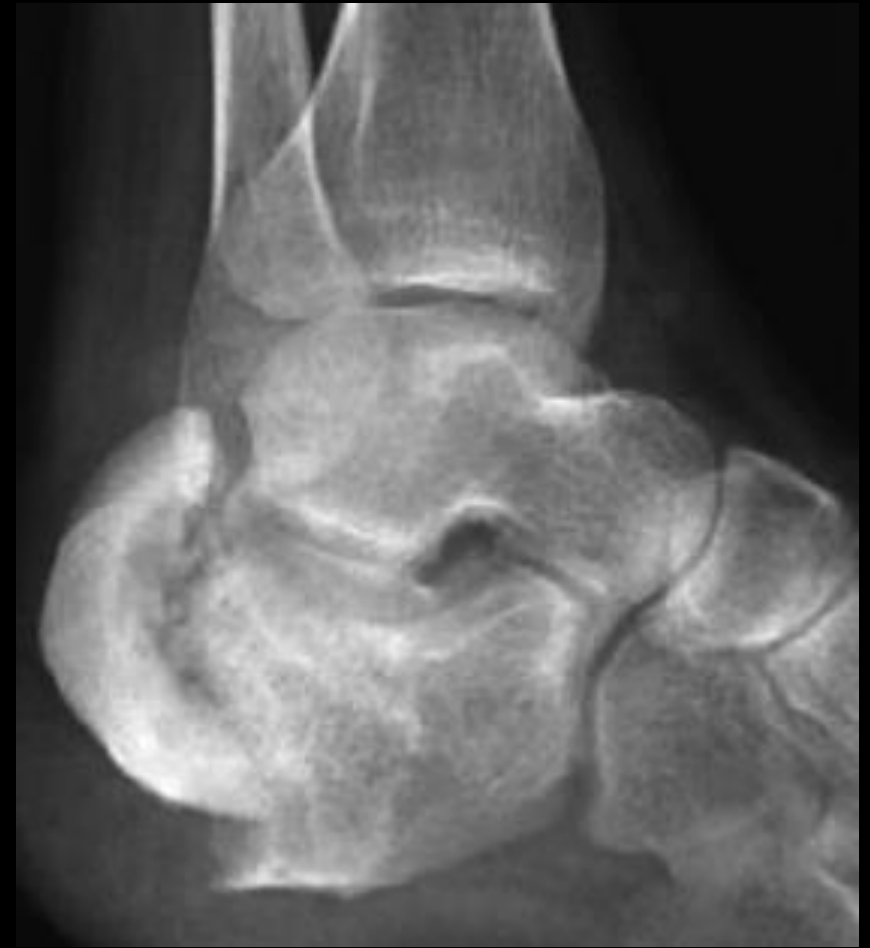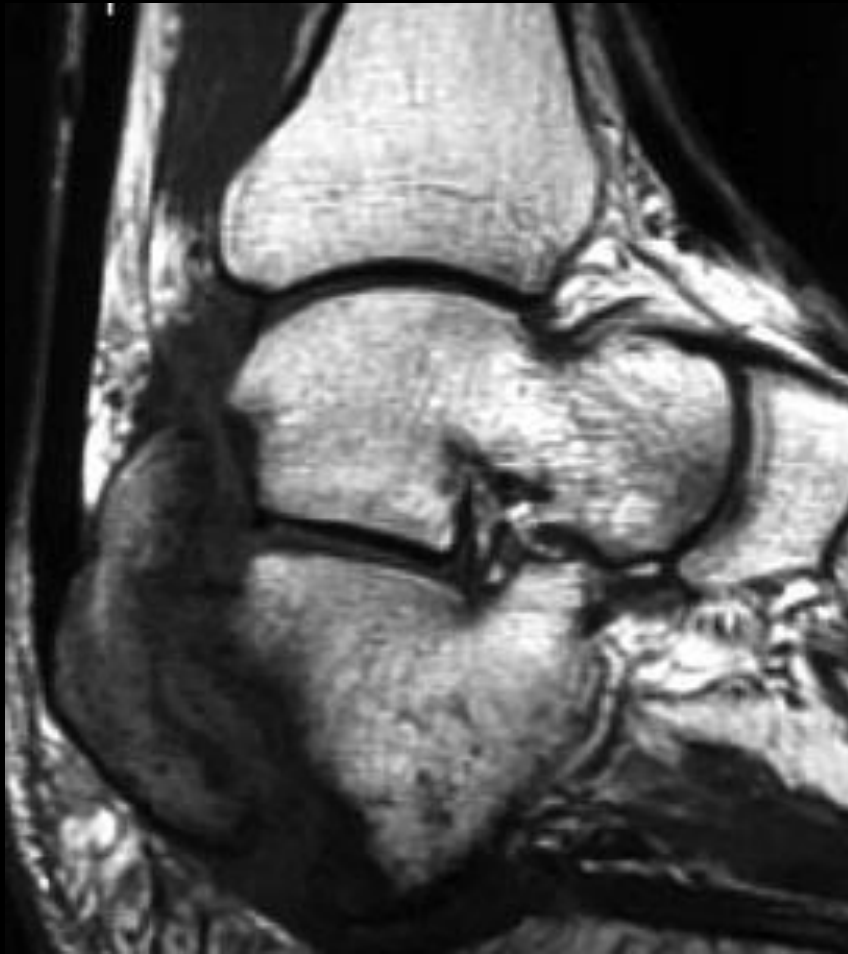
- Account for about 25% of calcaneal fractures
- All fractures that **do not involve the posterior facet of the subtalar joint**
- Displaced fractures involving more than 25% of the calcaneocuboid articular surface are usually treated with ORIF
- **Nonunion** is the most common complication



Extensor digitorum brevis Avulsion

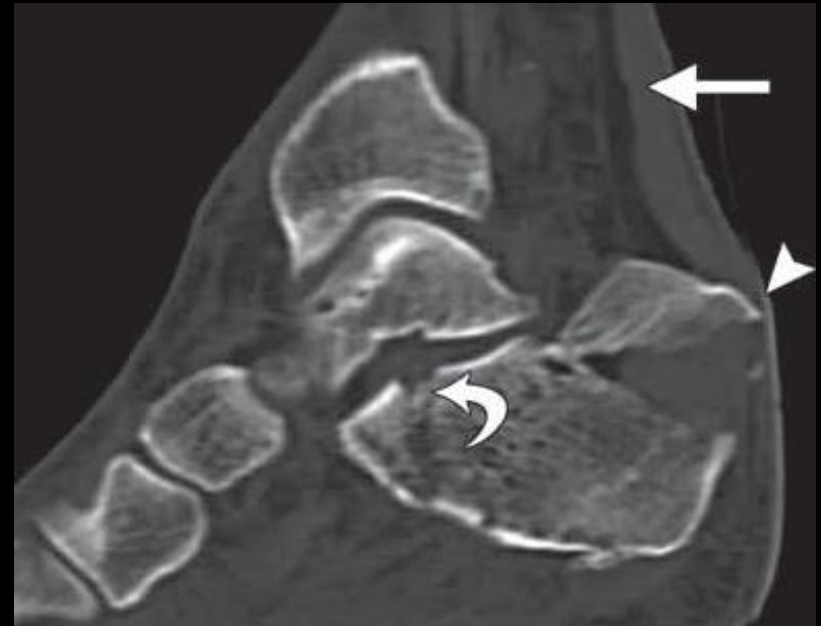


Achilles tendon avulsion type fracture



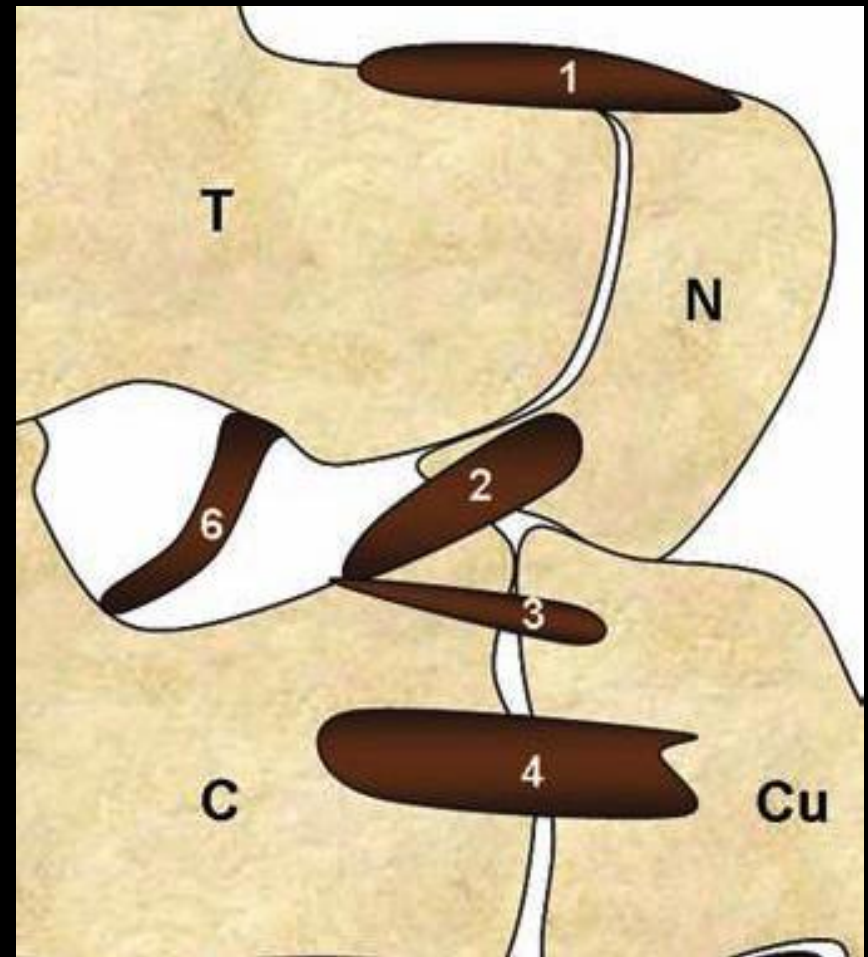
Achilles tendon avulsion type fracture

- **Achilles tendon:** avulsion type fracture of the calcaneal tuberosity posteriorly, there is a high risk of tissue necrosis and possible infection if management is delayed

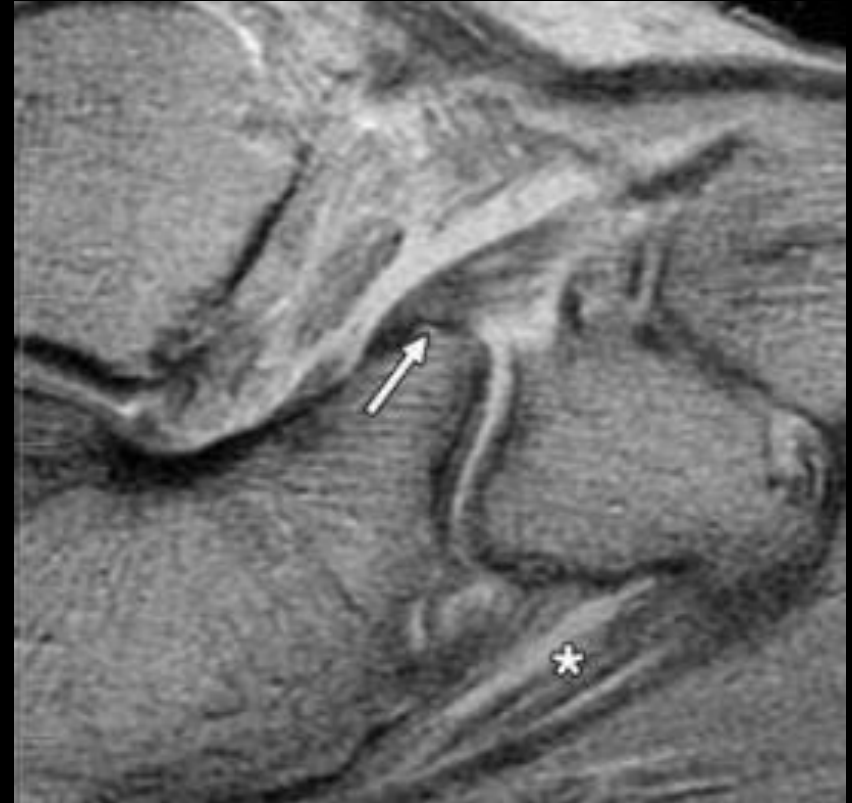
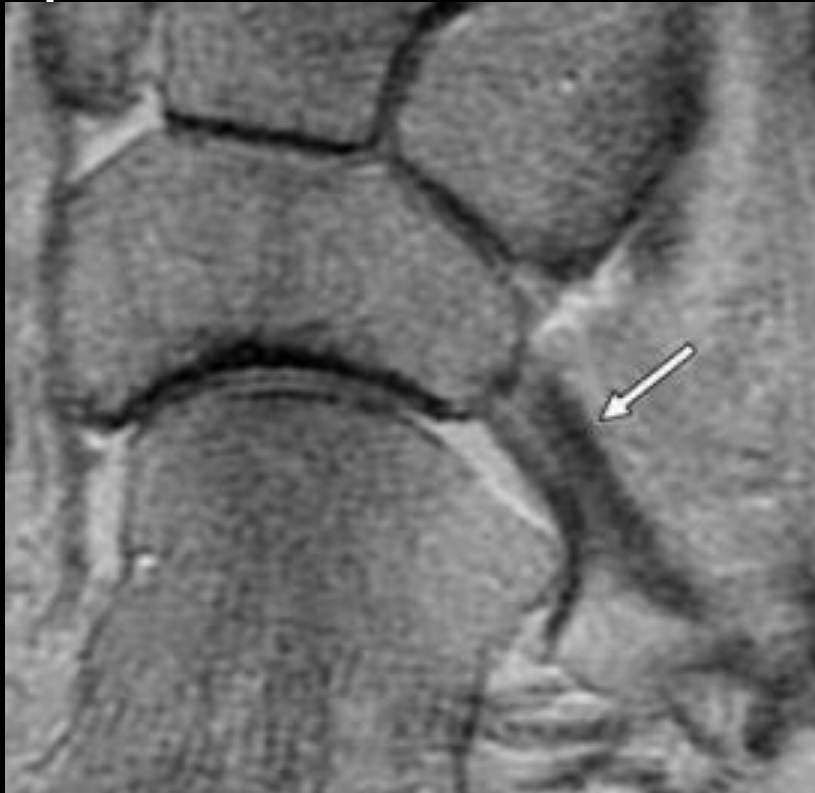

Bifurcate ligament

- The bifurcate ligament, also designated the “ligament of Chopart,” is formed by two ligaments: the medial calcaneocuboid ligament and lateral calcaneonavicular ligament



Bifurcate Ligament



Treatment (Conservative)

- Nonsurgical treatment is indicated for
- (a) **nondisplaced or minimally displaced** (Sanders type I) closed fractures;
- (b) **extraarticular fractures**; or
- (c) patients who have peripheral vascular disease, who smoke, or who have **other surgical contraindications**.
- Early range of motion without reduction or weight bearing

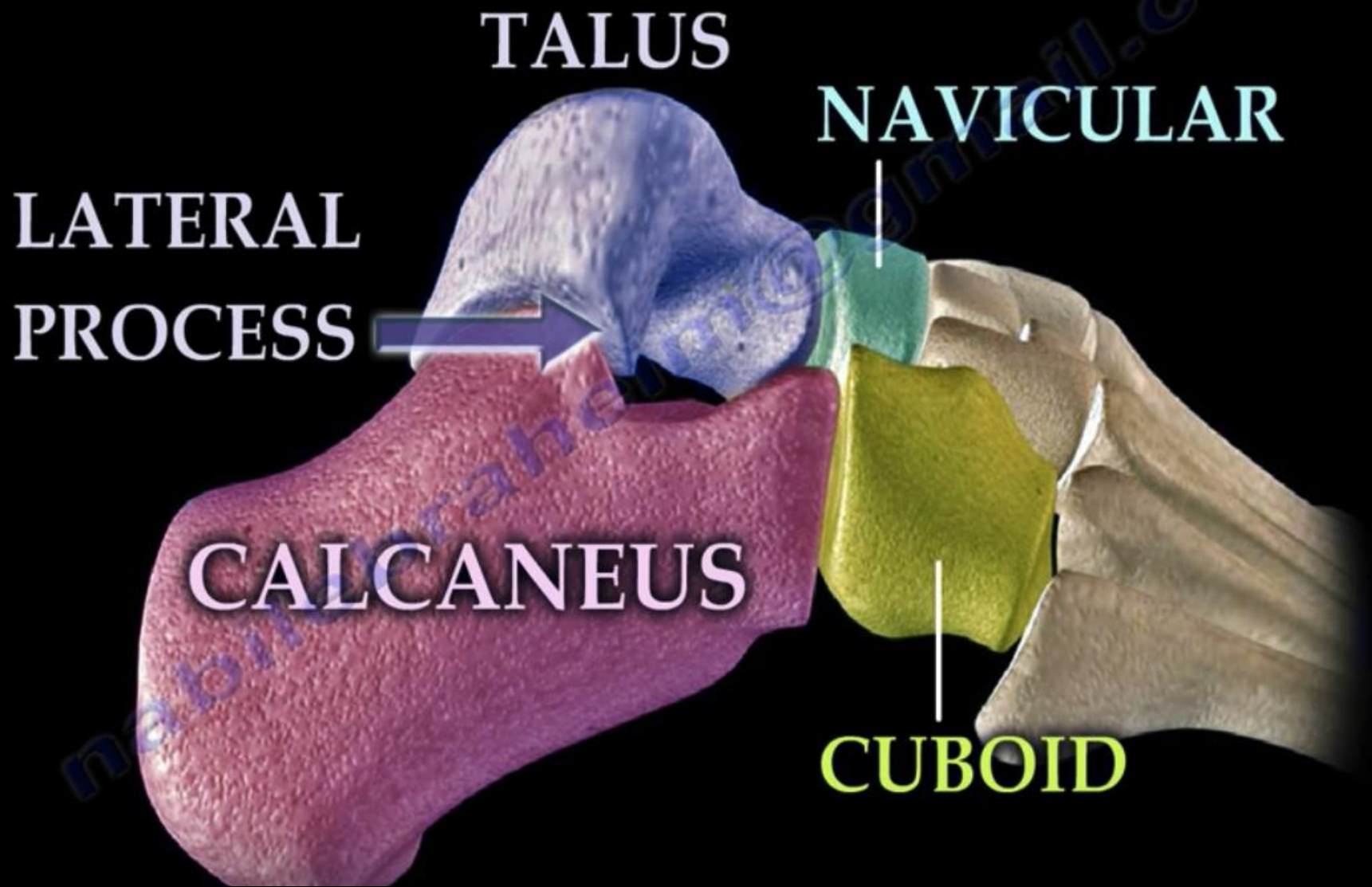
Treatment (surgical intervention)

- For displaced intraarticular (Sanders 2-4) and open fractures, surgical intervention is recommended within the first 3 weeks
- Before early consolidation of the fracture but not until swelling has decreased (skin wrinkles)
- Intervention consists of ORIF and arthrodesis if fracture is comminuted

You Tube Steph Curry George Hill



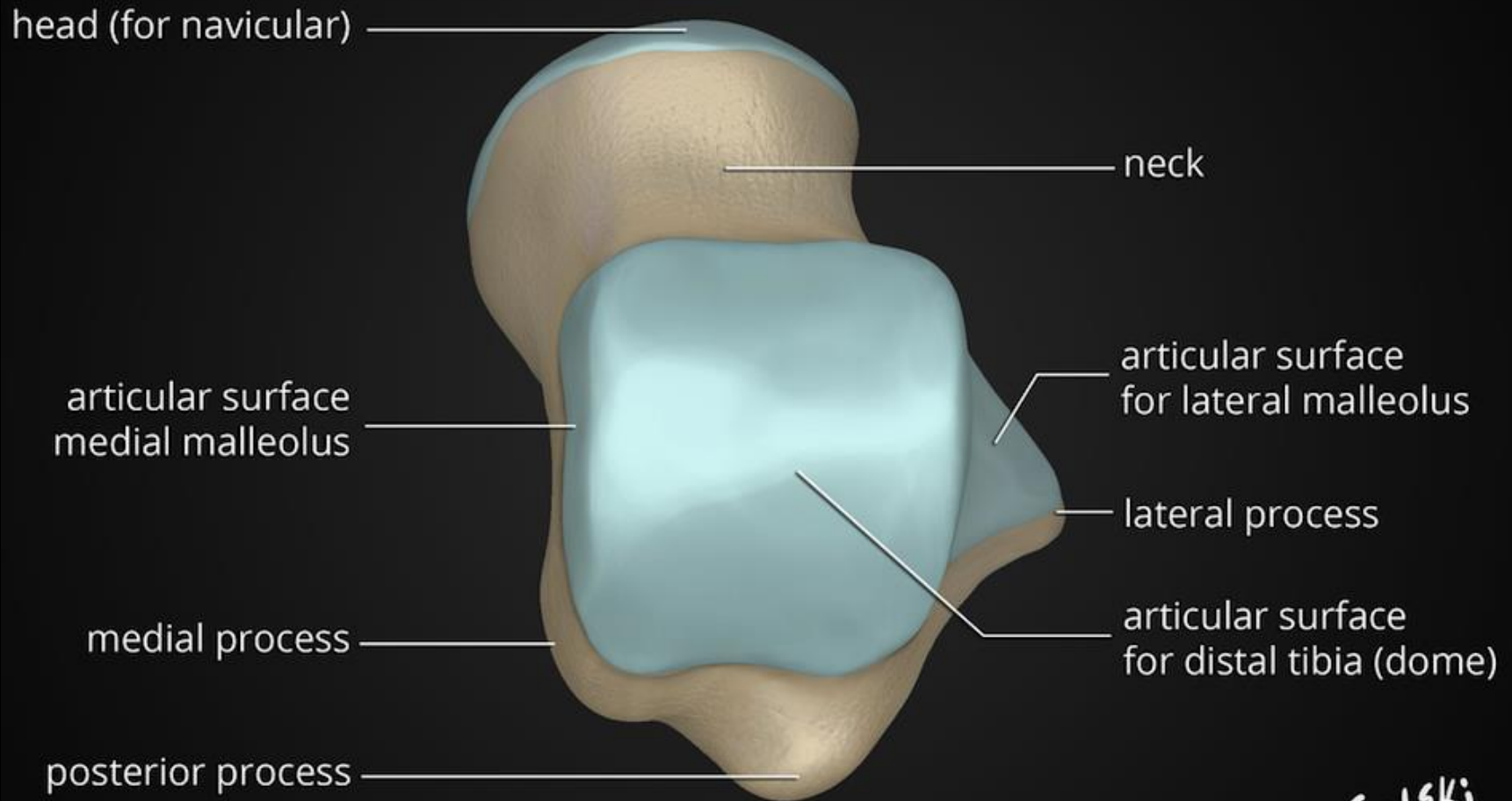
Talus



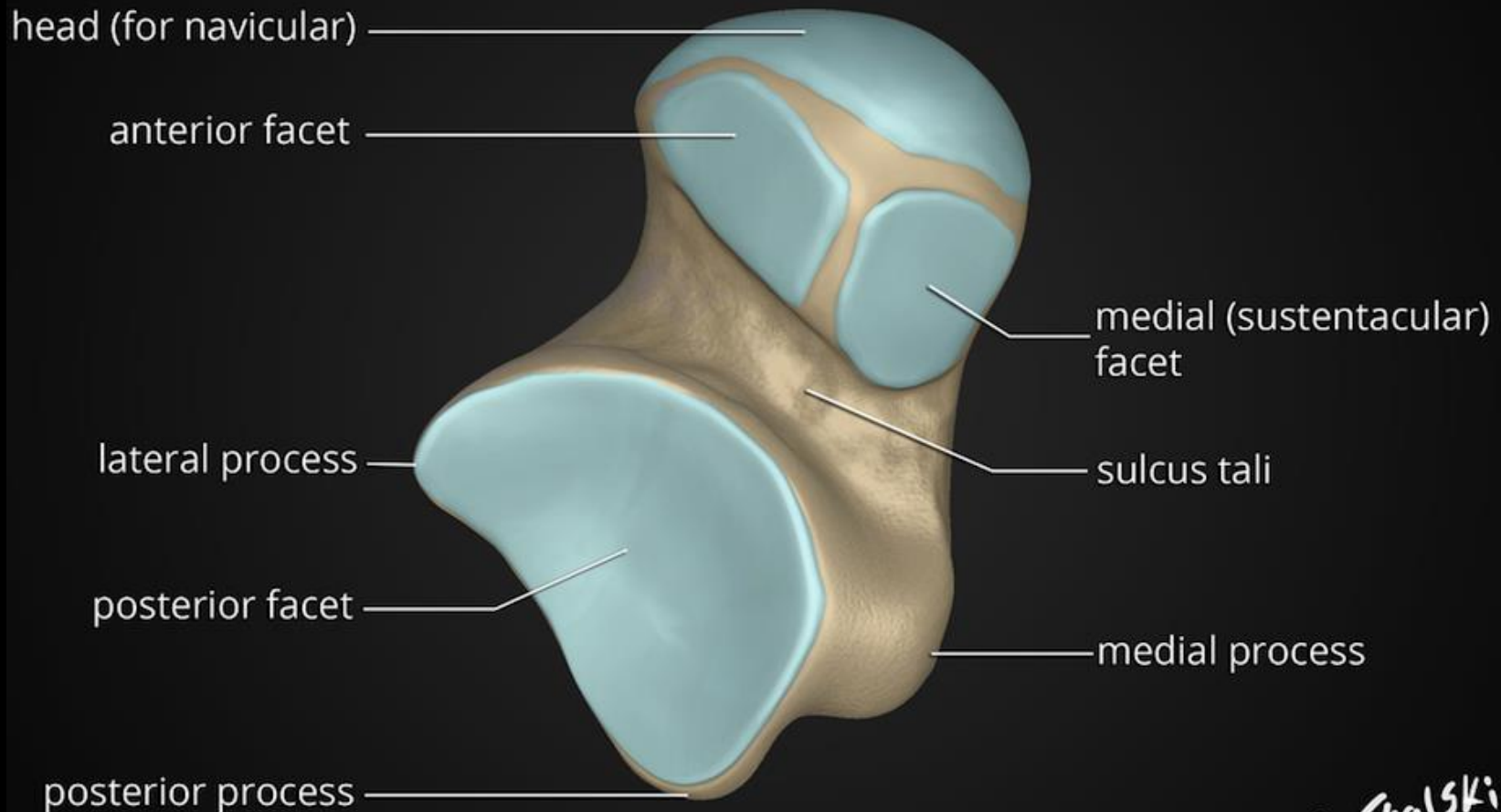
Talus Fractures

- less than 1% of all fractures
- 3% and 6% of fractures in the foot.
- Result of high-energy trauma
- Severity of talar injuries
- Complications and long-term disability
- Timely diagnosis and appropriate categorization are important for treatment planning

Talus Superior Projection

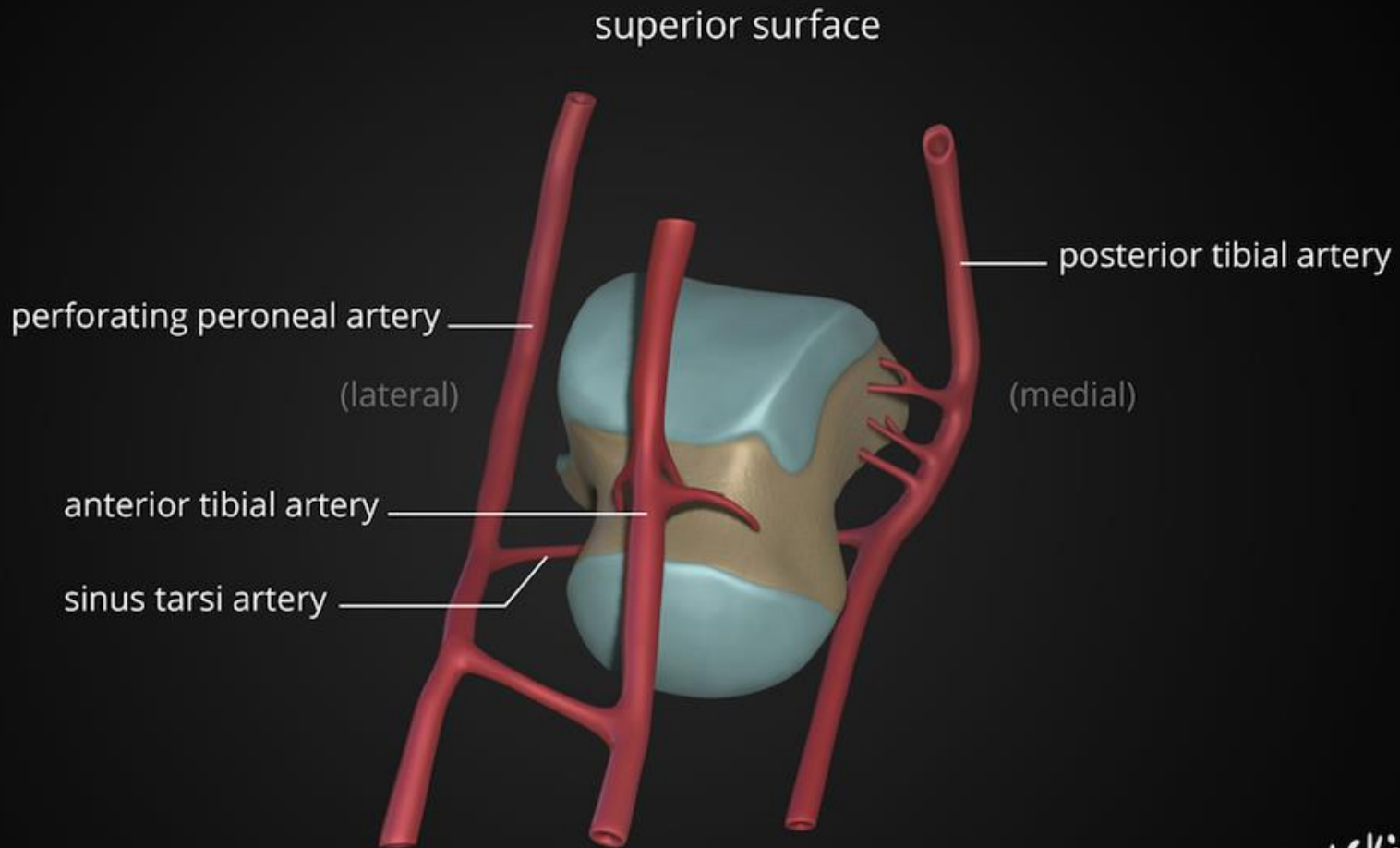


Talus Inferior Projection



M. Skalski

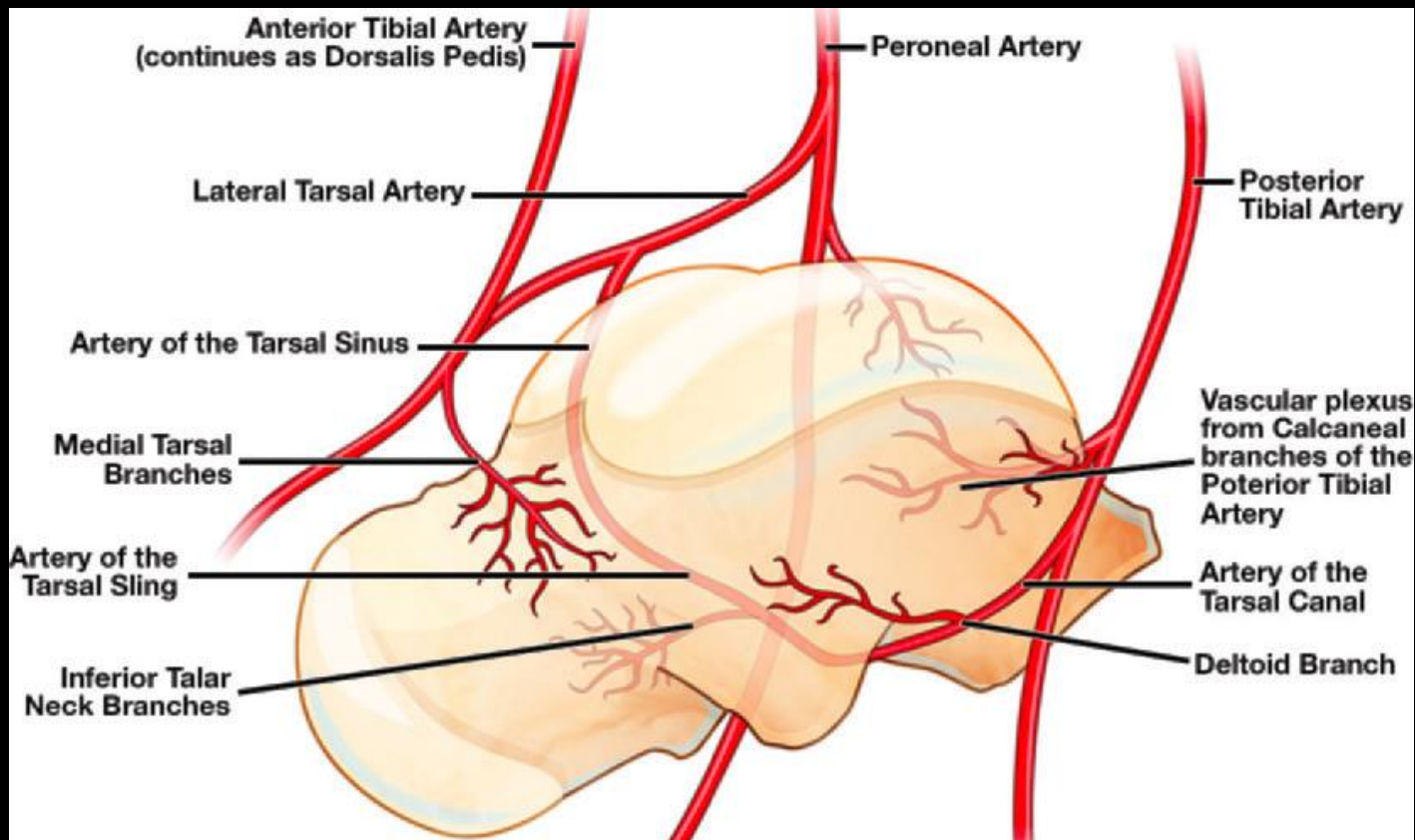
Vascular Anatomy of Talus

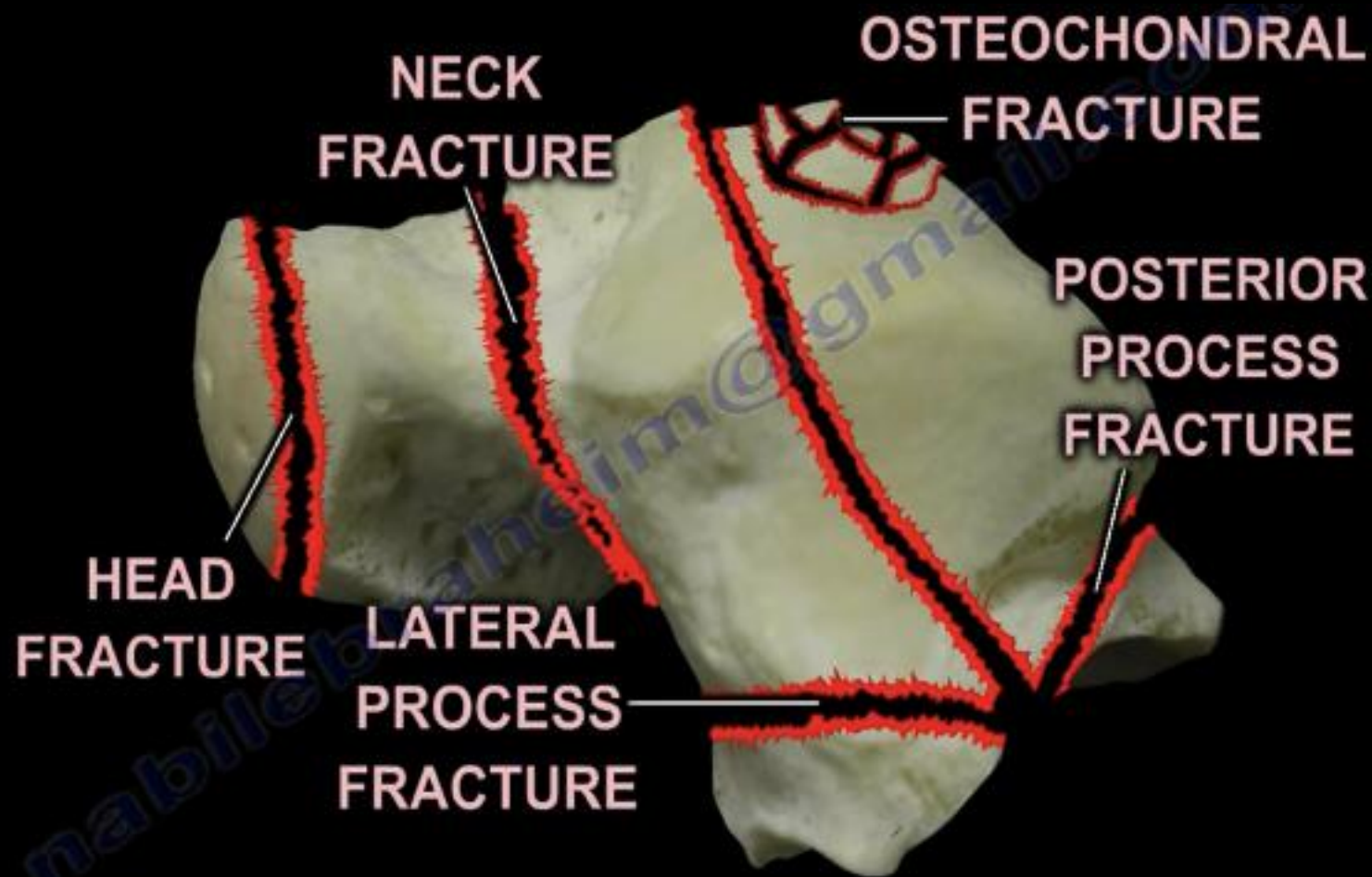


M. Skalski



Vascular Anatomy of Talus

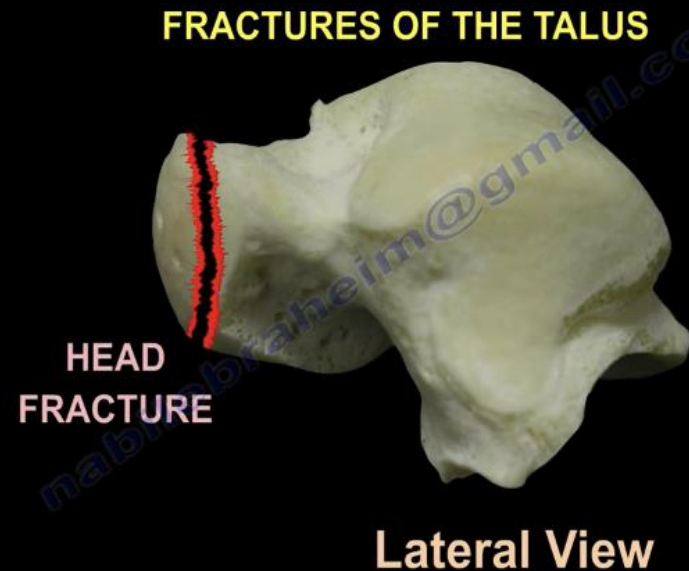




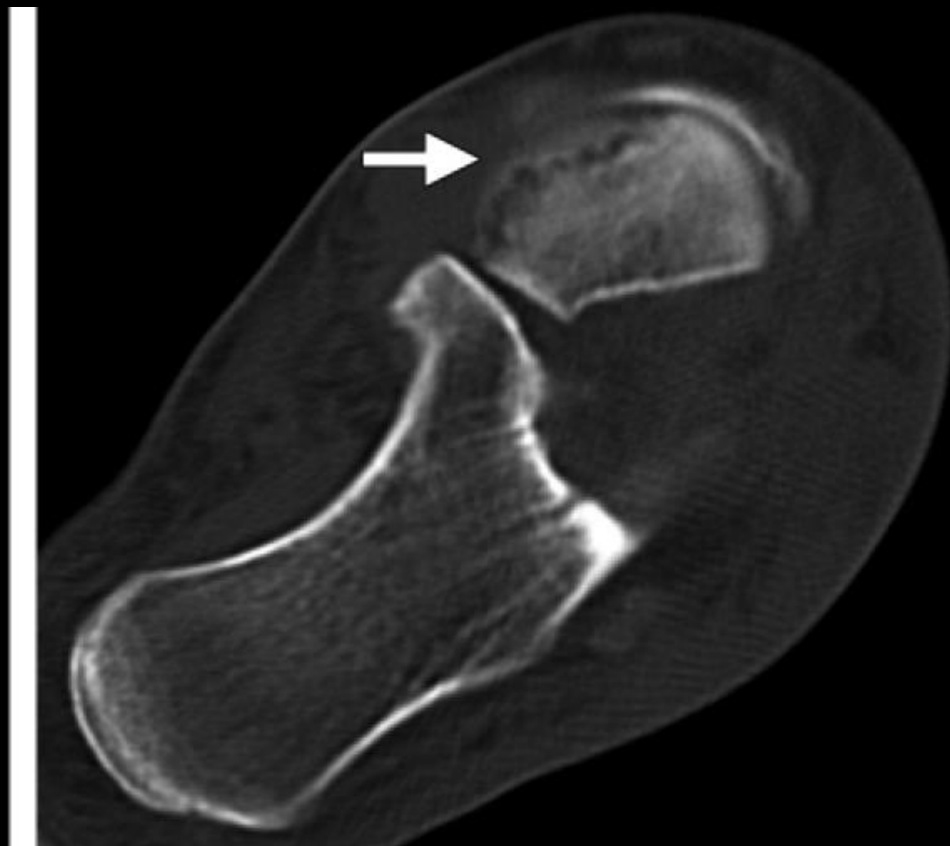
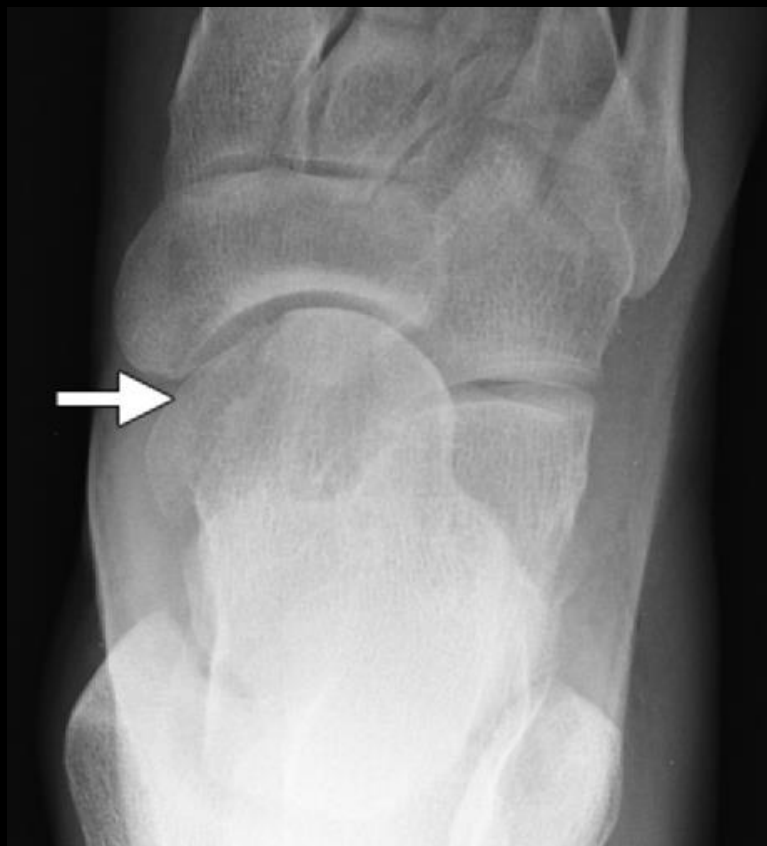Lateral View

Talar Head Fractures

- Articular surface of the talus at the talonavicular articulation
- least common, accounting for 5%– 10% of all talar fractures
- Two patterns have been described:
 - 1) crush injury
 - 2) shear fracture



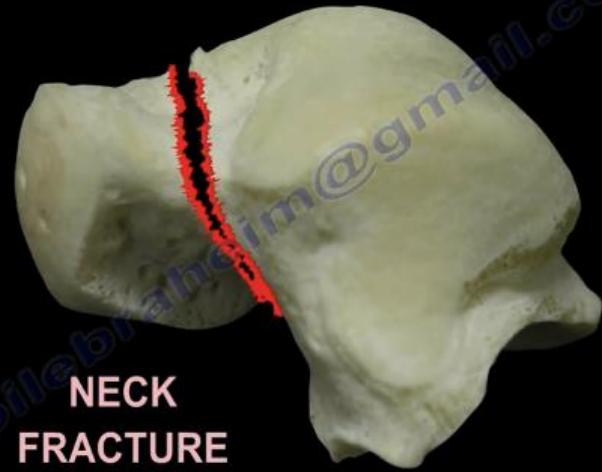
Talar Head Fractures



Talus Neck Fractures

- High incidence of talar neck fractures explained by its small cross-sectional area and vascular ingrowth, which increases the neck's porosity
- Mechanism of this injury is forced dorsiflexion of the talus against the anterior aspect of the tibia, preceded by rupture of the posterior subtalar ligaments.
- Motor vehicle or motorcycle collisions and high-level falls

FRACTURES OF THE TALUS



NECK
FRACTURE

Lateral View

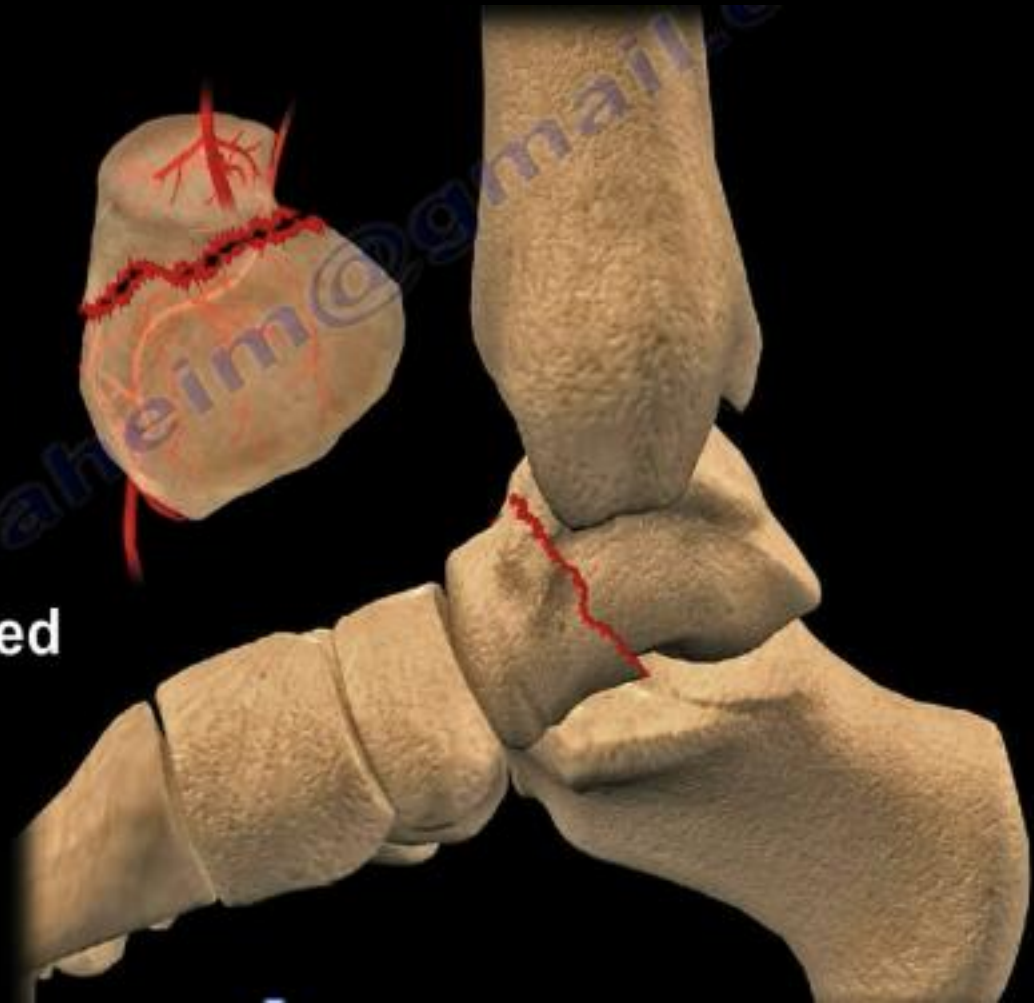Hawkins-Canale Type I

Table 1: Risk of Osteonecrosis in Hawkins-Canale–Type Talar Fractures

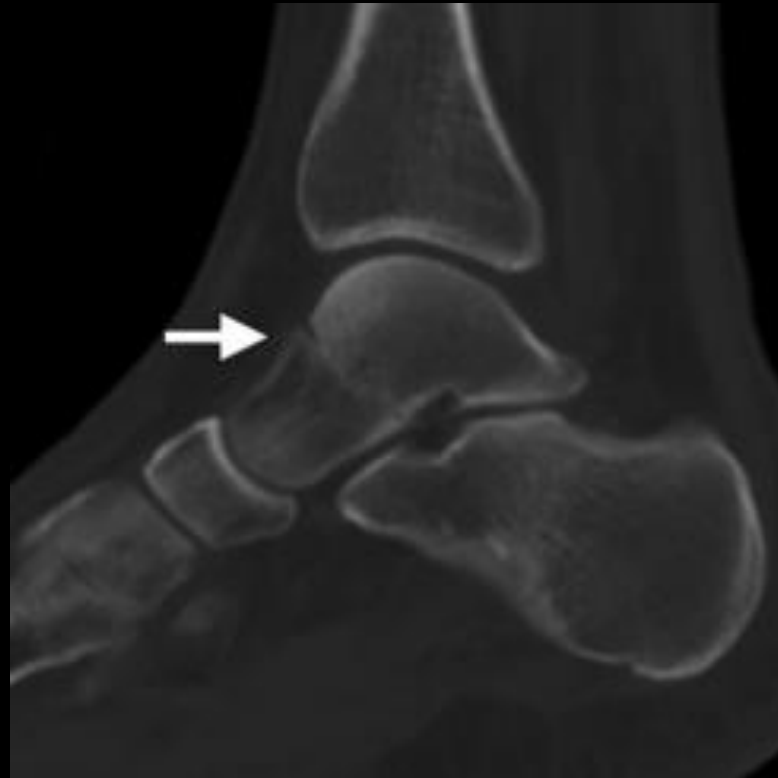Fracture Type	Description	Risk of Osteonecrosis (%)
I	Nondisplaced talar neck fracture	0–15
II	Talar neck fracture and talocalcaneal dislocation	20–50
III	Talar neck fracture, talocalcaneal dislocation, and tibiotalar dislocation	100
IV	Talar neck fracture and disruption of all talar articulations	100

TYPE I

- Non - displaced
- 10% AVN



Hawkins-Canale Type I



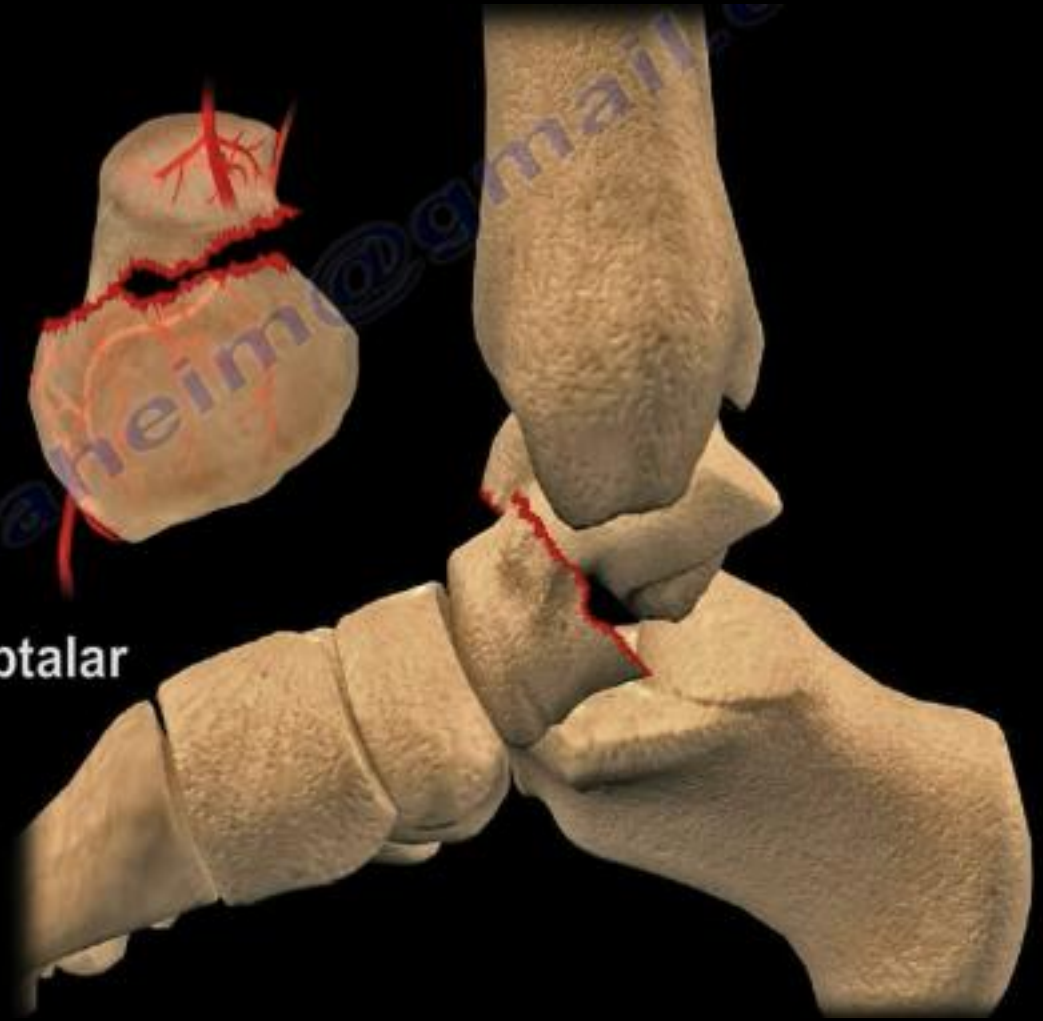
Hawkins-Canale Type 2

Table 1: Risk of Osteonecrosis in Hawkins-Canale–Type Talar Fractures

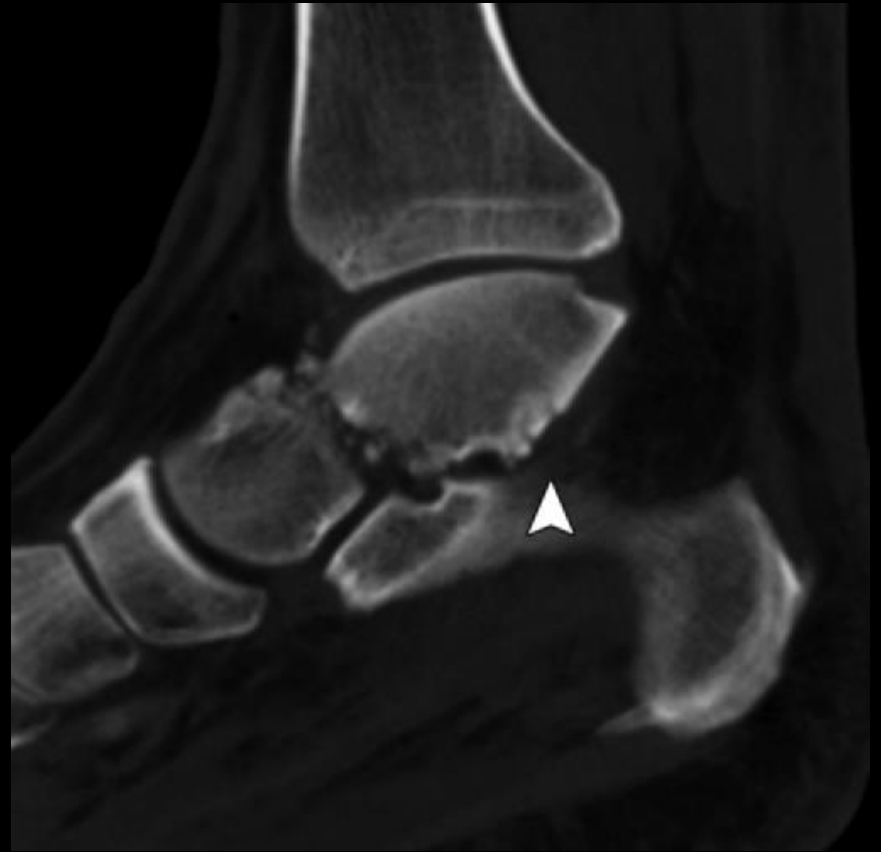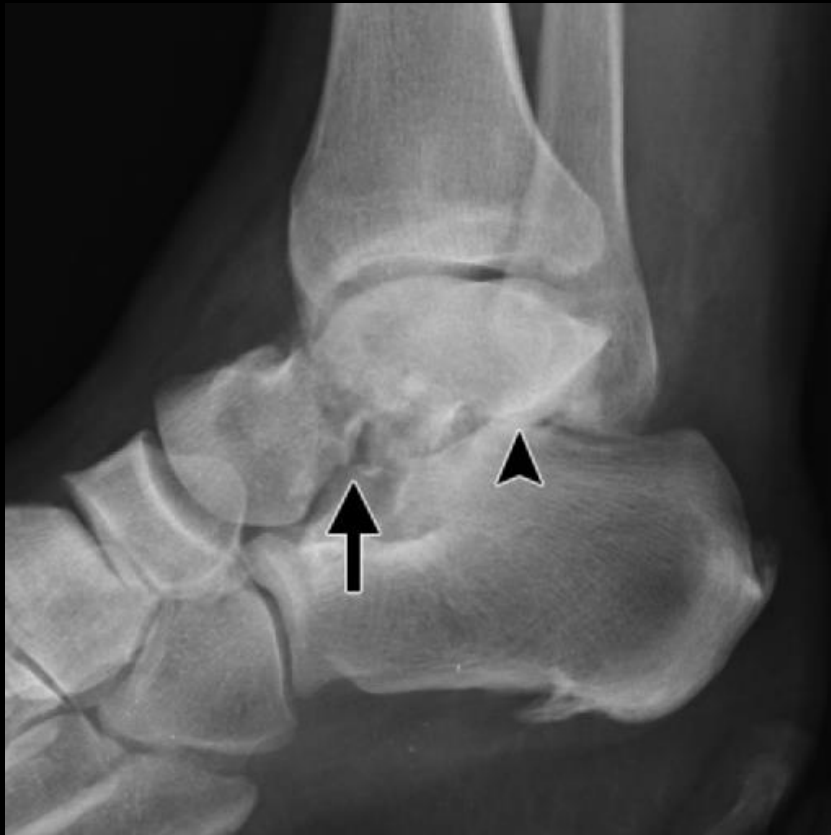Fracture Type	Description	Risk of Osteonecrosis (%)
I	Nondisplaced talar neck fracture	0–15
II	Talar neck fracture and talocalcaneal dislocation	20–50
III	Talar neck fracture, talocalcaneal dislocation, and tibiotalar dislocation	100
IV	Talar neck fracture and disruption of all talar articulations	100

TYPE II

- Fracture with subtalar dislocation or subluxation
- 50% AVN



Hawkins-Canale Type 2



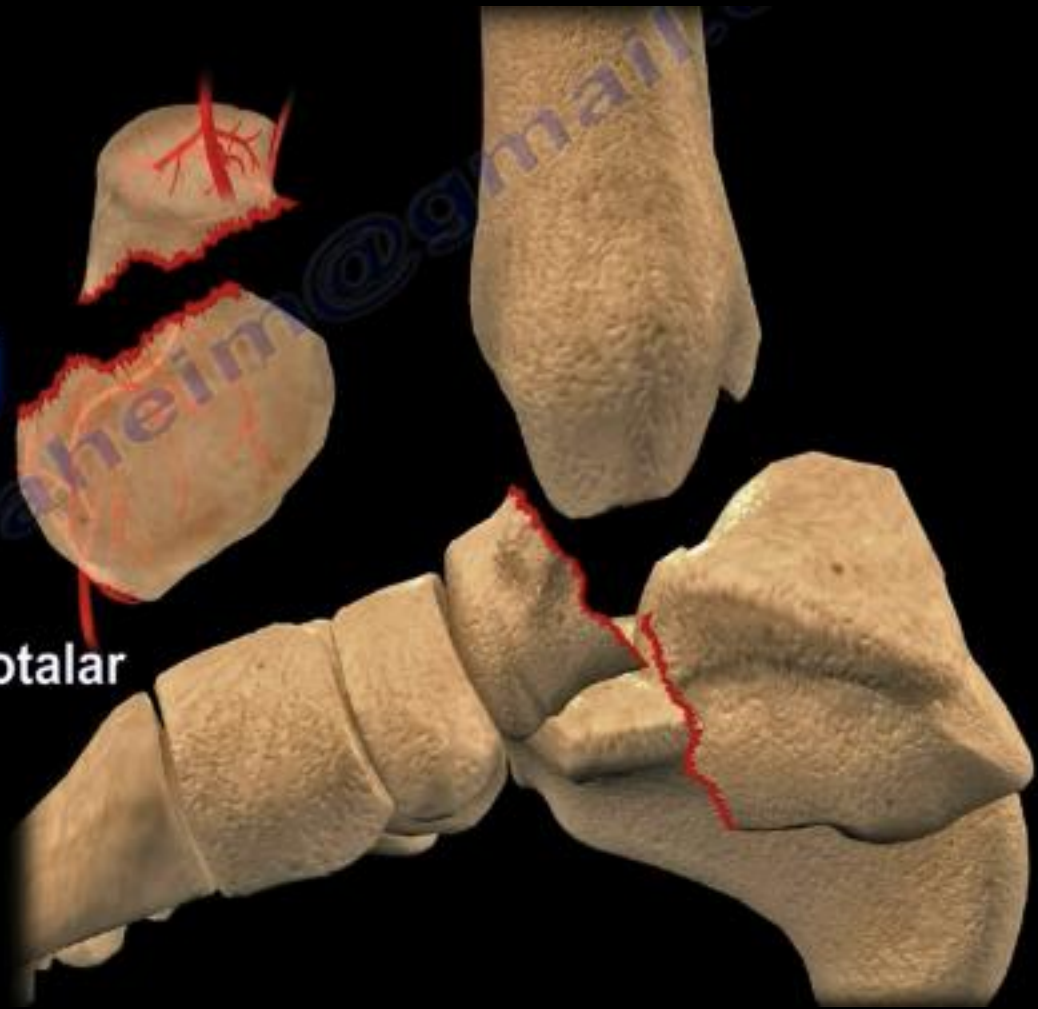Hawkins-Canale Type 3

Table 1: Risk of Osteonecrosis in Hawkins-Canale–Type Talar Fractures

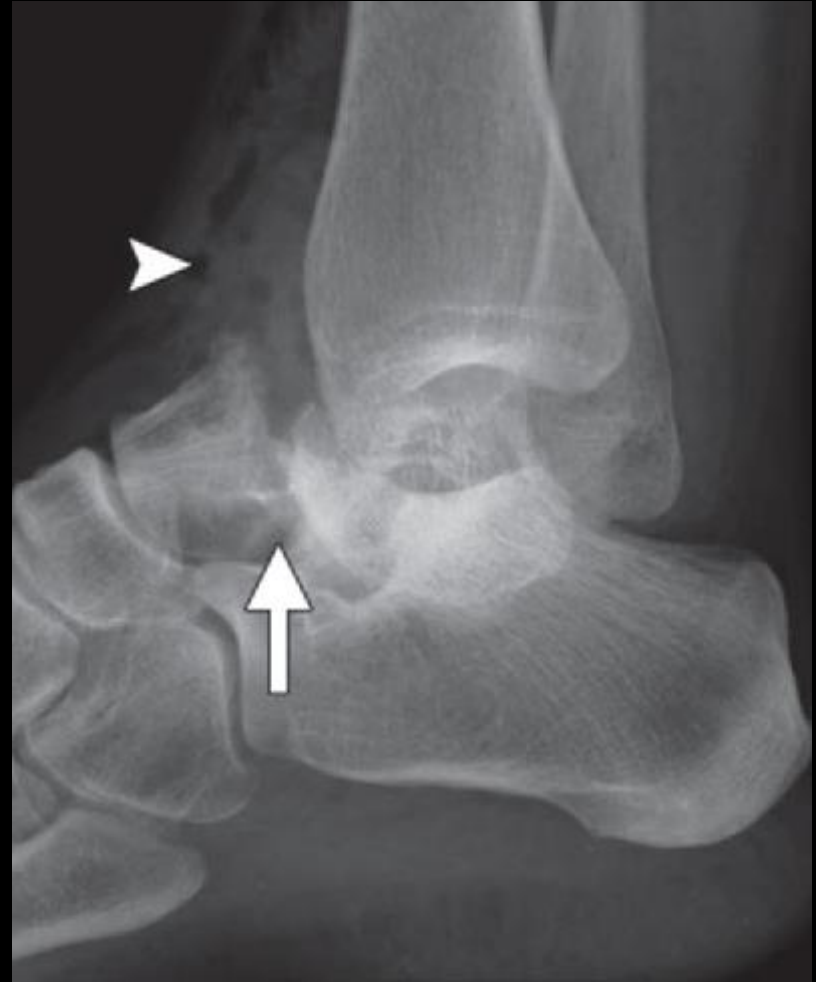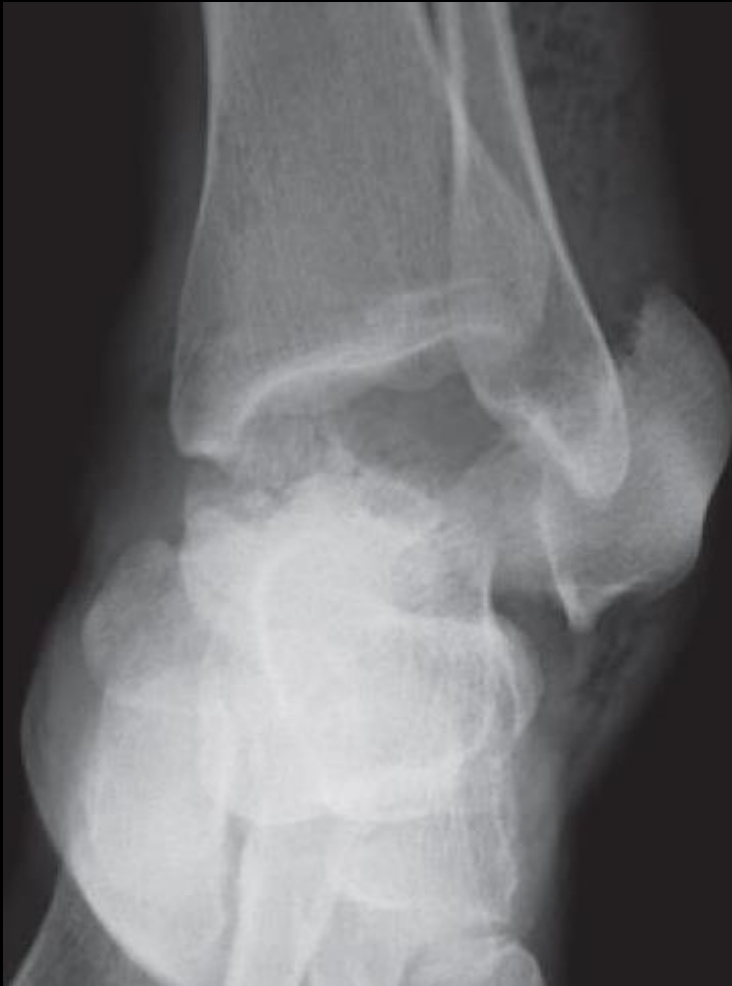Fracture Type	Description	Risk of Osteonecrosis (%)
I	Nondisplaced talar neck fracture	0–15
II	Talar neck fracture and talocalcaneal dislocation	20–50
III	Talar neck fracture, talocalcaneal dislocation, and tibiotalar dislocation	100
IV	Talar neck fracture and disruption of all talar articulations	100

TYPE III

- Fracture with subtalar and tibiotalar dislocation
- 90% AVN



Hawkins-Canale Type 3



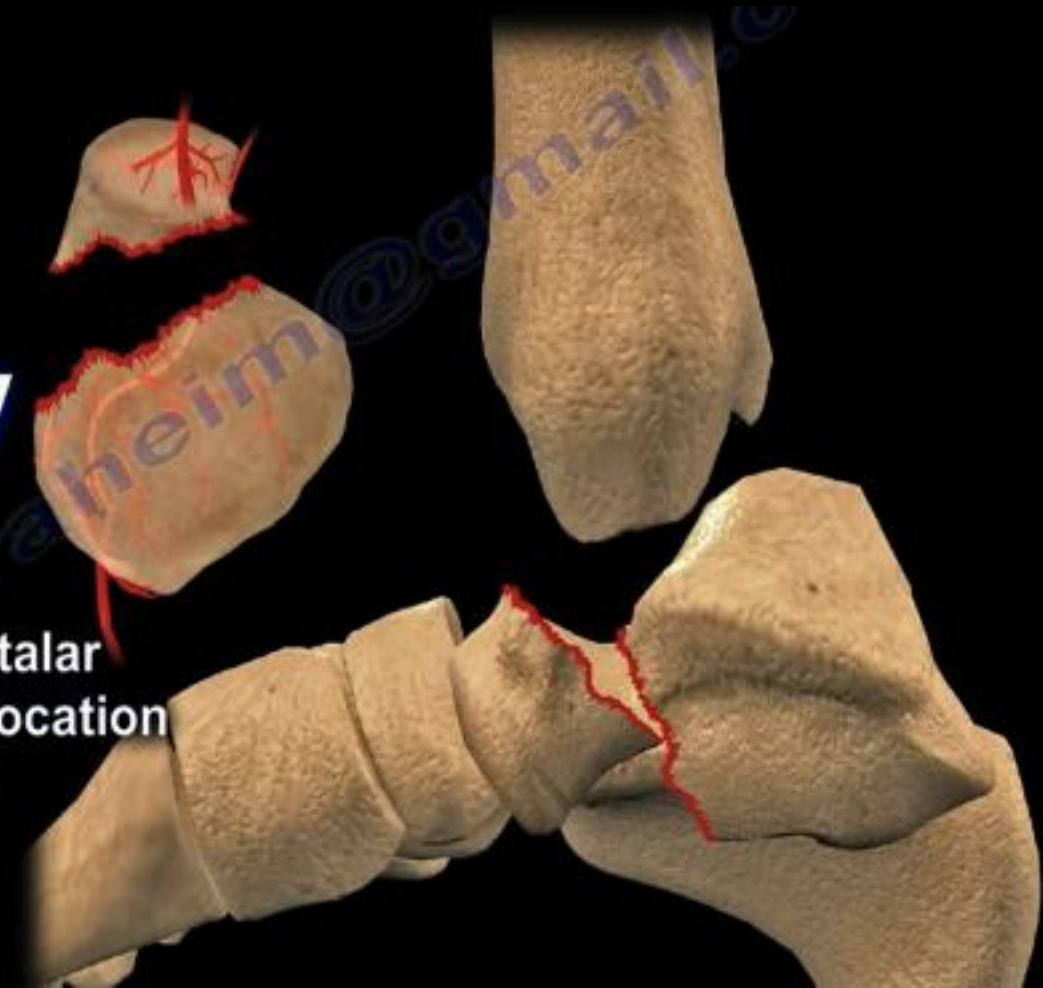Hawkins-Canale Type 4

Table 1: Risk of Osteonecrosis in Hawkins-Canale–Type Talar Fractures

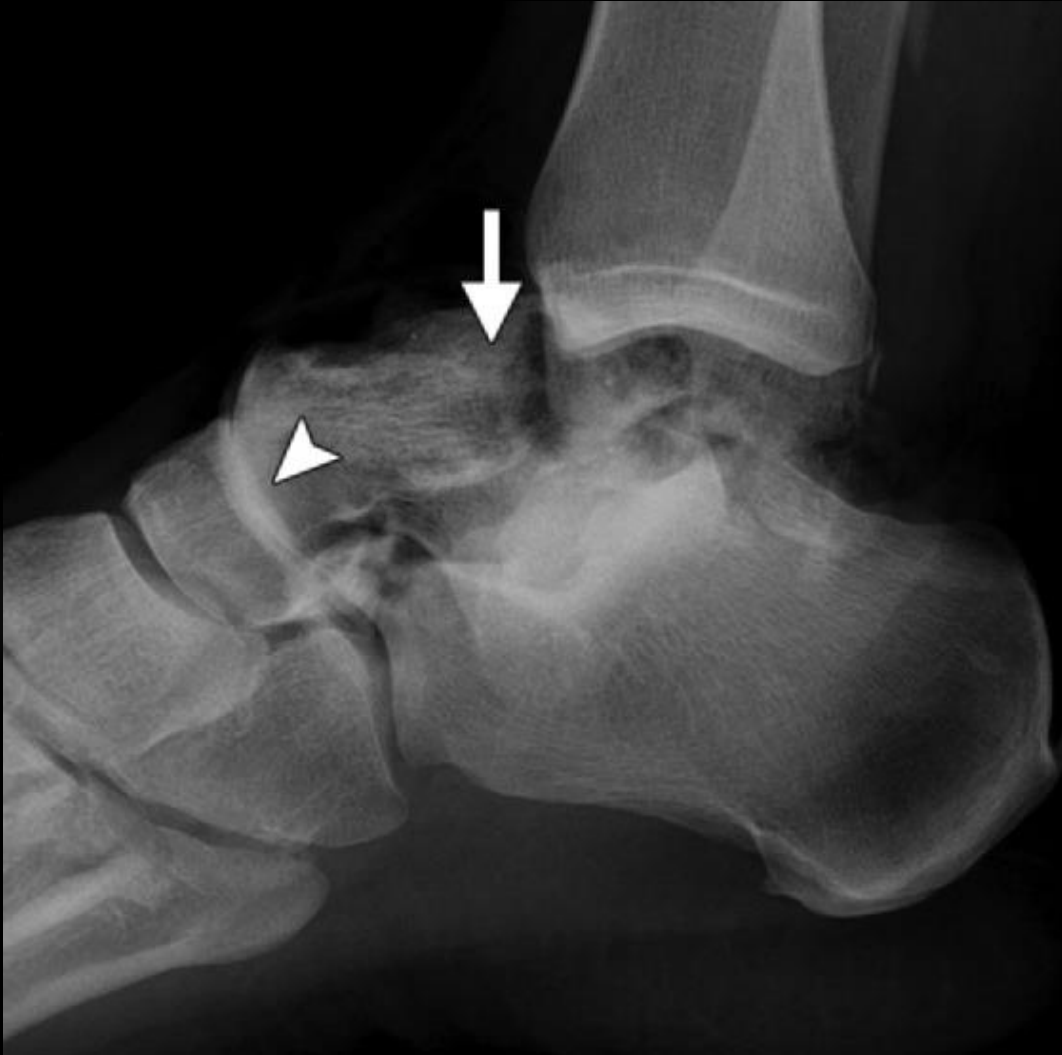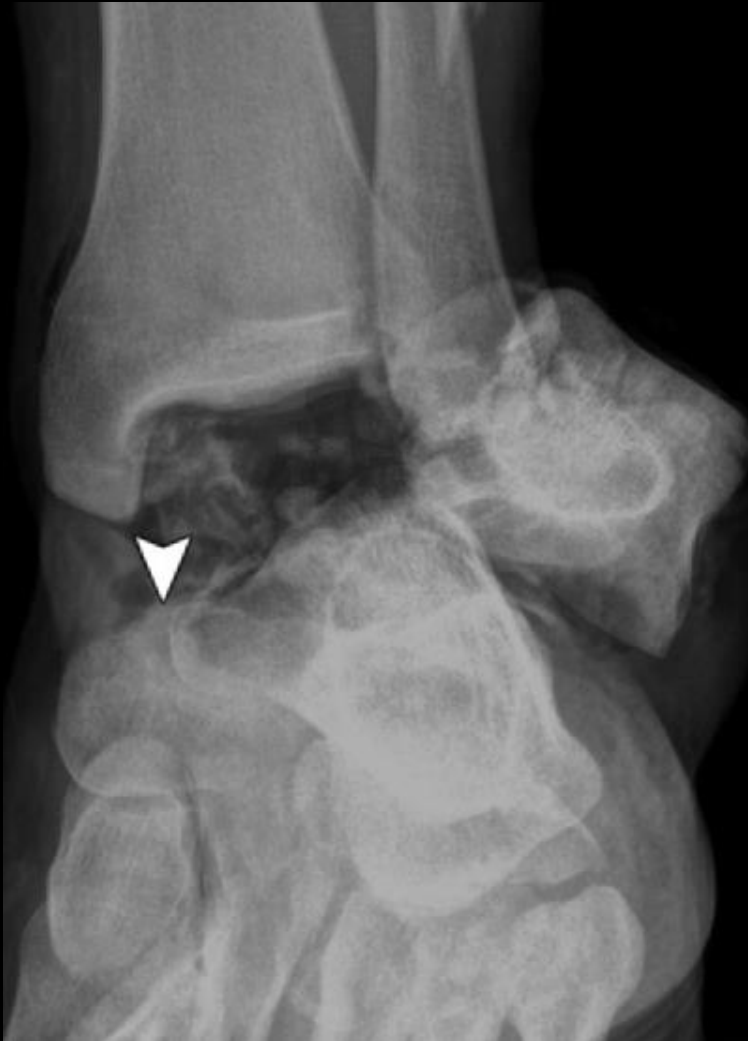Fracture Type	Description	Risk of Osteonecrosis (%)
I	Nondisplaced talar neck fracture	0–15
II	Talar neck fracture and talocalcaneal dislocation	20–50
III	Talar neck fracture, talocalcaneal dislocation, and tibiotalar dislocation	100
IV	Talar neck fracture and disruption of all talar articulations	100

TYPE IV

- Fracture with subtalar and tibiotalar dislocation and talonavicular subluxation or dislocation.



Hawkins-Canale Type 4



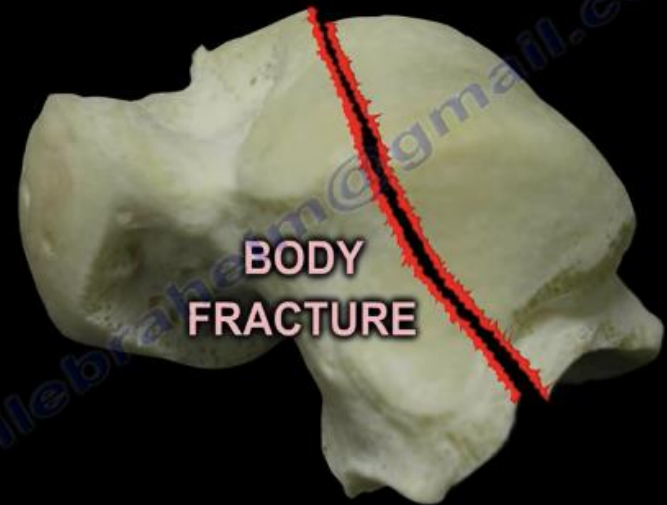
Surgery

- Conservative for nondisplaced talar neck fractures.
- Therefore, even subtle displacement of the talar neck fracture must be detected.
- Most type II fractures are treated with surgical reduction.
- In type III and IV fractures, closed reduction may be initially attempted in the emergency department to relieve skin tension and minimize soft-tissue injury followed with ORIF

Talar Body Fractures

- Intra-articular
- Incidence ranges widely from 13% to 61%
- Sneppen classification

FRACTURES OF THE TALUS



Lateral View

Sneppen Classification

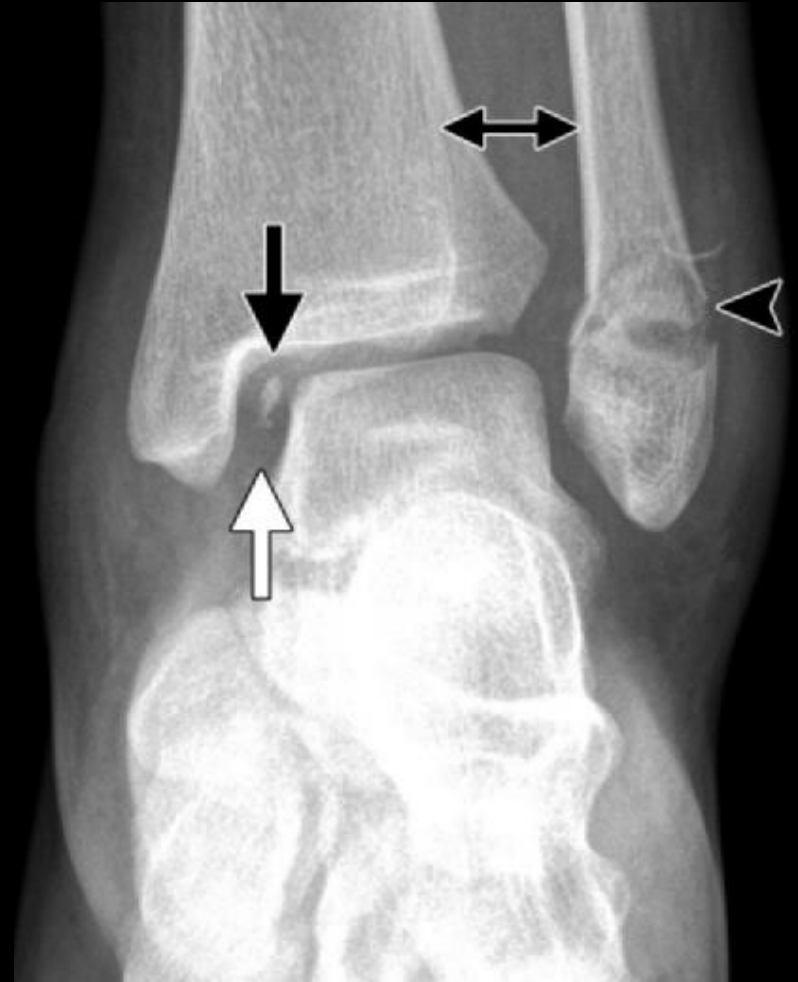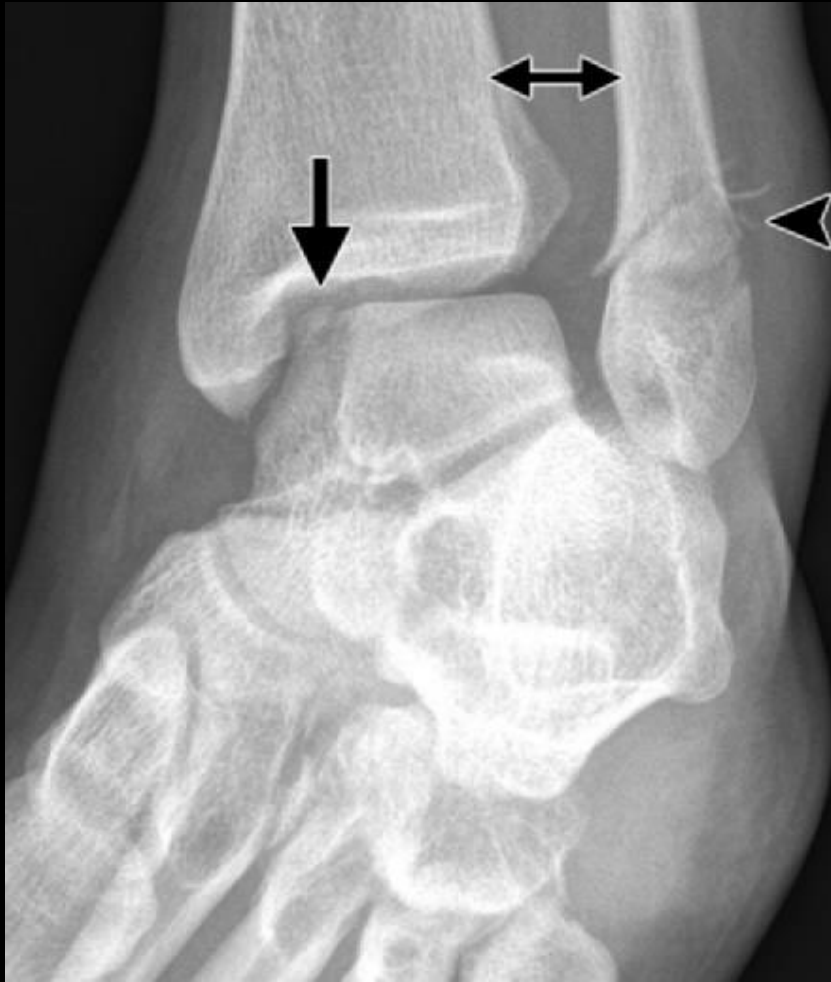Table 2: Sneppen Classification of Talar Body Fractures

Type	Description
A	Compression or osteochondral dome fracture
B	Coronal shear fracture
C	Sagittal shear fracture
D	Posterior tubercle fracture
E	Lateral tubercle fracture
F	Crush comminuted fracture

Table 2: Sneppen Classification of Talar Body Fractures

Type	Description
A	Compression or osteochondral dome fracture
B	Coronal shear fracture
C	Sagittal shear fracture
D	Posterior tubercle fracture
E	Lateral tubercle fracture
F	Crush comminuted fracture

Medial talar dome osteochondral fracture



Lateral talar dome osteochondral fracture

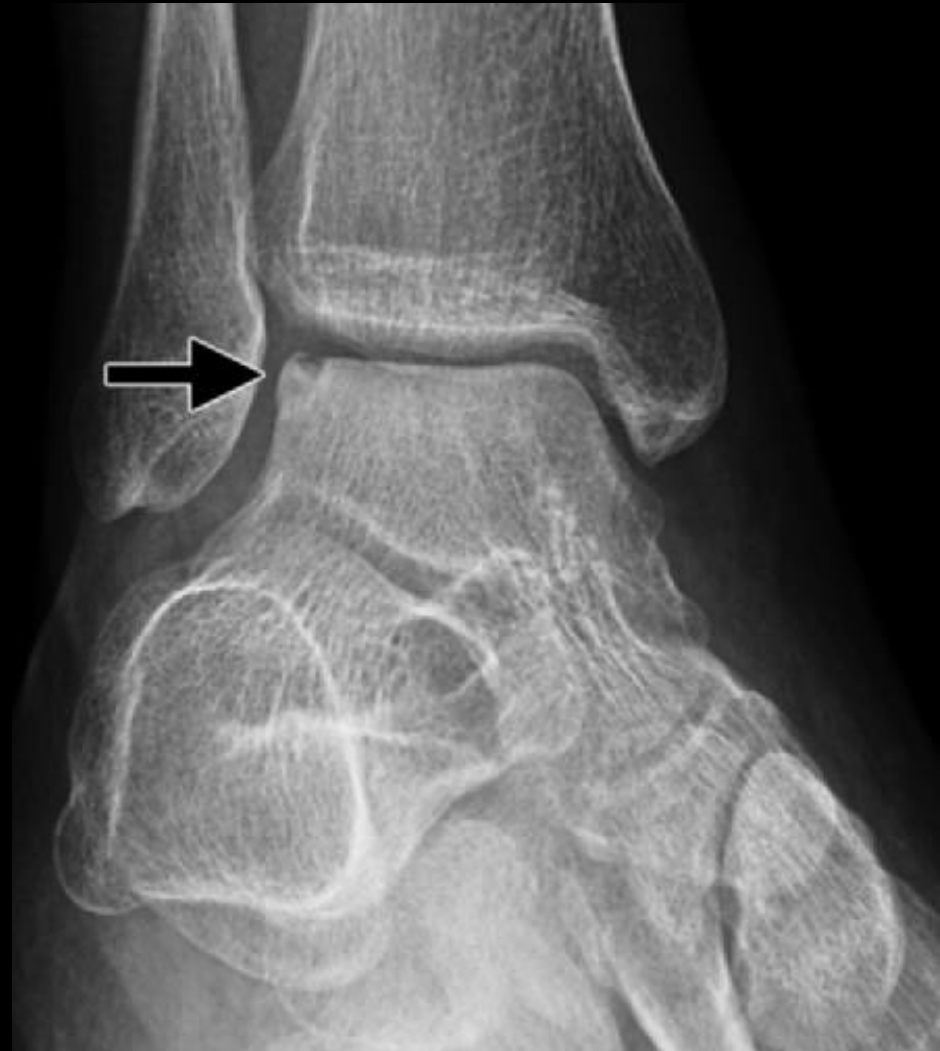
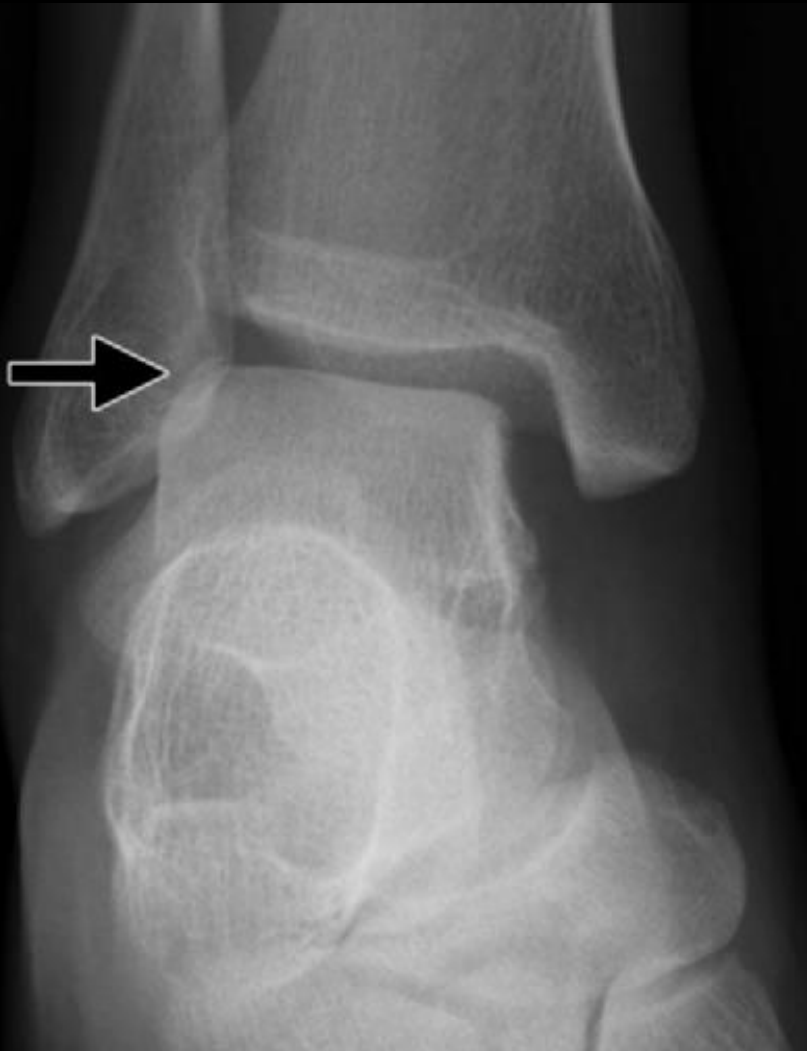
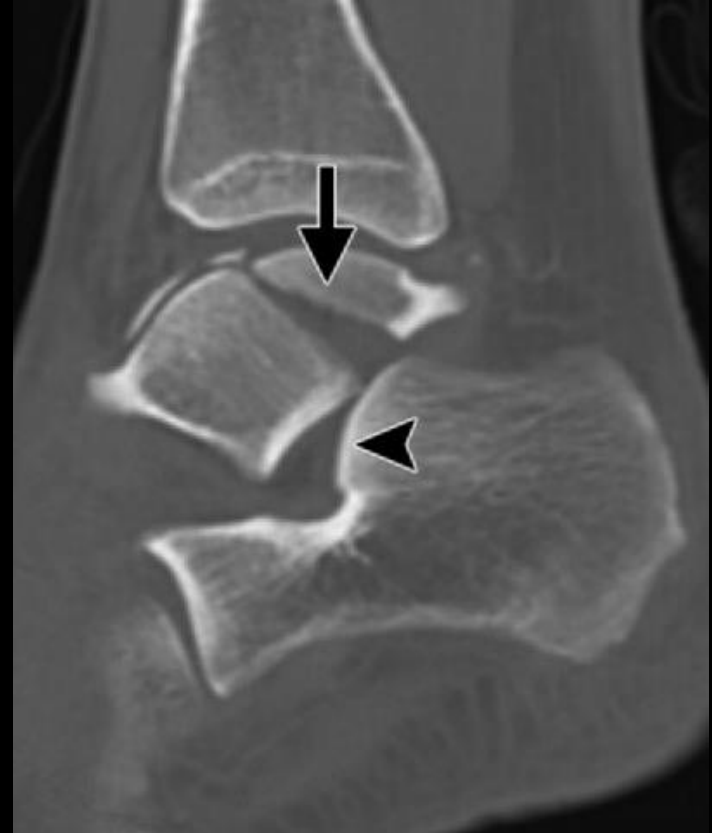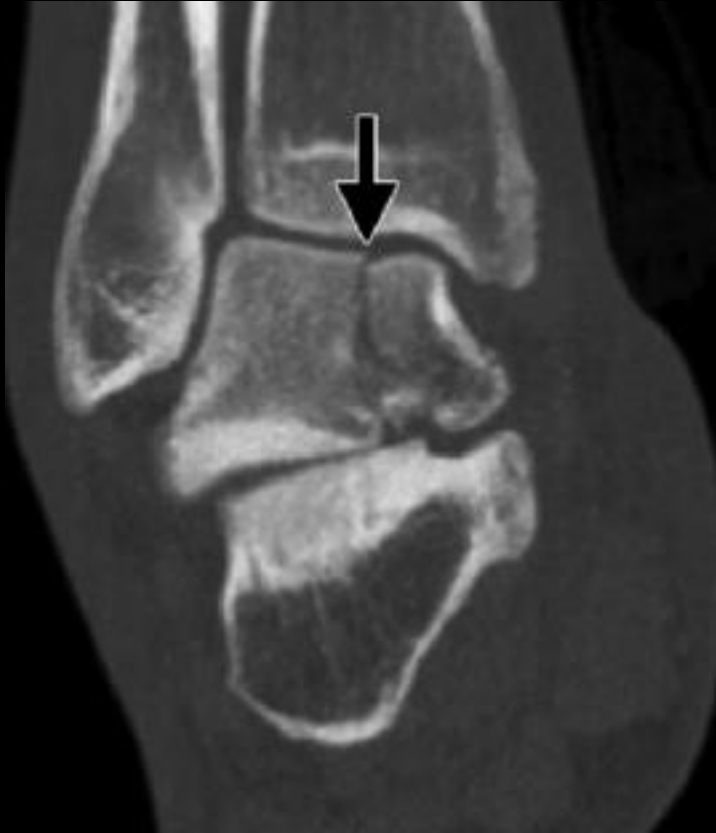Table 2: Sneppen Classification of Talar Body Fractures

Type	Description
A	Compression or osteochondral dome fracture
B	Coronal shear fracture
C	Sagittal shear fracture
D	Posterior tubercle fracture
E	Lateral tubercle fracture
F	Crush comminuted fracture

Table 2: Sneppen Classification of Talar Body Fractures

Type	Description
A	Compression or osteochondral dome fracture
B	Coronal shear fracture
C	Sagittal shear fracture
D	Posterior tubercle fracture
E	Lateral tubercle fracture
F	Crush comminuted fracture

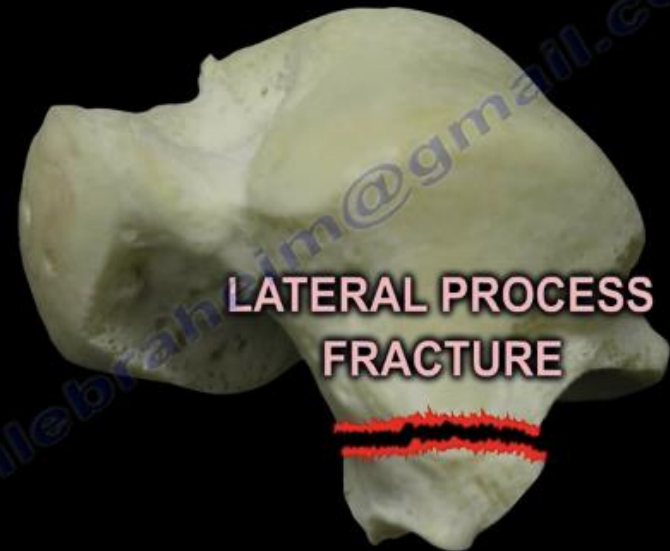
Sagittal and Coronal Shear Type



Lateral Process Fractures

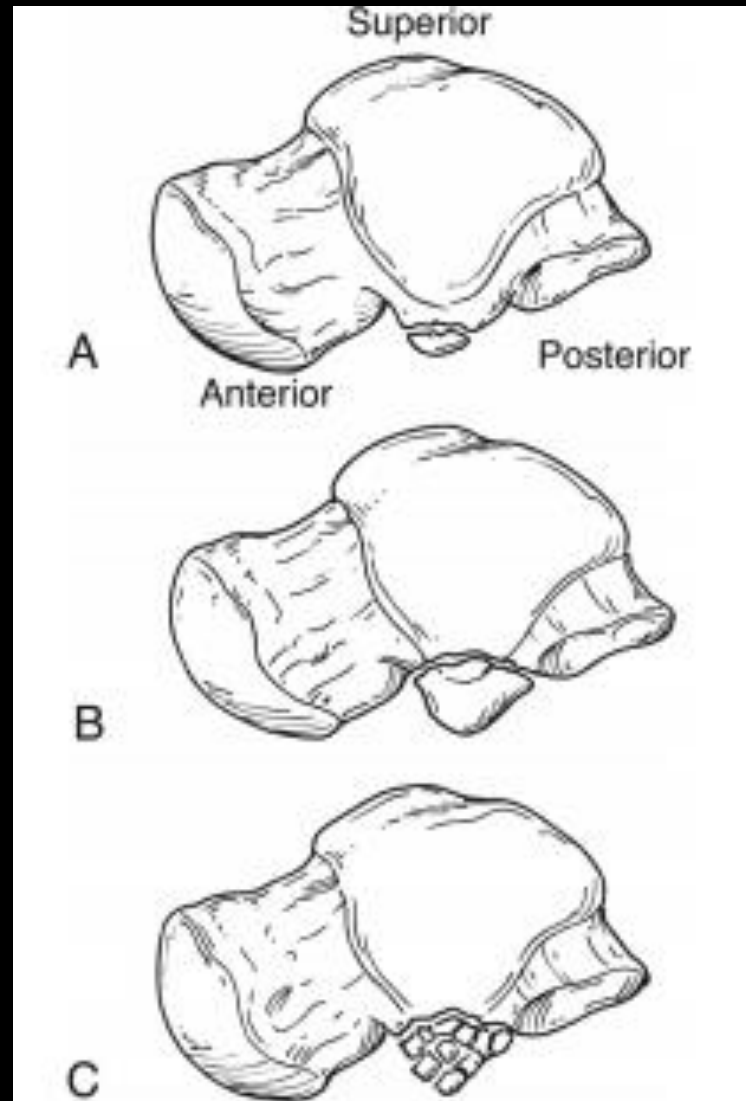
- Snowboarding: 17x more common
- 15% of all snowboarder ankle injuries
- Often occult on initial radiographs
- Persistent pain about the lateral side of the ankle after forced dorsiflexion and inversion injuries to the foot account
- Hawkins Classification

FRACTURES OF THE TALUS

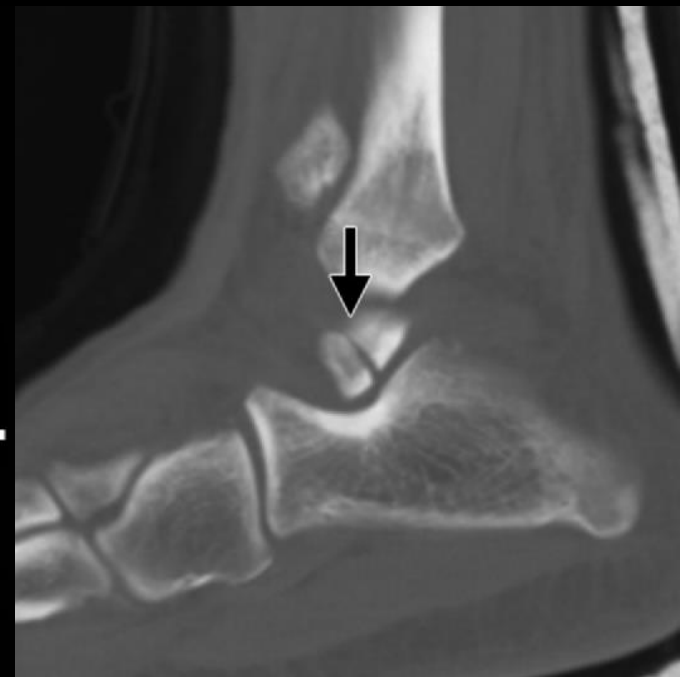
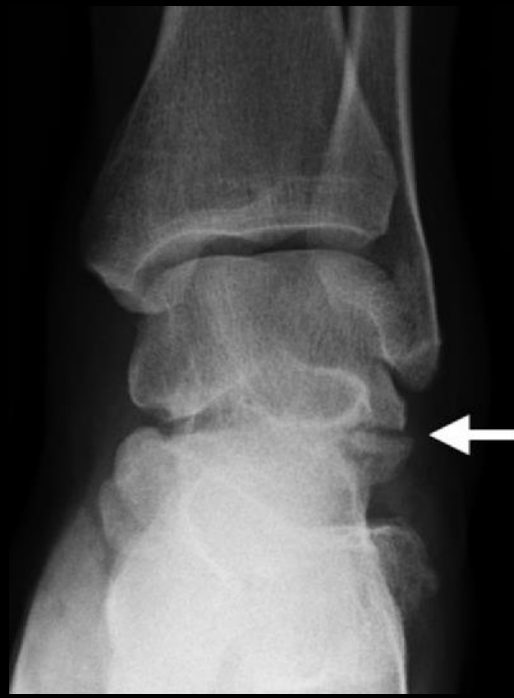
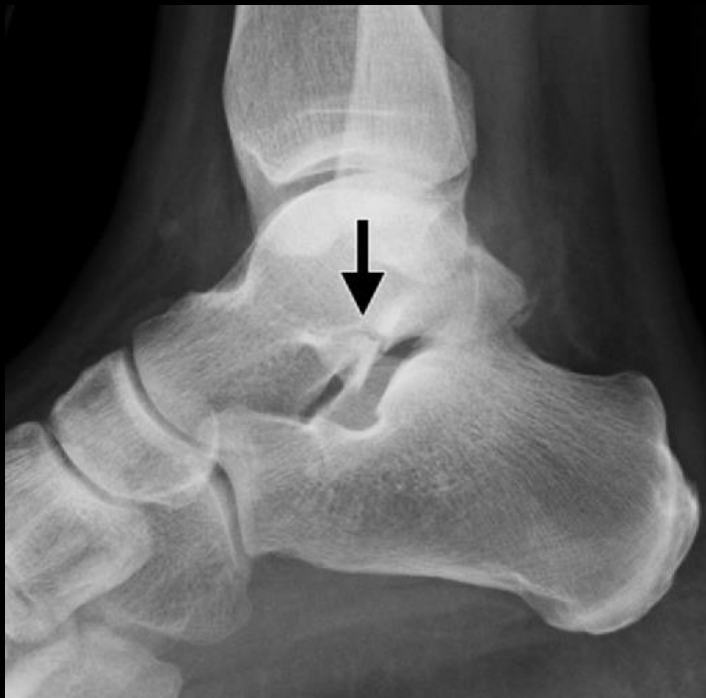Lateral View

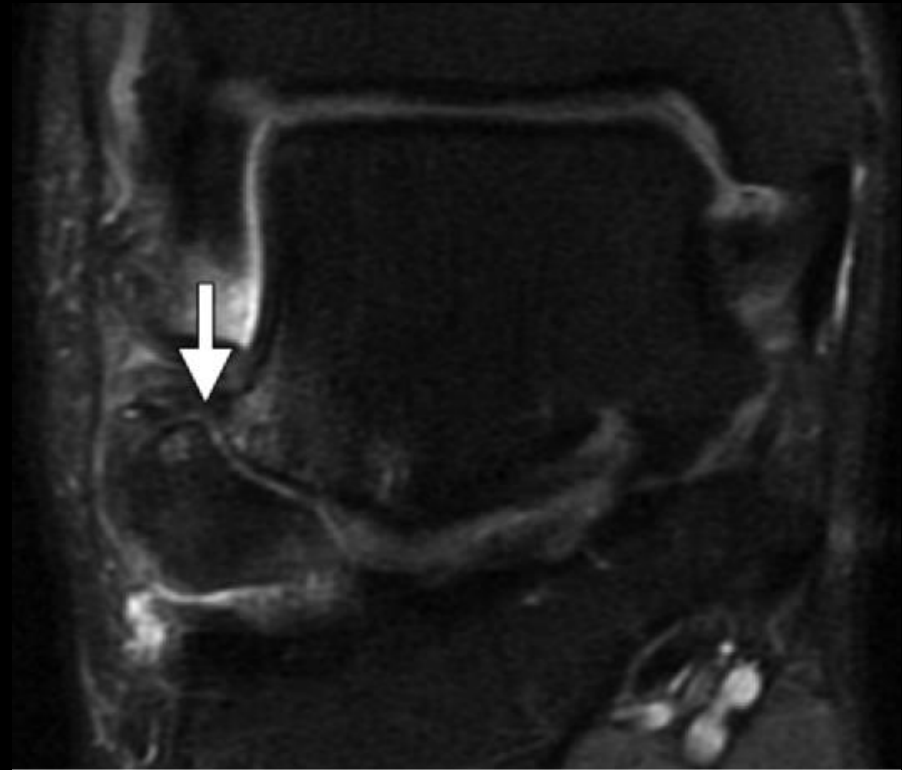
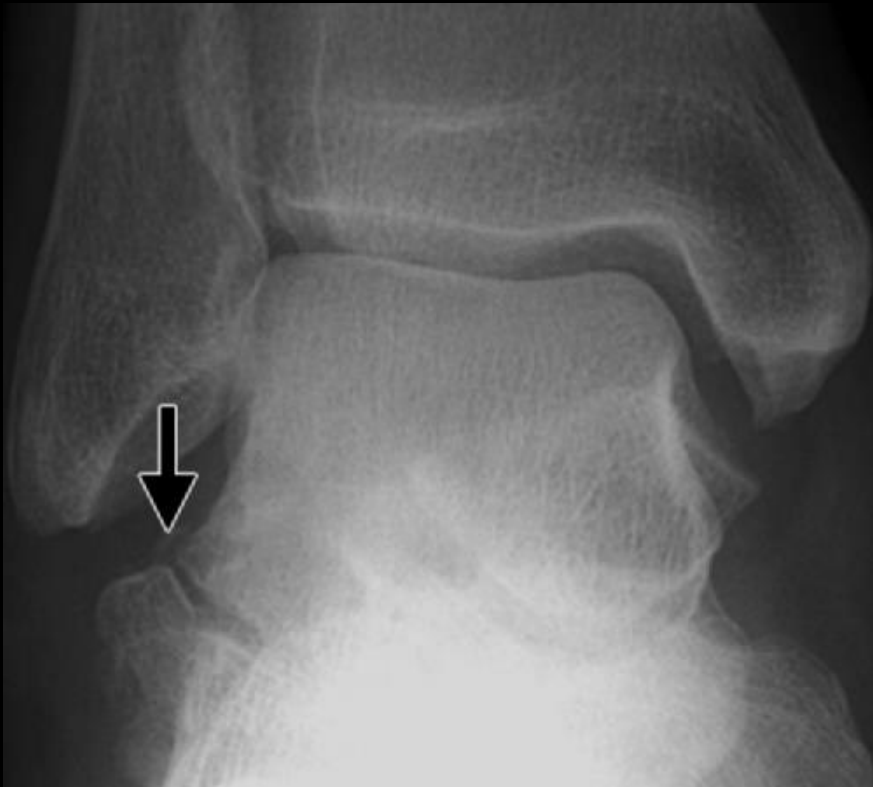“Hawkins Classification”



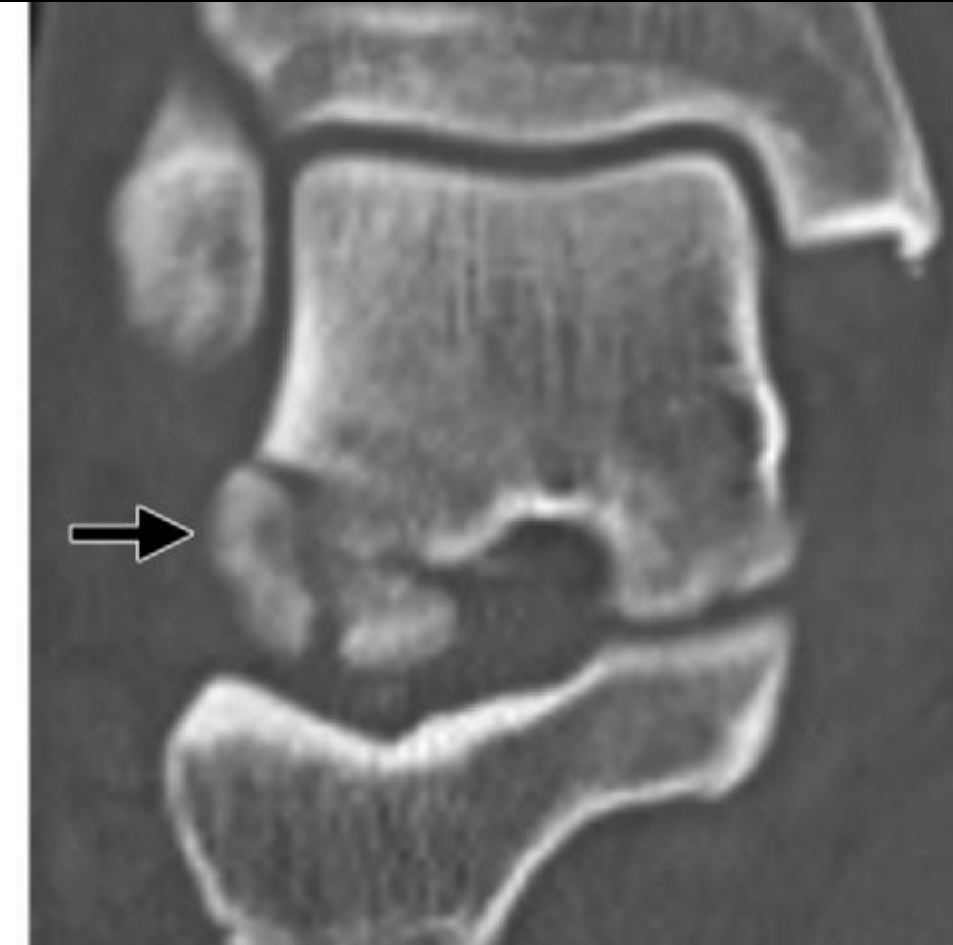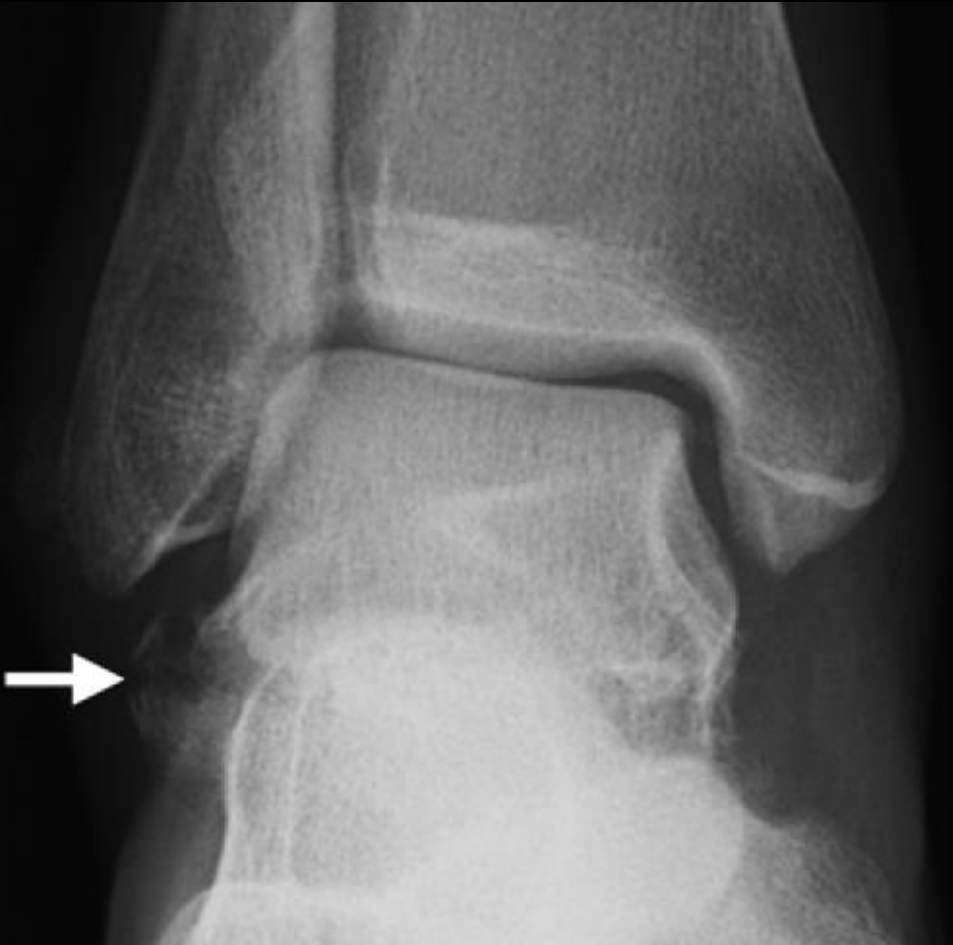Type I (simple) fracture



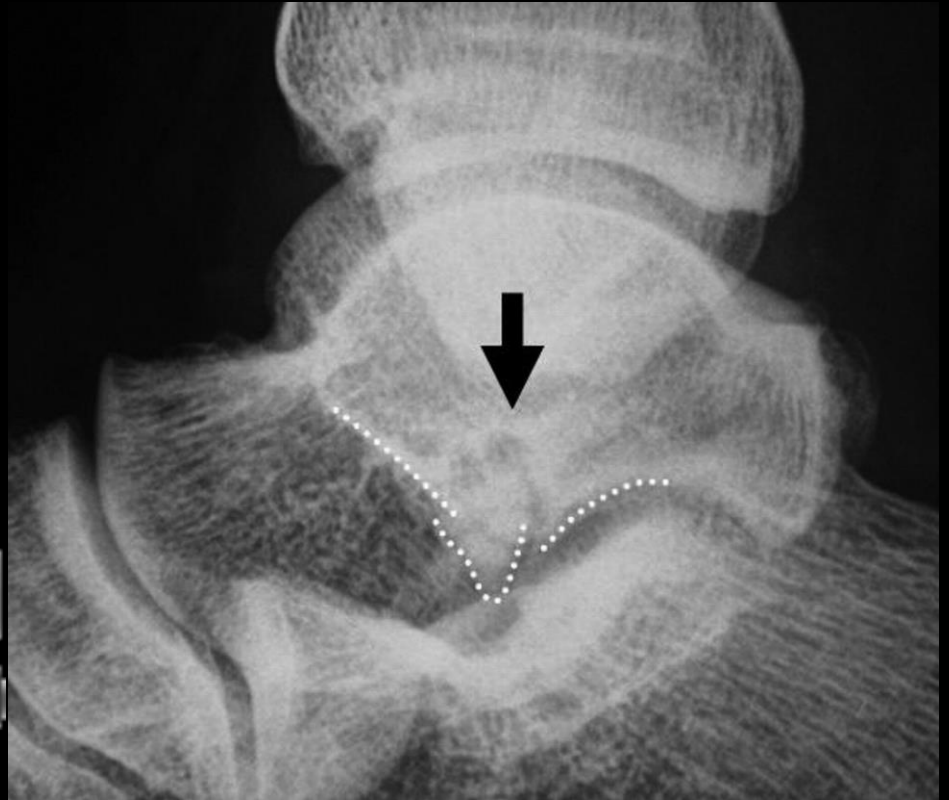
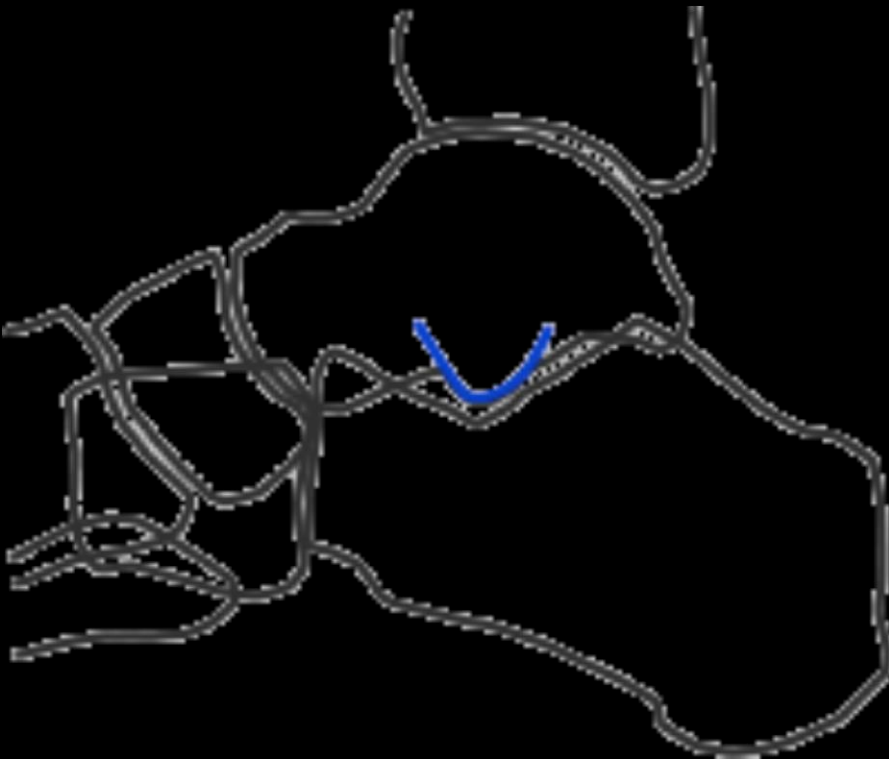Type II (cortical avulsion) fracture



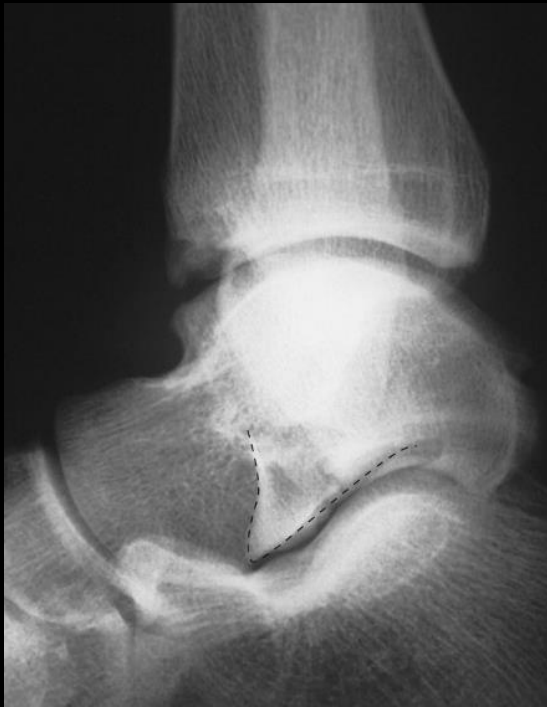Type III (comminuted)



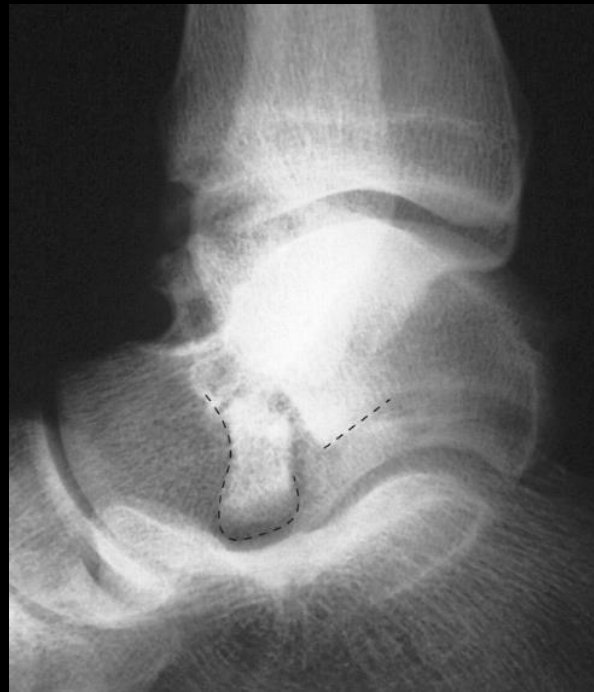Lateral Process Fractures



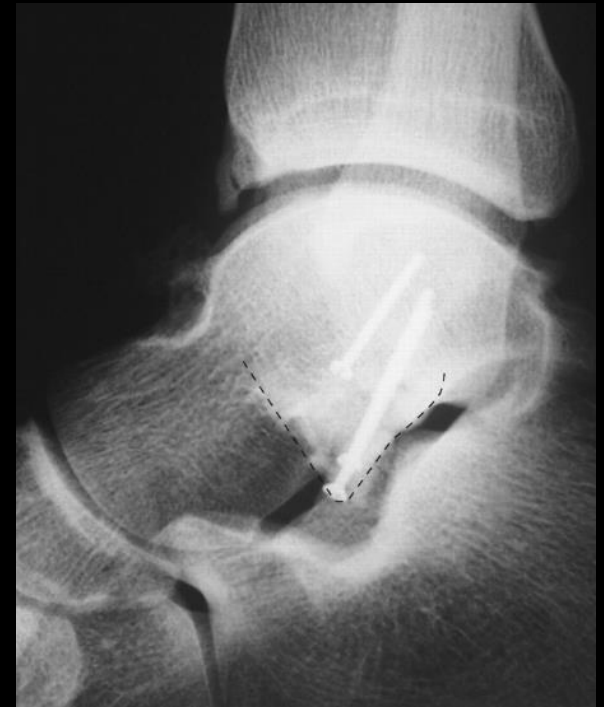Lateral Process Fractures



Immediately after injury

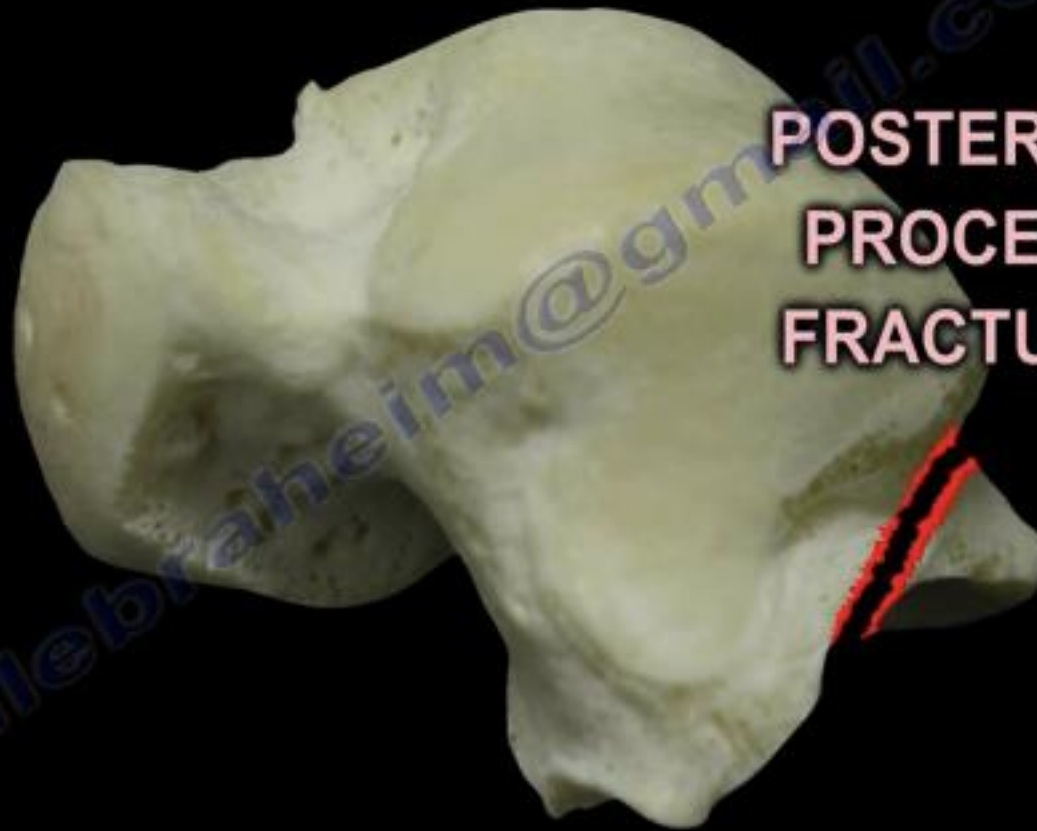

5 month



Post surgery

FRACTURES OF THE TALUS



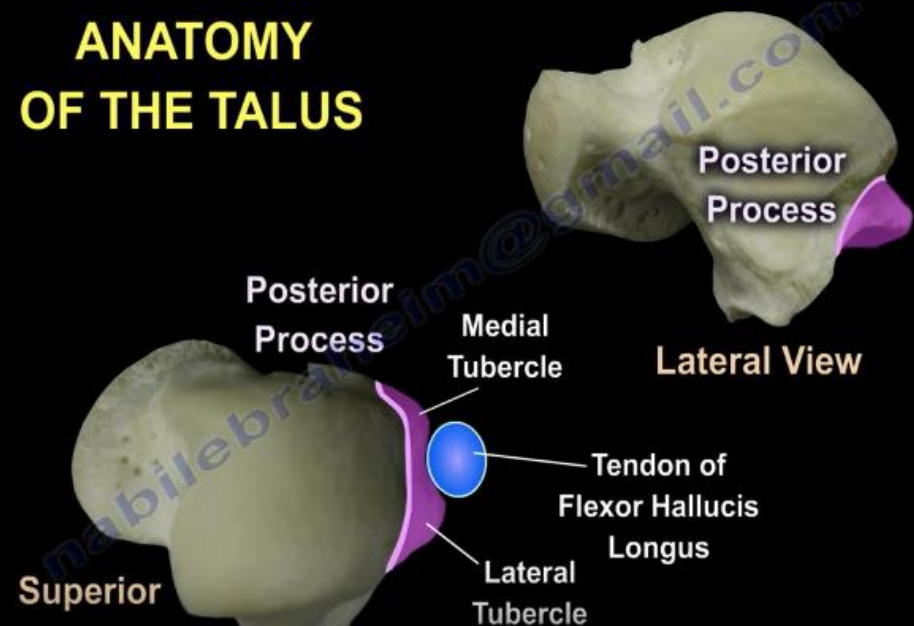
POSTERIOR
PROCESS
FRACTURE

Lateral View

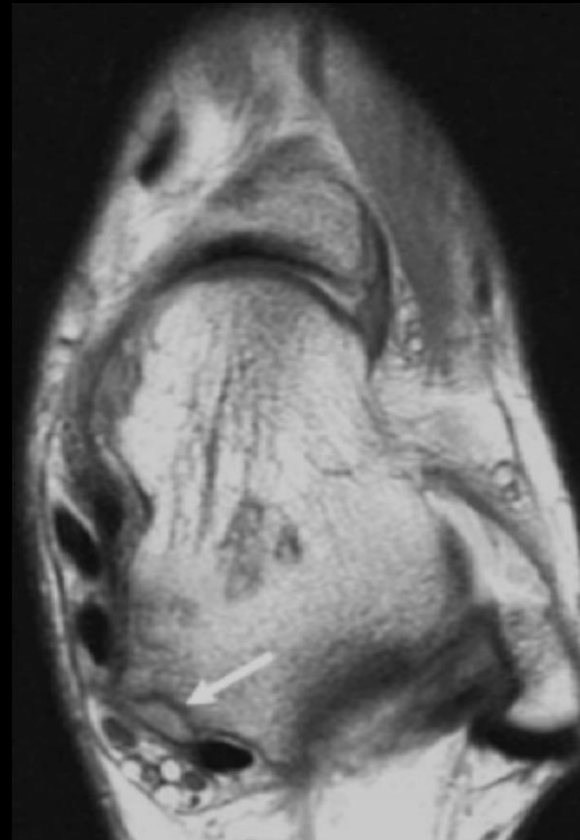
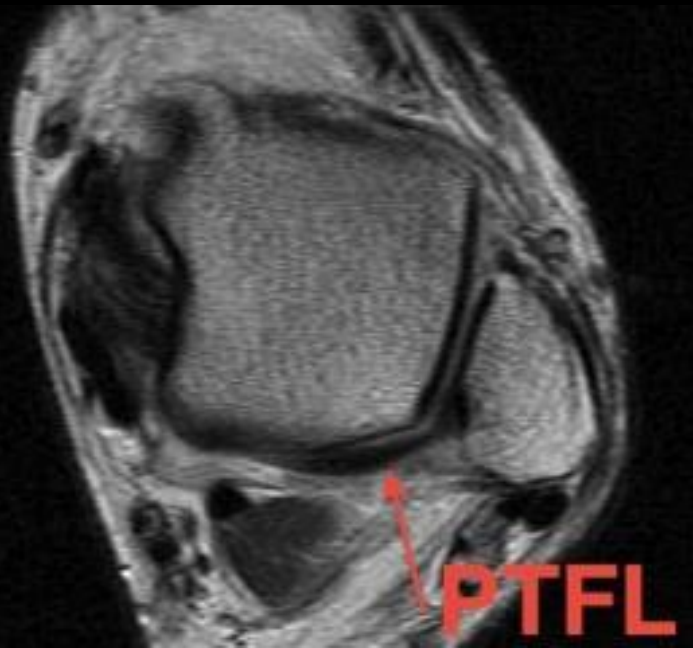Posterior Process Fracture

- Involve the lateral tubercle more than the medial tubercle
- Forced plantar flexion, leading to compression of the posterior process between the tibia and calcaneus.
- Also direct trauma to the posterior ankle.

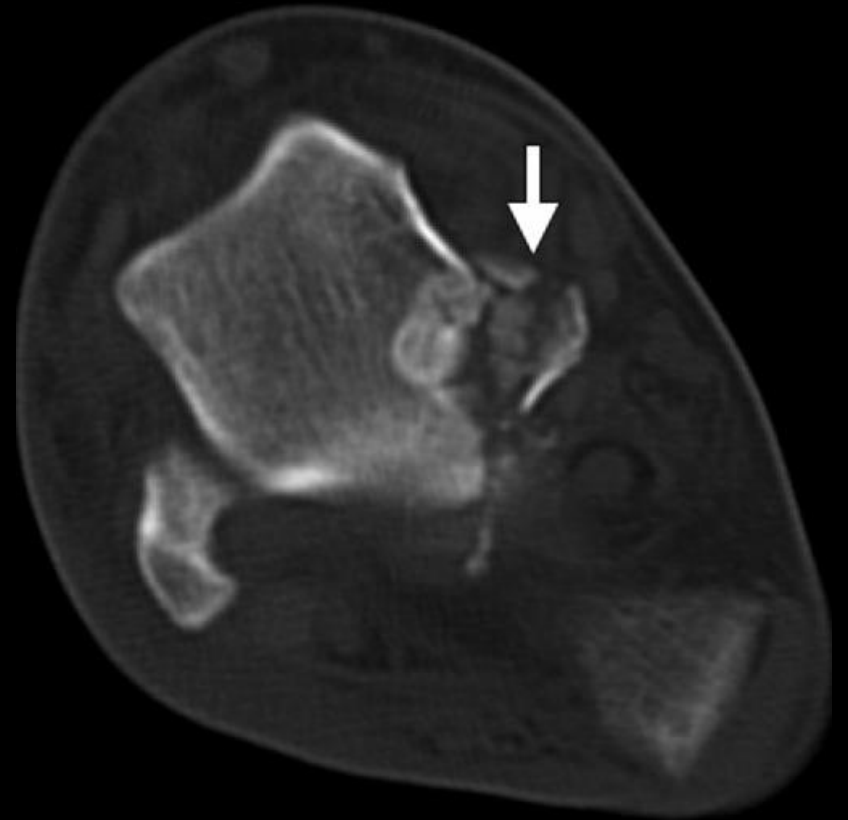
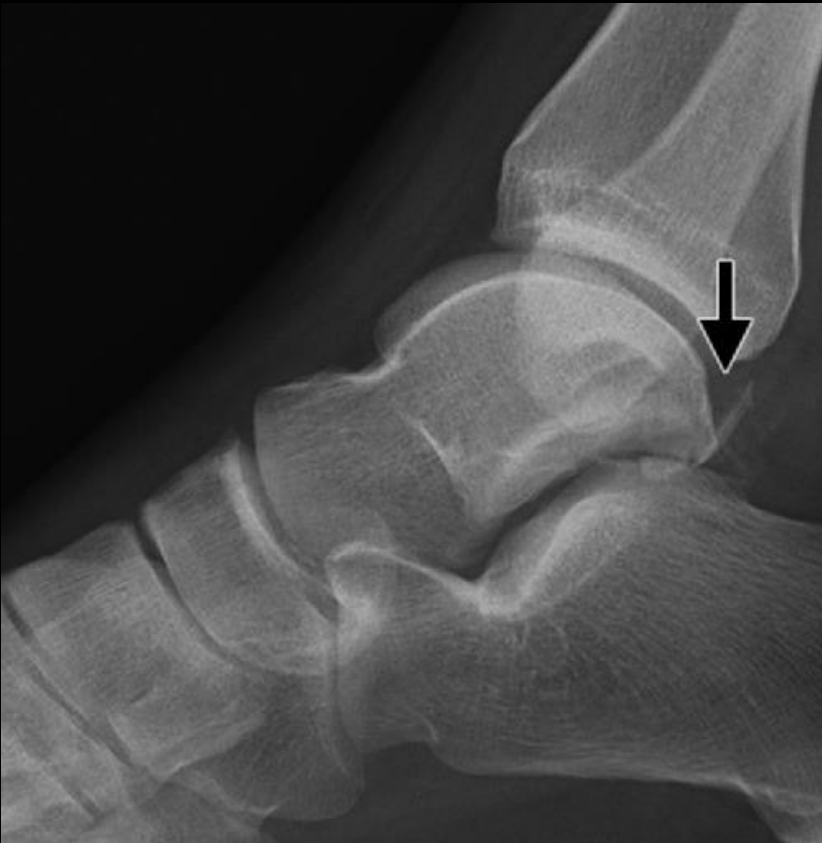ANATOMY OF THE TALUS



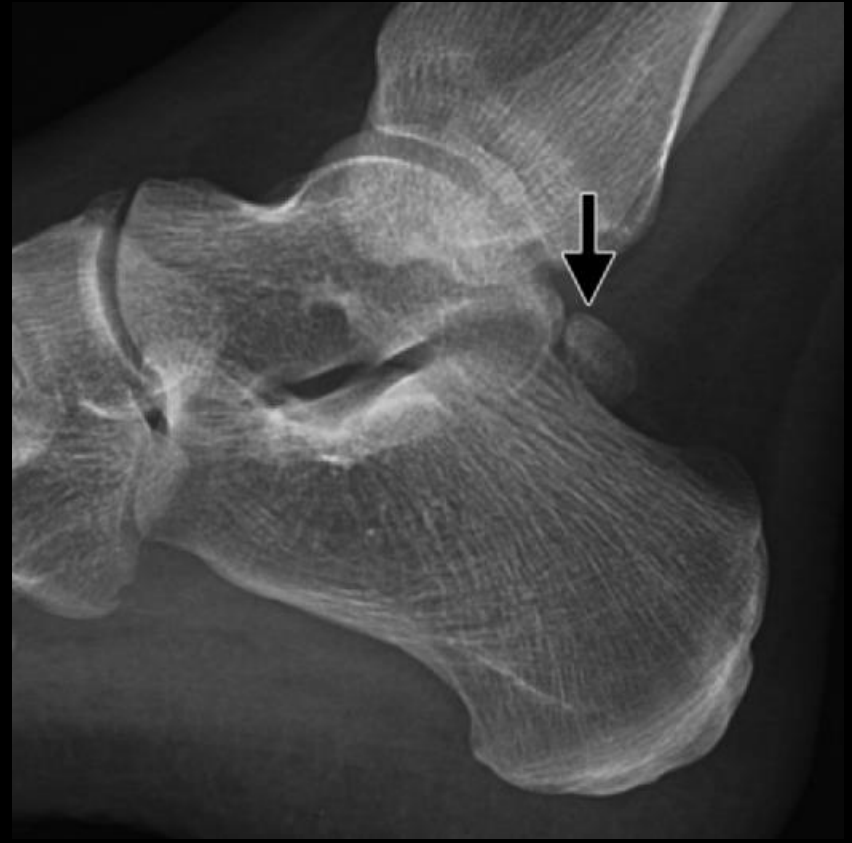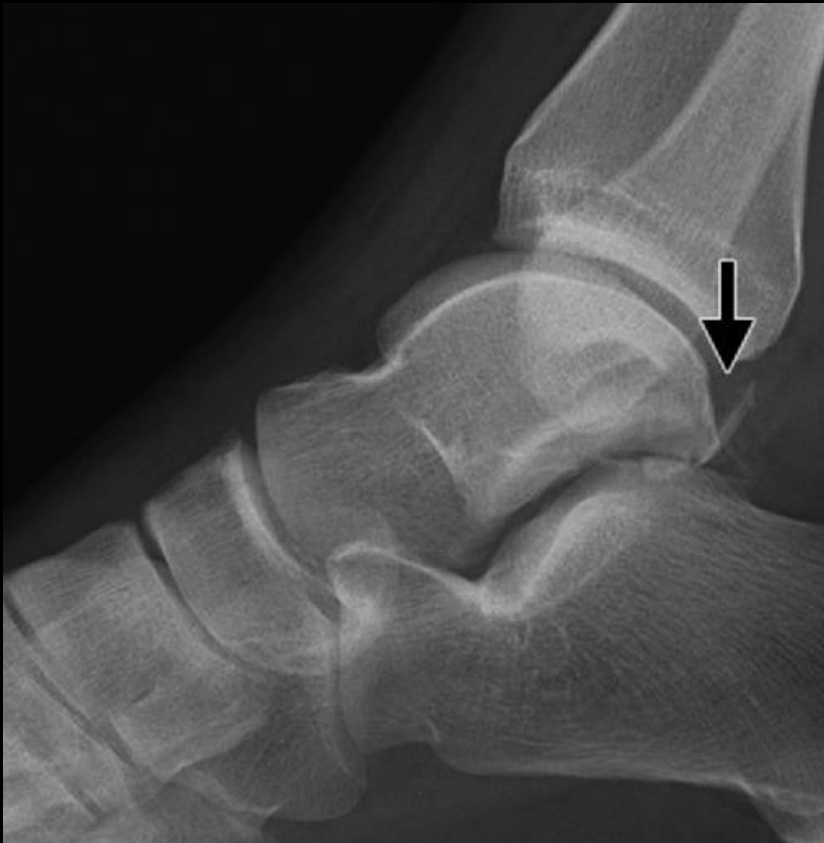Posterior medial tubercle fracture (Cedell Fracture) (Uncommon)



Posterior Process Fracture



Posterior Process Fracture



References

- Daftary A, Haims AH, Baumgaertner MR. Fractures of the calcaneus: a review with emphasis on CT. *RadioGraphics* 2005;25(5):1215–1226.
- Furey A, Stone C, Squire D, Harnett J. Os calcis fractures: analysis of interobserver variability in using Sanders classification. *J Foot Ankle Surg* 2003;42(1):21–23.7.
- Gray H. *Anatomy of the human body*. Philadelphia, Pa: Lea & Febiger, 1918; Bartelby.com; 2009.
- Soeur R, Remy R. Fractures of the calcaneus with displacement of the thalamic portion. *J Bone Joint Surg Br* 1975;57(4):413–421.
- Germann CA, Perron AD, Miller MD, Powell SM, Brady WJ. Orthopedic pitfalls in the ED: calcaneal fractures. *Am J Emerg Med* 2004;22(7):607–611.
- Berry GK, Stevens DG, Kreder HJ, McKee M, Schemitsch E, Stephen DJ. Open fractures of the calcaneus: a review of treatment and outcome. *J Orthop Trauma* 2004;18(4):202–206.
- Heier KA, Infante AF, Walling AK, Sanders RW. Open fractures of the calcaneus: soft-tissue injury determines outcome. *J Bone Joint Surg Am* 2003; 85-A(12):2276–2282.
- Nicklebur S, Dixon T, Probe R. Calcaneus fractures: eMedicine orthopedic surgery. <http://emedicine.medscape.com/article/1232246-overview>. Published October 1, 2009. Accessed May 2010.
- Richman JD, Barre PS. The plantar ecchymosis sign in fractures of the calcaneus. *Clin Orthop Relat Res* 1986;(207):122–125.
- Benson E, Conroy C, Hoyt DB, et al. Calcaneal fractures in occupants involved in severe frontal motor vehicle crashes. *Accid Anal Prev* 2007;39(4):794–799.
- Melinevski et al

