



# New and Improved Orthopedic Hardware for the 21st Century: Part 2, Lower Extremity and Axial Skeleton

Jonelle M. Petscavage<sup>1,2</sup>  
 Alice S. Ha<sup>1</sup>  
 Leila Khorashadi<sup>1,3</sup>  
 Kiley Perrich<sup>1,4</sup>  
 Felix S. Chew<sup>1</sup>

**Keywords:** arthroplasty, musculoskeletal imaging, orthopedic hardware, radiography

DOI:10.2214/AJR.10.5354

Received July 18, 2010; accepted after revision December 15, 2010.

<sup>1</sup>Department of Radiology, University of Washington Medical Center, Seattle, WA.

<sup>2</sup>Present address: Department of Radiology, Penn State Hershey Medical Center, 500 University Dr, Hershey, PA 17033. Address correspondence to J. M. Petscavage (jpetscavage@hmc.psu.edu).

<sup>3</sup>Present address: Schatzki Associates, Cambridge, MA.

<sup>4</sup>Present address: Radiology Associates of Hawaii, Honolulu, HI.

**WEB**  
 This is a Web exclusive article.

**CME/SAM**  
 This article is available for CME/SAM credit. See www.arrs.org for more information.

AJR 2011; 197:W434–W444

0361–803X/11/1973–W434

© American Roentgen Ray Society

**OBJECTIVE.** The purpose of this article is to provide a survey of new orthopedic products for use in the lower extremity and axial skeleton.

**CONCLUSION.** Knowledge of the physiologic purpose, orthopedic trends, imaging findings, and complications is important in assessing new orthopedic devices.

**N**umerous new orthopedic products are being developed for fracture fixation, arthrodesis, and arthroplasty. Keeping up with the latest and commonly used hardware technology is imperative homework for radiologists. Providing an eloquent, detailed description of orthopedic hardware and related complications is an essential part of interpreting musculoskeletal radiology studies and is more important than merely reporting the manufacturer name for a particular construct. This article will provide a survey of some of the more commonly used and newer orthopedic devices used in the axial skeleton and lower extremity over the past 5 years.

## Hardware Complications

A solid understanding of the common types of hardware complications is necessary before starting this review of newer orthopedic hardware. The hardware itself can fracture, disengage if there are multiple components, or loosen. Because of differences in stress distribution after hardware fixation, periprosthetic fractures are also possible. Some hardware materials introduce specific complications: Silicone is associated with silicone synovitis; polyethylene, with asymmetric wear and small-particle disease; and metal-on-metal designs, with higher rates of metallosis and lymphocytic reactions. Thus, knowledge of component design and material composition of the hardware is important for predicting and understanding complications.

## Ankle and Foot

Traditionally, arthrodesis, resection arthroplasty, and silicone arthroplasty have been

used for the treatment of metatarsophalangeal or interphalangeal joint arthritis. Resurfacing hemiarthroplasty (Figs. 1 and 2) and nonconstrained total metatarsophalangeal joint arthroplasty (Fig. 3) are newer options. The hardware is composed of metal or pyrolytic carbon and requires intact ligaments and tendons to maintain range of motion and transfer force away from the bone and hardware [1]. The most frequent complications include loosening, loss of motion in the axial and sagittal planes, subsidence, and implant dislocation.

For patients with pain from subtalar arthritis or hyperpronation or for pediatric patients with pes valgus, the sinus tarsi interference screw provides a new low-trauma option with a short recovery time [2] (Fig. 4). The newest implant design can be placed with an incision that is less than 1 inch long (2.5 cm) in approximately 10 minutes, thus causing little soft-tissue injury. No postoperative casting is required and activity can resume in 2–5 weeks compared with a 10- to 14-week minimum with standard arthrodesis. Screws are partially or fully threaded and are composed of metal, high-molecular-weight polyethylene, or bioabsorbable materials such as poly-L-lactide acid and polyglycolide acid. Over time, there should be fibrous soft-tissue ingrowth around and, if hollow-centered, into the center of the screw for stability and fixation. When there is insufficient ingrowth around the screw, the screw can completely back out or can be extruded if cervical ligaments are left intact (Fig. 5). Other specific complications include fracture, particle disease, injury to sinus tarsi ligaments, and decreased foot supination.

The TightRope Syndesmosis Repair Kit (Arthrex) with FiberWire (Arthrex) sutures is a

new orthopedic device to treat ankle fractures with tibiofibular joint syndesmotom injury [3]. The main advantage is that the TightRope allows fixation with some motion under tension, whereas plate-and-screw fixation does not. On radiographs, a drilled radiolucent track will be visualized parallel to the tibial plafond with EndoButtons (Smith & Nephew) along the lateral fibular and medial tibial cortices (Fig. 6). EndoButtons should be flush against the cortex with no widening of the syndesmosis over time or development of soft-tissue granulomatous masses adjacent to the EndoButtons. Adjacent to the EndoButtons, granulomatous masses will appear as soft-tissue densities on radiography and CT (isodense to muscle).

The Agility Total Ankle Arthroplasty (DePuy Orthopaedics) is the oldest total ankle arthroplasty in use, with the first version introduced in 1992 and the most recent version approved by the U.S. Food and Drug Administration (FDA) in 2005 [4] (Fig. 5). Several newer arthroplasty designs are available, including the Scandinavian Total Ankle Replacement (STAR Ankle, Small Bone Innovations) system in 2009 (Fig. 7), Salto Talaris Total Ankle (Tornier) in 2006, and INBONE Total Ankle (Wright) in 2005 (Fig. 8). The STAR is the only mobile-bearing, uncemented, nonconstrained design with no locking mechanism between the components [5]. A metal wire indicates the location of the polyethylene inlay. The Salto Talaris arthroplasty has a semiconstrained design and tibial component plug to secure the implant to bone. The INBONE is also a semiconstrained design but has a long tibial stem to decrease load on the polyethylene component. This design has the largest surface area of all ankle arthroplasty systems.

Potential complications of all total ankle arthroplasty designs include fracture, loosening, subsidence, particle disease, secondary osteoarthritis, syndesmotom nonunion, and polyethylene cysts (Fig. 9).

Arthrodesis is an alternative to foot and ankle arthroplasty. Different types of pins, wires, and staples are available. Memory Staples (DePuy), made of nitinol, are heat-activated by electrical cautery (Fig. 8). This new hardware leads to faster bony fusion and patient ambulation [6]. Potential complications include staple fracture, staple loosening, or nonunion.

### Knee

Bioabsorbable hardware is being used more frequently in the knee. The SmartNail (ConMed Linvatec) is a strong radiolucent

implant used for repair of fractures or osteochondral lesions [7] (Figs. 10A and 10B). The nail has a flat head to provide more compression across the fracture. After healing is completed, a second surgery is not required to remove the hardware.

Bioabsorbable interference screws are being used instead of metal tibial interference screws for anterior cruciate ligament graft reconstruction (Figs. 10C and 10D). Advantages include no artifact on future MRI, decreased stress on the allograft, and no need for hardware removal before revision surgery, unlike titanium screws that require both removal and bone loss [8]. Complications reported unique to these screws include fracture with subcutaneous migration, fracture with intraarticular migration and chondral injury, sterile drainage and joint effusions, lack of complete osseous ingrowth, and pretibial cyst formation [9].

### Hip and Pelvis

Resurfacing hip arthroplasty is a new option for young patients with inflammatory or posttraumatic arthritis or avascular necrosis. The technique is advocated less for patients older than 60 years in the orthopedic literature because a conventional hip replacement in older patients will likely last the rest of their lifetime. In younger patients, resurfacing arthroplasty preserves the femoral neck bone stock for future revision total hip arthroplasty. However, there is a 1–4% incidence of femoral neck fracture. This complication is believed to occur because of mechanical factors of component notching on the femoral neck, varus neck alignment, heavy impaction and large cysts in the head and neck, and underlying osteoporosis. Additionally, osteonecrosis of the femoral head can develop in resurfacing arthroplasty, possibly from damage to extraosseous blood vessels and intraoperative hypoxemia, and increases the risk of fracture of the femoral neck [10]. On radiographs, a vertical fracture line or a line extending from the femoral head obliquely to the metal femoral peg may be seen. Both total resurfacing arthroplasty and hemiresurfacing arthroplasty designs are available (Fig. 11A).

There has also been a resurgence of metal-on-metal designs of total hip arthroplasty partly in response to failure of total hip arthroplasty primarily from polyethylene wear (Fig. 11B). The new design has a larger femoral head component, greater than 36 mm, to increase range of motion at the hip

joint. Synovial joint fluid acts as the lubrication between the two metal components. The advantages of the metal-on-metal design are lower frequency of hip dislocations, less wear and inflammation from polyethylene particles, and larger range of motion [11]. However, there are reports of increased metal ion levels in blood and urine, metal-wear debris resulting in osteolysis, metal wear inciting either a delayed hypersensitivity reaction or lymphocytic infiltration of the joint and of pseudotumors after metal-on-metal hip arthroplasty [11].

### Thorax

Traditionally, treatment of flail chest has consisted of internal pneumatic splinting and long periods of mechanical ventilation. Rib plating using metal or bioabsorbable materials is a new option, with preliminary positive results of fewer days in the ICU, shorter duration of mechanical ventilation, lower incidence of pneumonia, and better pulmonary function at 1 and 6 months after the procedure [12]. Rib plates can also be used to treat fracture nonunion and to repair osteotomy fractures. One design is a locking mechanism, which allows less stress on the bone-hardware interface and angulation of screws (Fig. 12A). Alternatively, the RibLoc Rib Fracture Plating System (Acute Innovations) design consists of U-shaped titanium metal plates that are shorter than the single-surface plates (Synthes Locking Compression System, Synthes) to provide more stability and to support the fracture on three surfaces (Fig. 12B). Reported complications include superficial wound drainage with or without infection, hematoma, plate loosening, chest wall stiffness, and pain requiring plate removal [12].

Sternal wires have been the mainstay hardware for median sternotomy. The Sternal Talon (KLS Martin) is a new double hook device that provides firm fixation and does not rely on the quality of underlying bone. Early sternal dehiscence and infection are thought to be related to lack of wire fixation in patients with osteoporosis, diabetes, or obesity. Firm plate closure with the Talon—despite poor bone stock or quality—may result in a lower risk of dehiscence and of mediastinitis than closure with sternal wires [13] (Figs. 13A and 13B). The hook (Sternal Talon) pulls both sides of the sternum together using a ratchet mechanism that is locked in place by a screw on the anterior surface of the device.

Sternal locking plates have also been shown to provide greater stability for sternal closure

alone or with sternal wires [14] (Fig. 13C). Reported complications unique to plates include screw loosening and delayed (> 6 weeks) postoperative sterile sternal dehiscence.

### Spine

New disk prostheses are available for isolated cervical and lumbar degenerative disk disease. The ProDisc-C and ProDisc-L (Synthes) are semiconstrained ball-and-socket–designed disk replacements bridged by an articular surface polyethylene inlay [15] (Figs. 14A and 14B). The disks do not independently translate and have a low-profile design, meaning that they do not project beyond the anterior vertebral body. Thus the disk prosthesis has no contact with either the posterior or anterior ligaments, so there is less soft-tissue irritation. The Charité arthroplasty design (Charité Artificial Disc, DePuy) (Fig. 14C) also consists of a polyethylene inlay and metal endplates with small spikes for stability. However, the inlay is not fixed to the endplates; instead, it is held in place by compressive forces. On radiographs, the polyethylene inlay is surrounded by metal wire. For both the ProDisc and Charité designs, due to polyethylene inlay, polyethylene wear and particle disease are potential complications in addition to vertebral body fractures and anterior dislocation of the metal disks.

Alternative types of lumbar disk hardware include the Maverick Artificial Disc (Medtronic Spinal) and Kineflex Lumbar Artificial Disc (SpinalMotion) designs. The Maverick prosthesis has a ball-and-socket design but no polyethylene inlay [16] (Fig. 14D). A keel attaches to the vertebral body to enhance stabilization.

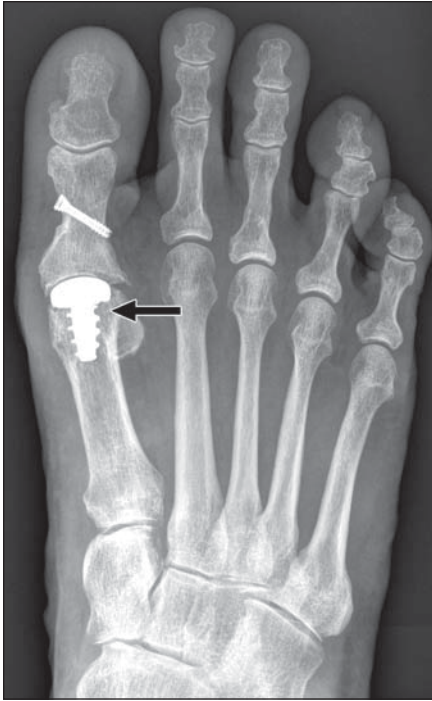A final new hardware used around the spine is X-STOP (Medtronic), the only FDA-approved interspinous process distraction device (Fig. 15). Interspinous process distraction devices are indicated in patients with lumbar spinal stenosis related to disk degenerative or facet joint arthritis, particularly those with symptoms relieved in flexion. The X-STOP is a titanium device inserted in an outpatient setting. It fits between contiguous spinous processes to limit pathologic extension that can compress nerves [16].

In conclusion, knowledge of the purpose, design, material components, and normal radiographic appearance is important for radiologists to keep pace with new developments of orthopedic hardware.

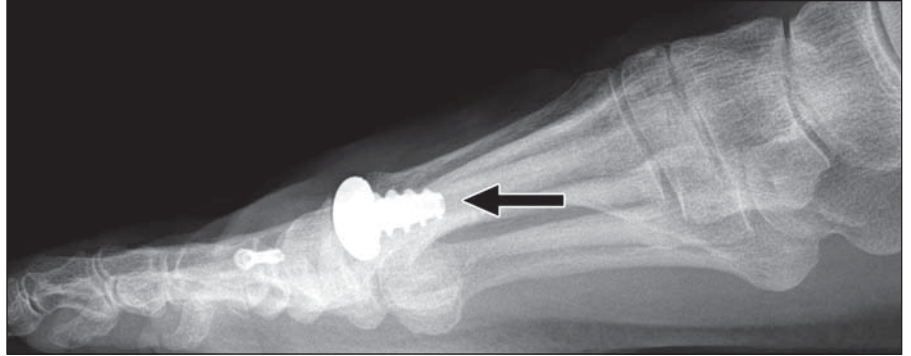
### References

1. Fuhrmann RA. MTP prosthesis (ReFlexion) for hallux rigidus. *Tech Foot Ankle Surg* 2005; 4:2–9
2. Becker A. A closer look at an emerging sinus tarsi implant. *Podiatry Today* 2007; 20:103
3. Petscavage J, Perez F, Khorashadi L, Richardson ML. Tightrope walking: a new technique in ankle syndesmosis fixation. *Radiology Case Reports [Online]* 2010; 5:354
4. Talijanovic MS, Hunter TB, Miller MD, Sheppard JE. Gallery of medical devices. Part I. Orthopedic devices for the extremities and pelvis. *RadioGraphics* 2005; 25:859–870
5. Bestic JM, Peterson JJ, DeOrio JK, Bancroft LW. Postoperative evaluation of the total ankle arthroplasty. *AJR* 2008; 190:1112–1123
6. Malal JJG, Kumar CS. The use of Memory staples in foot and ankle surgery. *J Bone Joint Surg Br* 2008; 90(suppl II):231
7. ConMed Linvatec Website. Fixation implants: SmartNail 2.4mm. [www.conmed.com/products\\_knee\\_fixation.php#smartnail](http://www.conmed.com/products_knee_fixation.php#smartnail). Accessed July 18, 2010
8. Purcell DB, Rudzki JR, Wright RW. Bioabsorbable interference screws in ACL reconstruction. *Oper Tech Sports Med* 2004; 12:180–187
9. Sassmannshausen G, Carr CF. Transcutaneous migration of a tibial bioabsorbable interference screw after anterior cruciate ligament reconstruction. *Arthroscopy* 2003; 19:E133–E136
10. Steffen RT, Foguet PR, Krikler SJ, et al. Femoral neck fractures after hip resurfacing. *J Arthroplasty* 2009; 24:614–619
11. Korovessis P, Petsinis G, Repanti M, Repantis T. Metallosis after contemporary metal-on-metal total hip arthroplasty: five- to 9-year follow-up. *J Bone Joint Surg Am* 2006; 88:1183–1191
12. Nirula R, Diaz JJ, Trunkey DD, Mayberry JC. Rib fracture repair: indications, technical issues, and future directions. *World J Surg* 2009; 33:14–22
13. KLS Martin USA Website. Sternal Talon. [www.klsmartinusa.com/Sternal\\_Talon.672.0.html](http://www.klsmartinusa.com/Sternal_Talon.672.0.html). Accessed July 18, 2010
14. Lee JC, Raman J, Song DH. Primary sternal closure with titanium plate fixation: plastic surgery effecting a paradigm shift. *Plast Reconstr Surg* 2010; 125:1720–1724
15. van den Eerenbeemt KD, Ostelo RW, van Royen BJ, Peul WC, van Tulder MW. Total disc replacement surgery for symptomatic degenerative lumbar disc disease: a systematic review of the literature. *Eur Spine J* 2010; 19:1262–1280
16. Brussee P, Hauth J, Donk RD, Verbeek AL, Bartels RH. Self-rated evaluation of outcome of the implantation of interspinous process distraction (X-Stop) for neurogenic claudication. *Eur Spine J* 2008; 17:200–203

## Orthopedic Hardware for the 21st Century

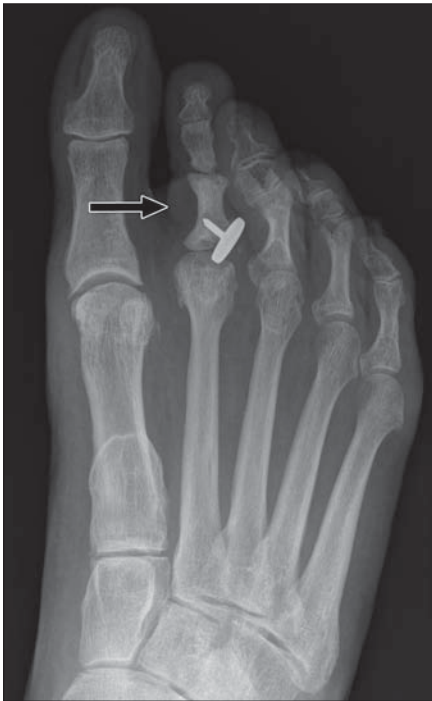

A

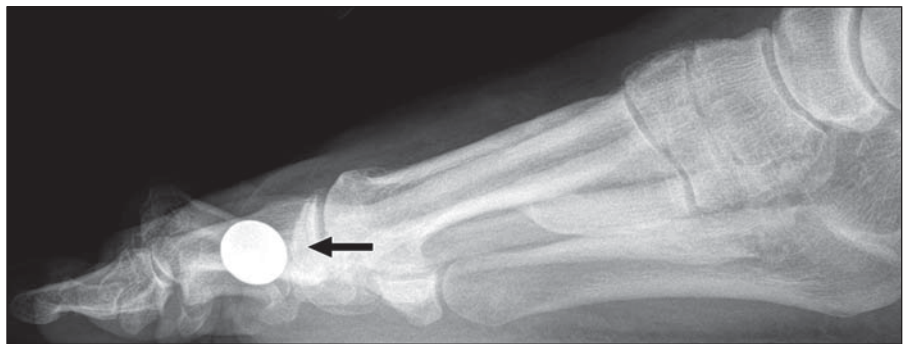

B

**Fig. 1**—Normal resurfacing metatarsophalangeal joint arthroplasty. **A** and **B**, Anteroposterior (**A**) and lateral (**B**) radiographs of right foot show appropriately positioned resurfacing metal arthroplasty (*arrows*) of first metatarsophalangeal joint in 55-year-old man. Also seen are screws within first proximal phalanx from prior osteotomy.



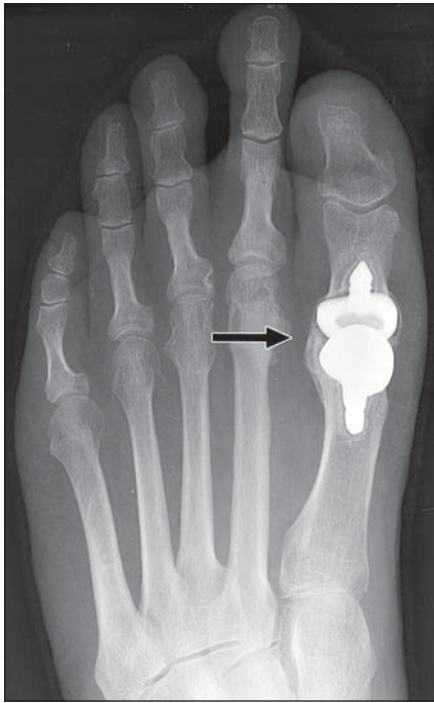
A



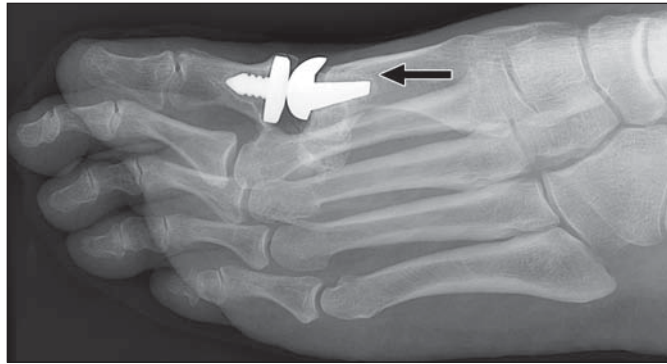
B

**Fig. 2**—Complication of resurfacing metatarsophalangeal arthroplasty. **A** and **B**, Anteroposterior (**A**) and lateral (**B**) radiographs of right foot show dislocation of second metatarsophalangeal joint resurfacing arthroplasty (*arrows*) in 59-year-old woman. There is lucency around stem of arthroplasty consistent with loosening. On lateral view, flat head of resurfacing component is seen *en face* due to dislocation.



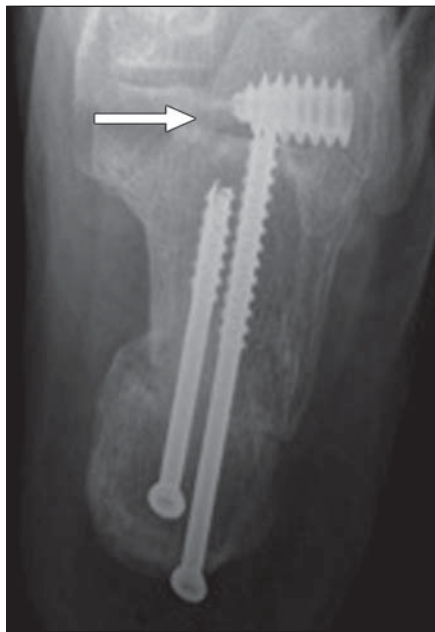

A

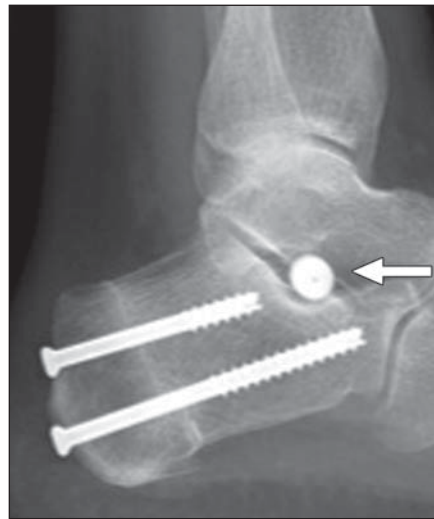


B

**Fig. 3**—Normal total metatarsophalangeal joint arthroplasty. **A** and **B**, Anteroposterior (**A**) and oblique lateral (**B**) radiographs of left foot show nonconstrained total first metatarsophalangeal joint arthroplasty (arrows) in 58-year-old man.



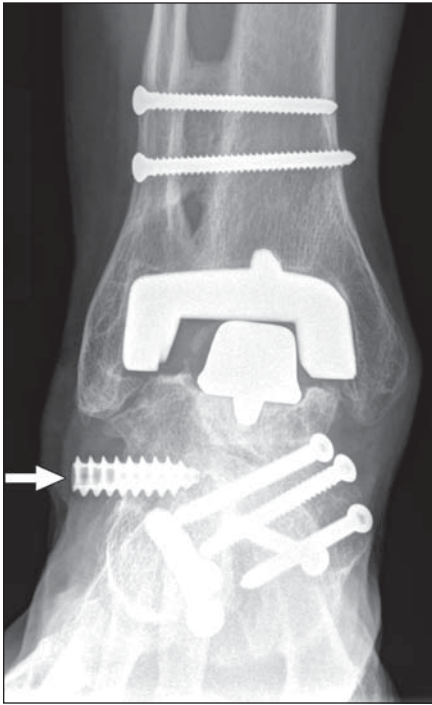
A



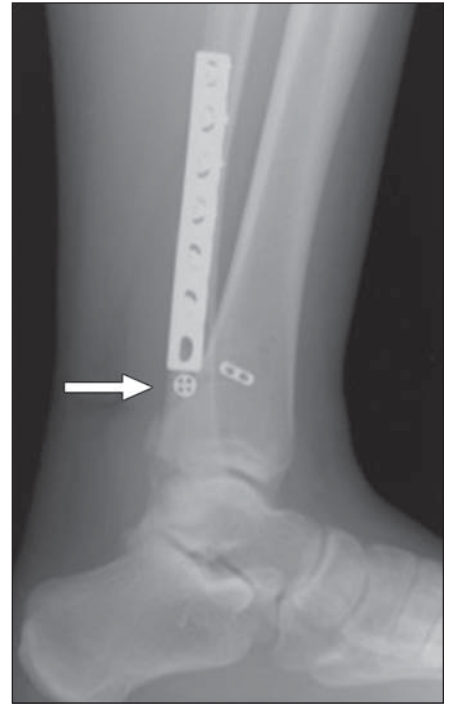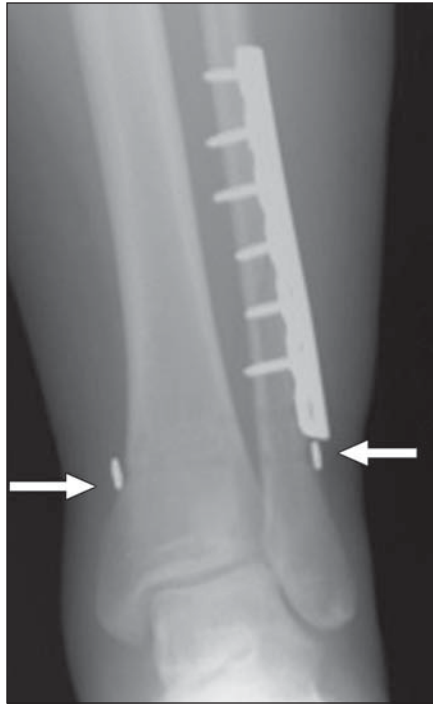
B

**Fig. 4**—Normal interference screw. **A** and **B**, Anteroposterior (**A**) and lateral (**B**) views of calcaneus show fully threaded sinus tarsi interference screw (arrows) in 51-year-old woman. If polyethylene or poly-L-lactide acid material screws are used, there is risk of particle disease and fibrous reaction. Note is made of two screws bridging calcaneal osteotomy.

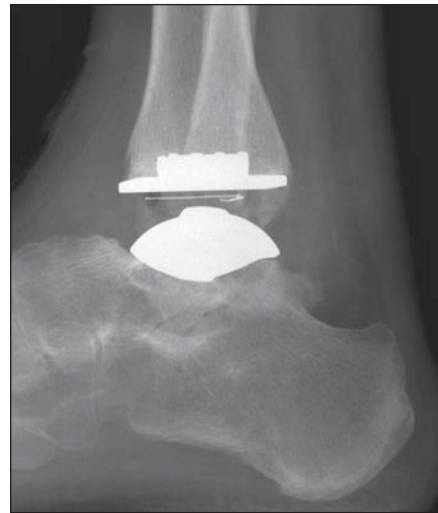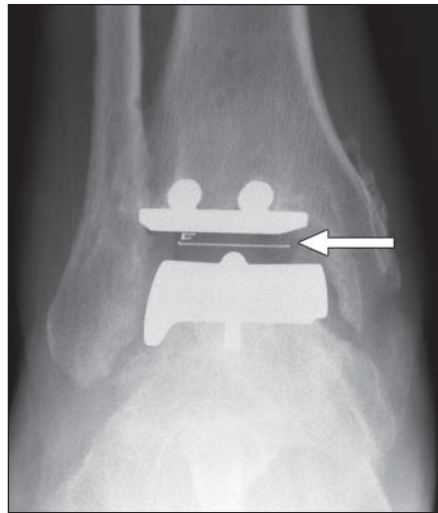
Orthopedic Hardware for the 21st Century



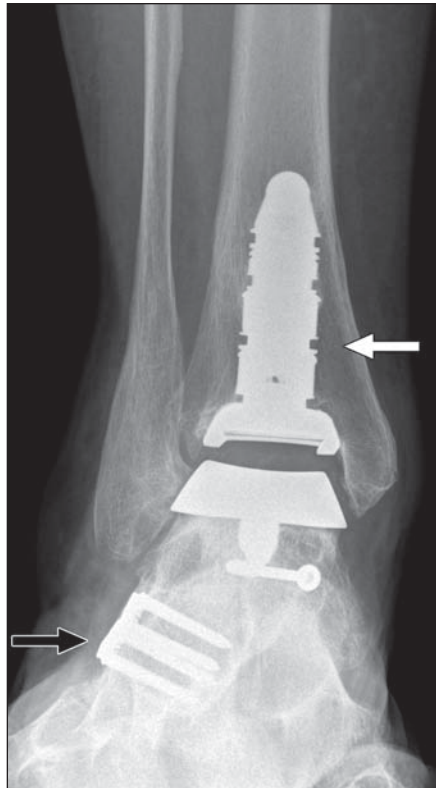
**Fig. 5**—Complication of interference screw. Anteroposterior radiograph of 64-year-old woman shows sinus tarsi interference screw that is backing out into lateral soft tissues (*arrow*). Also seen is Agility Total Ankle Arthroplasty (DePuy Orthopaedics) with subsidence of talar component. Screws are present for syndesmotic fusion, midfoot fusion, and calcaneal osteotomy.



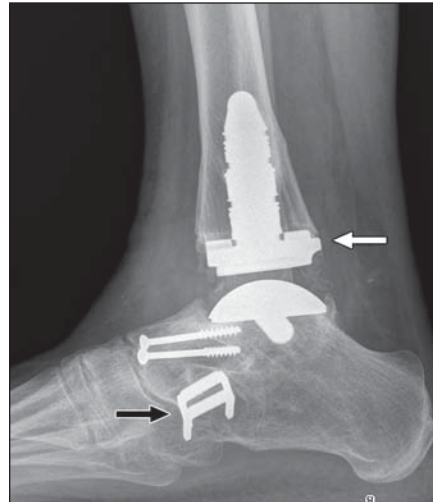
**Fig. 6**—Normal TightRope Syndesmosis Repair Kit (Arthrex). **A** and **B**, Anteroposterior (**A**) and lateral (**B**) radiographs of 21-year-old man show EndoButtons (Smith & Nephew) (*arrows*) along medial tibial and lateral fibular cortices and radiolucent tract of TightRope FiberWire sutures (Arthrex). Plate-and-screw fixation of distal one third of fibular shaft fracture above syndesmosis is also seen and confirms need for FiberWire fixation.



**Fig. 7**—Normal ankle arthroplasty. **A** and **B**, Anteroposterior (**A**) and lateral (**B**) radiographs show Scandinavian Total Ankle Replacement (STAR Ankle, Small Bone Innovations) in 77-year-old woman. This design was approved by U.S. Food and Drug Administration in 2009 and is only unconstrained total ankle system to date. Polyethylene component is indicated by horizontal metal wire (*arrow*, **A**) and is not fixed to either metal tibial or talar components. Inlay is held in place by compressive force.

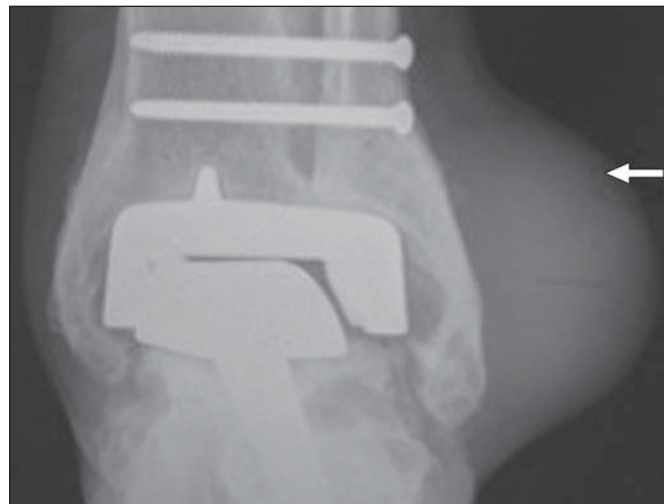


A



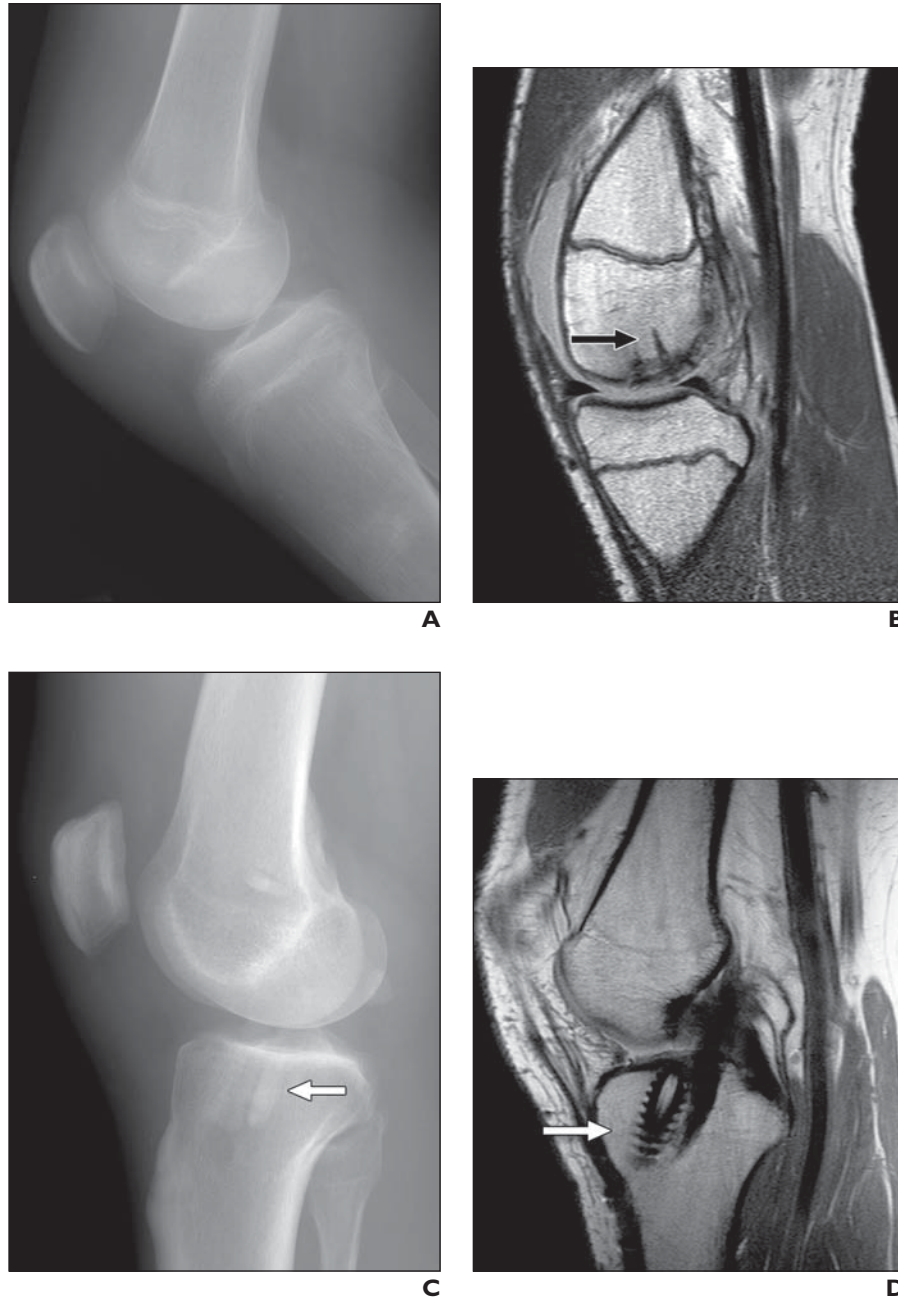
B

**Fig. 8**—Normal ankle arthroplasty and staples. **A** and **B**, Anteroposterior (**A**) and lateral (**B**) radiographs of 62-year-old woman show INBONE Total Ankle (Wright) arthroplasty (*white arrows*) with long tibial stem, metal talar component, and radiolucent polyethylene. Heat-activated staples (*black arrows*) are seen bridging fusion of calcaneocuboid joint. Two screws fuse talonavicular joint.



**Fig. 9**—Complication of ankle arthroplasty. Anteroposterior radiograph of 69-year-old woman with Agility Total Ankle Arthroplasty (DePuy Orthopaedics) with syndesmotic screws shows large soft-tissue mass (*arrow*) adjacent to lateral malleolus. Finding was new since initial postoperative images. Also seen is osteolysis around lateral and medial tibial components and in lateral talus. Findings are consistent with polyethylene wear. Aspiration of soft-tissue mass showed polyethylene-wear cyst, known potential complication of total ankle arthroplasty.

## Orthopedic Hardware for the 21st Century



**Fig. 10**—Normal bioabsorbable knee hardware.

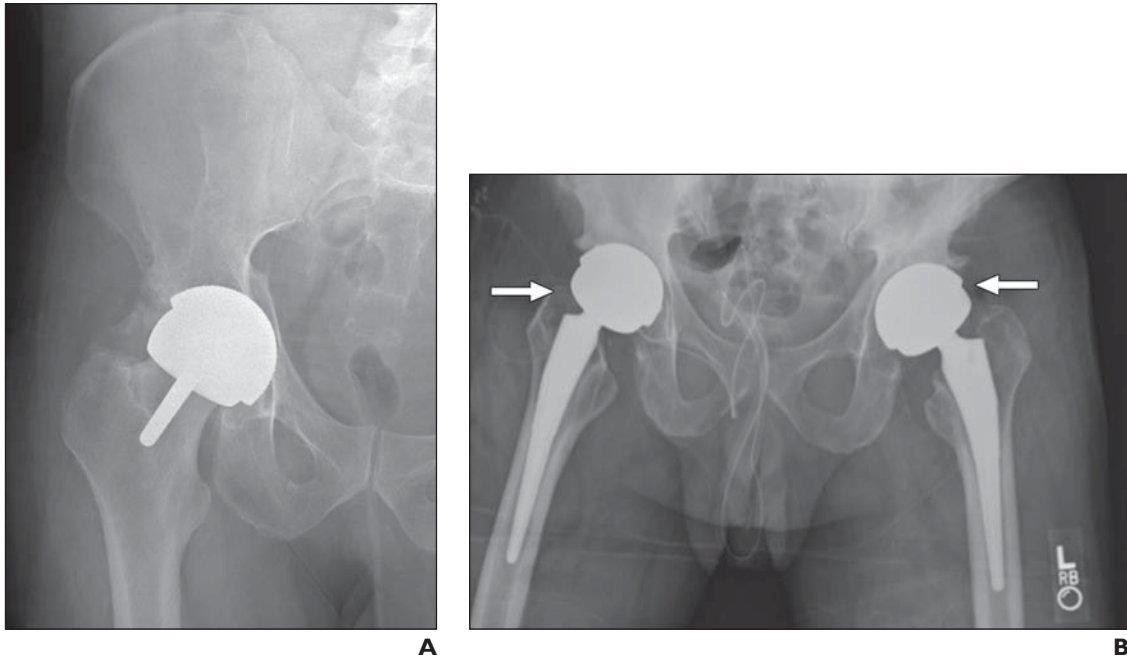
**A**, Lateral radiograph of knee in 17-year-old boy shows no radiodense hardware.

**B**, Sagittal proton density-weighted MR image of same patient's knee shows several linear, low-signal-intensity nails (*arrow*) fixating osteochondral defect of medial femoral condyle. Flat head of nails is flush with condylar cartilage.

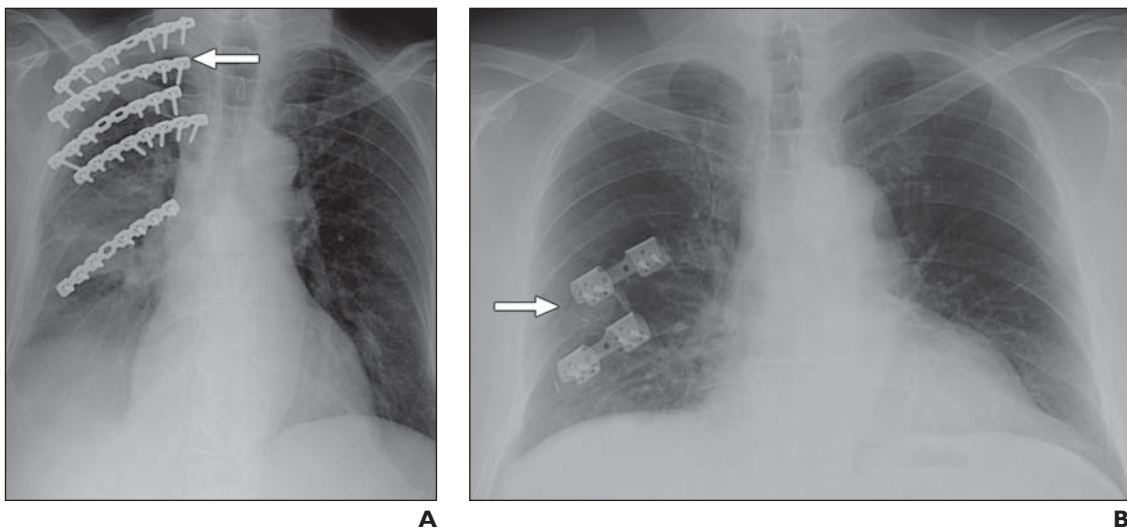
**C**, Lateral radiograph of knee in 35-year-old man shows radiolucent anterior cruciate ligament (ACL) reconstruction graft with nonmetal bioabsorbable tibial interference screw (*arrow*).

**D**, Sagittal proton density-weighted MR image of patient shown in **C** shows low-signal-intensity threads of interference screw (*arrow*) and intact ACL reconstruction graft.



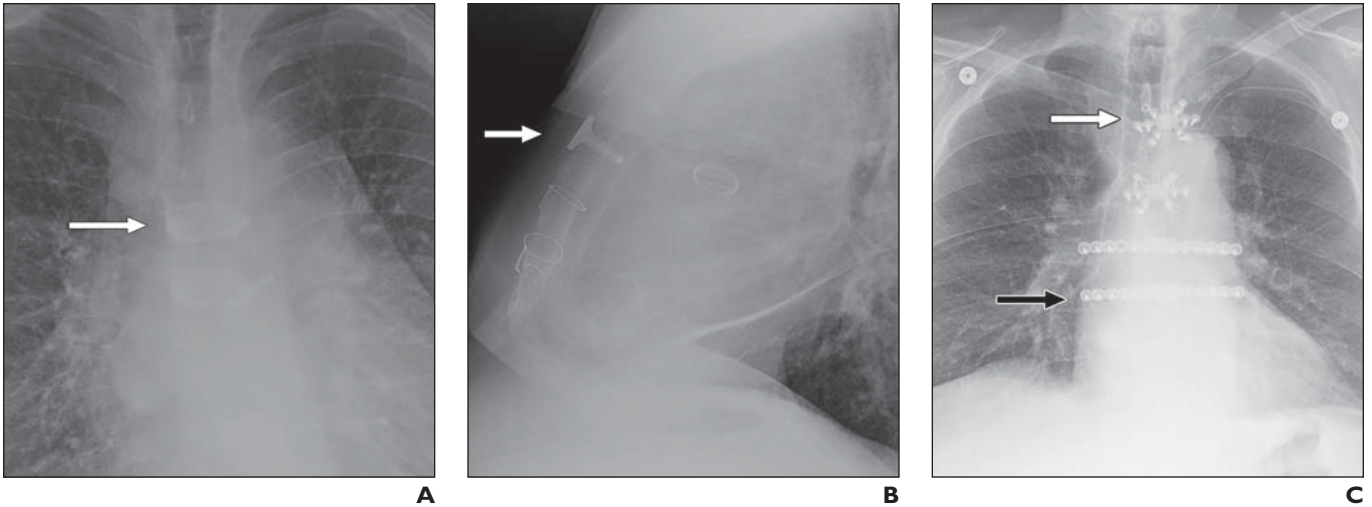


**Fig. 11**—Normal metal-on-metal arthroplasty designs.  
**A**, Anteroposterior radiograph of right hip in 31-year-old man shows total hip resurfacing arthroplasty with metal acetabular cup and metal femoral head cup with femoral neck stem. Resurfacing arthroplasty was placed for prior avascular necrosis of right femoral head.  
**B**, Anteroposterior radiograph of 36-year-old man shows bilateral metal-on-metal total hip arthroplasties (*arrows*). Femoral head components of metal-on-metal design are larger than polyethylene models and appear oversized compared with acetabular cups. This provides greater range of motion at hip joint. Foley catheter overlies pelvis.



**Fig. 12**—Normal rib plates.  
**A**, Anteroposterior radiograph of 64-year-old man shows precontoured locking flexible rib plates (*arrow*) fixating multiple right-sided anterior rib fractures that were causing flail chest.  
**B**, Anteroposterior radiograph of 34-year-old man shows two posterior plates (RibLoc Rib Fracture Plating System, Acute Innovations) (*arrow*) fixating two right rib fractures.

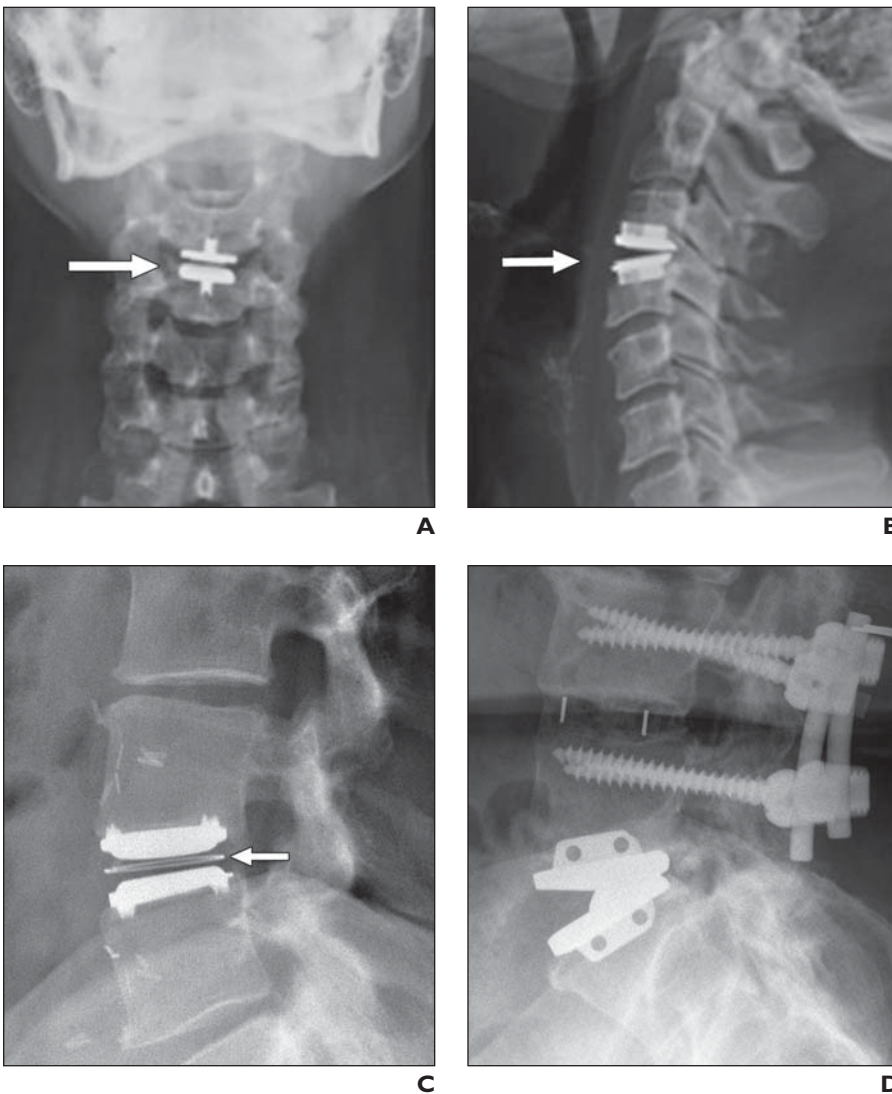
## Orthopedic Hardware for the 21st Century



**Fig. 13**—Normal sternal hardware.

**A and B**, 68-year-old man with history of multiple mediastinal procedures. Anteroposterior (**A**) and lateral (**B**) radiographs of chest show two Sternal Talons (KLS Martin) (arrows) being used for sternal closure. Sternal closure wires and prosthetic cardiac valves are also present.

**C**, 64-year-old woman. Anteroposterior radiograph of chest shows two sternal body locking plates (white arrow) and two rib-to-sternum locking plates (black arrow).

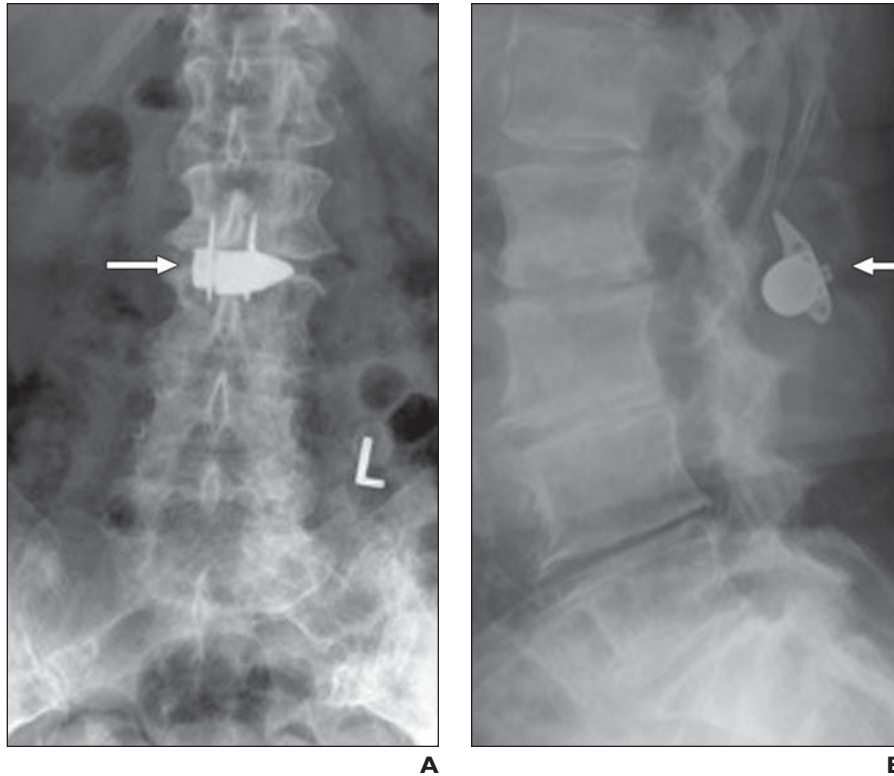


**Fig. 14**—Normal disk arthroplasty.

**A and B**, Anteroposterior (**A**) and lateral (**B**) radiographs of 55-year-old woman show intervertebral disk replacement (ProDisc, Synthes) (arrows) at C3–4.

**C**, Lateral radiograph of 38-year-old man shows artificial disk (Charité Artificial Disc, DePuy) replacement at L4–L5 level. A metal ring (arrow) identifies polyethylene insert, which is not affixed to either metal endplate.

**D**, Lateral radiograph of 39-year-old woman shows artificial disk (Maverick Artificial Disc, Medtronic Spinal) replacement at L5–S1 level. No polyethylene inlay is present in this design. Also present are posterior fusion rods, paired pedicle screws, and intervertebral spacer at L4–L5 level.



**Fig. 15**—Normal interspinous device. **A** and **B**, Anteroposterior (**A**) and lateral (**B**) radiographs of 53-year-old woman with spinal stenosis and radiculopathy show interspinous process distraction device (X-STOP, Medtronic) (*arrows*) between L2 and L3 spinous processes.

#### FOR YOUR INFORMATION

The Self-Assessment Module accompanying this article can be accessed via [www.ajronline.org](http://www.ajronline.org) at the article link labeled "CME/SAM."

The American Roentgen Ray Society is pleased to present these Self-Assessment Modules (SAMs) as part of its commitment to lifelong learning for radiologists. Each SAM is composed of two journal articles along with questions, solutions, and references, which can be found online. Read each article, then answer the accompanying questions and review the solutions online. After submitting your responses, you'll receive immediate feedback and benchmarking data to enable you to assess your results against your peers.

Continuing medical education (CME) and SAM credits are available in each issue of the *AJR* and are **free to ARRS members. Not a member?** Call 1-866-940-2777 (from the U.S. or Canada) or 703-729-3353 to speak to an ARRS membership specialist and begin enjoying the benefits of ARRS membership today!