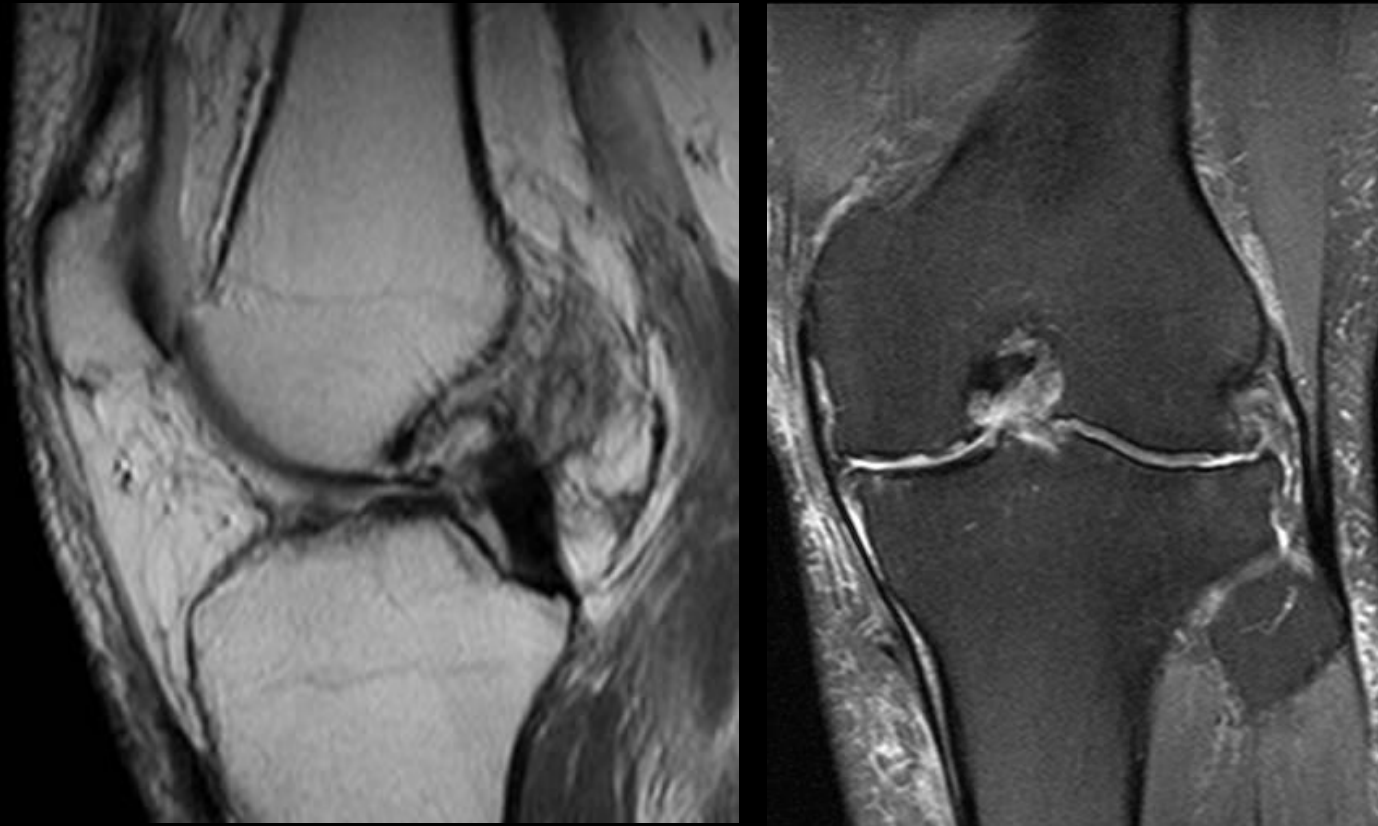

June 8, 2006

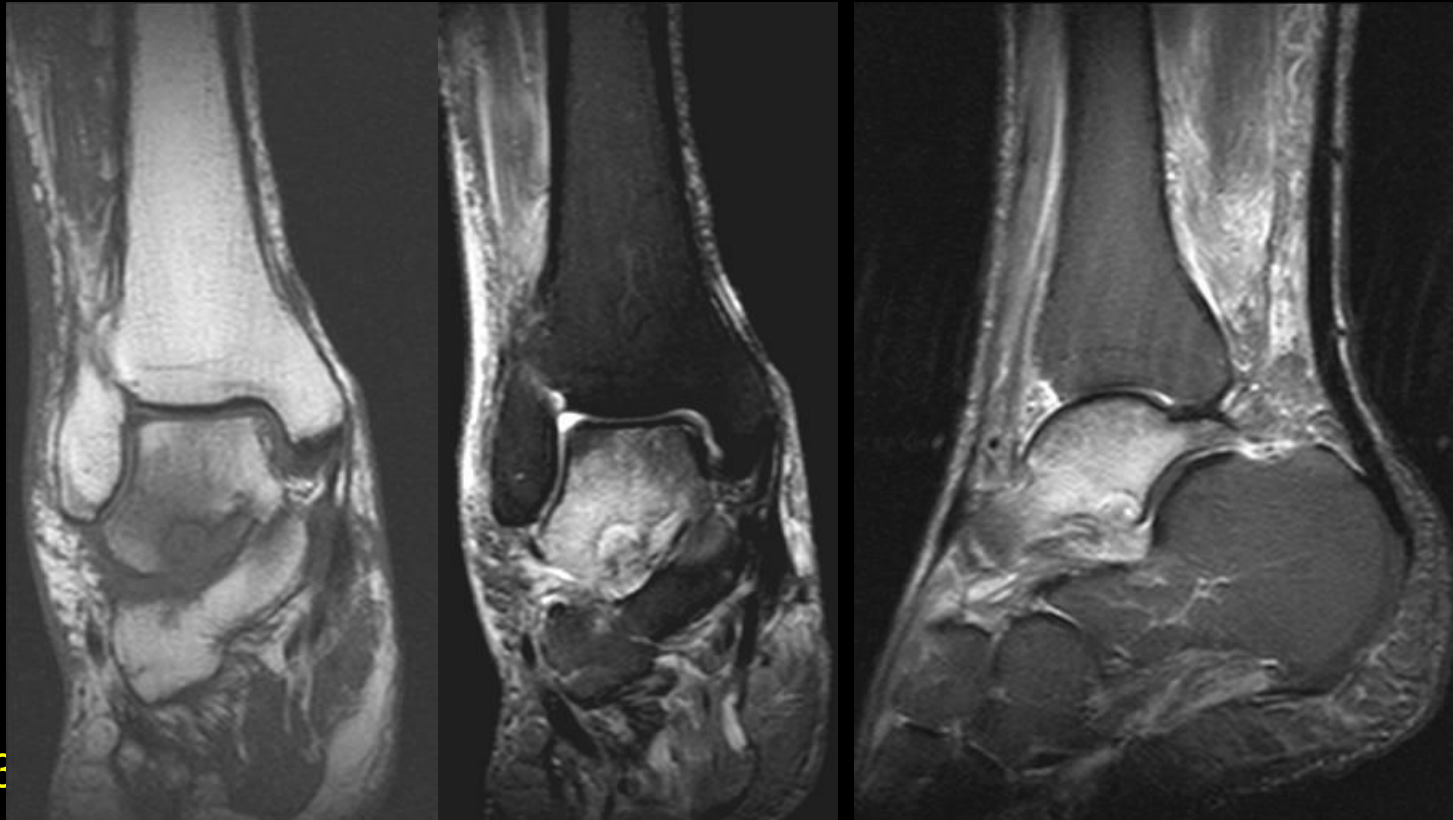
CASE

66 year old woman with chronic ACL tear. Conjoined tendon seen on coronal images.



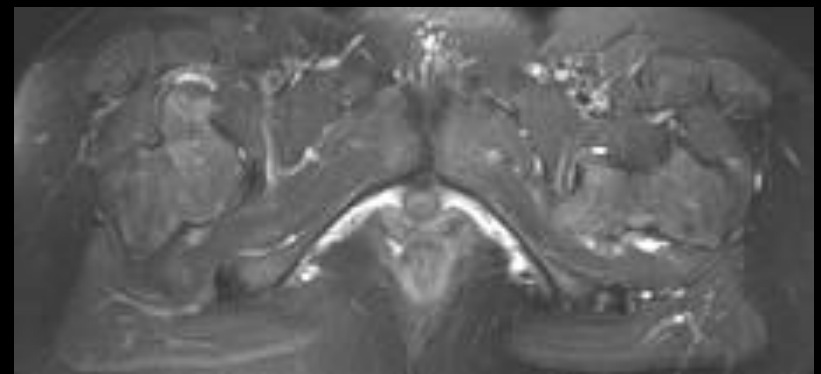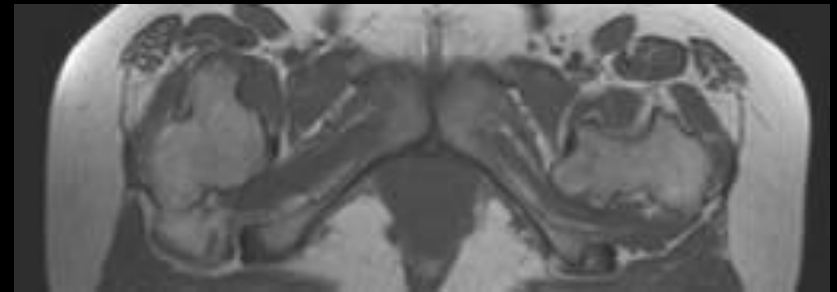
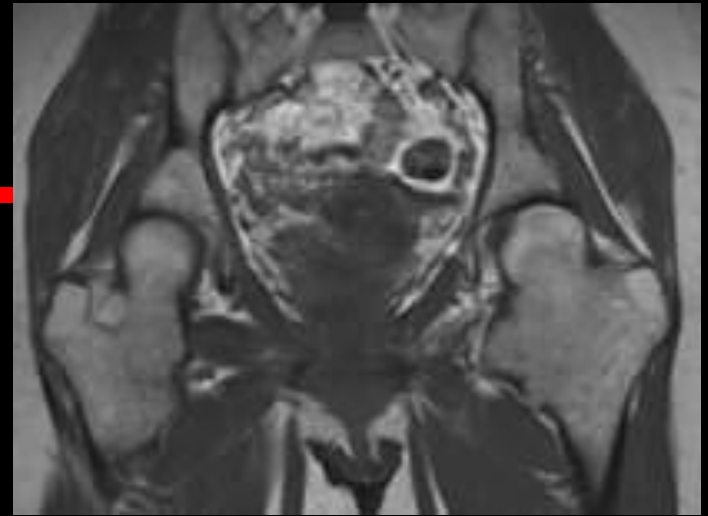
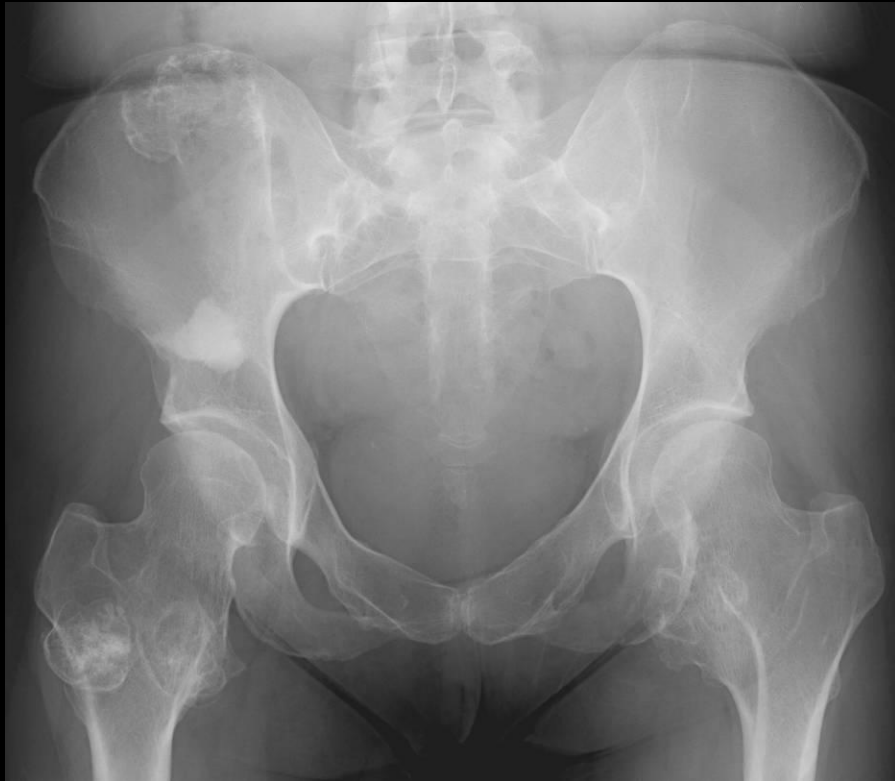CASE

79 year old man with hyperuricemia and gout like symptoms. Initial ankle aspiration (1/13) was negative for crystal. Suspect crystal deposition disease from MR.



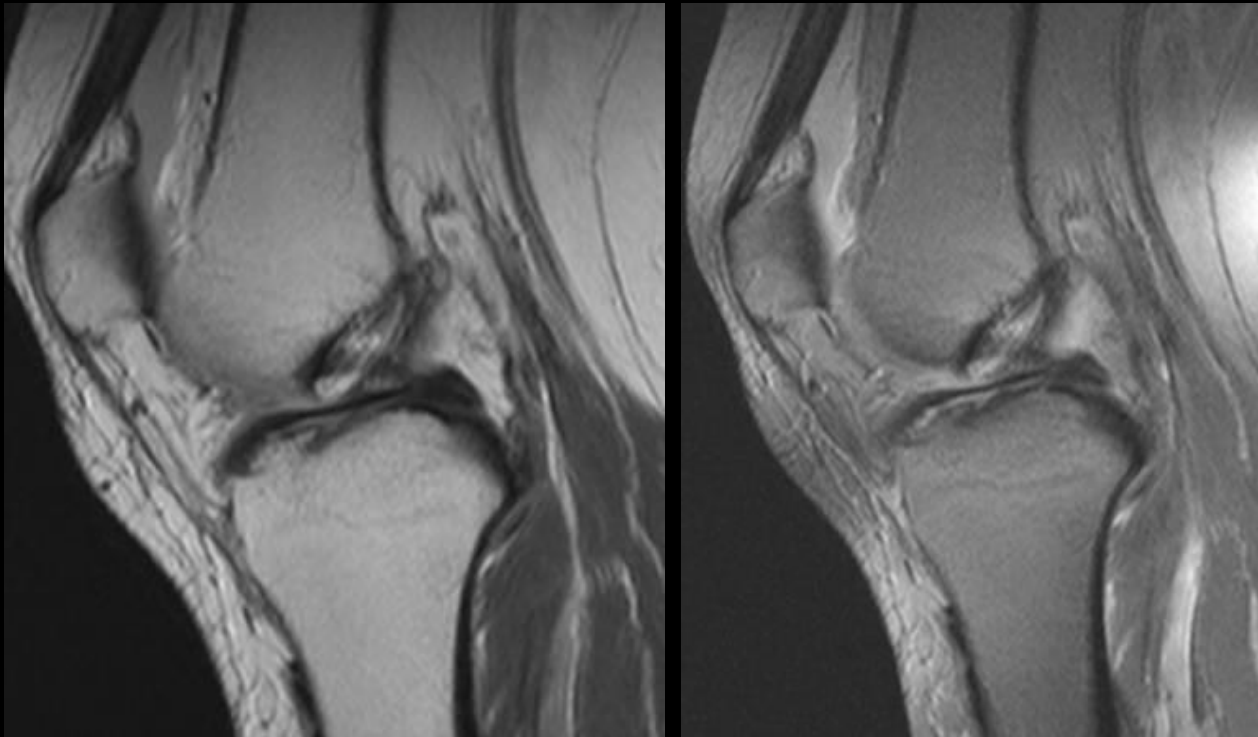
CASE

43 year old woman with hip pain



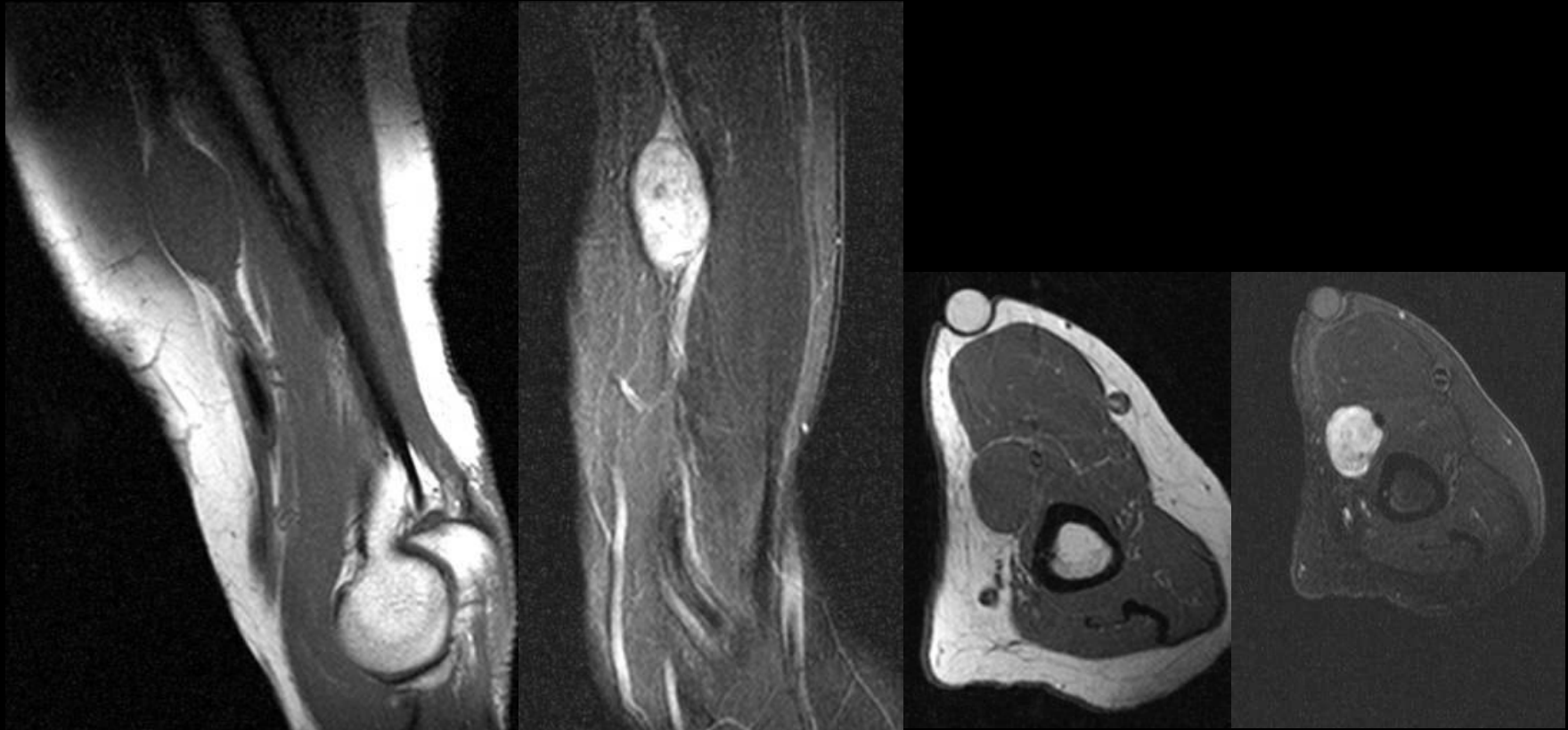
CASE

63 year old woman with knee pain. Nice example of prominent oblique menisco-meniscal ligament



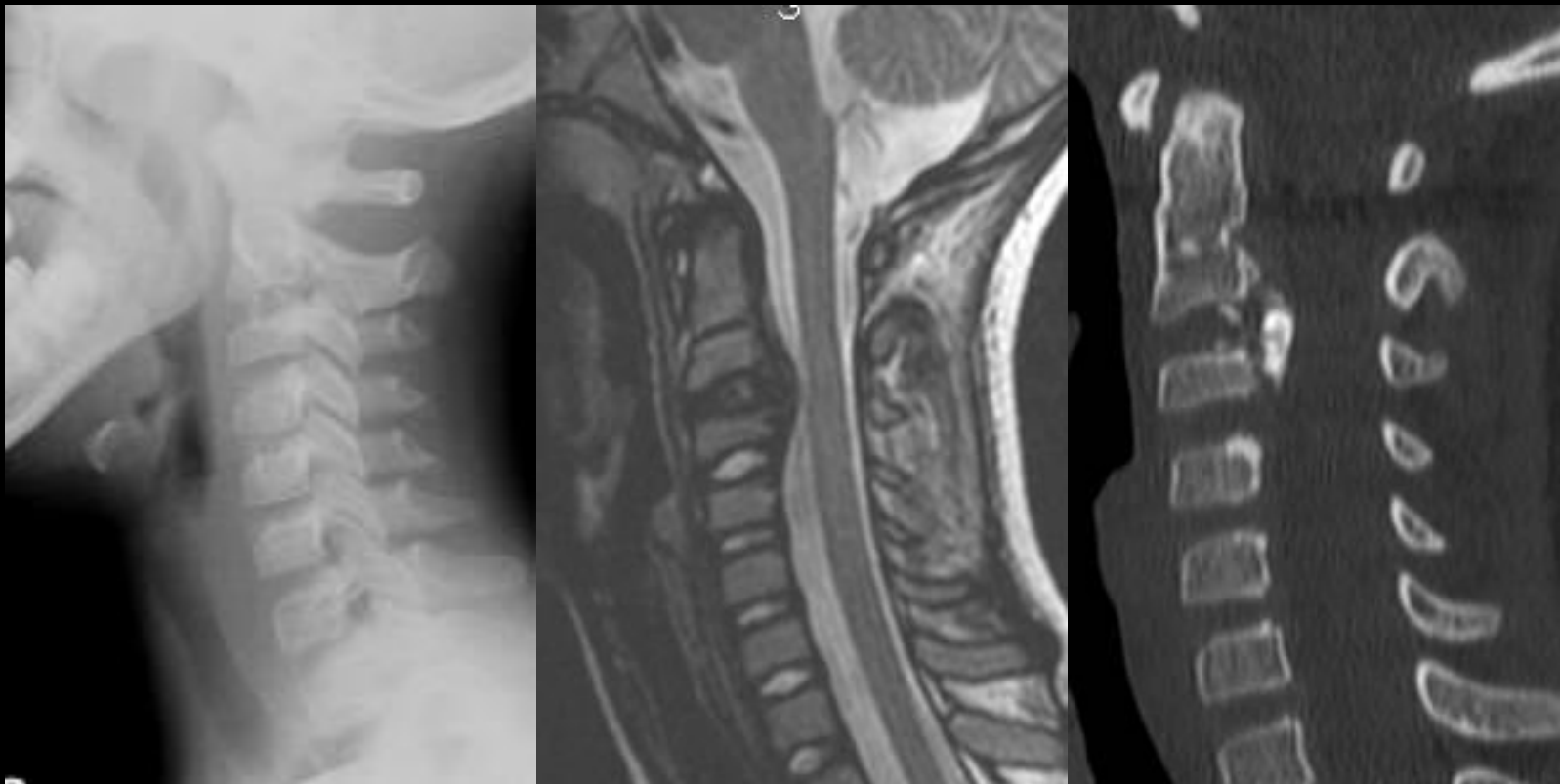
CASE

71 year old woman with golf ball sized mass in the upper arm. When compressed, pain and tingling radiates down her arm.



CASE

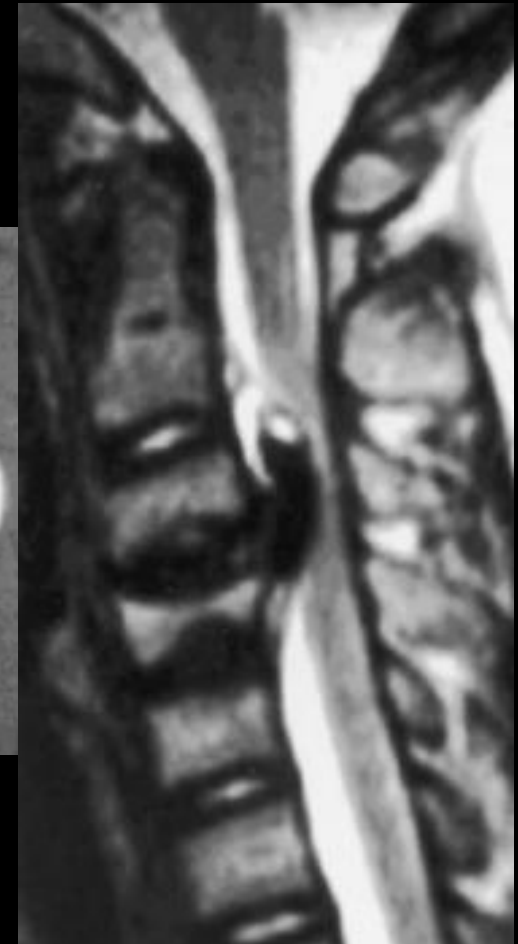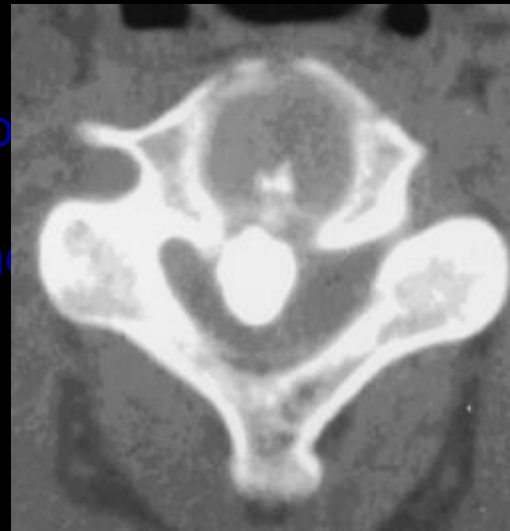
8 yo girl fell 2 ft from bed, knee hit chin, and neck snapped back!



CASE

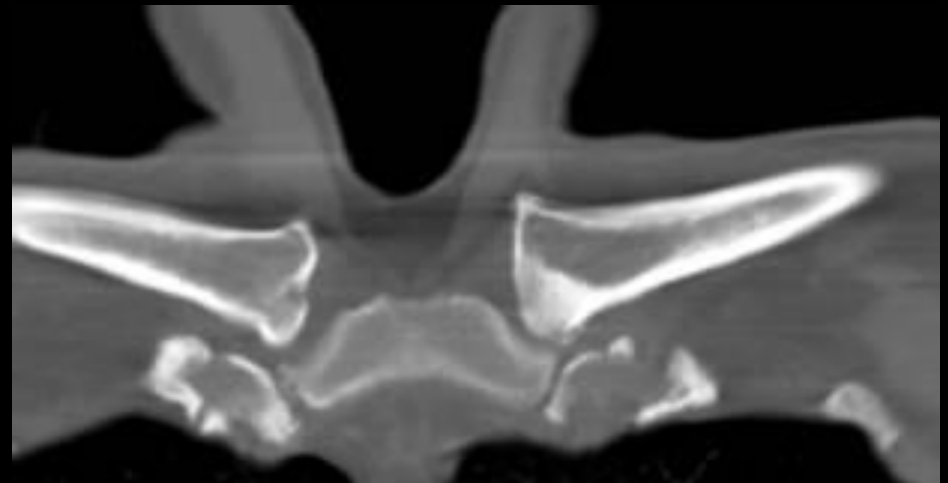
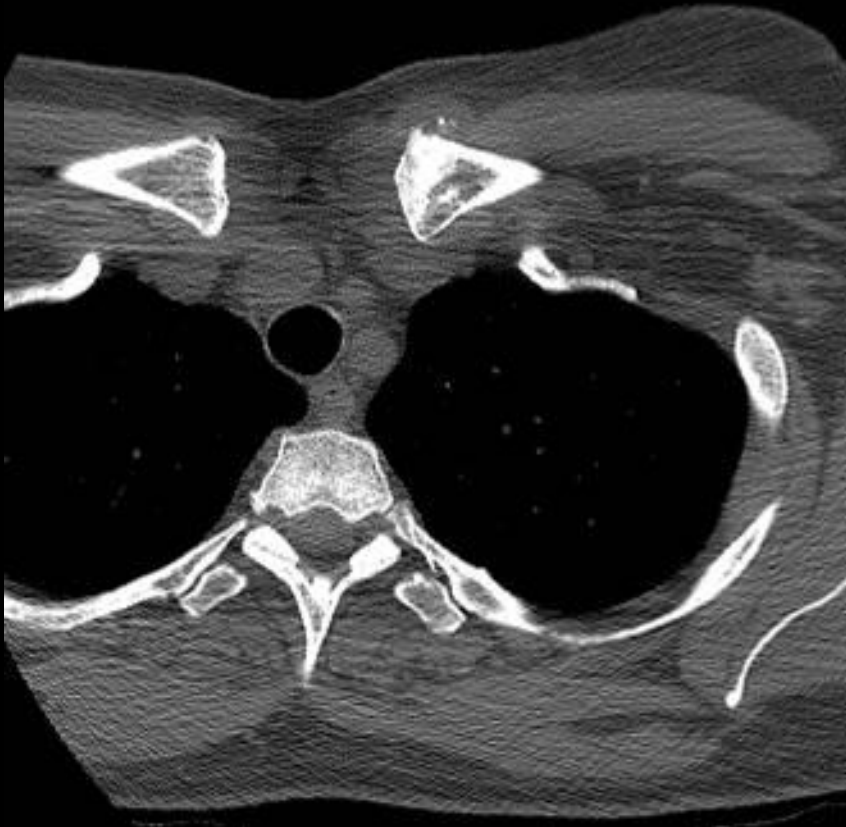
Another Example

A five-year-old boy with neck pain, torticollis, and arm pain. There had been numbness radiating down the forearm into the thumb, index, and long fingers. Computed tomography and MRI revealed a calcified disc herniated into the spinal canal with canal compromise of 60%.



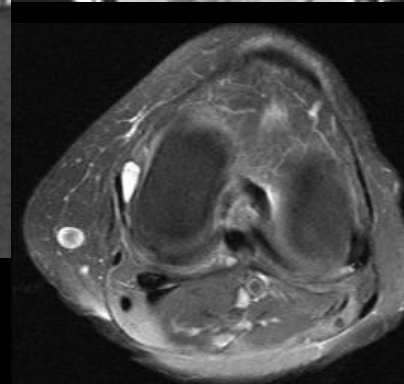
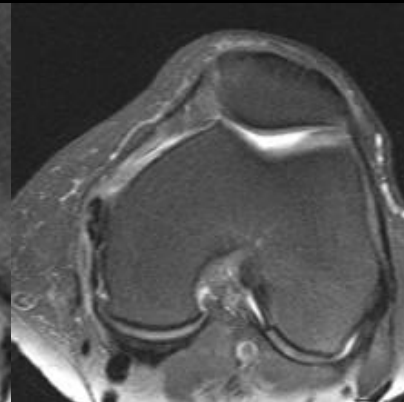
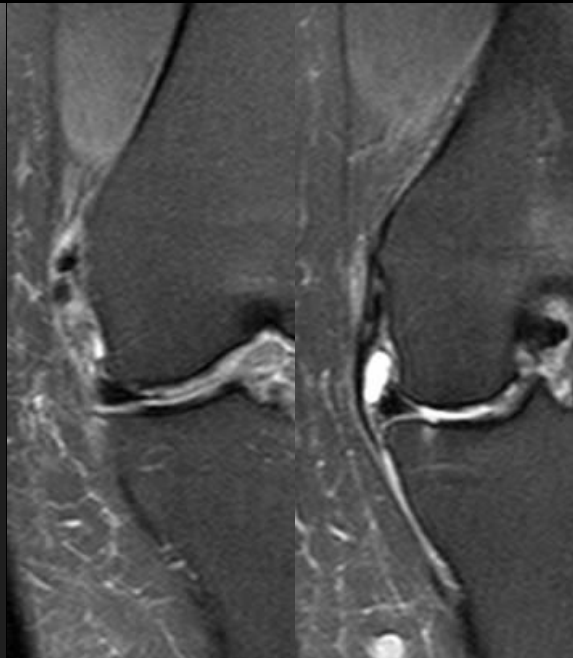
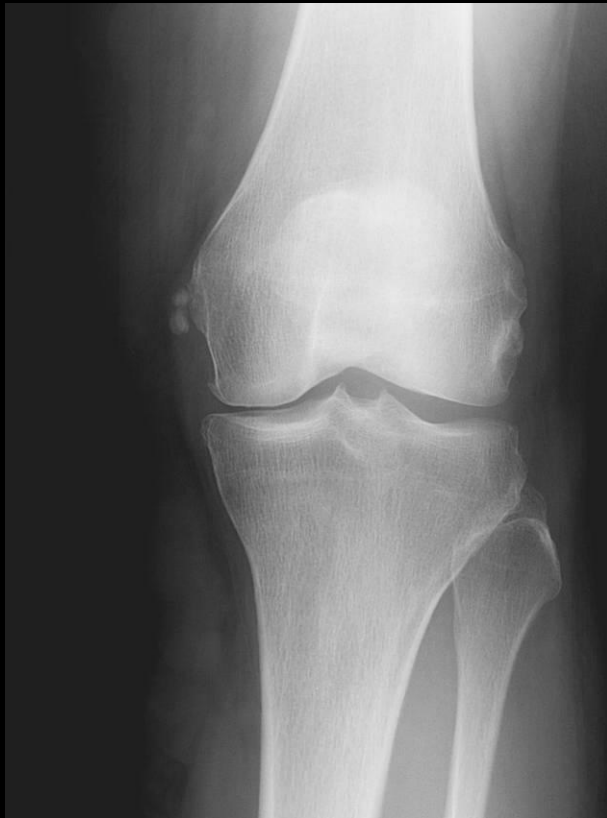CASE

History: 52 year old female who noticed a non-painful lump over medial aspect of the left sternoclavicular joint.



CASE

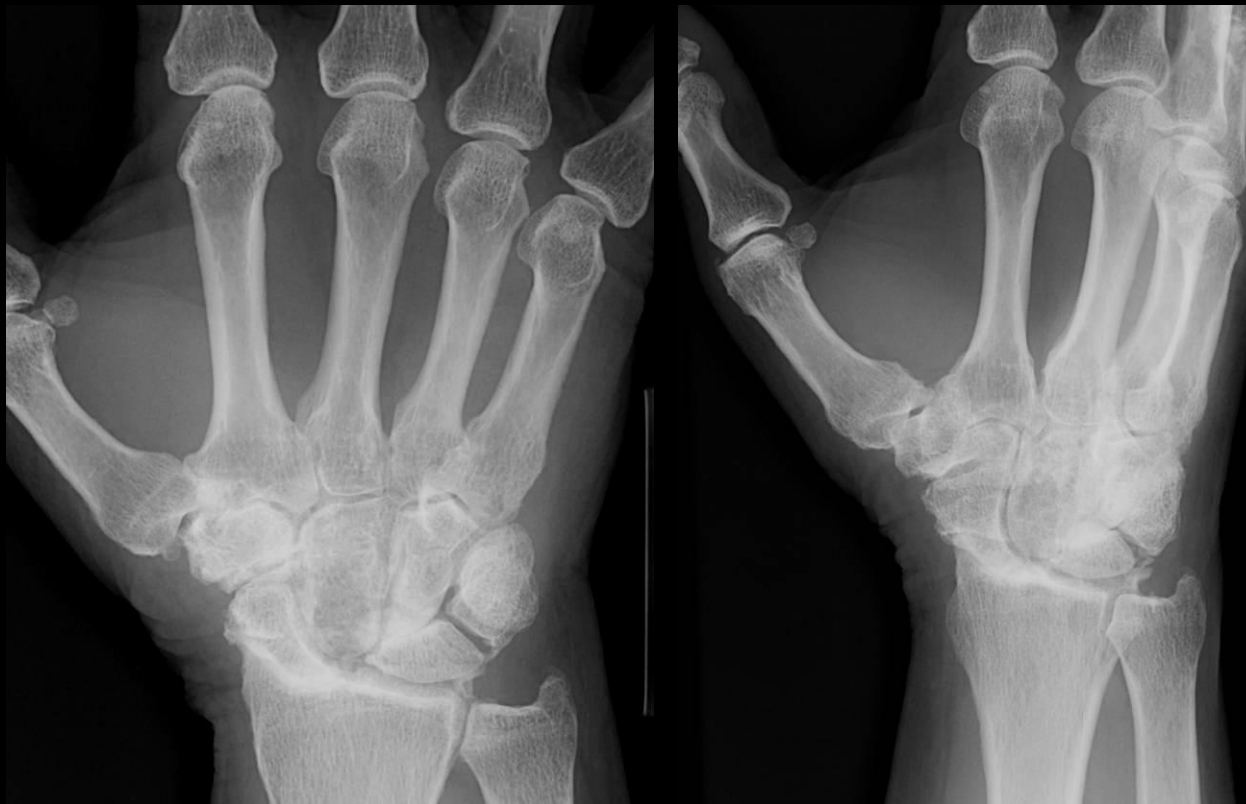60 y/o female with severe knee pain considering unicondylar versus total joint replacement. Pain is predominantly medial.



HADD
and
MCL
Bursitis

CASE

57 year old man with wrist pain



SLAC vs
CPPD

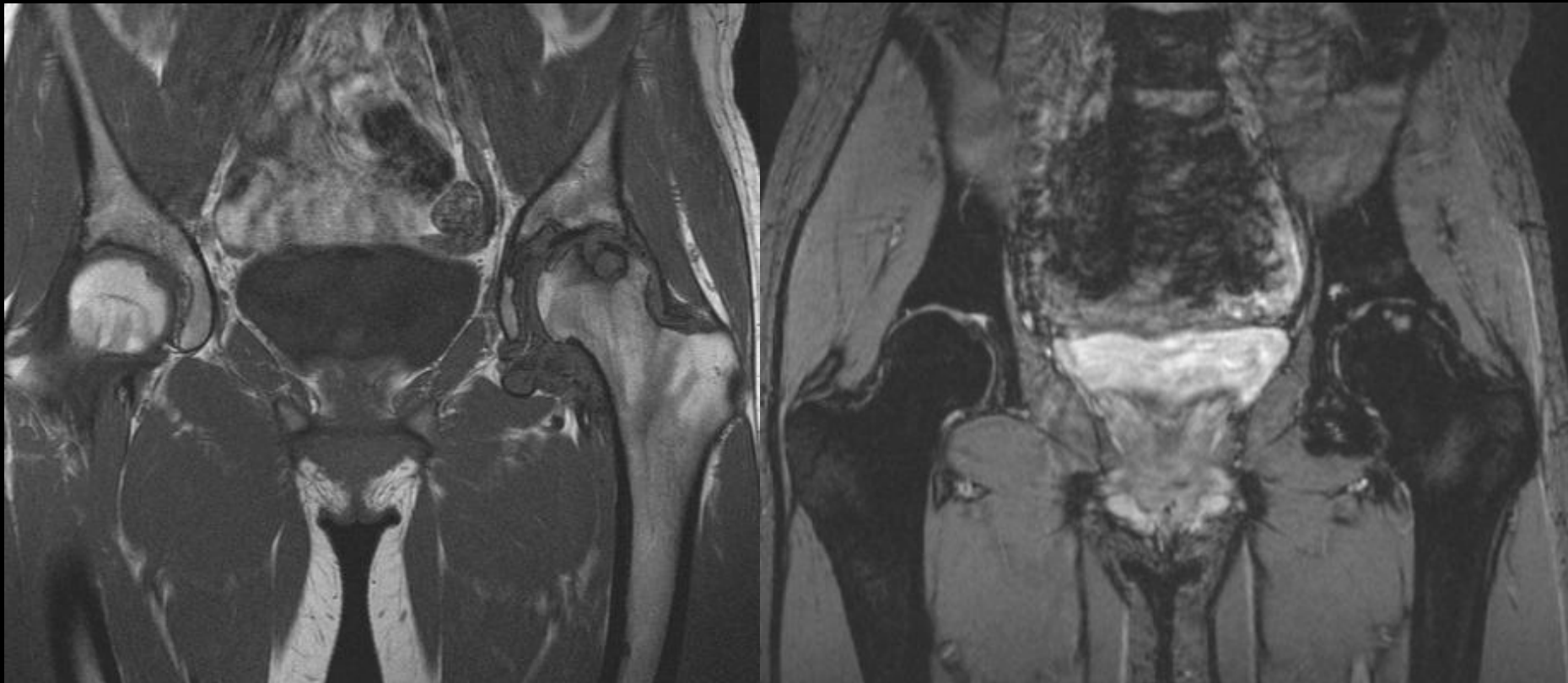
CASE

Young Alaskan pt with monoarticular arthropathy

T1

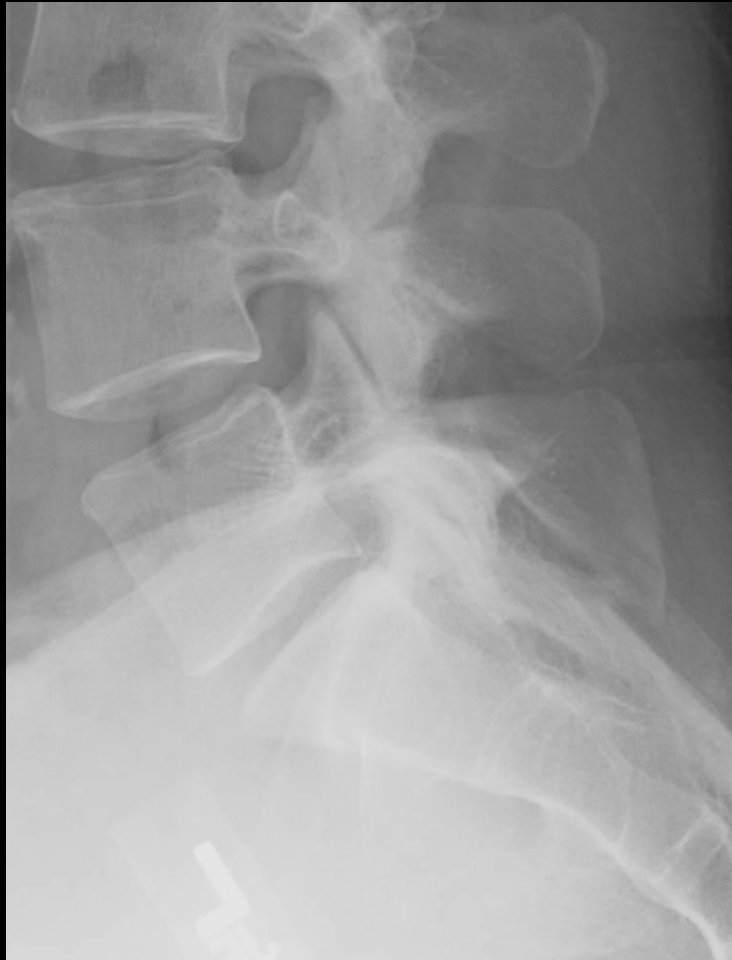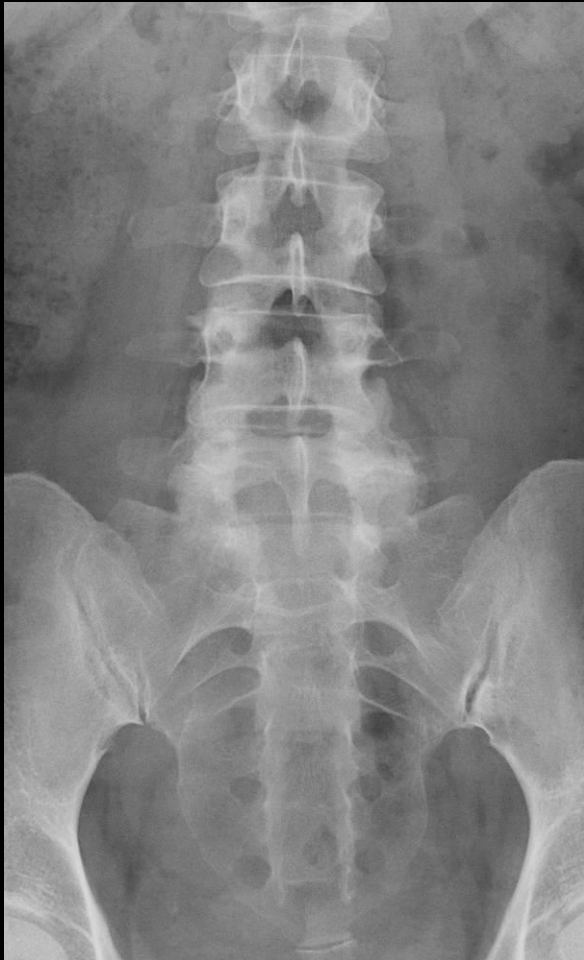GRE

?PVNS



CASE

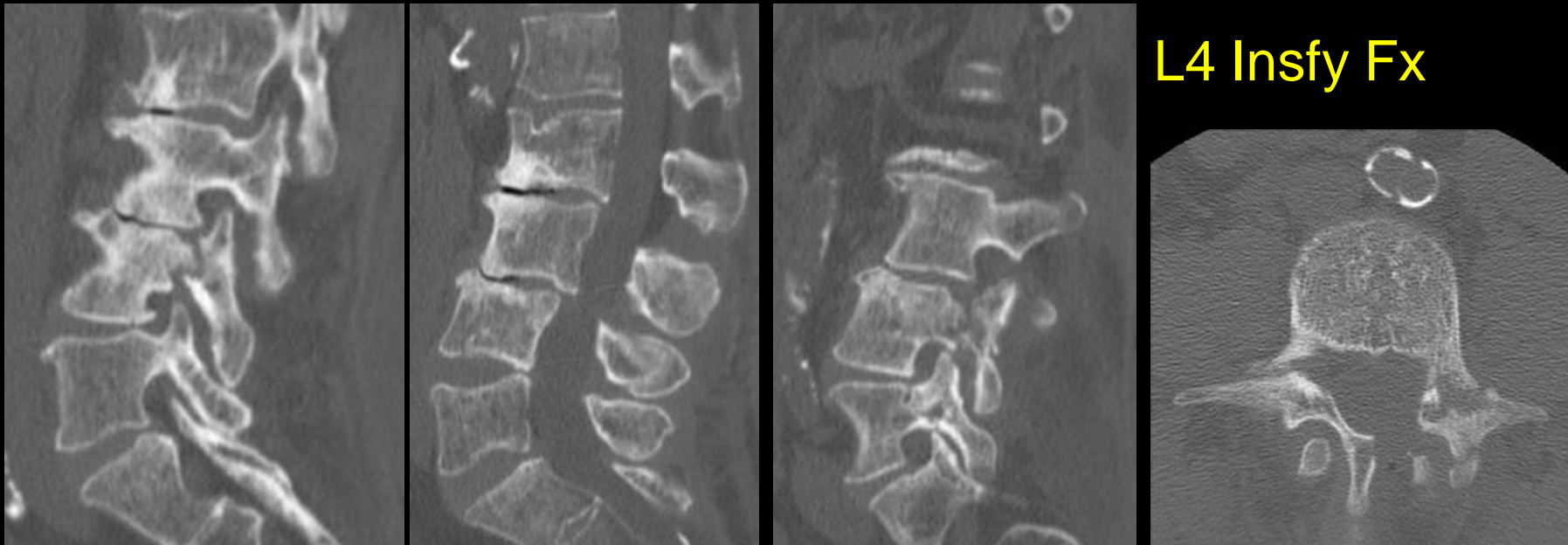
51 y/o with back pain



Clasp
knife

CASE

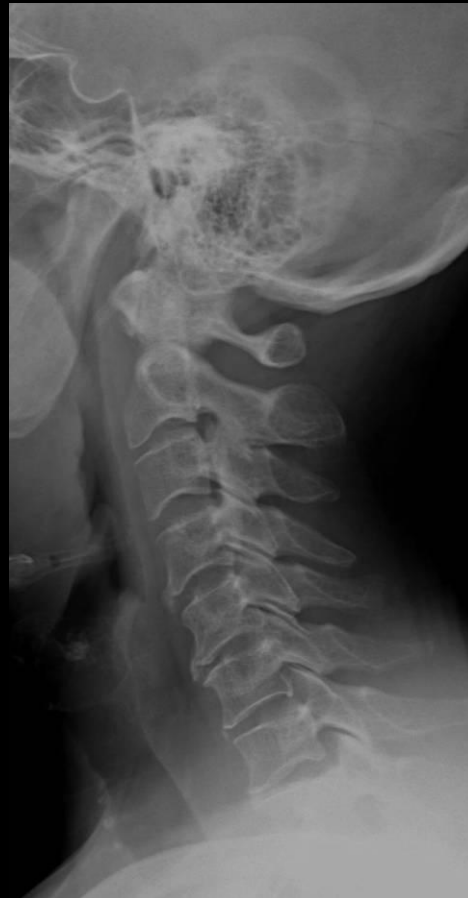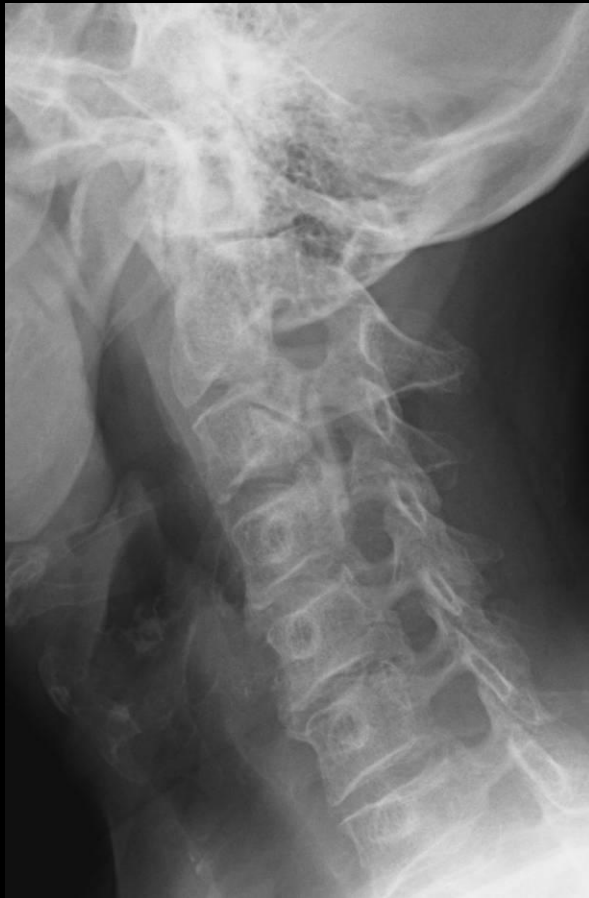75 y/o pt being worked up for possible spinal infection
mild elevation of CRP and Sed Rate. No other history
available re trauma, etc.



L4 Insfy Fx

CASE

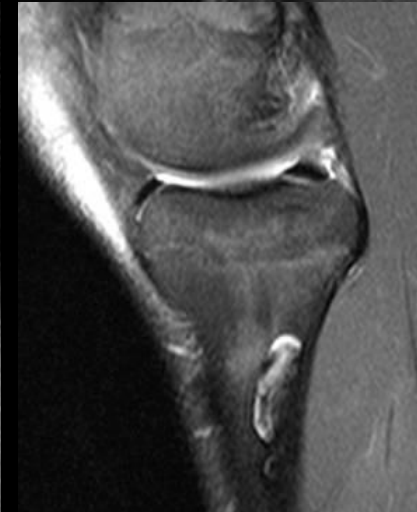
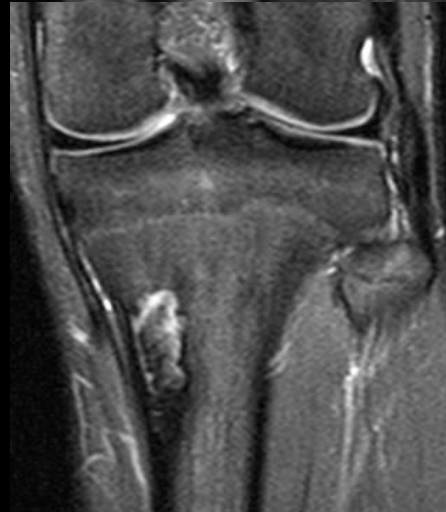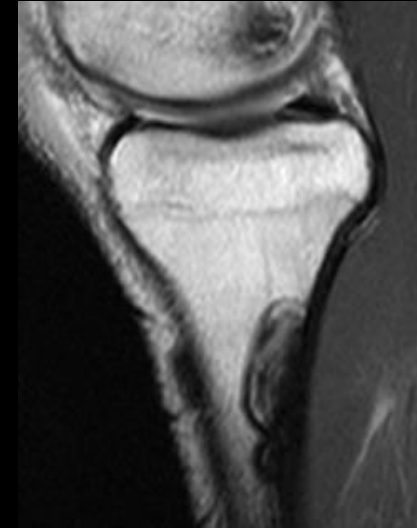
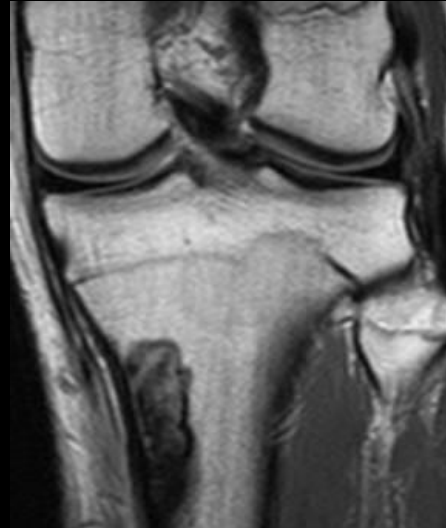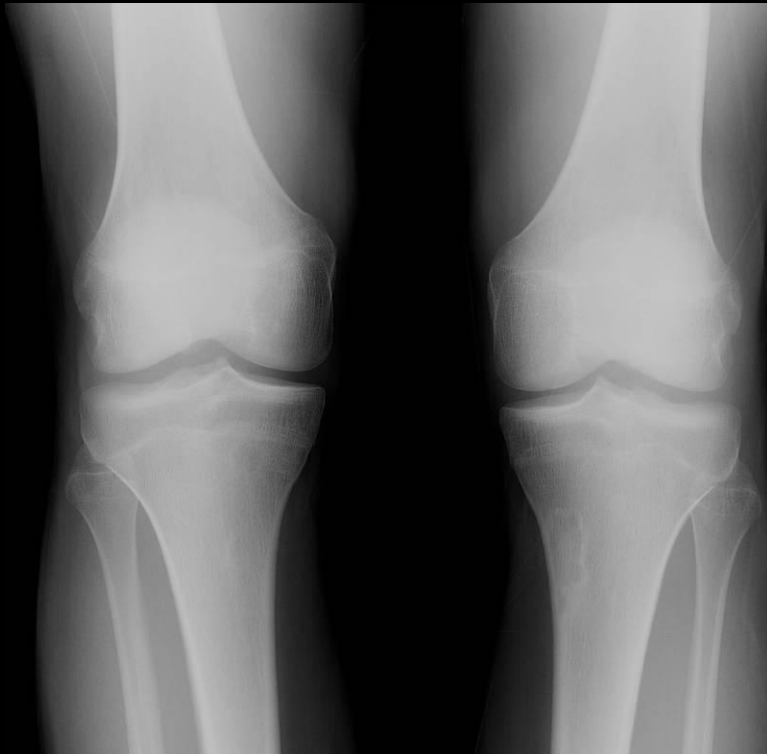60 years old with cervicalgia



OPLL

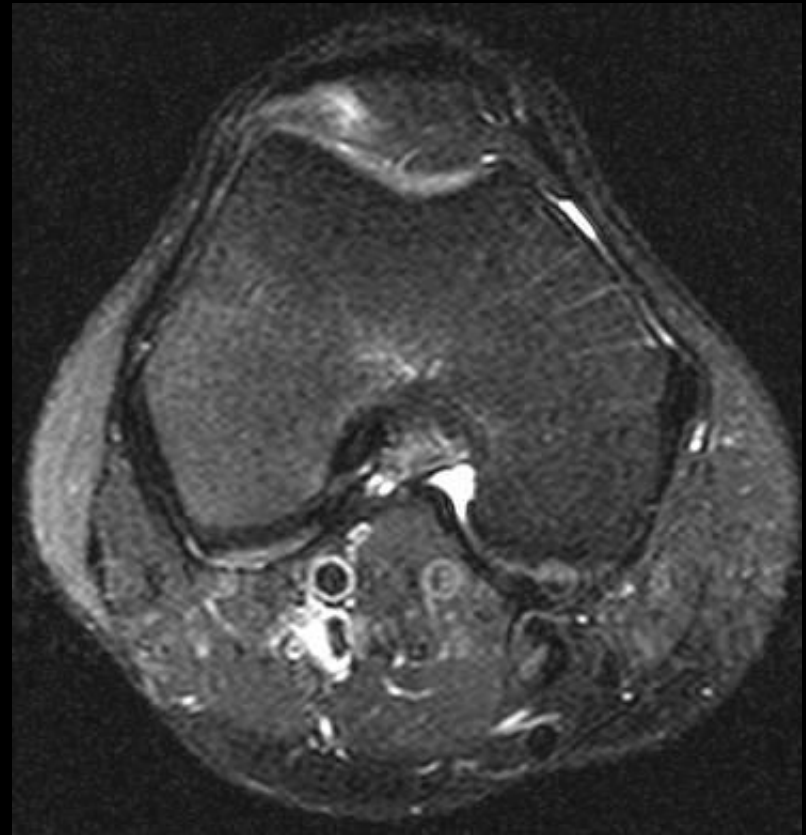
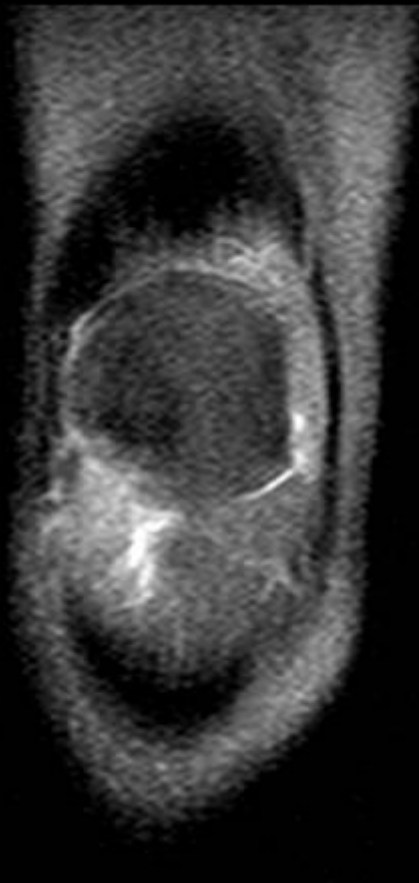
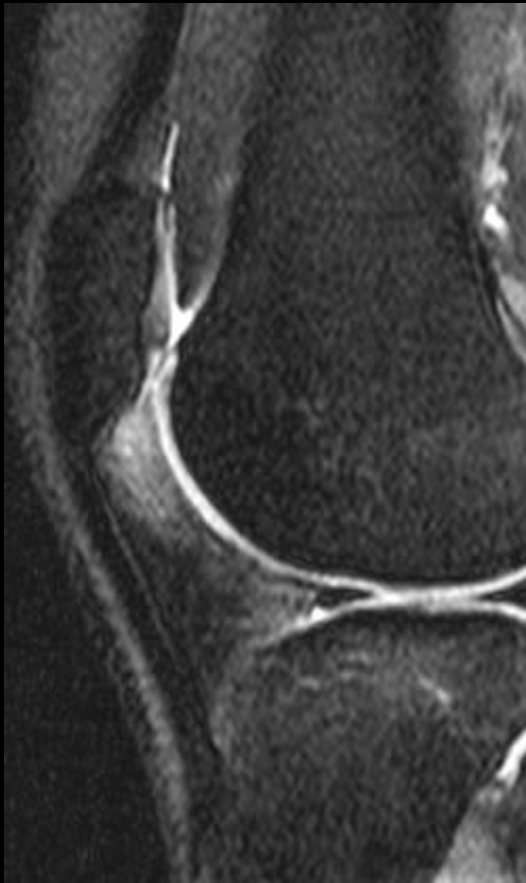CASE

Wrestler with benign lesions seen on plain film



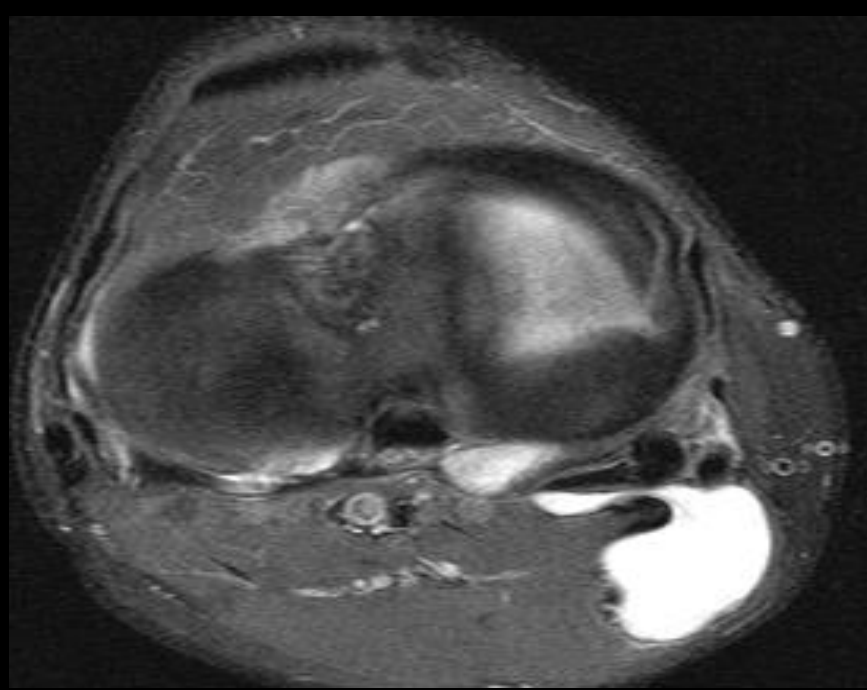
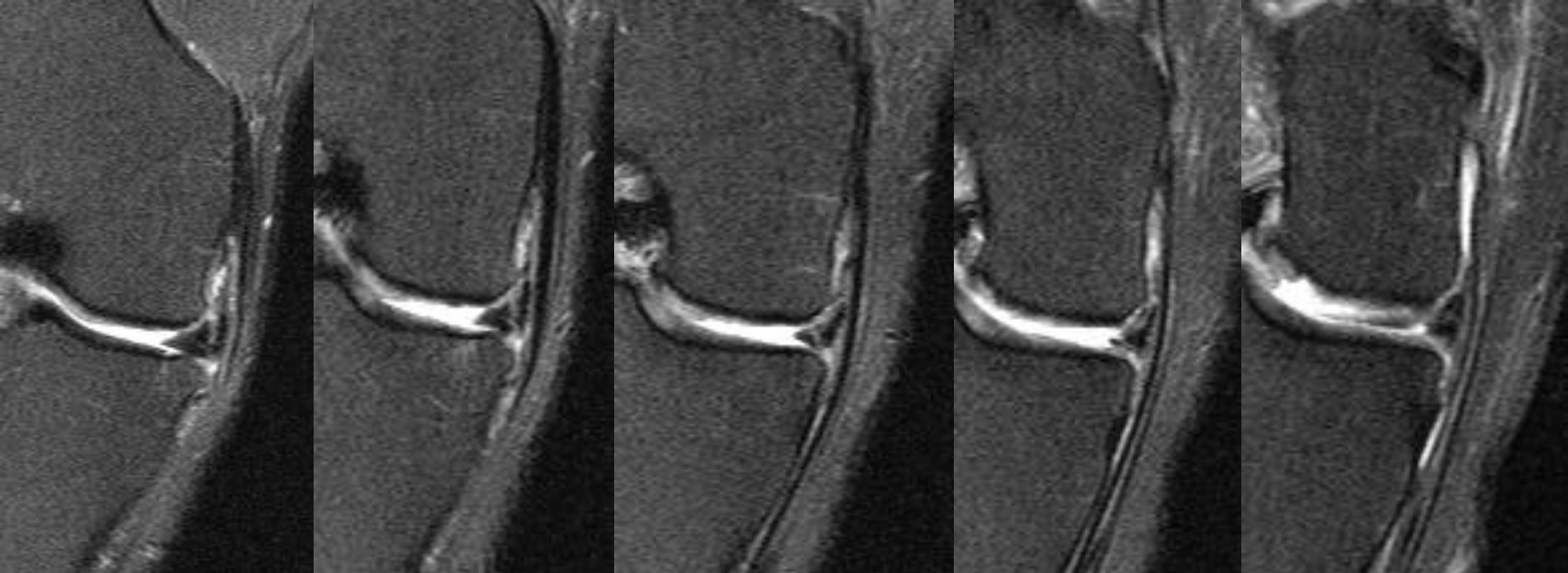
CASE

~~26 year old female with lateral knee aching with trouble squatting and catching symptoms~~



CASE

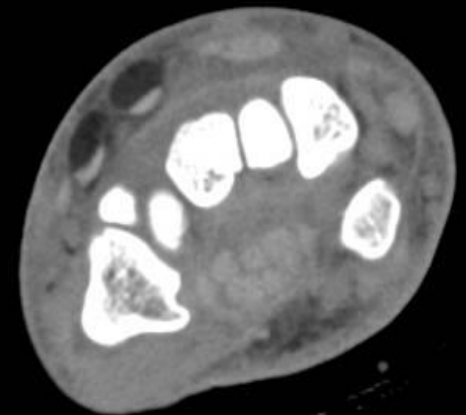
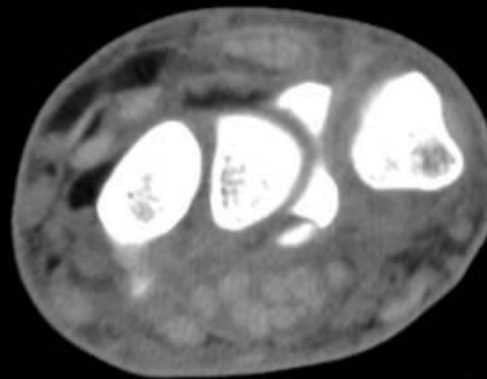
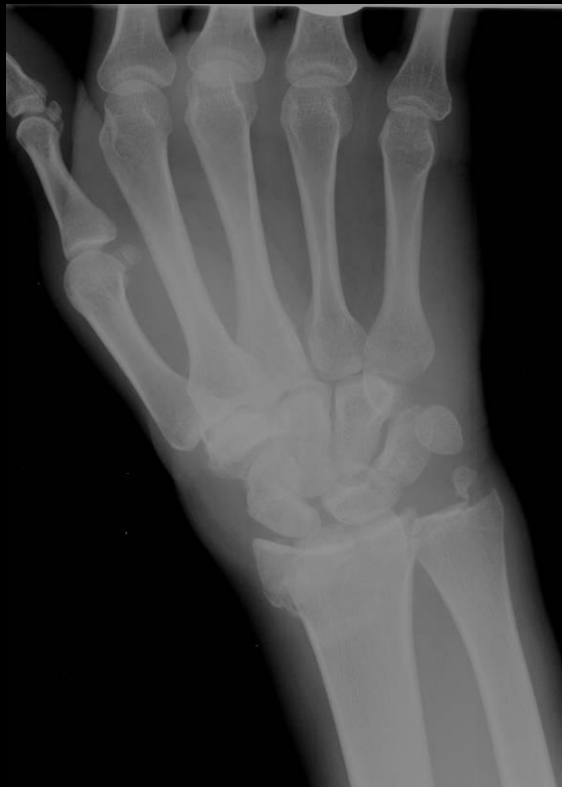~~43 year old male with right medial knee pain,~~
recurrent effusions and popliteal cyst. History
of partial medial meniscectomy 1.5 years ago



Re-tear

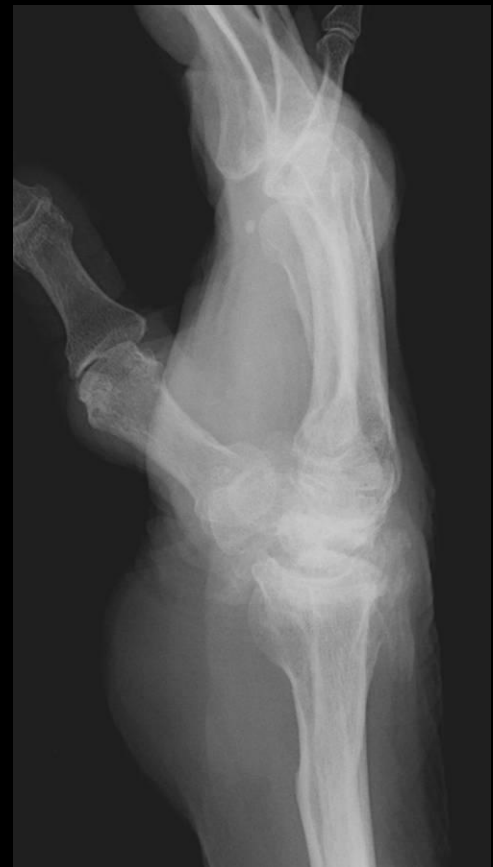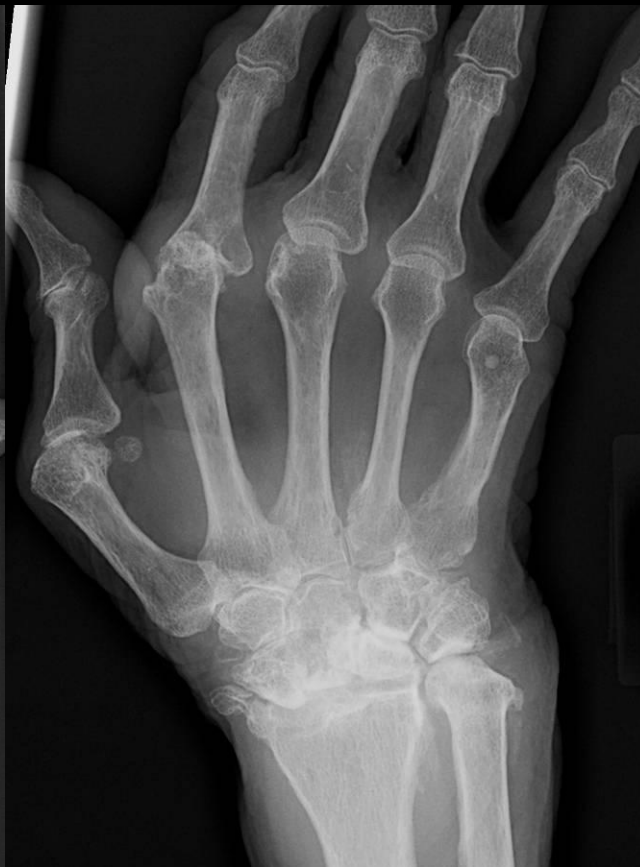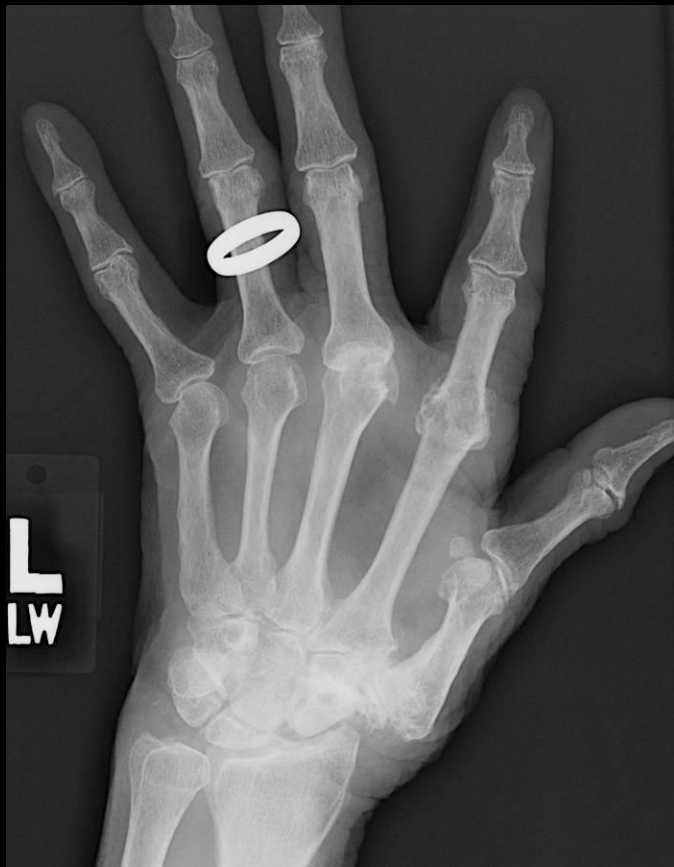CASE

19 year old female status post fall off motorcycle.
Distal radial intra-articular fracture with
lipohemarthrosis in radiocarpal joint and
extension to extensor tendon sheaths



CASE

Plain film in pt with RA and CPPD arthropathy.?? Ventral synovial cyst



CASE

82 y/o pt with hx of CREST syndrome. Eval arthropathy

