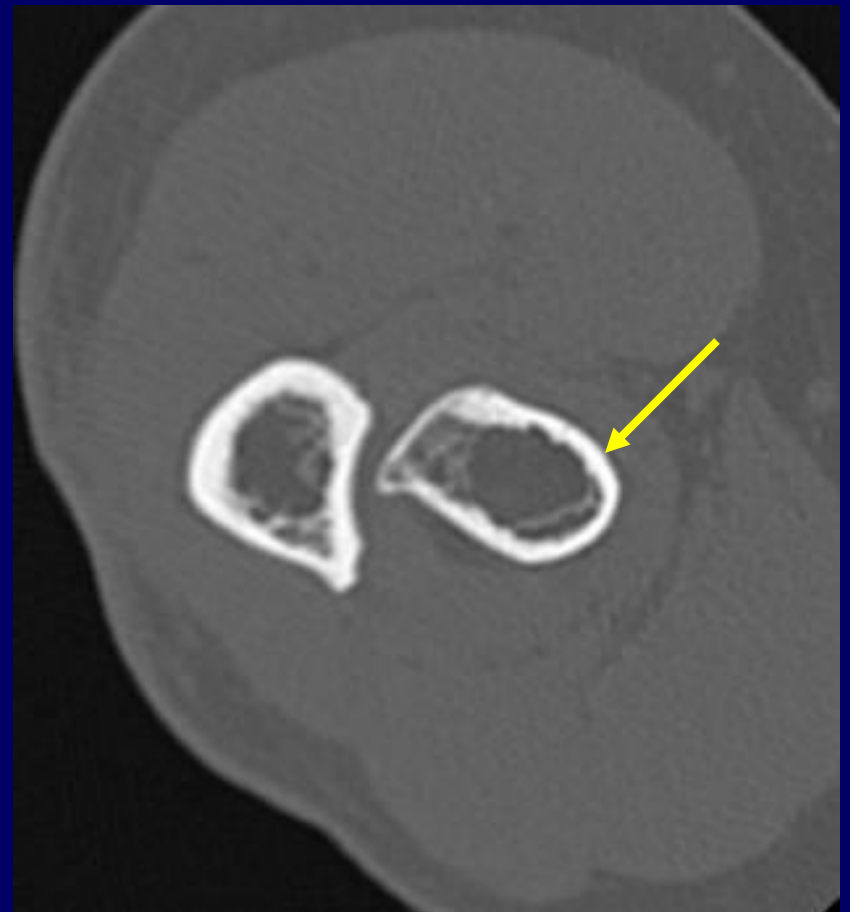
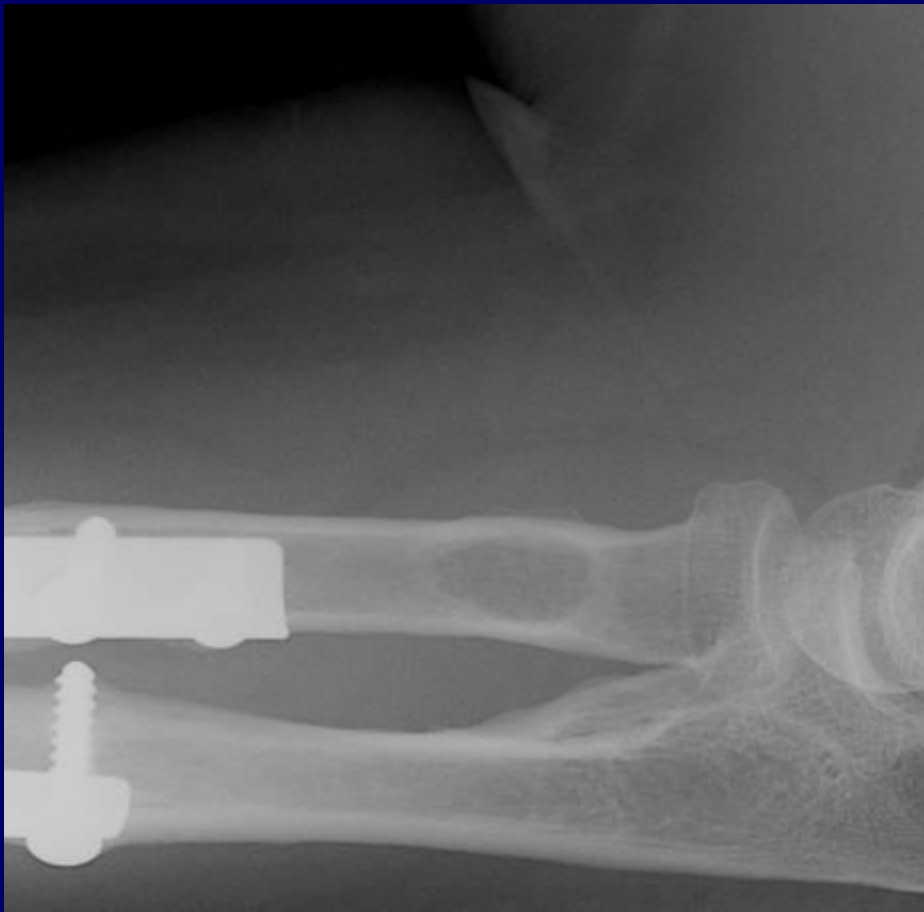


November 16, 2006

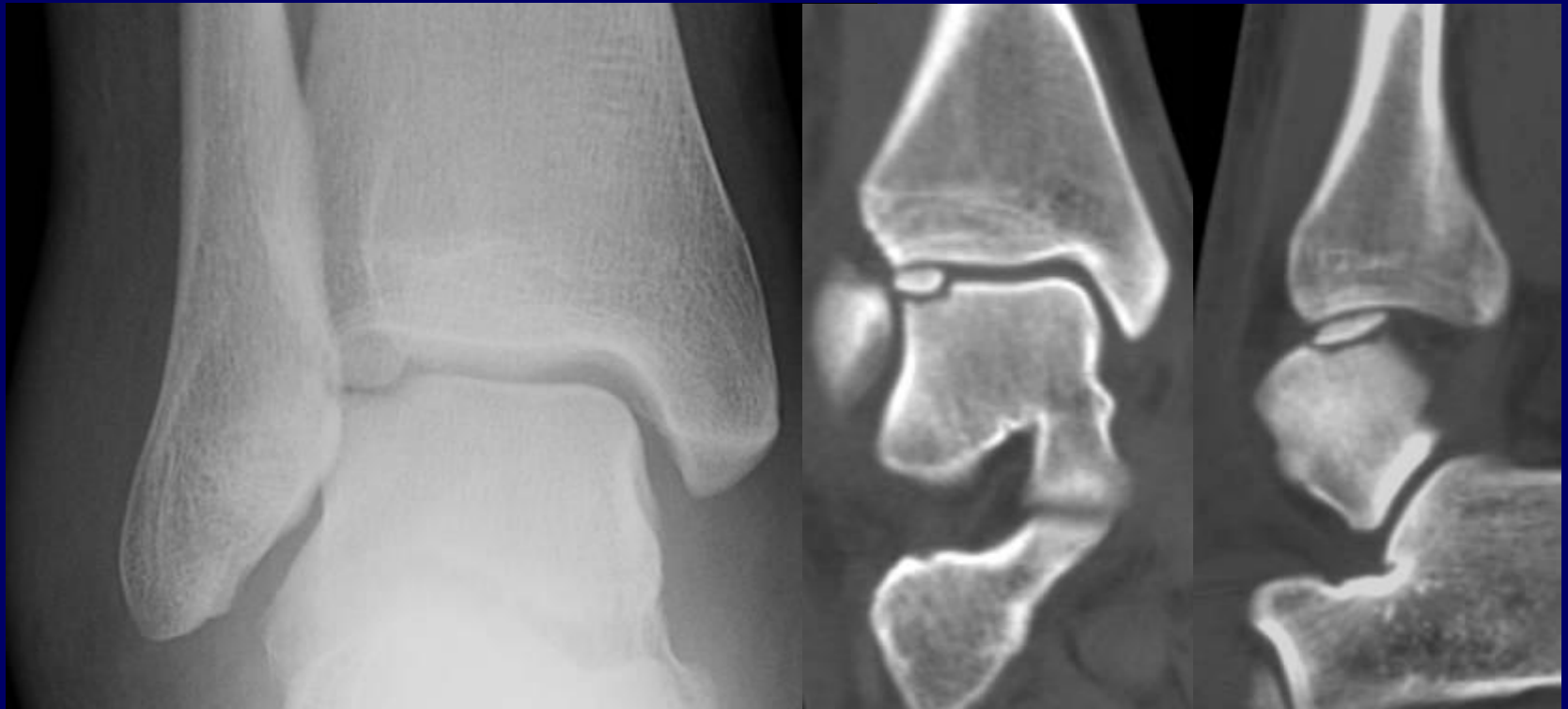CASE

CT workup of osteolytic lesion seen on plain films



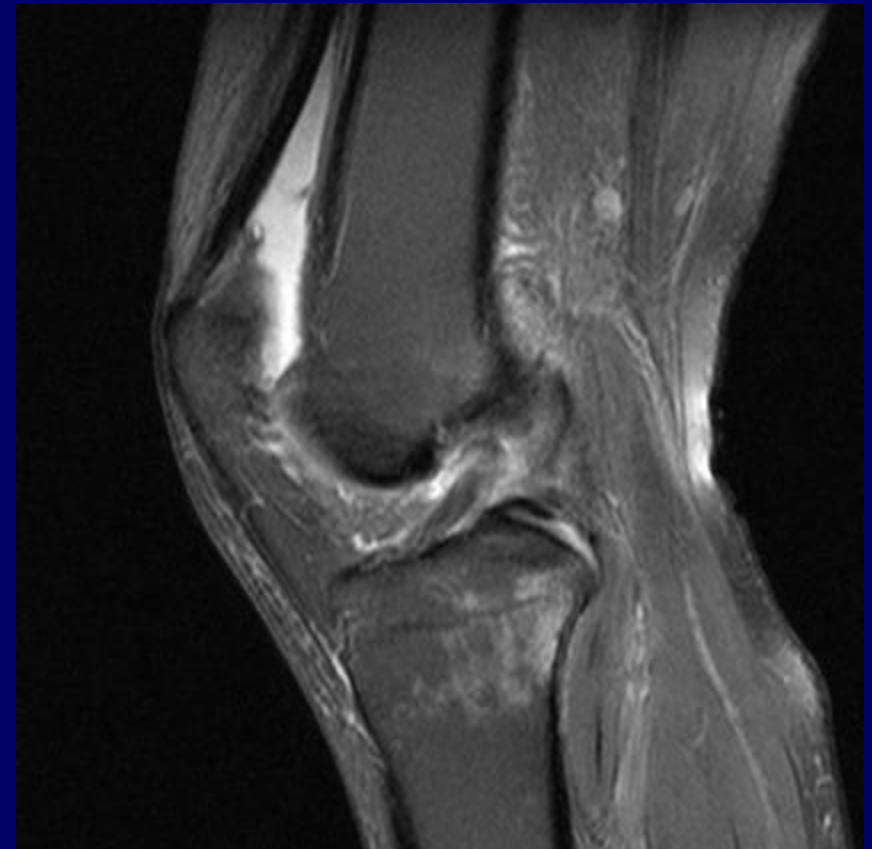
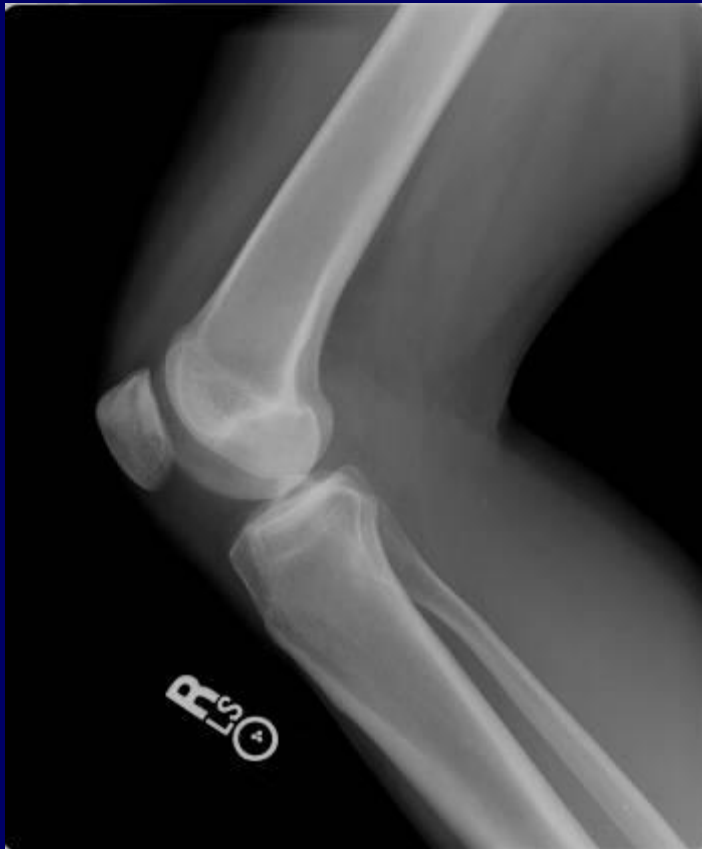CASE

Flipped Talar Dome Osteochondral Lesion
20 year female in with talar dome fx



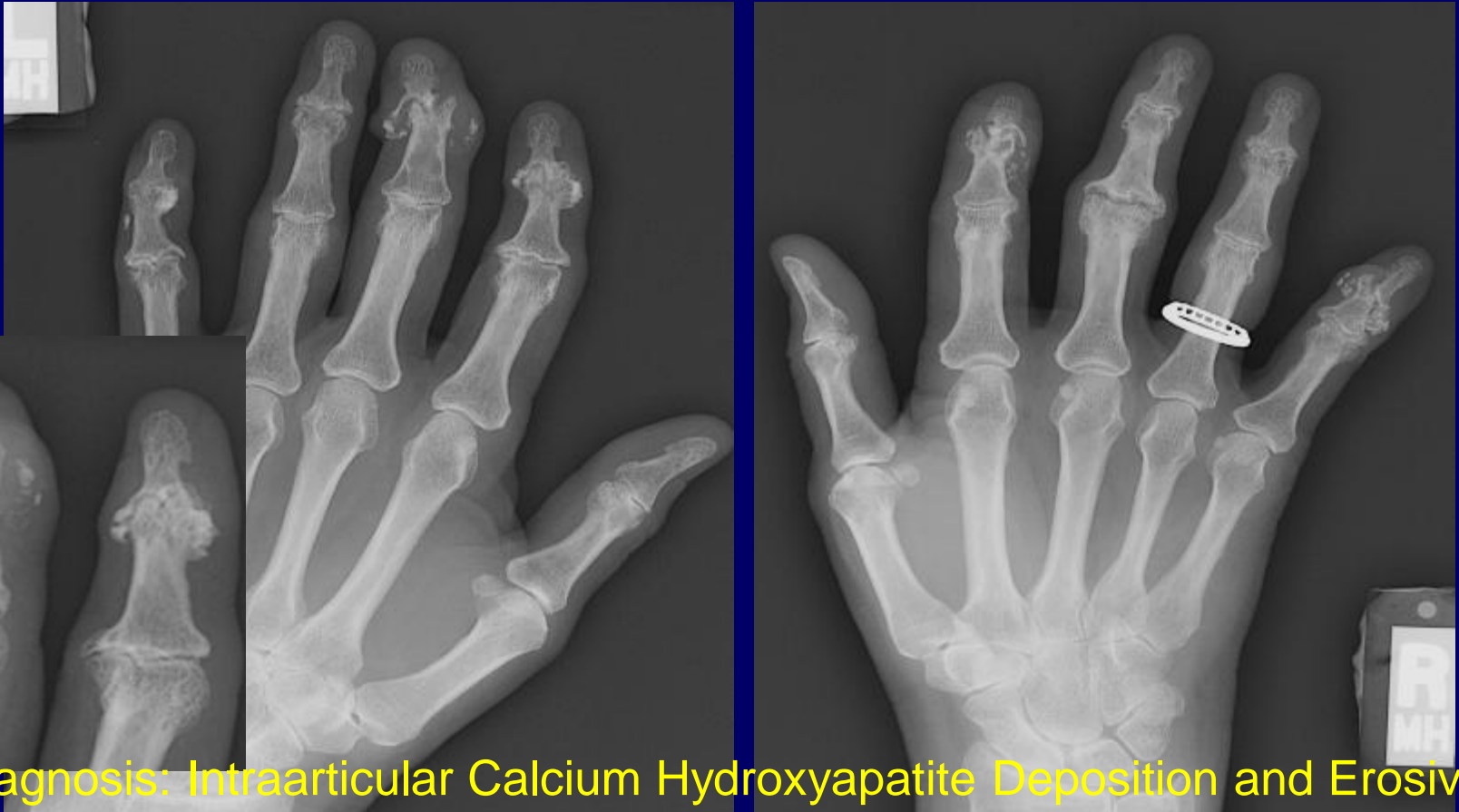
CASE

ACL tear from direct trauma to posterior tibia
36 yo female who collided with another softball player 10 wks prior



CASE

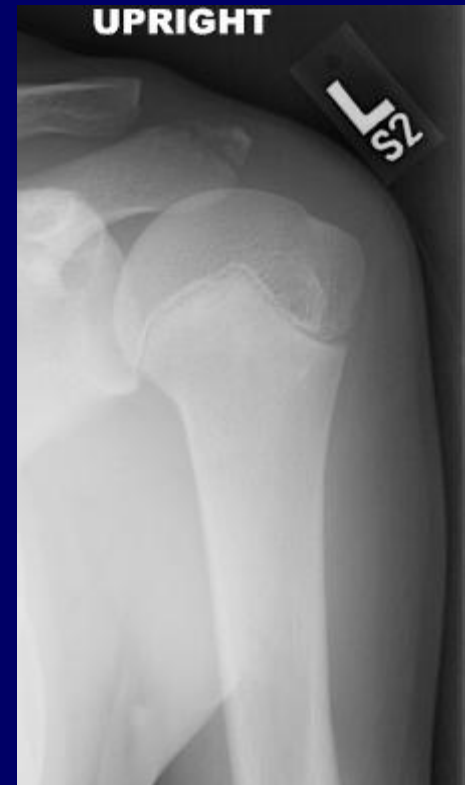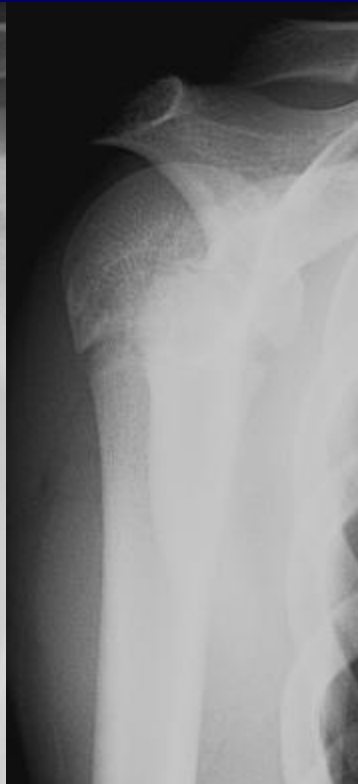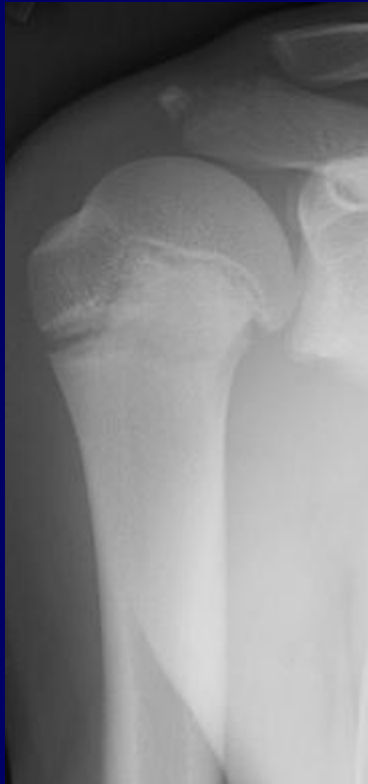57 yo female with bilateral DIP tenderness



Diagnosis: Intraarticular Calcium Hydroxyapatite Deposition and Erosive Osteoarthritis

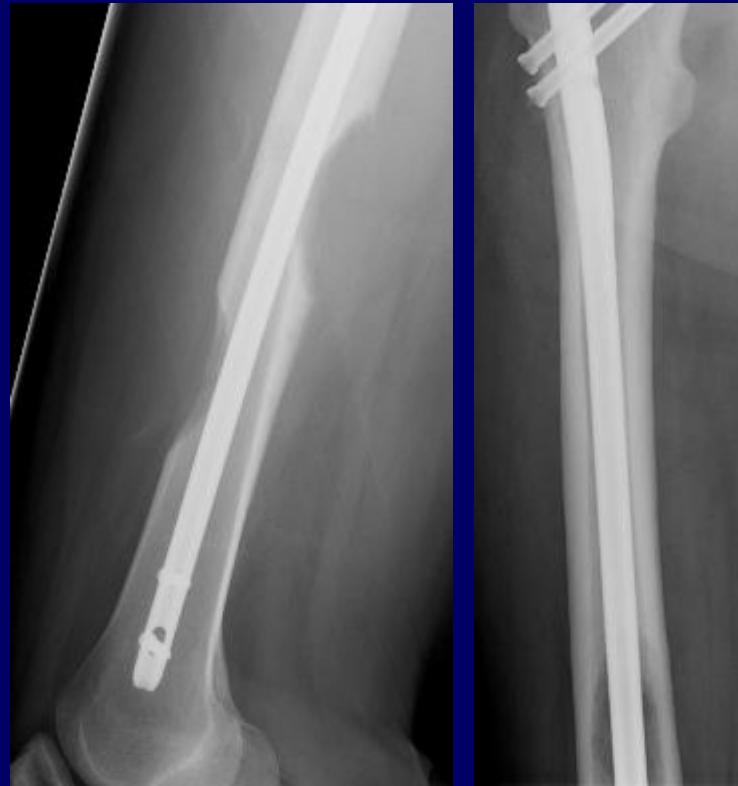
CASE

- 12 year-old with pain in right shoulder.
- Findings: Widening of the lateral aspect of the humeral physis consistent with little Leaguer's shoulder.



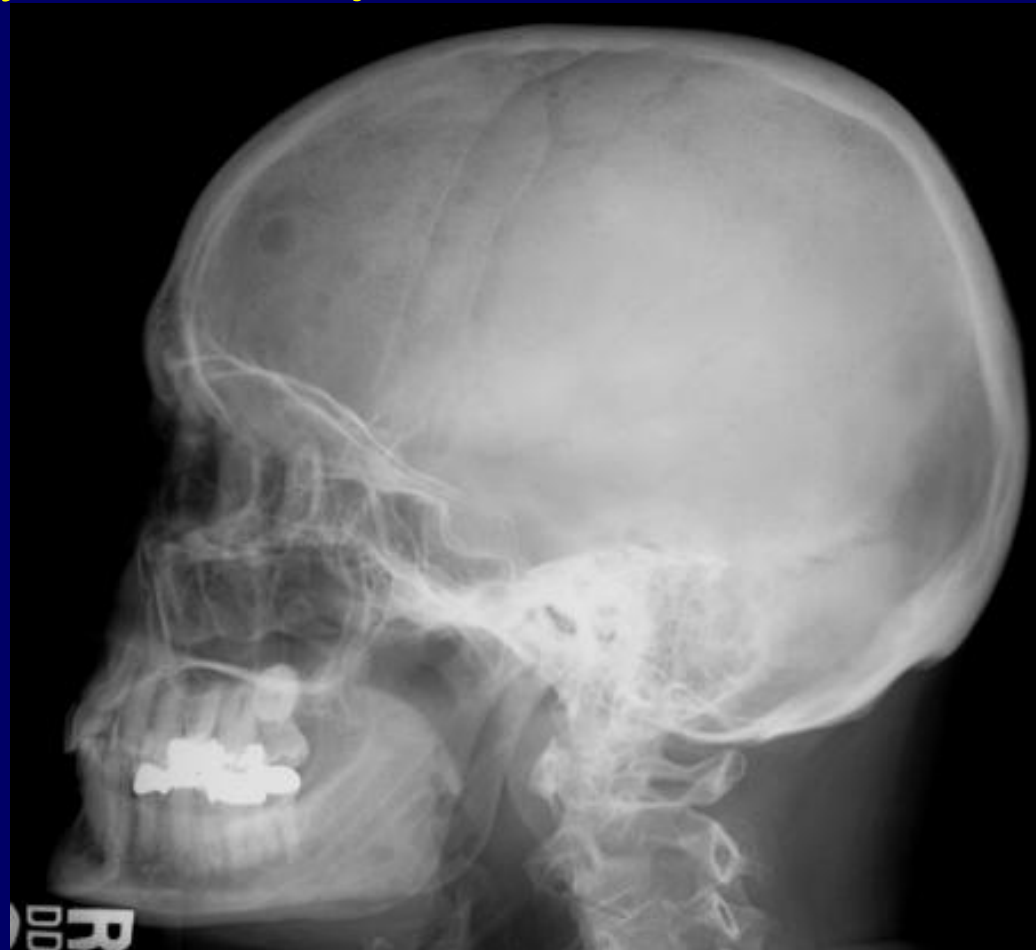CASE

- 58 year-old woman with known renal cell carcinoma metastatic to the bone.
- Findings: Cookie bite lesion to the femur from renal cell carcinoma.



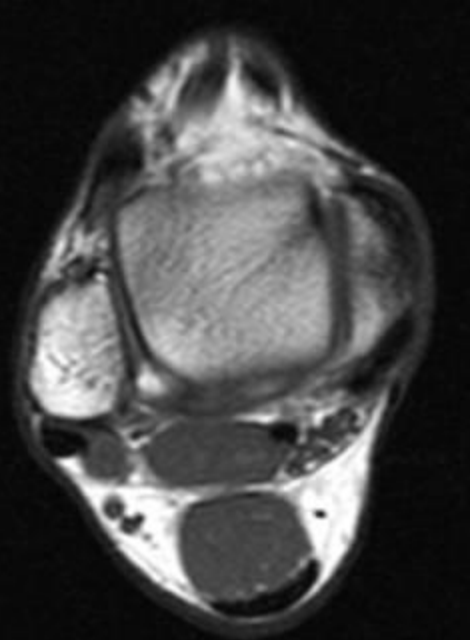
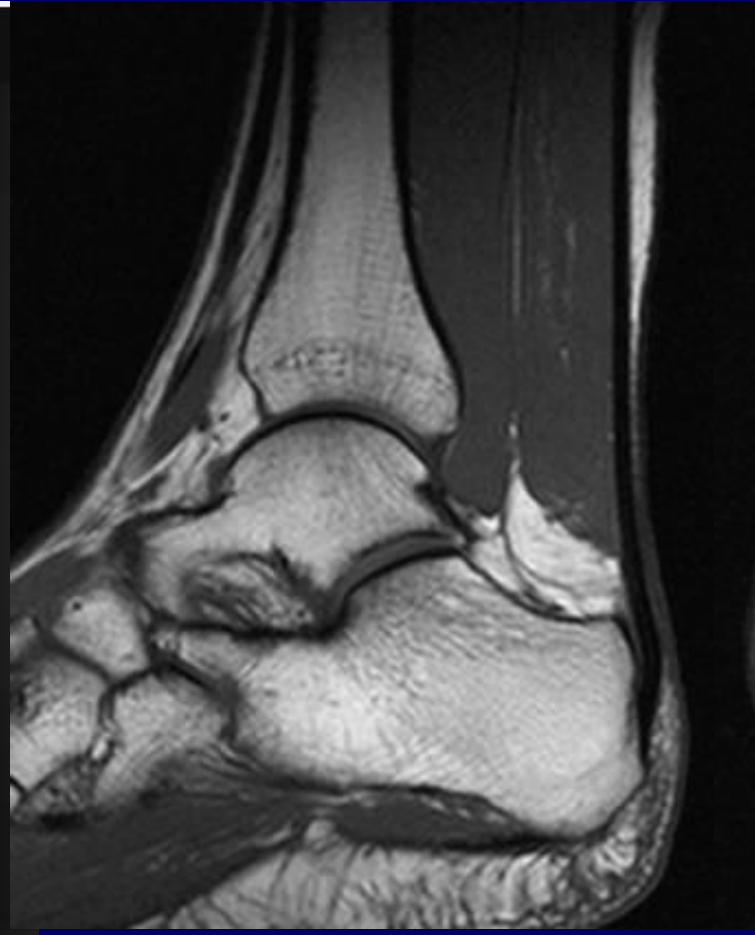
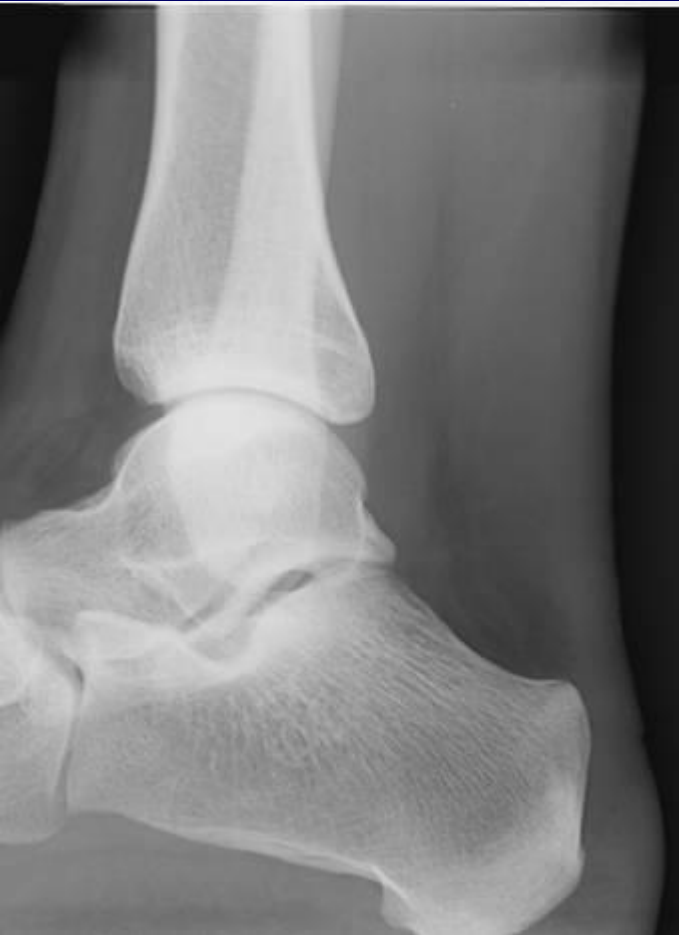CASE

Myeloma with jaw and skull lesions



CASE

Low lying soleus

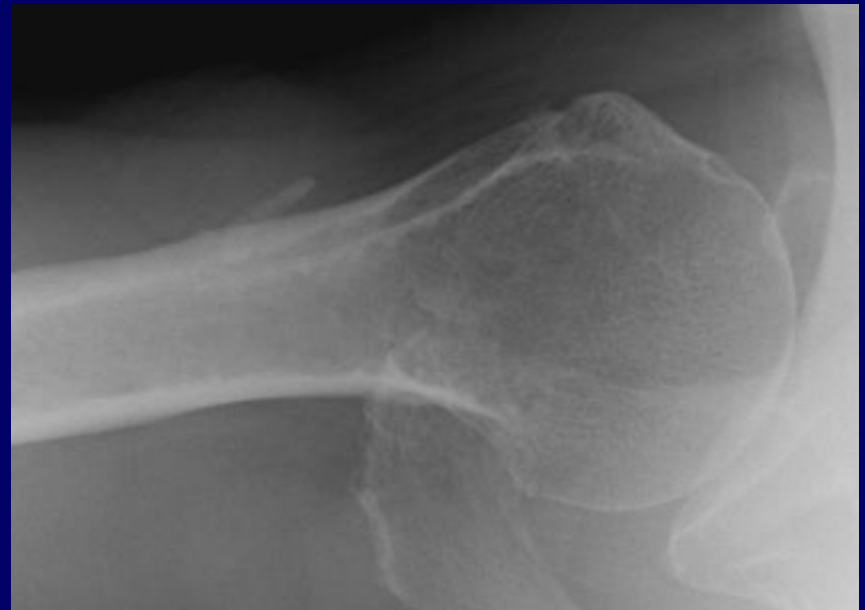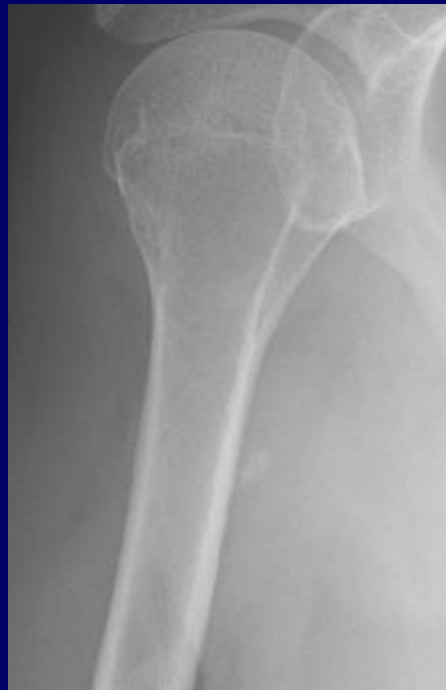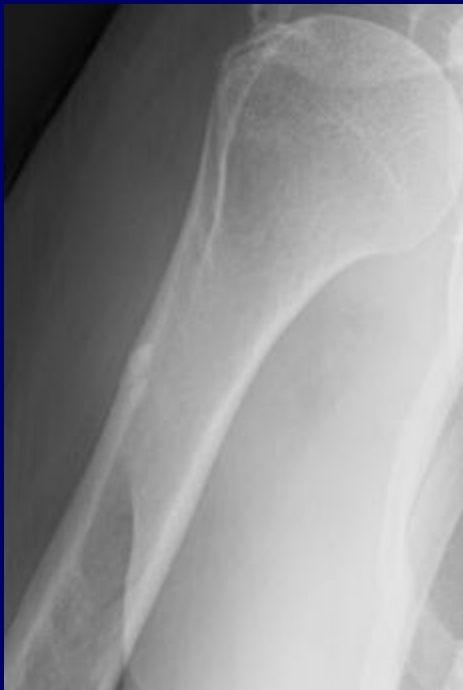


CASE

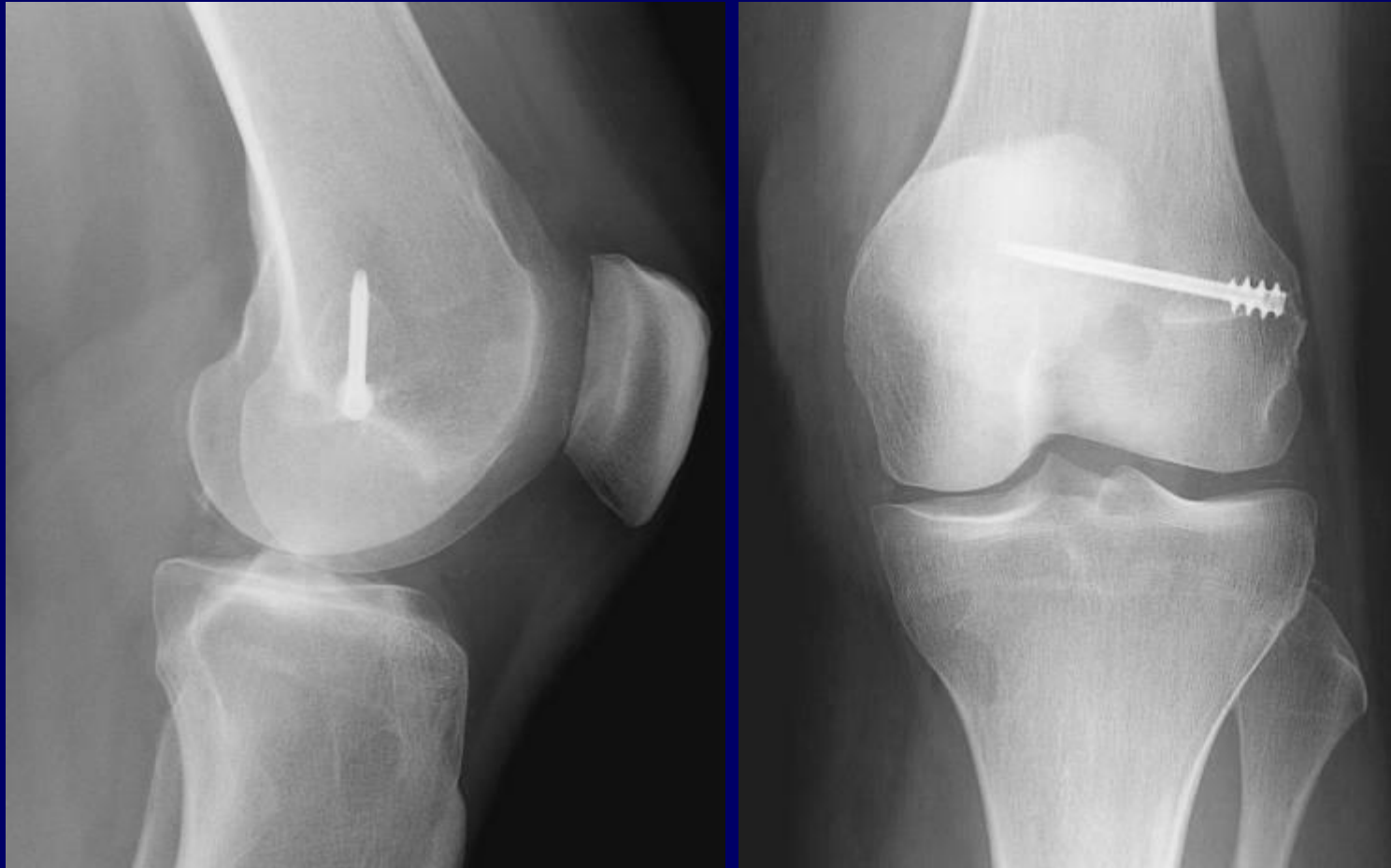
HADD

biceps myotendinous junction

74 yo male with bilateral shoulder pain



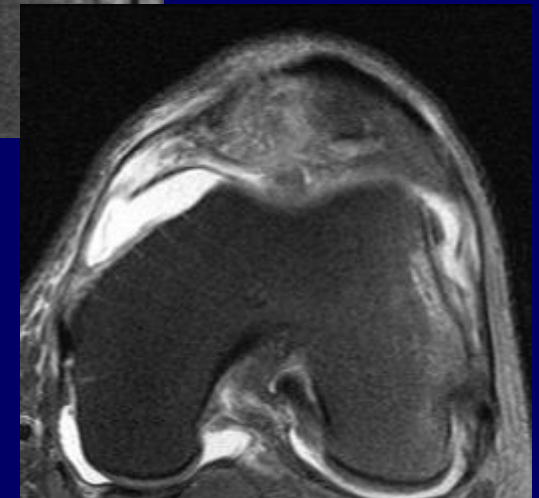
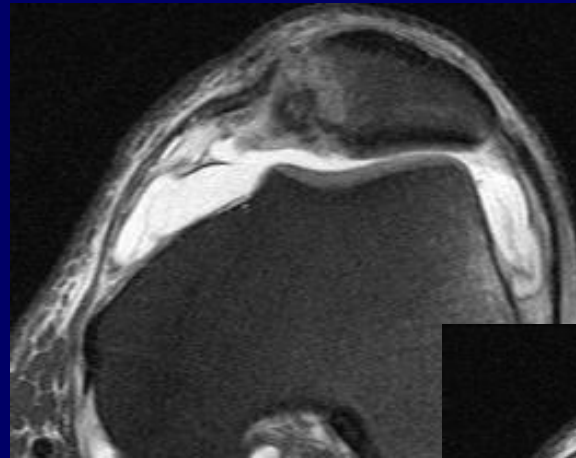
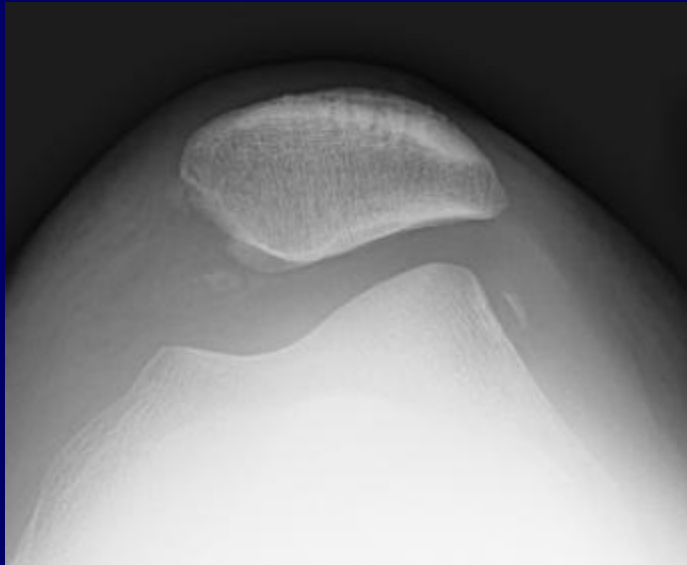
CASE



CPPD deposition s/p ACL repair

CASE

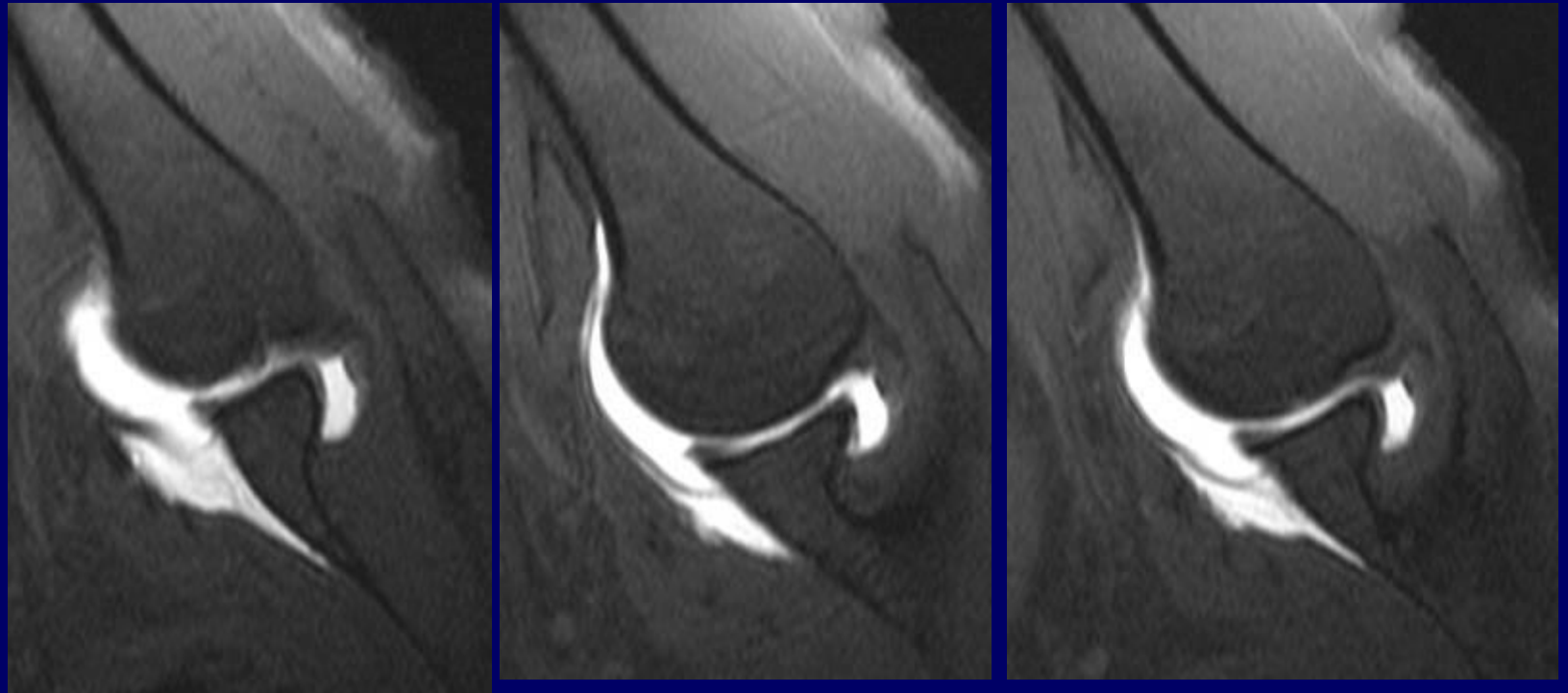
35 year old male with history of chronic patellar subluxation since age 6. Recently re-injured his knee with dislocation and severe pain.



Patellar dislocation

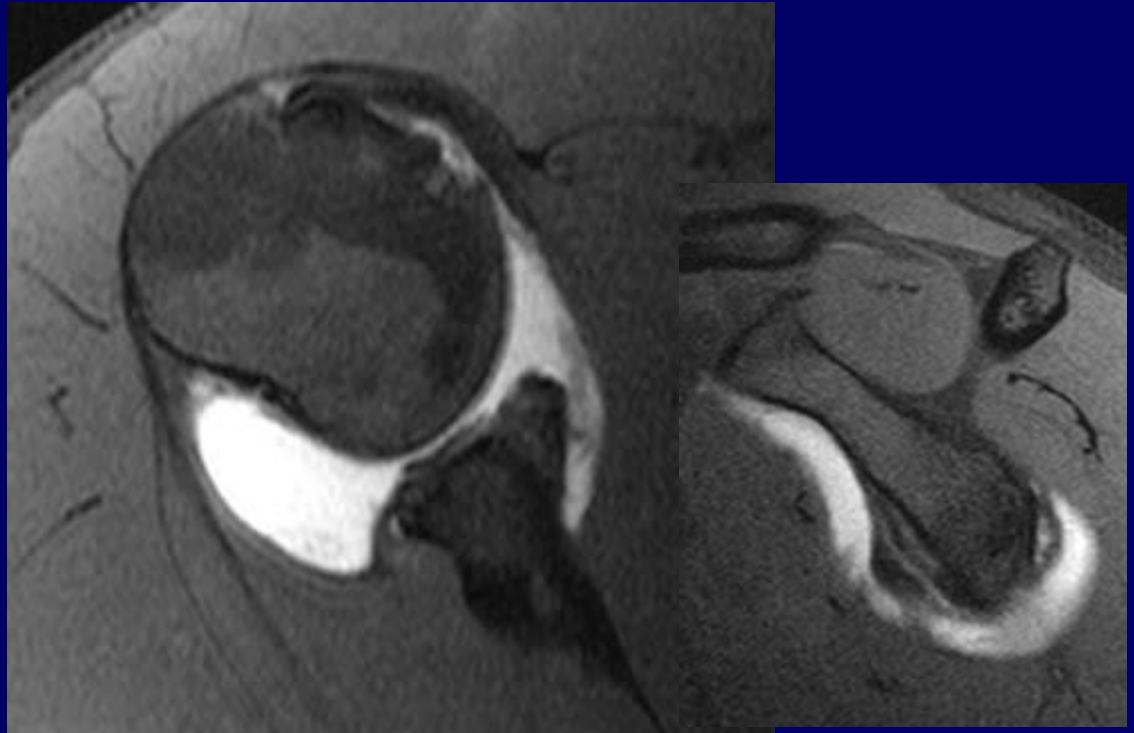
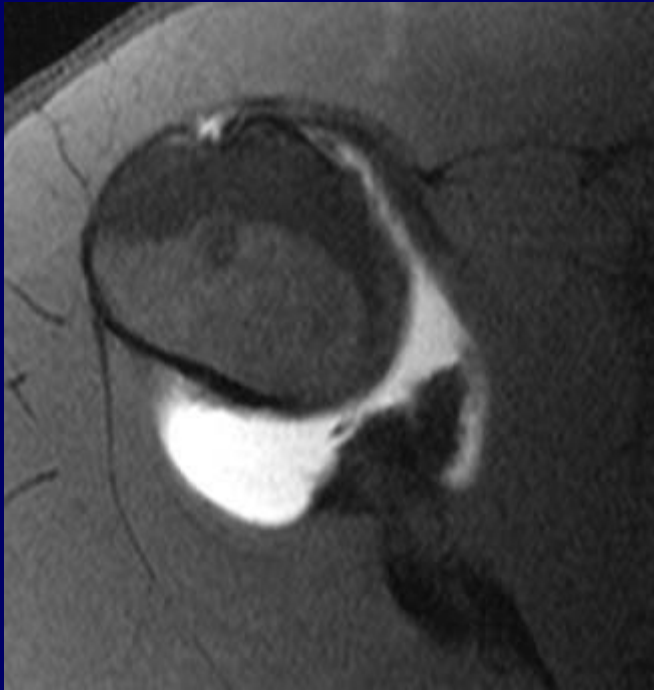
CASE

40 y/o policewoman with acute shoulder injury while subduing a suspect. Findings of Anterior band glenohumeral ligament preiosteal sleeve avulsion with an intact subjacent labrum (ALIPSA)



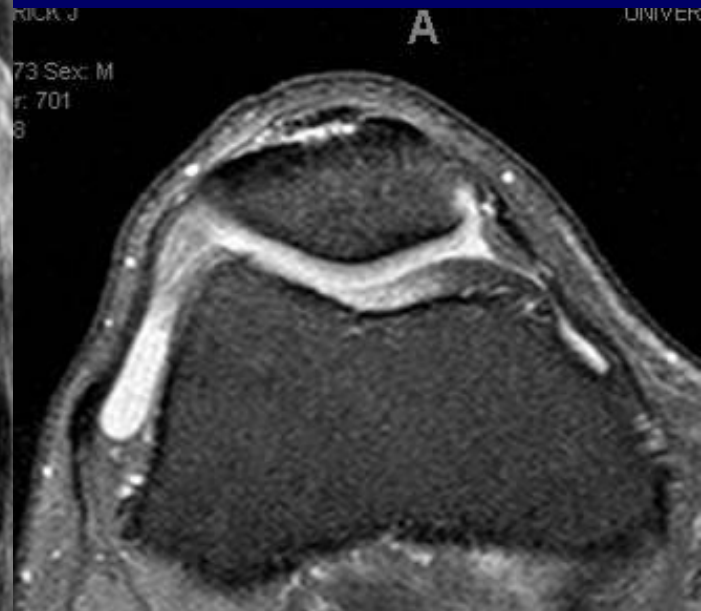
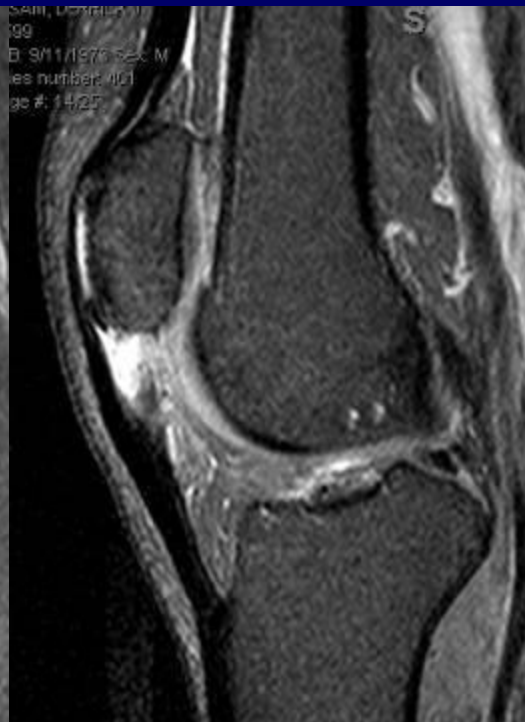
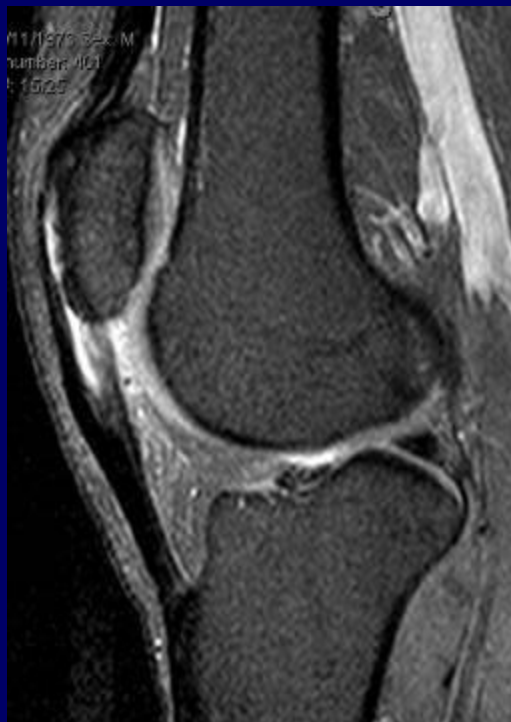CASE

25 y/o with chronic shoulder dislocations. MR findings of chronic bankhart or chronic alpsa.



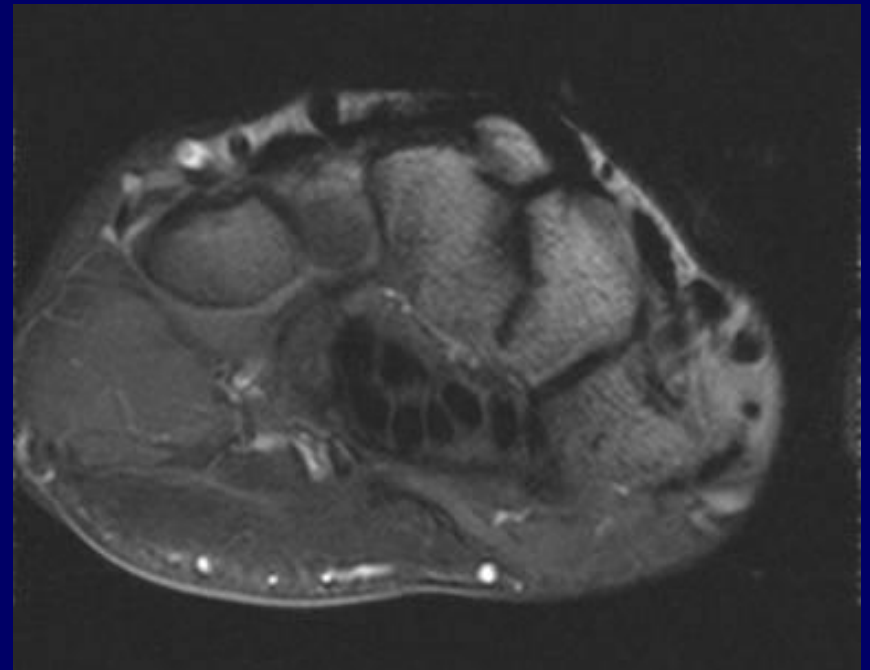
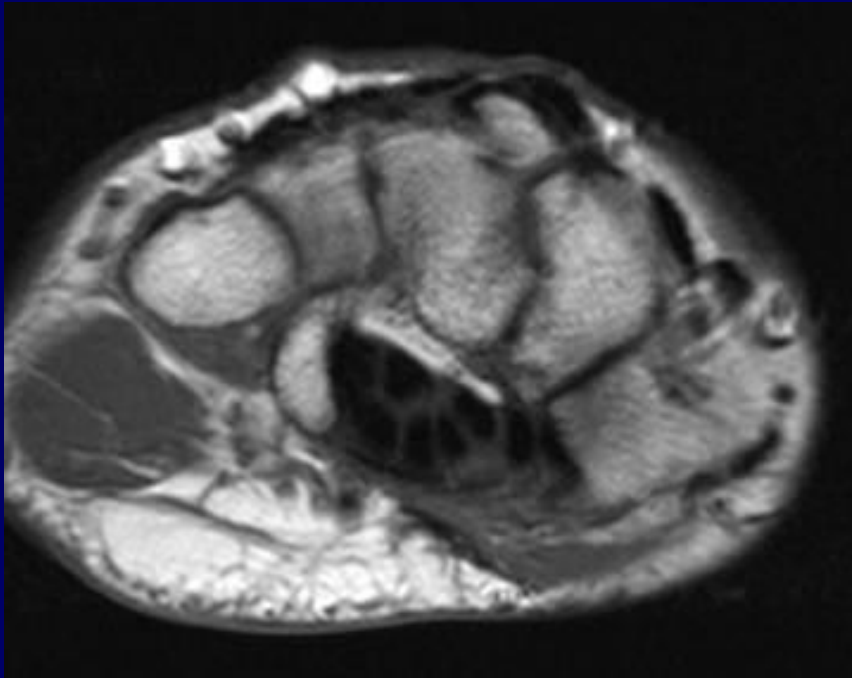
CASE

32-year-old male with right knee pain after softball injury 2 mos ago. Now presents with anterior knee pain and soreness.



CASE

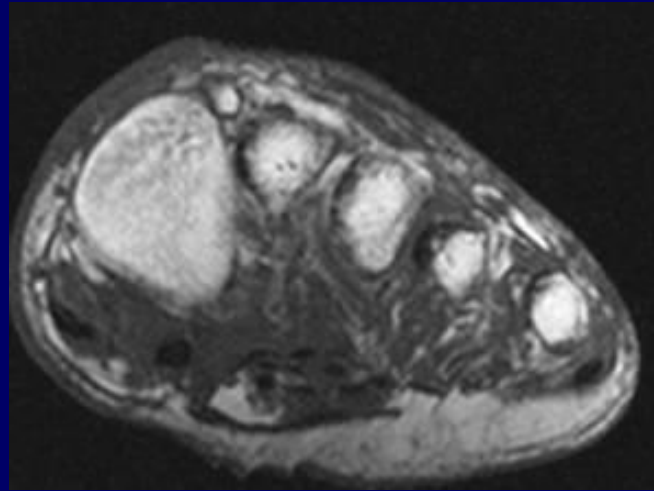
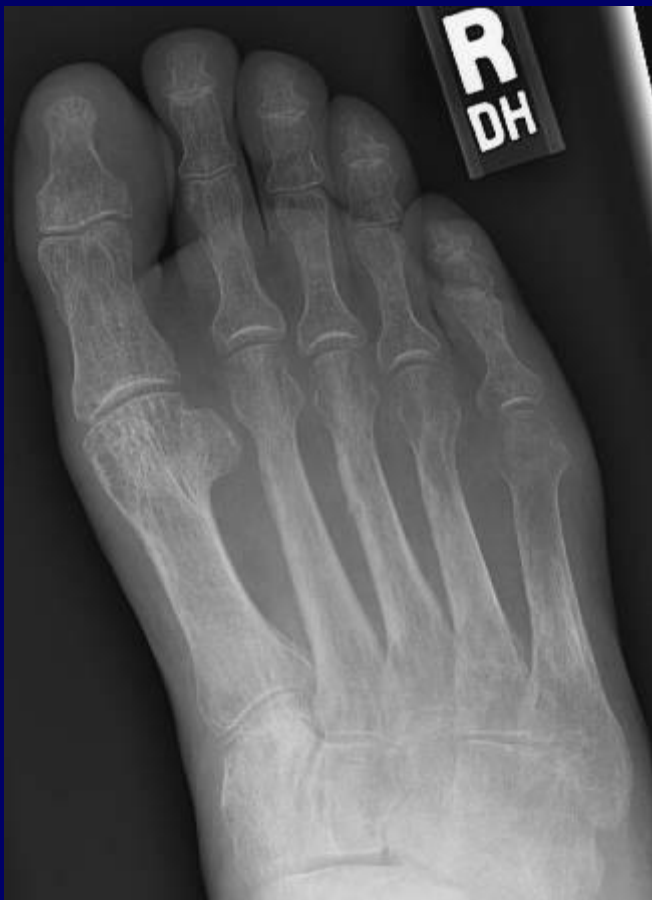40 YEARS OLD PAIN IN HAND



Carpal boss

CASE

91 YEARS OLD PAIN ON THE DORSAL
ASPECT OF FOOT



Os
intermetarseum

