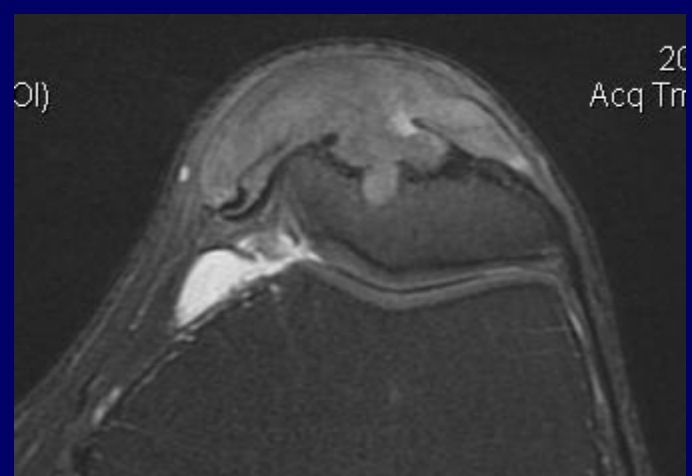
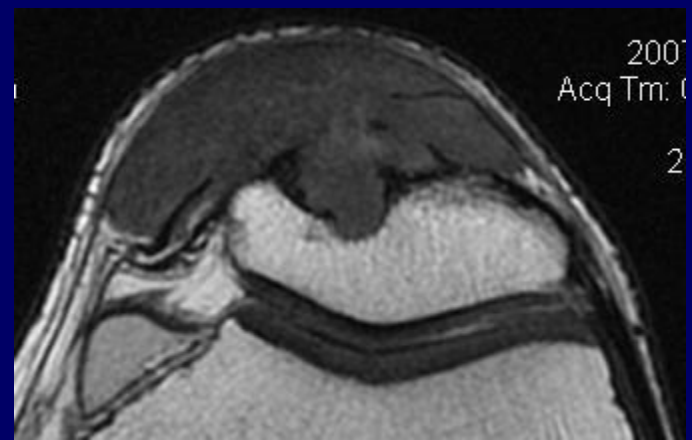
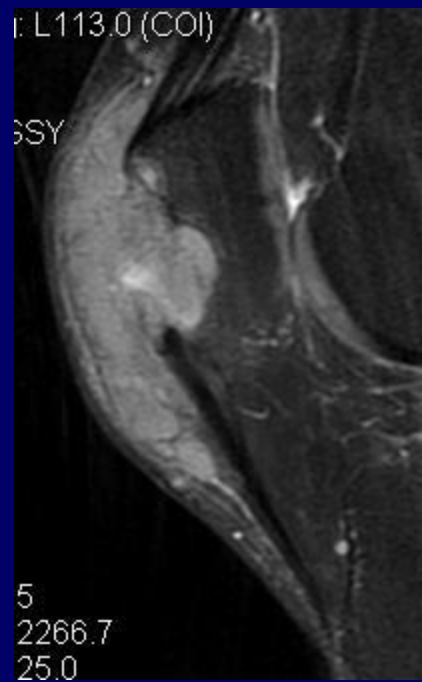
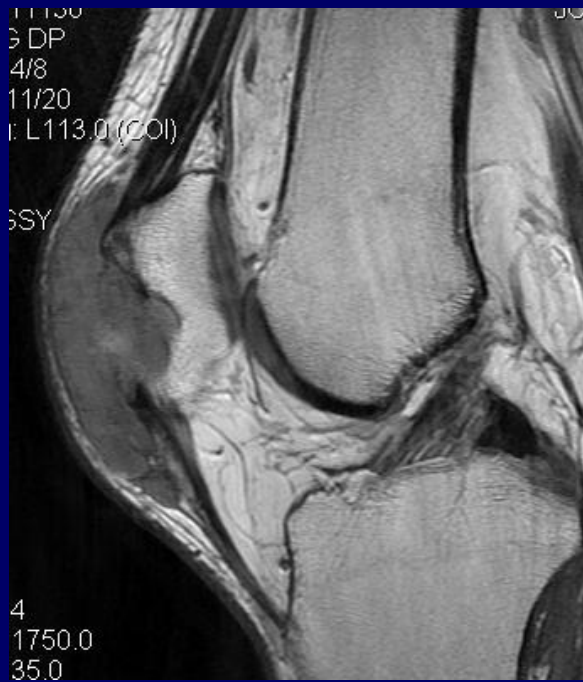

OCTOBER 18, 2007

# CASE

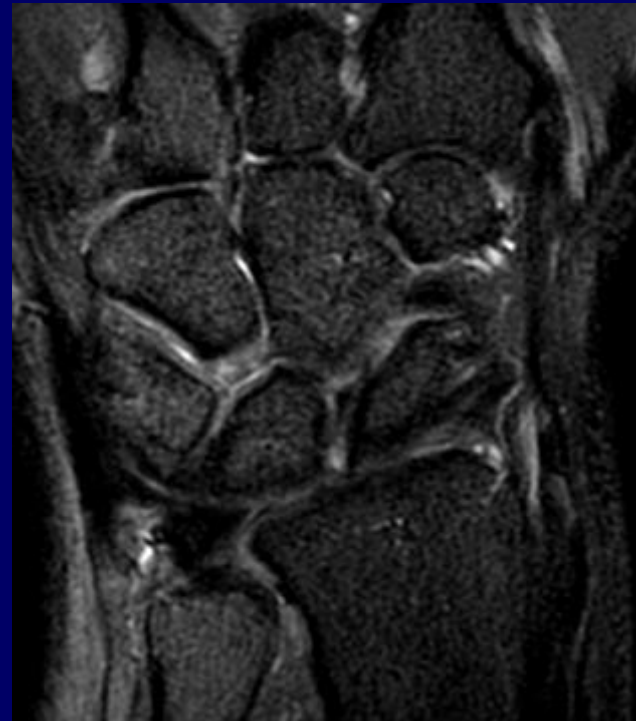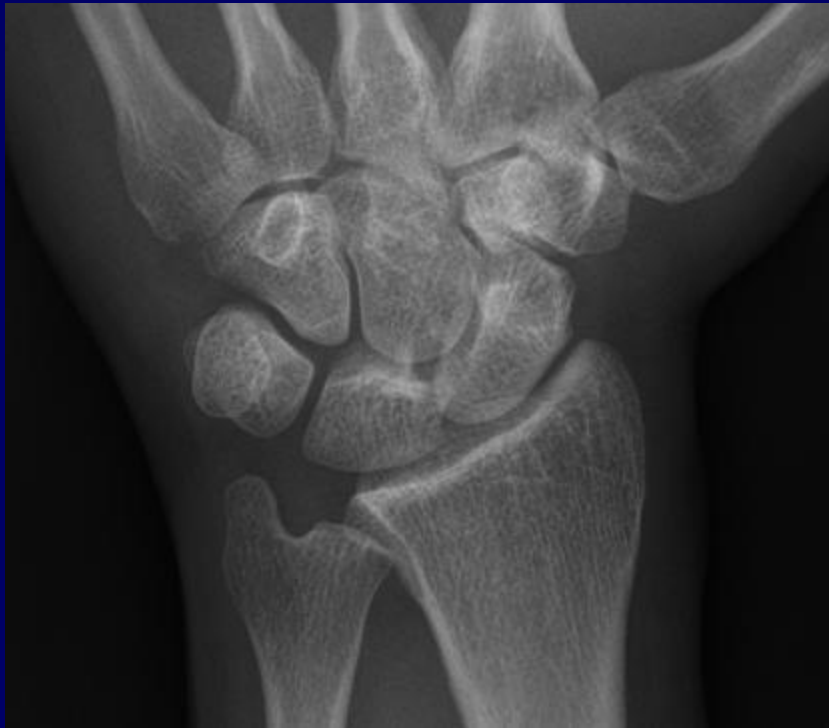
- Hx – PROGRESSIVE KNEE PAIN. R/O TUMOR



M D'ABREU

GOUT

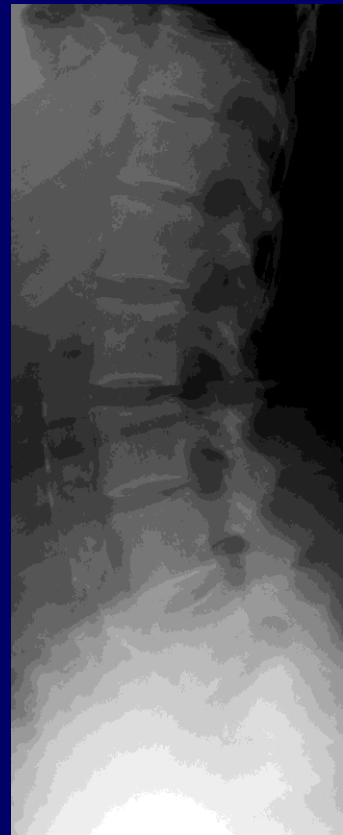
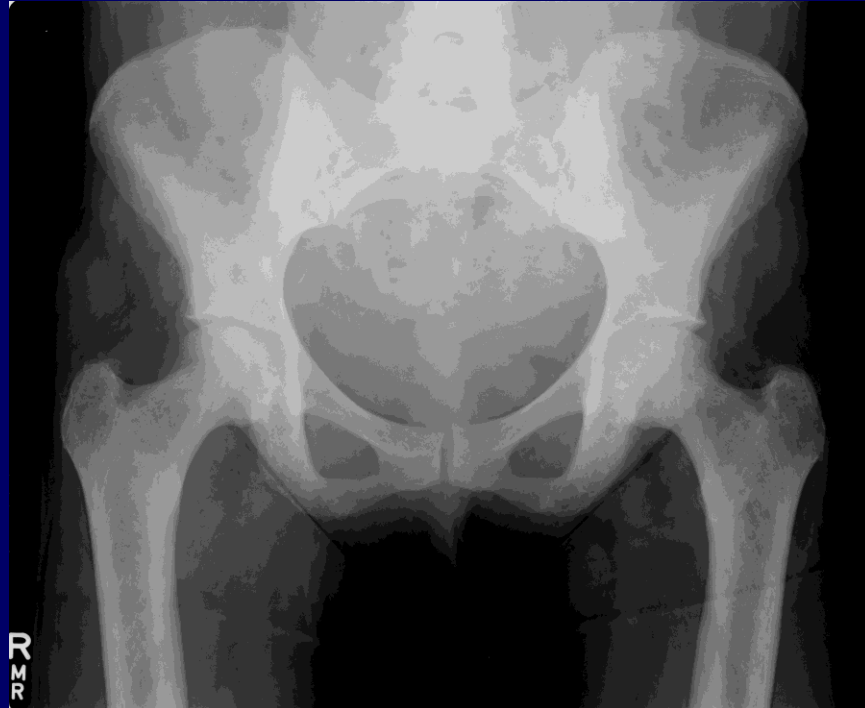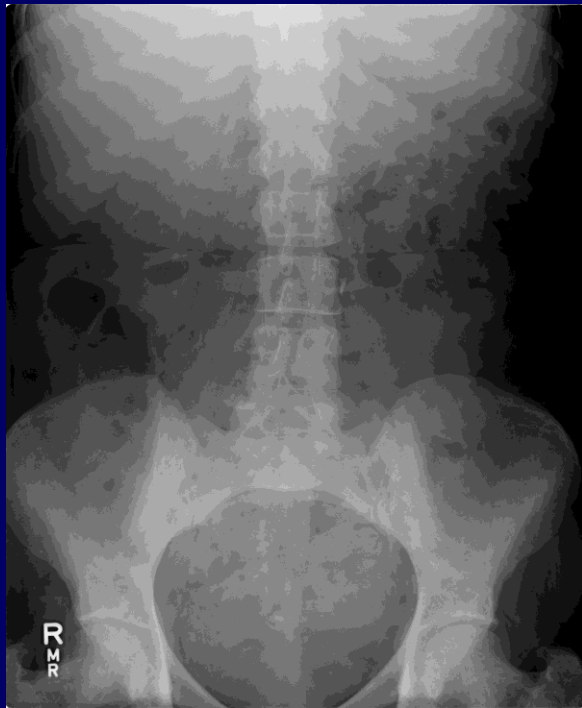# CASE



LUNATE – HAMATE ARTHROSIS

# CASE

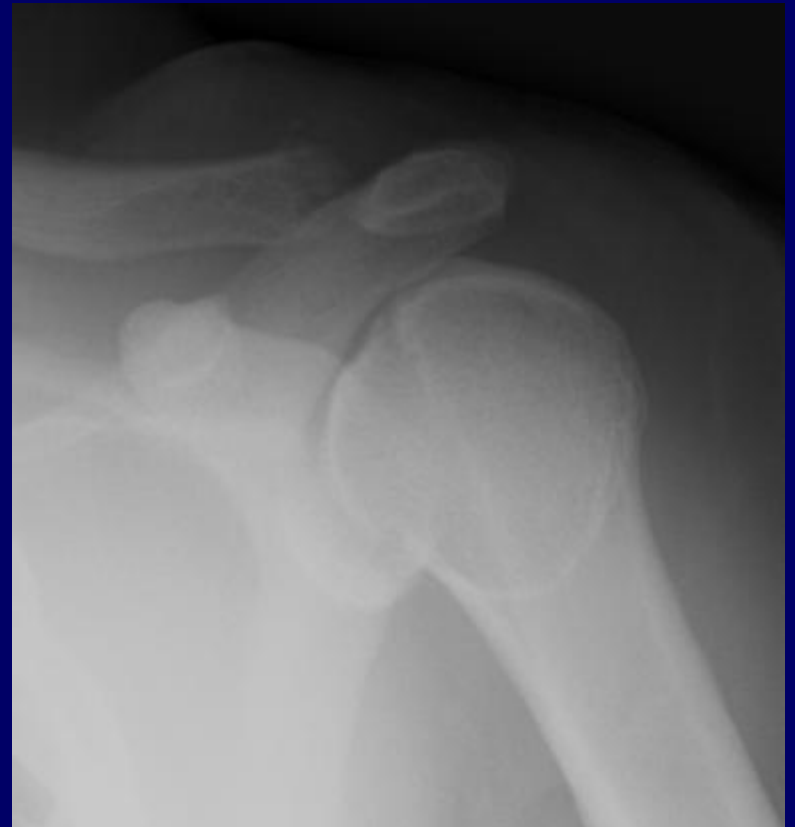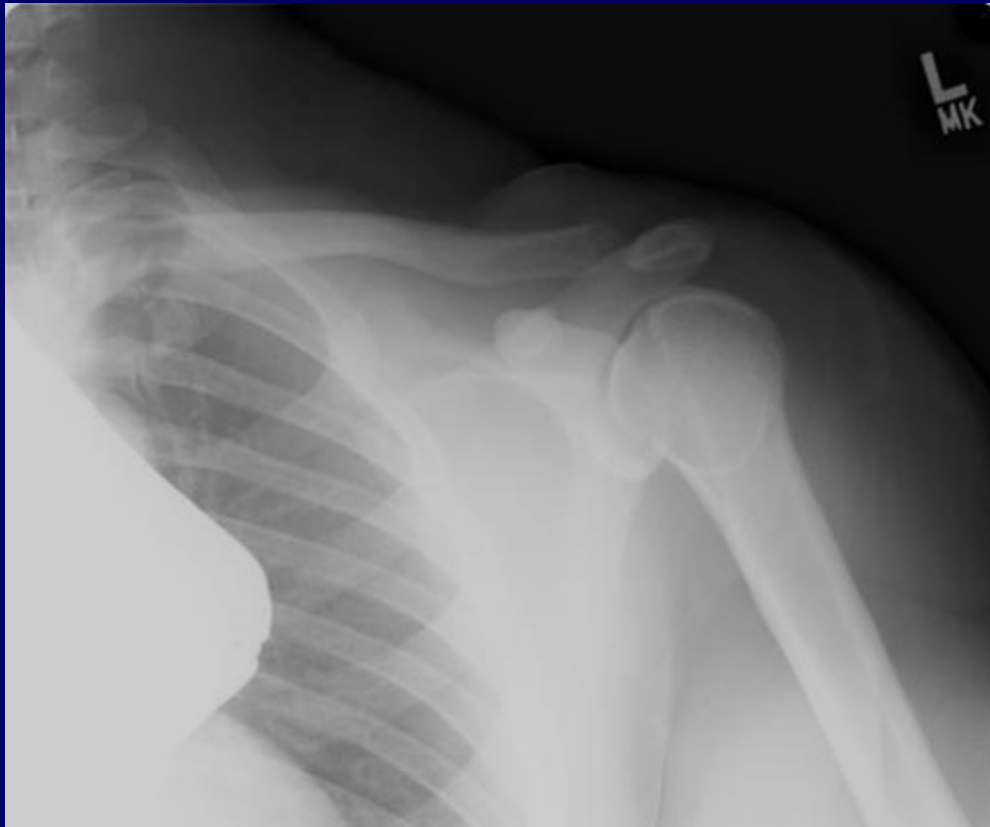64 y/o MAN WITH KNOWN DIAGNOSIS



MASTOCYTOSIS

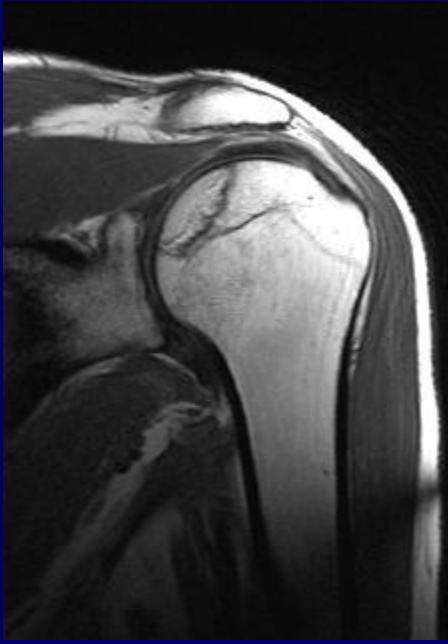
# CASE

weightlifter's osteolysis

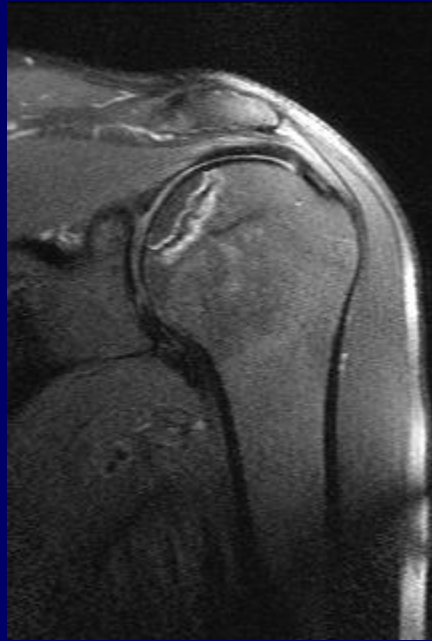


# CASE

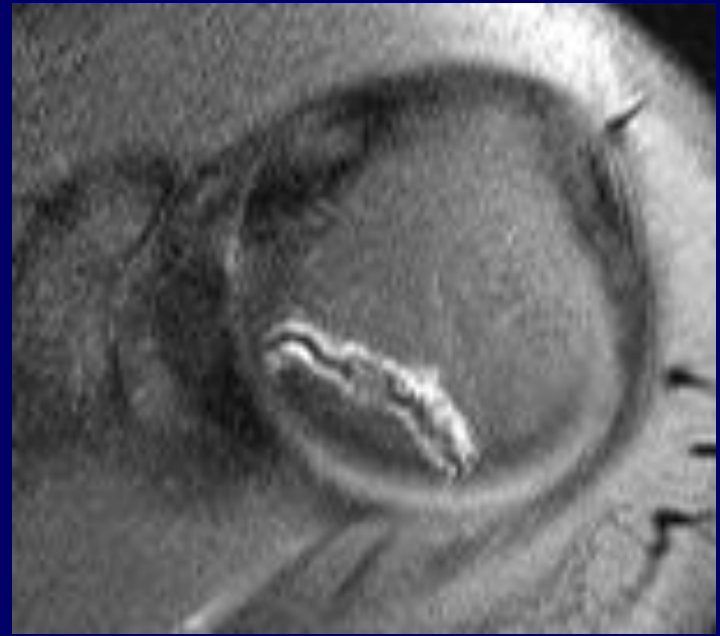
45 year old male with left shoulder  
and neck pain



T1

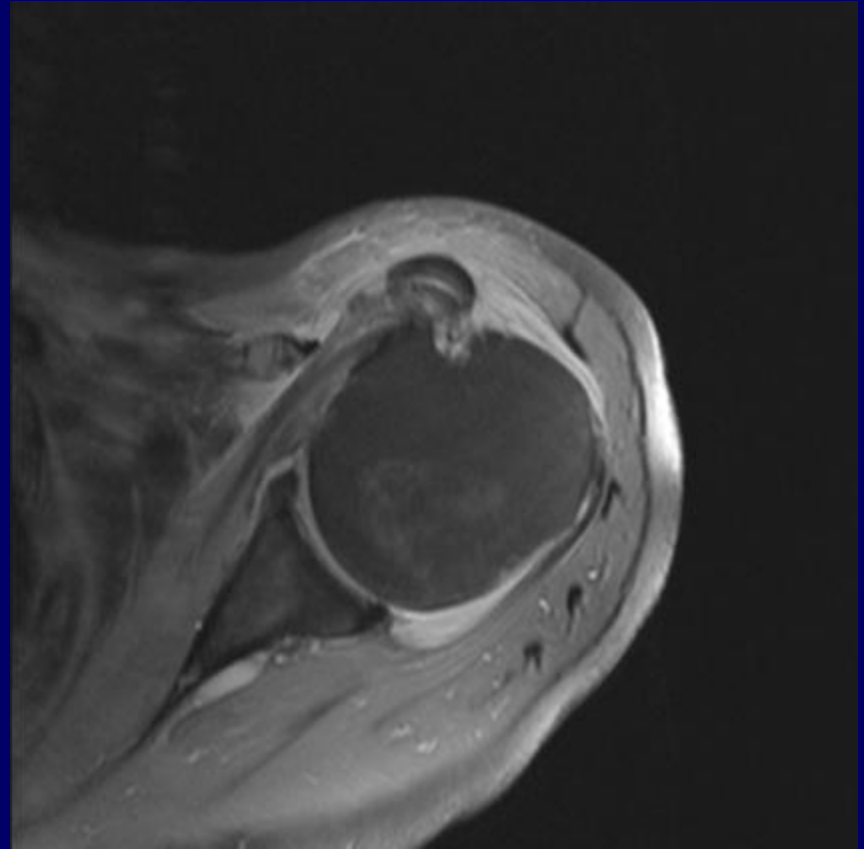
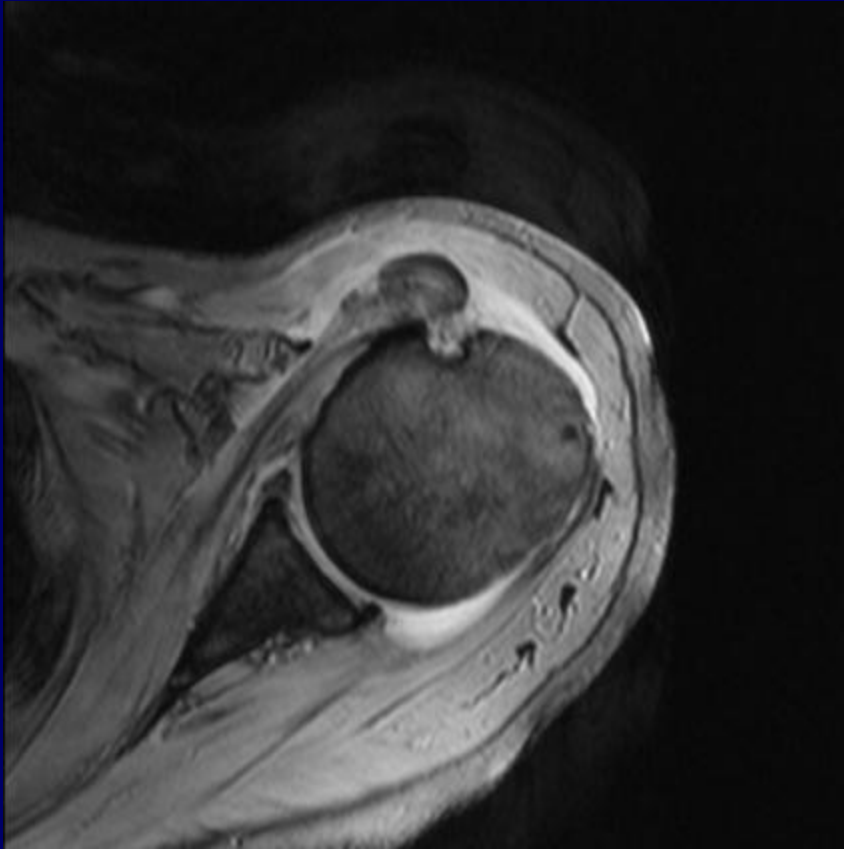


T2 FS FSE



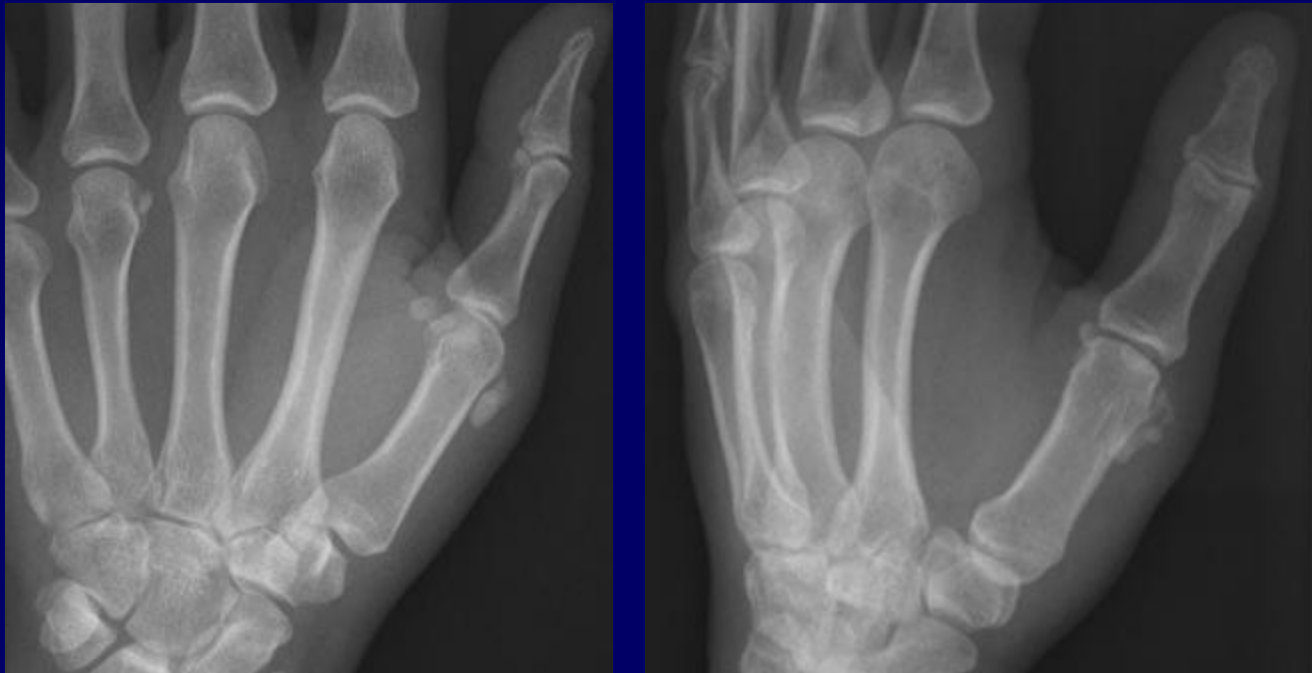
# CASE

## HADD WITH TENDON DELAMINATION



CASE

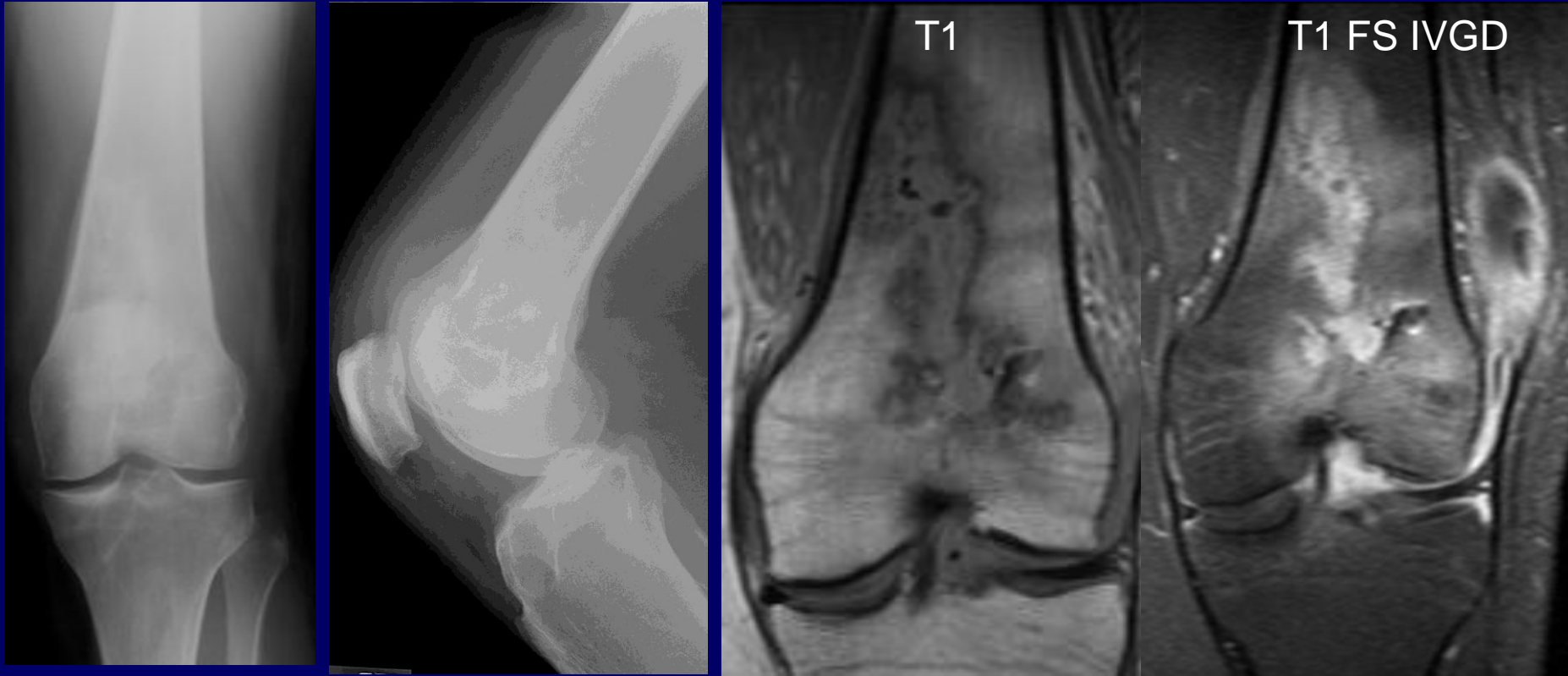
HADD





# CASE

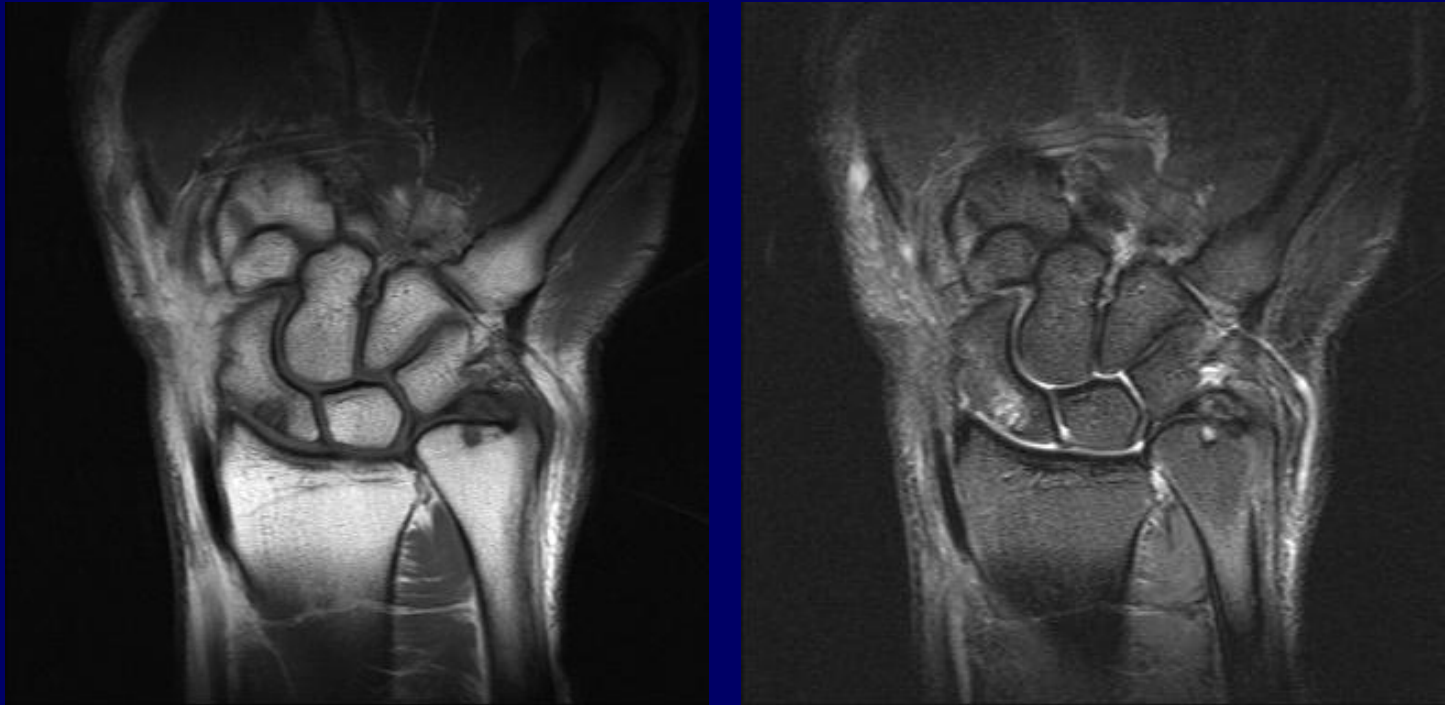
26 year-old status ACL reconstruction.



PSEUDOMONAS OSTEO MYELITIS AND SEPTIC ARTHRITIS

# CASE

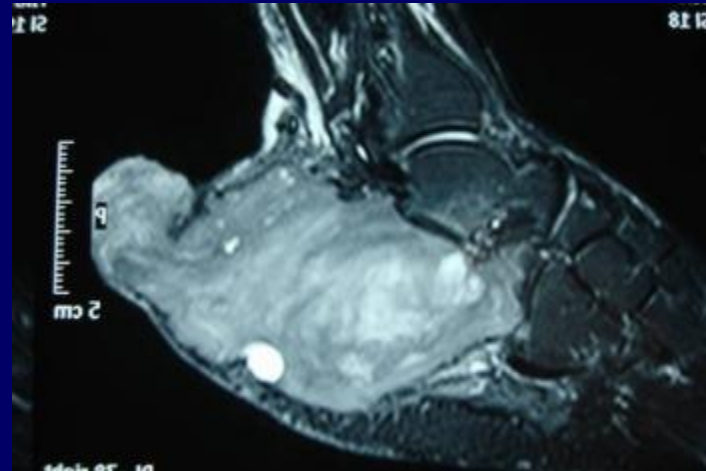
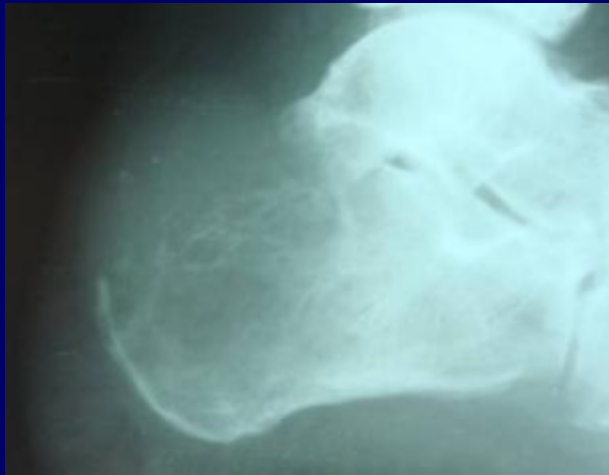36 y/o golfer with wrist pain



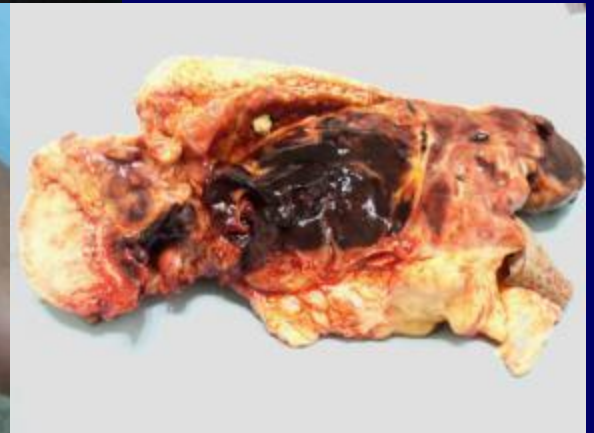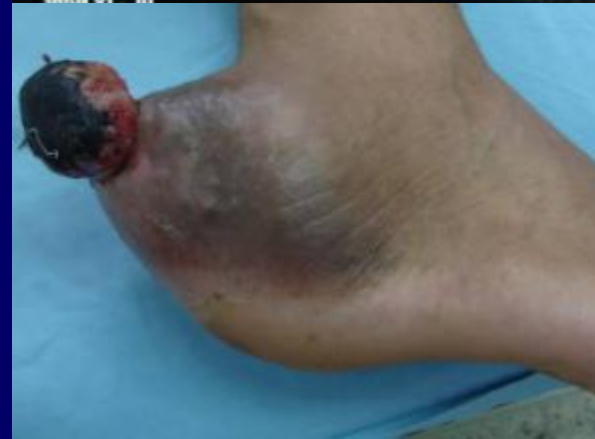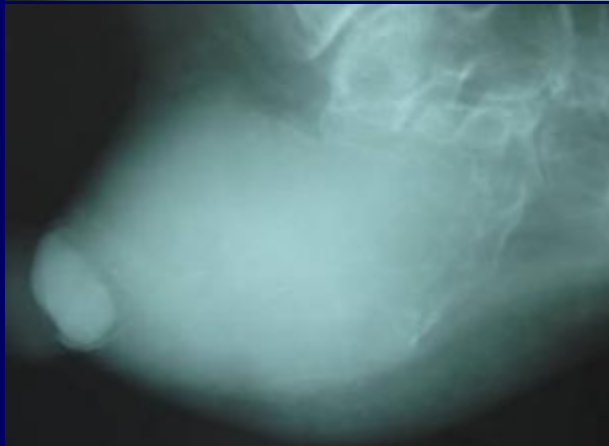
ULNAR POSITIVE VARIANCE

# CASE

YOUNG MAN WITH SLOWLY ENLARGING MASS

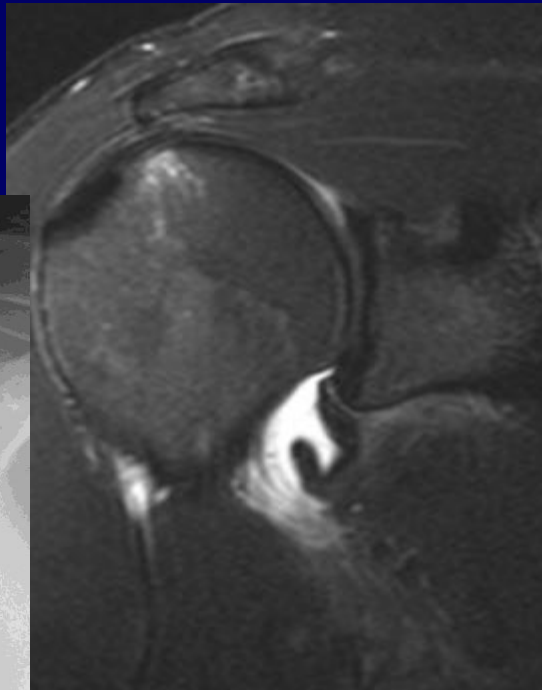
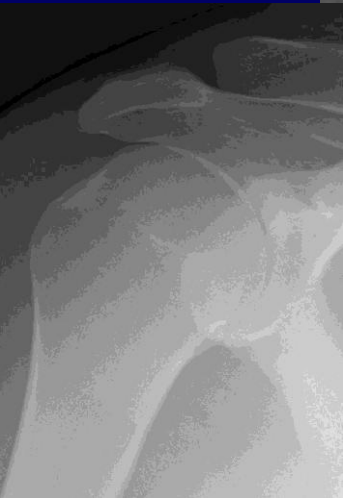


GIANT  
CELL  
TUMOR

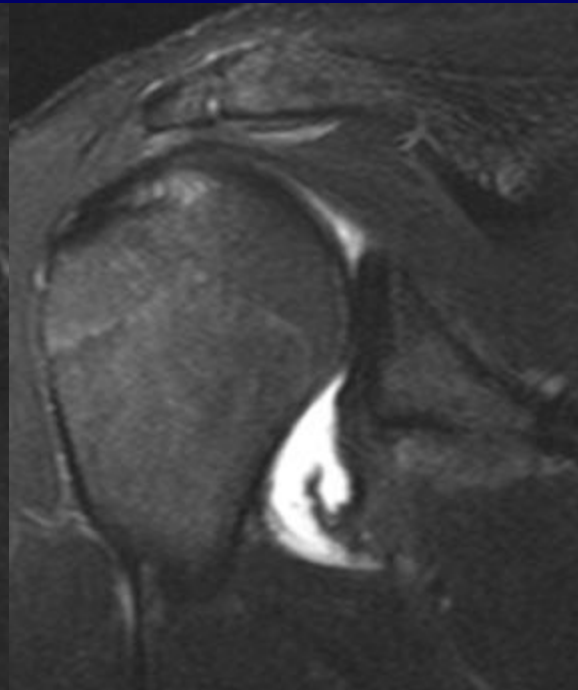


# CASE

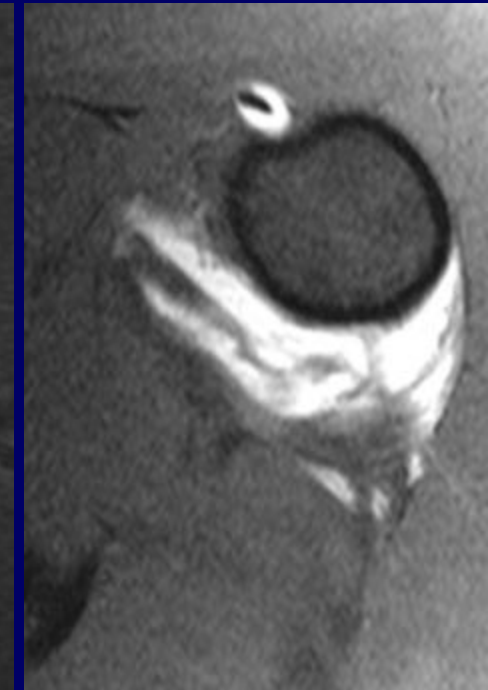
23 year old minor league baseball player with shoulder injury while sliding into base. Pain is posterior in location.



ANTERIOR

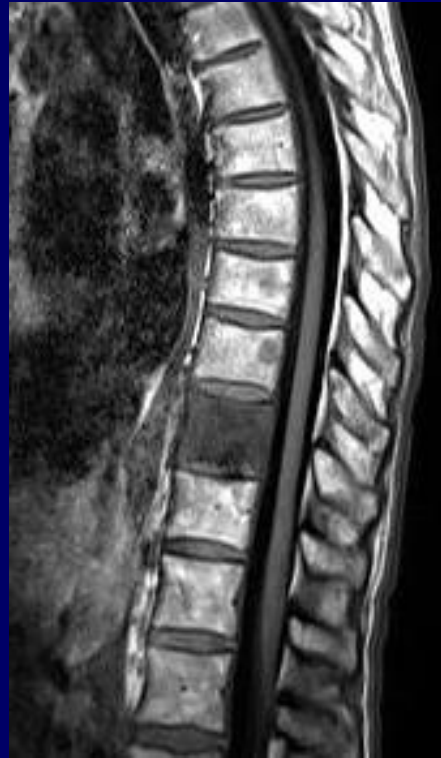


POSTERIOR

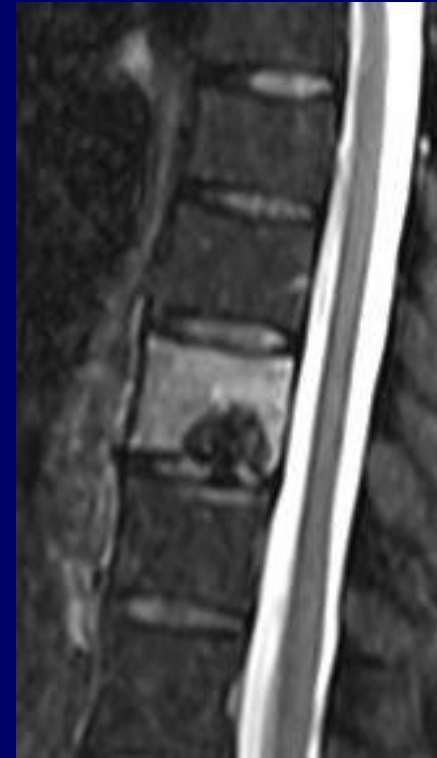


HAGL, PHAGL, AND AXILLARY POUCH DISRUPTION

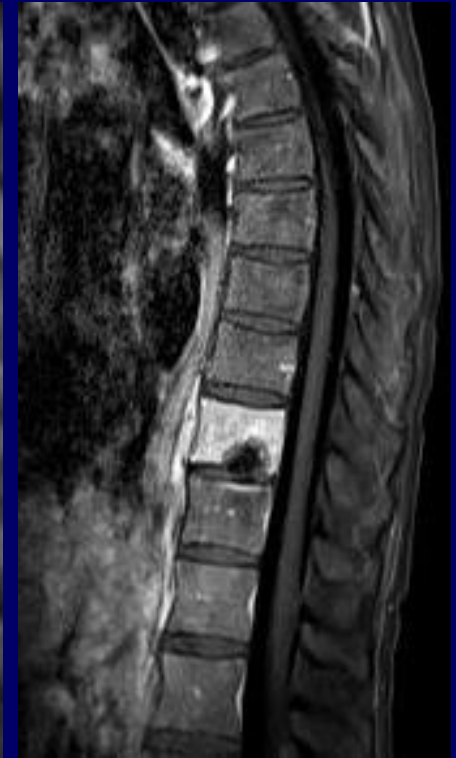# CASE



T1



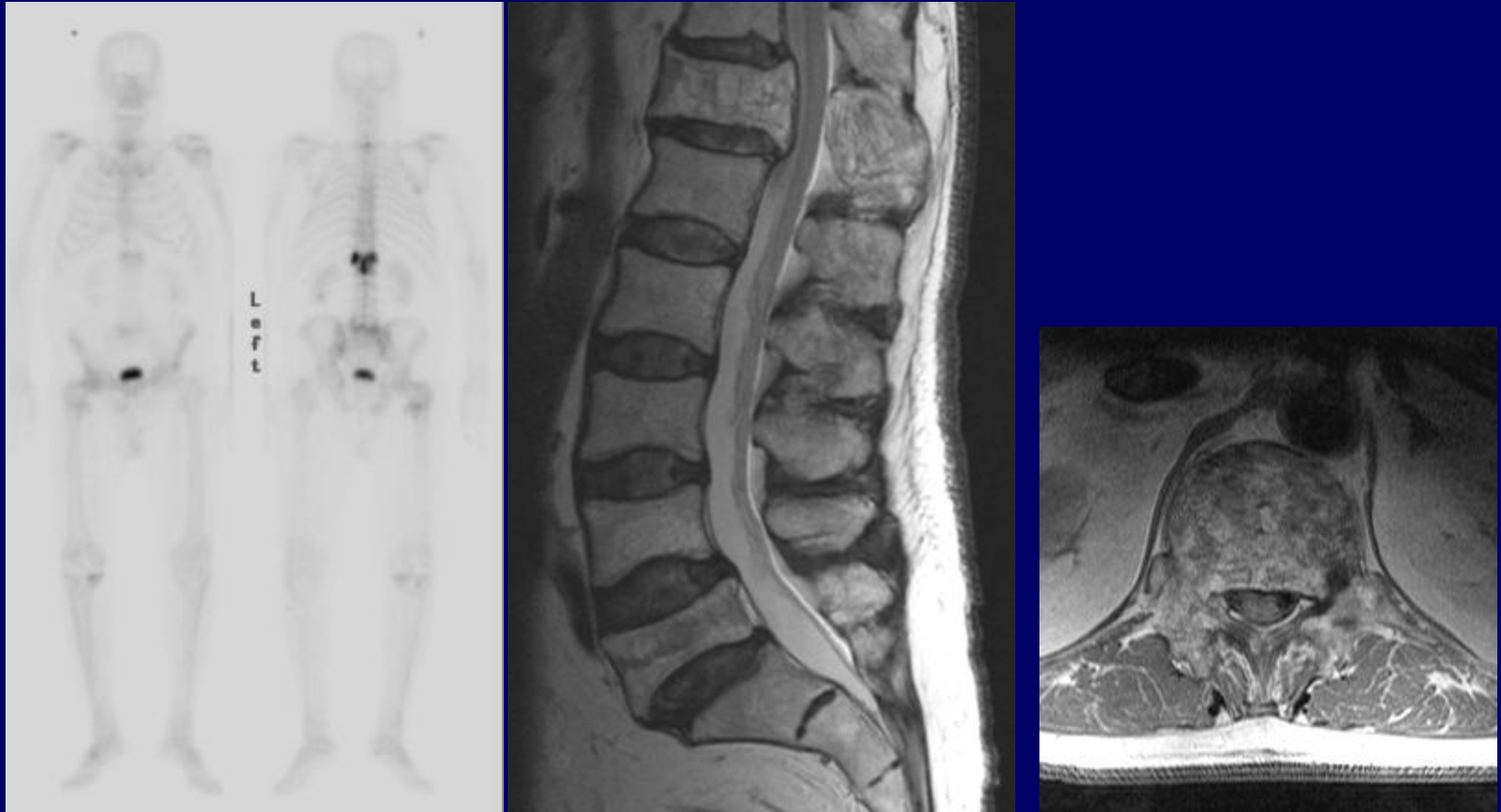
T2FS FSE



T1 FS IVGD



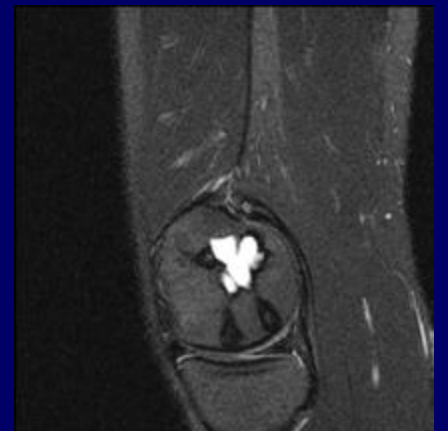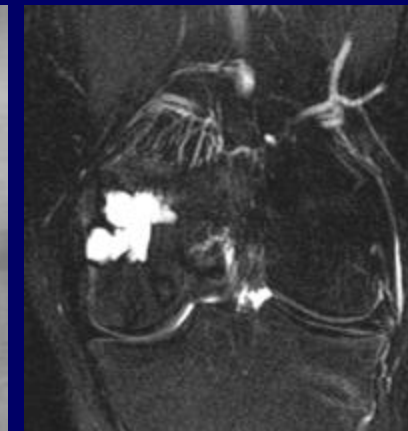
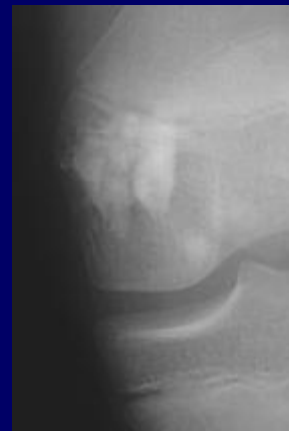
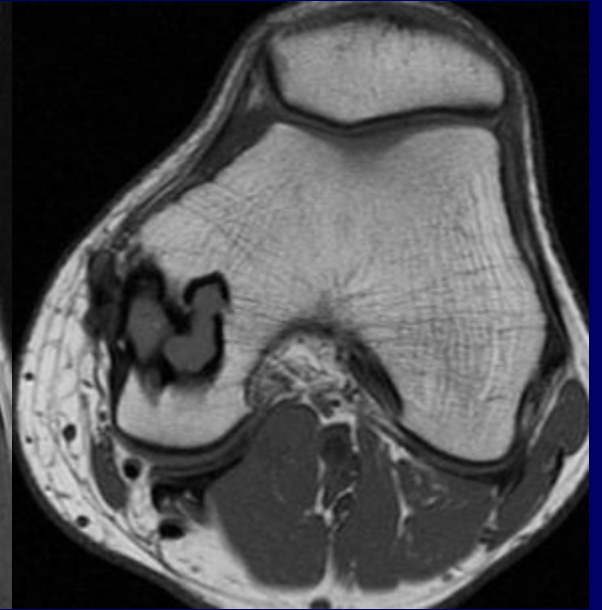
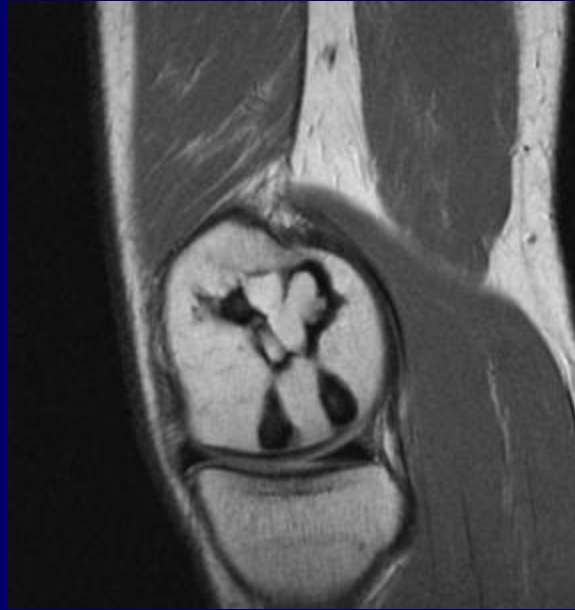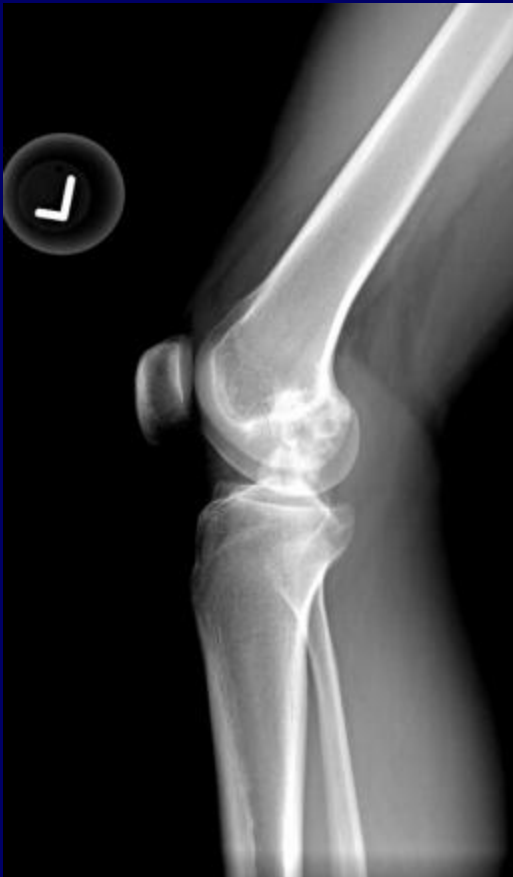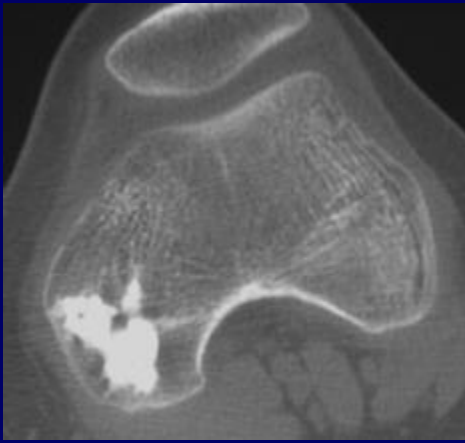
# CASE



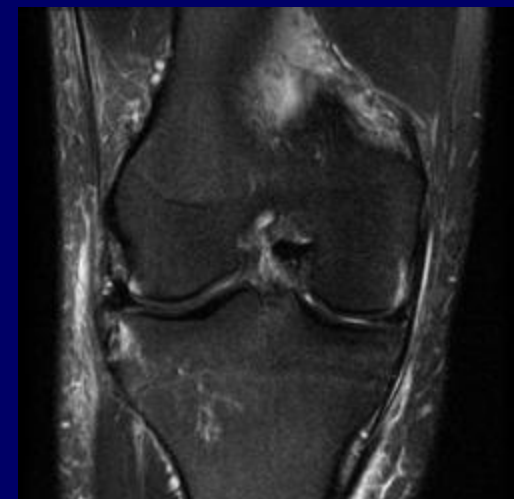
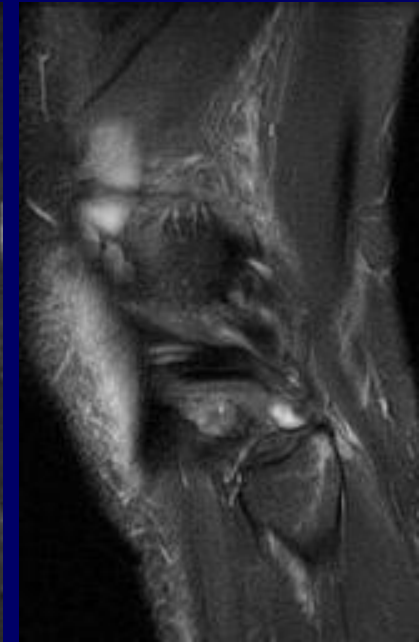
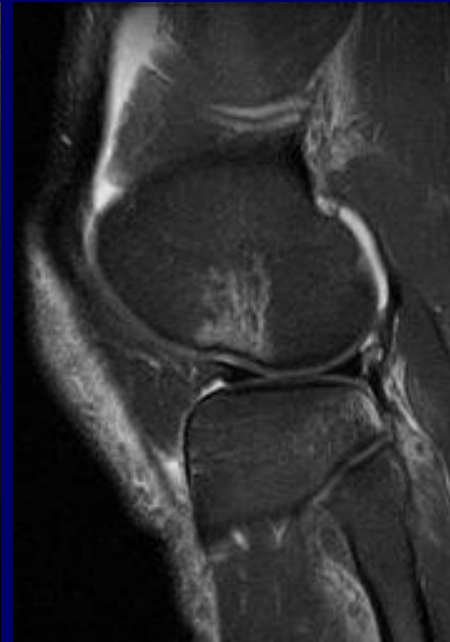
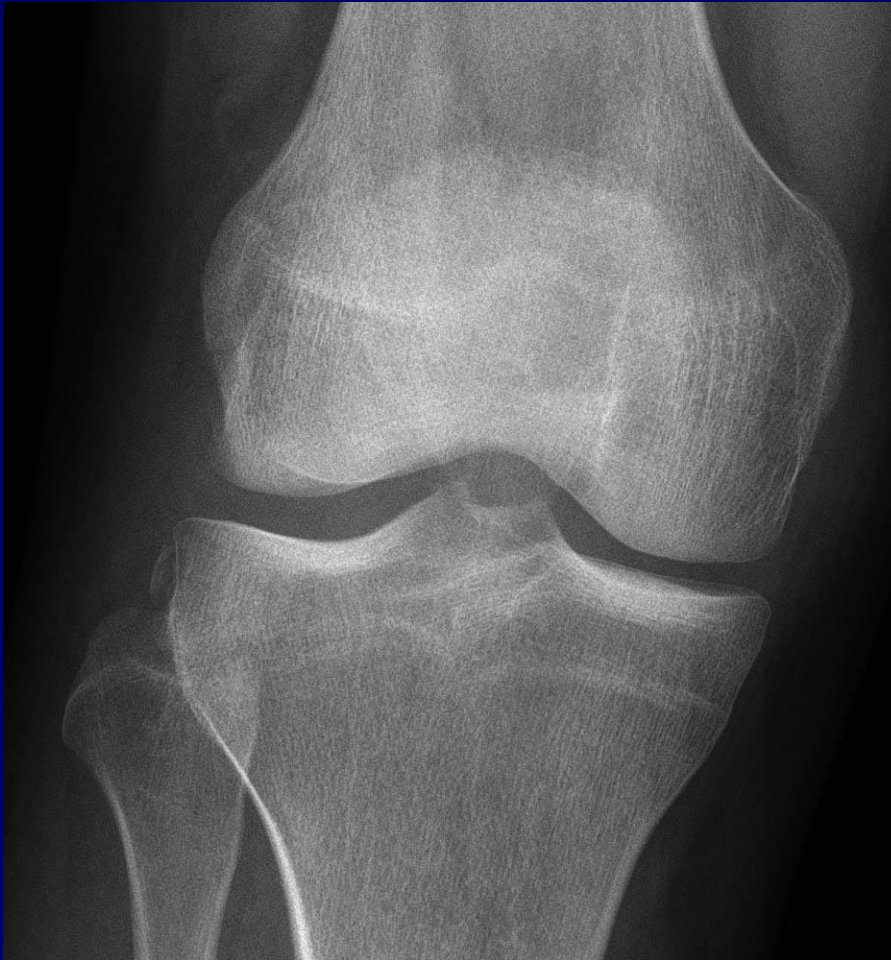Paget's disease

# CASE

? MELORHEOSTOSIS



# CASE



**FLEXION, IR, VARUS-VALGUS**

D GOODWIN