

Arthrography

General indications

- Assessment of internal derangement
- Intraarticular bodies
- Aspiration for sepsis or crystals
- Steroid injections
- Diagnostic LA injection

General Arthrography Technique

- Consent
- Clean
- LA usually
- Enter joint
- Aspirate
- Confirm position with contrast
- Contrast flows away from needle
- Use dynamic subtraction if available esp. wrist
- Stop if blob
- Fill joint with appropriate contrast
- Take full series no matter what

Technique

Septic arthritis

- Some Lidocaine is bacteriostatic – avoid in joint
- If dry tap
 - Confirm needle position with air
 - Non ionic contrast probably not bacteriostatic
 - Irrigate with - Non bacteriostatic saline
 - Use bung on syringe, or transport medium

MRI Arthrography Technique

- Gd 1:200-250 dilution
- Tech. usually adds 1ml of Gd to 100ml bag of saline (or 5 to 500)
- You draw up 10mls of this and add 10 mls of 300 mg/dl iodine = 1:200 Gd
- Don't dilly dally after injection
 - Contrast is absorbed from joint
 - Especially in synovitis
 - Check MRI is ready for patient

MRI Arthrography

Indirect Technique

- 10mls of Gd IV
- Wait 15-30 mins to scan
- Best with inflammed joints

Anaesthetic Arthrography Technique

- Inform patient - Pain will recur prior to steroid effect
- Keep a diary - Activity V's pain
 - Until see referring physician
- Record where contrast/LA goes
- Second dose usually more effective
- Keep it simple
 - Only use Bupivacaine/Marcaine if pain intermittent
- 1-5mls of 1% sufficient
- Give steroid first before joint fills up
 - Top up with LA
 - Patient wants the steroid

Single contrast - Iodine

- Most commonly used in shoulder
- Outlines articular surface
- Combine with CT for knee menisci
- 240 mg/dl

Single contrast - Air

- No iodine
- Usually combined with CT
- Best for IA bodies inc. GSW
- Most commonly used in elbow

Double contrast

- Tiny amount of iodinated contrast to line joint
- Fill up with air
- CO₂ rapidly absorbed
- Shoulder with CT for labrum
- Shoulder for rotator cuff tear

Joint volumes

- Shoulder 10-12 mls
- Elbow 5 mls
- Wrist 2-3 mls
- Hip 10 mls
- Knee up to 50 mls
- Ankle 5mls
- Subtalar 3-5 mls
- TMJ 1 ml

General contraindications

- Few
- Controversial to inject contrast if aspirate pus

Imaging for Access

- Fluoroscopy usually sufficient
- CT may be of benefit for SIJ in elderly with OA to see osteophytes
- Ultrasound probably complicates matters

Joint	Approach	Technique	Aristospan	Aristocort/ Kenalog	Depo- medrol	Dexa- methasone
Hip	Anterolateral	Fluoro	20mg	40mg	80mg	4mg
Knee	Subpatella	Fluoro	20mg	40mg	80mg	4mg
Ankle	Anterior	Fluoro	10mg	20mg	40mg	2mg
Subtalar	Lateral	Fluoro	5mg	10mg	20mg	1mg
SIJ	Posterior	Fluoro/CT	10mg	20mg	40mg	2mg
Shoulder	Anterior/Post	Fluoro	20mg	40mg	80mg	4mg
Elbow	Lateral	Fluoro	10mg	20mg	40mg	2mg
Wrist	Posterior	Fluoro	5mg	10mg	20mg	1mg
Sub deltoid bursa	Anterior	US	10mg	20mg	40mg	2mg
Tendon sheaths		US	5mg	10mg	20mg	1mg

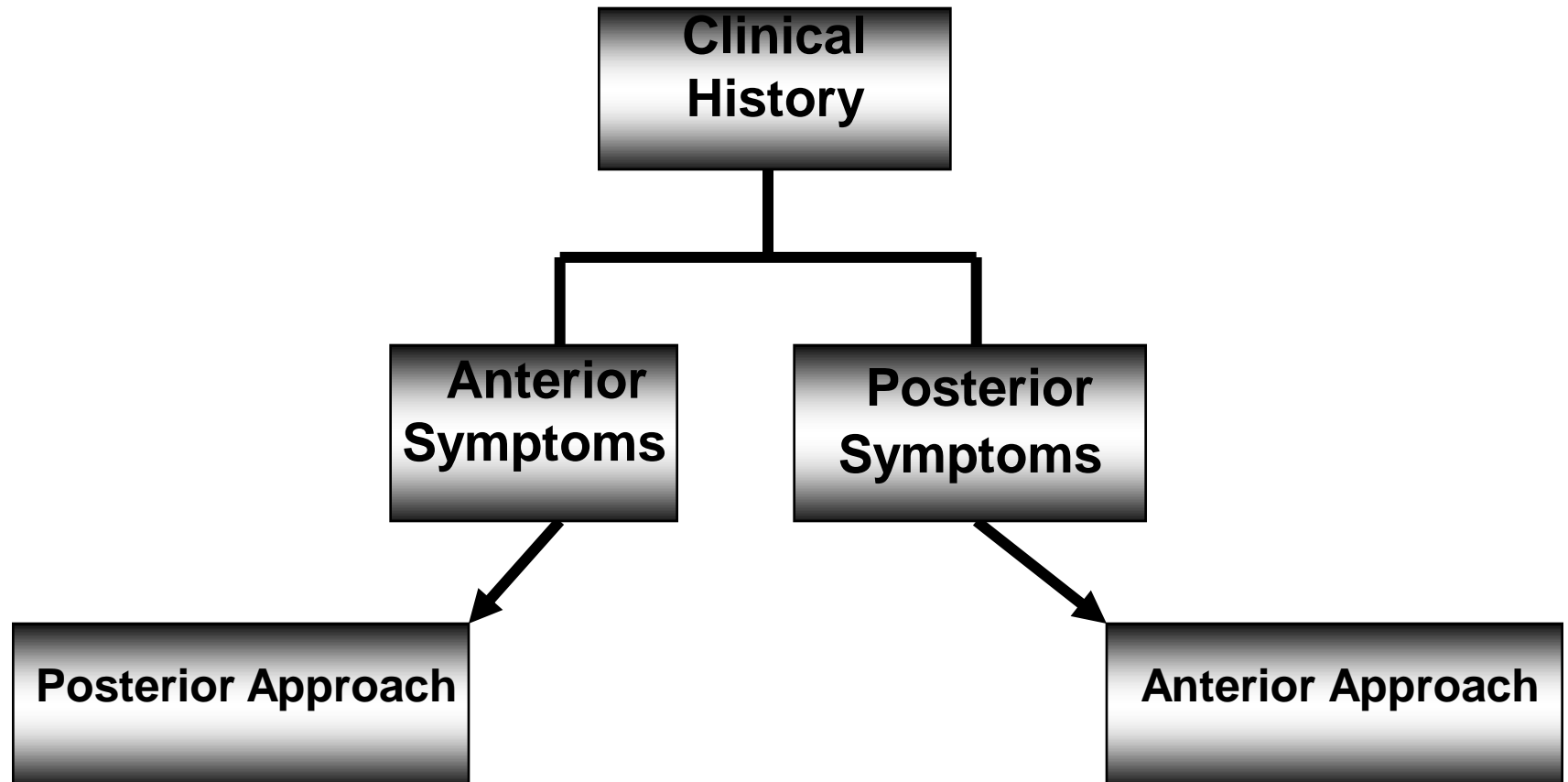
Double this is maximum at one time, can be repeated after 3/12

Shoulder Arthrography

Indications

- RCT
- Labral pathology
- Synovitis
- Adhesive capsulitis

Tailored Approach to MR Arthrography



Shoulder Arthrography Technique

- Anterior approach
 - External rotation
 - Keep below subcoracoid bursa
- Posterior approach
 - Internal rotation

Elbow Arthrography

Indications

- IA bodies
- Internal derangement

Elbow Arthrography Technique

- Hand on tummy or above head
- Neutral rotation
- Pad under elbow
- 38mm 21-23G

Elbow Arthrography CT

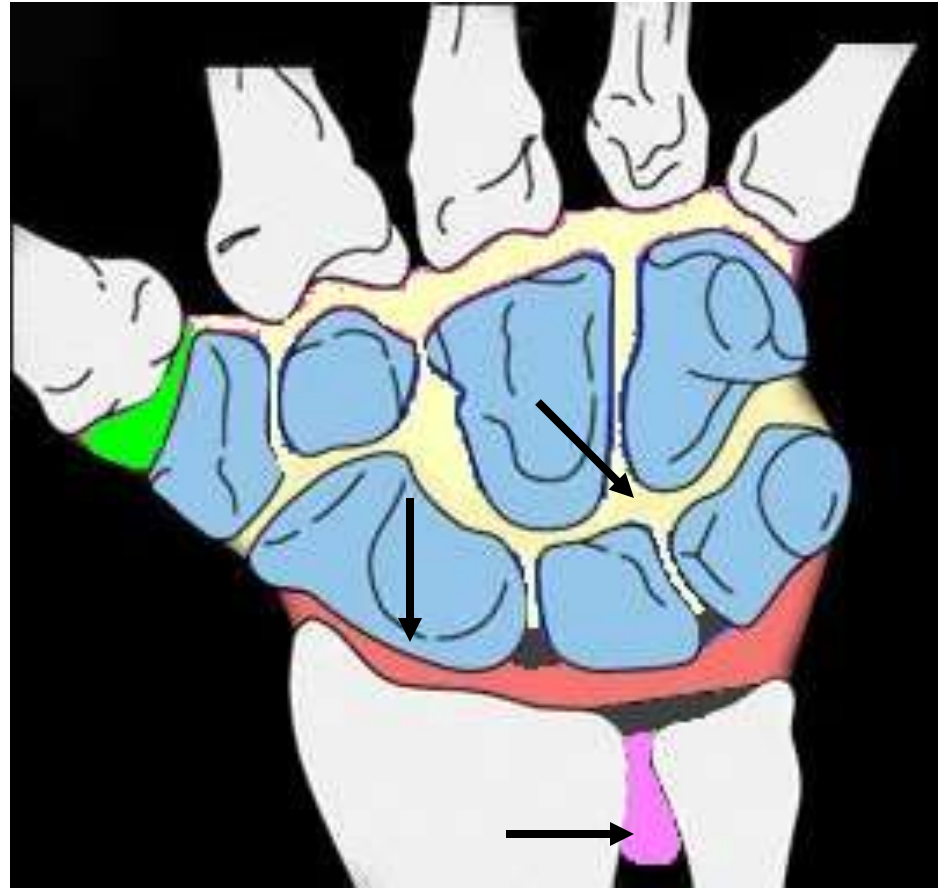
- Arm above head
- Avoid scanning in plane of radius and ulna
- Scan all injected contrast + or –
- 1-2 mm
- Recon all 3 orthogonal planes
- Less good – arm by side

Wrist arthrography

- Intercarpal ligaments
- Triangular fibrocartilage
- Scaphoid nonunion
- Soft tissue ganglia
- Wrist prosthesis

Wrist compartments

- First carpometacarpal
- Midcarpal, which communicates with common carpometacarpal
- Radiocarpal
- Distal radioulnar



Target sites

Wrist arthrography

- Controversy about which compartments and how many compartments need to be injected
- Most common single injection is radiocarpal

SIJ Arthrography Technique

- Remember anatomy
- Joint close together posterior
- Wide apart anterior
- Patient prone
- Roll onto side of interest to line up joint
- Aim for inferior joint

Hip Arthrography

Indications

- Labral pathology with MRI
- Post THR for loosening/infection
- Fistula confirmation
- Pain
 - Diagnosis
 - Lidocaine
 - Treatment
 - Steroid injection

Positioning

- Patient supine
- 15 degrees internal rotation of the hips
 - Toes taped together
- Knees slightly bent
 - Pillow under the knees

Hip Arthrography Technique

- Feel artery
- Draw artery on skin
- Nerve lateral to artery
- Mark mid neck
- Mark intertroch
- Aim in line of femoral neck
- THR start just lateral
- Contrast should not be in line of
psoas

Knee Arthrography

Indications

- Conventional arthrogram for meniscal injury
- Recurrent meniscal tear post surgery
- OCD stability

Knee Arthrography Technique

- Lateral V's medial
- 38mm 21G
- Prime needle and connecting tube
- Feel PF groove
- Imagine angle
- Single stab
- Finger on patella
- Alternative
 - Infrapatellar
 - Medial or lateral
 - Aim upwards

Knee Arthrography

Infrapatellar Technique

- One bit of advice regarding this approach - it is best to find the soft spot immediately below the inferomedial patella. This is simple if you put your finger on the patella, then slide down to the origin of the patellar tendon, then "slide off" the tendon medially. The key is not to go too inferior, because you will end up traversing a thicker part of Hoffa's fat pad and will need a longer needle.

Conventional Knee Arthrography Radiography

- Divide knee into 4 quadrants
- Medial front to back
- Lateral front to back
- Roll patient and stress to open joint
- Needs good tech

Ankle arthrography

Technique

- Feel dorsalis pedis
- Mark on skin
- Screen AP
 - Mark middle of joint
- Turn lateral
 - 38mm needle
 - 21 gauge
 - Either side of artery
 - Aim for joint

Subtalar Arthrography

Indications

- Usually anaesthetic arthrogram to determine source of pain

Subtalar Arthrography Technique

- Lateral approach
- Roll foot to work out which is lateral
- Fluoro mark anterior aspect of posterior joint
- Must record communications of joint
- CT may be helpful

TMJ Arthrography

Indications

- Clicking
- Pain
- Instability
- Negative conventional MRI

TMJ Arthrography Technique

- Palpate joint
- Mark
- Pray
 - Screening difficult
- Open the mouth with the needle on the condyle, then advance