

MR of the Pelvis and Hip

- Technique
- AVN
- Transient bone marrow edema
- Pelvic trauma
 - Bony
 - Stress
 - Occult
- Arthritis
 - Labrum
- Bursa
- Tendons
- Muscles
- Pediatric hip disorders
- Tumors

Technique

- Supine
- Prone if buttock mass or sacral ulcer
- Elevate femur parallel to tabletop

Pelvis/Hip MR protocol

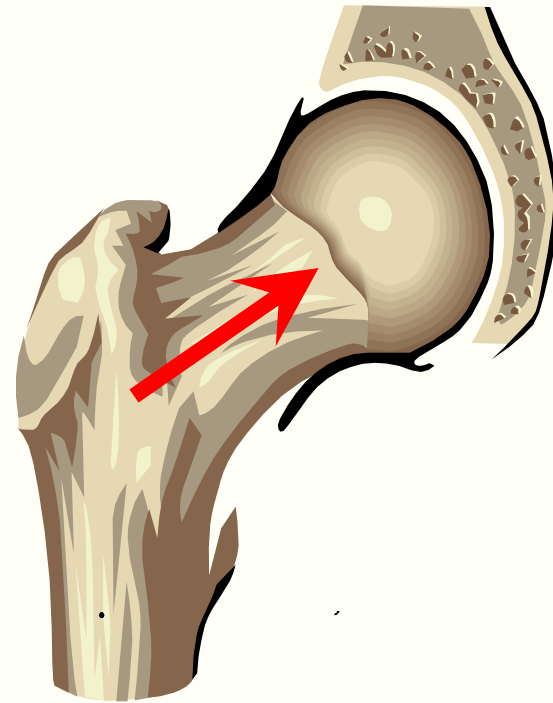
Plane	Seq	TR/TE	FOV	Slice	Matrix	NEX	Time
Localizer	FMPIR	3500/17/160	40	5	128	2	2:05
Coronal	T1 SE	600/14	36	5	192	1	4:50
Sagittal	T1 SE	600/20	20	4	256	1	6:24
Axial	T2 FSE-fs	3000/90	36	5	192	2	5:30
Coronal	T2 FSE-fs	3000/90	36	5	192	2	5:12

Hip MR Arthrography Indications

- Labral tear
- Paralabral ganglion
- Preoperative assessment of DDH
- Intraarticular bodies

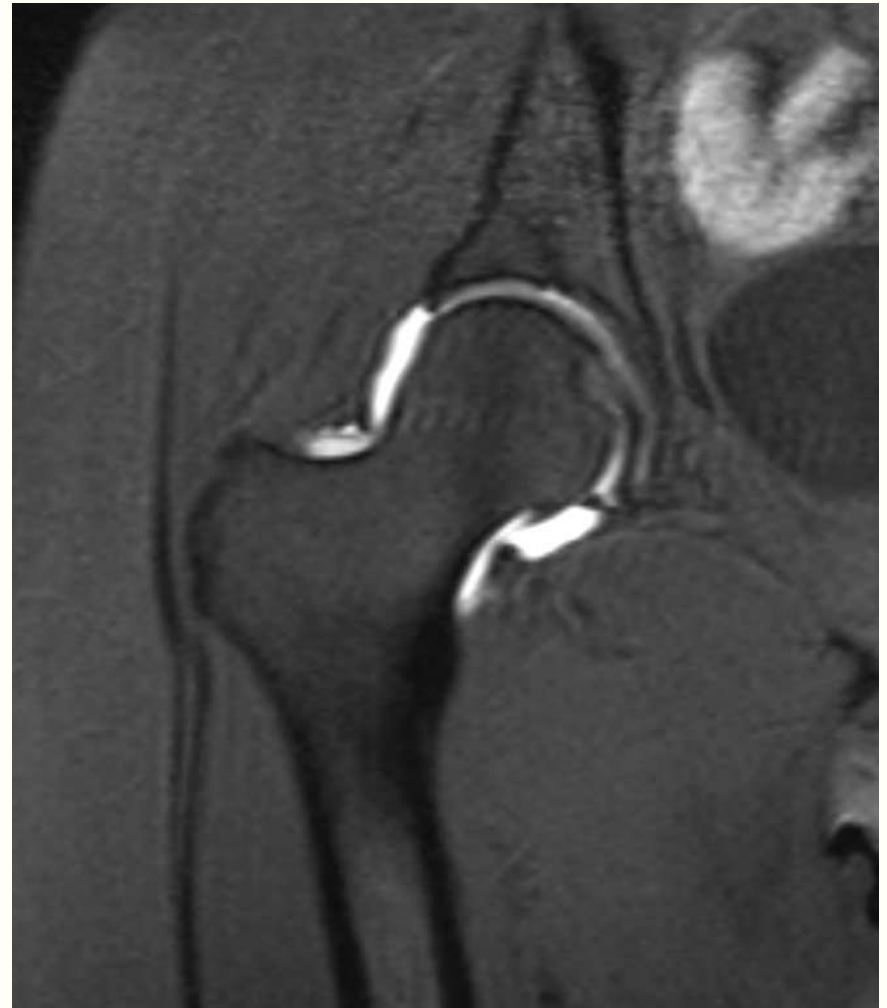
Hip MRA technique

- Local anesthesia
- Anterolateral approach to femoral head-neck junction
- Confirm needle position with <1 cc contrast
- Inject 12 cc of diluted Gd-DTPA



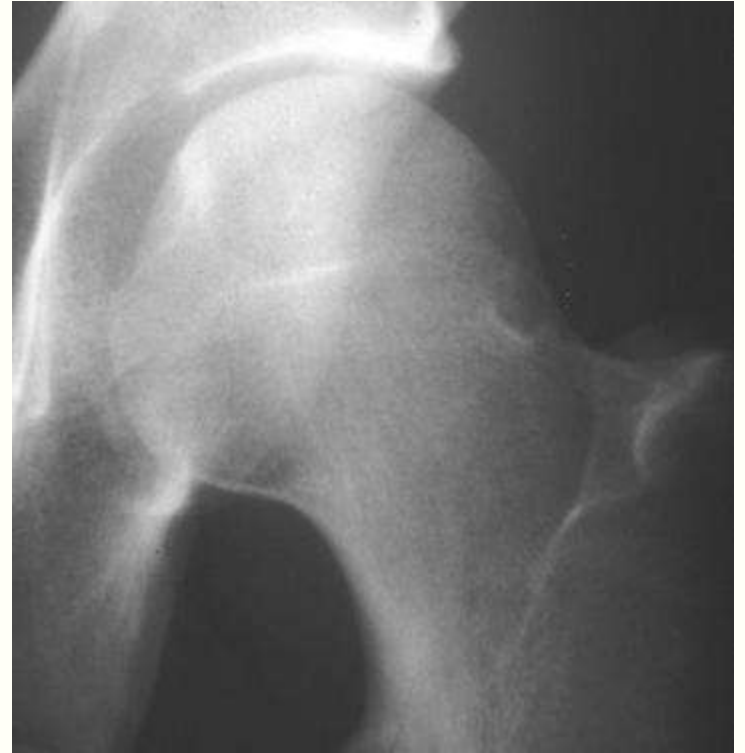MR arthrography

- Anterolateral approach
- Inject 12-15 cc of 1:200 Gd-DTPA
- 3 planes of imaging with T1 fat-sat
- Coronal IR or T2-w FSE



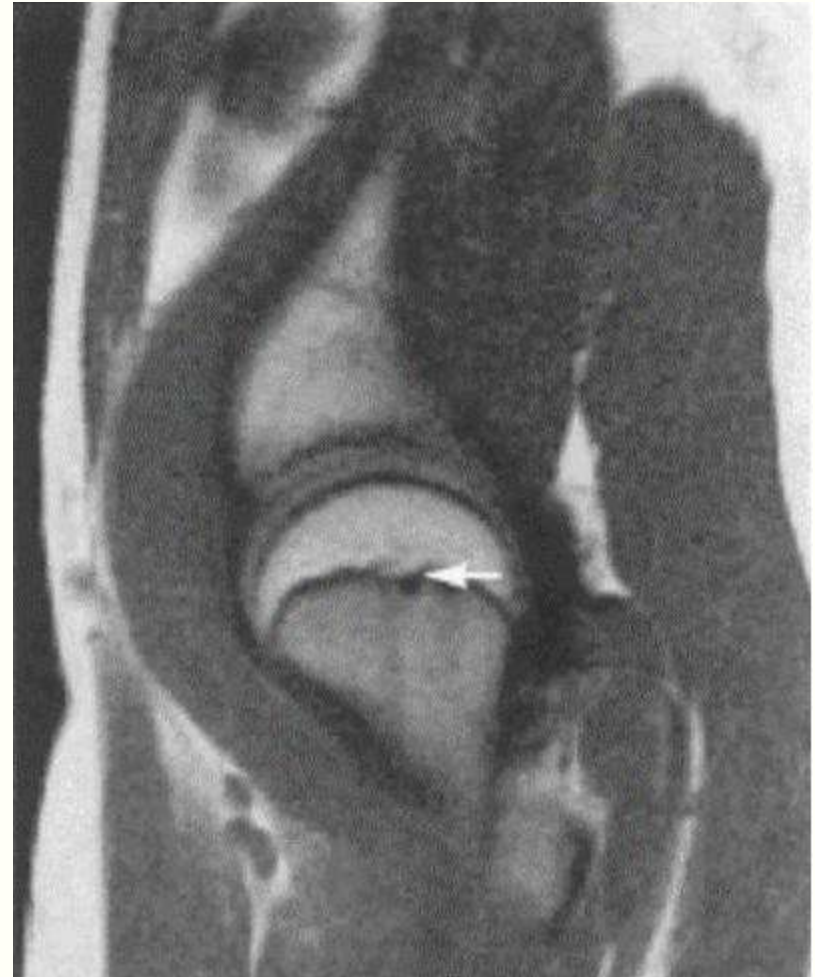Normal variants

- Epiphyseal scar
- Synovial herniation pit
- Fovea
- Trabecular bands
- Intertrochanteric marrow



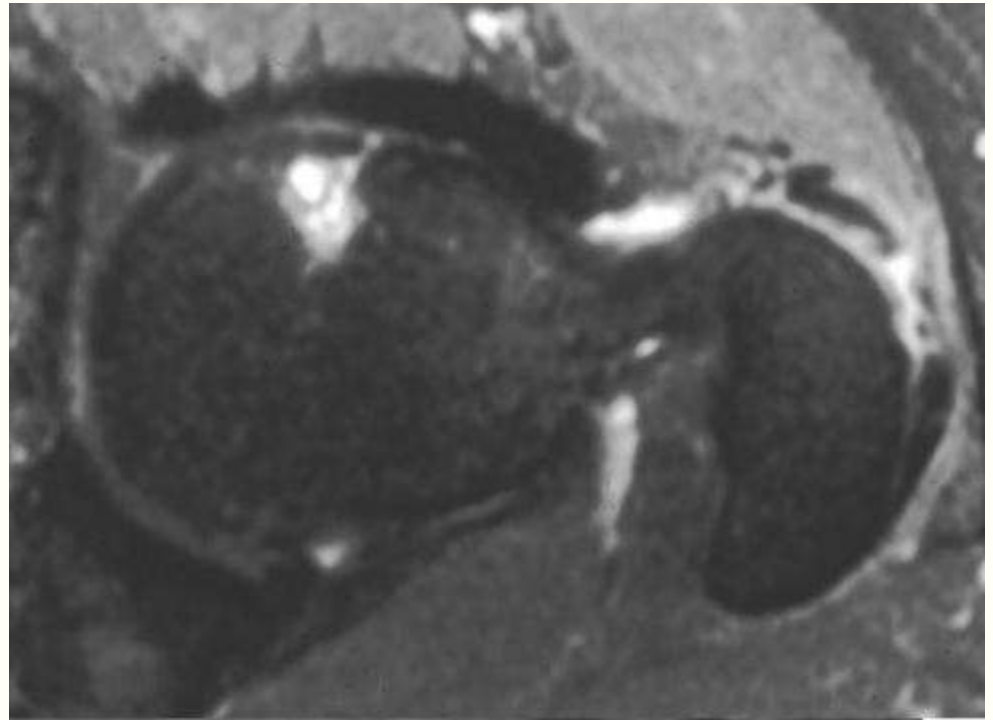
Physeal scar

- Normal finding, can be present at all ages
- Normal remnant of epiphyseal line
- Crescentic low density band at head-neck junction



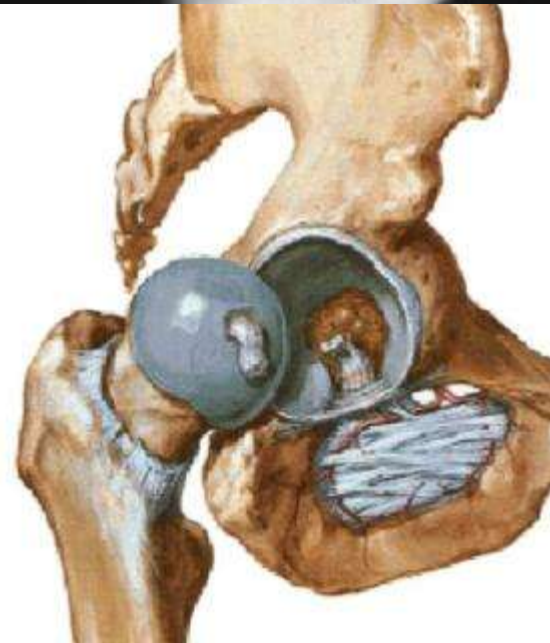
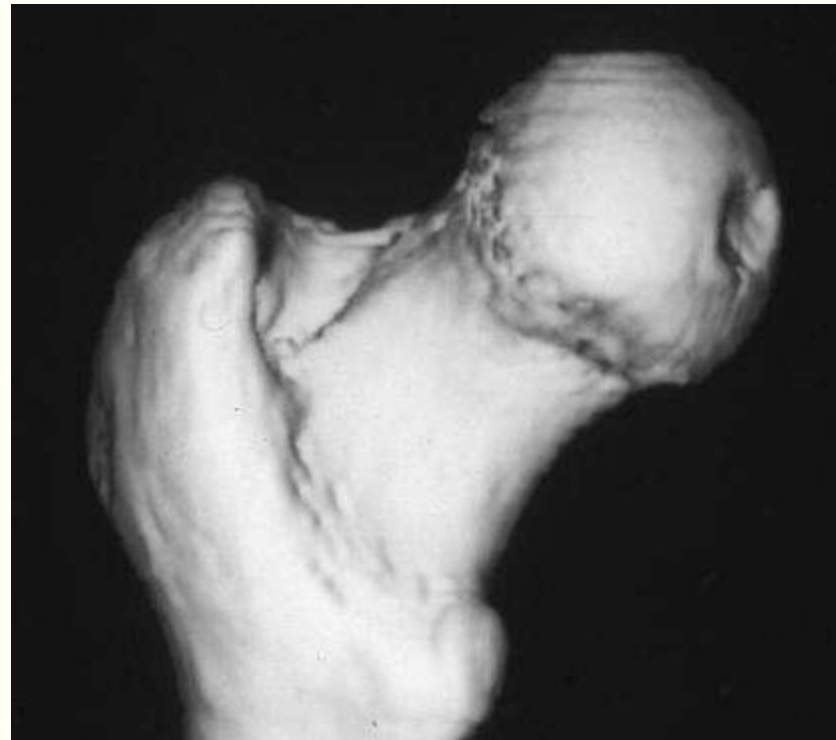
Synovial herniation pit

- 1-2 cm
- Round or oval lytic lesion
- Anterior femoral neck



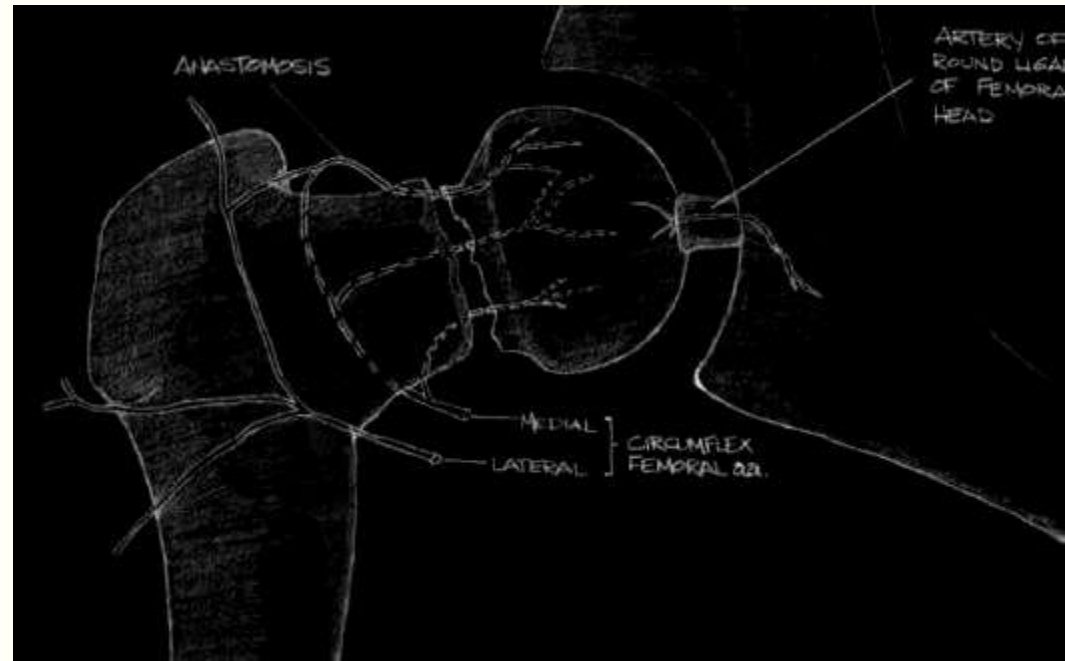
Fovea

- Depression on central surface of the femoral head
- Devoid of cartilage
- Ligamentum teres femoris arises from this depression



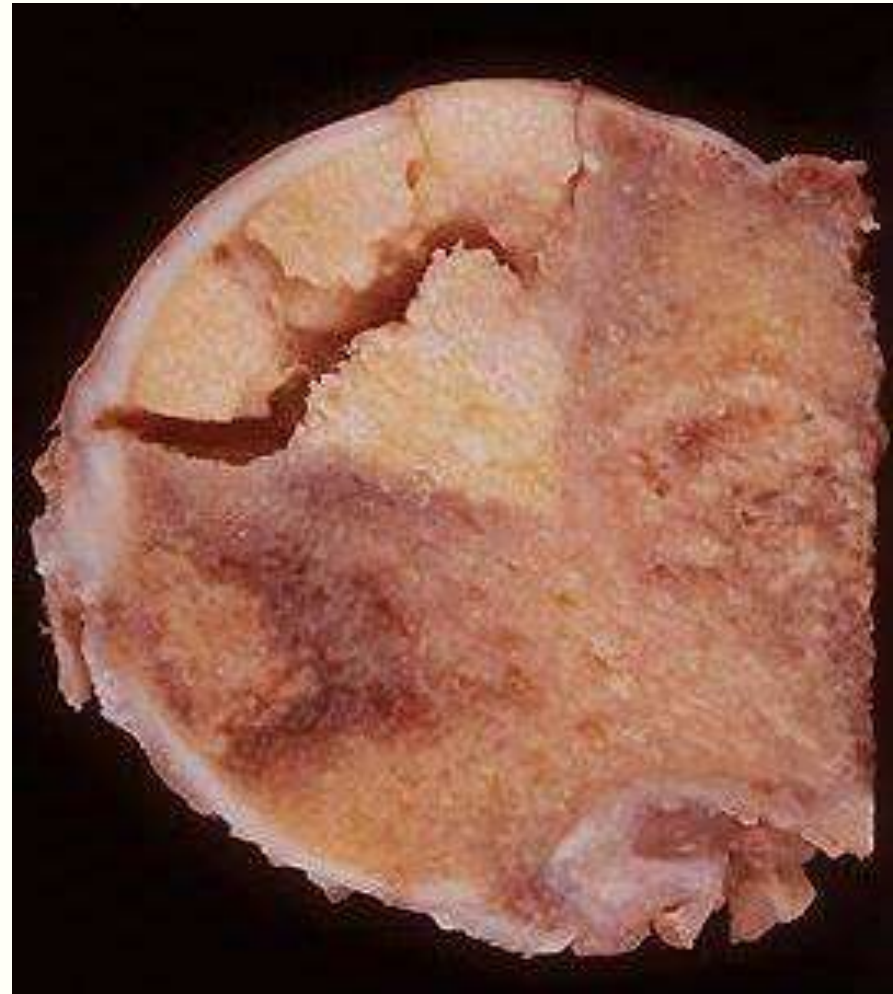Avascular necrosis (AVN)

- Avascular necrosis
- Aseptic necrosis
- Osteonecrosis
- Ischemic necrosis
- Bone infarction



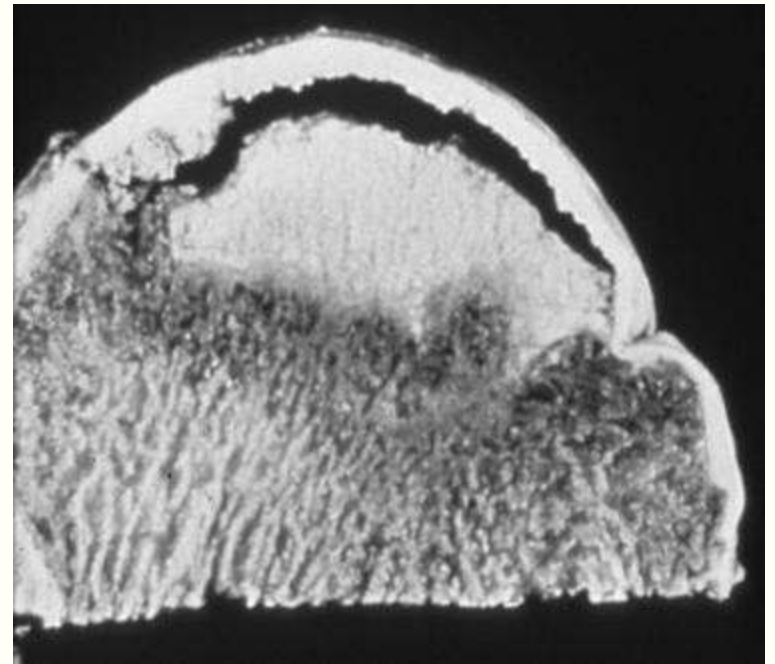
Stages of AVN

- Cell death
 - Hematopoietic < Fat
 - < Mesenchymal
- Cell proliferation adjacent to necrosis
- Revascularization and resorption of necrotic segment
- Reossification by creeping substitution



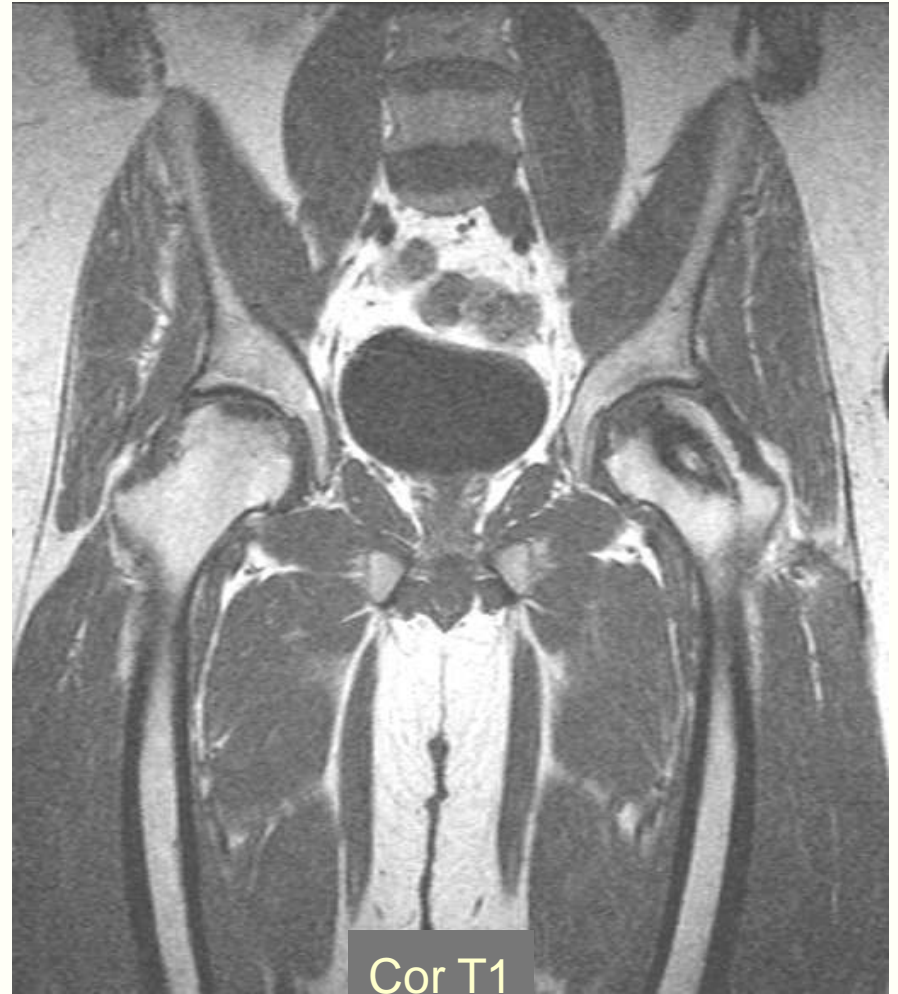
Arlet-Ficat staging

Stage	
1	Normal radiographs
2	Lysis and sclerosis
3	Subchondral fracture
4	Collapse
5	Secondary osteoarthritis

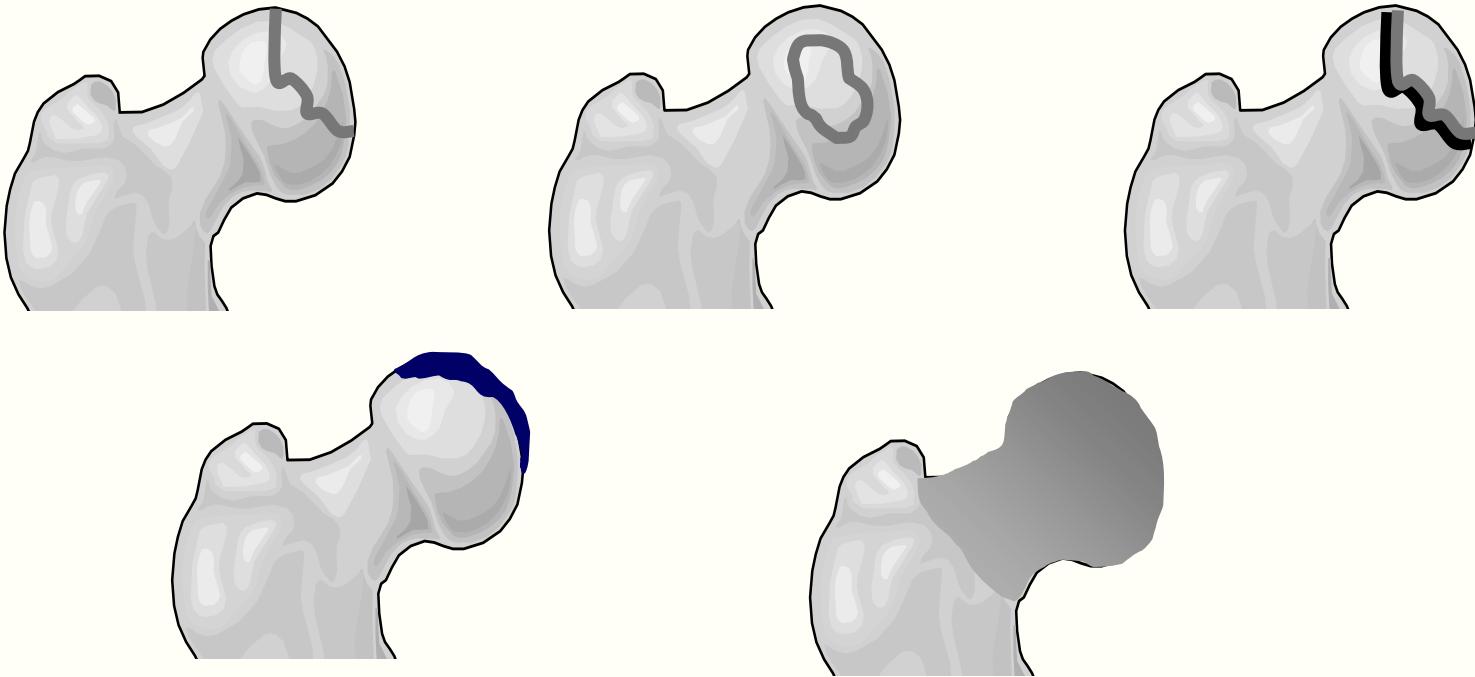


AVN

- MR is the most sensitive method for noninvasive early detection
- Controversy about need for early detection
- Early therapeutic options limited



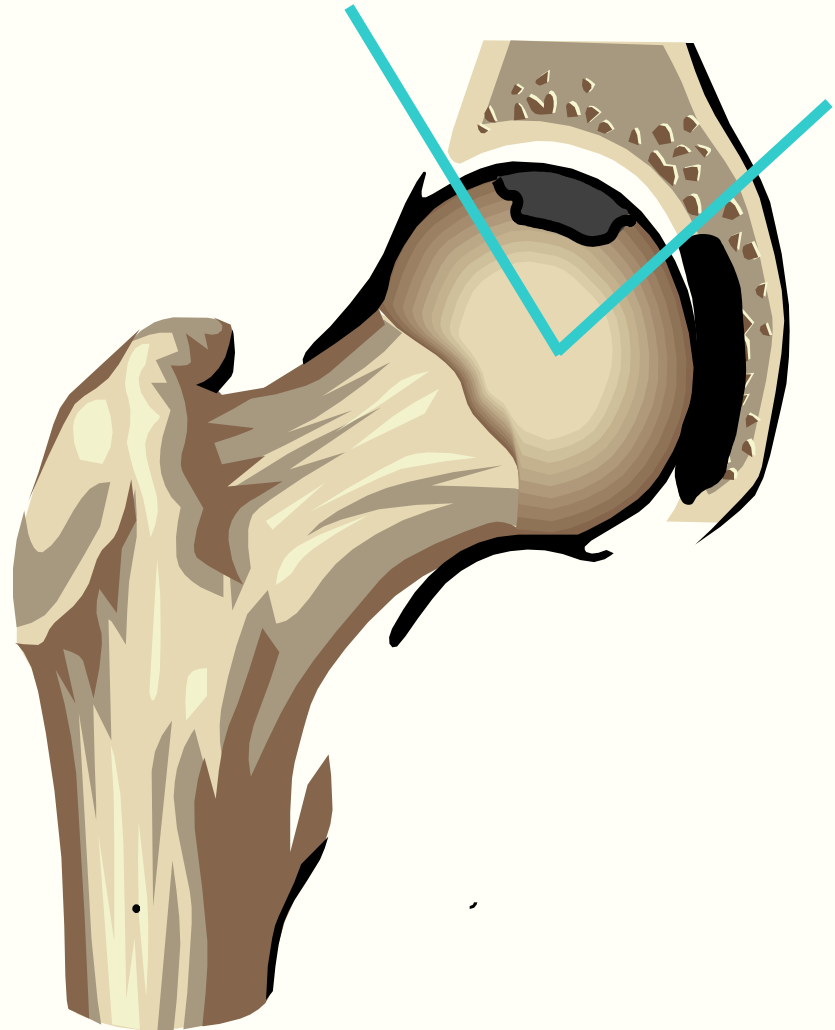
Avascular necrosis



- Line, band or ring of low signal
- Double-line sign
- Deformity
- Marrow edema

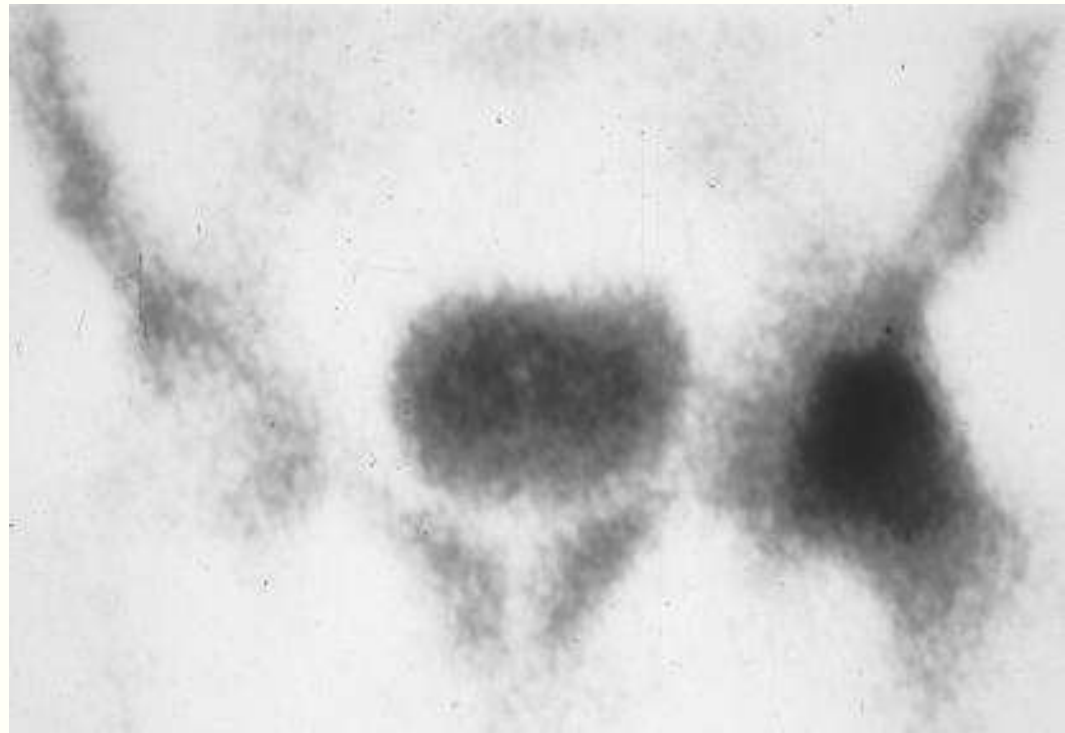
AVN

- Extent of disease used to predict likelihood of collapse
- Coronal image
- Extent of weight-bearing surface involved



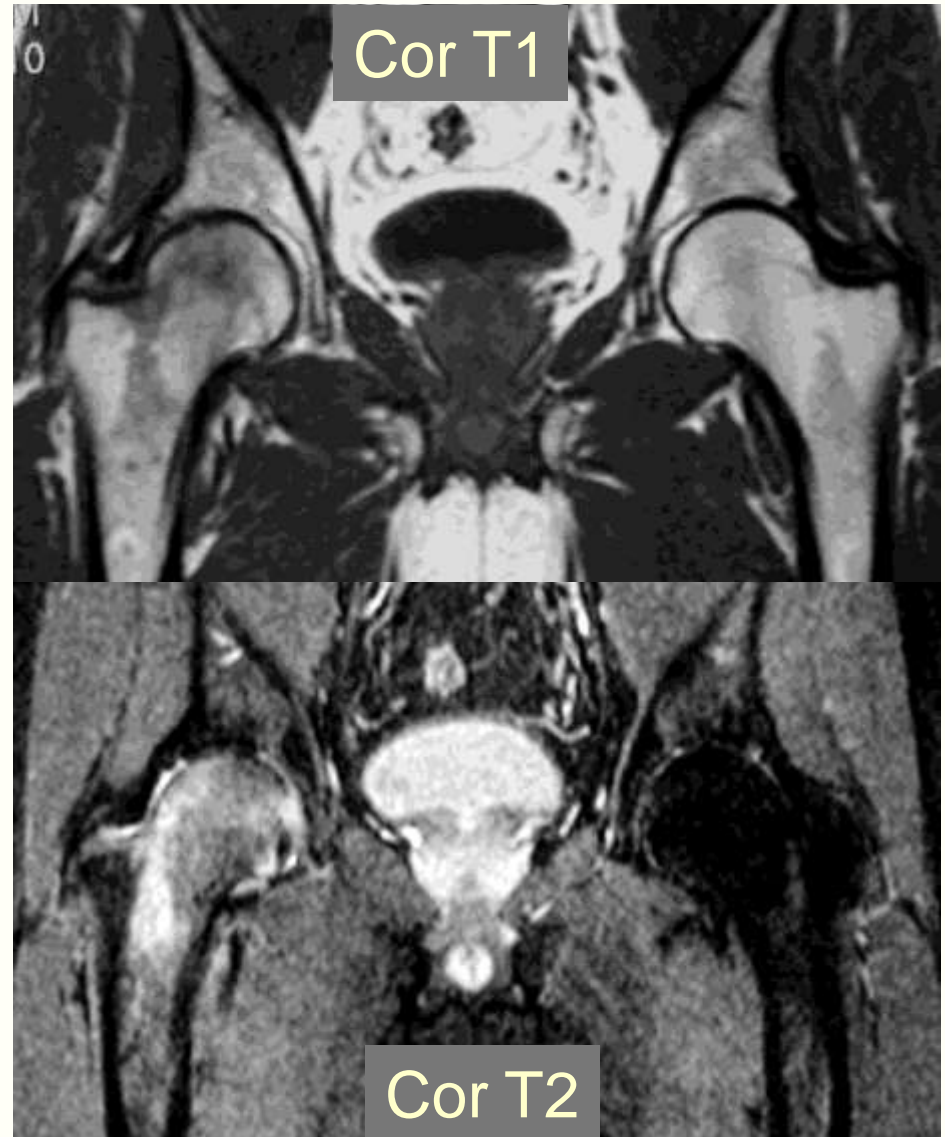Idiopathic bone marrow edema

- Middle-aged, male predominance
- Last trimester of pregnancy
- Left hip involved in 2/3 of cases
- Unknown etiology
- Self-limited



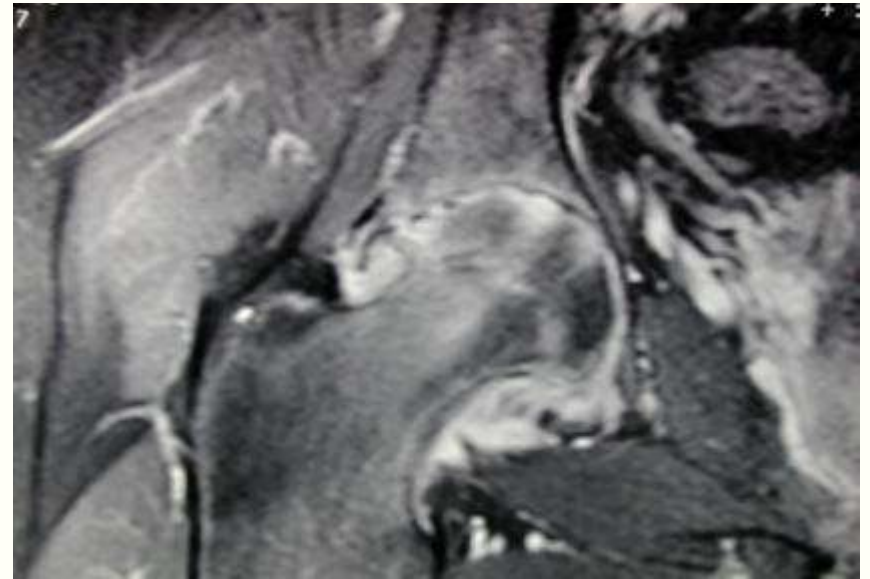
Idiopathic marrow edema

- Geographic signal loss on T1w in femoral head and neck
- Signal loss extends to intertrochanteric line
- High signal on T2w and STIR
- No arcuate or linear bands of low signal
- No deformity



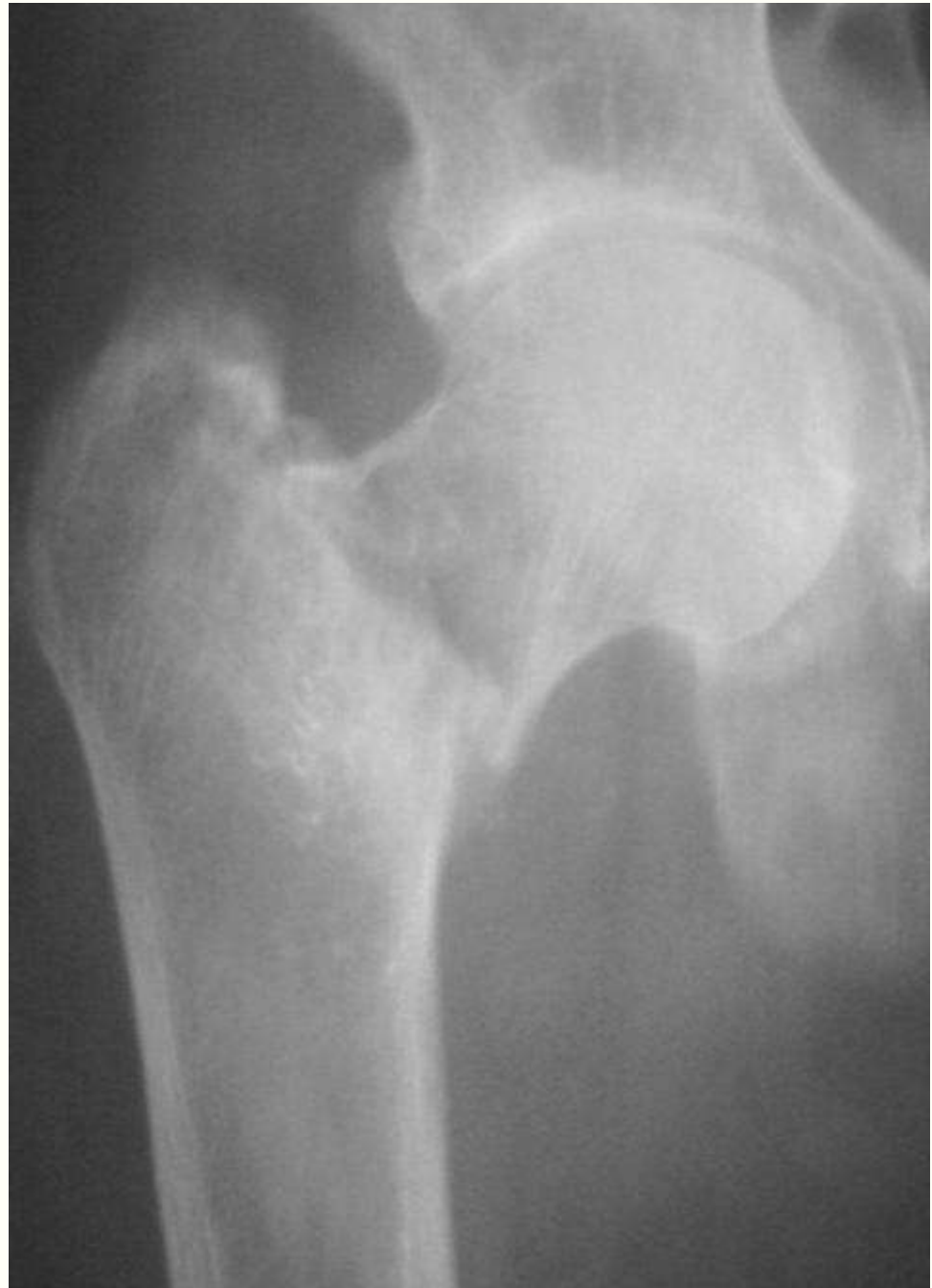Edema: differential diagnosis

- Very early avascular necrosis
- Osteomyelitis
- Osteoarthritis
- Stress fracture

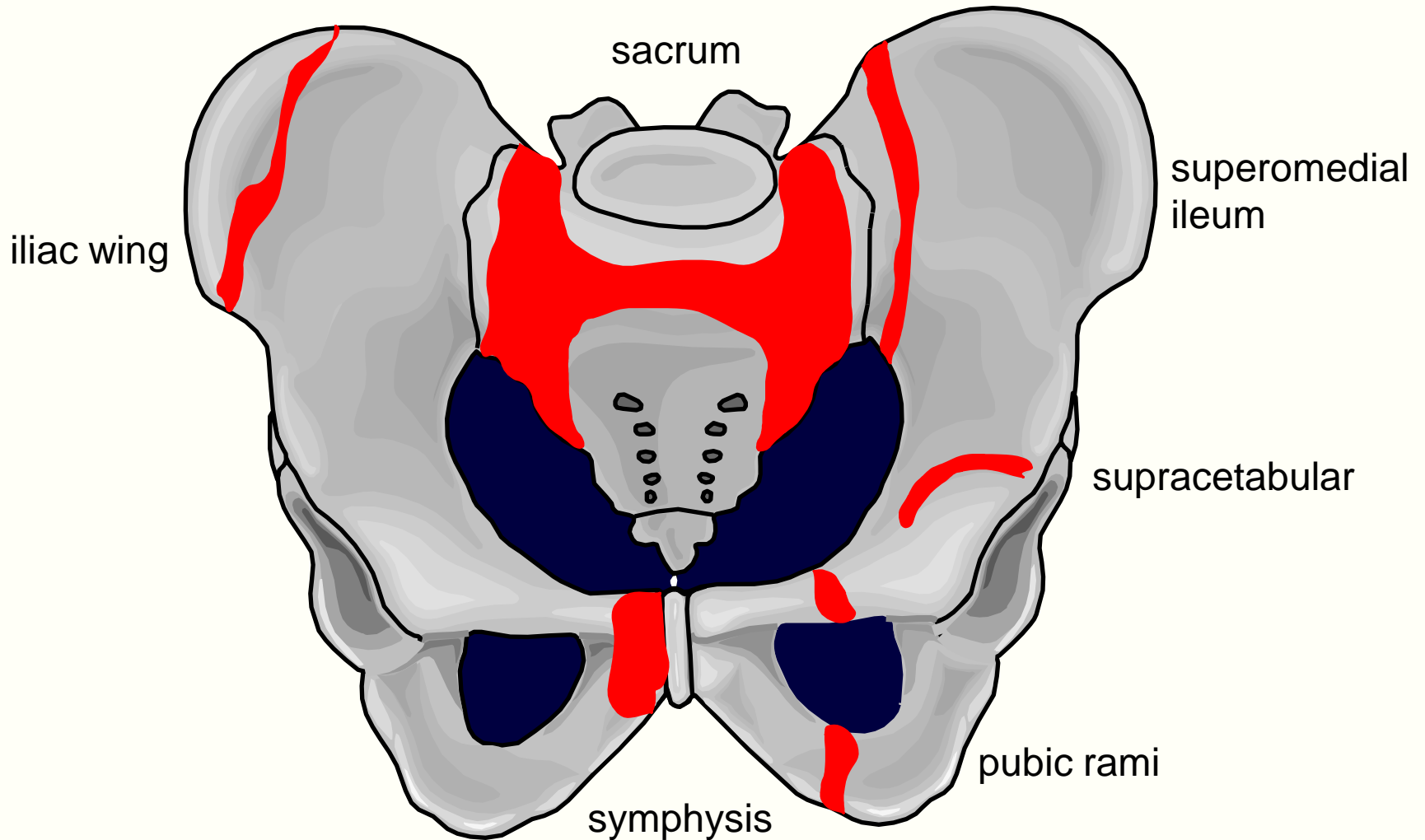


Pelvic trauma

- Stress fracture
 - Fatigue
 - Insufficiency
- Occult fracture
- Soft tissue injury

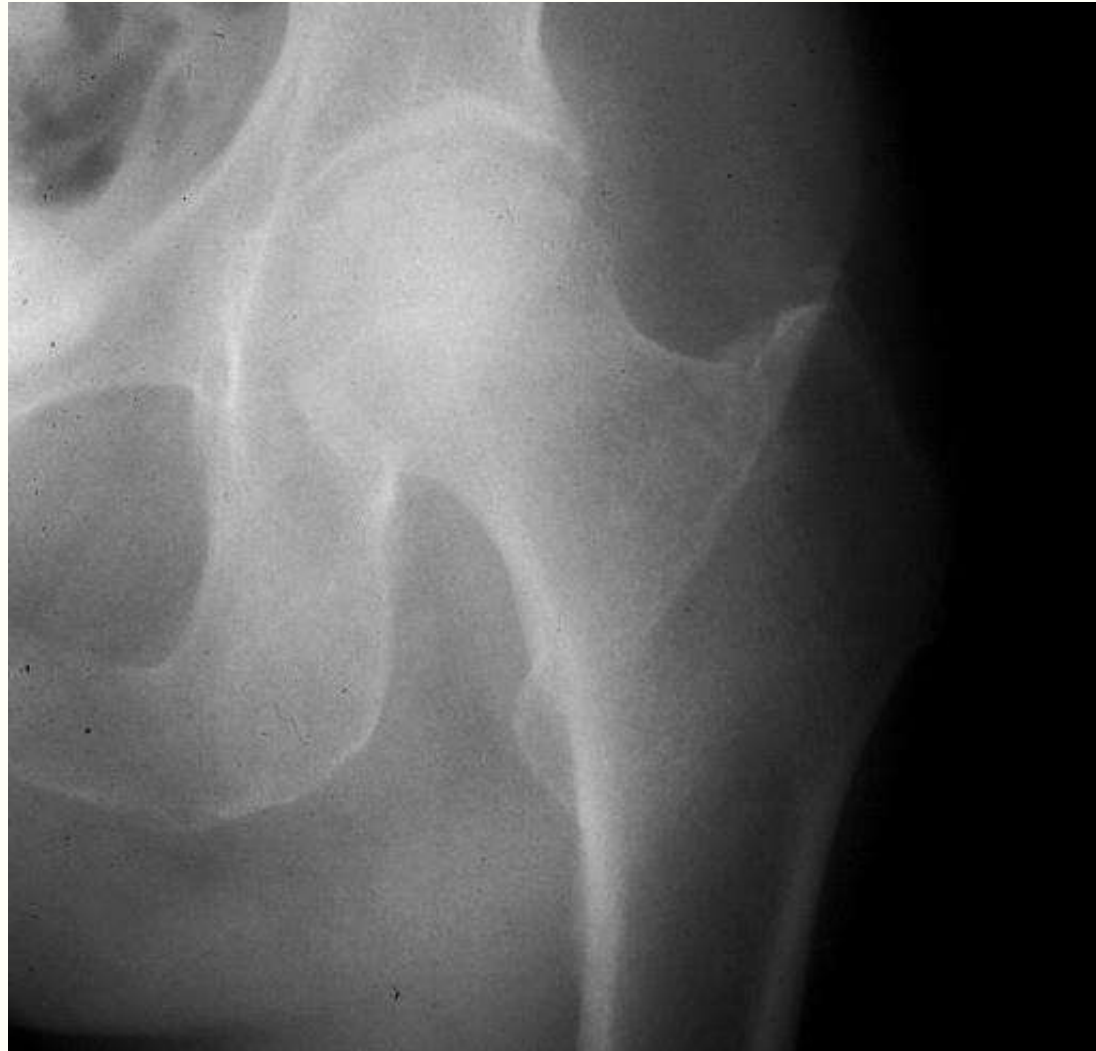

Insufficiency fractures



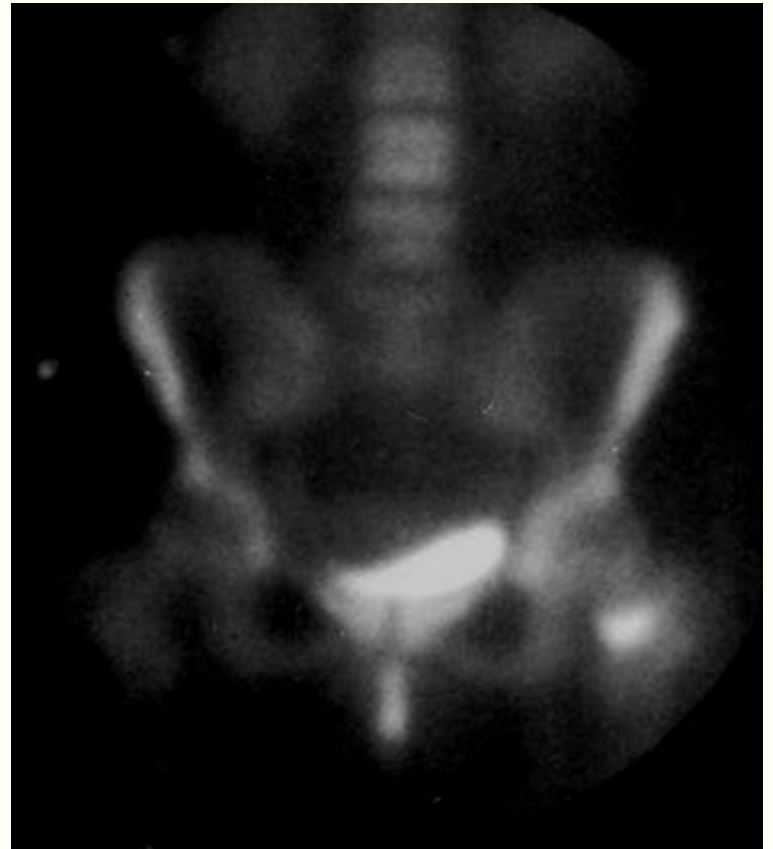MR of occult fracture

- Normal or equivocal radiographs
- High clinical suspicion
- Major weight-bearing region



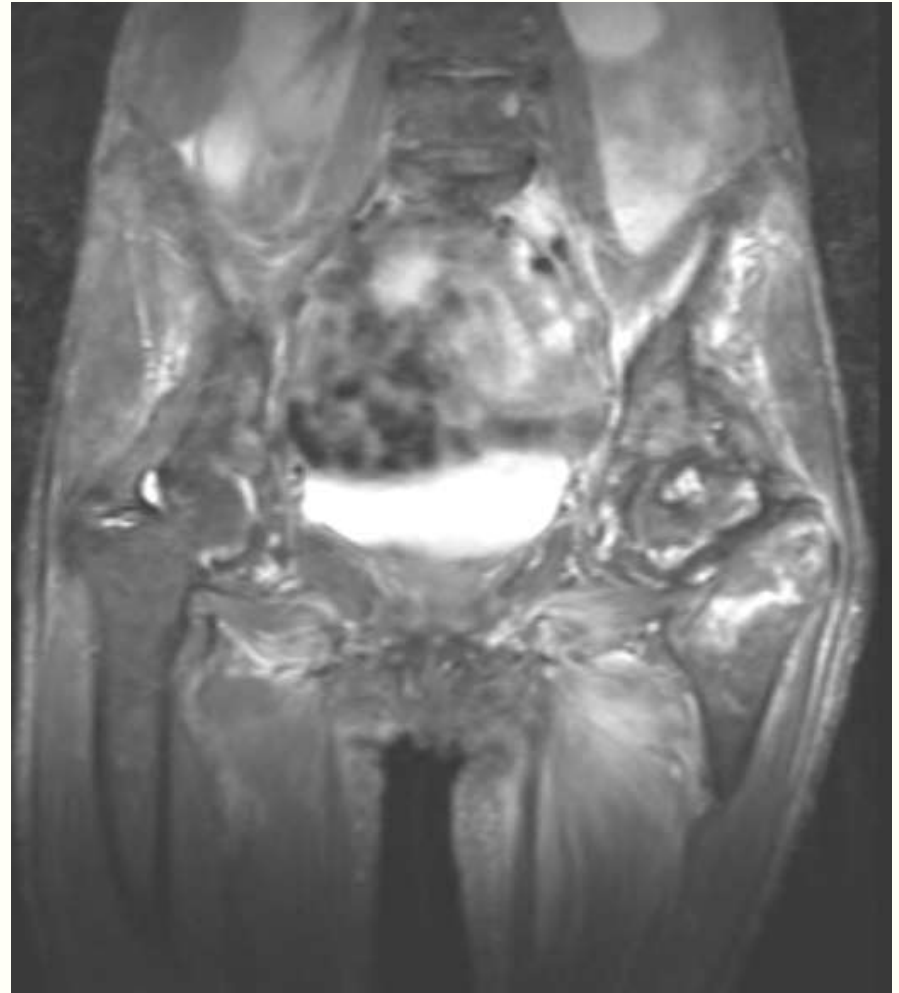
Occult fracture

- Additional radiographs
- Fluoroscopy
- Scintigraphy
- Conventional tomography
- Computed tomography
- Magnetic resonance imaging



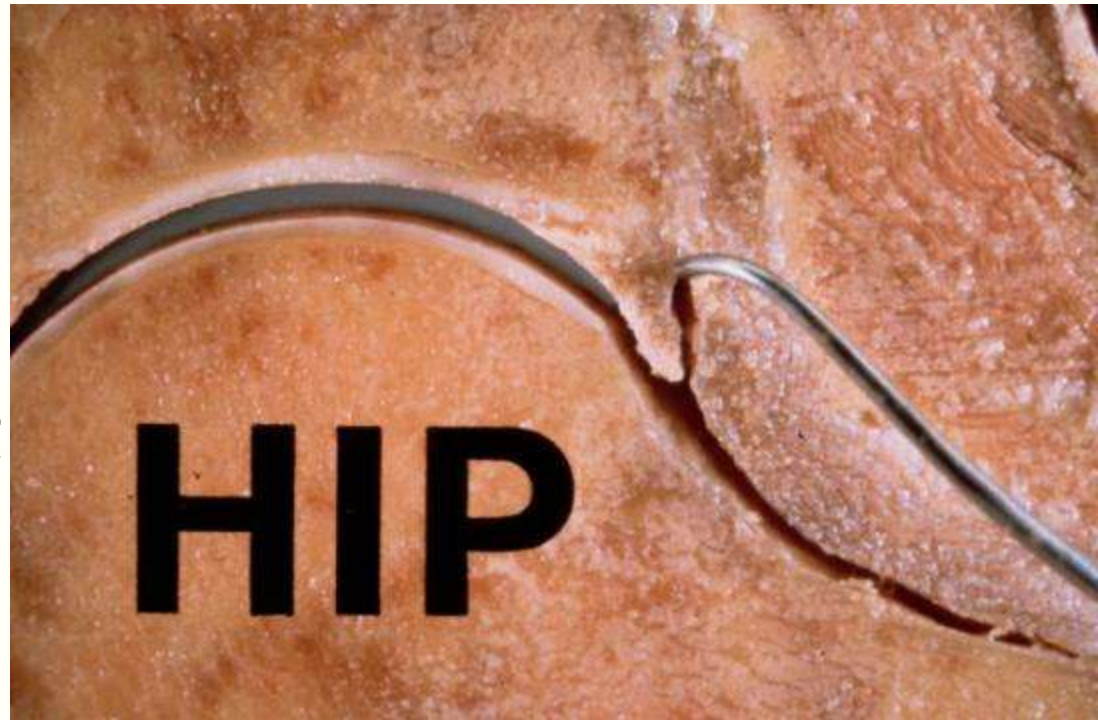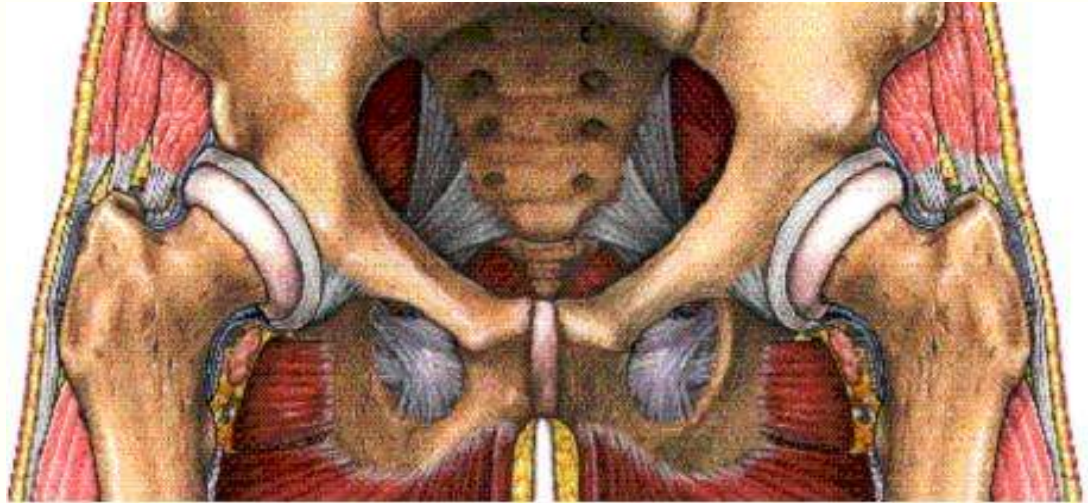MR of occult fractures

- Coronal STIR of entire pelvis
- Smaller FOV images of injured area
 - T1 (or PD FSE)
- Entire study less than 15 minutes



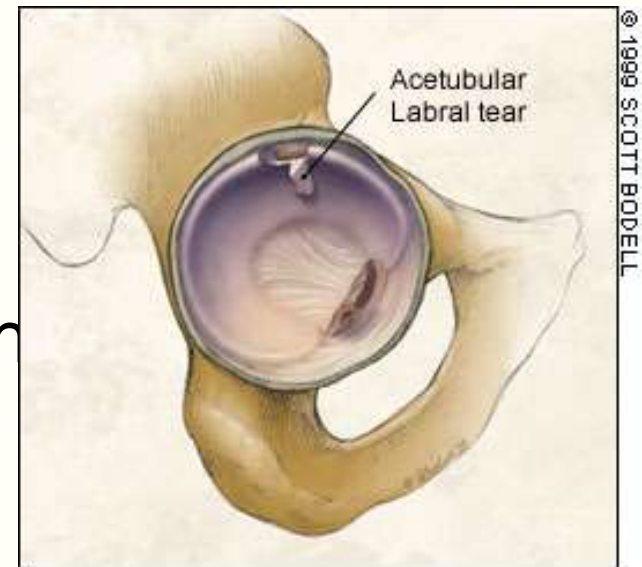
Labrum

- Attached directly to osseous rim
- Triangular, thickest posterosuperiorly
- Blends with transverse ligament at acetabular notch



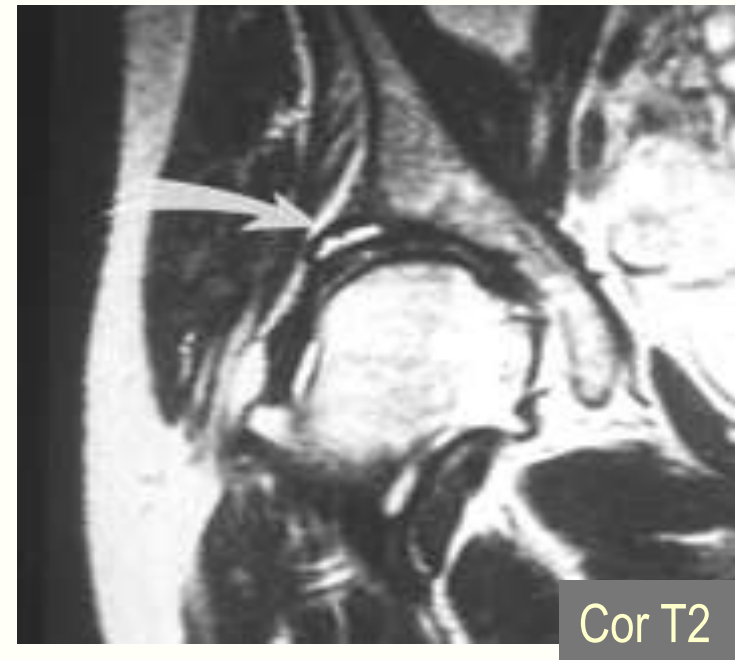
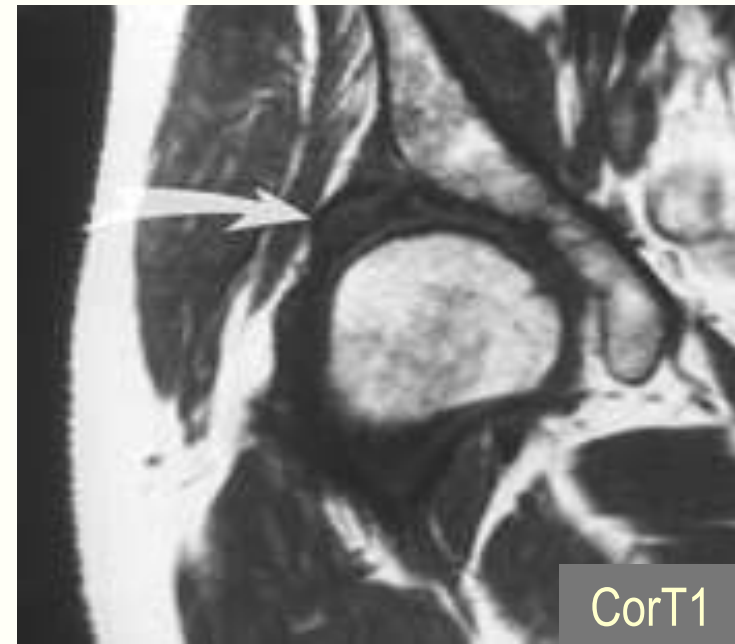
Labral tears

- Traumatic or degenerative
- Pain, locking or premature osteoarthritis
- Higher incidence in patients with hip dysplasia
- Associated with supracetabular ganglion



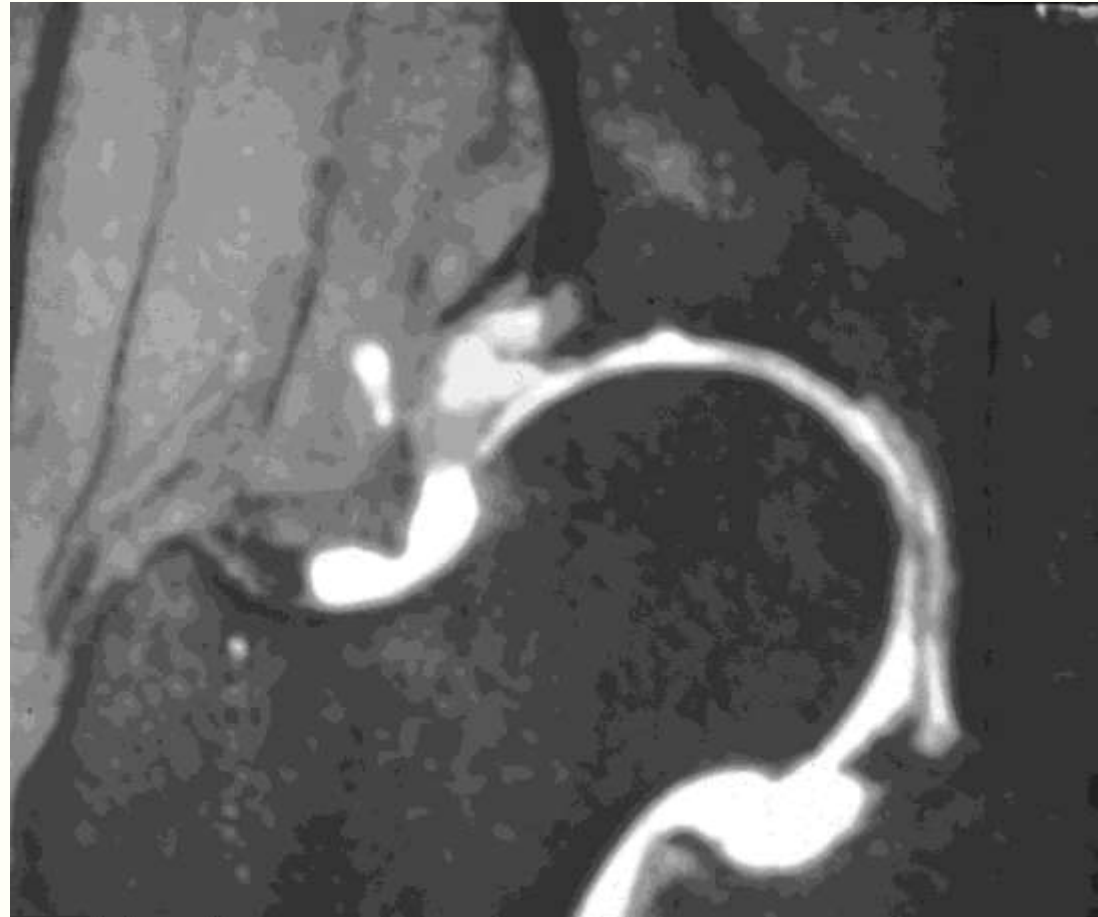
Labral tear

- T1 images only show swelling of labrum
- T2 images show high signal in labrum
- MR arthrography most accurate



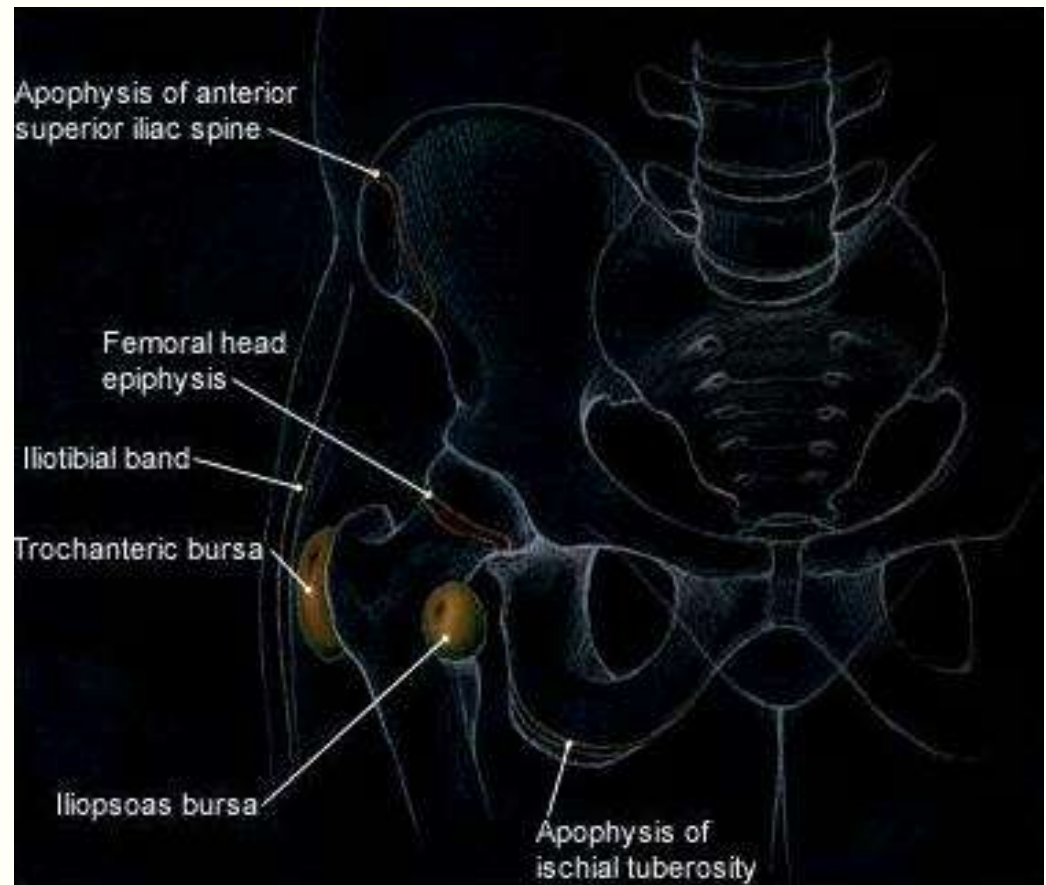
Supracetabular ganglion

- Benign cystic lesion in acetabular roof or soft tissue lateral to labrum
- May contain gas, may erode bone
- Associated with hip dysplasia and labral tears



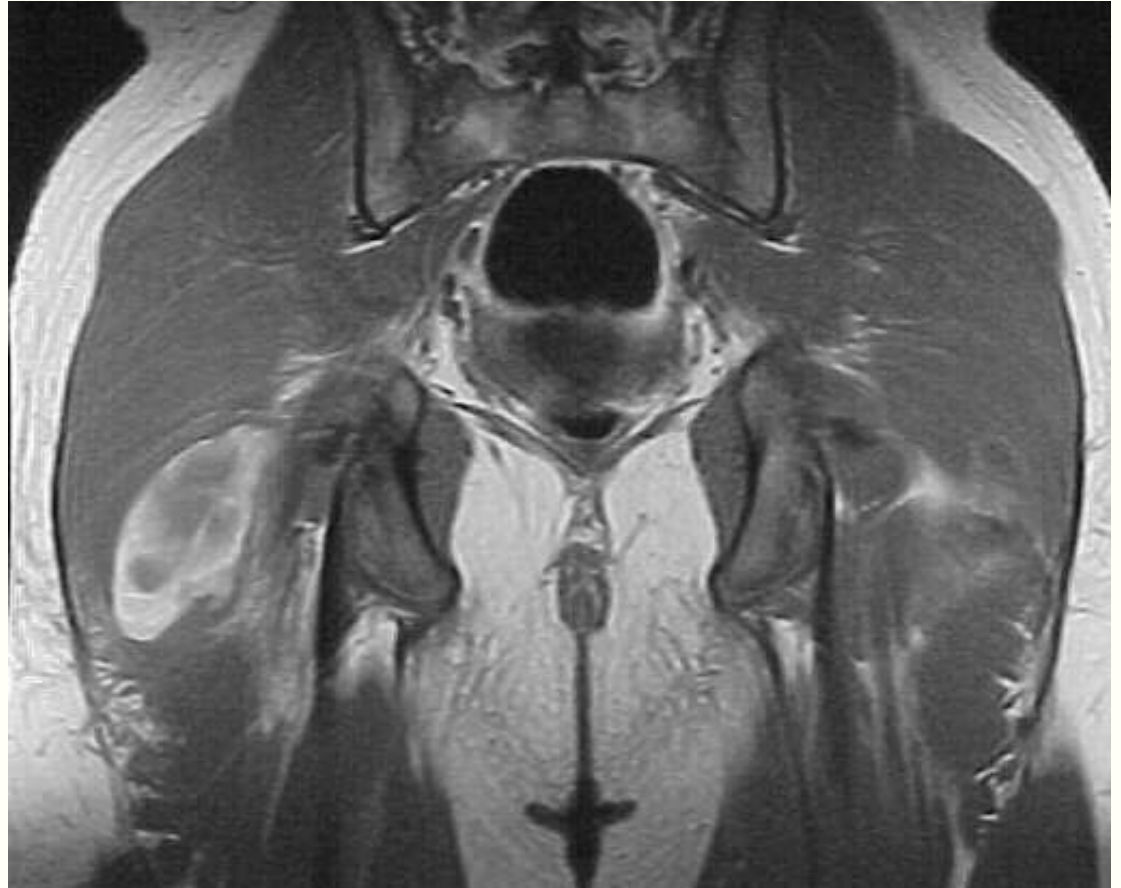Bursal anatomy

- Communicating bursae
 - Iliopsoas
- Noncommunicating bursae
 - Trochanteric
 - Subgluteal



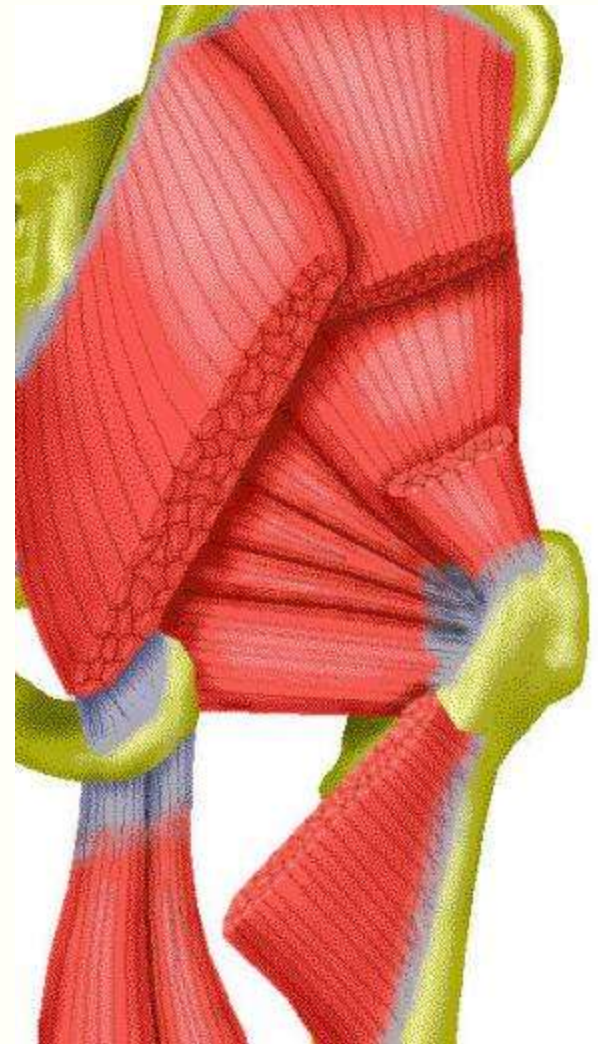
Soft tissue injury

- Muscle strain
- Hematoma
- Tendon tear

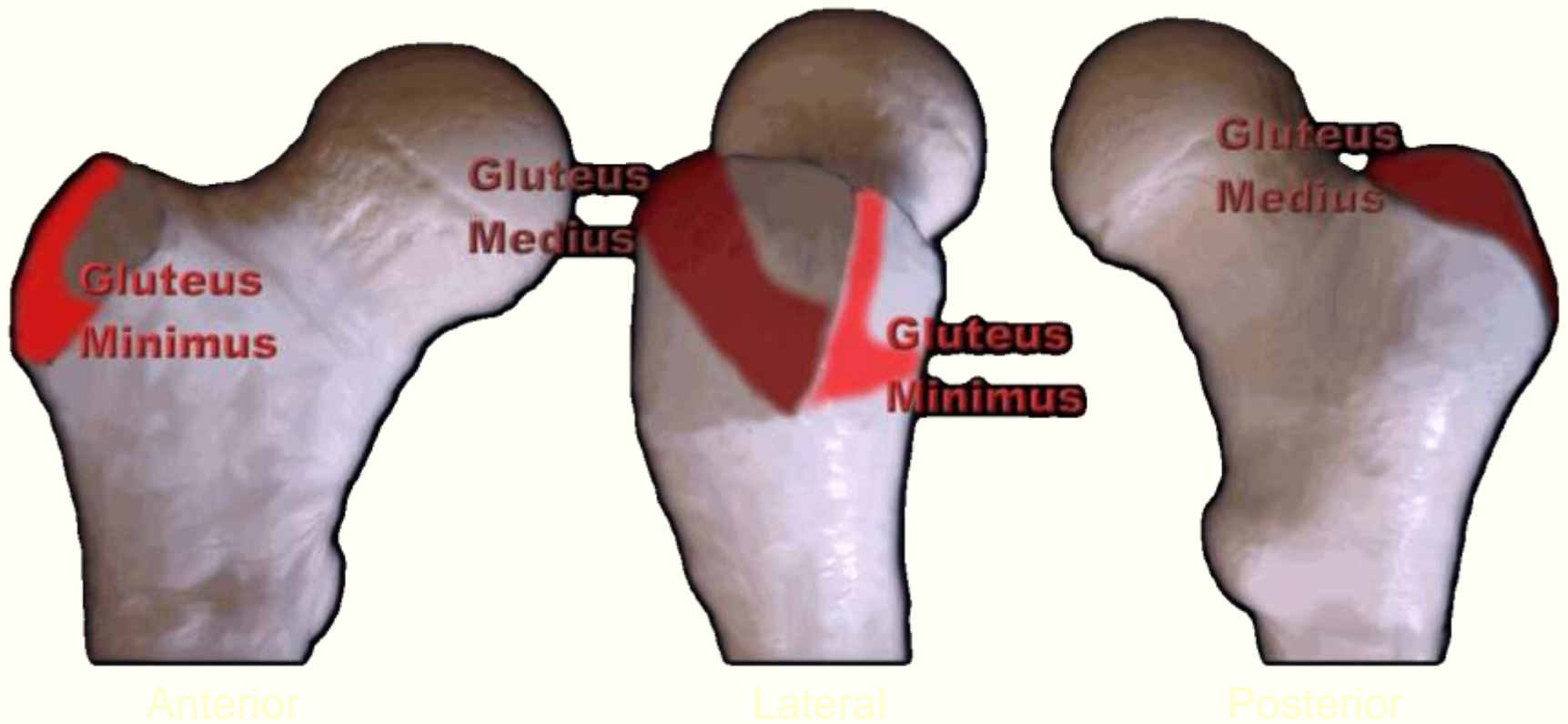


Myotendinous avulsions

- Greater trochanter
 - Gluteus medius
 - Gluteus minimus
- Ischium
 - Hamstrings

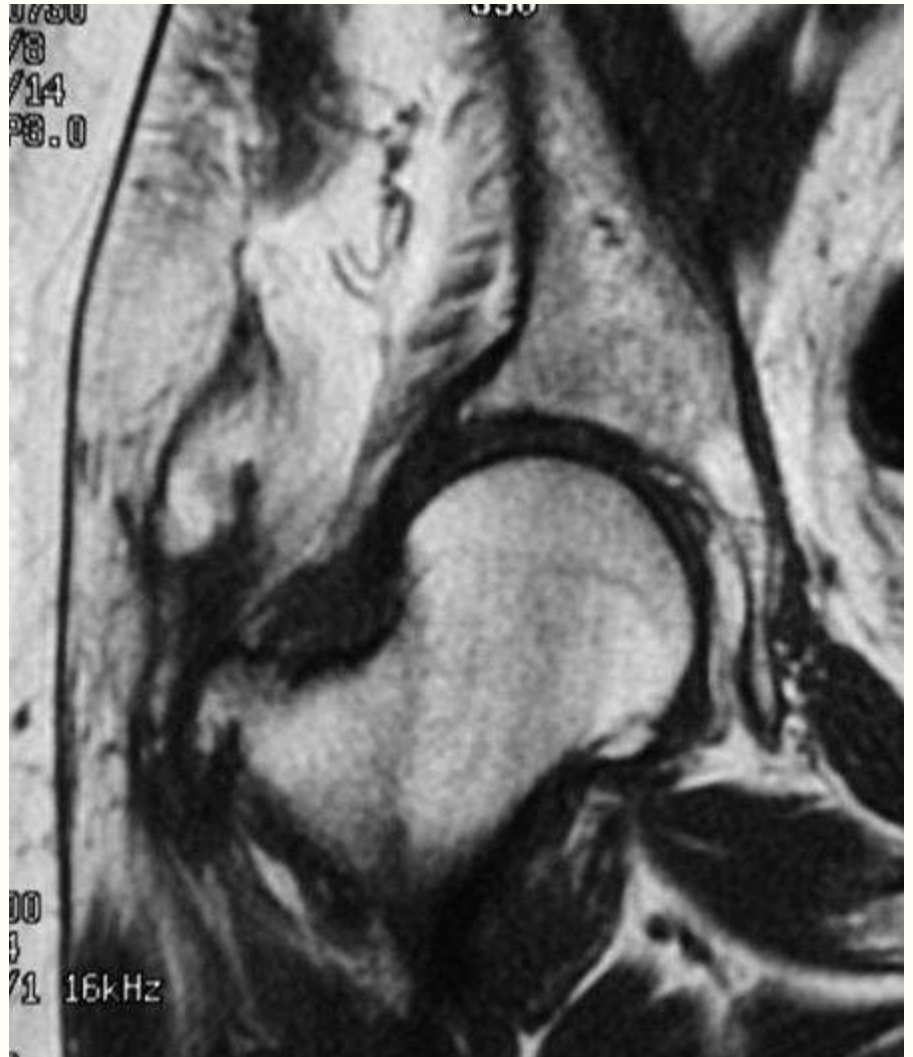


Gluteal attachments



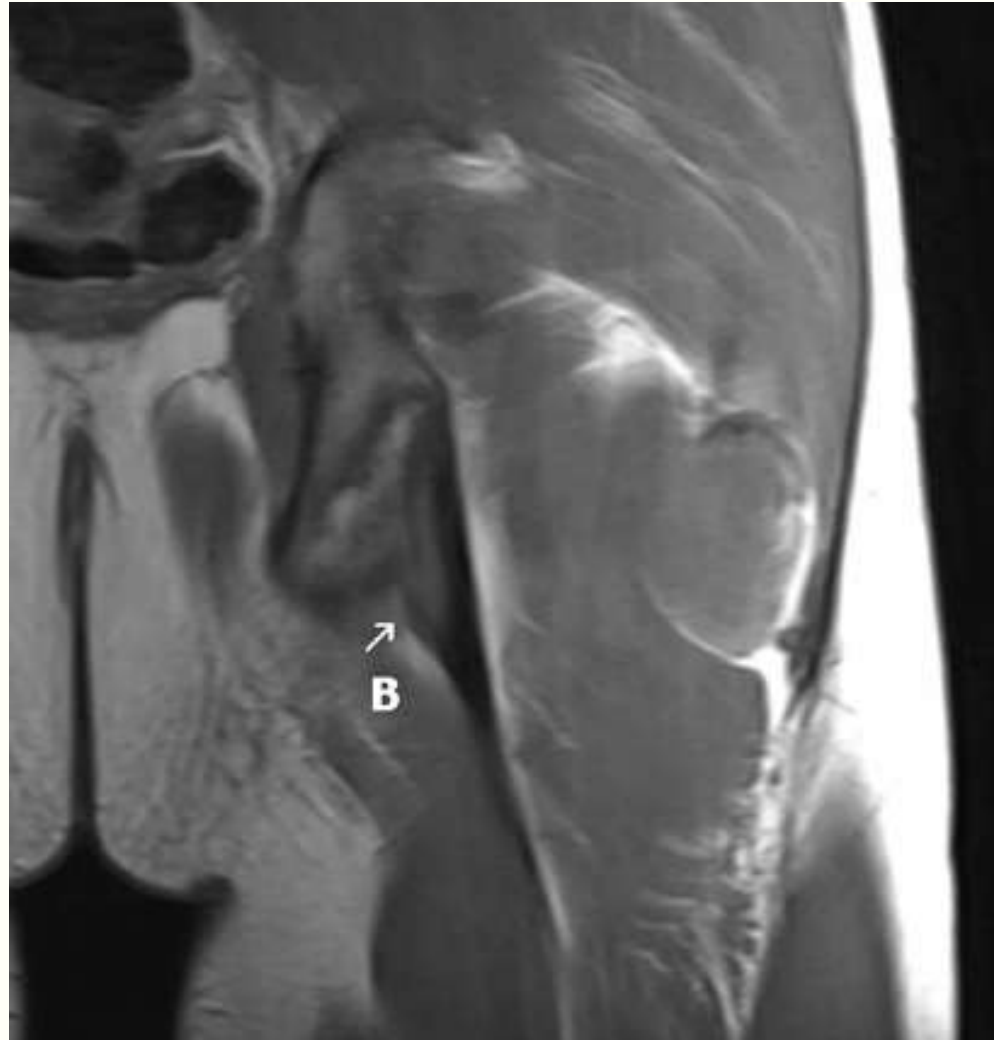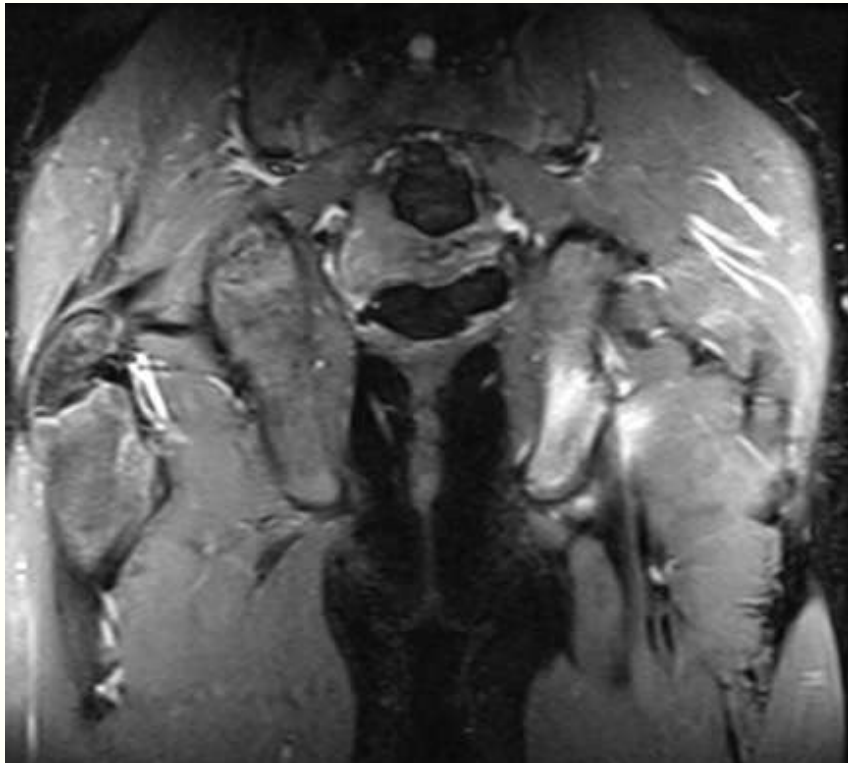
Gluteal tendon tear

- Elderly
- Tear of gluteus medius or minimus tendon
- “Rotator cuff tear of the hip”



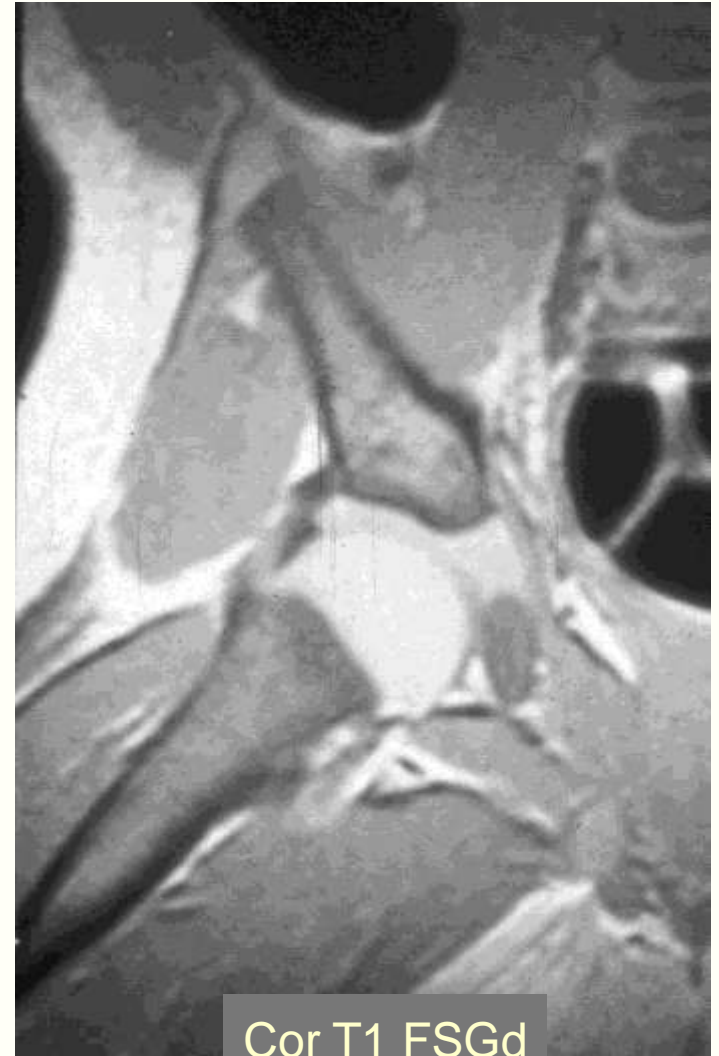Hamstring avulsion

- Young athlete
- Elderly patient



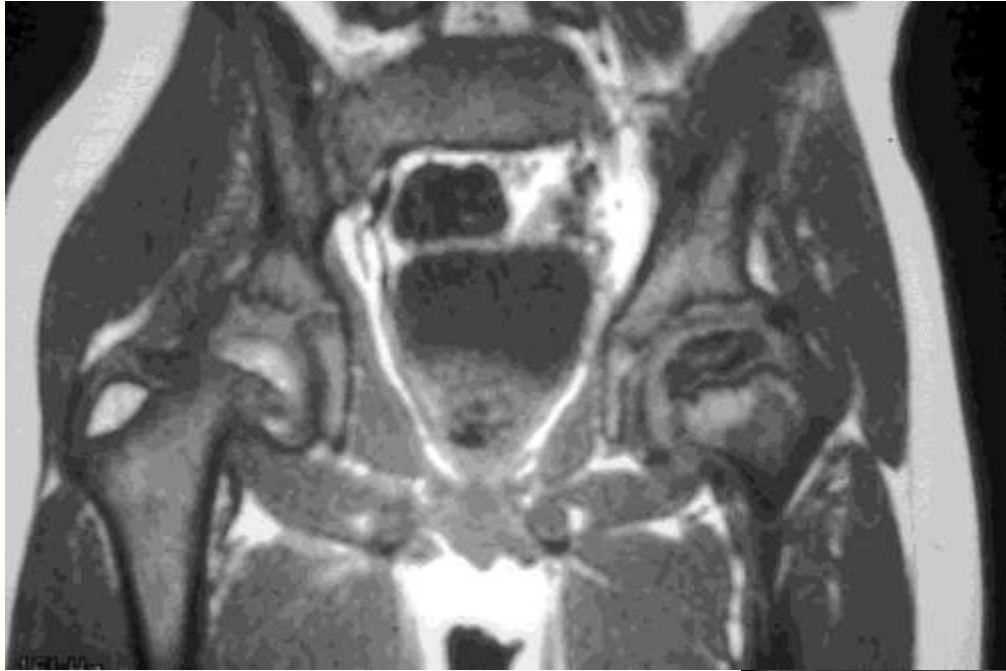Pediatric hip disorders

- Developmental dysplasia
- Proximal focal femoral deficiency
- Transient synovitis
- Legg-Calve-Perthe's disease
- Slipped capital femoral epiphysis



Cor T1 FSGd

Legg-Calvé-Perthes disease



- Idiopathic necrosis of femoral head in children
- Ages 4-7

